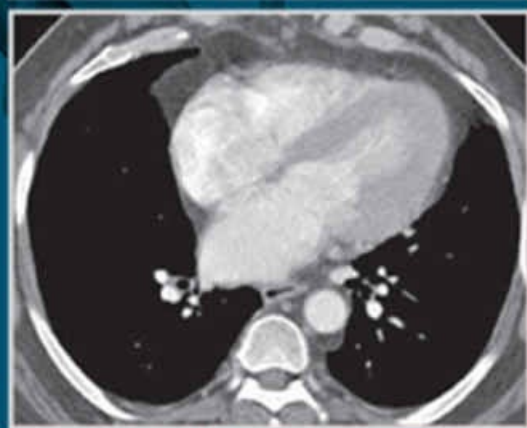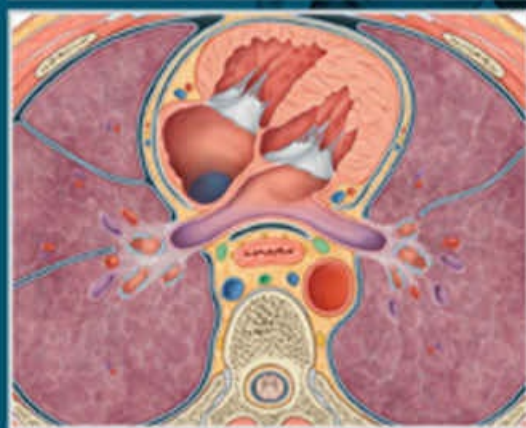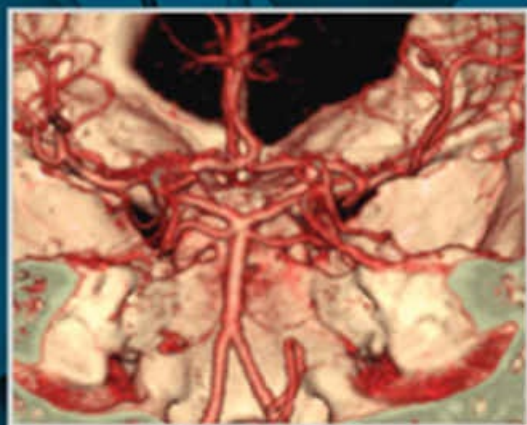


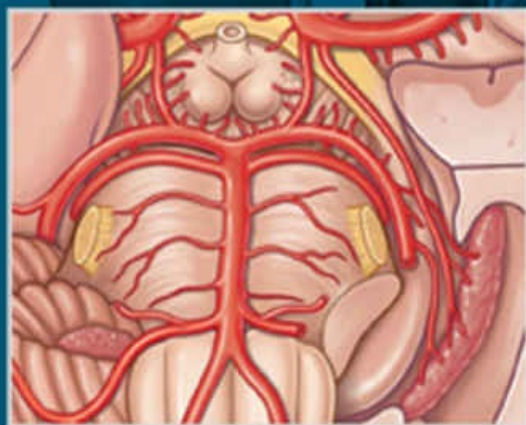

Enhanced  
**DIGITAL  
VERSION**  
Included

# GRAY'S ATLAS OF ANATOMY



**Richard L. Drake   A. Wayne Vogl   Adam W.M. Mitchell**  
**Richard M. Tibbitts   Paul E. Richardson**



Third Edition



مدیسکا  
*Medisca*

Telegram : @Meddisca

# GRAY'S ATLAS OF ANATOMY

---

THIRD EDITION

*Richard L. Drake, PhD, FAAA*

*Director of Anatomy, Professor of Surgery, Cleveland Clinic Lerner College of Medicine, Case Western Reserve University, Cleveland, Ohio, USA*

*A. Wayne Vogl, PhD, FAAA*

*Professor of Anatomy and Cell Biology, Department of Cellular and Physiological Sciences, Faculty of Medicine, University of British Columbia, Vancouver, British Columbia, Canada*

*Adam W.M. Mitchell, MBBS, FRCS, FRCR*

*Consultant Radiologist and Senior Lecturer Imperial College, Chelsea and Westminster Hospital, London, UK*

***Illustrated by***

*Richard M. Tibbitts*

*Saffron Walden, UK*

*Paul E. Richardson*

*Cambridge, UK*

*Photographs by*

Ansell Horn



**ELSEVIER**

---

# Table of Contents

---

Cover image

Title page

Copyright

Dedication

ACKNOWLEDGMENTS

FOREWORD

FOREWORD

PREFACE

Chapter 1: THE BODY

Anatomical position, terms, and planes

Anatomical planes and imaging

Surface anatomy: anterior view

Surface anatomy: posterior view

Skeleton: anterior

Skeleton: posterior

Muscles: anterior

Muscles: posterior

Vascular system: arteries

Vascular system: veins

Lymphatic system

Nervous system

Sympathetics

Parasympathetics

Dermatomes

Cutaneous nerves

## Chapter 2: BACK

Surface anatomy

Vertebral column

Regional vertebrae

Cervical vertebrae

Thoracic vertebrae

Lumbar vertebrae

Sacrum

Intervertebral foramina and discs

Intervertebral disc problems

Joints and ligaments

Back musculature: surface anatomy

Superficial musculature

Intermediate musculature

Deep musculature

Back musculature: transverse section

Suboccipital region

Spinal nerves

Spinal cord

Spinal cord vasculature

Venous drainage of spinal cord

Meninges

Spinal cord: imaging

Transverse section: thoracic region

Dermatomes and cutaneous nerves

Tables

## Chapter 3: THORAX

Surface anatomy with bones

Bony framework

Ribs

Articulations

Breast



Pectoral region

Thoracic wall muscles

Diaphragm

Arteries of the thoracic wall

Veins of the thoracic wall

Nerves of the thoracic wall

Lymphatics of the thoracic wall

Intercostal nerves and arteries

Pleural cavities and mediastinum

Parietal pleura

Surface projections of pleural recesses

Right lung

Left lung

Lung lobes: surface relationship

Lung lobes: imaging

Bronchial tree

Bronchopulmonary segments

Pulmonary vessels and plexus

Pulmonary vessels: imaging

Mediastinum

Pericardium

Pericardial layers

Anterior surface of heart

Base and diaphragmatic surface of heart

Right atrium

Right ventricle

Left atrium

Left ventricle

Aortic valve and cardiac skeleton

Cardiac chambers and heart valves

Coronary vessels

Coronary arteries and variations

Cardiac conduction system

Auscultation points and heart sounds

Cardiac innervation

Superior mediastinum: thymus

Superior mediastinum: veins and arteries

Superior mediastinum: arteries and nerves

Superior mediastinum: imaging

Superior mediastinum: veins and trachea

Mediastinum: imaging

Mediastinum: view from right

Mediastinum: imaging – view from right

Mediastinum: view from left

Mediastinum: imaging – view from left

Posterior mediastinum

Mediastinum: imaging

Transverse section: TVIII level

Dermatomes and cutaneous nerves

Visceral efferent (motor) innervation of the heart

Visceral afferents

Tables

## Chapter 4: ABDOMEN

Surface anatomy

Quadrants and regions

Abdominal wall

Muscles

Muscles: rectus sheath

Vessels of the abdominal wall

Arteries and lymphatics of the abdominal wall

Nerves of the abdominal wall

Dermatomes and cutaneous nerves

Inguinal region

Inguinal canal in men

Inguinal canal in women

Inguinal hernias

Anterior abdominal wall

Greater omentum

Abdominal viscera

Peritoneal cavity

Abdominal sagittal section

Abdominal coronal section

Arterial supply of viscera

Stomach

Spleen

Arteries of stomach and spleen

Duodenum

Small intestine

Large intestine

Ileocecal junction

Gastrointestinal tract: imaging

Mesenteric arteries

Liver

Vessels of the liver

Segments of the liver

Pancreas and gallbladder

Vasculature of pancreas and duodenum

Venous drainage of viscera

Portosystemic anastomoses

Posterior wall

Vessels of the posterior wall

Diaphragm

Kidneys

Gross structure of kidneys

Kidneys: imaging

Renal vasculature

Branches of the abdominal aorta

Inferior vena cava

Abdominal aorta and inferior vena cava: imaging

Lumbar plexus

Lumbar plexus: cutaneous distribution

Lymphatics

Abdominal innervation

Splanchnic nerves

Visceral efferent (motor) innervation diagram

Visceral afferent (sensory) innervation and referred pain diagram

Kidney and ureter visceral afferent (sensory) diagram

Tables

## Chapter 5: PELVIS AND PERINEUM

Surface anatomy and articulated pelvis in men

Surface anatomy and articulated pelvis in women

Pelvic girdle

Pelvic girdle: imaging

Lumbosacral joint

Sacro-iliac joint

Pelvic inlet and outlet

Orientation of pelvic girdle and pelvic brim

Pelvic viscera and perineum in men

Pelvic viscera and perineum in men: imaging

Pelvic viscera and perineum in women

Pelvic viscera and perineum in women: imaging

Lateral wall of pelvic cavity

Floor of pelvic cavity: pelvic diaphragm

Rectum and bladder in situ

Rectum

Bladder in men

Bladder in women

Reproductive system in men

Prostate

Prostate and seminal vesicles

Scrotum

Testes

Penis

Reproductive system in women

Uterus and ovaries

Uterus

Uterus: imaging

Pelvic fascia

Arterial supply of pelvis

Venous drainage of pelvis

Vasculature of the pelvic viscera

Vasculature of uterus

Venous drainage of prostate and penis

Venous drainage of rectum

Sacral and coccygeal nerve plexuses

Pelvic nerve plexus

Hypogastric plexus

Surface anatomy of the perineum

Borders and ceiling of the perineum

Deep pouch and perineal membrane

Muscles and erectile tissues in men

Erectile tissue in men: imaging

Muscles and erectile tissues in women

Erectile tissue in women: imaging

Internal pudendal artery and vein

Pudendal nerve

Vasculature of perineum

Nerves of perineum

Lymphatics of pelvis and perineum in men

Lymphatics of pelvis and perineum in women

Lymphatics

Dermatomes

Innervation of reproductive system in men

Innervation of reproductive system in women

Innervation of bladder

Pelvic cavity imaging in men

Pelvic cavity imaging in women

Tables



## Chapter 6: LOWER LIMB

Surface anatomy

Bones of the lower limb

Pelvic bones and sacrum

Articulated pelvis

Proximal femur

Hip joint

Hip joint: structure and arterial supply

Gluteal region: attachments and superficial musculature

Gluteal region: superficial and deep muscles

Gluteal region: arteries and nerves

Distal femur and proximal tibia and fibula

Thigh: muscle attachments

Thigh: anterior superficial musculature

Thigh: posterior superficial musculature

Thigh: anterior compartment muscles

Thigh: medial compartment muscles

Femoral triangle

Anterior thigh: arteries and nerves

Anterior thigh: arteries

Thigh: posterior compartment muscles

Posterior thigh: arteries and nerves

Transverse sections: thigh

Knee joint

Ligaments of the knee

Menisci and cruciate ligaments

Knee: bursa and capsule

Knee surface: muscles, capsule, and arteries

Popliteal fossa

Tibia and fibula

Bones of the foot

Bones and joints of the foot

Talus and calcaneus

Ankle joint

Ligaments of the ankle joint

Leg: muscle attachments

Posterior leg: superficial muscles

Posterior compartment: deep muscles

Posterior leg: arteries and nerves

Lateral compartment: muscles

Anterior leg: superficial muscles

Anterior compartment: muscles

Anterior leg: arteries and nerves

Leg: cutaneous nerves

Transverse sections: leg

Foot: muscle attachments

Foot: ligaments

Dorsum of foot

Dorsum of foot: arteries and nerves

Plantar aponeurosis

Plantar region (sole) musculature: first layer

Plantar region (sole) musculature: second layer

Plantar region (sole) musculature: third layer

Plantar region (sole) musculature: fourth layer

Plantar region (sole): arteries and nerves

Dorsal hood and tarsal tunnel

Superficial veins of the lower limb

Lymphatics of the lower limb

Anterior cutaneous nerves and dermatomes of the lower limb

Posterior cutaneous nerves and dermatomes of the lower limb

Tables

## Chapter 7: UPPER LIMB

Surface anatomy

Bones of the upper limb

Bony framework of shoulder

Scapula

Clavicle: joints and ligaments

Proximal humerus

Glenohumeral joint

Muscle attachments

Pectoral region

Deep pectoral region

Walls of the axilla

The four rotator cuff muscles

Deep vessels and nerves of the shoulder

Axillary artery

Brachial artery

Brachial plexus

Medial and lateral cords

Posterior cord

Distal end of humerus and proximal end of radius and ulna

Muscle attachments

Anterior compartment: muscles

Anterior compartment: arteries and nerves

Veins of the arm

Posterior compartment: muscles

Posterior compartment: arteries and nerves

Lymphatics of the arm

Transverse sections: arm

Anterior cutaneous nerves of the arm

Posterior cutaneous nerves of the arm

Elbow joint

Elbow joint: capsule and ligaments

Cubital fossa

Radius and ulna

Bones of the hand and wrist joint

Imaging of the hand and wrist joint

Bones of the hand

Joints and ligaments of the hand

Muscle attachments of forearm

Anterior compartment of forearm: muscles

Anterior compartment of forearm: arteries and nerves

Posterior compartment of forearm: muscles

Posterior compartment of forearm: arteries and nerves

Transverse sections: forearm

Carpal tunnel

Muscle attachments of the hand

Superficial palmar region (palm) of hand

Tendon sheaths of hand

Lumbrical muscles

Intrinsic muscles of hand

Palmar region (palm) of hand: arteries and nerves

Arteries of the hand

Innervation of the hand: median and ulnar nerves

Dorsum of hand

Dorsal hoods

Dorsum of hand: arteries

Dorsum of hand: nerves

Anatomical snuffbox

Superficial veins and lymphatics of forearm

Anterior cutaneous nerves of forearm

Posterior cutaneous nerves of upper limb

Tables

## Chapter 8: HEAD AND NECK

Surface anatomy with bones

Bones of the skull

Skull: anterior view

Skull: lateral view

Skull: posterior view

Skull: superior view and roof

Skull: inferior view

Skull: cranial cavity

Ethmoid, lacrimal bone, inferior concha, and vomer

Maxilla and palatine bone

Skull: muscle attachments

Scalp and meninges

Dural partitions

Dural arteries and nerves

Dural venous sinuses

Brain

Brain: imaging

Cranial nerves

Arterial supply to brain

Cutaneous distribution of trigeminal nerve [V]

Facial muscles

Vasculature, facial nerve [VII] and lymphatics

Deep arteries and veins of parotid region

Bony orbit

Section through orbit and structures of eyelid

Eyelids and lacrimal apparatus

Innervation of the lacrimal gland

Muscles of the eyeball

Innervation of the orbit and eyeball

Eye movements

Vasculature of orbit

Eyeball

Eye imaging

Ear surface and sensory innervation

Ear

Middle ear

Internal ear

Ear imaging

Temporal and infratemporal fossae

Bones of the temporal and infratemporal fossae

Temporal and infratemporal fossae

Temporomandibular joint

Mandibular division of the trigeminal nerve [V]

Parasympathetic innervation



Arteries and veins of temporal and infratemporal fossae

Pterygopalatine fossa

Neck surface anatomy

Bones of the neck

Compartments and fascia of the neck

Superficial veins of the neck

Muscles of the neck

Nerves in the neck

Cranial nerves in the neck

Cervical plexus and sympathetic trunk

Arteries of the neck

Root of the neck: arteries

Lymphatics of the neck

Pharynx

Muscles of the pharynx

Innervation of the pharynx

Vasculature of the pharynx

Larynx

Laryngeal cavity

Muscles of the larynx

Innervation of the larynx

Thyroid gland

Vasculature of the thyroid gland

Nose and paranasal sinuses

Nasal cavity: bones

Nasal cavity: mucosal linings

Vasculature and innervation of the nasal cavity

Sinus imaging

Oral cavity: bones

Teeth

Teeth: imaging

Anatomy of teeth

Vessels and nerves supplying teeth

Innervation of teeth and gums

Muscles and salivary glands of the oral cavity

Vessels and nerves of the tongue

Tongue

Hard and soft palate

Palate

Innervation of oral cavity

Cranial nerves

Visceral motor pathways in the head

Tables

INDEX



# Copyright

---

Elsevier  
1600 John F. Kennedy Blvd.  
Ste 1800  
Philadelphia, PA 19103-2899

GRAY'S ATLAS OF ANATOMY, THIRD EDITION  
INTERNATIONAL EDITION

ISBN: 978-0-323-63639-1  
ISBN: 978-0-323-63640-7

**Copyright © 2021 by Elsevier, Inc. All rights reserved.**

No part of this publication may be reproduced or transmitted in any form or by any means, electronic or mechanical, including photocopying, recording, or any information storage and retrieval system, without permission in writing from the publisher. Details on how to seek permission, further information about the Publisher's permissions policies and our arrangements with organizations such as the Copyright Clearance Center and the Copyright Licensing Agency, can be found at our website: [www.elsevier.com/permissions](http://www.elsevier.com/permissions).

This book and the individual contributions contained in it are protected under copyright by the Publisher (other than as may be noted herein).

## Notices

Practitioners and researchers must always rely on their own experience and knowledge in evaluating and using any information, methods, compounds or experiments described herein. Because of rapid advances in the medical sciences, in particular, independent verification of diagnoses and drug dosages should be made. To the fullest extent of the law, no responsibility is assumed by Elsevier, authors, editors or contributors for any injury and/or damage to persons or property as a matter of products liability, negligence or otherwise, or from any use or operation of any methods, products,

instructions, or ideas contained in the material herein.

Previous editions copyrighted 2015 and 2008.

**Library of Congress Control Number: 2019957237**

*Content Strategist:* Jeremy Bowes

*Director, Content Development:* Rebecca Gruliow

*Publishing Services Manager:* Catherine Jackson

*Senior Project Manager:* Daniel Fitzgerald

*Design and Art Direction:* Antbits Ltd.

*Cover design:* Amy Buxton

Printed in Canada

Last digit is the print number: 9 8 7 6 5 4 3 2 1



Working together  
to grow libraries in  
developing countries

[www.elsevier.com](http://www.elsevier.com) • [www.bookaid.org](http://www.bookaid.org)

---

# Dedication

---

To my wife who supports me and to my parents who are always  
with me.

*Richard L. Drake*

To my family, to my professional colleagues and role models, and to  
my students.

*A. Wayne Vogl*

Thanks, to Cathy, Max and Elsa

*Adam W.M. Mitchell*

To my family – my inspiration, Evi, Zoë, and Nicholas

*Richard M. Tibbitts*

To my wife Fern, Junior, Ava and Henry, to Lesley and in memory of  
AMR and JER

*Paul E. Richardson*



---

# ACKNOWLEDGMENTS

---

The following reviewers helped enormously with their detailed critiques and suggestions for every chapter. Their assistance was invaluable.

Mark Hankin, PhD, University of Toledo College of Medicine, Toledo, Ohio

Marios Loukas, MD, PhD, St. George's University School of Medicine, Grenada

James J. Rechten, DO, PhD, Michigan State University School of Medicine, East Lansing, Michigan

William A. Roy, PT, PhD, Touro University, Henderson, Nevada

Susan Standring, MBE, PhD, DSc, FRC, Hon FRCS, Emeritus Professor of Anatomy, King's College London, London

William Swartz, PhD, Louisiana State University Health Sciences Center, Baton Rouge, Louisiana

Mark F. Teaford, PhD, Johns Hopkins University School of Medicine, Baltimore, Maryland

We want to thank Dr. Bruce Crawford for a radiograph of the head and neck and Dr. Murray Morrison for laryngoscopic images of the larynx; Dr. Jerry Healy for three images in the Abdomen section: the celiac artery, the bile duct system, and a three-dimensional view of abdominal vessels; and Siemens Medical Solutions USA and the following individuals with that company: Mollie Beaver, Director, CT Clinical Solutions, and Dr. Louise McKenna, Global Clinical Marketing Manager, CT Oncology, who supplied a *syngo* Multi-modality Workplace, which was used to acquire the majority of the clinical images.

Stuart Morrison, MD, helped with all aspects of coordinating the collection of the radiographic material. Radiological assistance and images were contributed in each of the following areas:

<b>Back</b>	Mark Kayanja, MD, PhD Jeffrey S. Ross, MD
<b>Thorax</b>	Mario Garcia, MD A. Michael Lincoff, MD
<b>Abdomen</b>	Namita Gandhi, MD Michelle Inkster, MD, PhD Brian R. Lane, MD Anand Rao, MD James S. Wu, MD
<b>Pelvis</b>	Matthew Barber, MD, MHS Tommaso Falcone, MD J. Stephen Jones, MD Eunice Moon, MD James S. Newman, MD, PhD
<b>Extremities</b>	Hakan Ilaslan, MD Bradford J. Richmond, MD Joshua Polster, MD
<b>Head and Neck</b>	Todd W. Stultz, DDS, MD J. Martin Paloma, DDS, MSD Cindy McConnaughy Ronald Lemmo, DDS

---

# FOREWORD

---

A working knowledge of anatomy is not an “optional extra” for health care professionals – it is fundamental. Acquiring that knowledge has always challenged even the most motivated students. Over many generations, learning materials that aid the process effectively have been warmly welcomed by students and their teachers (and by patients, who are the ultimate beneficiaries of that knowledge). I remember my own students’ response when I first included illustrations from *Gray’s Anatomy for Students* in a lecture – afterward, I was asked repeatedly for the source of the marvelous pictures. Looking beyond the “wow” factor that leapt from the pages of the book, it was clear that an enormous amount of thought and skill had gone into producing the artwork.

This atlas contains a series of additional outstanding pieces of anatomical art from the illustrative team of Richard Tibbitts and Paul Richardson that will complement those in *Gray’s Anatomy for Students*, combined with relevant clinical pictures, surface anatomy, and images from a range of modern imaging procedures. Of course, anatomy cannot be learned from books and interactive DVDs alone, no matter how excellent they may be. Anatomy is a practical subject, best learned by gaining hands-on experience of the body. Students should spend as much time as they can examining cadaveric dissections (if they do not have the opportunity to dissect themselves) and should always read from screen or page with the appropriate bones in front of them. They need to combine and correlate information from a wide variety of sources in order to gain the working knowledge mentioned earlier.

This atlas will provide a valuable companion to their studies, and I am confident that it will remain in their libraries long after they have completed the early stages of their training.

**Susan Standring, MBE, PhD, DSc, FKC, Hon FRCS,** Emeritus Professor of  
Anatomy, King’s College, London



مدیسکا  
*Medisca*

Telegram : @Meddisca

# FOREWORD

---

We began working on *Gray's Atlas of Anatomy* in 2005 following the publication of our textbook, *Gray's Anatomy for Students*. We wanted to produce an atlas that would build on themes and concepts established in the textbook and that would couple artistic renderings of “internal” gross anatomy with actual “living” anatomy, as visualized with modern imaging techniques and with surface anatomy. We believe that the final atlas, now in its third edition, presents a fresh and integrated approach to anatomy that is accessible to entry-level students in anatomy, as well as to students at more advanced levels.

Because an atlas is used in a much different way than a textbook, we could not simply repackage figures used in *Gray's Anatomy for Students* and put them in the atlas. Consequently, most of the figures in the atlas are new and were designed to present structures in a more complete context than in the textbook, even though the color palette and overall look of the figures in both the atlas and textbook are similar. Also, figures in the atlas provide additional detail not included in the textbook and directly correlate artistic representations of anatomy with computed tomography (CT) and magnetic resonance imaging (MRI). Where appropriate, we have included endoscopic, laryngoscopic, and laparoscopic views of the anatomy and have included examples of ultrasound images. In a number of regions, we also have reconstructed the internal anatomy of patients by abstracting specific information from multiple MR or CT images, and we present these reconstructions together with artwork of the same anatomy. Although the artwork was done independently of the reconstructed images, the two types of representations are strikingly similar.

Each page of this atlas was planned prior to beginning work on the figures, and all of the artwork was generated digitally. Most of the figures were created from an extensive digital database created for the textbook. In this third edition, we have updated the images and added a few new ones in response to feedback from our readers.

We hope that the textbook and this edition of the atlas used together will provide powerful learning tools for students of human gross anatomy.

The Authors





---

# PREFACE

---

This 3rd edition of *Gray's Atlas of Anatomy* continues in the tradition of the first two editions, coupling artistic rendering with actual living anatomy as visualized with modern imaging techniques and surface anatomy. The combination of modern illustrations, imaging, and surface anatomy is unique among atlases available today.

At the end of every chapter, tables and schematic drawings allow for quick review of subject matter. These include major nerves plexuses throughout the body, branching patterns of major arteries, summaries of muscles organized into compartments or regions, and other helpful information. This material is designed to provide the reader quick access to information.

It's our hope that the 3rd edition of *Gray's Atlas of Anatomy* will become a valuable learning aid for students encountering anatomy for the first time or for the individual seeking to review information critical to their daily experiences.

The Authors



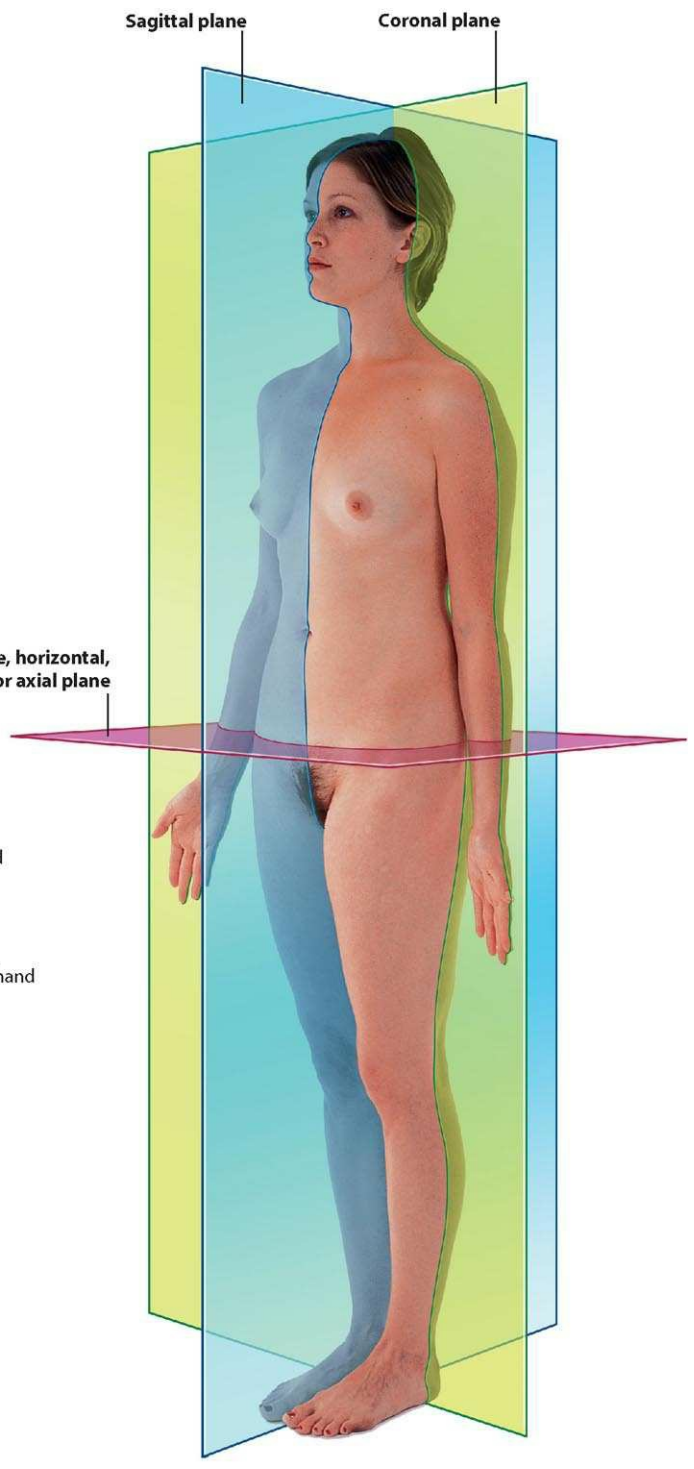
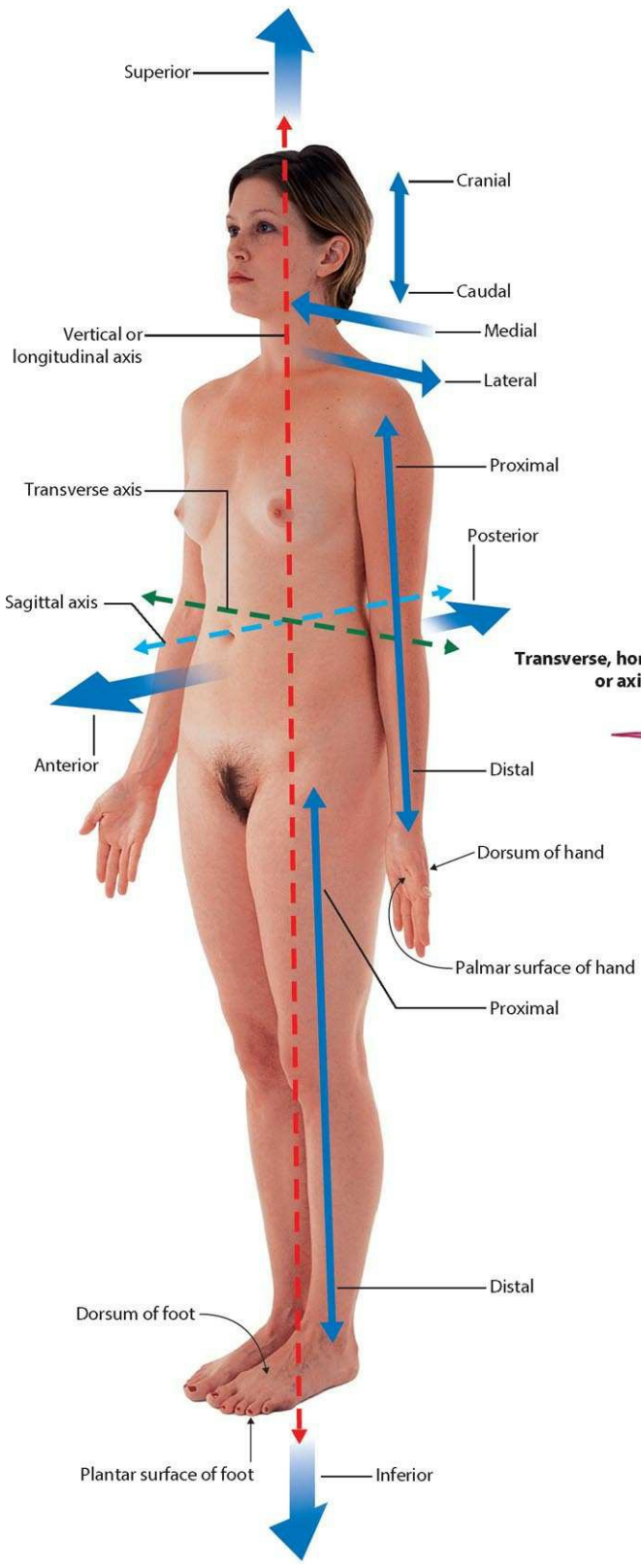
# THE BODY

---

# CONTENTS

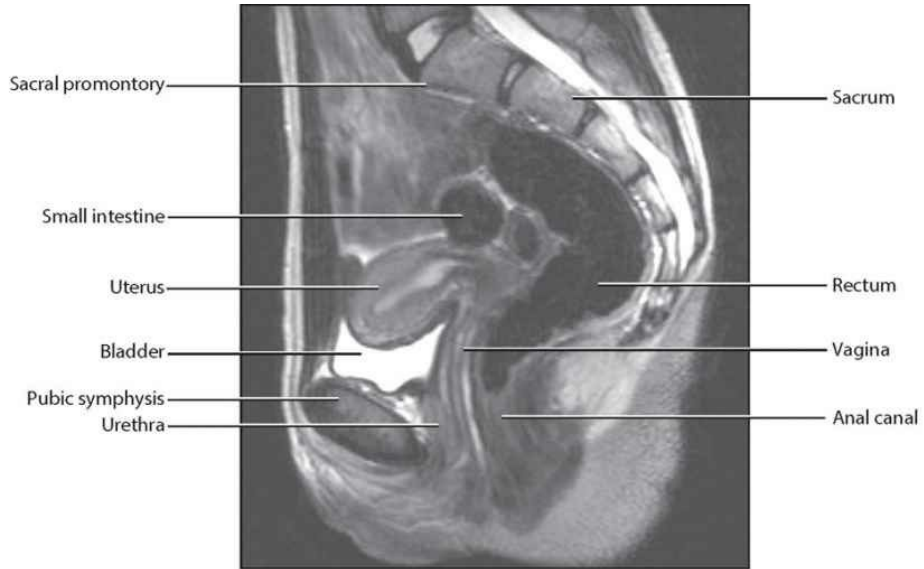
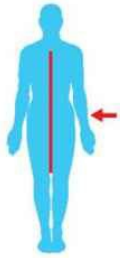
Anatomical position, terms, and planes	2
Anatomical planes and imaging	3
Surface anatomy: anterior view	4
Surface anatomy: posterior view	5
Skeleton: anterior	6
Skeleton: posterior	7
Muscles: anterior	8
Muscles: posterior	9
Vascular system: arteries	10
Vascular system: veins	11
Lymphatic system	12
Nervous system	13
Sympathetics	14
Parasympathetics	15
Dermatomes	16
Cutaneous nerves	17

# **Anatomical position, terms, and planes**

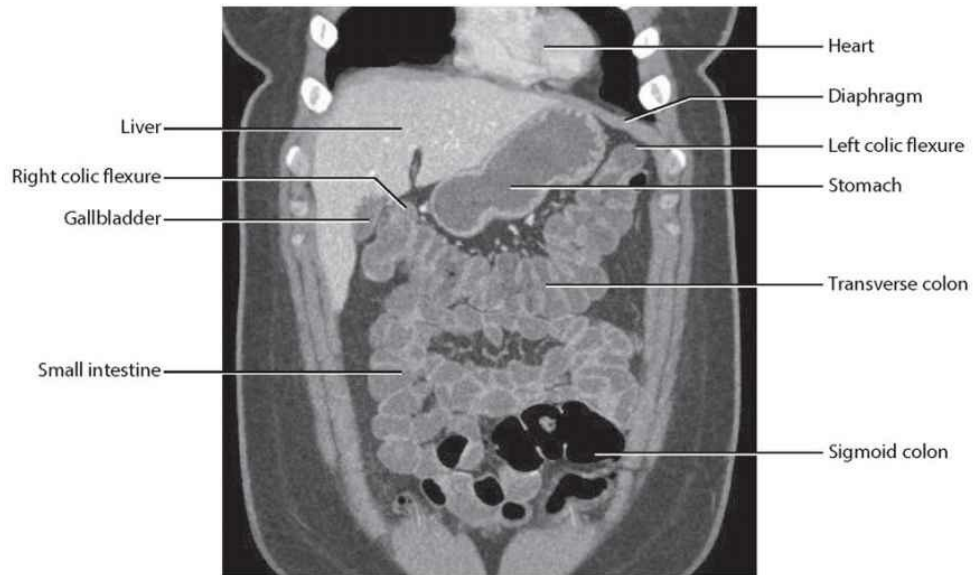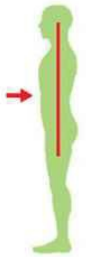


# Anatomical planes and imaging

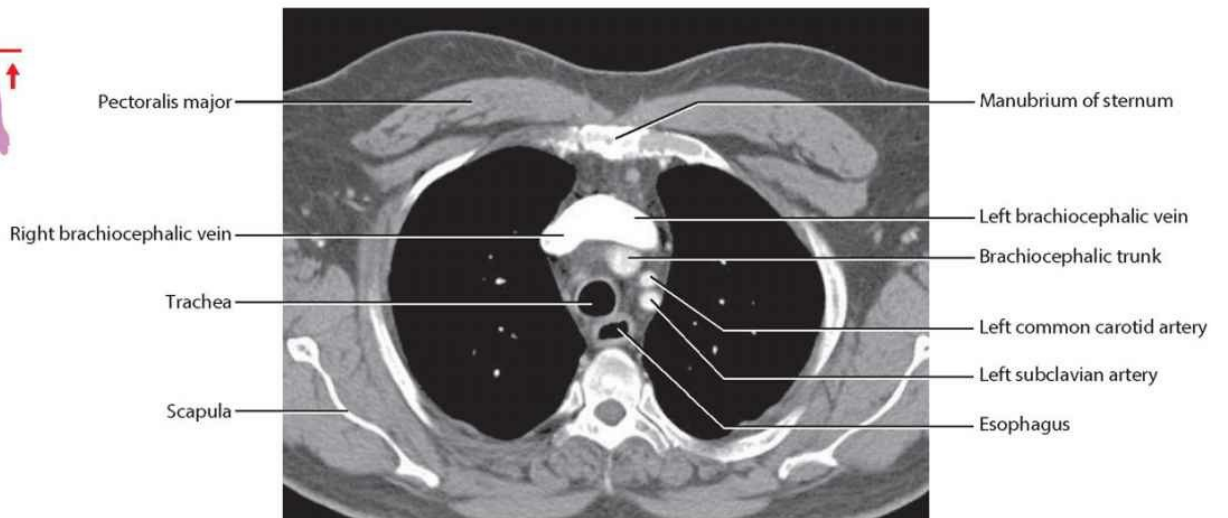
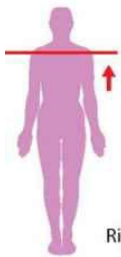




T2-weighted MR image, in sagittal plane



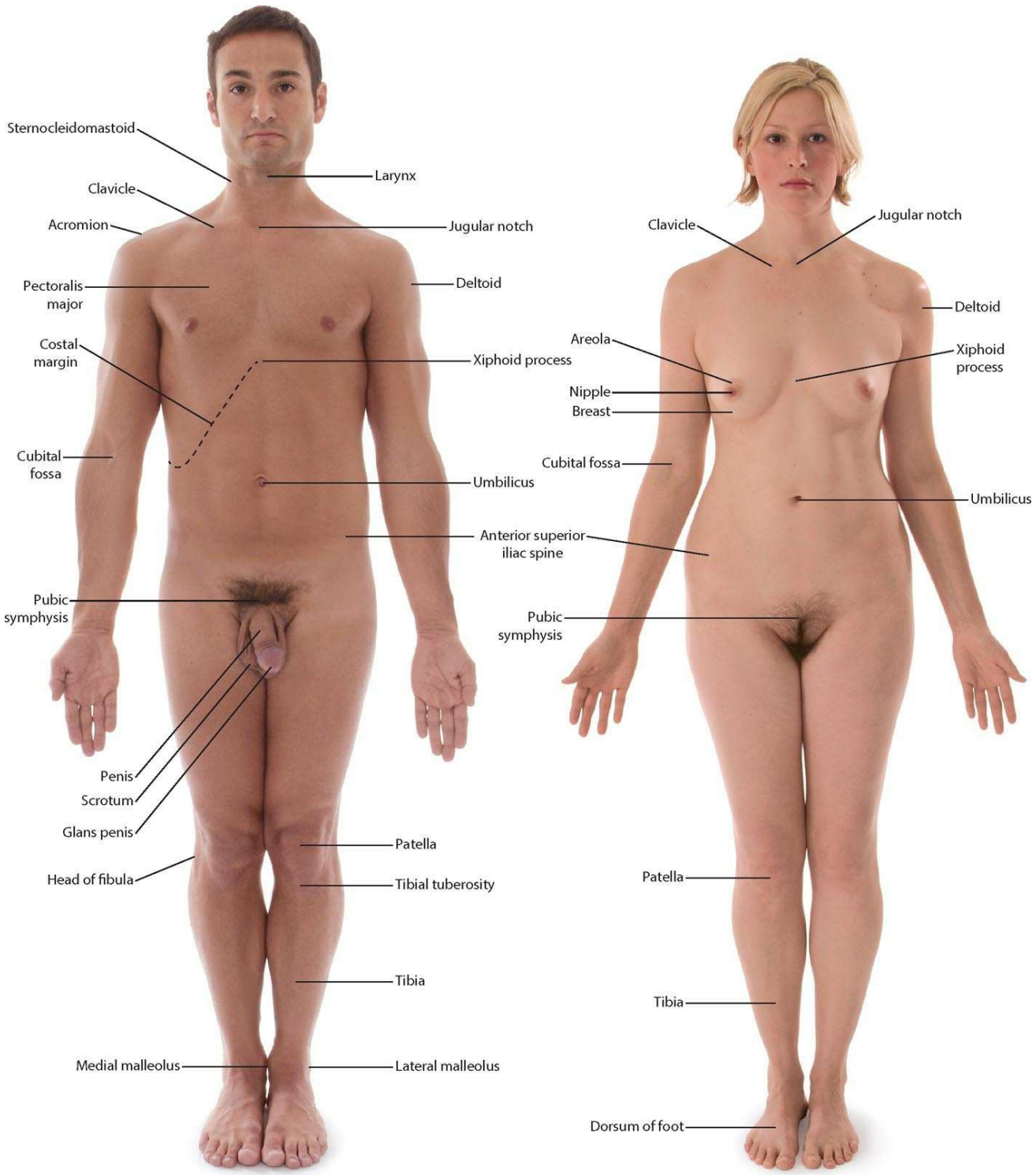
CT image, with contrast, in coronal plane



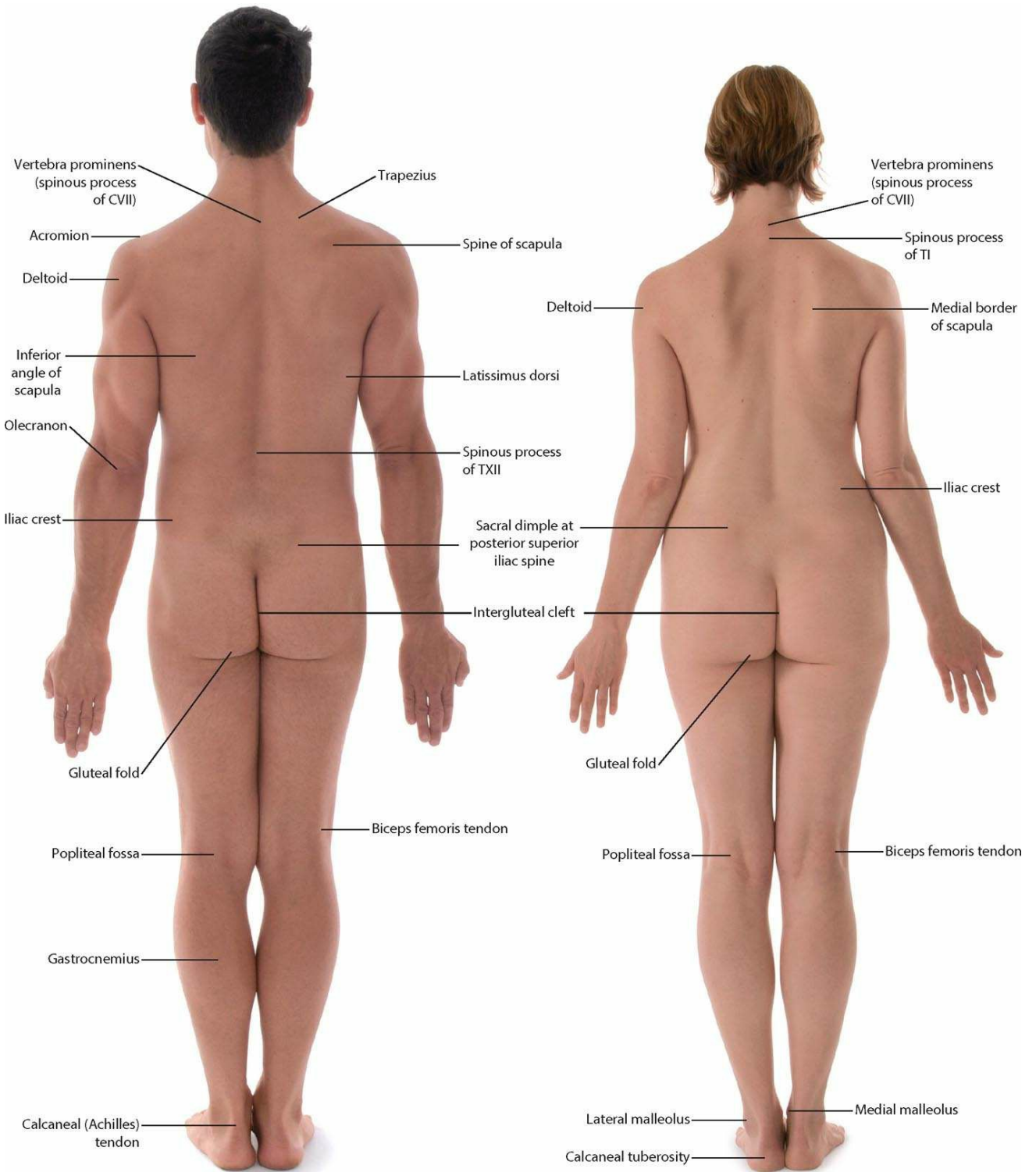
CT image, with contrast, in axial plane



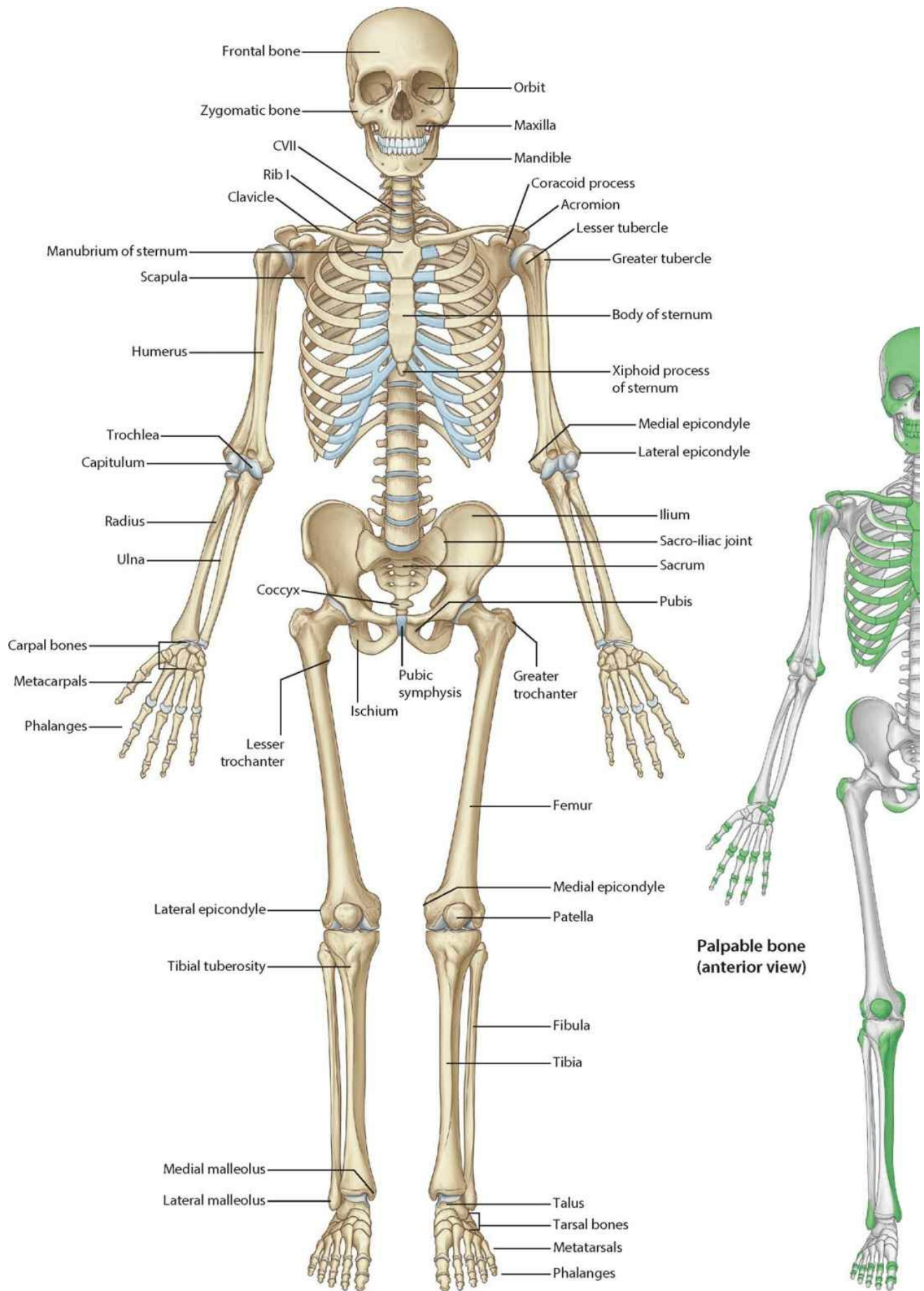
## Surface anatomy: anterior view



## Surface anatomy: posterior view



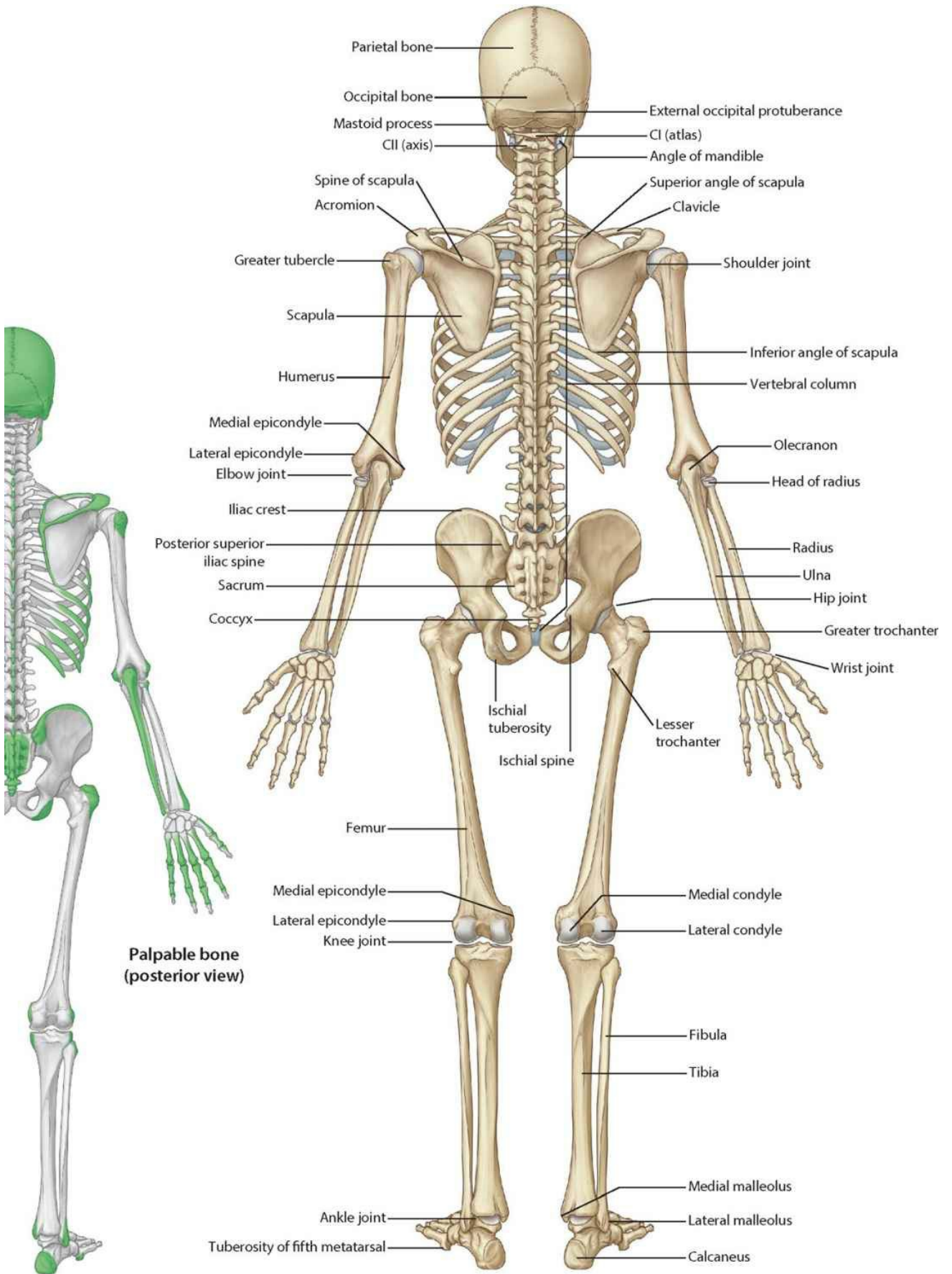
**Skeleton: anterior**



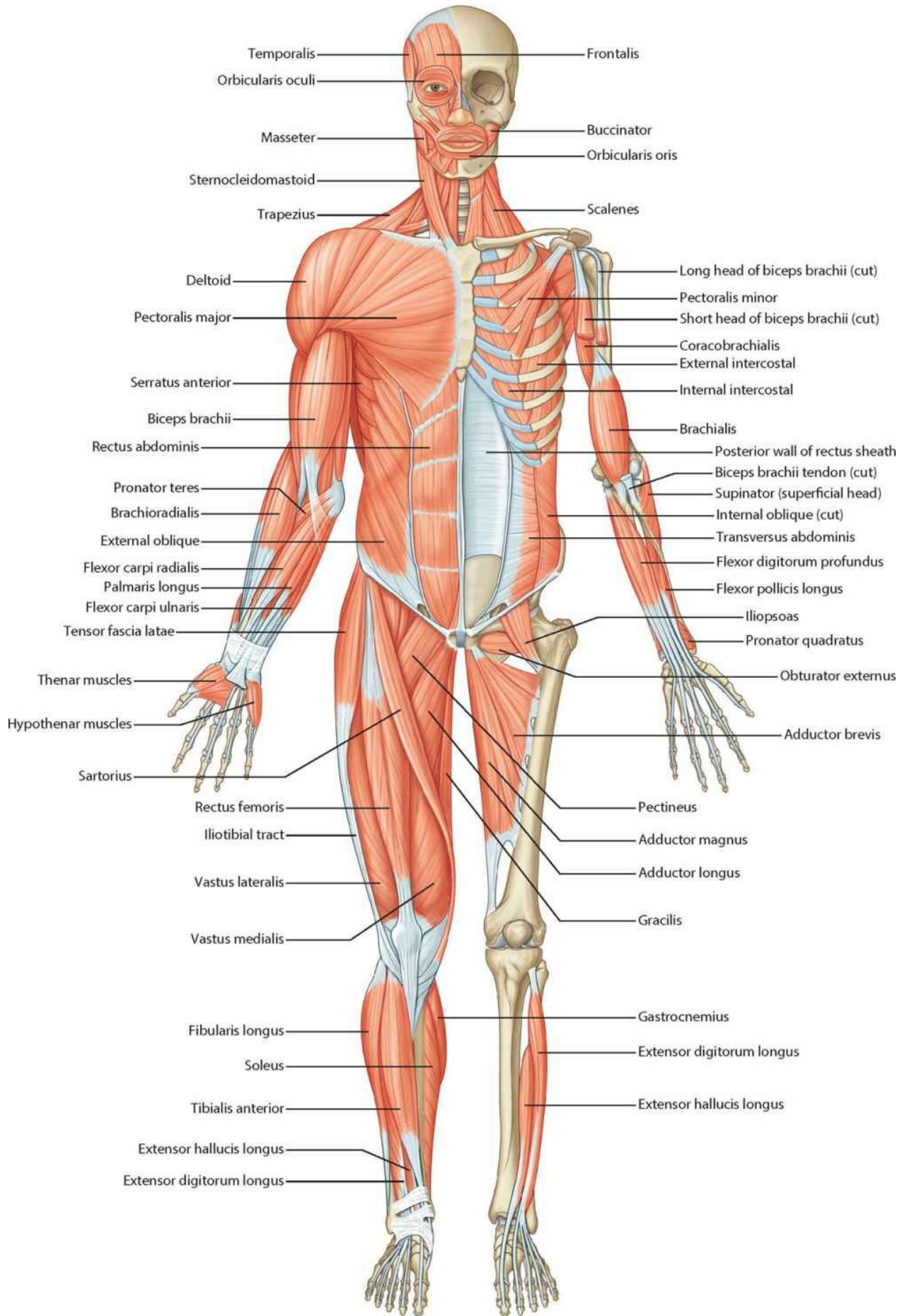




## **Skeleton: posterior**

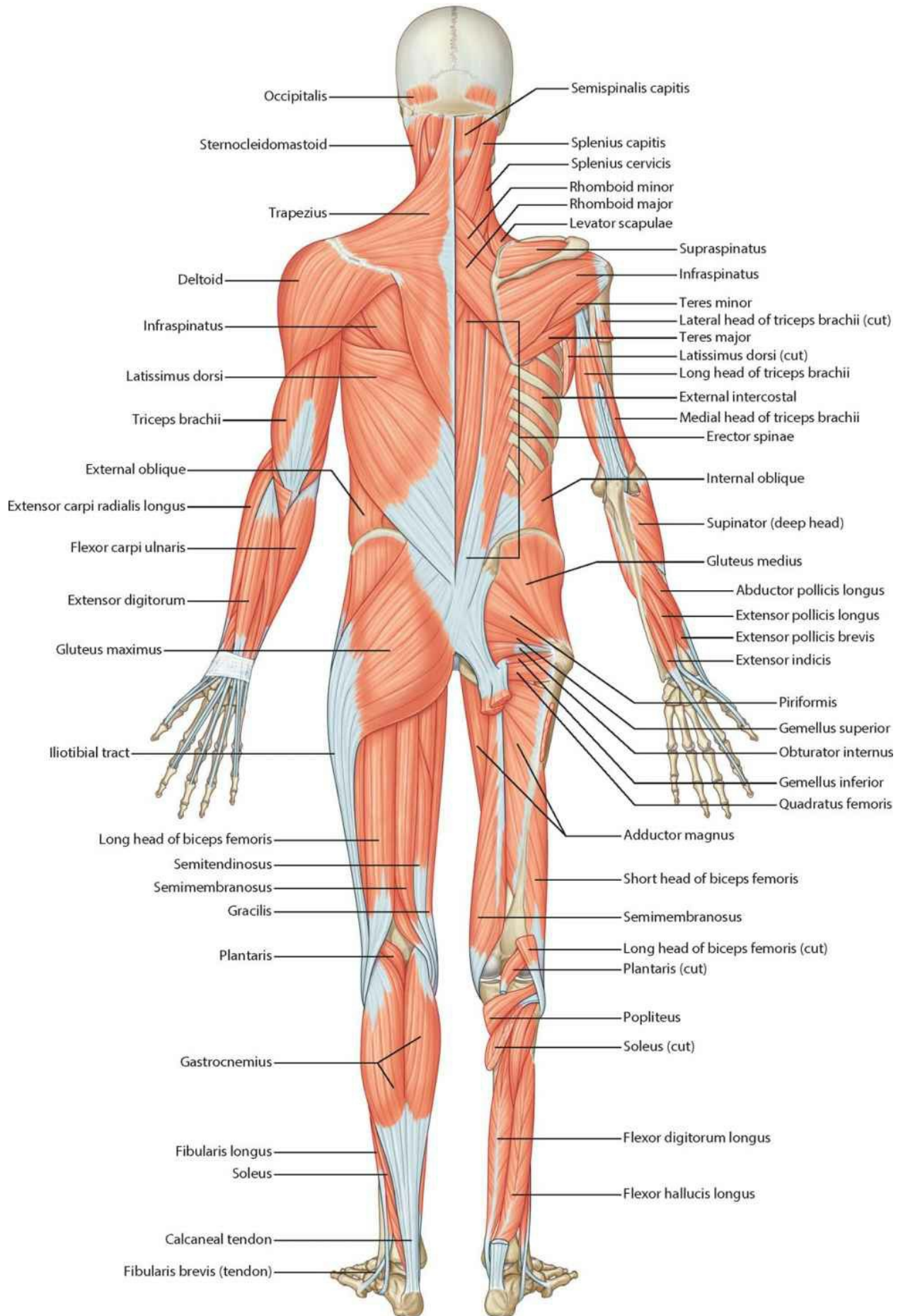


## **Muscles: anterior**





## **Muscles: posterior**



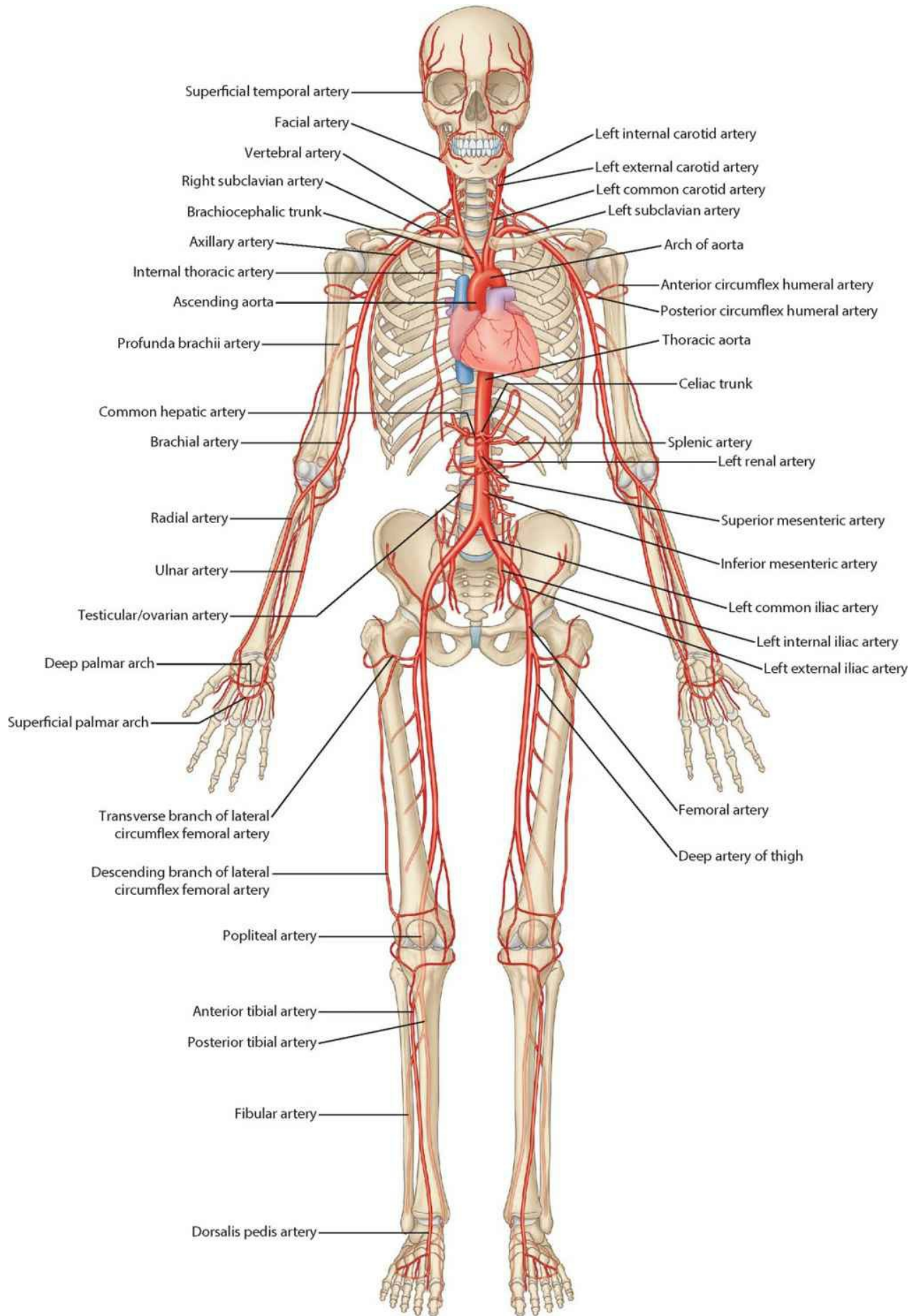




مدیسکا  
*Medisca*

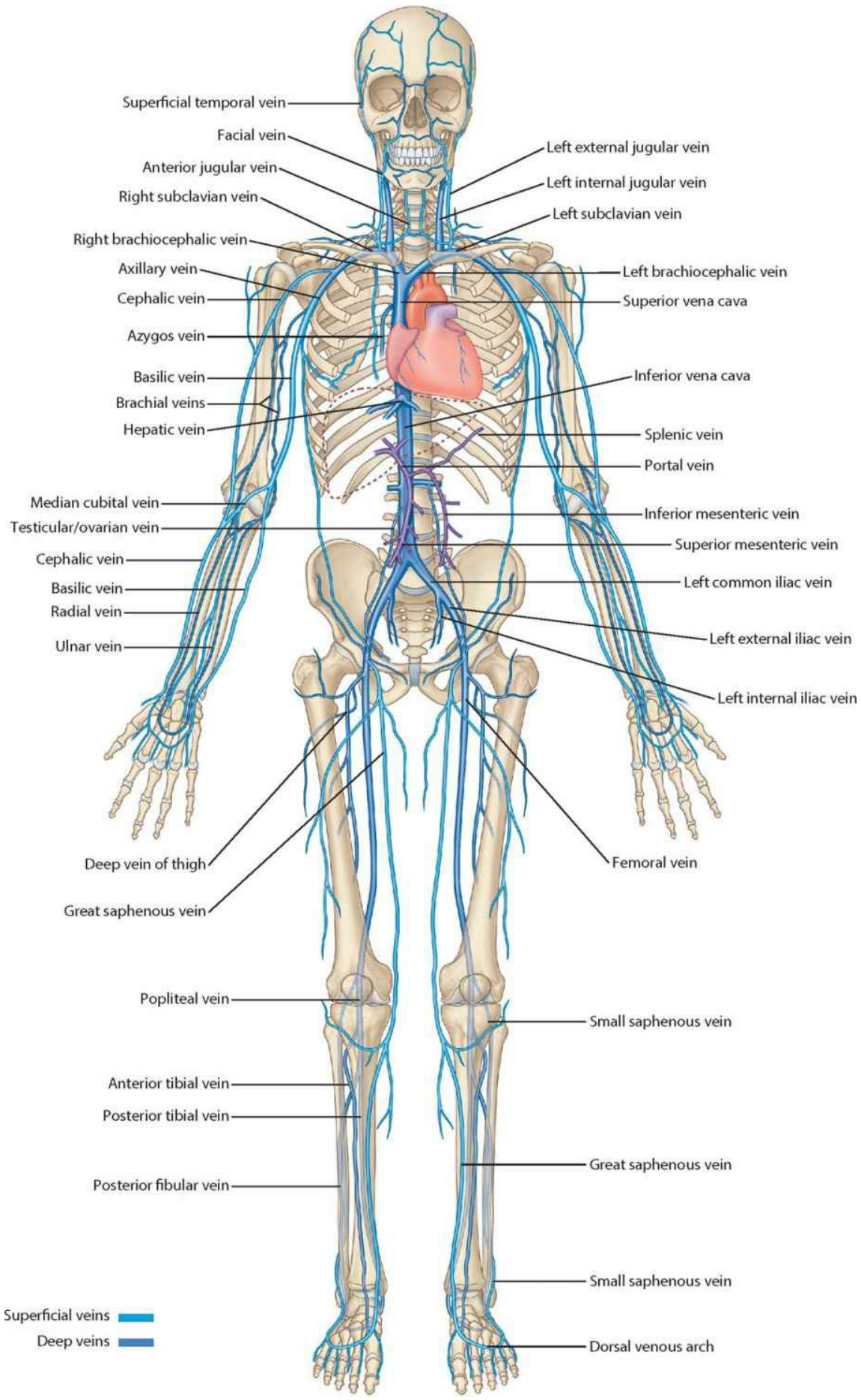
Telegram : @Meddisca

# Vascular system: arteries





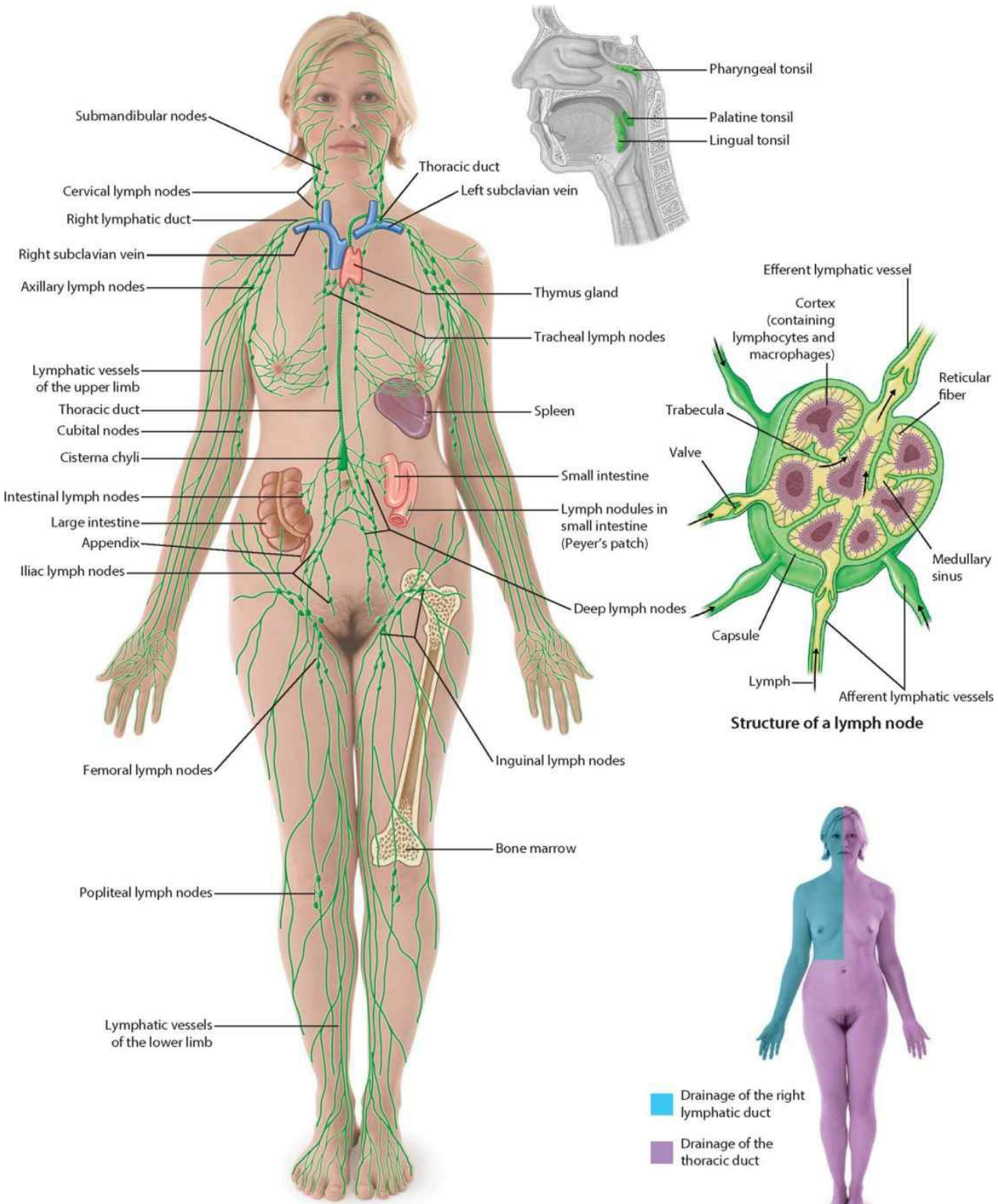
# Vascular system: veins





# Lymphatic system



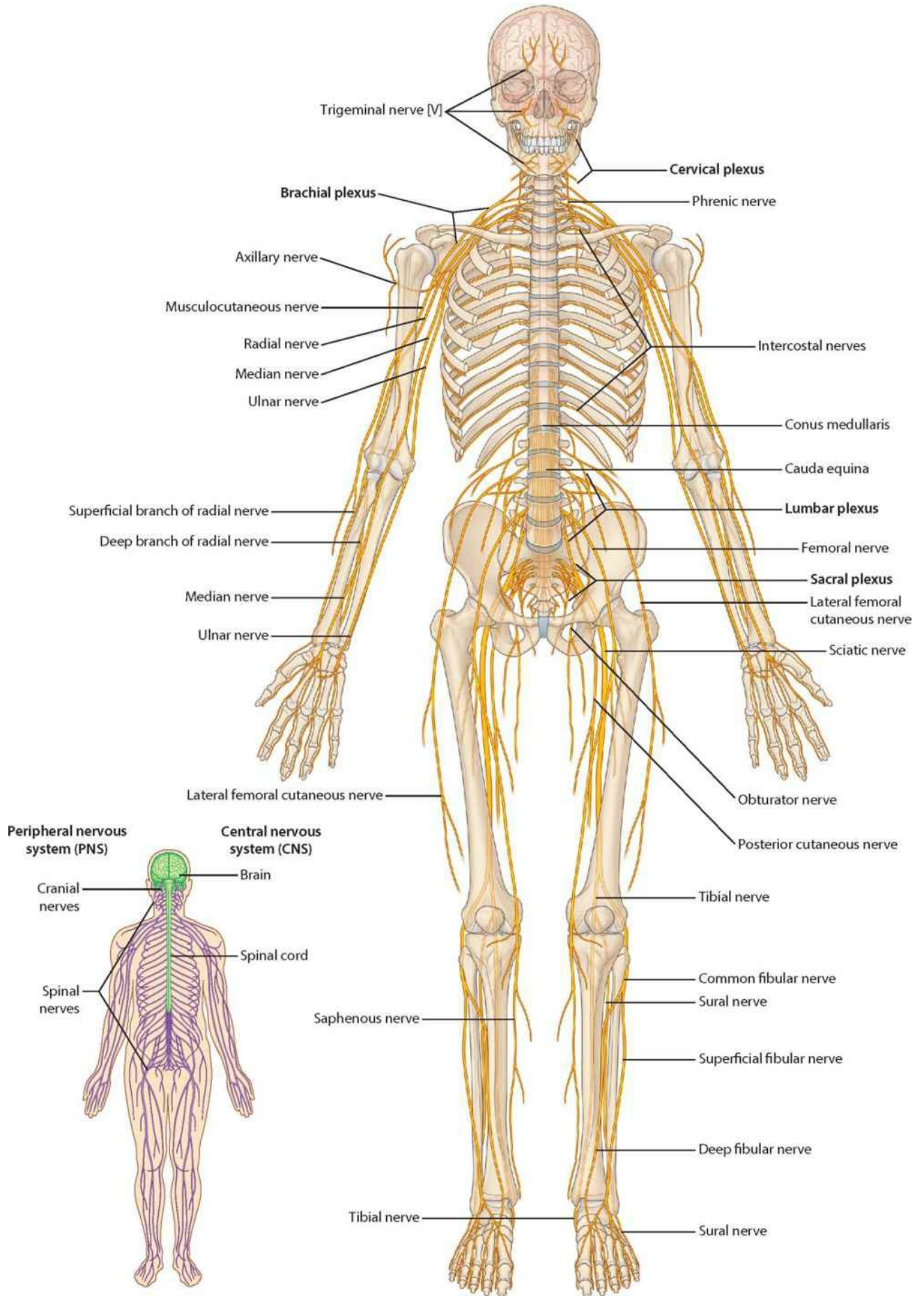


Principal components of the lymphatic system

Structure of a lymph node

■ Drainage of the right lymphatic duct  
■ Drainage of the thoracic duct

# Nervous system

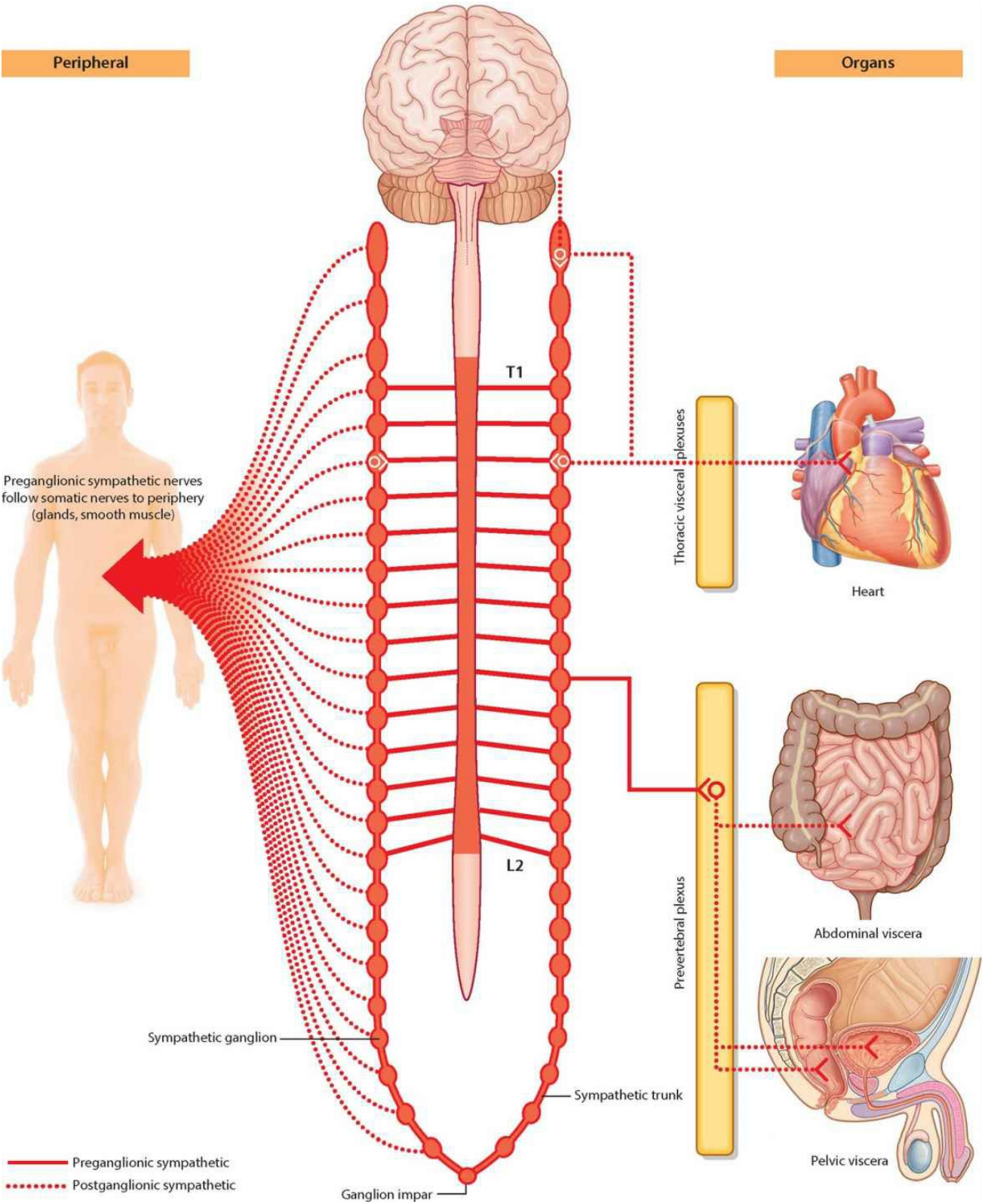




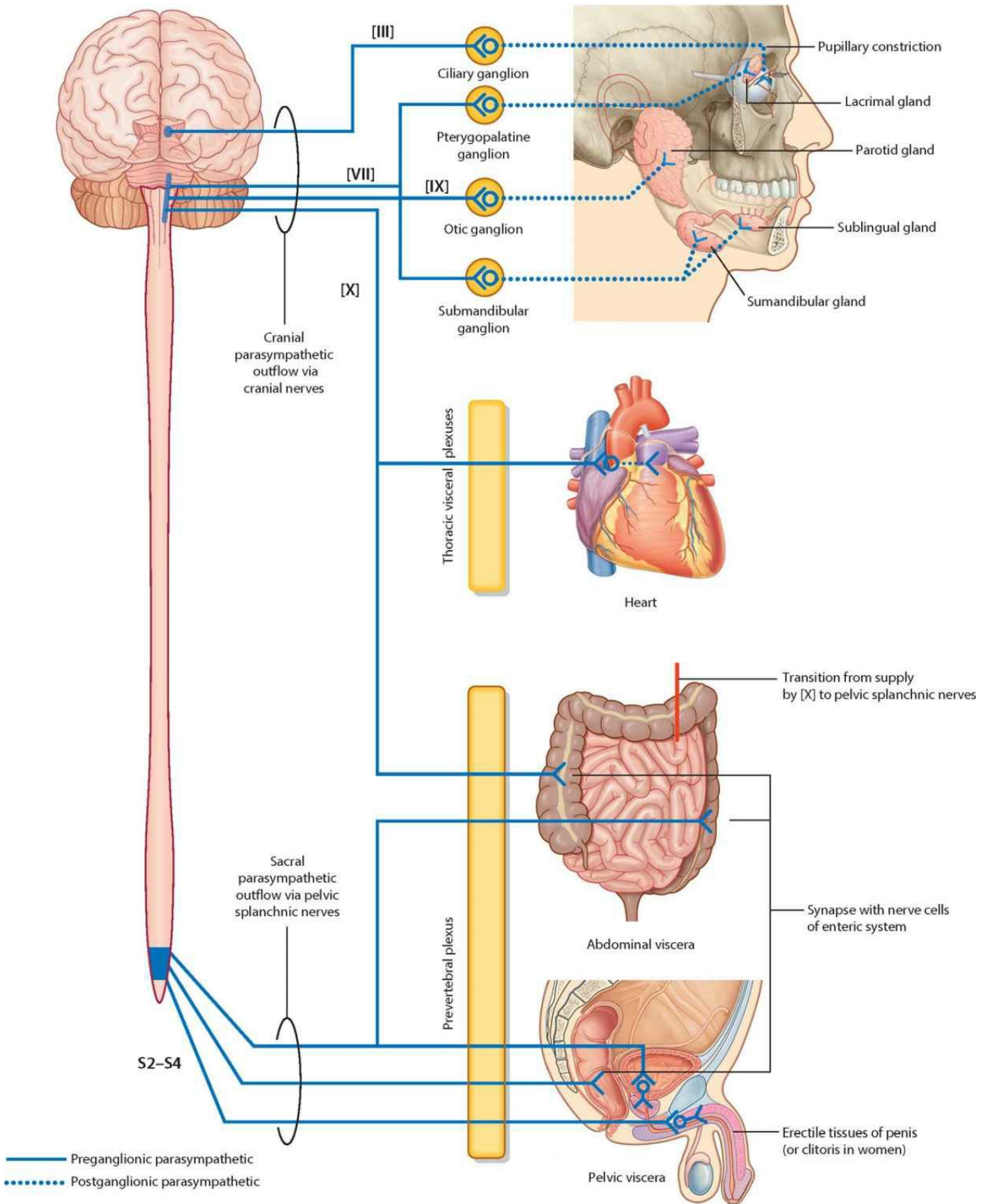
# Sympathetics

Peripheral

Organs

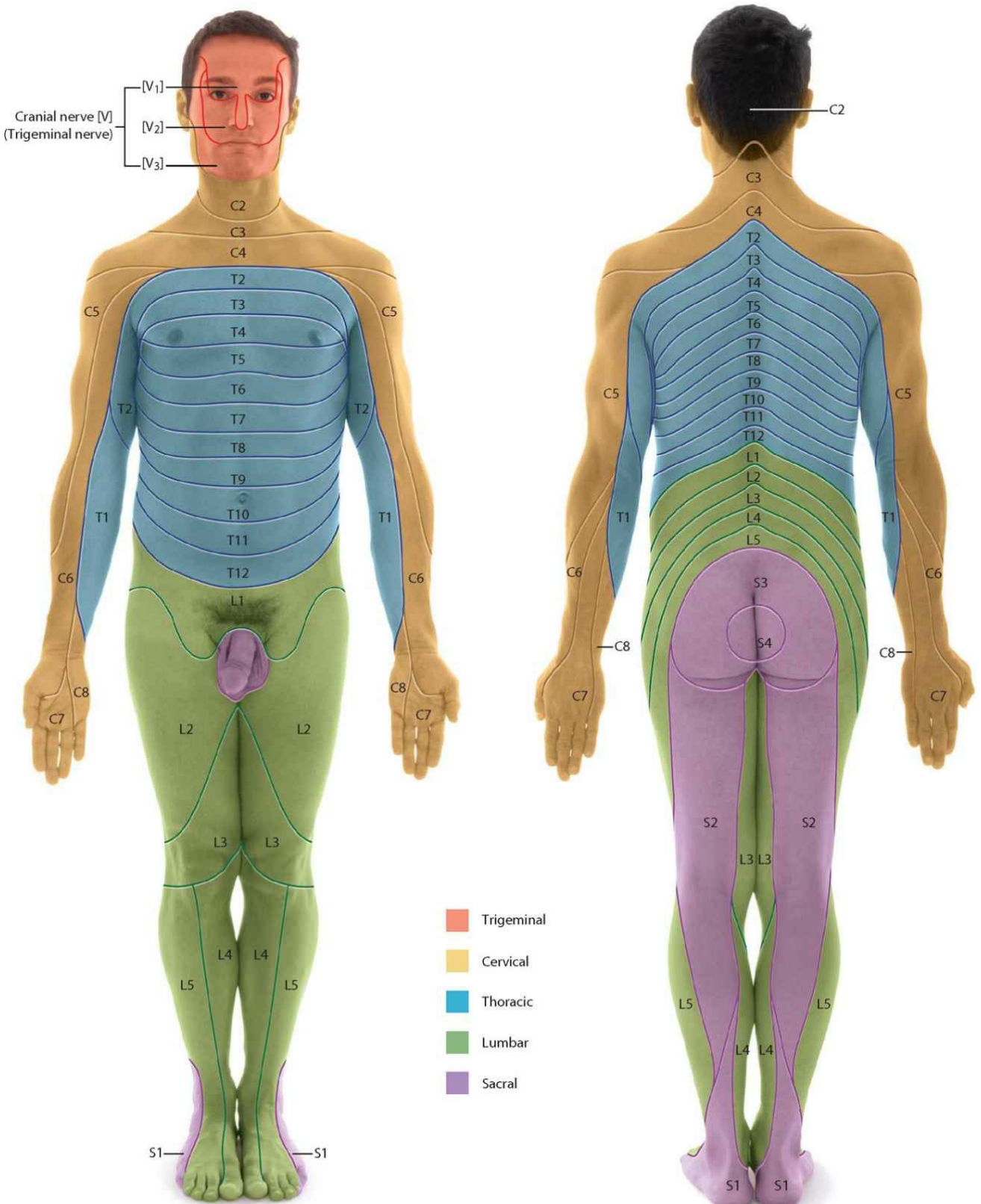


# Parasympathetics



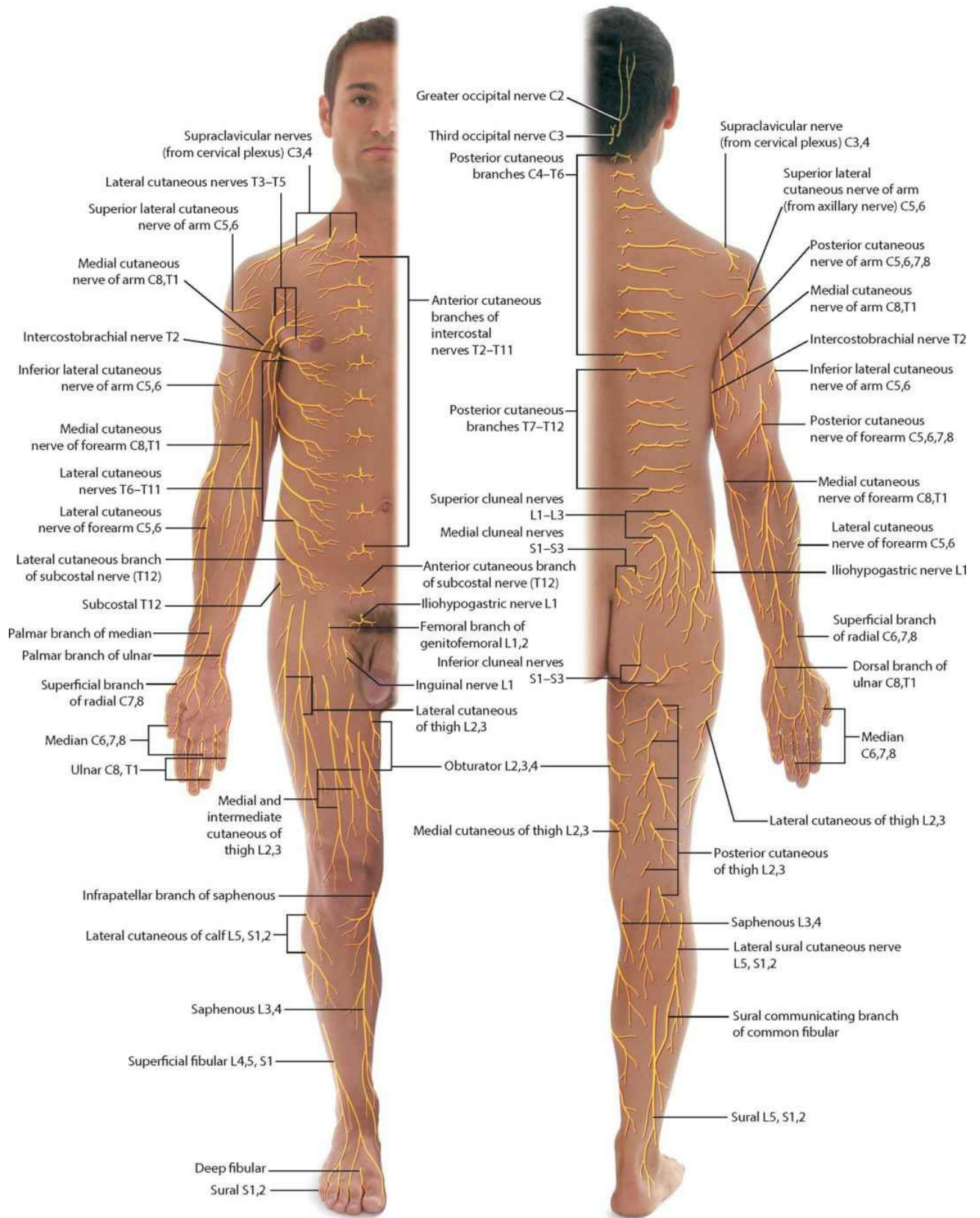


# Dermatomes



**Dermatome map**  
(cutaneous distribution of nerves)

# Cutaneous nerves





**BACK**

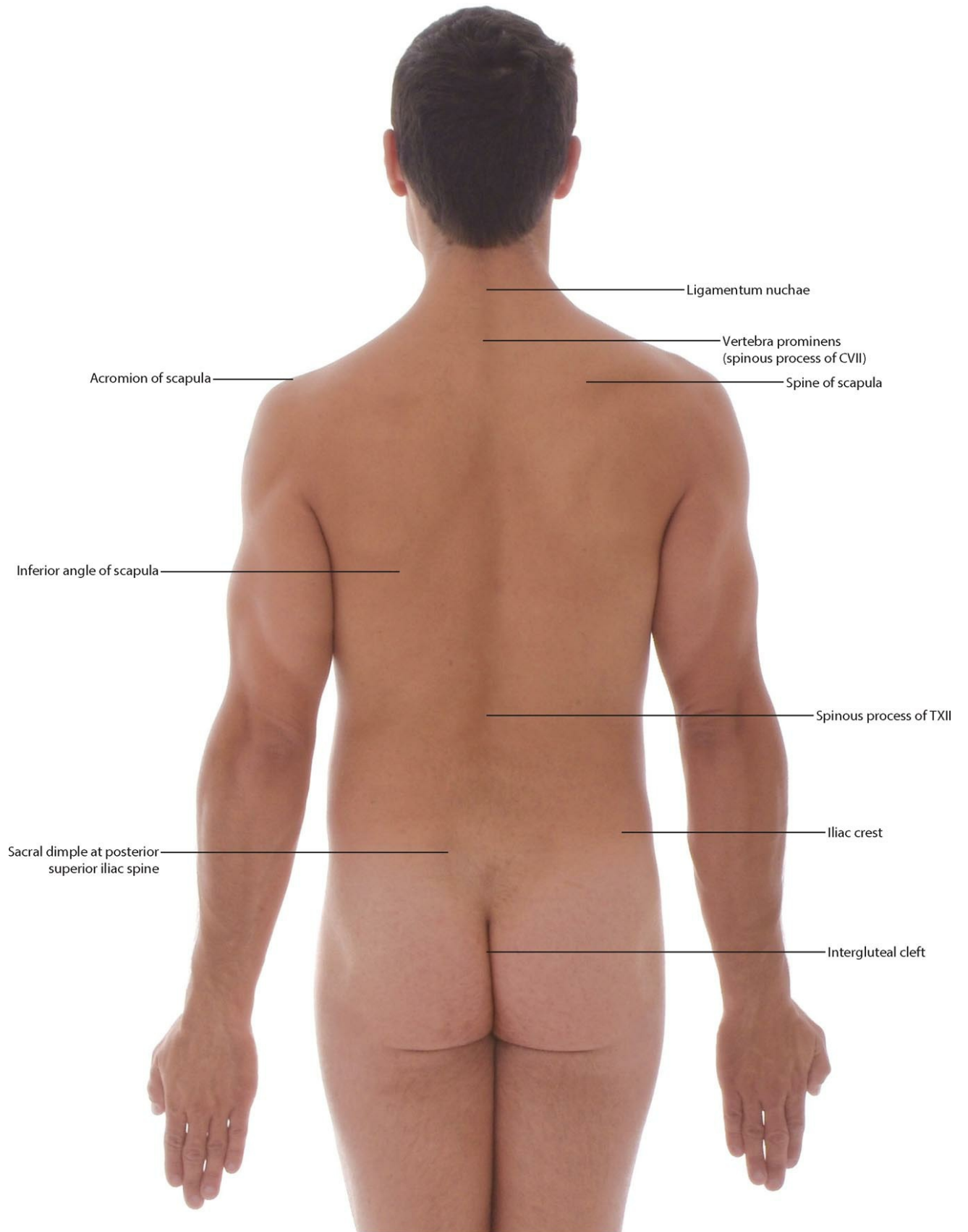
---

# CONTENTS

Surface anatomy	20
Vertebral column	21
Regional vertebrae	22
Cervical vertebrae	23
Thoracic vertebrae	26
Lumbar vertebrae	28
Sacrum	31
Intervertebral foramina and discs	32
Intervertebral disc problems	33
Joints and ligaments	35
Back musculature: surface anatomy	36
Superficial musculature	37
Intermediate musculature	39
Deep musculature	40
Back musculature: transverse section	42
Suboccipital region	43
Spinal nerves	44
Spinal cord	45
Spinal cord vasculature	46
Venous drainage of spinal cord	47
Meninges	48
Spinal cord: imaging	50
Transverse section: thoracic region	52
Dermatomes and cutaneous nerves	53
Tables	54

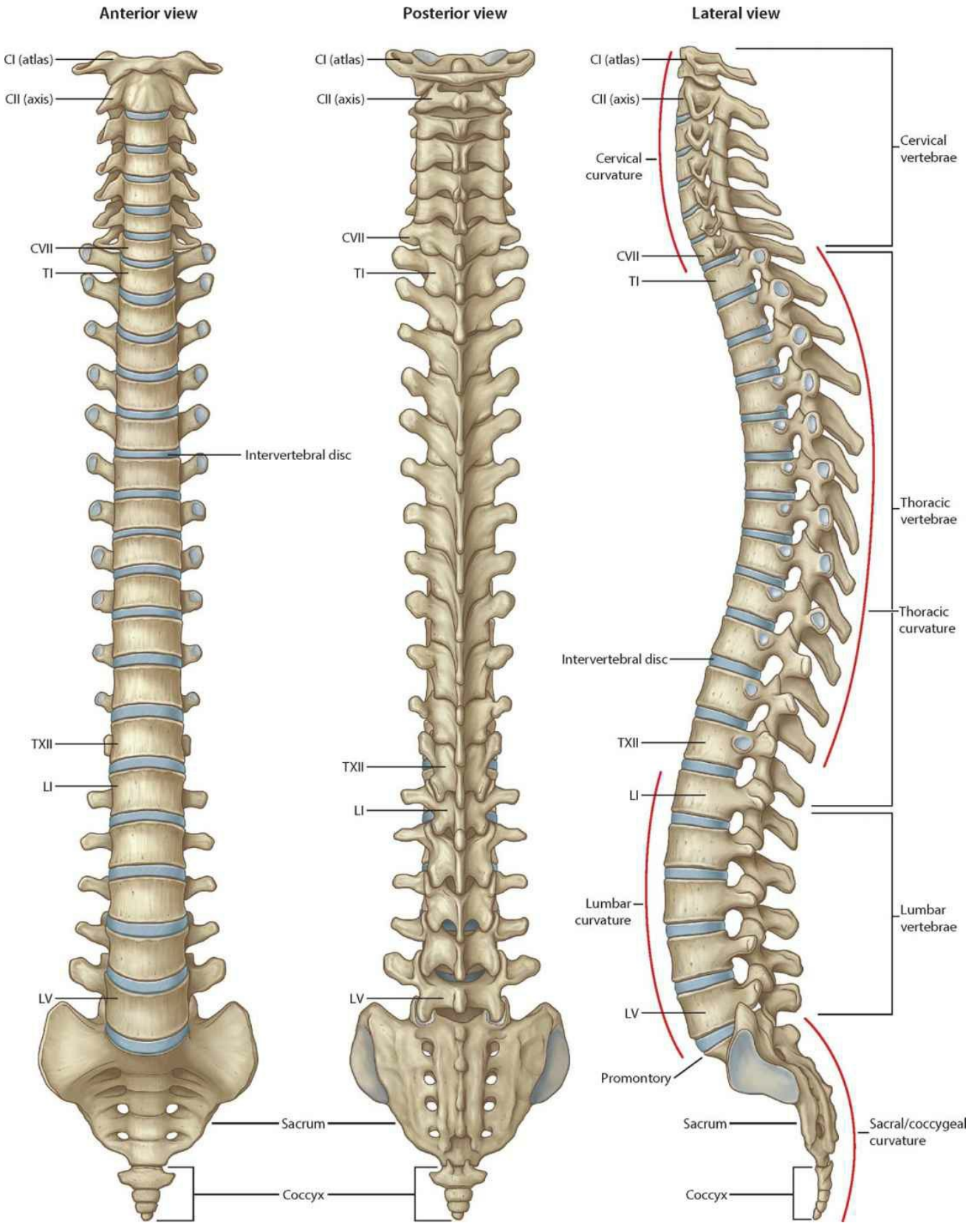
# Surface anatomy



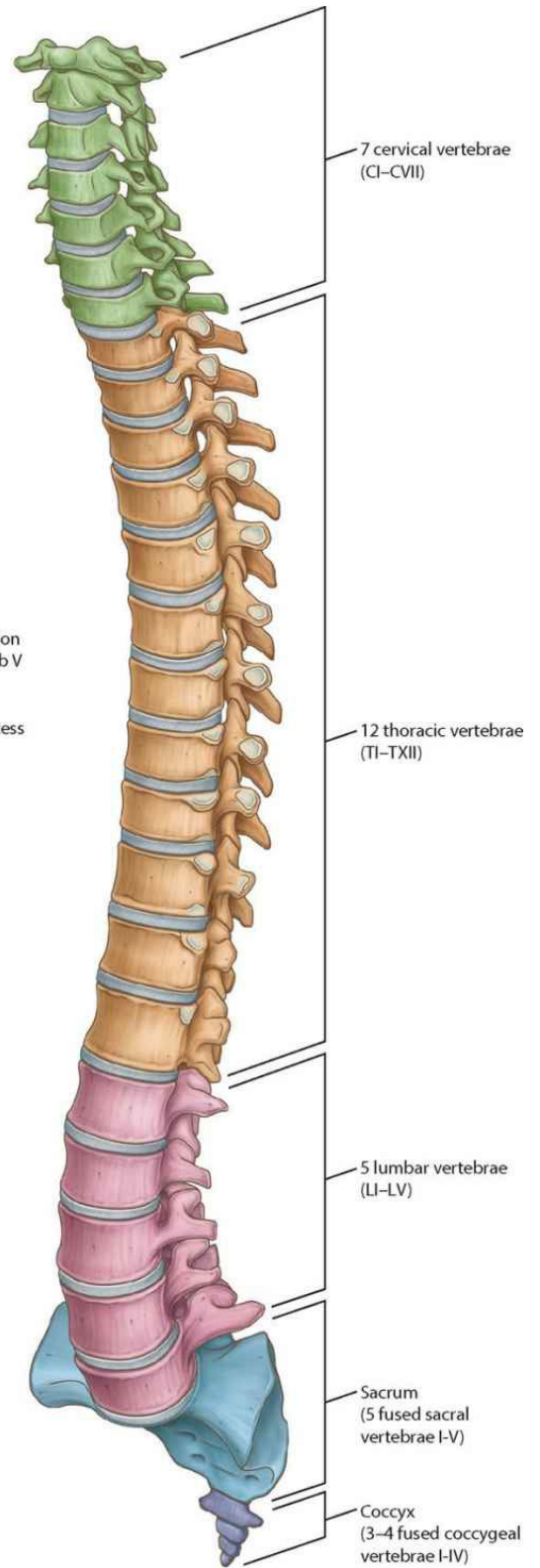
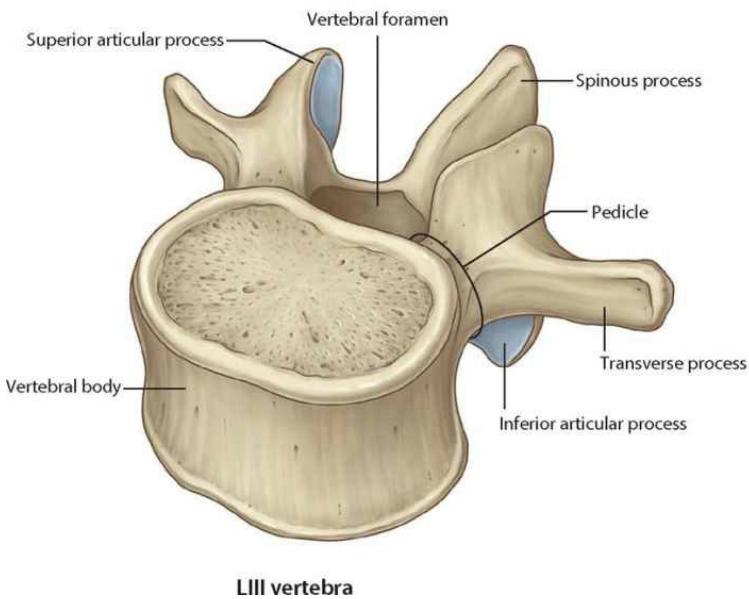
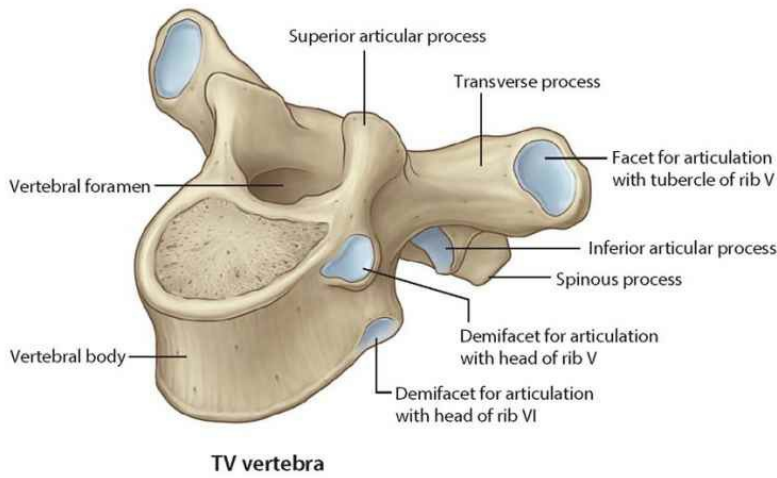
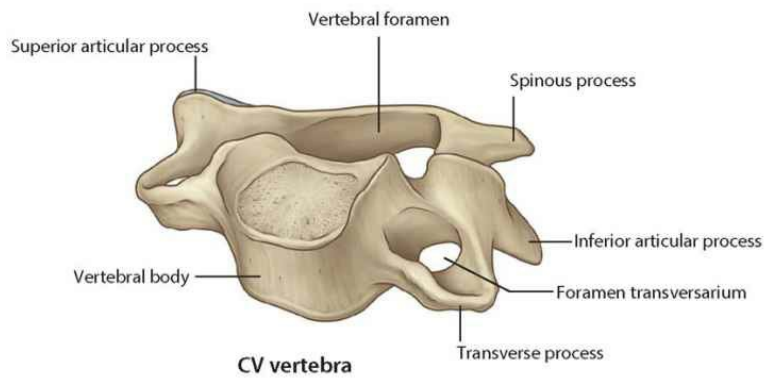


Surface anatomy of the back

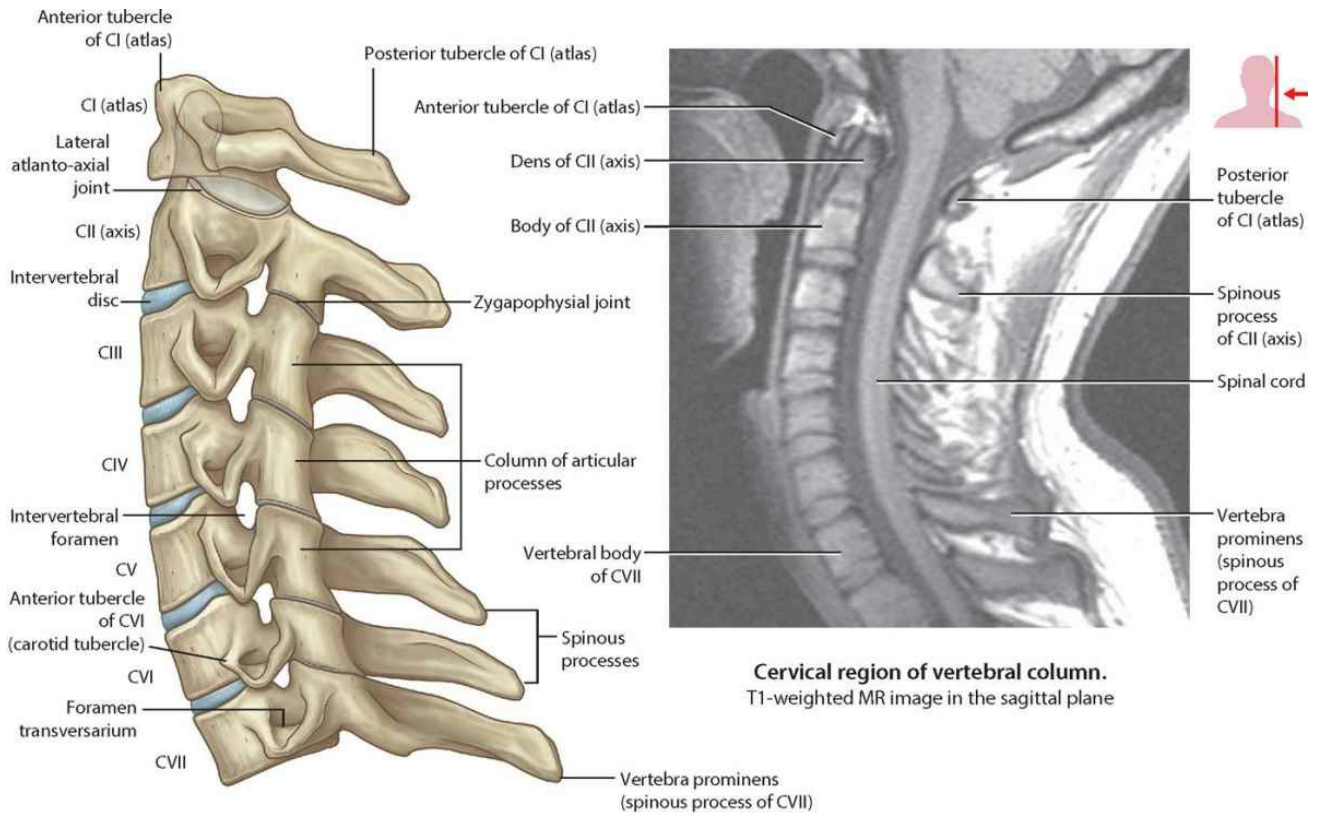
# Vertebral column



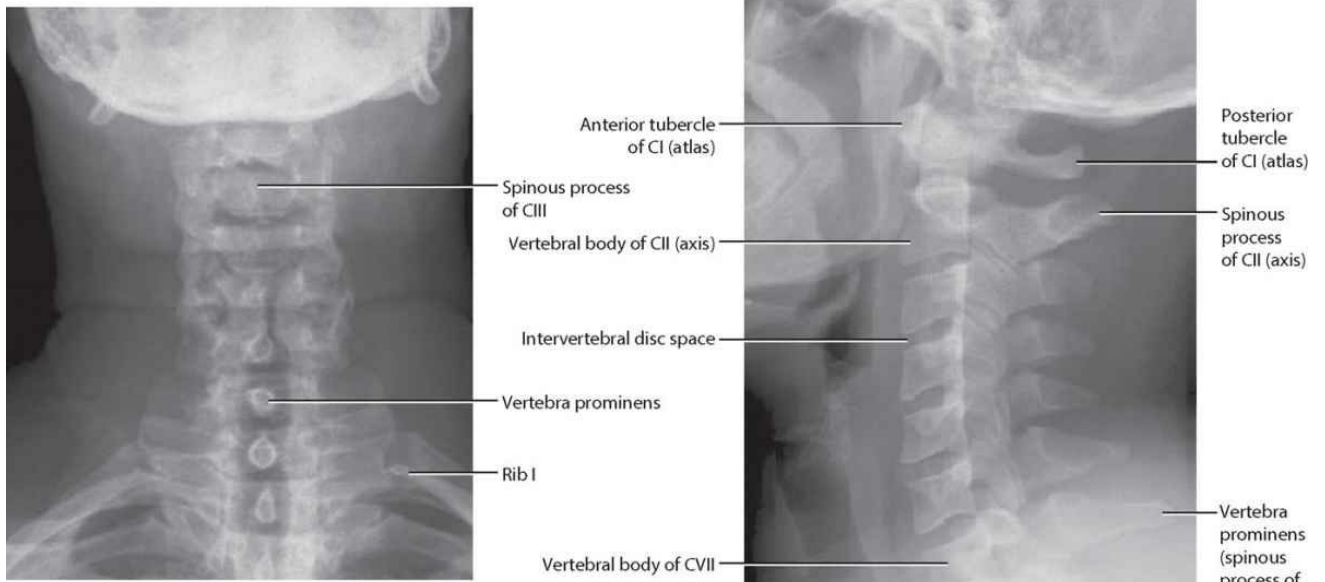
# Regional vertebrae



# Cervical vertebrae

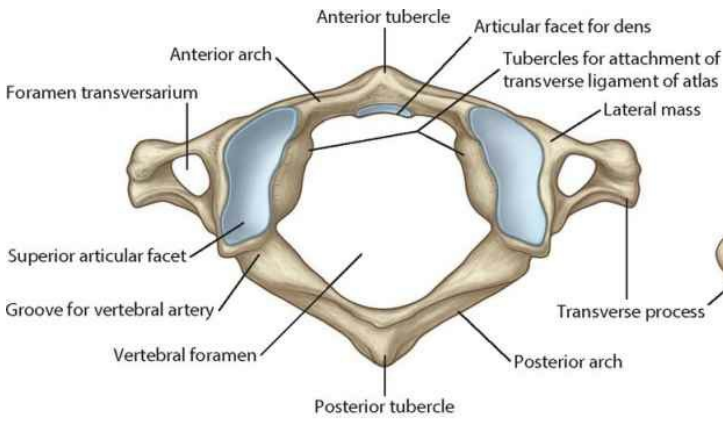


Cervical vertebrae lateral view

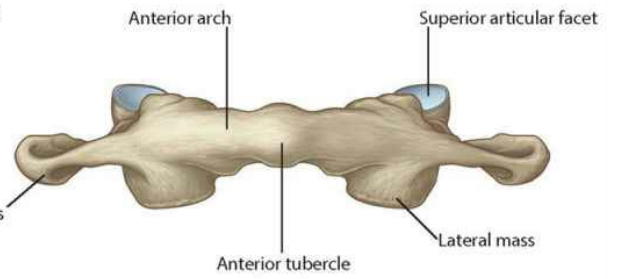


Cervical region of vertebral column. Radiograph, AP view

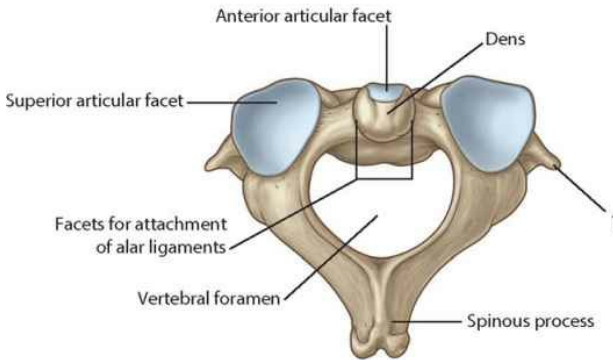
Cervical region of vertebral column. Radiograph, lateral view



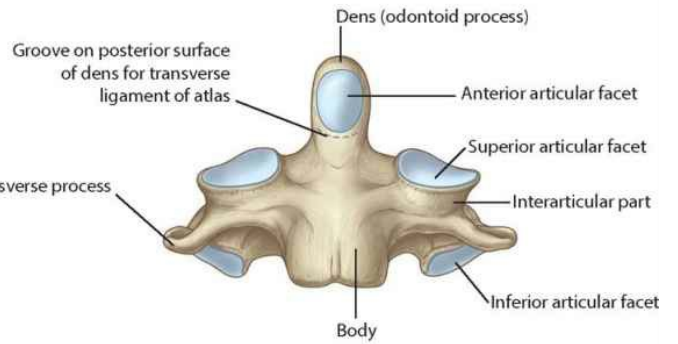
**C1 vertebra (atlas) superior view**



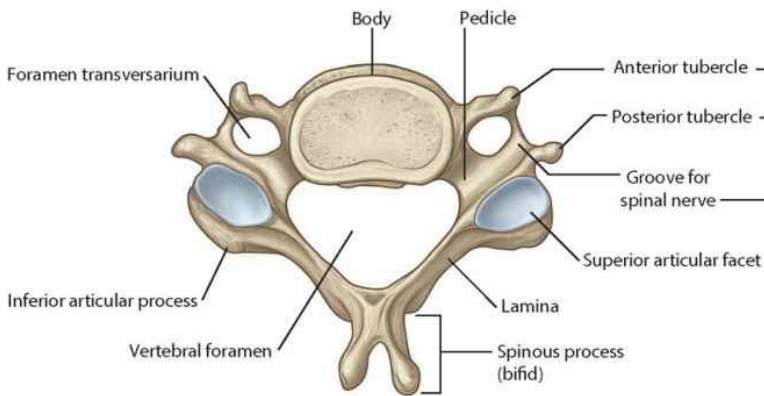
**C1 vertebra (atlas) anterior view**



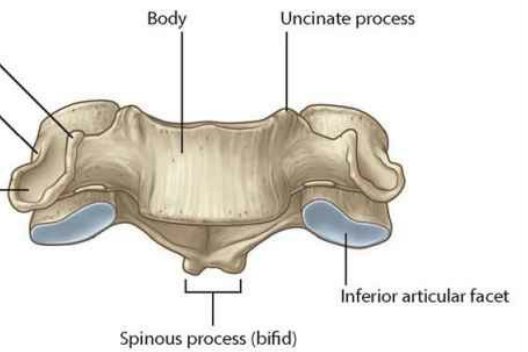
**C2 vertebra (axis) superior view**



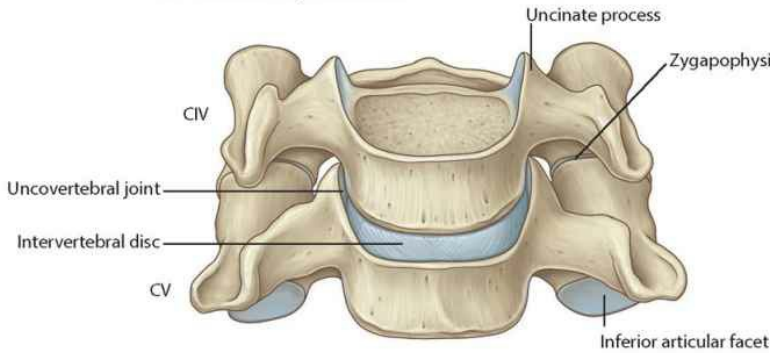
**C2 vertebra (axis) anterior view**



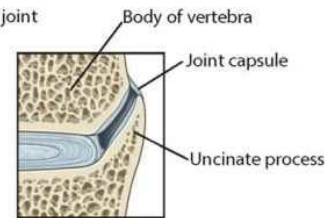
**C5 vertebra superior view**



**C5 vertebra anterior view**



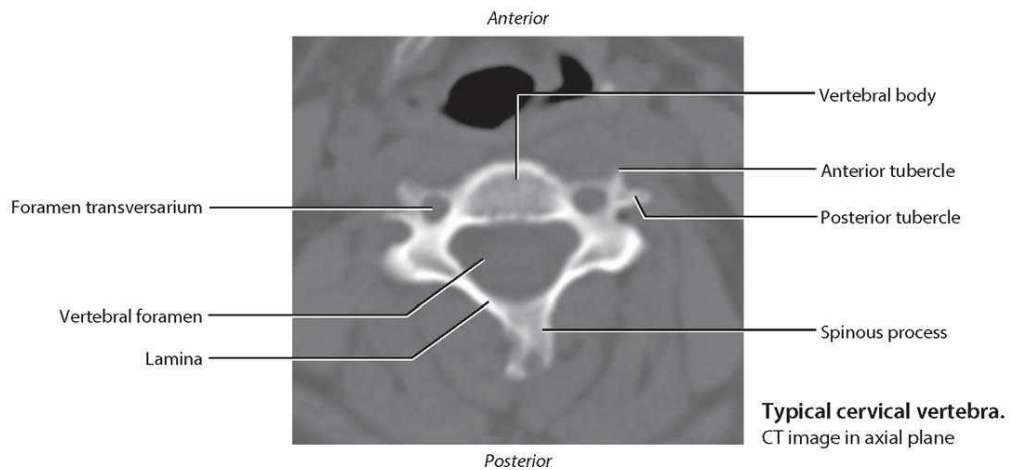
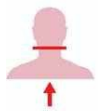
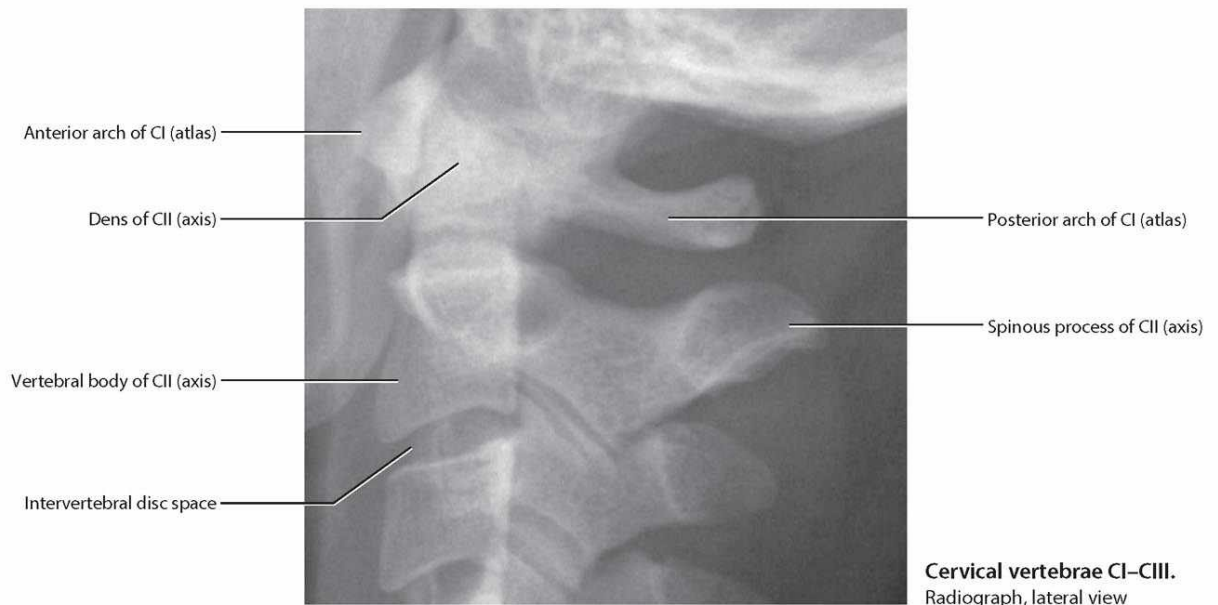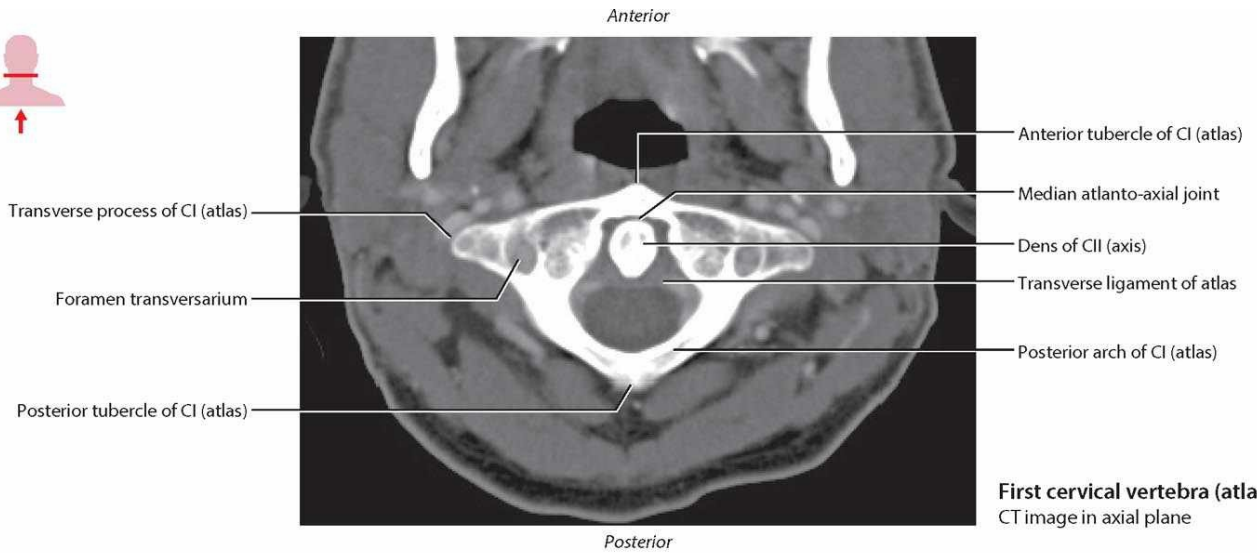
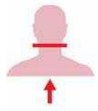
**C4/C5 vertebrae anterior view**



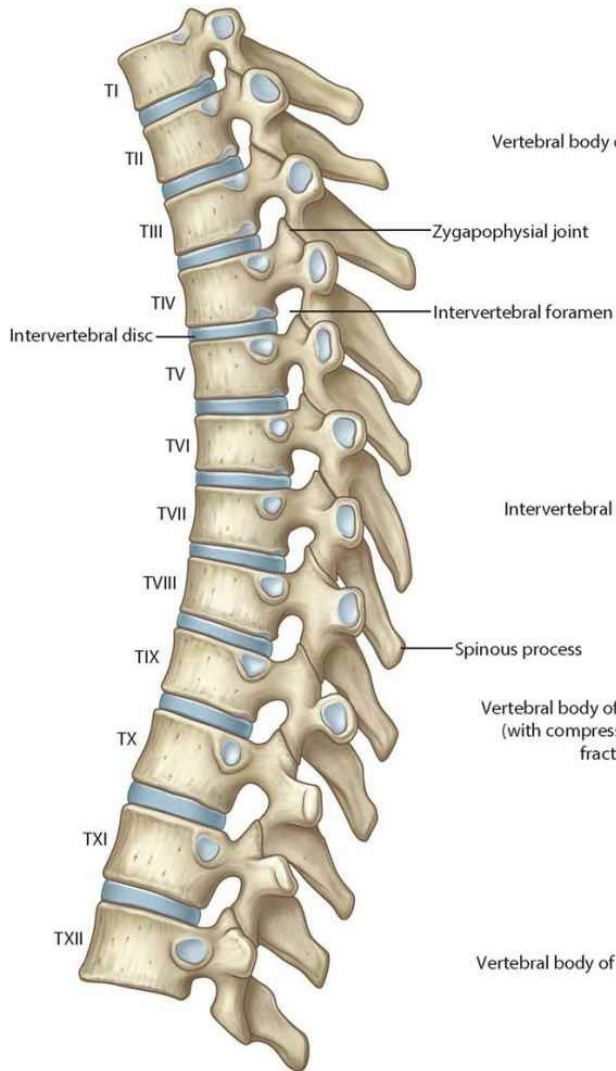
**Uncovertebral joint**



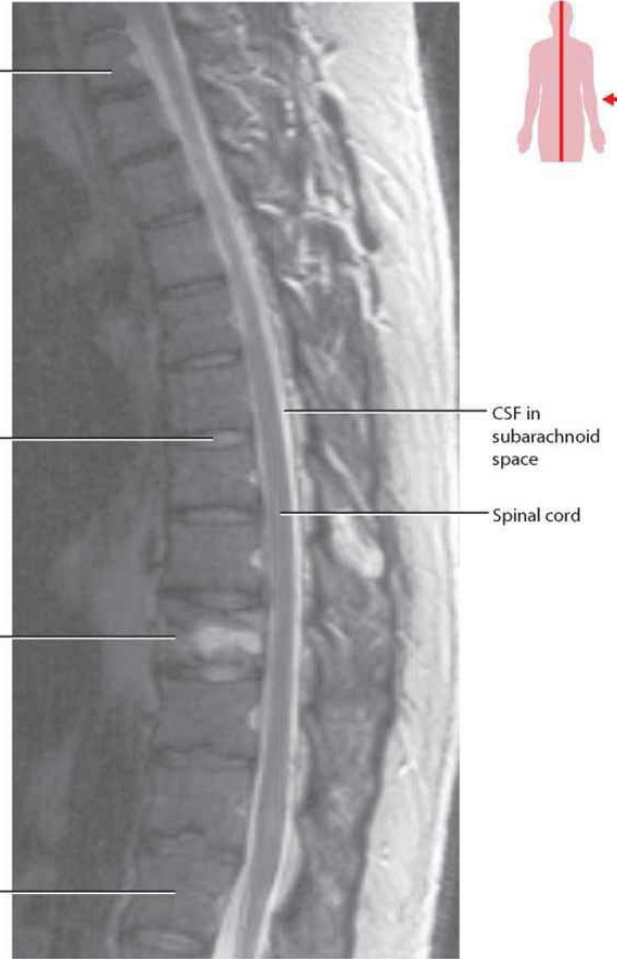




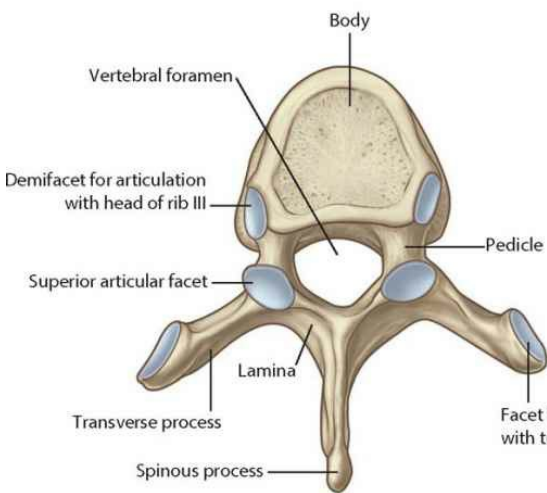
# Thoracic vertebrae



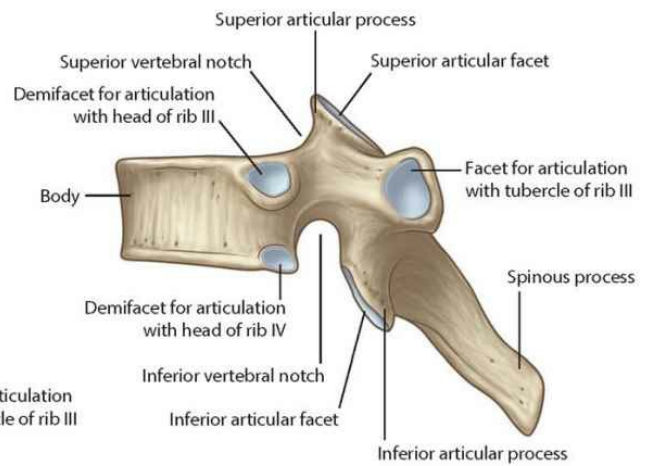
**Thoracic vertebrae lateral view**



**Thoracic region of vertebral column.**  
T2-weighted MR image in sagittal plane (compression fracture TIX)

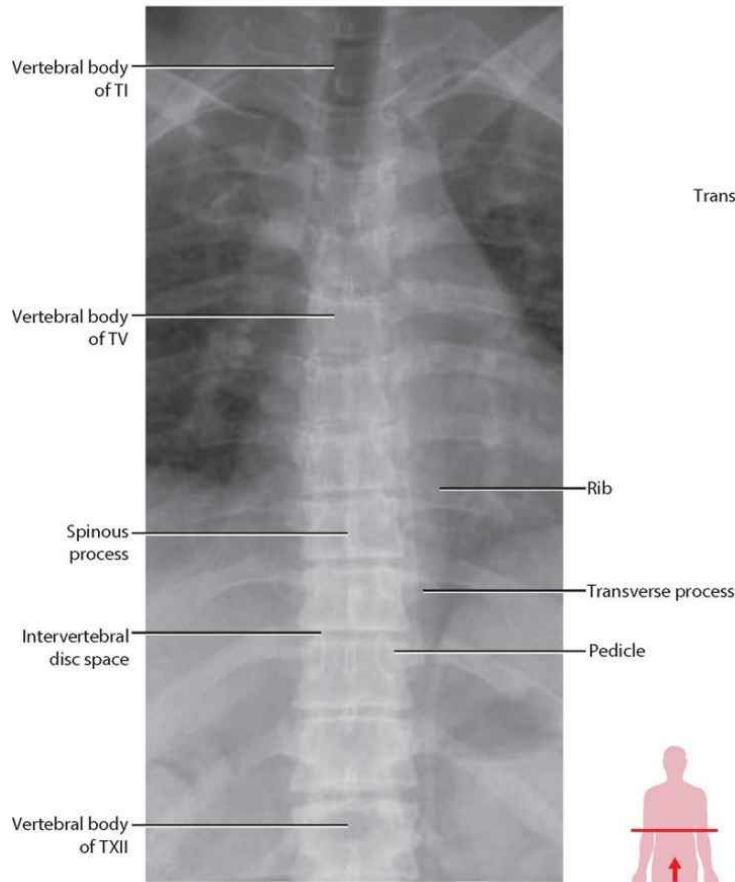


**TIII vertebra superior view**

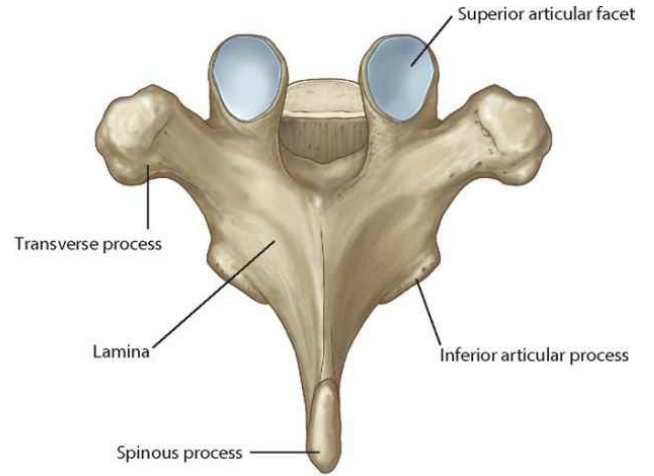


**TIII vertebra lateral view**

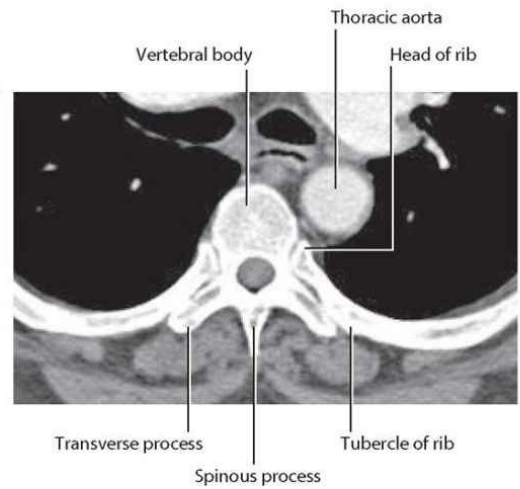




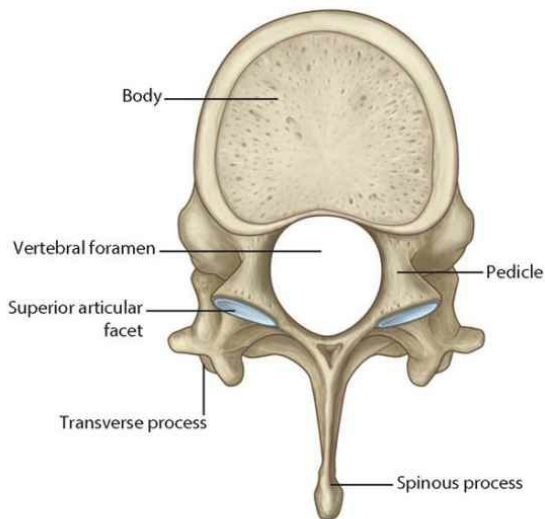
**Thoracic region of vertebral column.**  
Radiograph, AP view



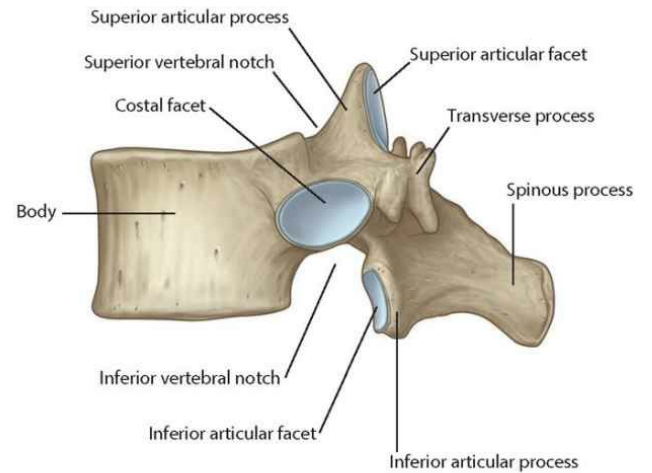
**T11 vertebra posterior view**



**Thoracic vertebra with rib articulations.**  
CT image in axial plane

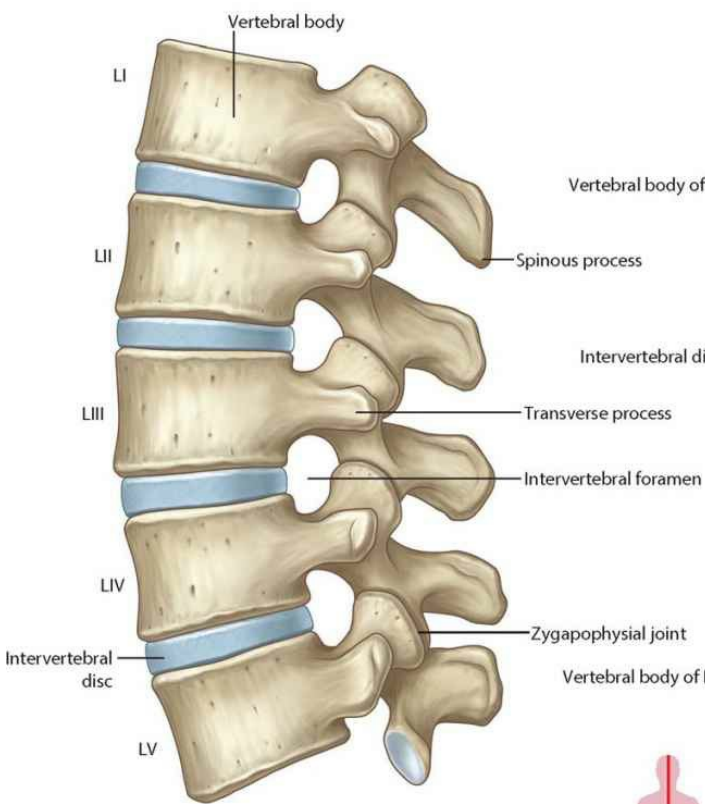


**T12 vertebra superior view**

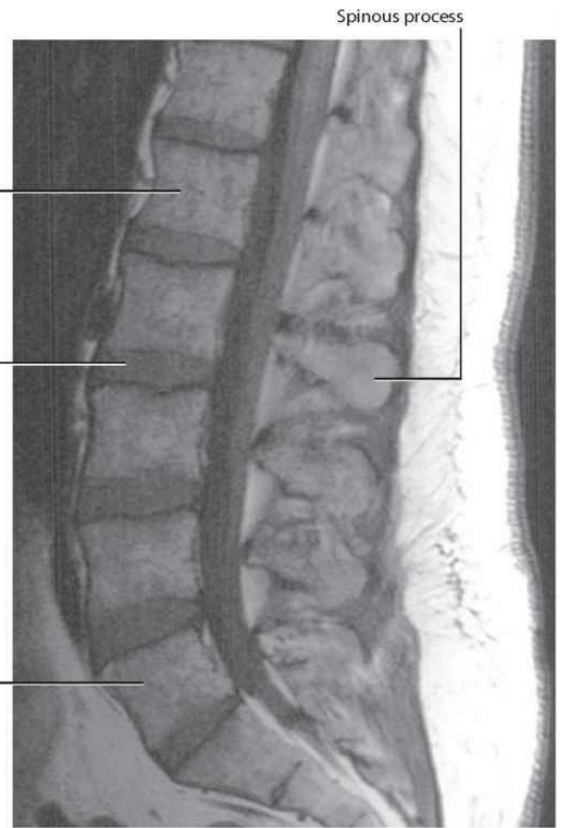


**T12 vertebra lateral view**

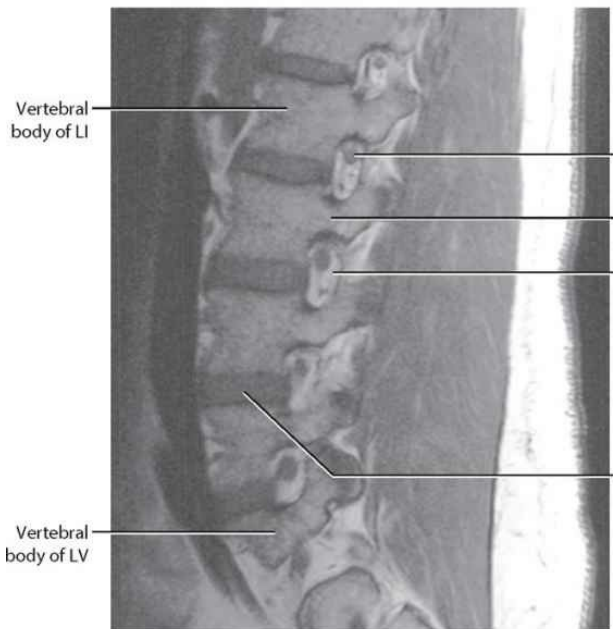
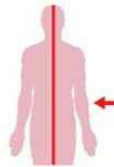
# Lumbar vertebrae



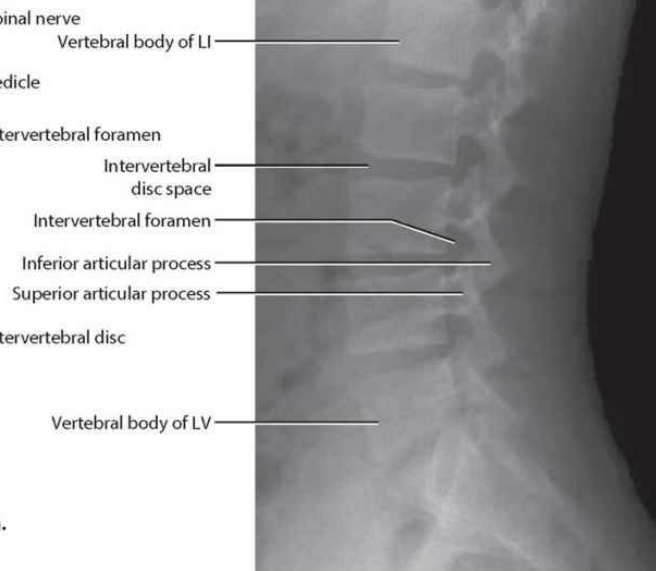
**Lumbar vertebrae lateral view**



**Lumbar region of vertebral column.**  
T1-weighted MR image in sagittal plane

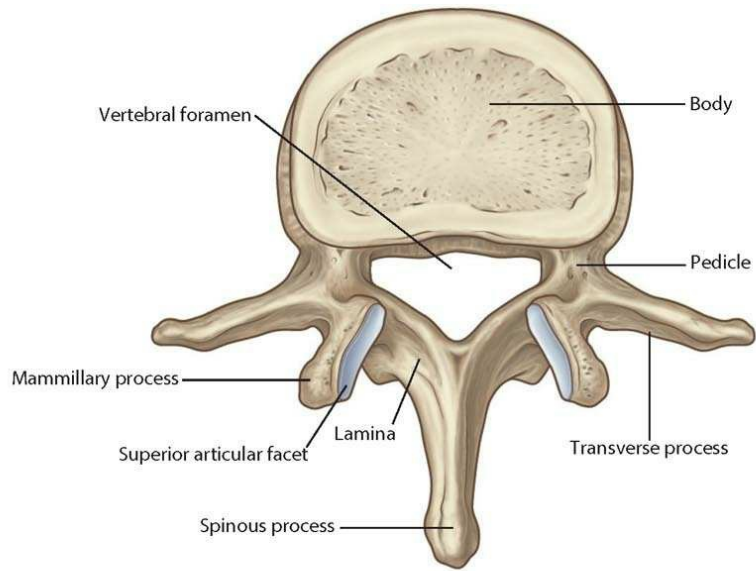


**Intervertebral foramina of lumbar region of vertebral column.**  
T1-weighted MR image in sagittal plane

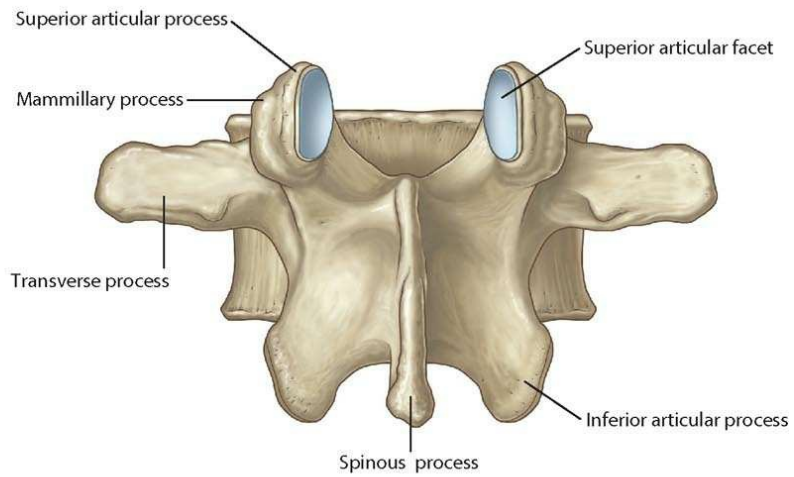


**Lumbar region of vertebral column.**  
Radiograph, lateral view

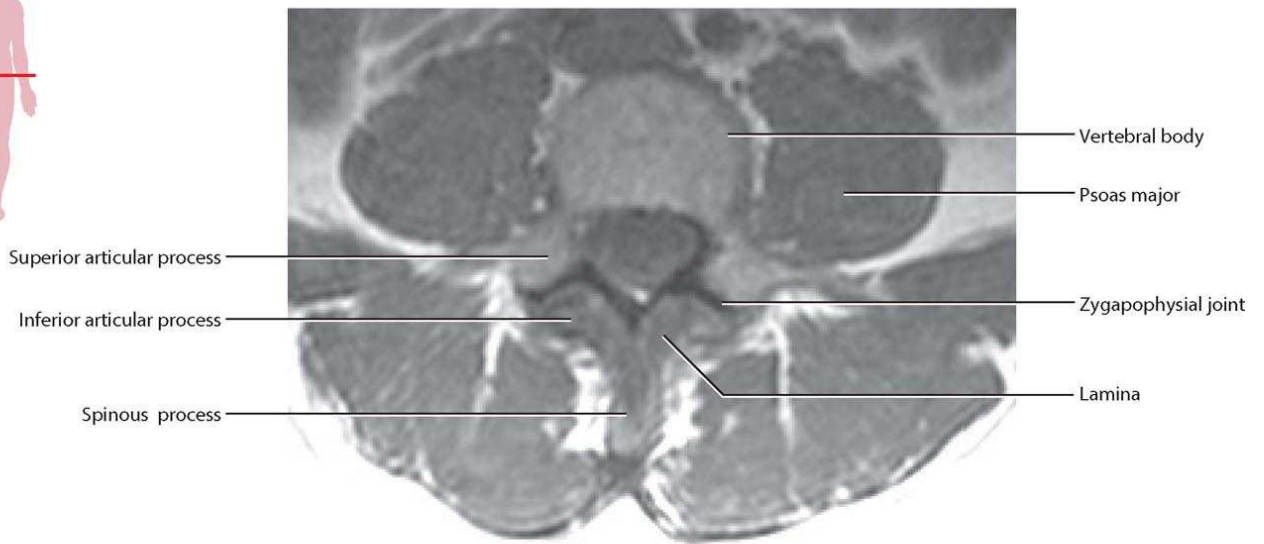
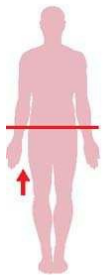




**LIV vertebra superior view**

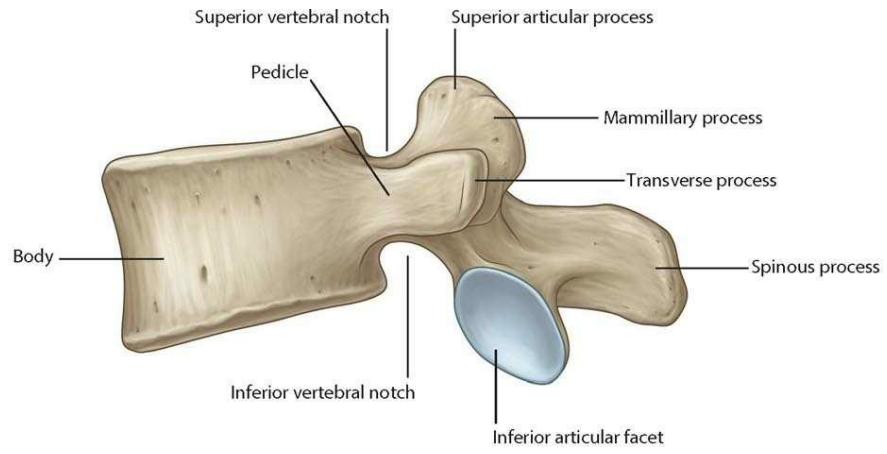


**LIV vertebra posterior view**

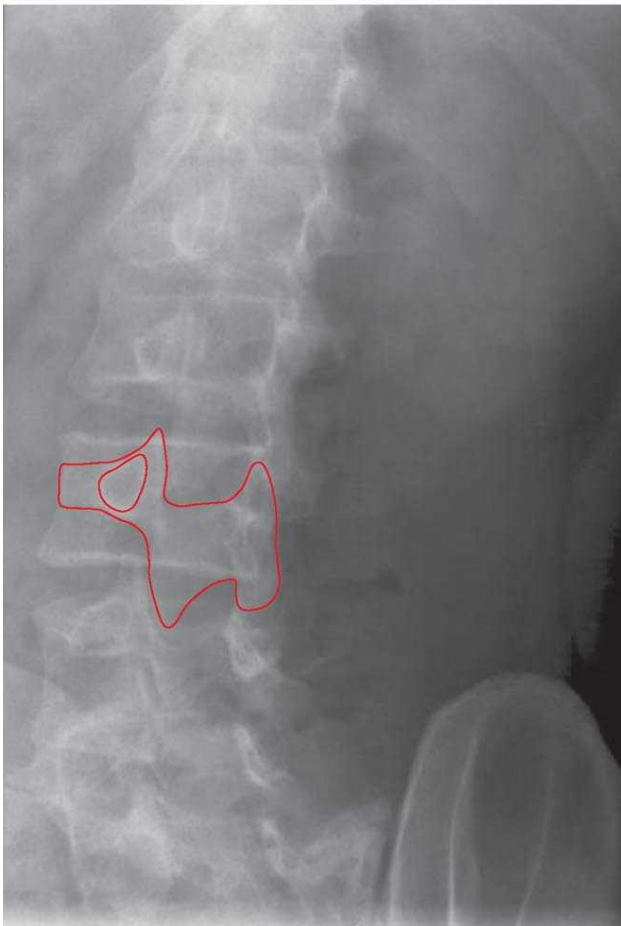


**Articulation of lumbar vertebrae.**  
T1-weighted MR image in axial plane

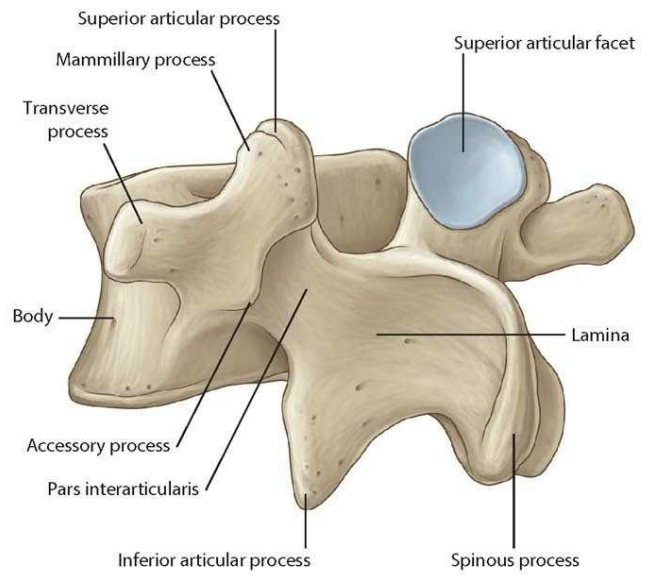




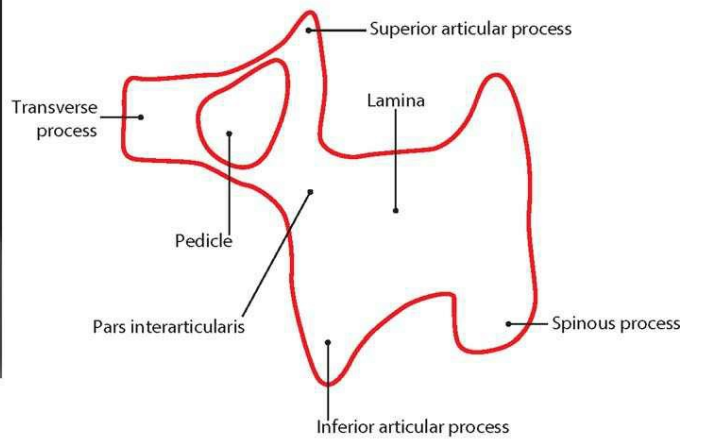
LIV vertebra lateral view



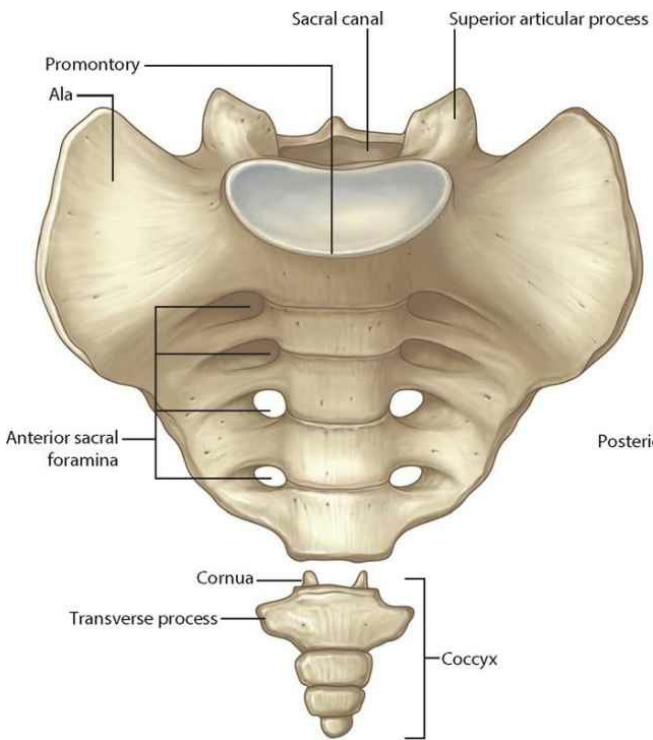
Lumbar region of vertebral column ("Scottie dog").  
Radiograph, oblique view



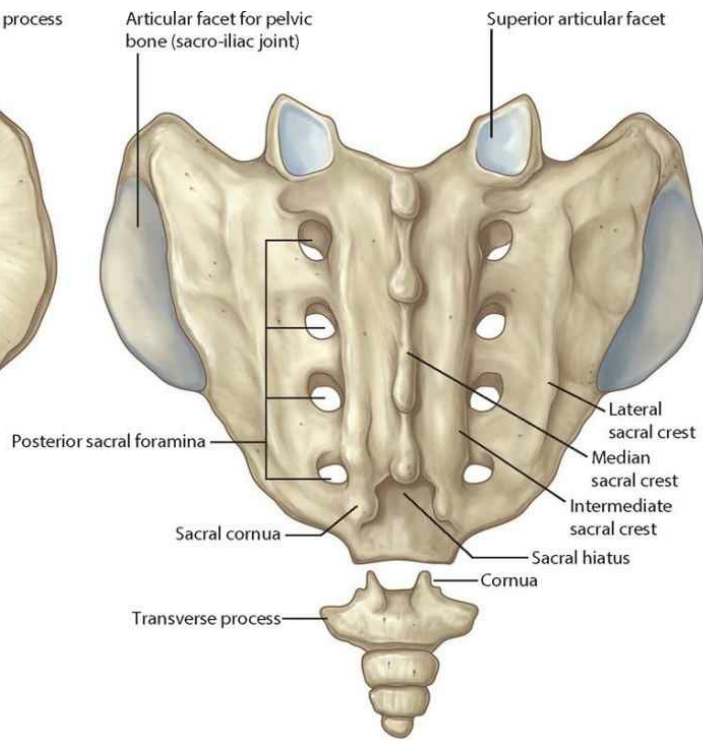
LIV vertebra oblique view



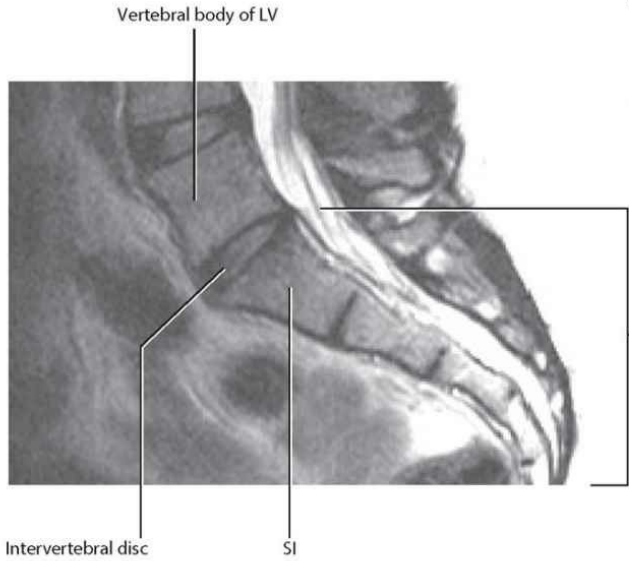
# Sacrum



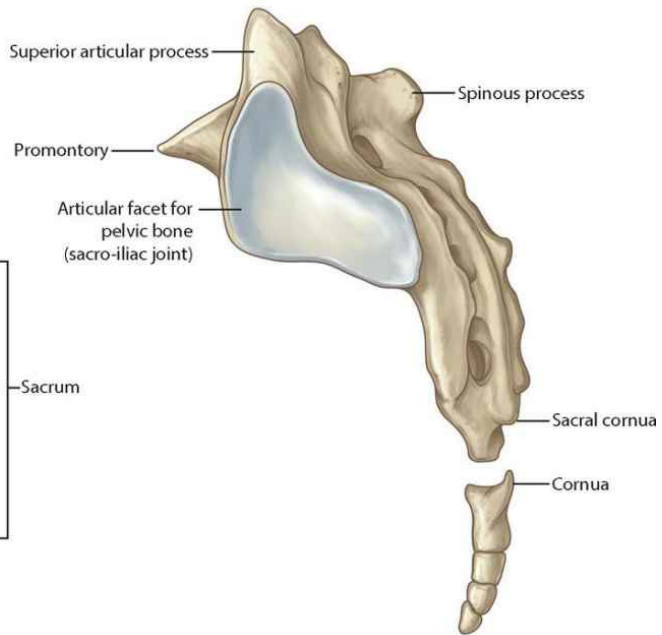
**Sacrum and coccyx anterior view**



**Sacrum and coccyx posterior view**



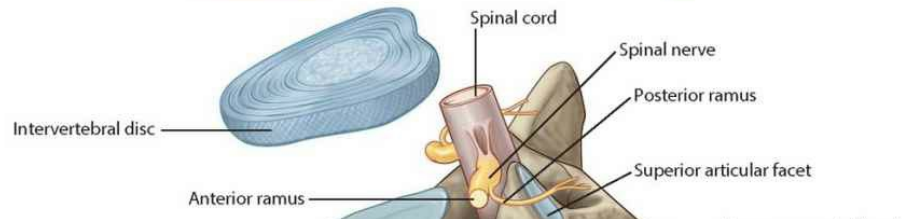
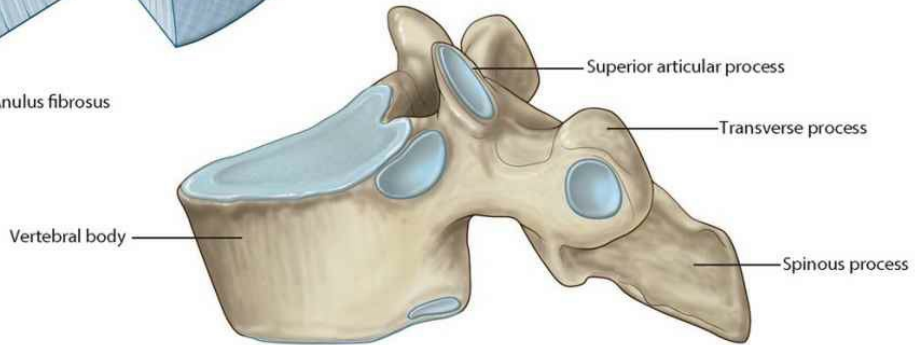
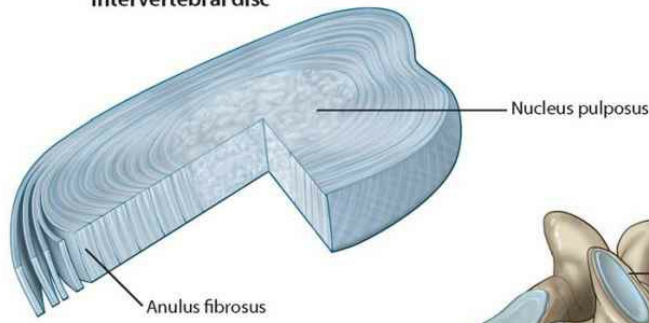
**Sacral region of vertebral column.**  
T2-weighted MR image in sagittal plane



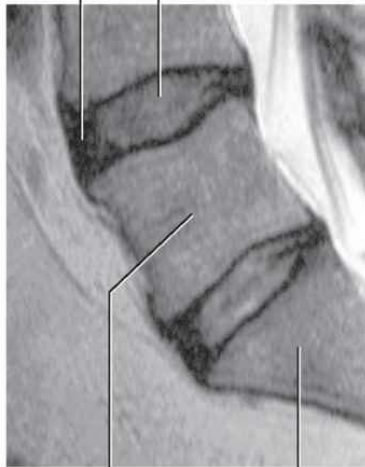
**Sacrum and coccyx lateral view**

# Intervertebral foramina and discs

**Intervertebral disc**

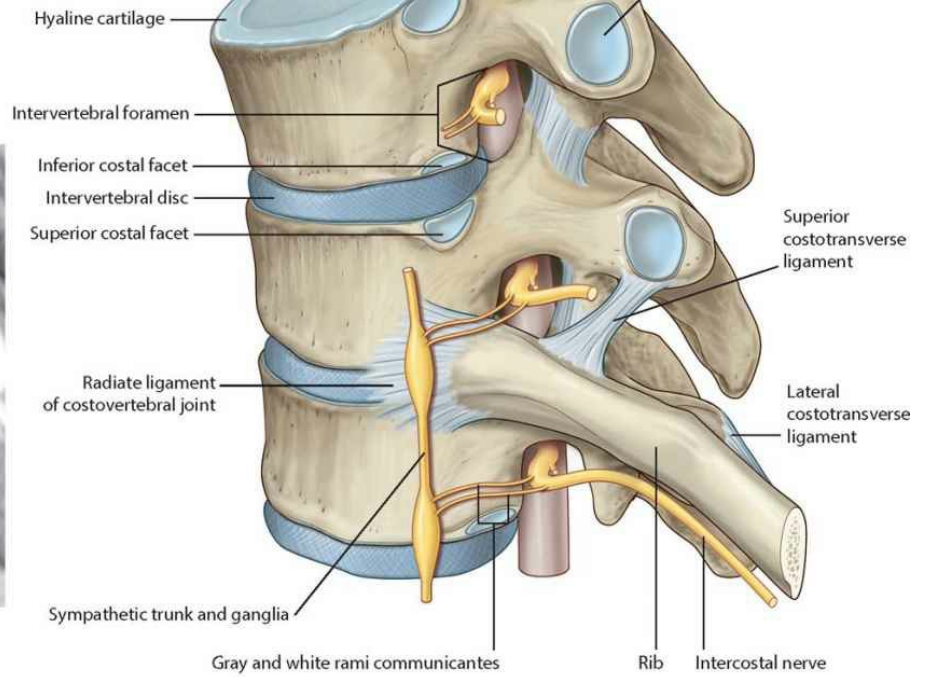


Intervertebral disc  
 Anulus fibrosus    Nucleus pulposus



Vertebral body of LV    Sacrum

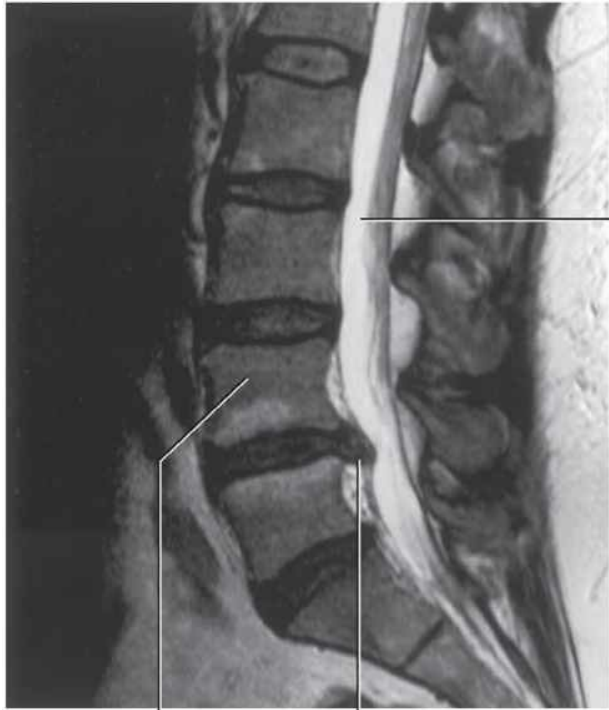**Intervertebral disc in lower lumbar region of vertebral column.**  
 T2-weighted MR image in sagittal plane



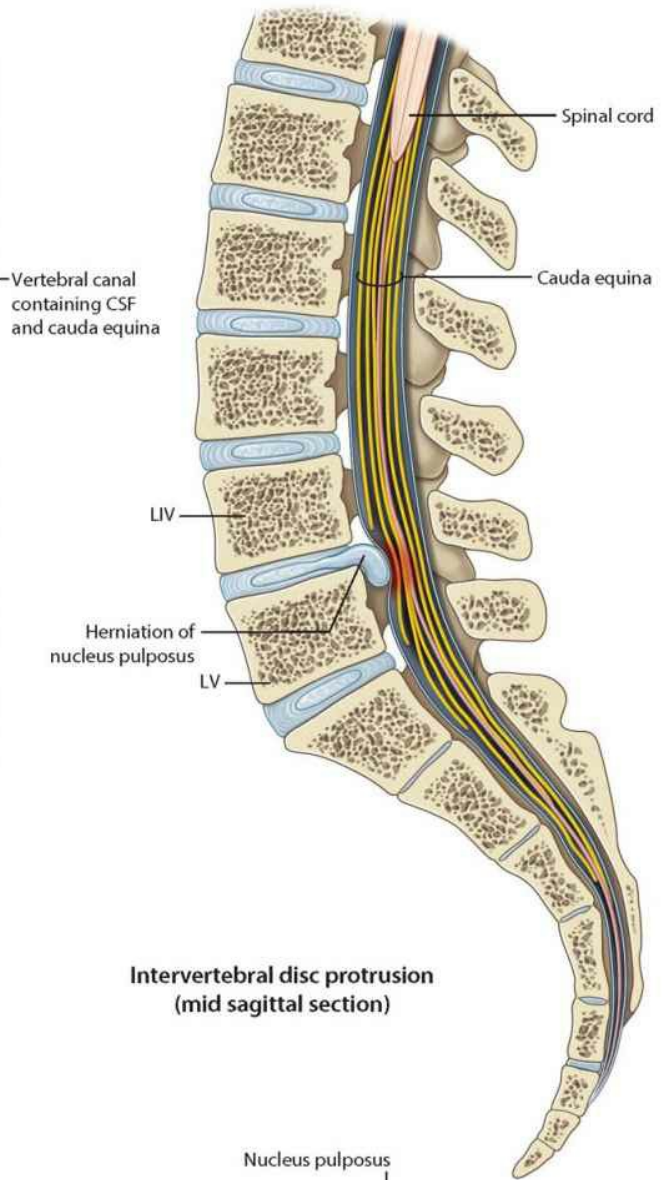
**Intervertebral foramina and discs in the thoracic region**

# Intervertebral disc problems

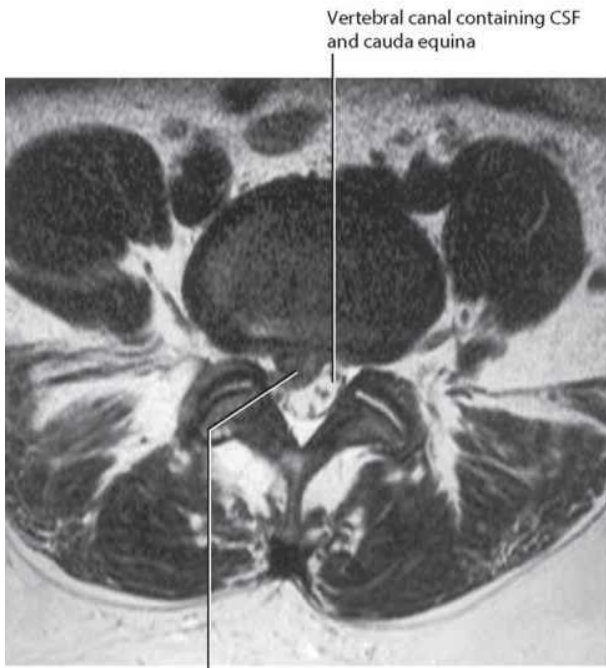




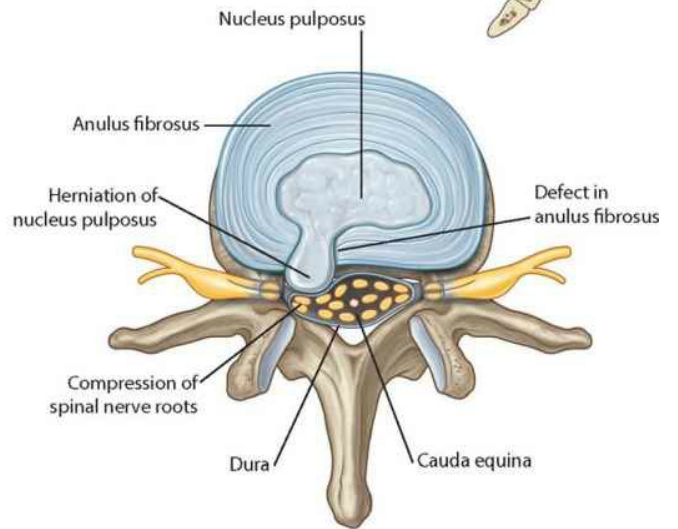
**Intervertebral disc protrusion in lower lumbar region of vertebral column.**  
T2-weighted MR image in sagittal plane



**Intervertebral disc protrusion (mid sagittal section)**

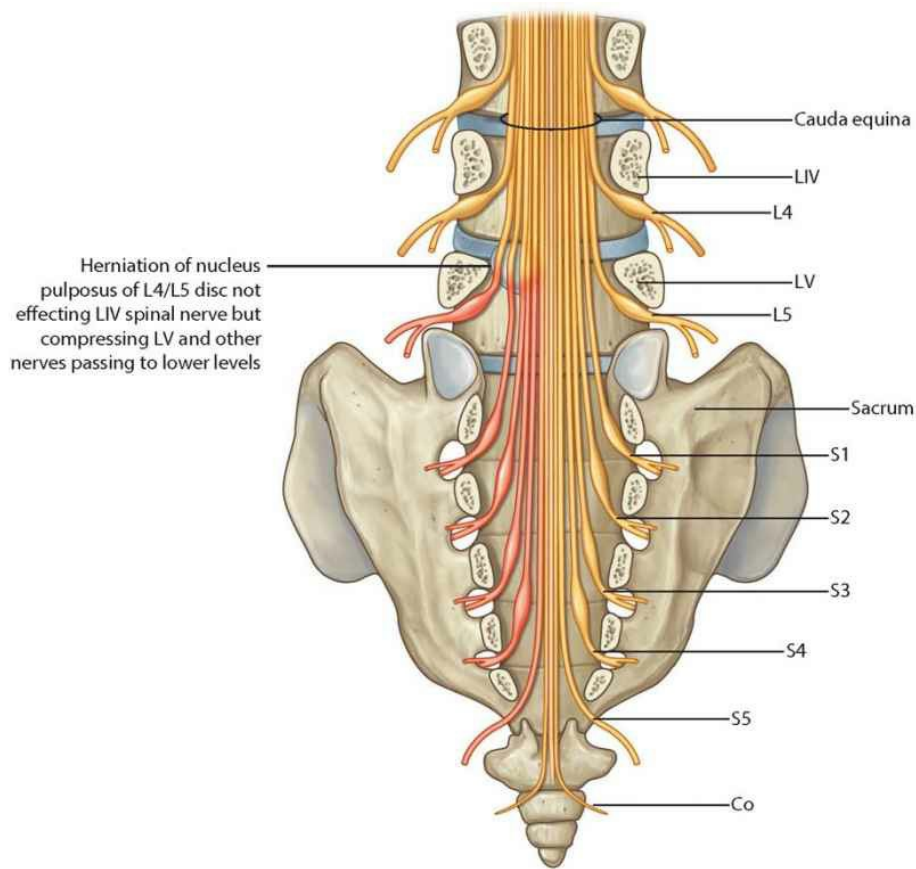


**Intervertebral disc protrusion in lower lumbar region of vertebral column.**  
T2-weighted MR image in axial plane



**Intervertebral disc protrusion (superior view)**

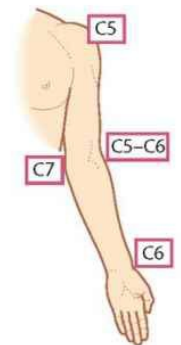




Intervertebral disc protrusion (posterior view)

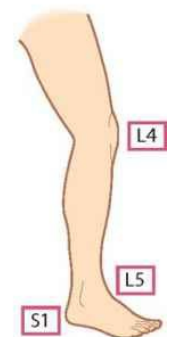
Nerve root	Main weakness	Reflex decreased	Area of sensory decrease	Disc involved
C5	Deltoid (biceps)	(biceps, pectoralis)	Shoulder, upper lateral arm	C4–C5
C6	Wrist extension	(biceps, brachioradialis)	1st and 2nd digits (lateral forearm)	C5–C6
C7	Triceps	Triceps	Third finger	C6–C7
C8	Intrinsic hand muscles		4th and 5th digits (medial forearm)	C7–T1

Clinically important nerve roots in the upper limb

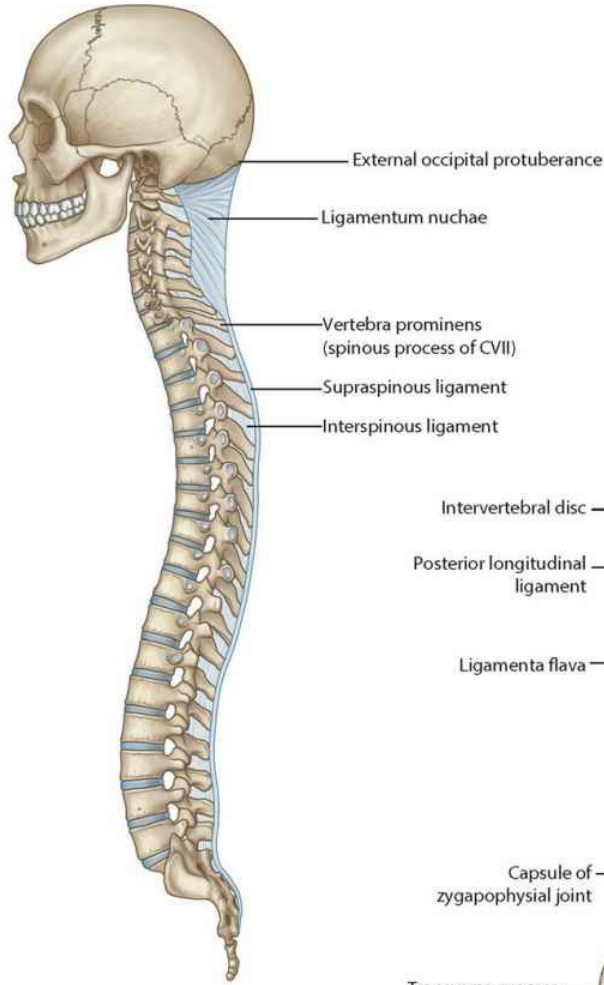


Nerve root	Main weakness	Reflex decreased	Area of sensory decrease	Disc involved
L4	Iliopsoas and quadriceps	Patellar tendon (knee jerk)	Knee, medial lower leg	L3–L4
L5	Dorsiflexion of foot at ankle (big toe extension, foot eversion and inversion)		Dorsum of foot, big toe	L4–L5
S1	Plantar flexion of foot at ankle	Achilles tendon (ankle jerk)	Lateral foot, small toe, sole	L5–S1

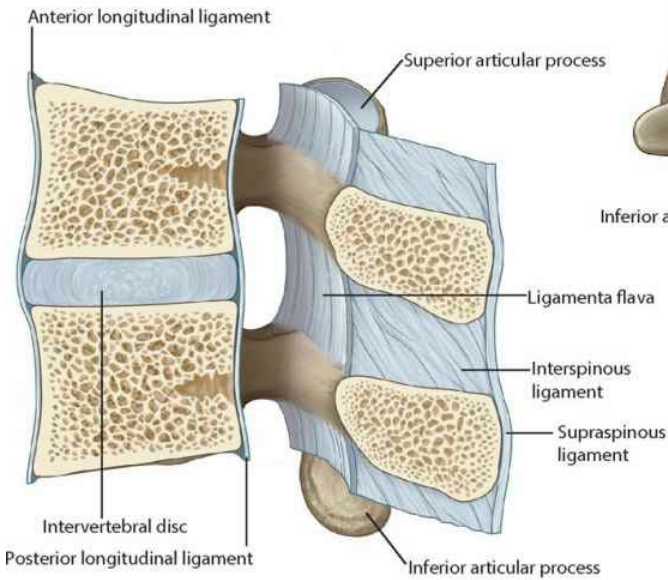
Clinically important nerve roots in the lower limb



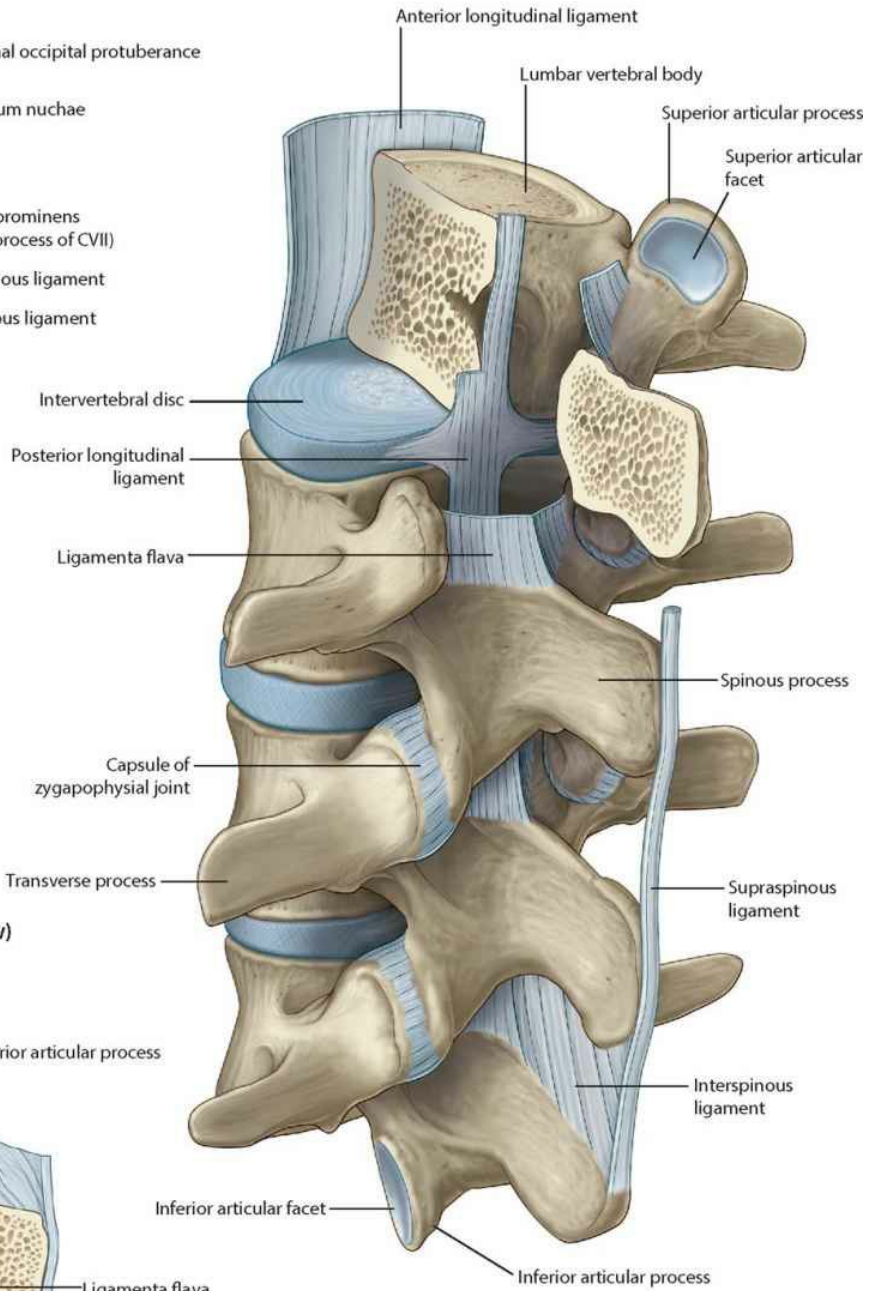
# Joint and ligaments



**Ligamentum nuchae and supraspinous ligament (lateral view)**

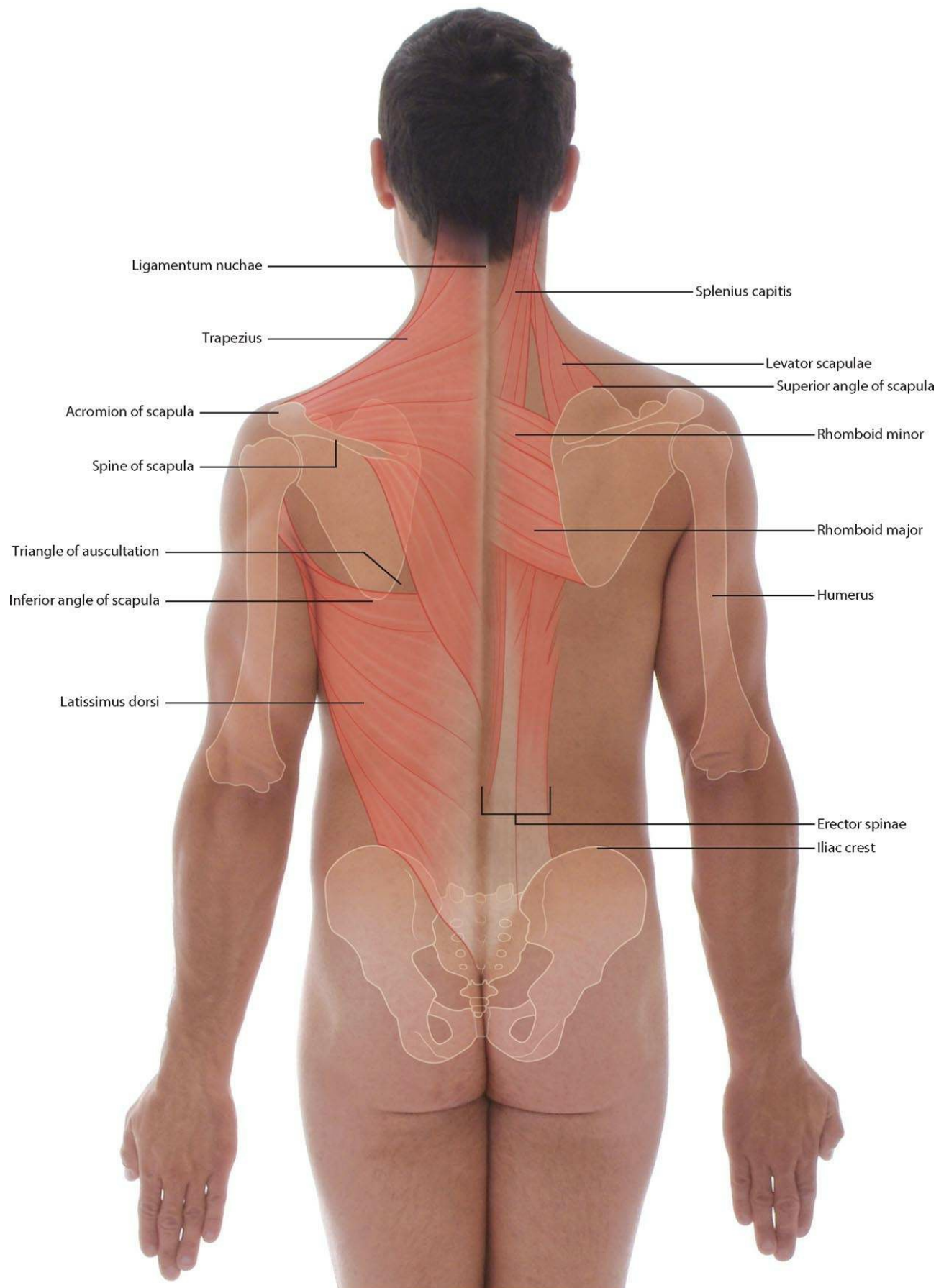


**Ligamenta flava**



**Vertebral ligaments of the lumbar region (posterior oblique view)**

# Back musculature: surface anatomy

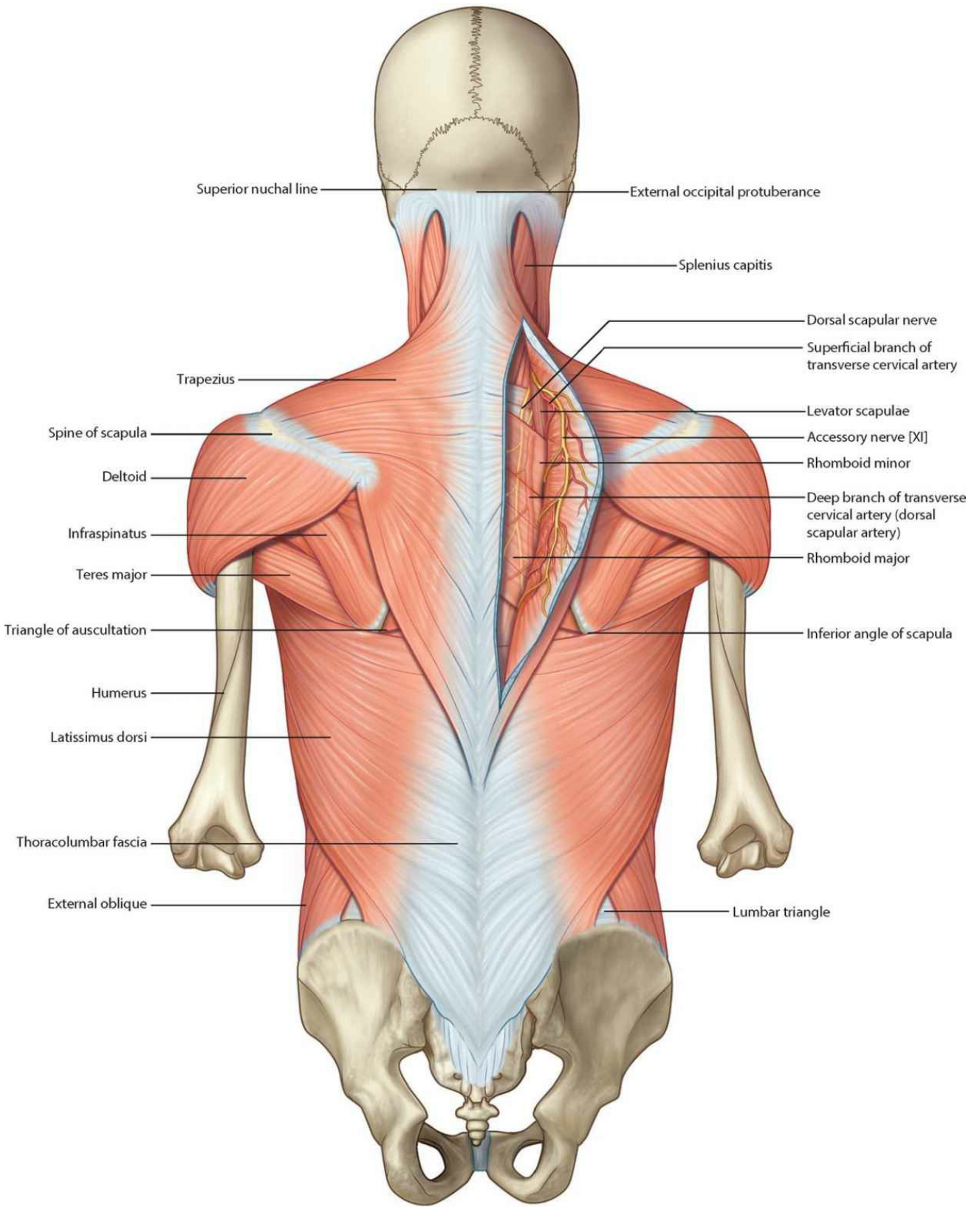


Posterior view of male showing surface projections of back muscles



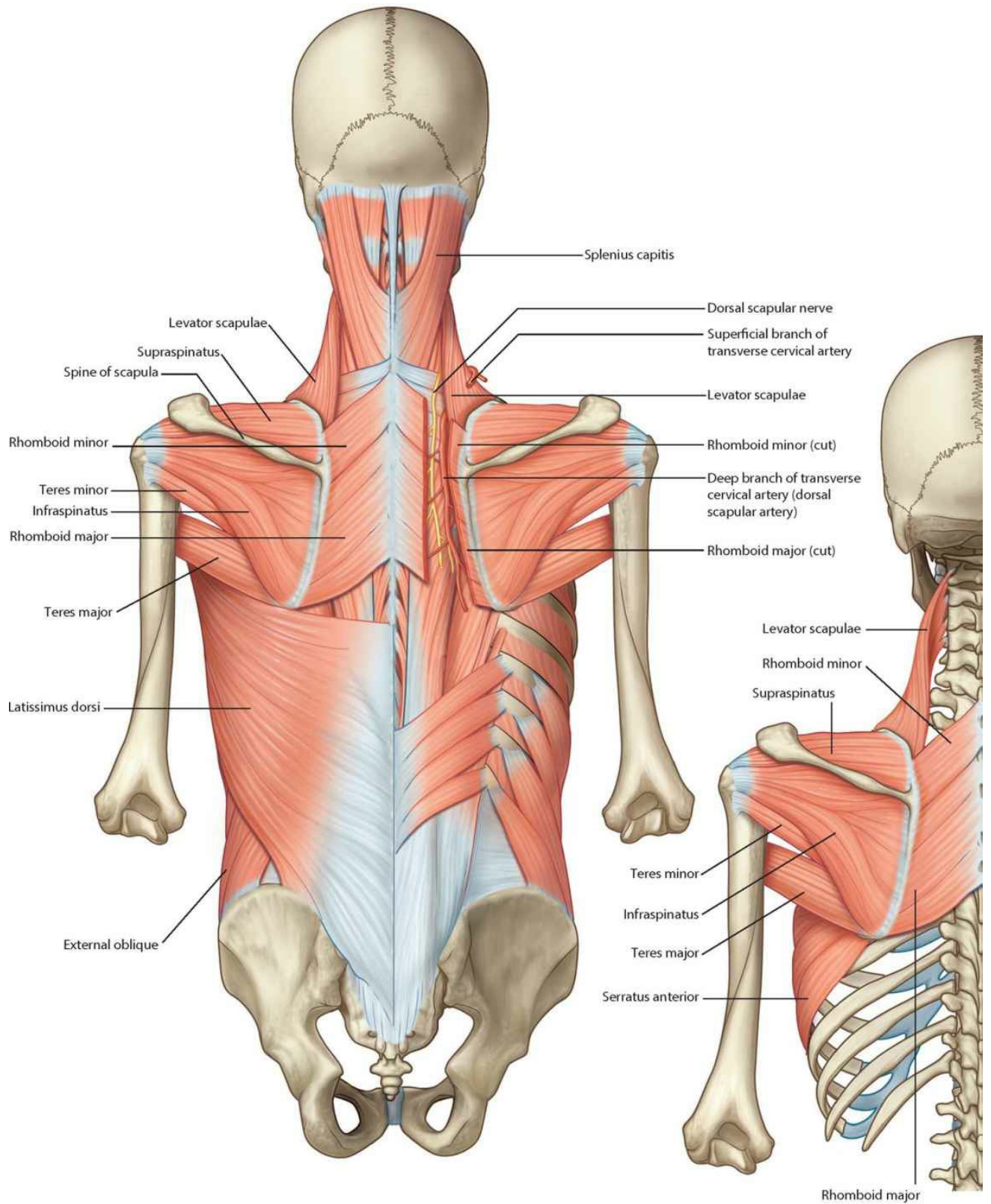


# Superficial musculature



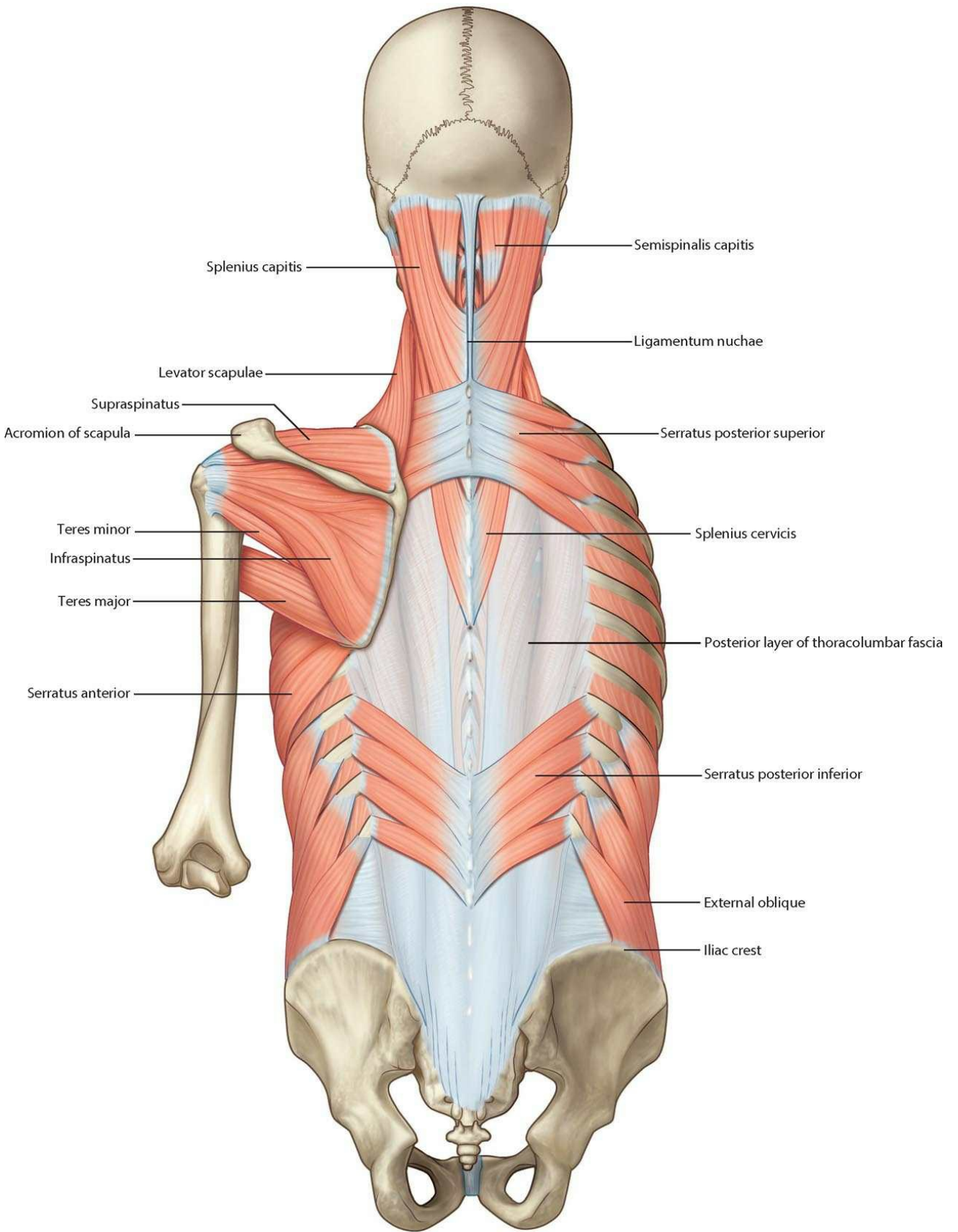
Superficial musculature – trapezius and latissimus dorsi





Superficial musculature – levator scapulae and rhomboid major and minor

# Intermediate musculature

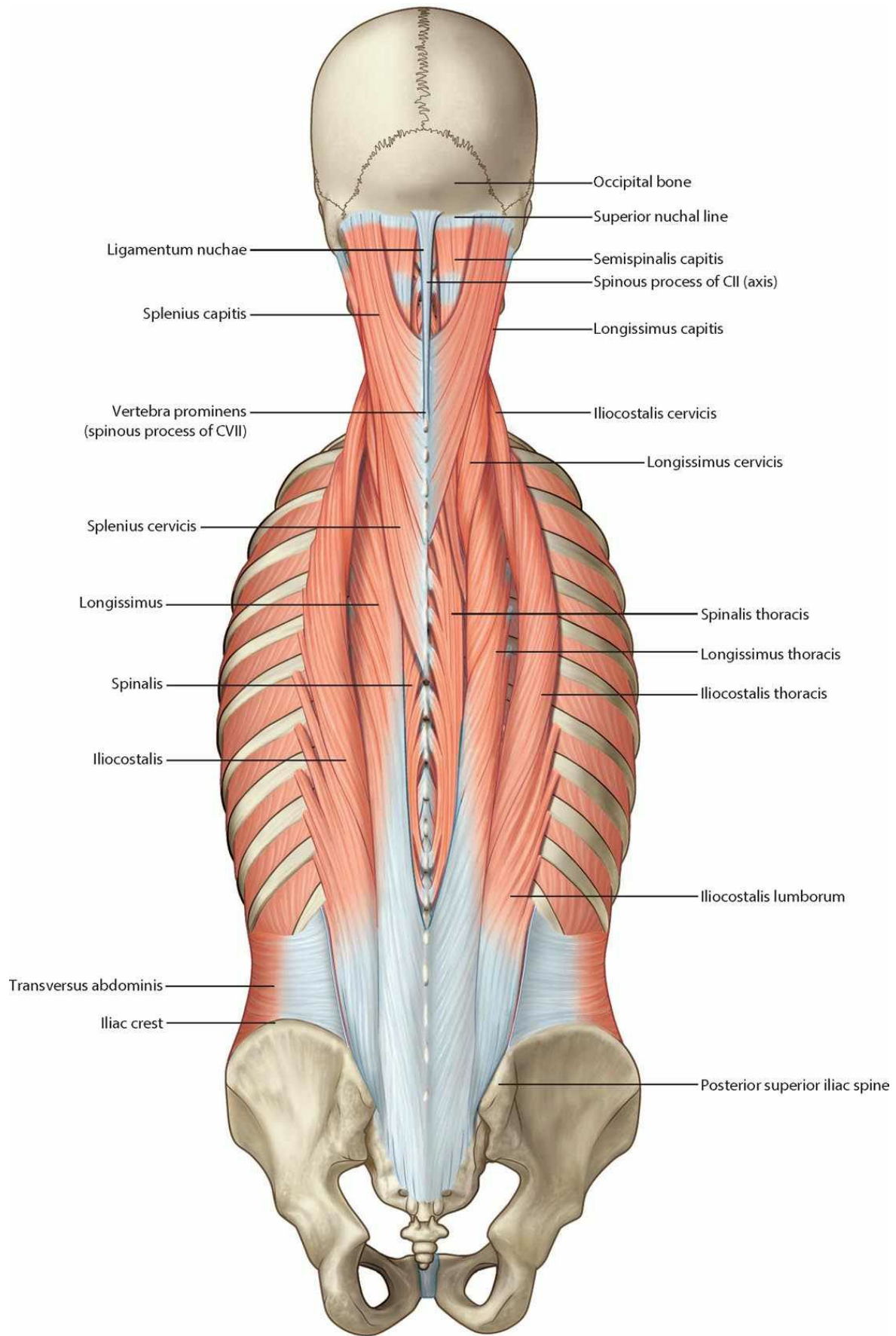


Intermediate musculature



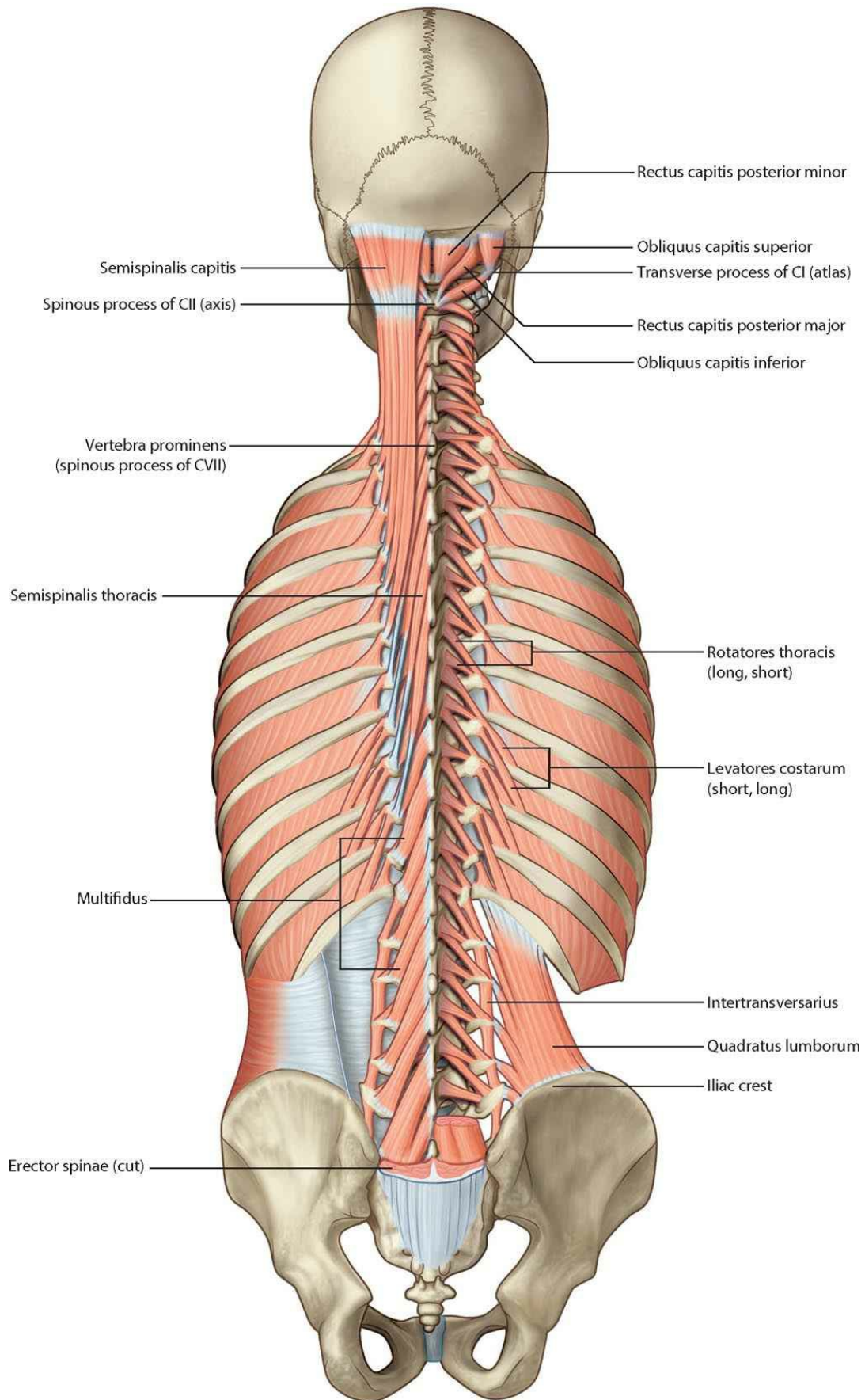
# Deep musculature





Deep group of back muscles – erector spinae muscles

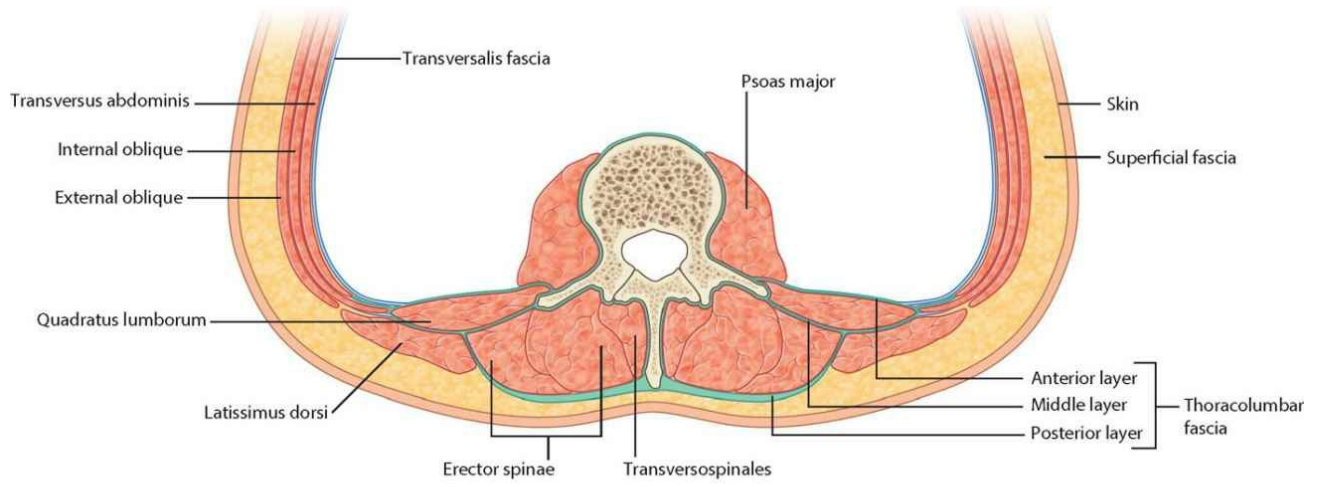




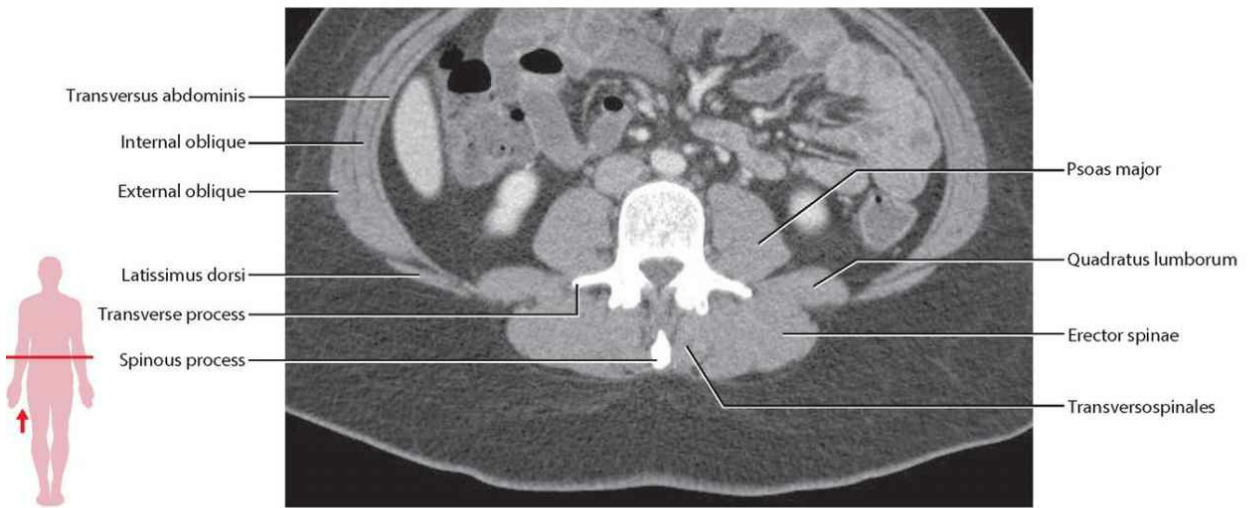
Deep group of back muscles – transversospinales and segmental muscles



## **Back musculature: transverse section**

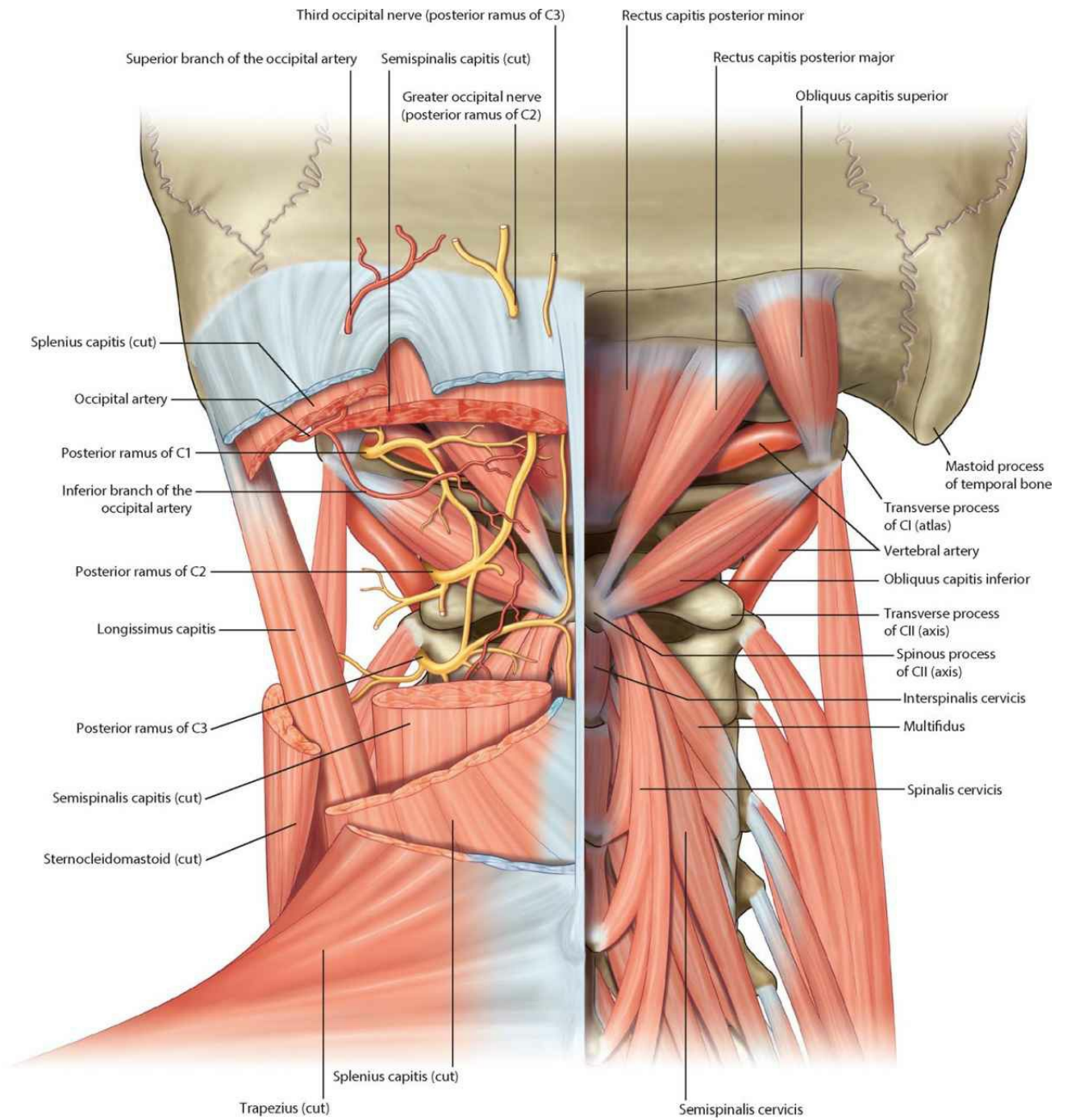


**Thoracolumbar fascia and the deep back muscles  
(transverse section – lumbar region)**



**Lumbar region (LIII) showing back musculature.  
CT image in axial plane**

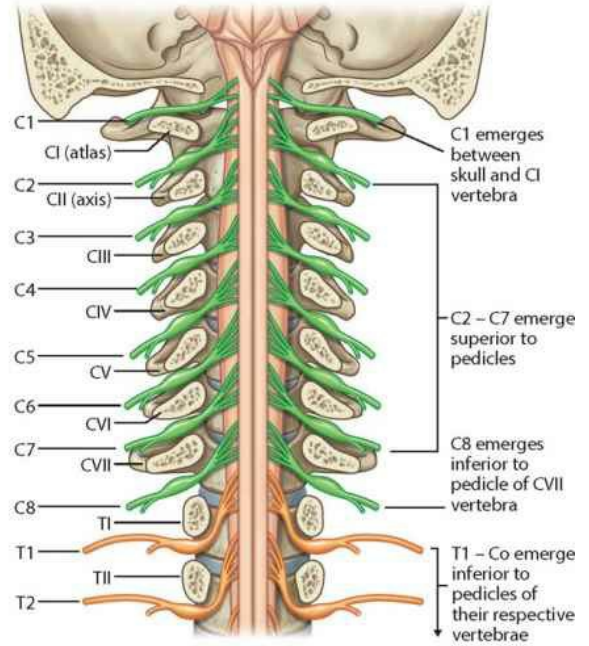
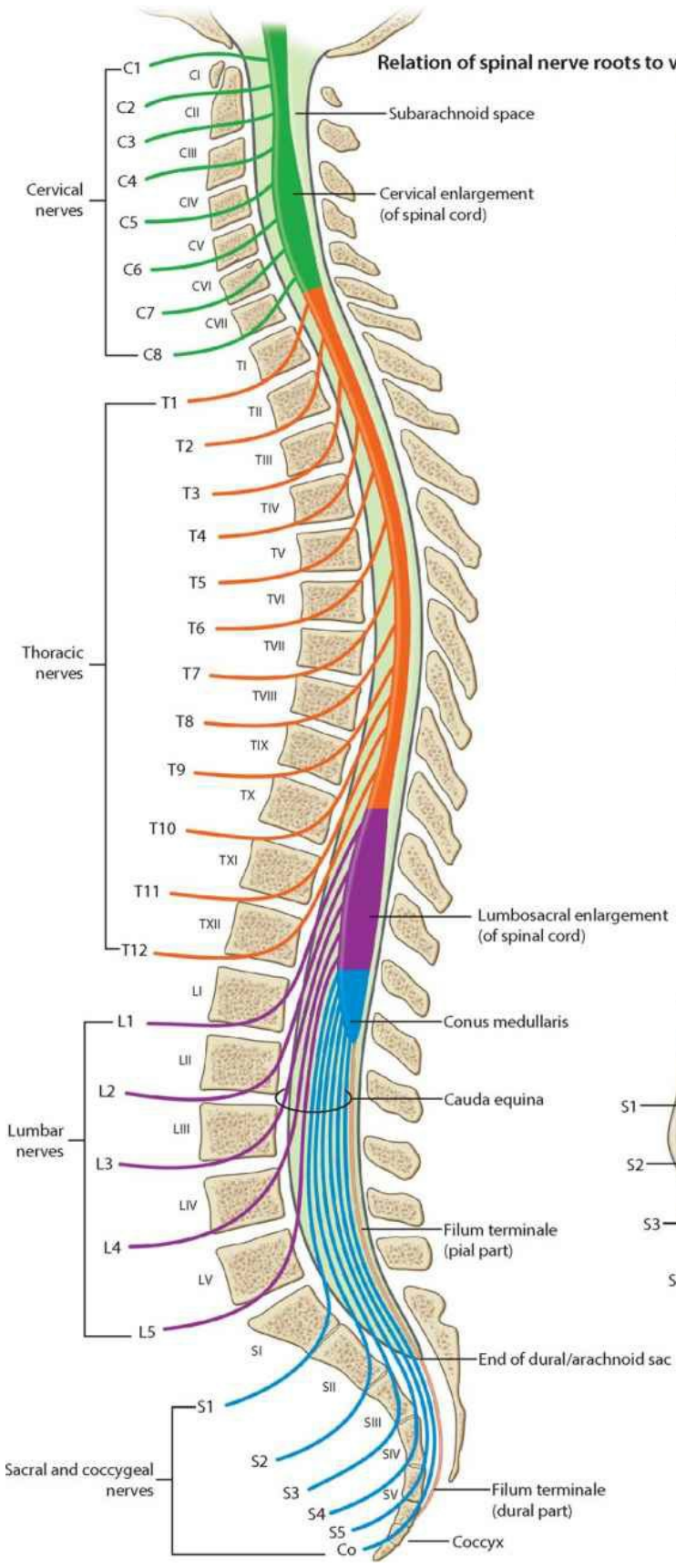
# Suboccipital region



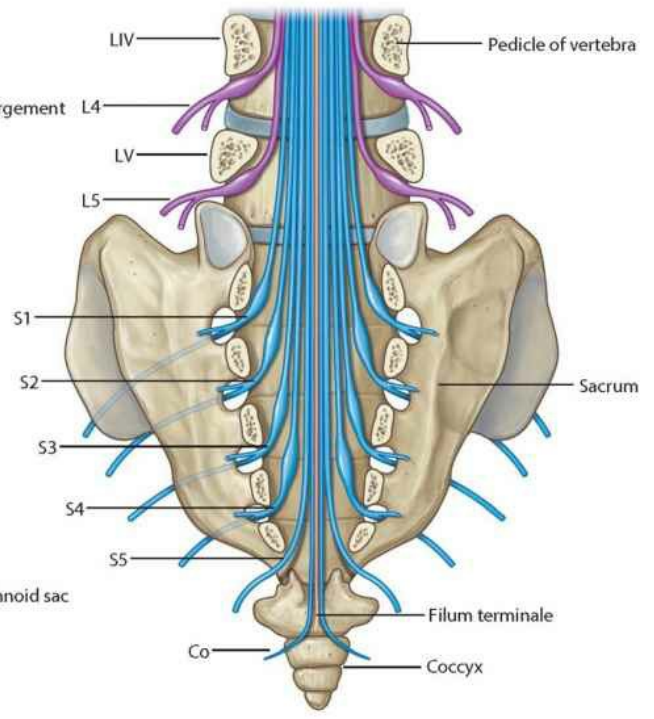
Suboccipital region



# Spinal nerves

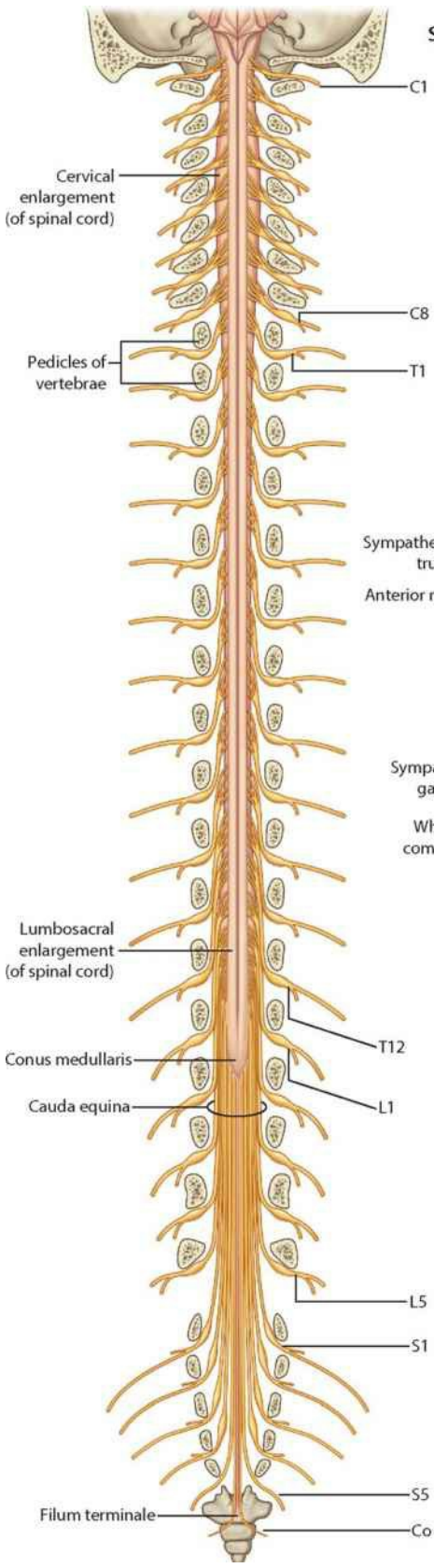


**Nomenclature of spinal nerves (posterior view)**

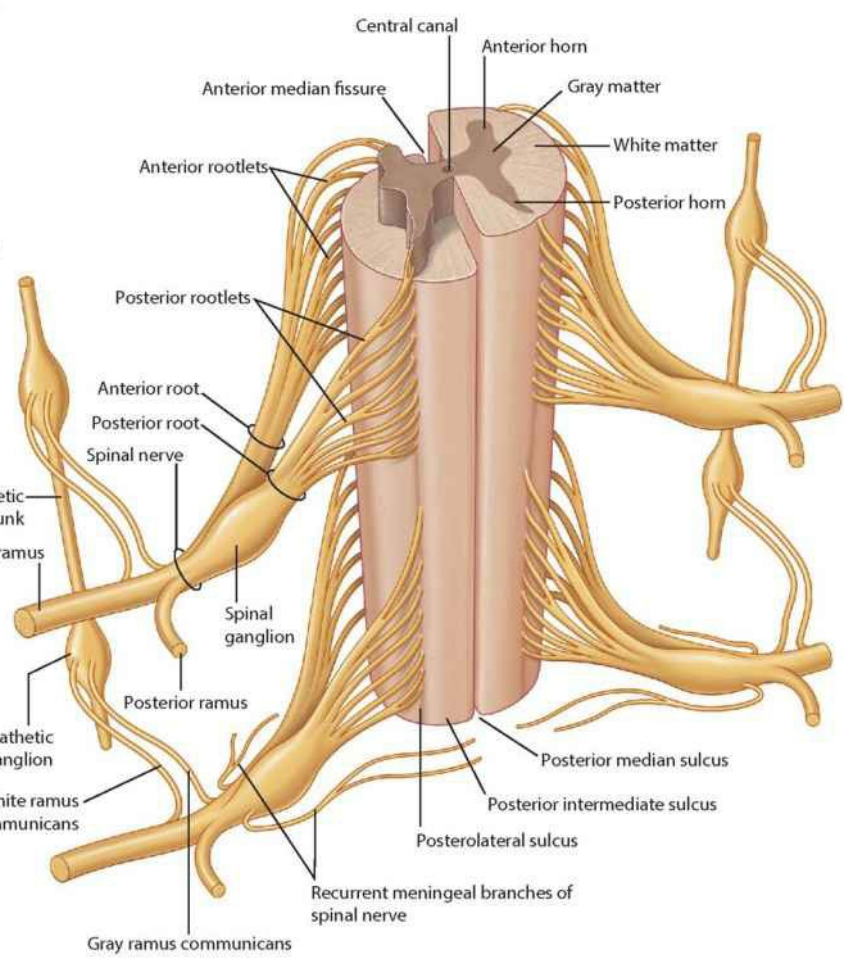


**Sacral and coccygeal nerves (posterior view - vertebral arches removed)**

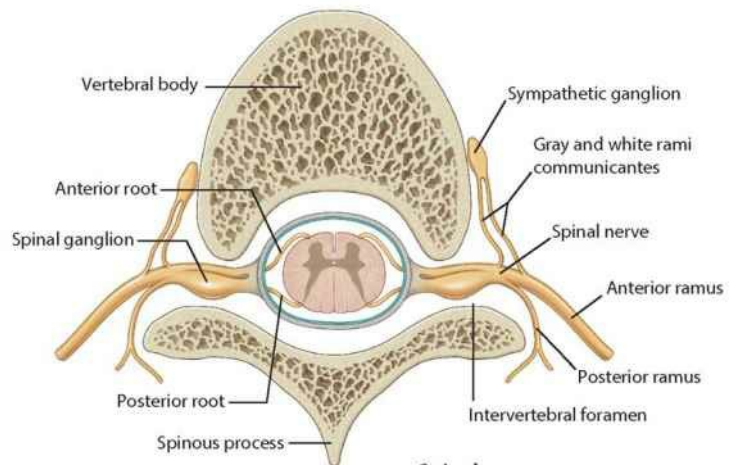
# Spinal cord



**Spinal cord and spinal nerves in vertebral canal**

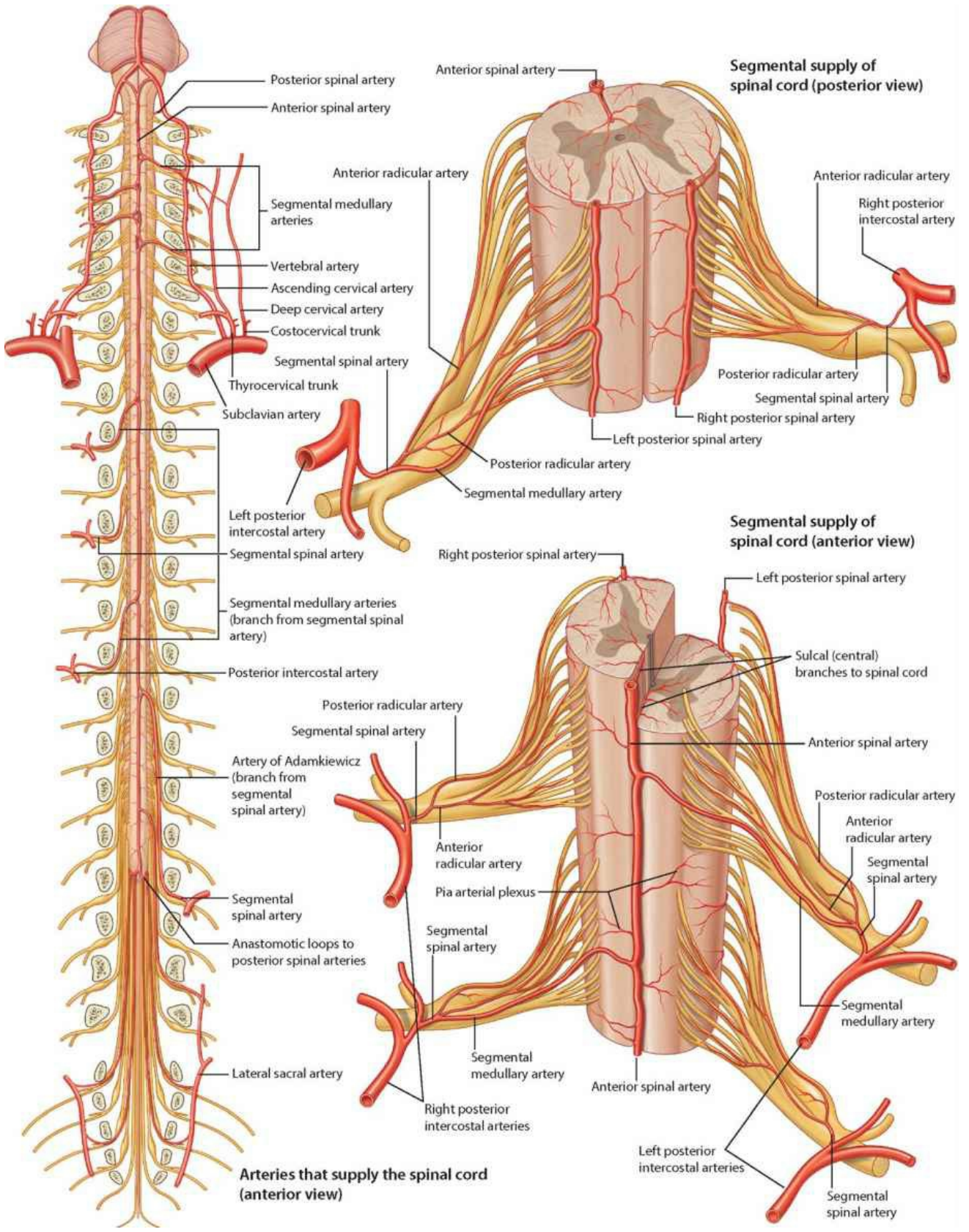


**Features of the spinal cord (thoracic region) and basic organization of a spinal nerve (posterior view)**



**Spinal nerves (transverse section)**

# Spinal cord vasculature



**Segmental supply of spinal cord (posterior view)**

**Segmental supply of spinal cord (anterior view)**

**Arteries that supply the spinal cord (anterior view)**

Posterior spinal artery  
Anterior spinal artery

Anterior spinal artery

Segmental medullary arteries

Vertebral artery  
Ascending cervical artery  
Deep cervical artery  
Costocervical trunk

Segmental spinal artery

Thyrocervical trunk  
Subclavian artery

Left posterior intercostal artery  
Segmental spinal artery

Segmental medullary arteries (branch from segmental spinal artery)

Posterior intercostal artery

Artery of Adamkiewicz (branch from segmental spinal artery)

Segmental spinal artery

Anastomotic loops to posterior spinal arteries

Lateral sacral artery

Anterior radicular artery

Posterior radicular artery  
Segmental medullary artery

Right posterior spinal artery

Posterior radicular artery  
Segmental spinal artery

Anterior radicular artery  
Pia arterial plexus

Segmental spinal artery

Segmental medullary artery

Right posterior intercostal arteries

Anterior radicular artery  
Right posterior intercostal artery

Posterior radicular artery  
Segmental spinal artery

Right posterior spinal artery  
Left posterior spinal artery

Left posterior spinal artery

Sulcal (central) branches to spinal cord

Anterior spinal artery

Posterior radicular artery  
Anterior radicular artery

Segmental spinal artery

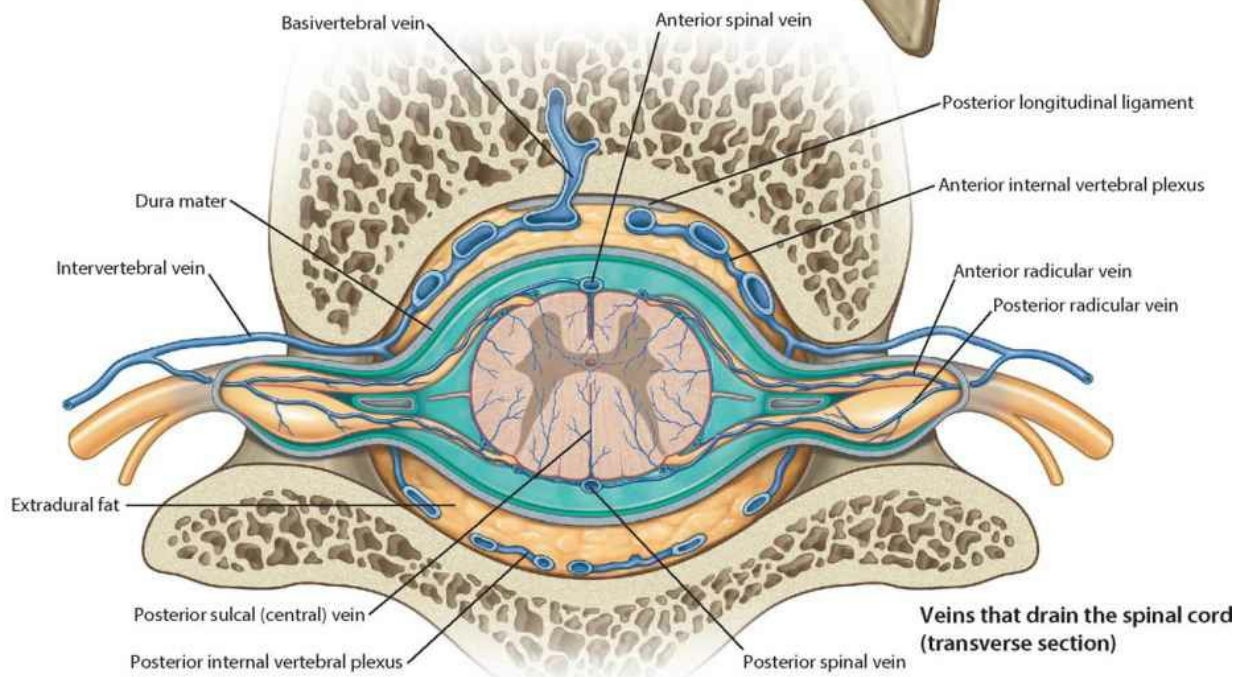
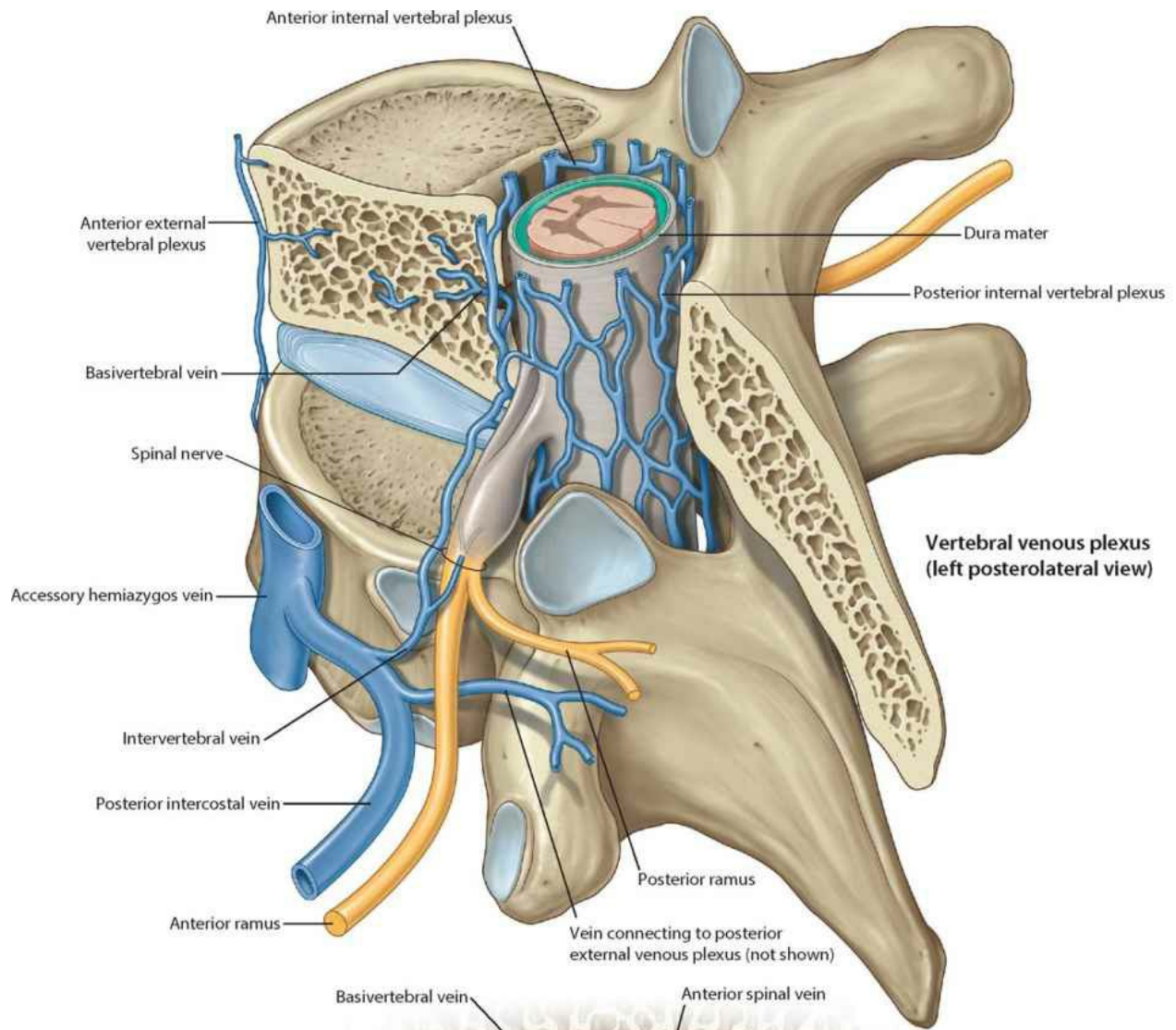
Segmental medullary artery

Anterior spinal artery

Left posterior intercostal arteries

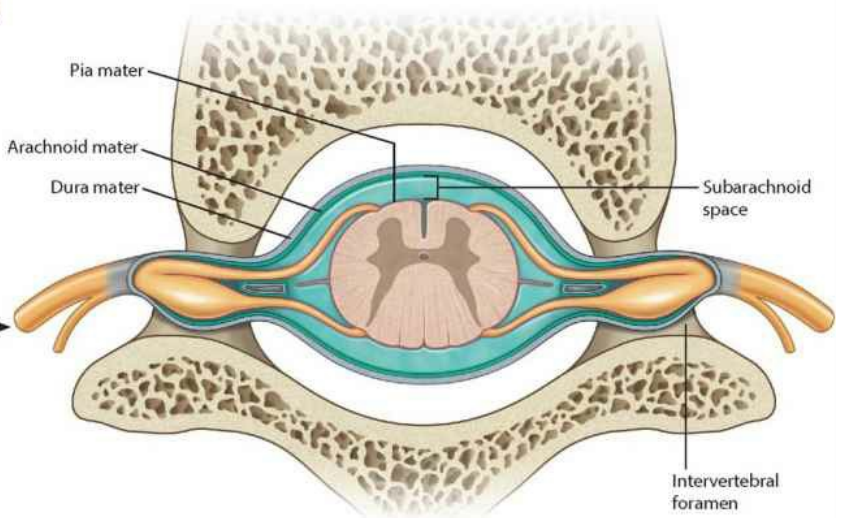
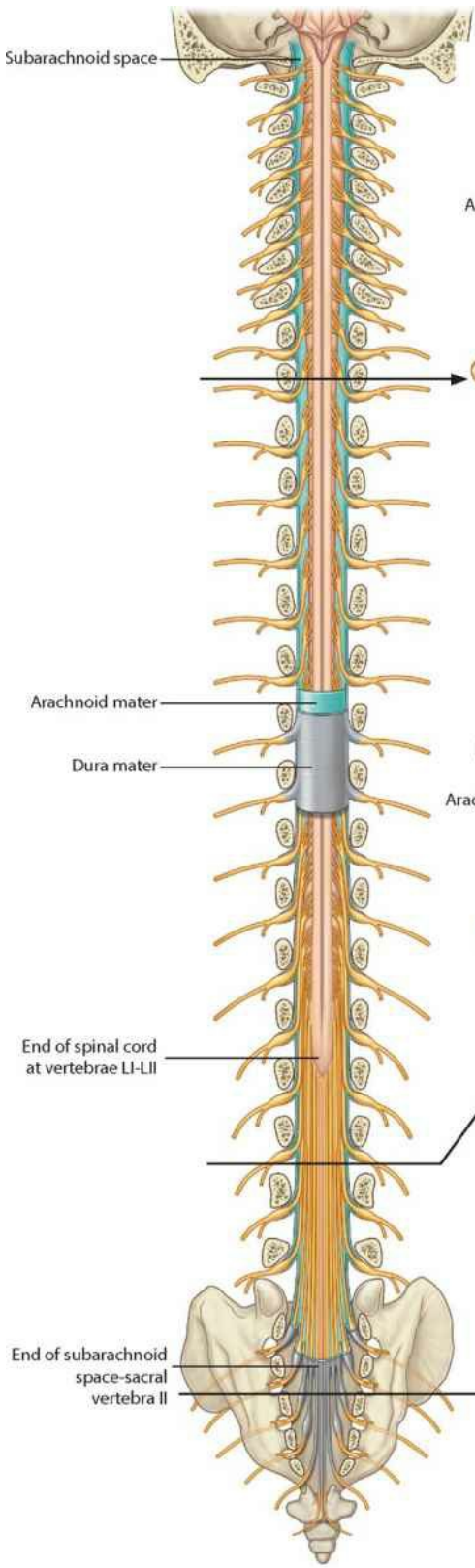
Segmental spinal artery

# **Venous drainage of spinal cord**

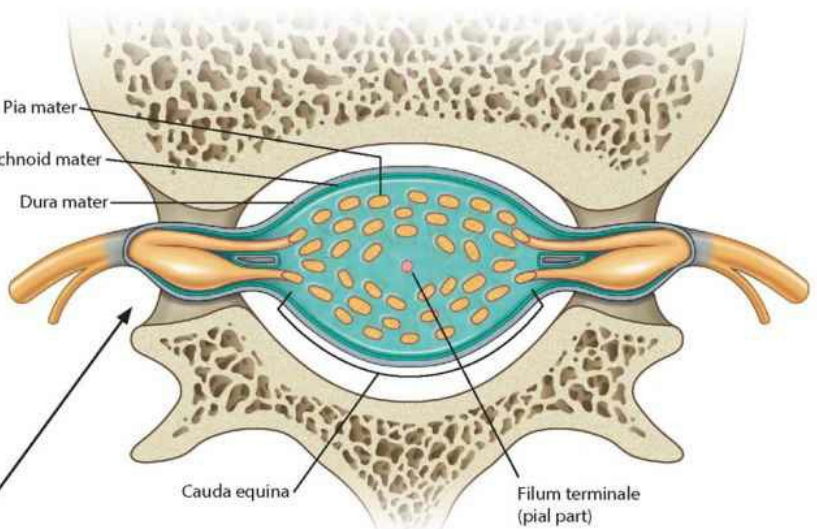




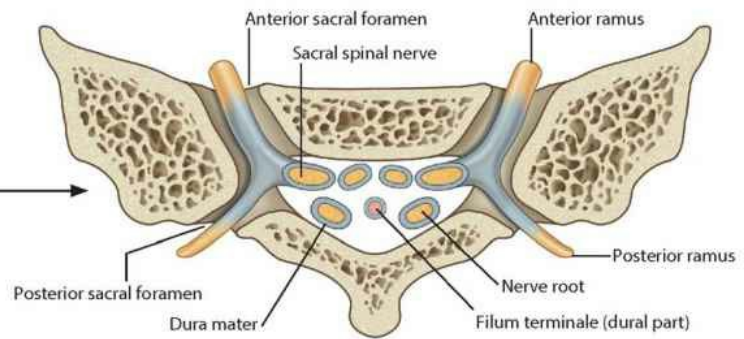
# Meninges



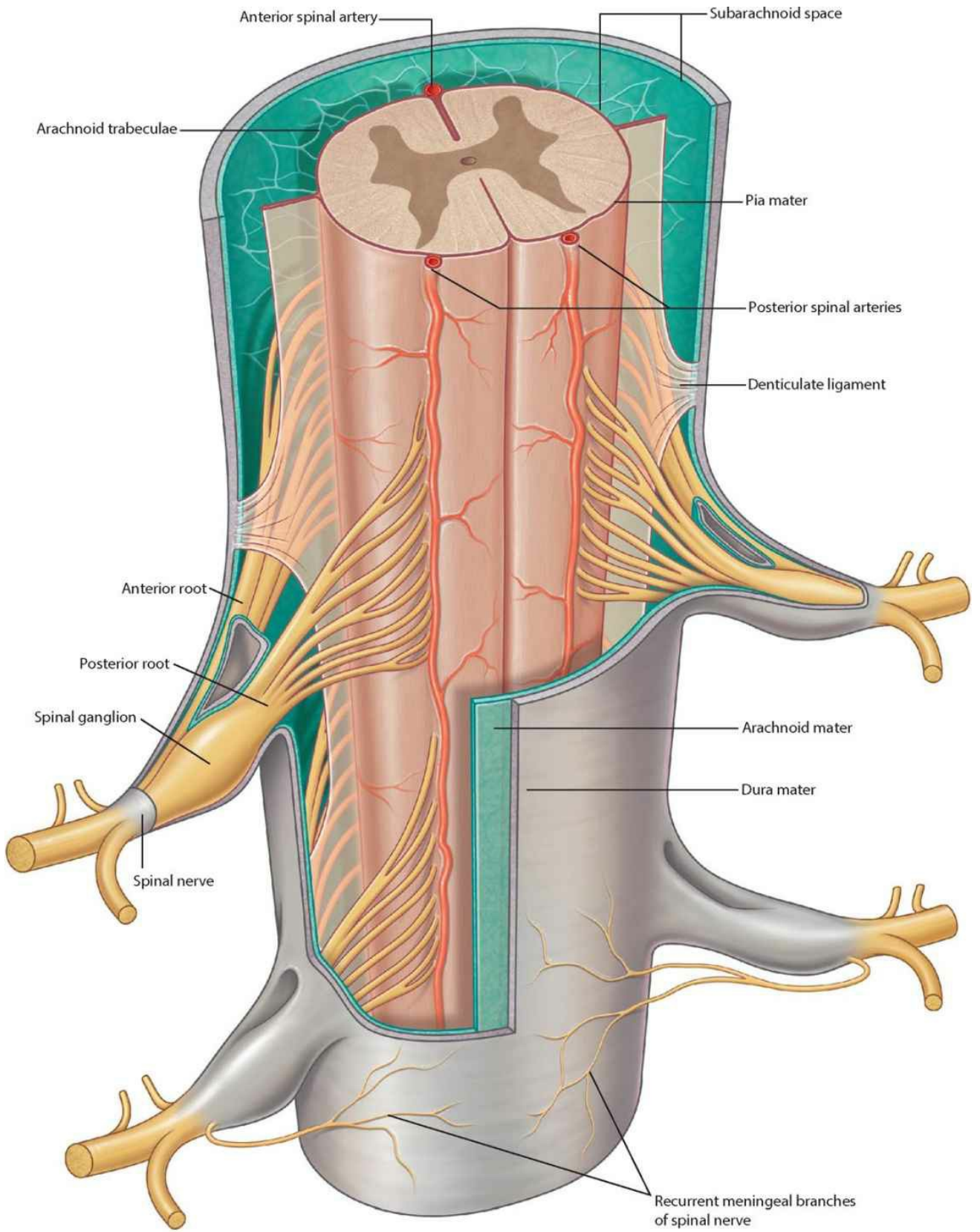
**Cord and meninges at thoracic level**



**Cauda equina and meninges at lumbar level**

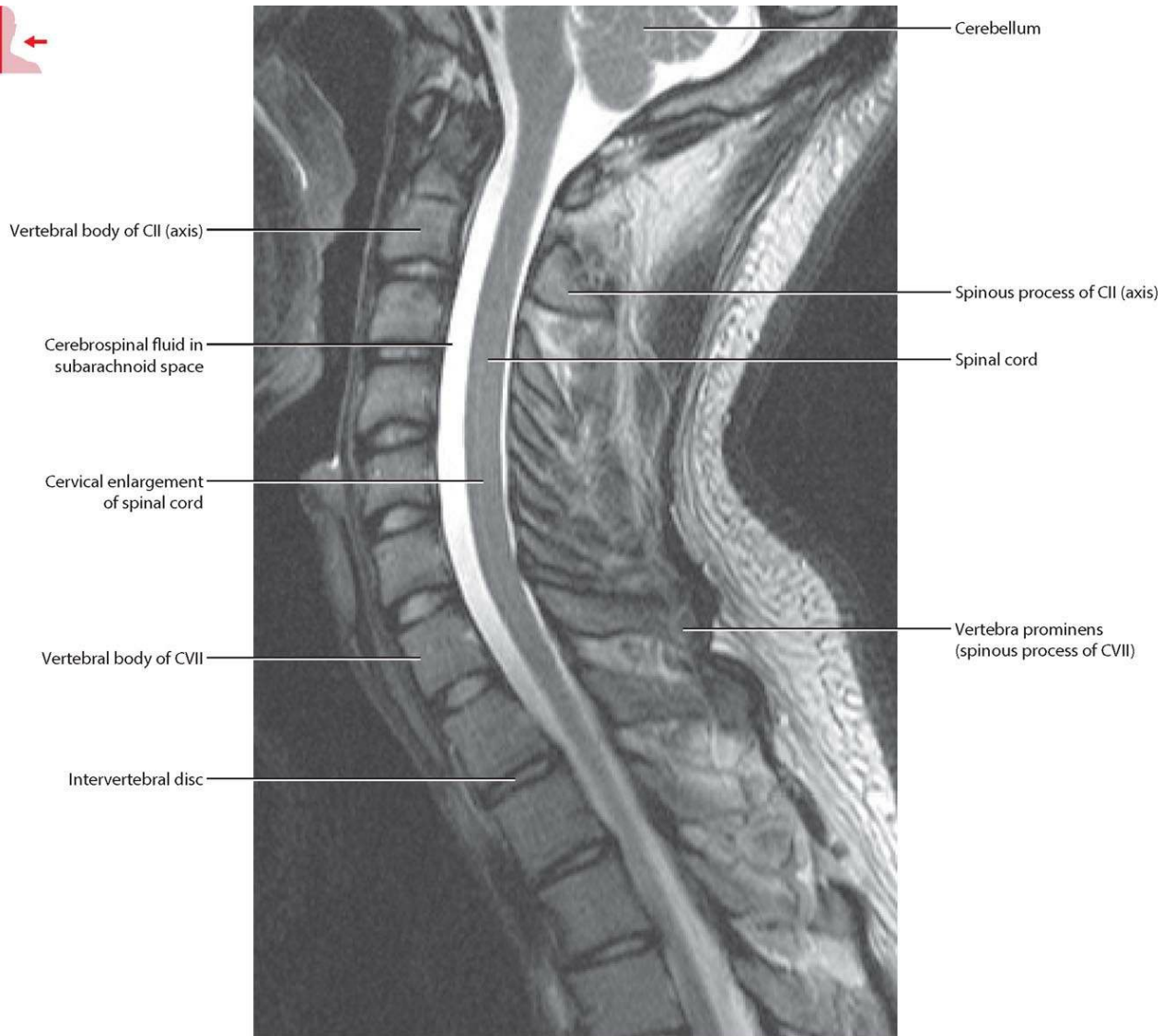
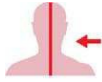


**Nerve roots and meninges at sacral level**

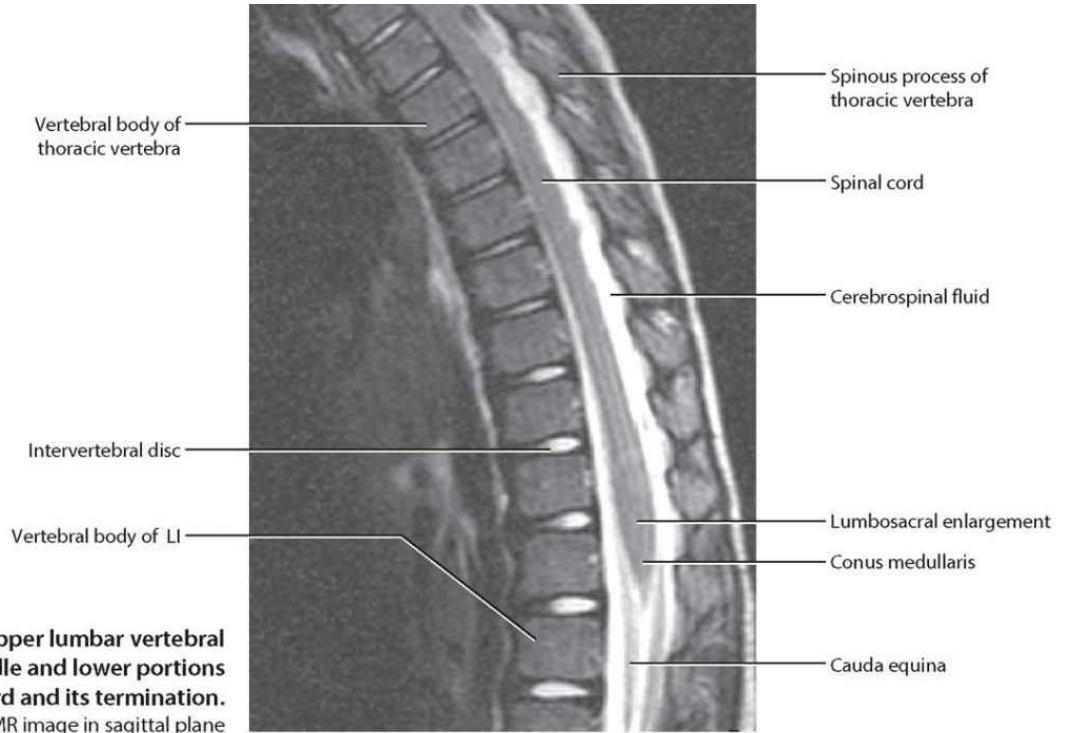
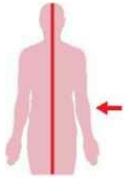


**Meninges covering parts of the thoracic region of the spinal cord (posterior view)**

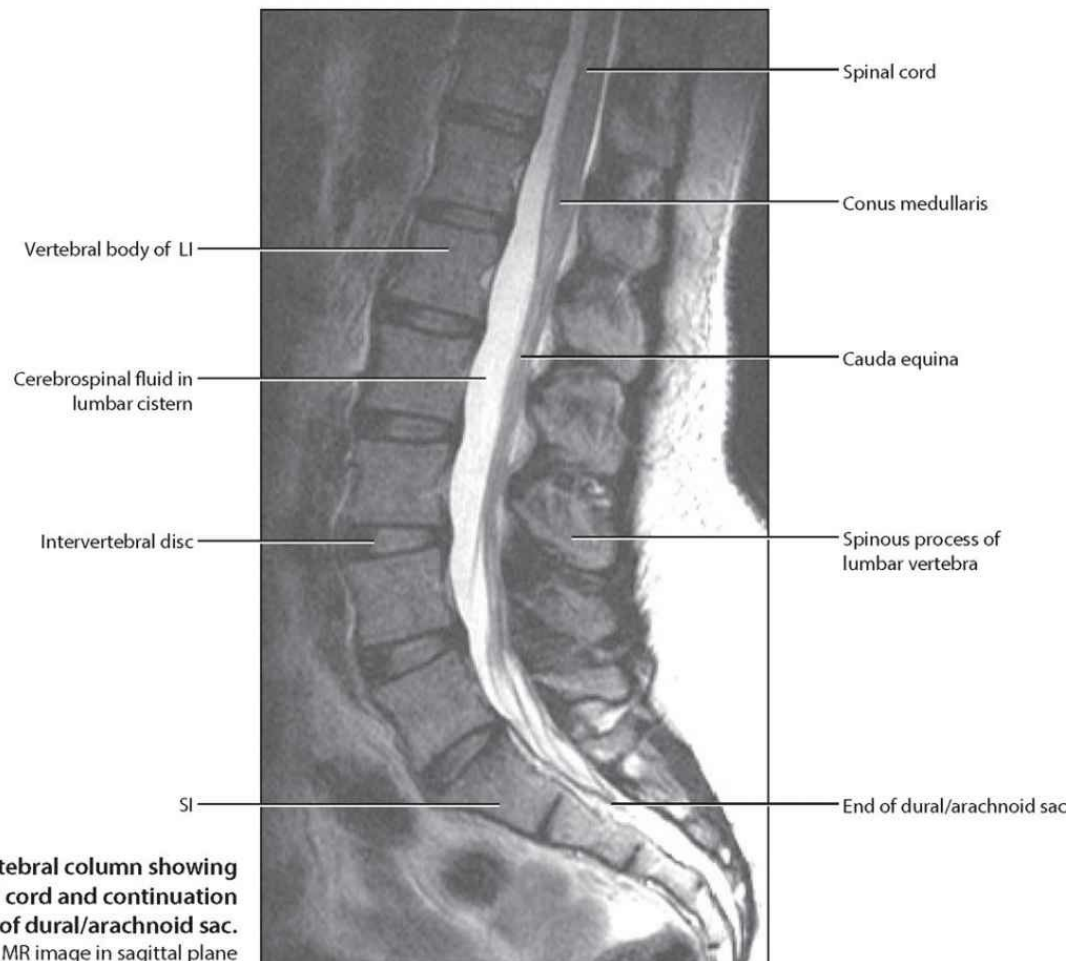
# Spinal cord: imaging



**Cervical and upper thoracic vertebral column showing upper and middle portions of spinal cord.**  
T2-weighted MR image in sagittal plane

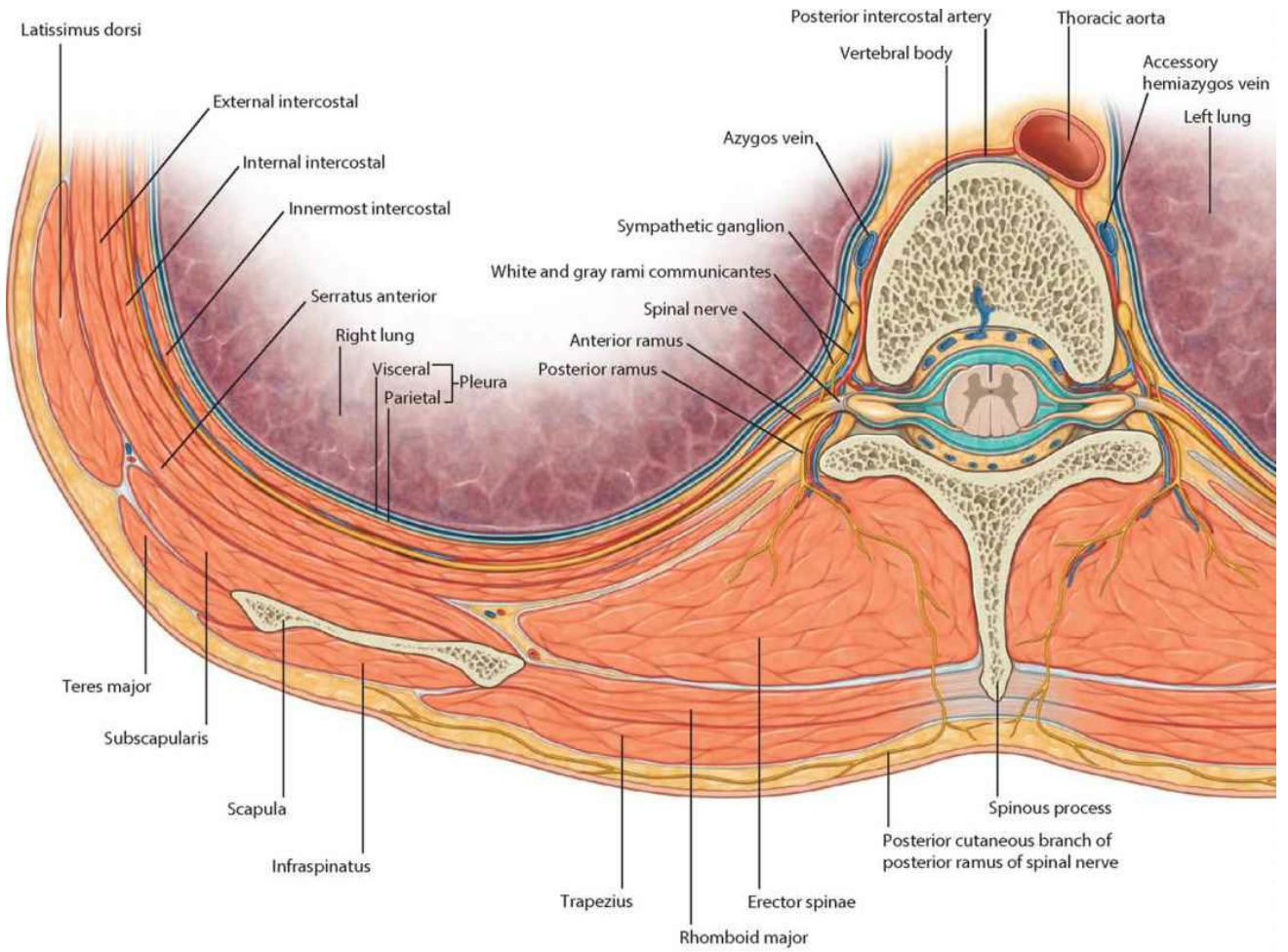


**Thoracic and upper lumbar vertebral column showing middle and lower portions of spinal cord and its termination.**  
T2-weighted MR image in sagittal plane

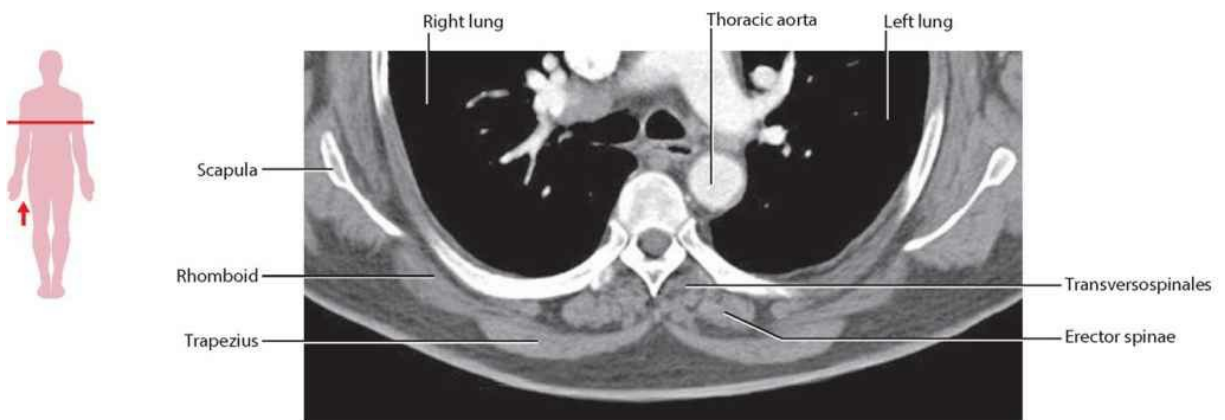


**Lumbar and sacral vertebral column showing termination of spinal cord and continuation and termination of dural/arachnoid sac.**  
T2-weighted MR image in sagittal plane

# Transverse section: thoracic region



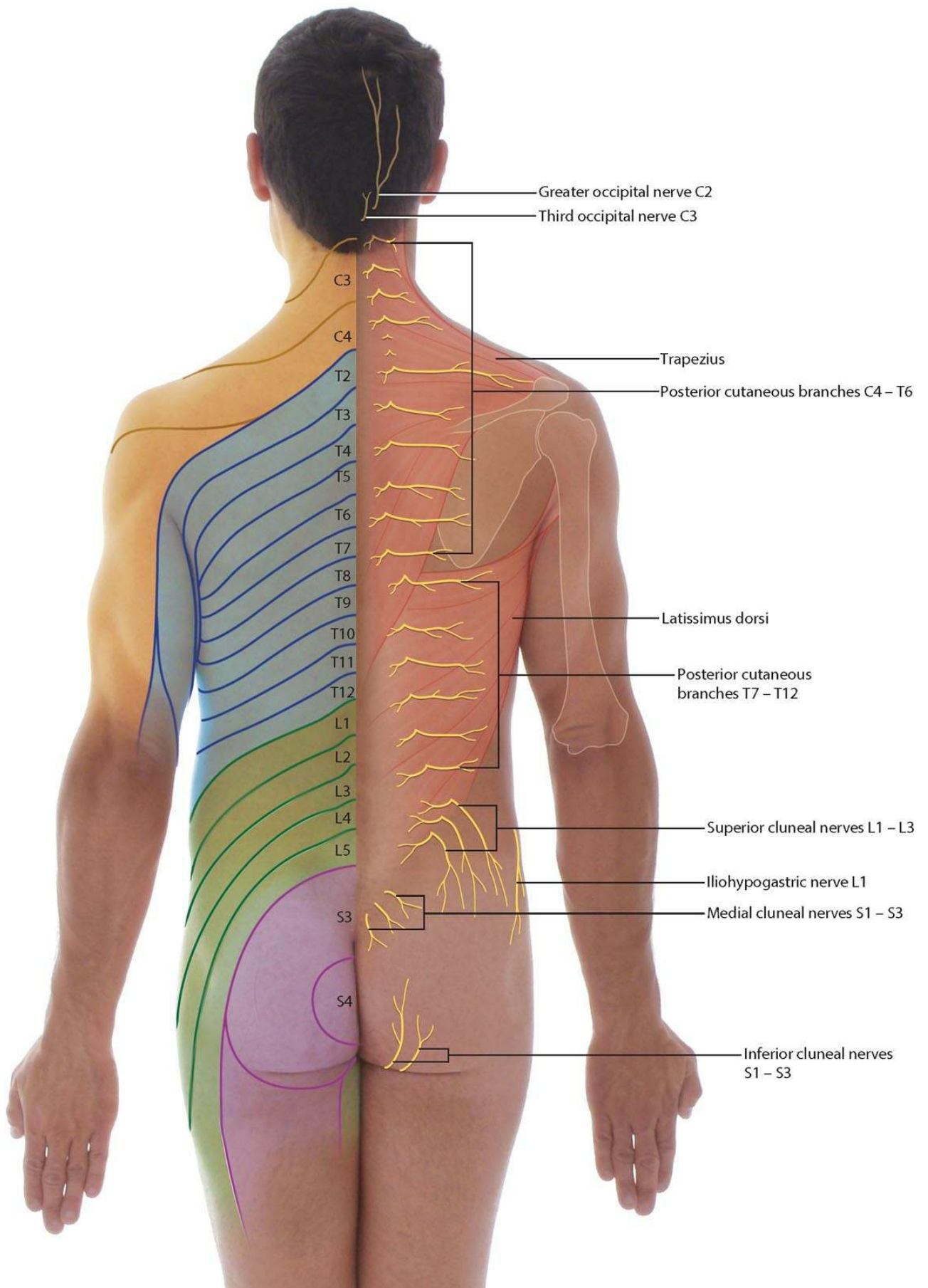
Transverse section through thoracic region of vertebral column



Thoracic region of back.  
CT image in axial plane



# Dermatomes and cutaneous nerves



**Dermatomes and cutaneous nerves of the back**



# Tables

## Superficial (appendicular) group of back muscles

Muscle		Origin	Insertion	Innervation	Function
Trapezius	1	Superior nuchal line, external occipital protuberance, ligamentum nuchae, spinous processes of CVII to TXII	Lateral one-third of clavicle, acromion, spine of scapula	Motor—accessory nerve [XI]; proprioception—C3 and C4	Assists in rotating the scapula during abduction of humerus above horizontal; upper fibers elevate, middle fibers adduct, and lower fibers depress scapula
Latissimus dorsi	2	Spinous processes of TVII to LV and sacrum, iliac crest, ribs X to XII	Floor of intertubercular sulcus of humerus	Thoracodorsal nerve (C6 to C8)	Extends, adducts, and medially rotates humerus
Levator scapulae	3	Transverse processes of C1 to CIV	Upper portion medial border of scapula	C3 to C4 and dorsal scapular nerve (C4, C5)	Elevates scapula
Rhomboid major	4	Spinous processes of TII to TV	Medial border of scapula between spine and inferior angle	Dorsal scapular nerve (C4, C5)	Retracts (adducts) and elevates scapula
Rhomboid minor	5	Lower portion of ligamentum nuchae, spinous processes of CVII and TI	Medial border of scapula at the spine of scapula	Dorsal scapular nerve (C4, C5)	Retracts (adducts) and elevates scapula

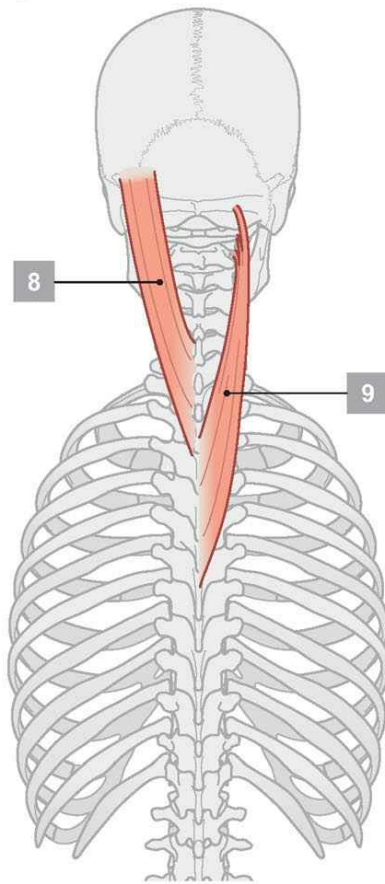
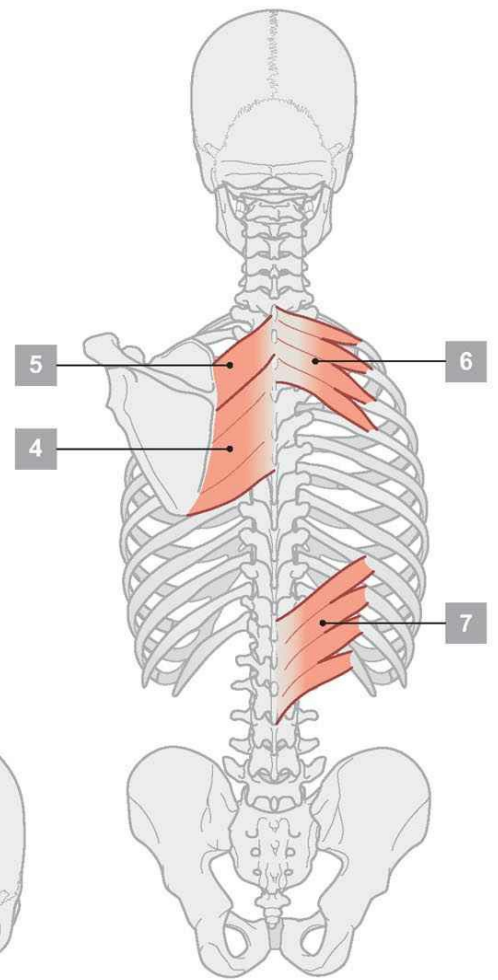
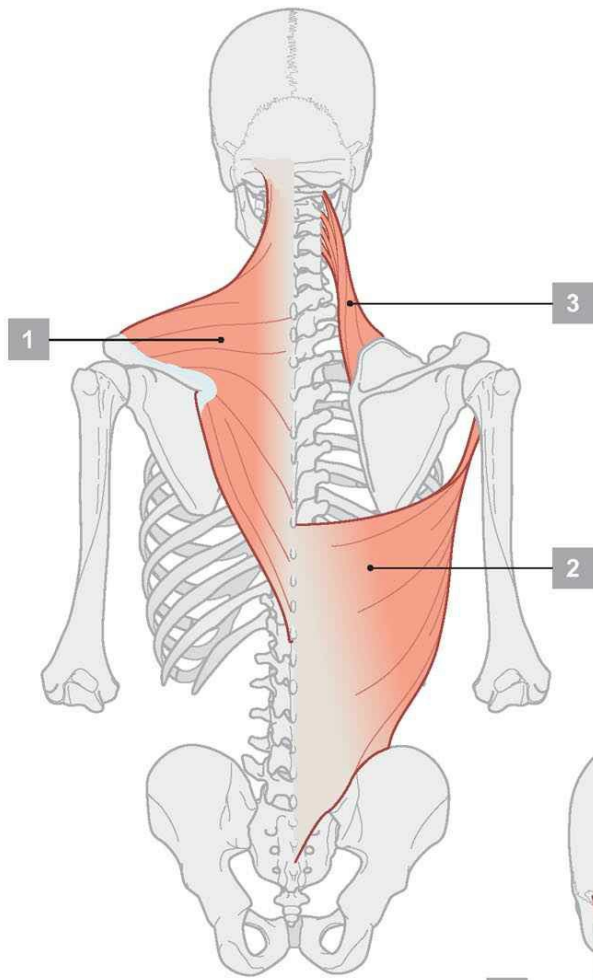
## Intermediate (respiratory) group of back muscles

Serratus posterior superior	6	Lower portion of ligamentum nuchae, spinous processes of CVII to TIII and supraspinous ligaments	Mastoid process, skull below lateral one-third of superior nuchal line	Anterior rami of upper thoracic nerves (T2 to T5)	Elevates ribs II to V
Serratus posterior inferior	7	Spinous processes of TXI to LIII and supraspinous ligaments	Lower border of ribs IX to XII just lateral to their angles	Anterior rami of lower thoracic nerves (T9 to T12)	Depresses ribs IX to XII and may prevent lower ribs from being elevated when the diaphragm contracts

## Spinotransversales muscles

Splenius capitis	8	Lower half of ligamentum nuchae, spinous processes of CVII to TIV	Mastoid process, skull below lateral one-third of superior nuchal line	Posterior rami middle cervical nerves	Together—draw head backward, extending neck; individually—draw and rotate head to one side (turn face to same side)
Splenius cervicis	9	Spinous processes of TIII to TVI	Transverse processes of C1 to CIII	Posterior rami lower cervical nerves	Together—extend neck; individually—draw and rotate head to one side (turn face to same side)



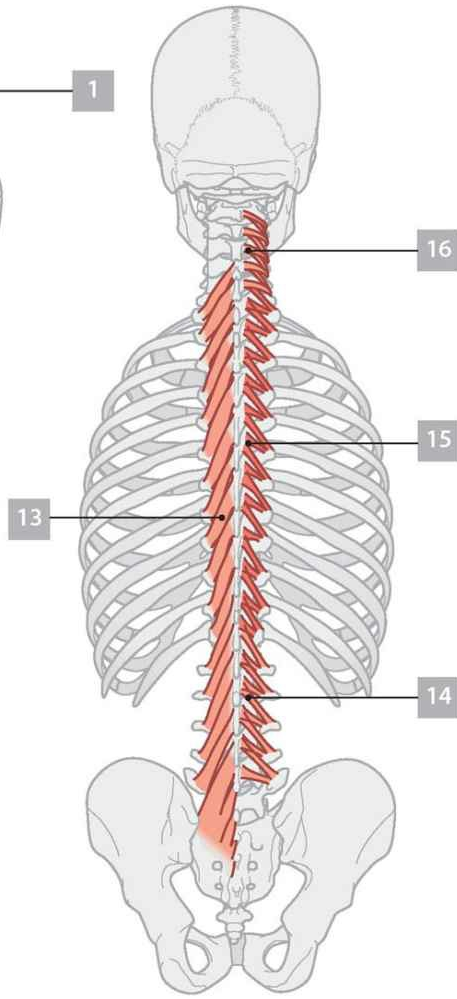
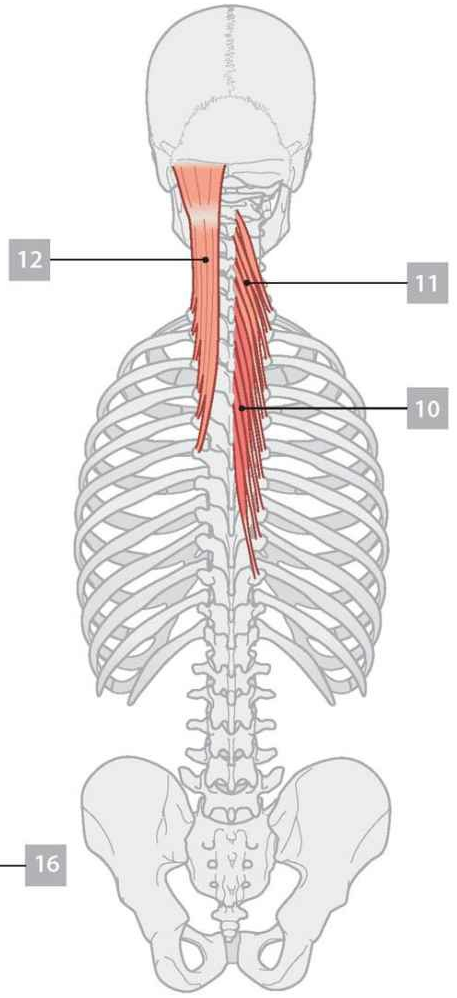
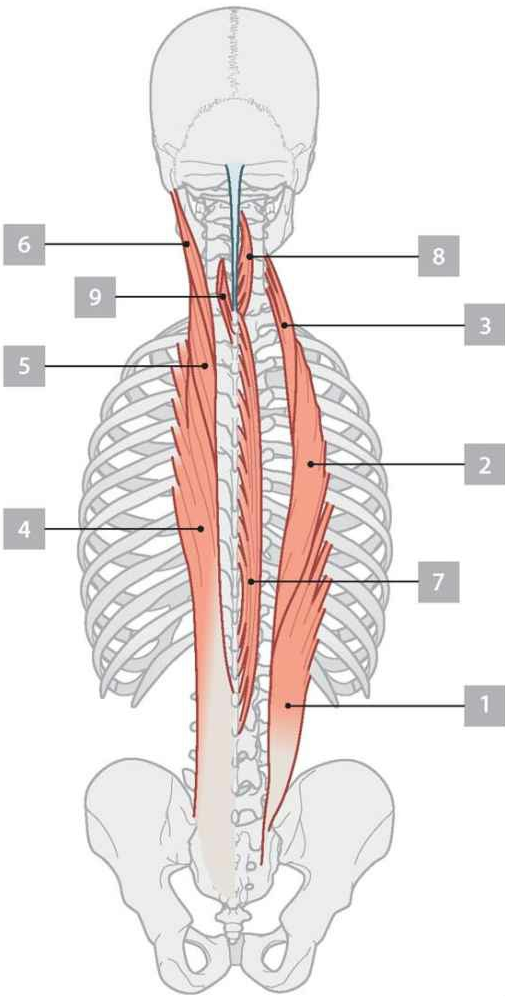


## Erector spinae group of back muscles

Muscle		Origin	Insertion
Iliocostalis lumborum	1	Sacrum, spinous processes of lumbar and lower two thoracic vertebrae and their supraspinous ligaments, and the iliac crest	Angles of the lower six or seven ribs
Iliocostalis thoracis	2	Angles of the lower six ribs	Angles of the upper six ribs and the transverse process of CVII
Iliocostalis cervicis	3	Angles of ribs III to VI	Transverse processes of CIV to CVI
Longissimus thoracis	4	Blends with iliocostalis in lumbar region and is attached to transverse processes of lumbar vertebrae	Transverse processes of all thoracic vertebrae and just lateral to the tubercles of the lower nine or ten ribs
Longissimus cervicis	5	Transverse processes of upper four or five thoracic vertebrae	Transverse processes of CII to CVI
Longissimus capitis	6	Blends with iliocostalis in lumbar region and is attached to transverse processes of lumbar vertebrae	Transverse processes of all thoracic vertebrae and just lateral to the tubercles of the lower nine or ten ribs
Spinalis thoracis	7	Spinous processes of TX or TXI to LII	Spinous processes of TI to TVIII (varies)
Spinalis cervicis	8	Lower part of ligamentum nuchae and spinous process of CVII (sometimes TI to TIII)	Spinous process of CII (axis)
Spinalis capitis	9	Usually blends with semispinalis capitis	With semispinalis capitis

## Transversospinales group of back muscles

Semispinalis thoracis	10	Transverse processes of TVI to TX	Spinous processes of upper four thoracic and lower two cervical vertebrae
Semispinalis cervicis	11	Transverse processes of upper five or six thoracic vertebrae	Spinous processes of CII (axis) to CV
Semispinalis capitis	12	Transverse processes of TI to TVI (or TVII) and CVII and articular processes of CIV to CVI	Medial area between the superior and inferior nuchal lines of occipital bone
Multifidus	13	Sacrum, origin of erector spinae, posterior superior iliac spine, mammillary processes of lumbar vertebrae, transverse processes of thoracic vertebrae, and articular processes of lower four cervical vertebrae	Base of spinous processes of all vertebrae from LV to CII (axis)
Rotatores lumborum	14	Mammillary processes of lumbar vertebrae	Spinous processes of lumbar vertebrae
Rotatores thoracis	15	Transverse processes of thoracic vertebrae	Spinous processes of thoracic vertebrae
Rotatores cervicis	16	Articular processes of cervical vertebrae	Spinous processes of cervical vertebrae

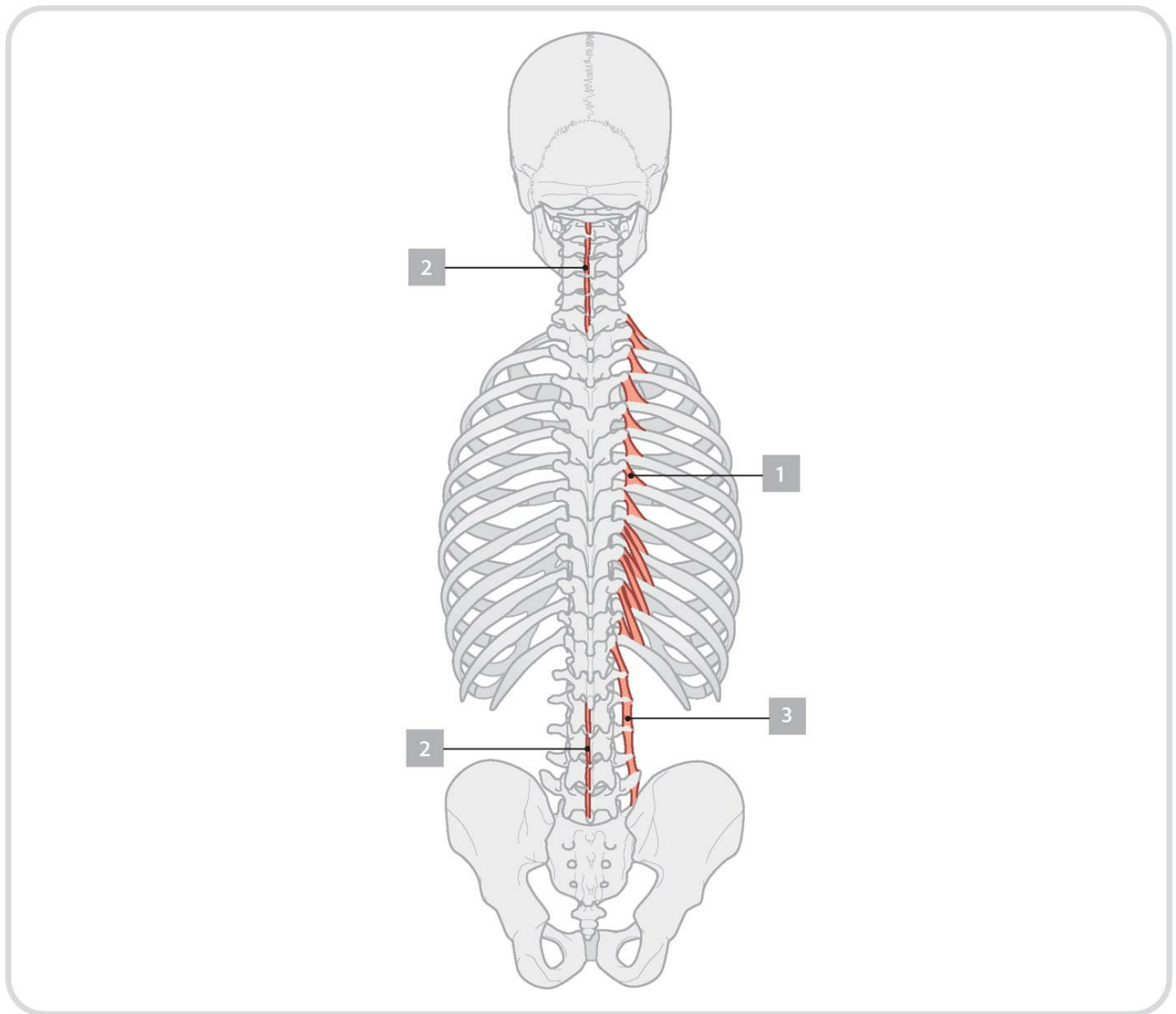




## Segmental back muscles

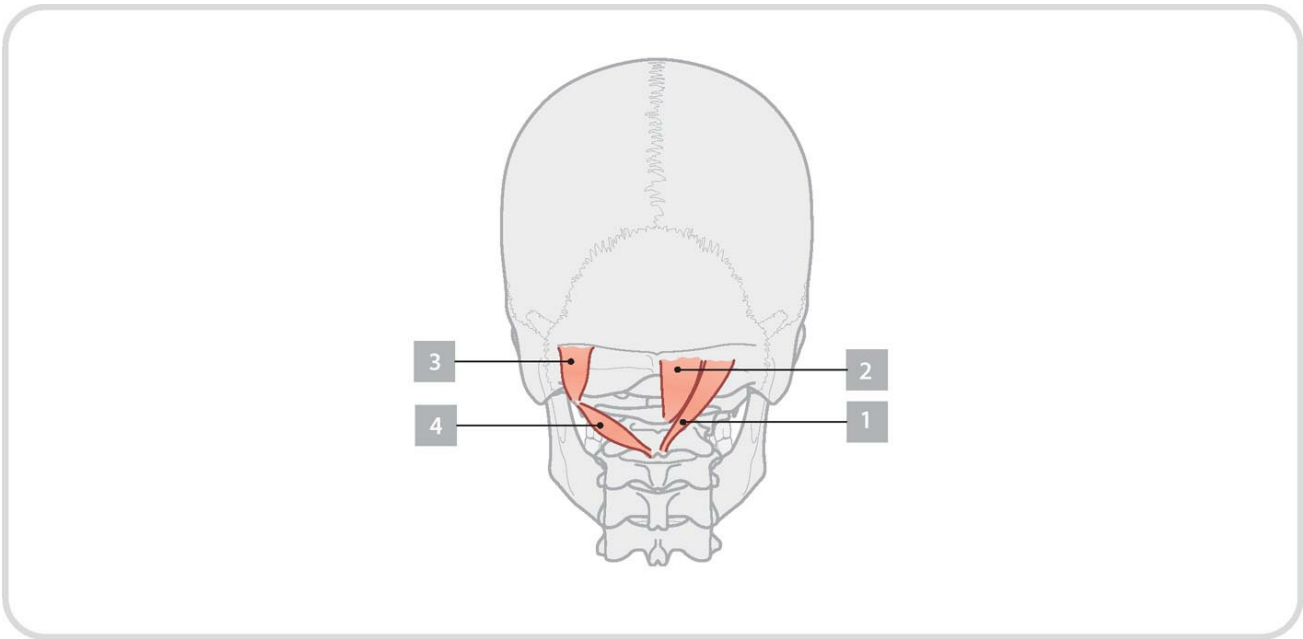
---

Muscle		Origin	Insertion	Function
<b>Levatores costarum</b>	1	Short paired muscles arising from transverse processes of CVII to TXI	The rib below vertebra of origin near tubercle	Contraction elevates rib
<b>Interspinales</b>	2	Short paired muscles attached to the spinous processes of contiguous vertebrae, one on each side of the interspinous ligament		Postural muscles that stabilize adjoining vertebra during movements of vertebral column
<b>Intertransversarii</b>	3	Small muscles between the transverse processes of contiguous vertebrae		Postural muscles that stabilize adjoining vertebra during movements of vertebral column



## Suboccipital group of back muscles

Muscle		Origin	Insertion	Innervation	Function
Rectus capitis posterior major	1	Spinous process of axis (C2)	Lateral portion of occipital bone below inferior nuchal line	Posterior ramus of C1	Extension of head; rotation of face to same side as muscle
Rectus capitis posterior minor	2	Posterior tubercle of atlas (C1)	Medial portion of occipital bone below inferior nuchal line	Posterior ramus of C1	Extension of head
Obliquus capitis superior	3	Transverse process of atlas (C1)	Occipital bone between superior and inferior nuchal lines	Posterior ramus of C1	Extension of head and bends it to same side
Obliquus capitis inferior	4	Spinous process of axis (C2)	Transverse process of atlas (C1)	Posterior ramus of C1	Rotation of face to same side





# THORAX

---

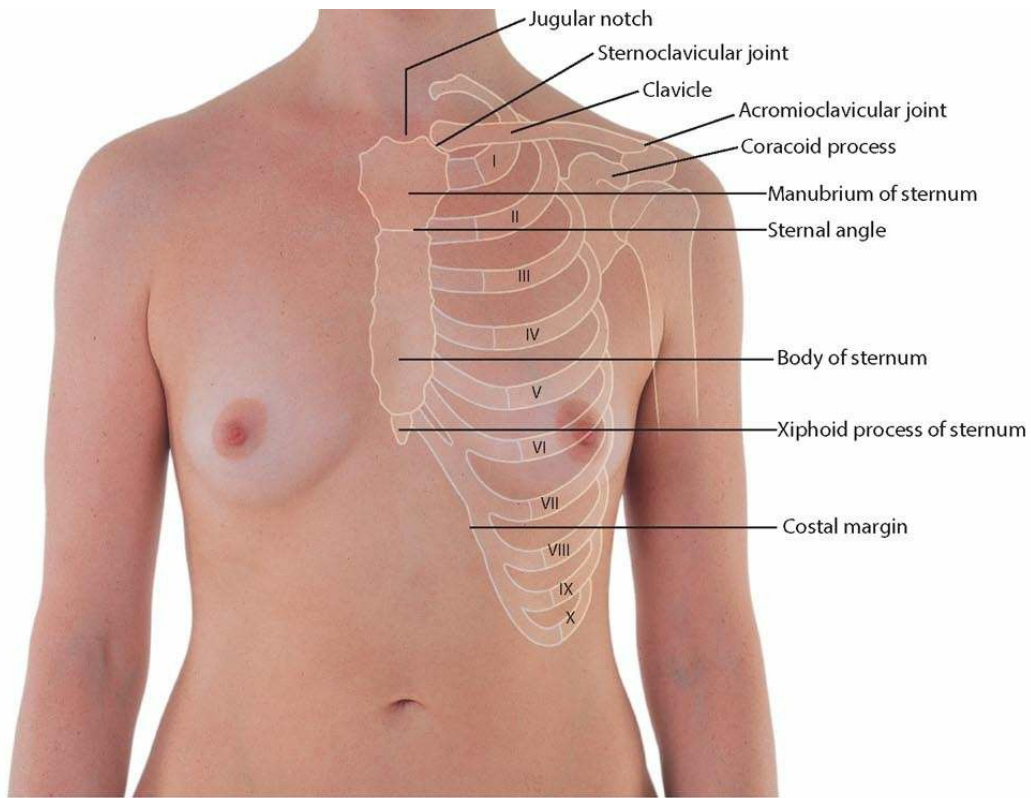
# CONTENTS

Surface anatomy with bones	62
Bony framework	63
Ribs	65
Articulations	66
Breast	68
Pectoral region	70
Thoracic wall muscles	72
Diaphragm	73
Arteries of the thoracic wall	74
Veins of the thoracic wall	75
Nerves of the thoracic wall	76
Lymphatics of the thoracic wall	77
Intercostal nerves and arteries	78
Pleural cavities and mediastinum	79
Parietal pleura	80
Surface projections of pleural recesses	81
Right lung	82
Left lung	83
Lung lobes: surface relationship	84
Lung lobes: imaging	85
Bronchial tree	86
Bronchopulmonary segments	87
Pulmonary vessels and plexus	88
Pulmonary vessels: imaging	89
Mediastinum	91
Pericardium	92
Pericardial layers	93
Anterior surface of heart	94
Base and diaphragmatic surface of heart	95

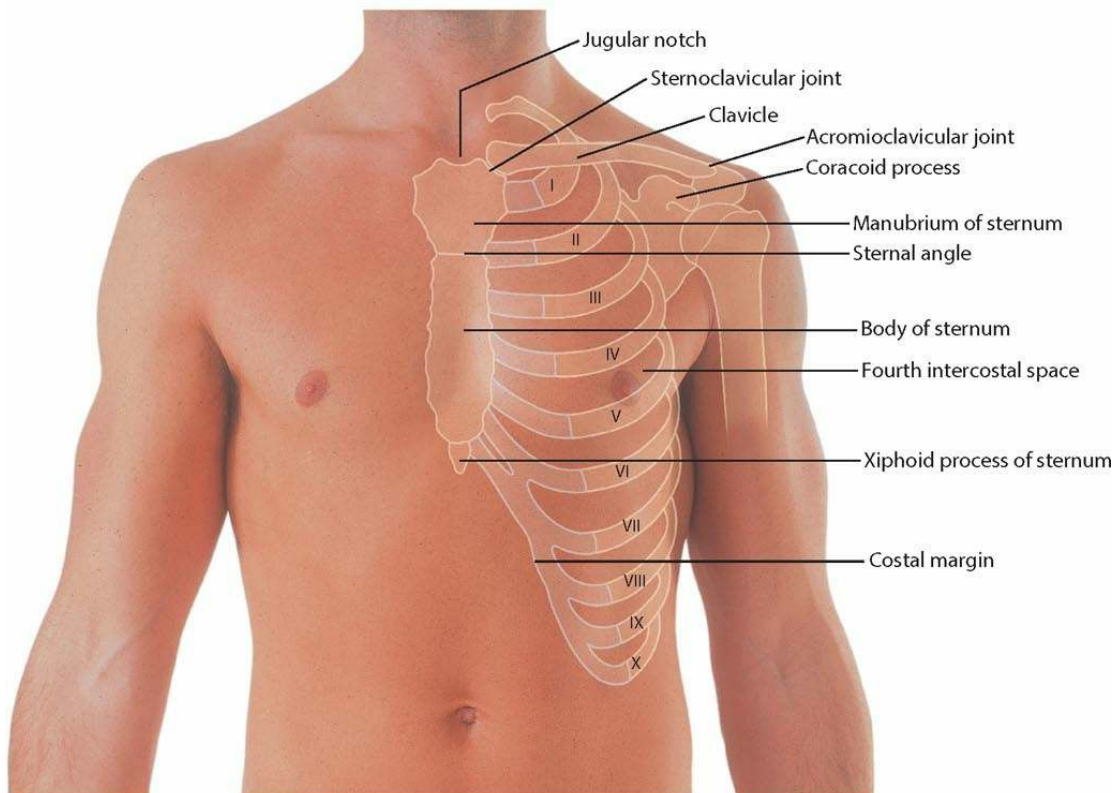
Right atrium [96](#)  
Right ventricle [97](#)  
Left atrium [98](#)  
Left ventricle [99](#)  
Aortic valve and cardiac skeleton [100](#)  
Cardiac chambers and heart valves [101](#)  
Coronary vessels [102](#)  
Coronary arteries and variations [103](#)  
Cardiac conduction system [105](#)  
Auscultation points and heart sounds [106](#)  
Cardiac innervation [107](#)  
Superior mediastinum: thymus [108](#)  
Superior mediastinum: veins and arteries [109](#)  
Superior mediastinum: arteries and nerves [110](#)  
Superior mediastinum: imaging [111](#)  
Superior mediastinum: veins and trachea [112](#)  
Mediastinum: imaging [113](#)  
Mediastinum: view from right [114](#)  
Mediastinum: imaging – view from right [115](#)  
Mediastinum: view from left [116](#)  
Mediastinum: imaging – view from left [117](#)  
Posterior mediastinum [118](#)  
Mediastinum: imaging [120](#)  
Transverse section: TVIII level [124](#)  
Dermatomes and cutaneous nerves [125](#)  
Visceral efferent (motor) innervation of the heart [126](#)  
Visceral afferents [127](#)  
Tables [128](#)

# Surface anatomy with bones





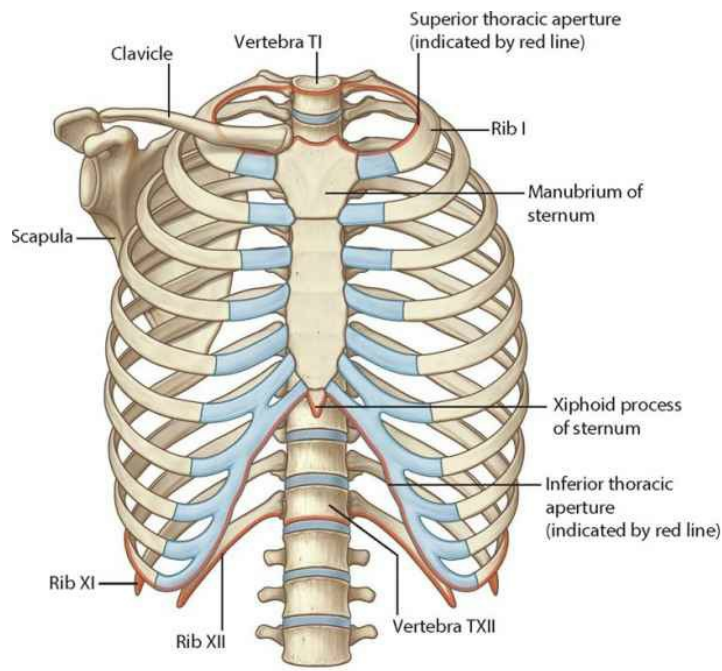
**Anterior chest wall in a woman**



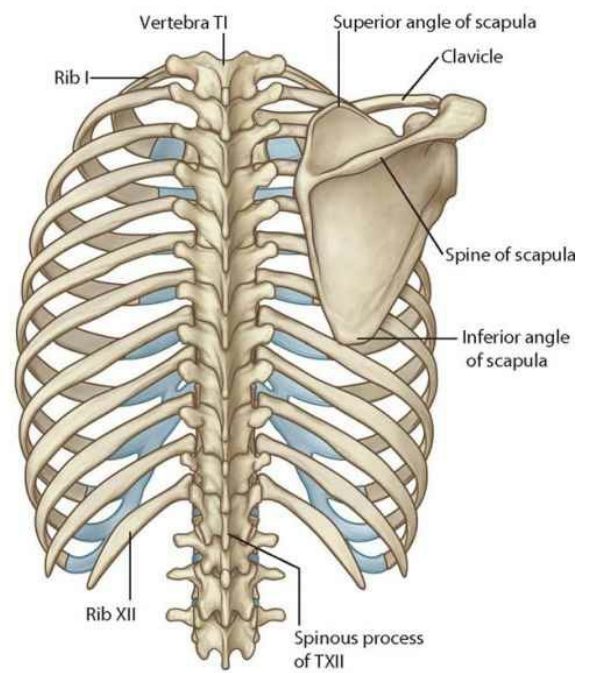
**Anterior chest wall in a man**



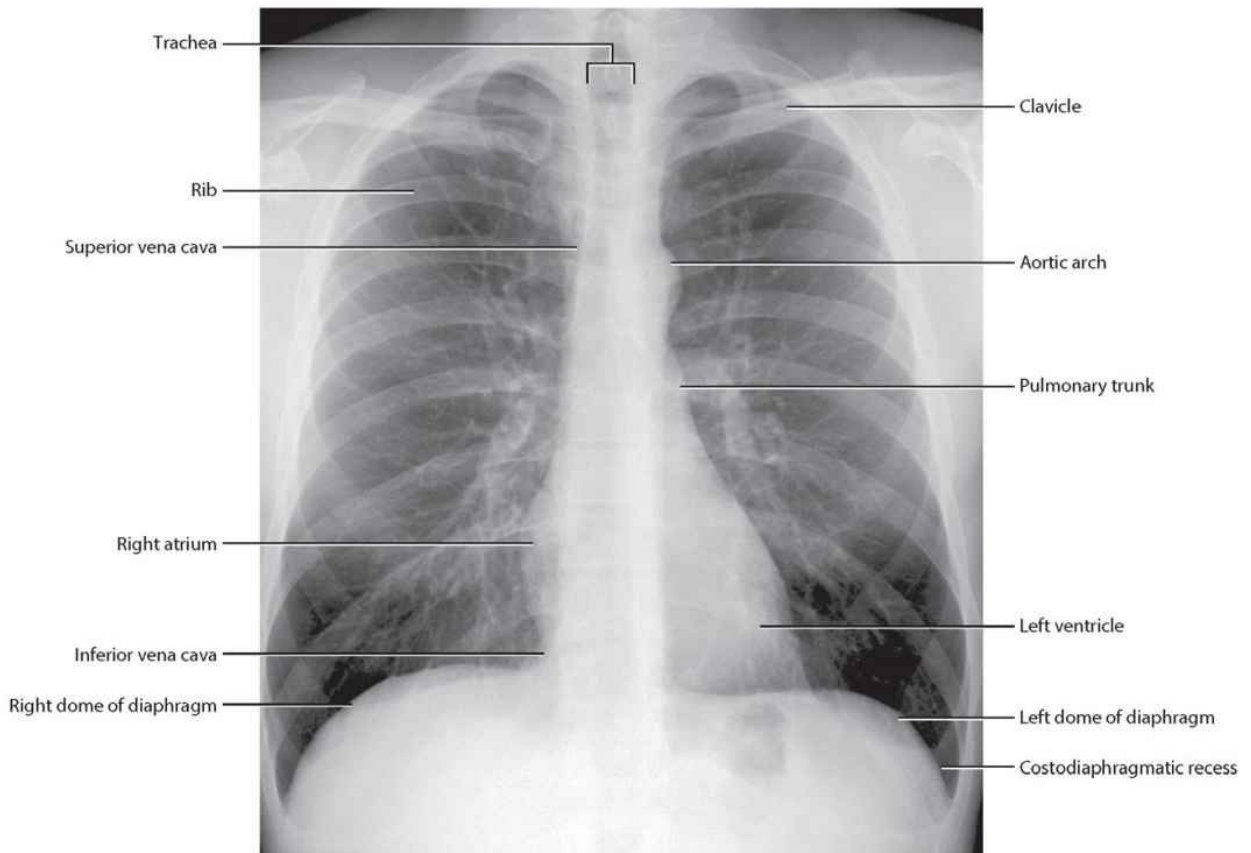
# Bony framework



**Bony framework of thorax (anterior view)**

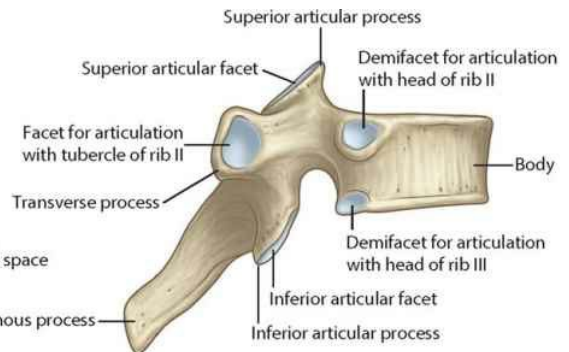
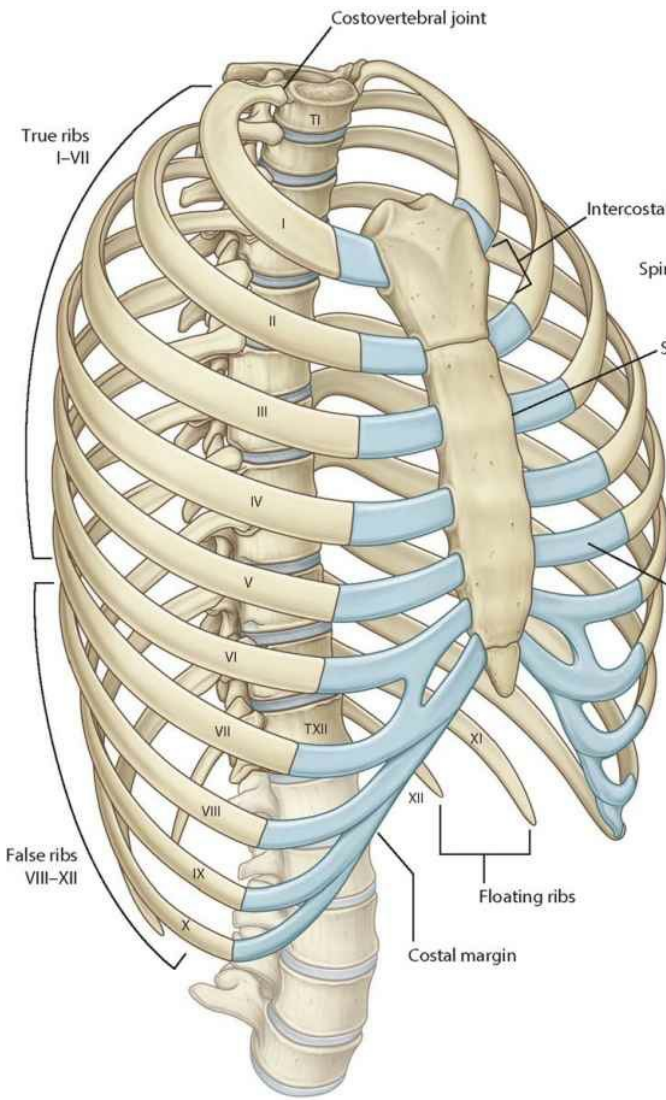


**Bony framework of thorax (posterior view)**

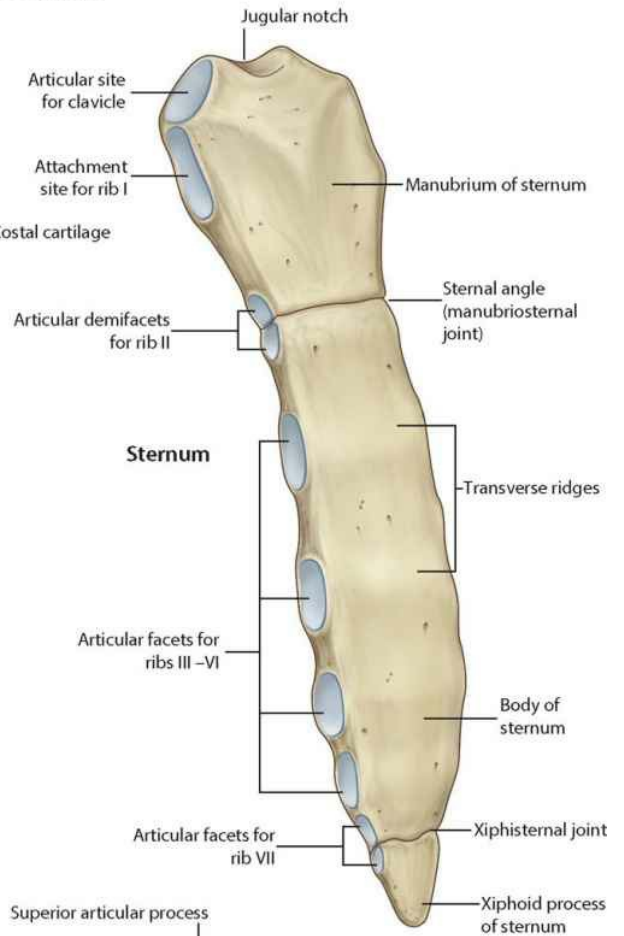


**Positioning of structures in chest.**  
Radiograph, AP view

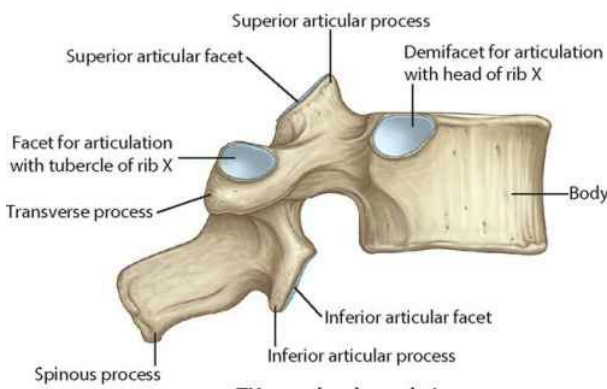




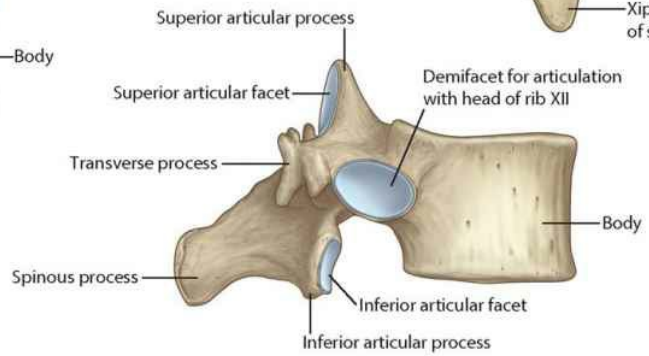
**TII vertebra lateral view**



**Sternum**

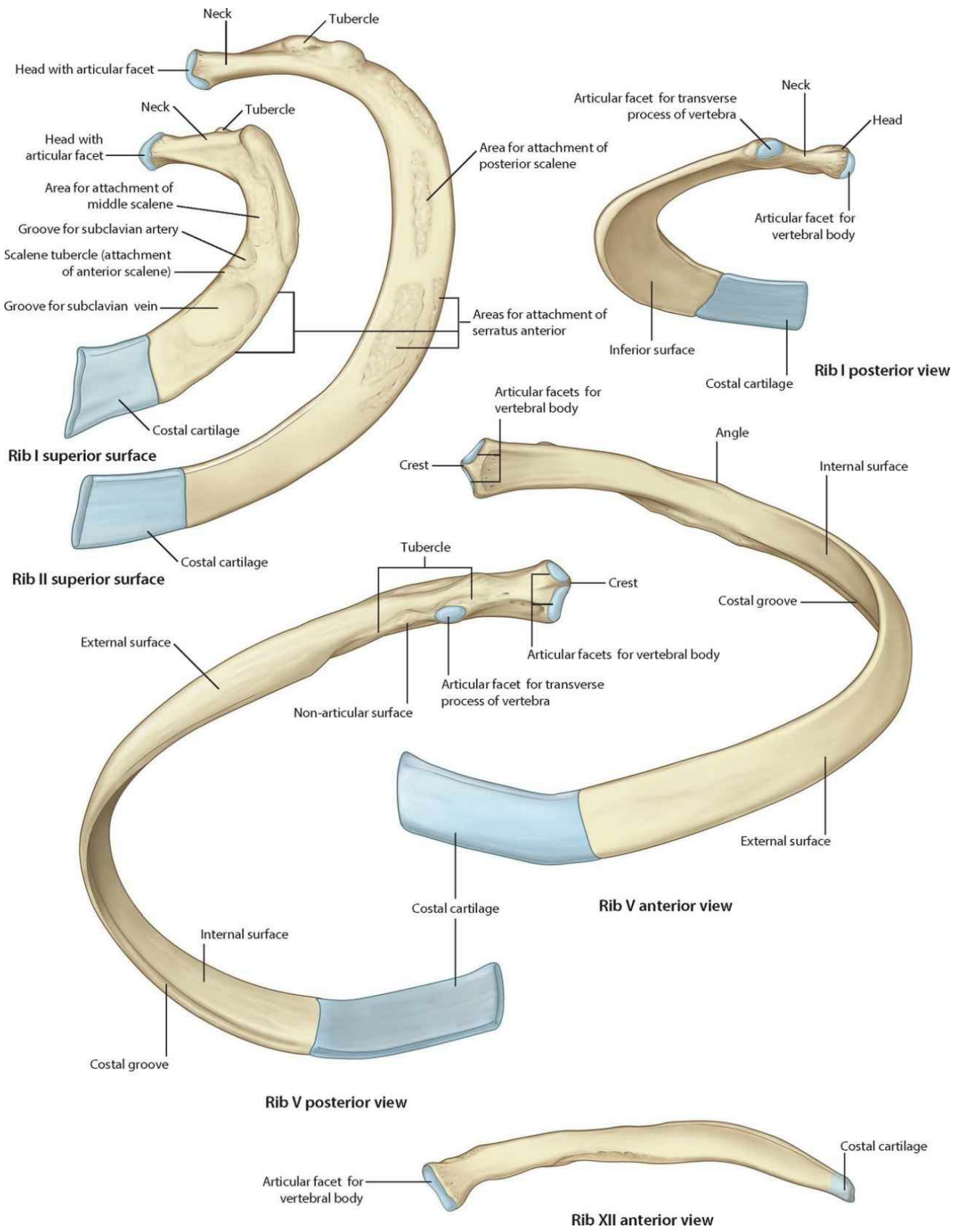


**TX vertebra lateral view**



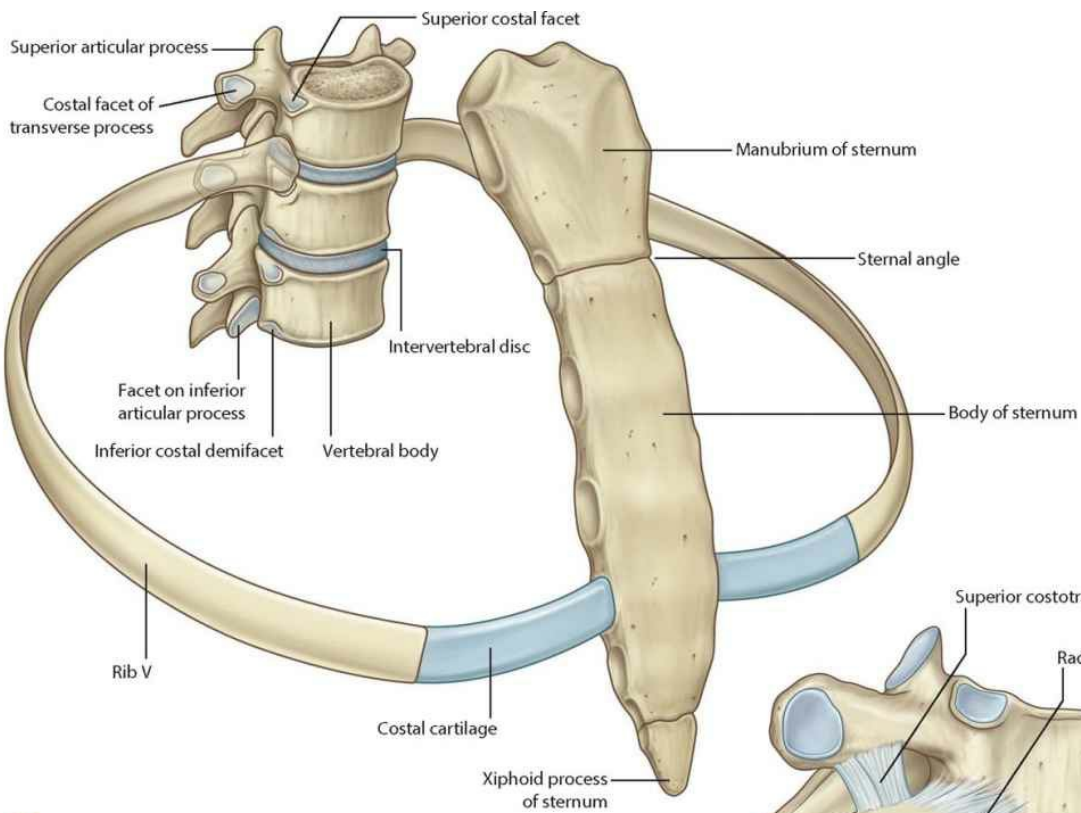
**TXII vertebra lateral view**

# Ribs

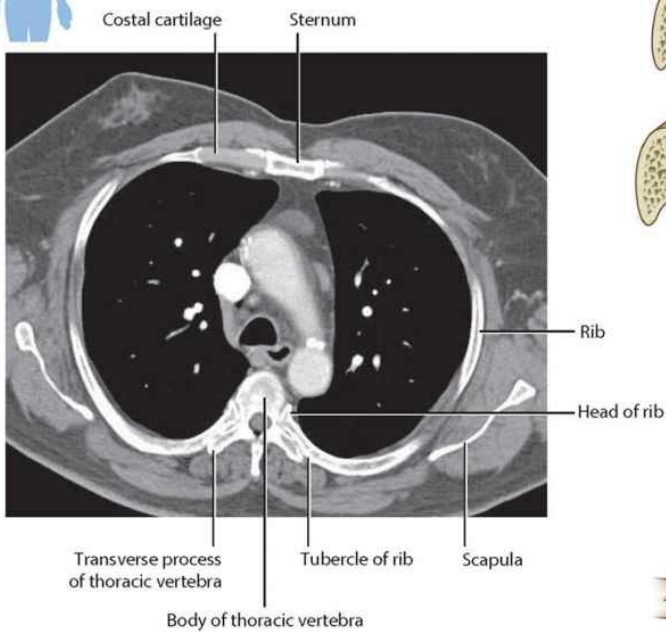
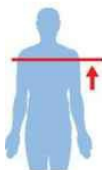




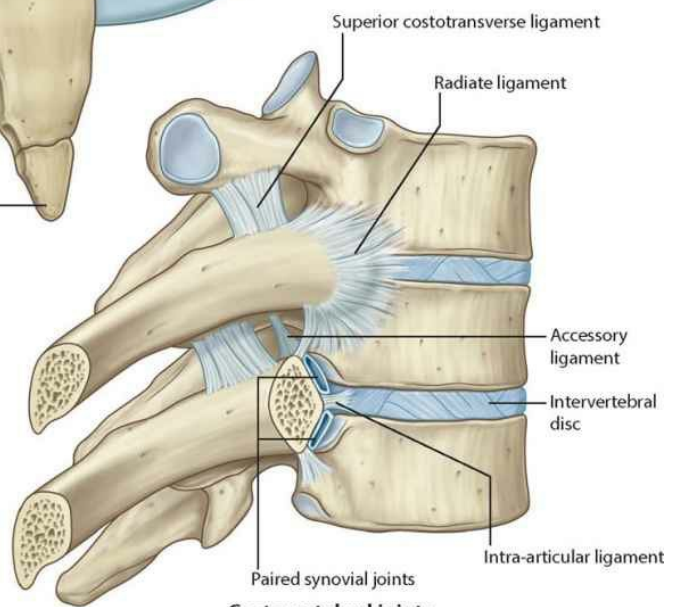
# Articulations



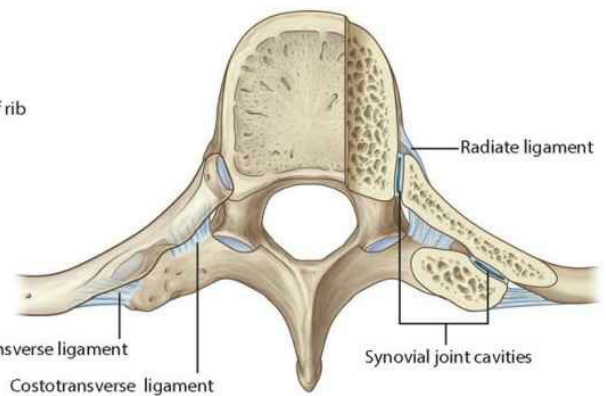
**Costovertebral and sternocostal joints**



**Articulation of rib with thoracic vertebra (TIV).**  
CT image, with contrast, in axial plane

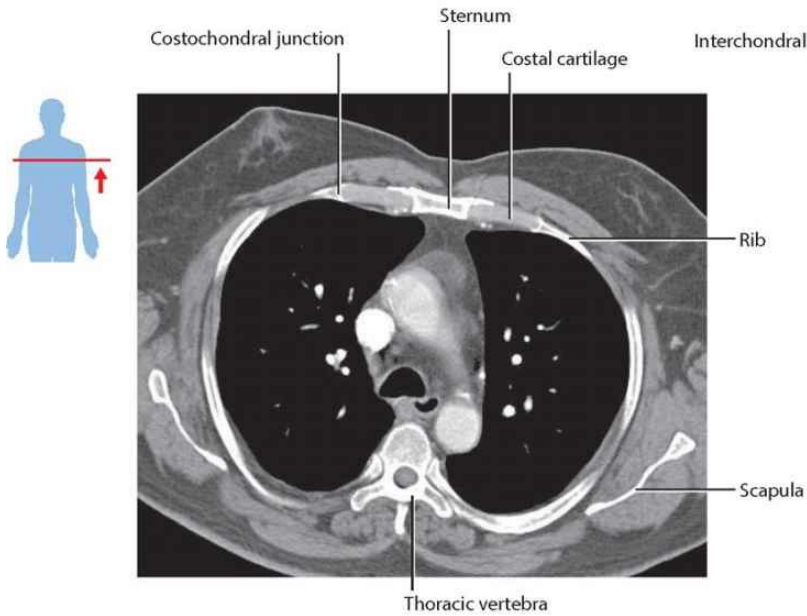
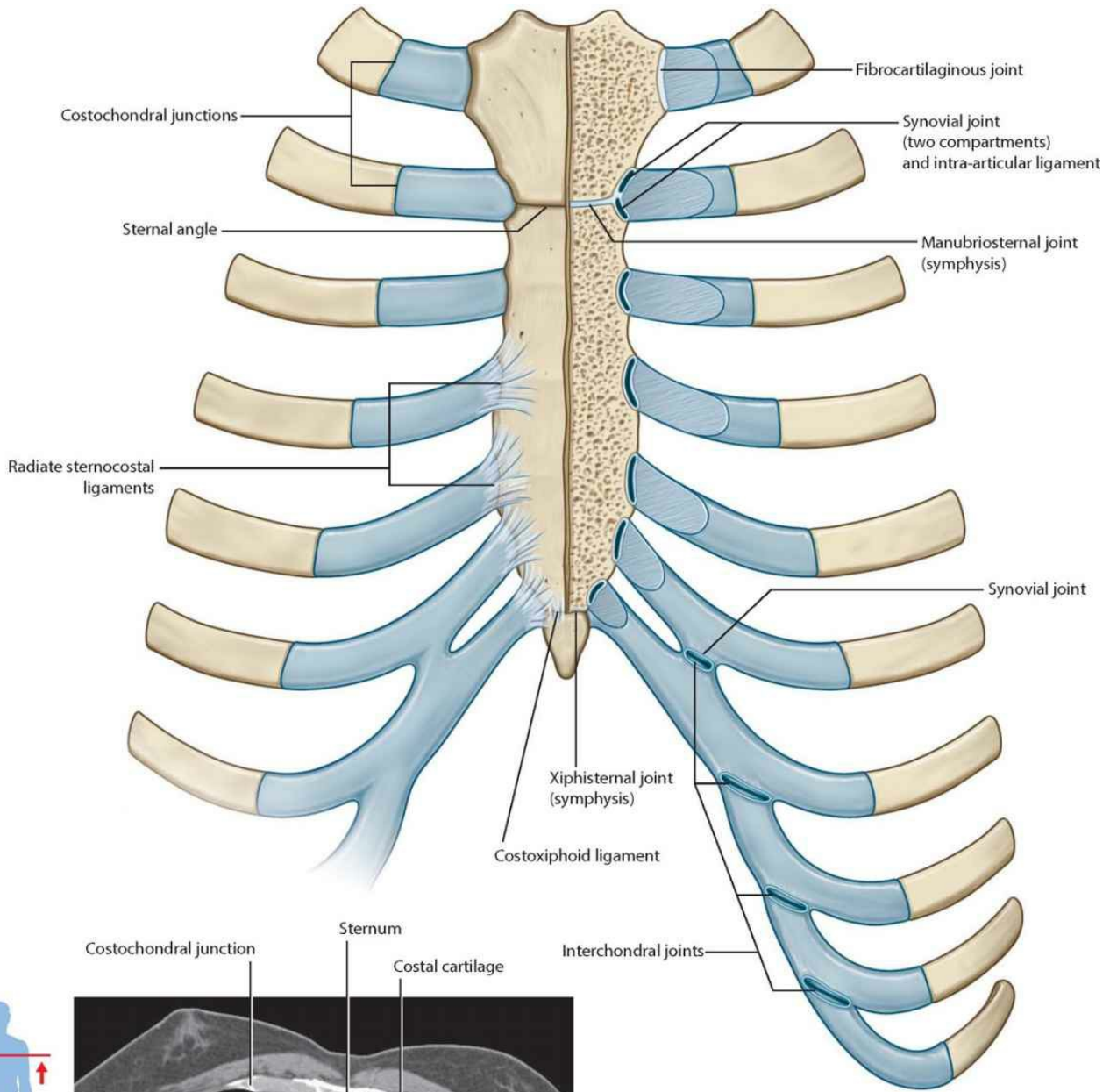


**Costovertebral joints (lateral view)**



**Costovertebral joints (superior view)**

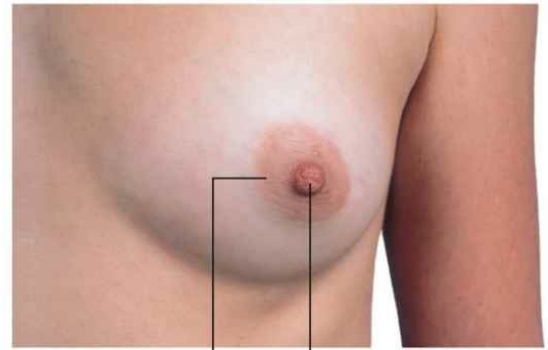
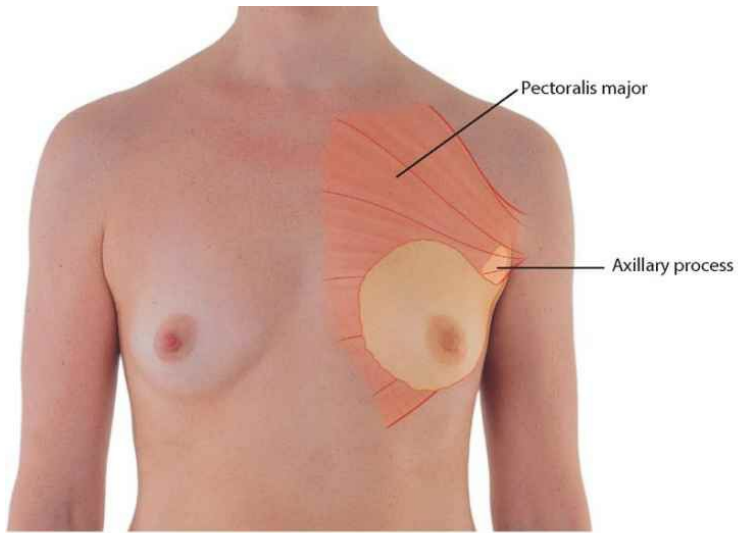




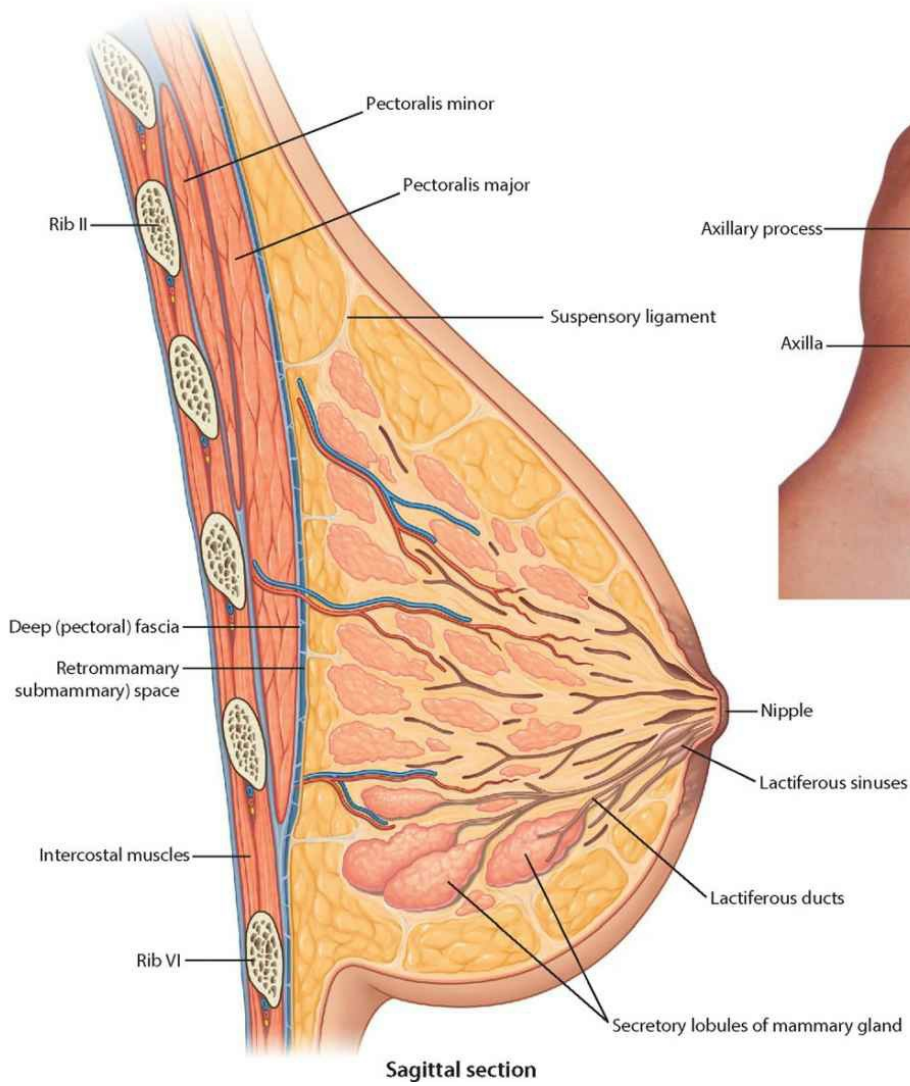
**Sternocostal and interchondral joints**

**Articulation of costal cartilage with sternum.**  
CT image, with contrast, in axial plane

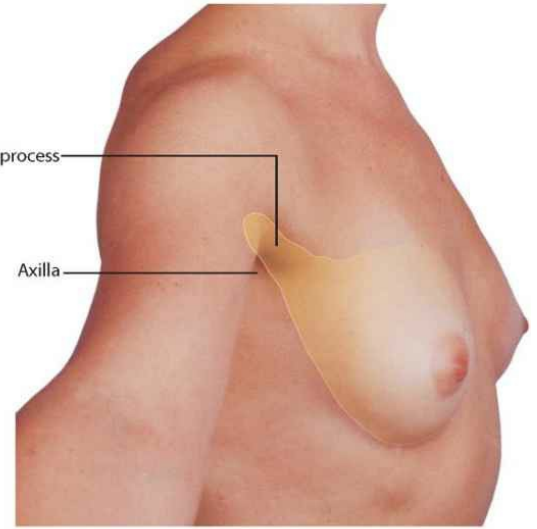
# Breast



Anterior view

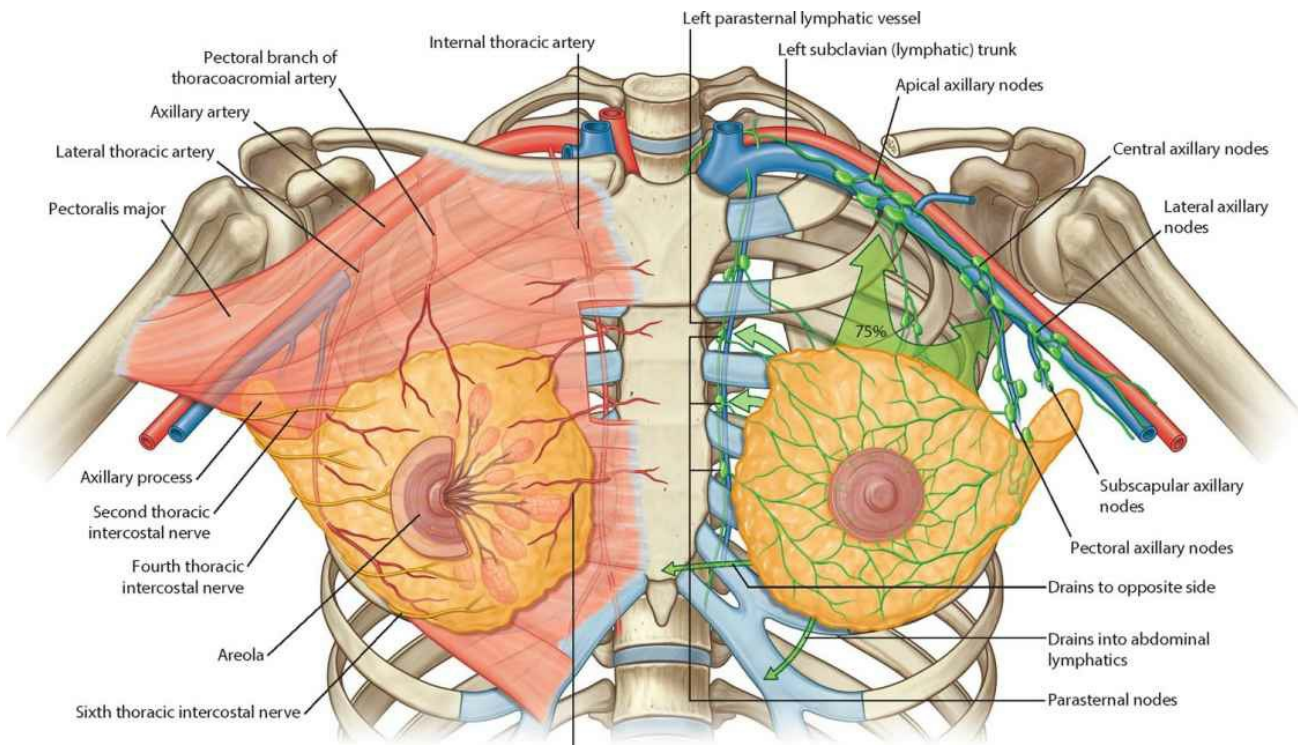


Sagittal section



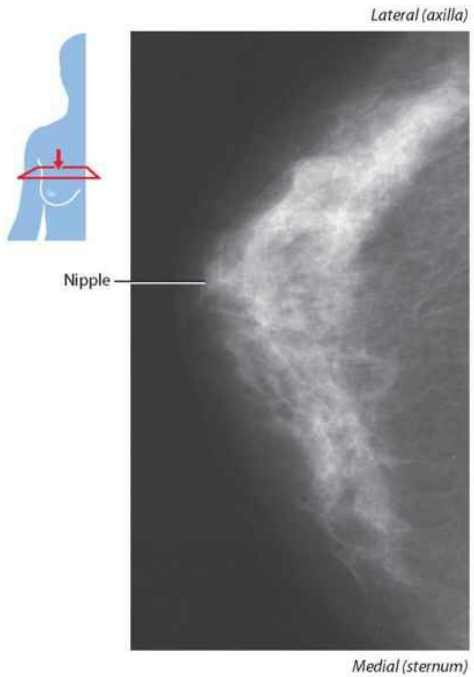
Lateral view



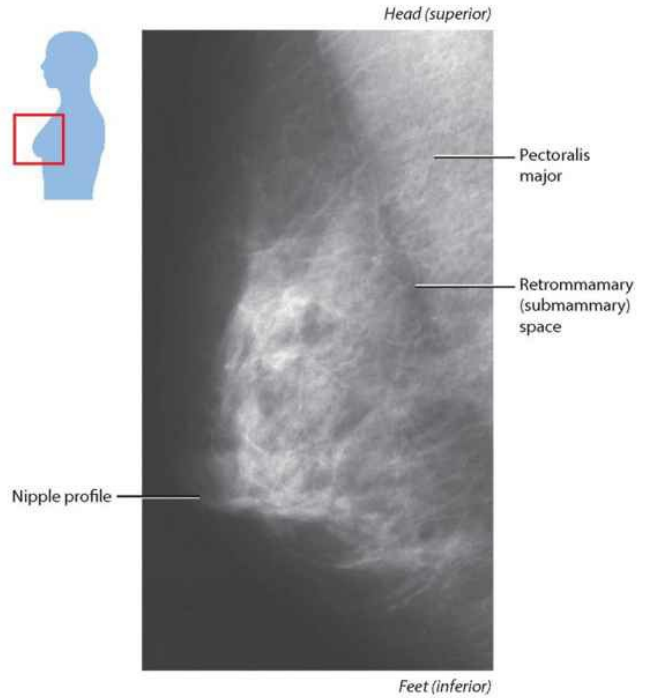


**Arteries and innervation of breast**

**Lymphatic drainage of breast**



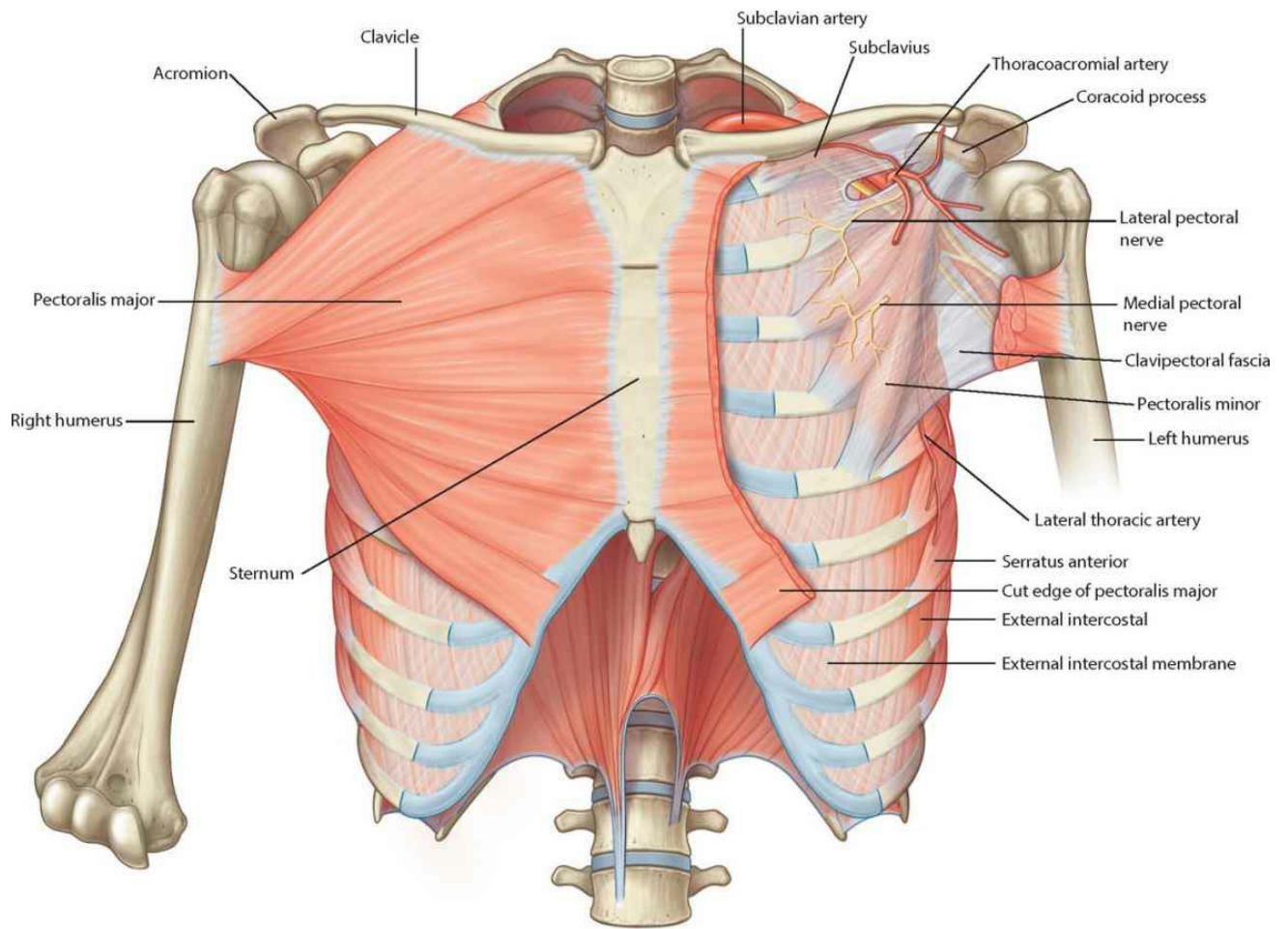
**Mammography. Craniocaudal (cc) view of a normal right breast showing a heterogeneously dense appearance**



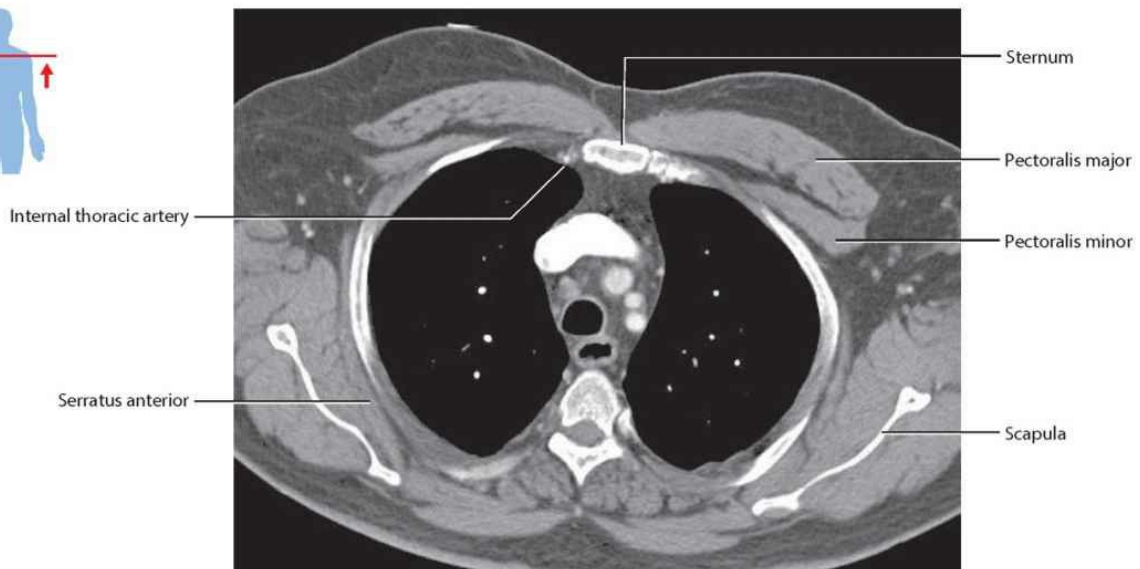
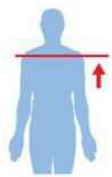
**Mammography. Mediolateral oblique (mlo) view of a normal right breast showing a heterogeneously dense appearance**



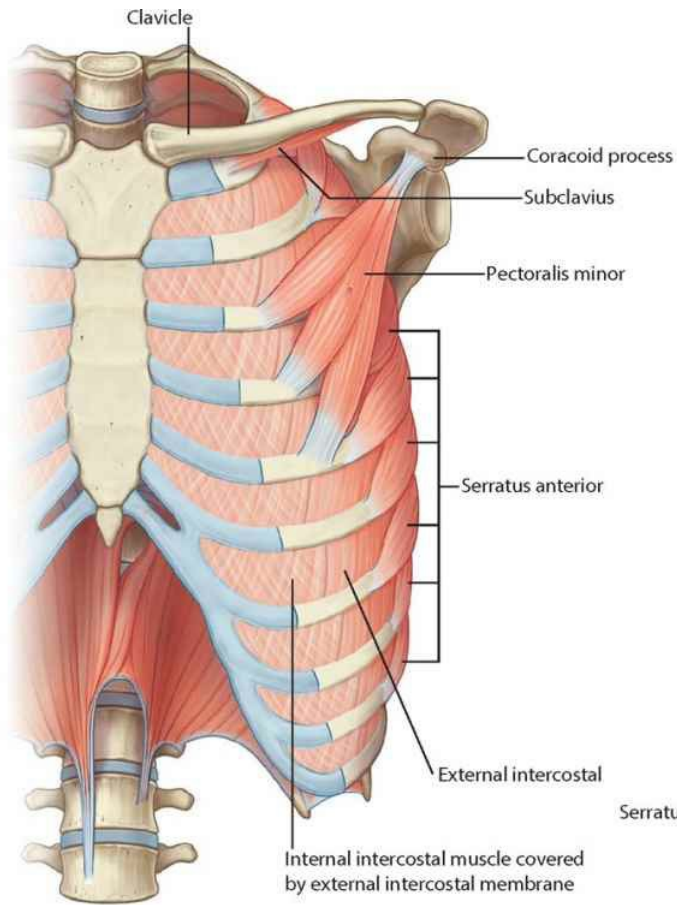
# Pectoral region



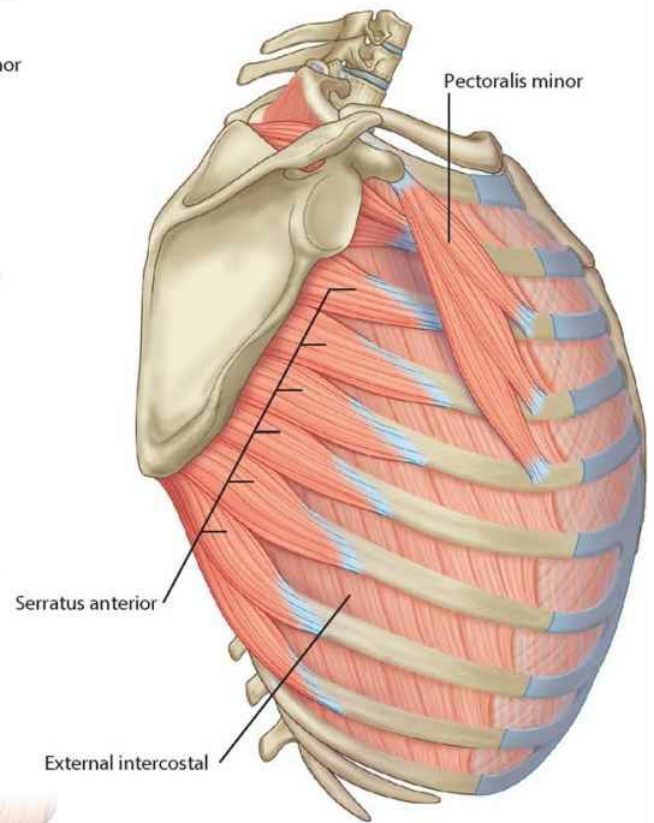
**Pectoralis major muscle and related deep structures**



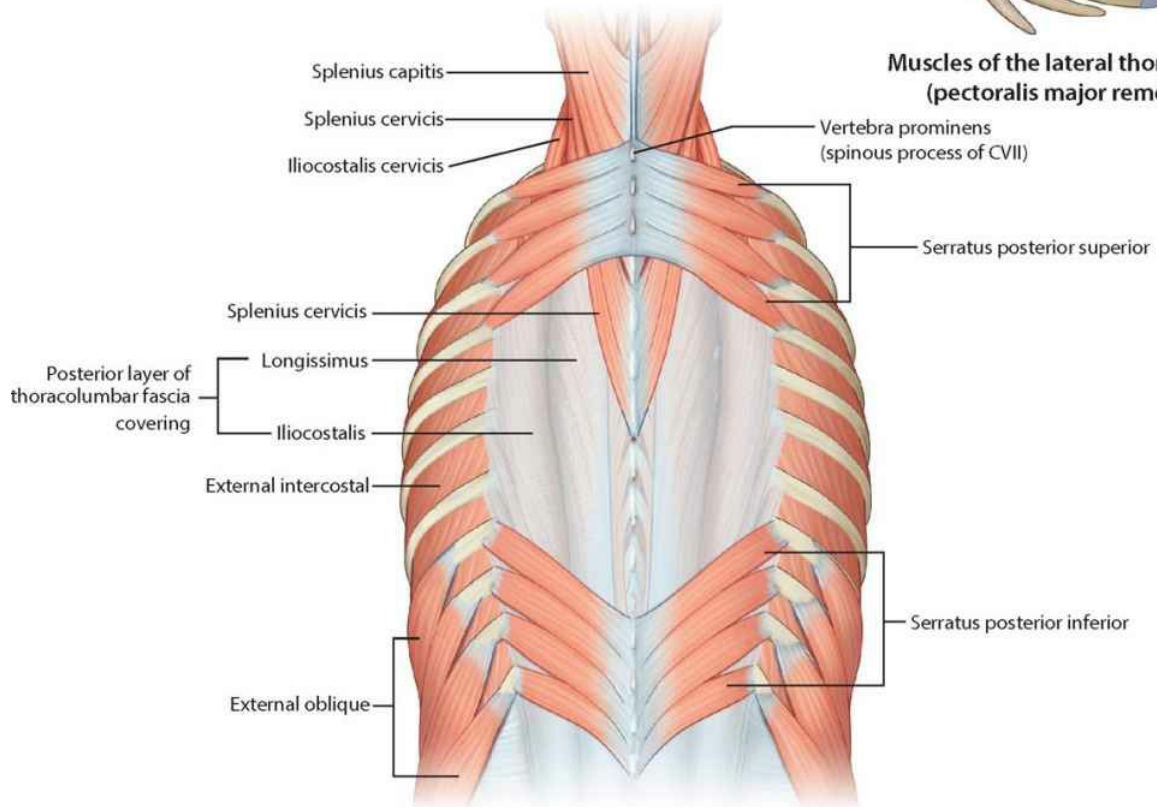
**Pectoralis major and minor muscles on anterior thoracic wall.**  
CT image, with contrast, in axial plane



**Pectoralis minor and the anterior thoracic wall  
(pectoralis major removed)**



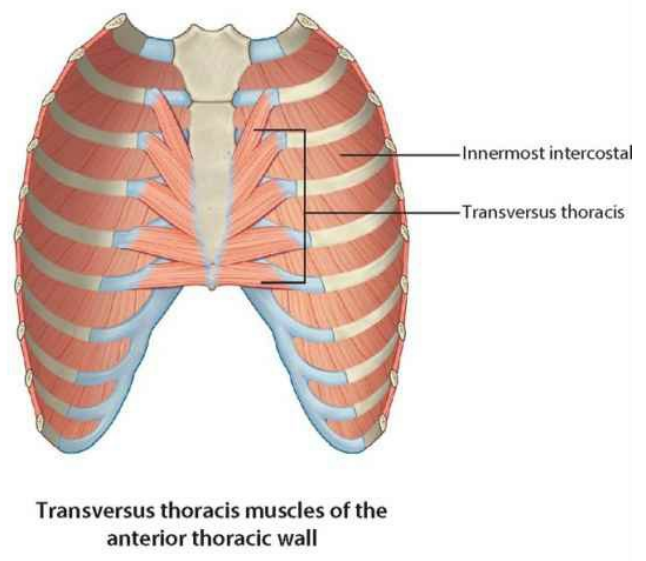
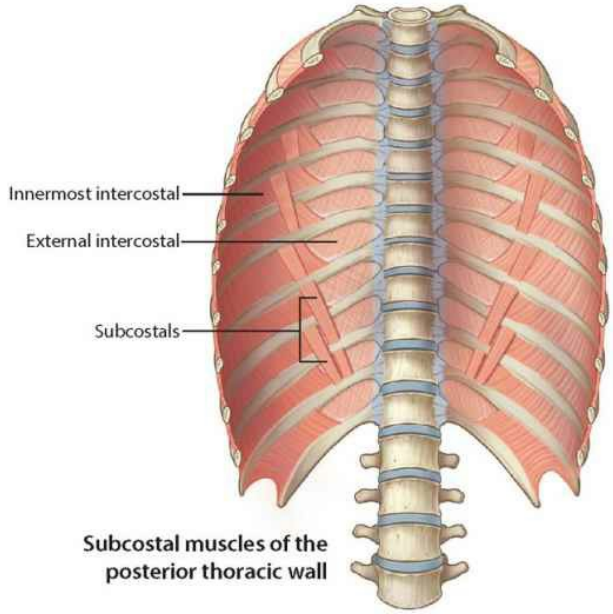
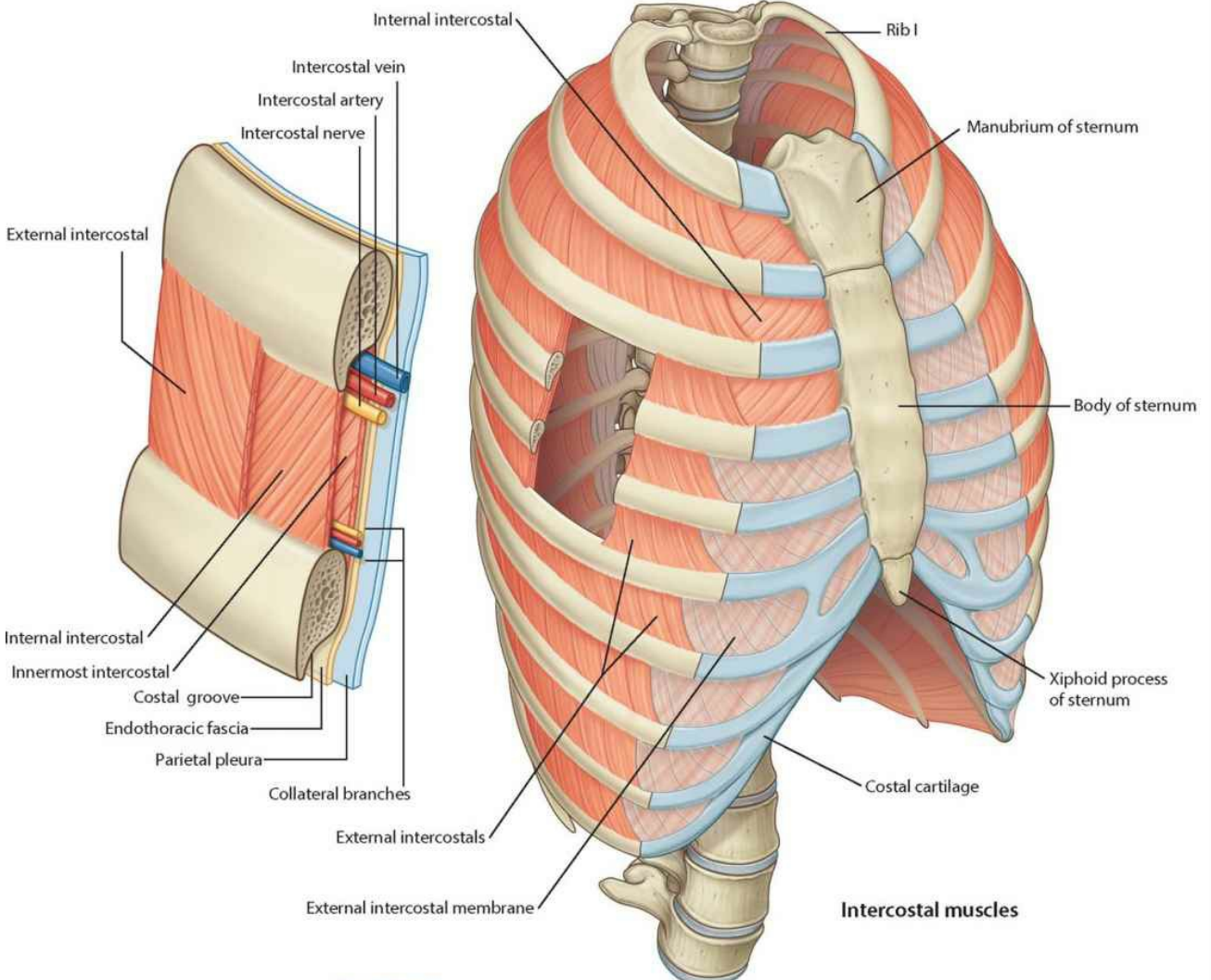
**Muscles of the lateral thoracic wall  
(pectoralis major removed)**



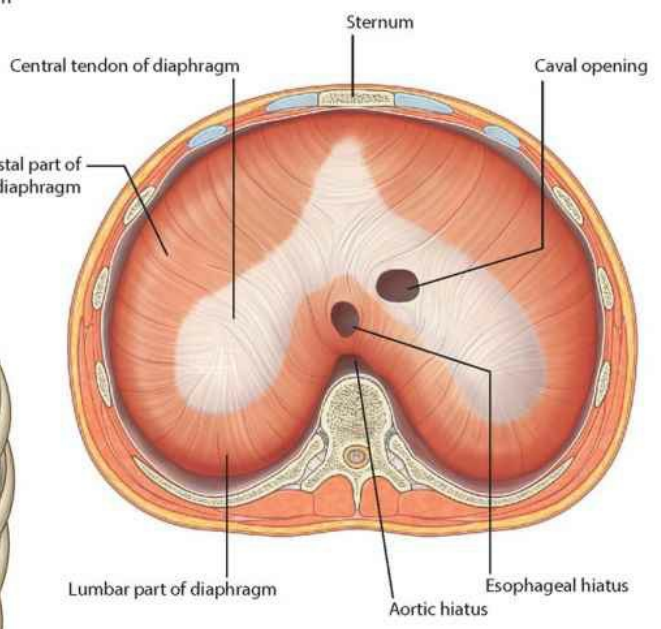
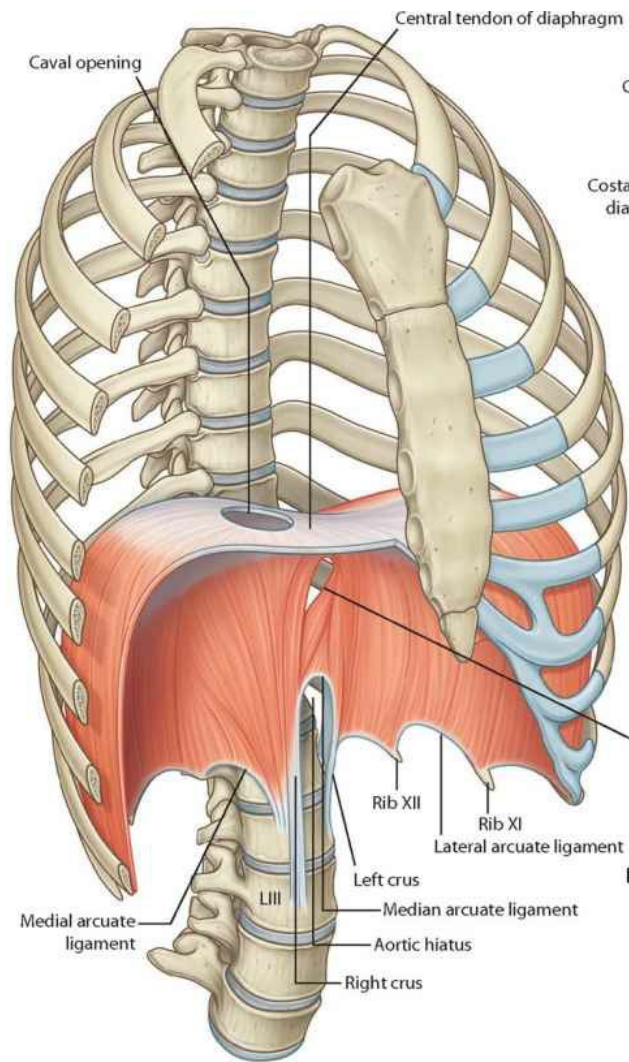
**Muscles of the posterior thoracic wall**



# Thoracic wall muscles

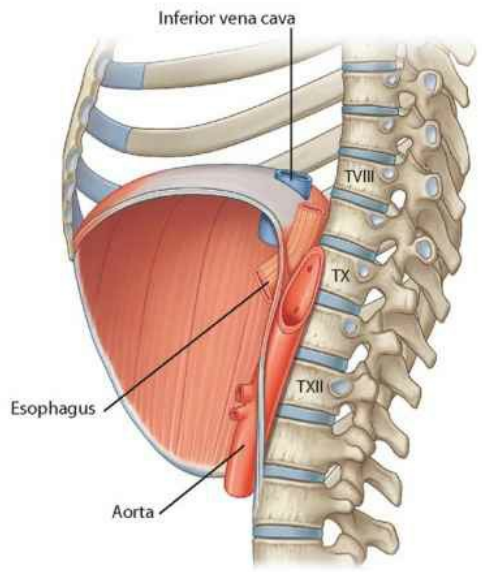


# Diaphragm

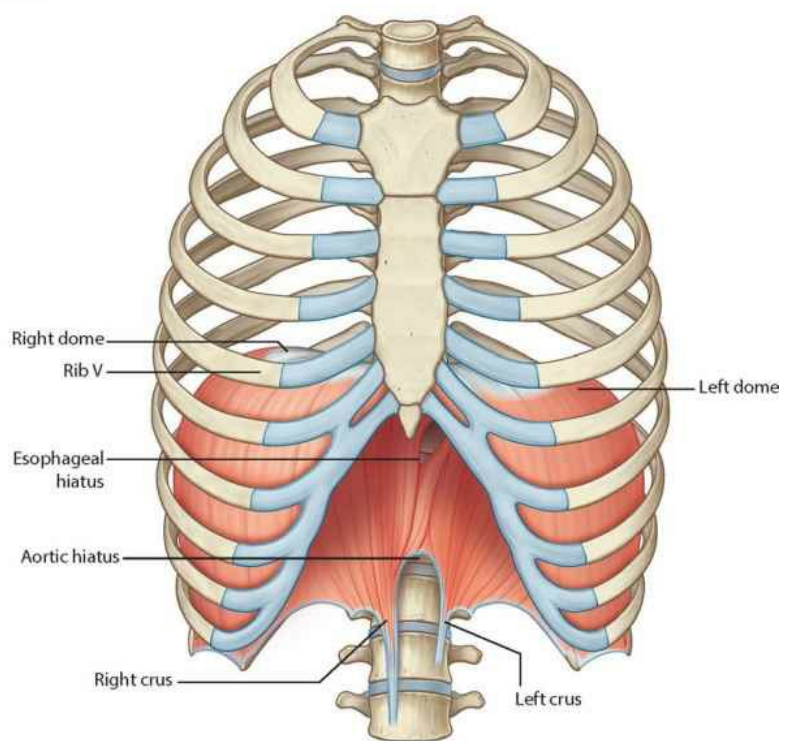


**Diaphragm superior view**

**Diaphragm within the rib cage**



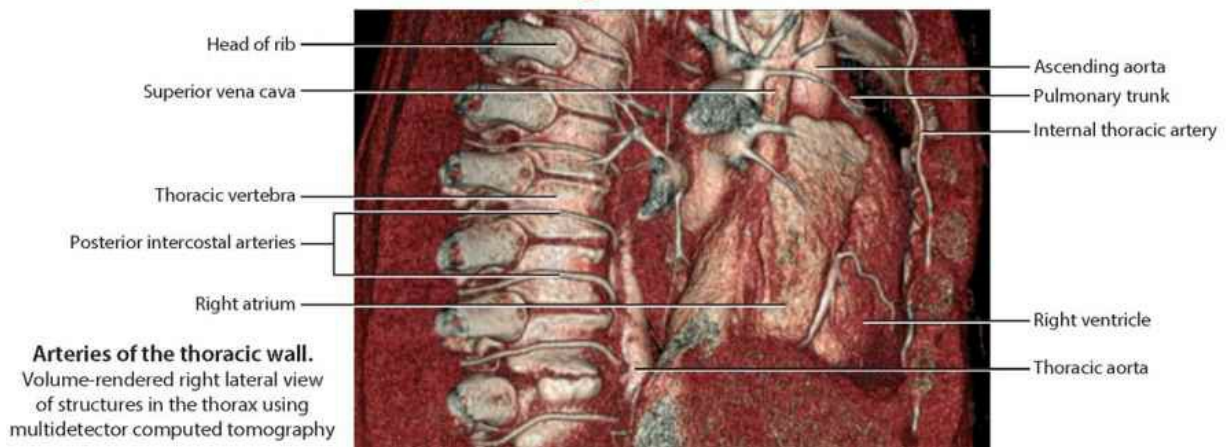
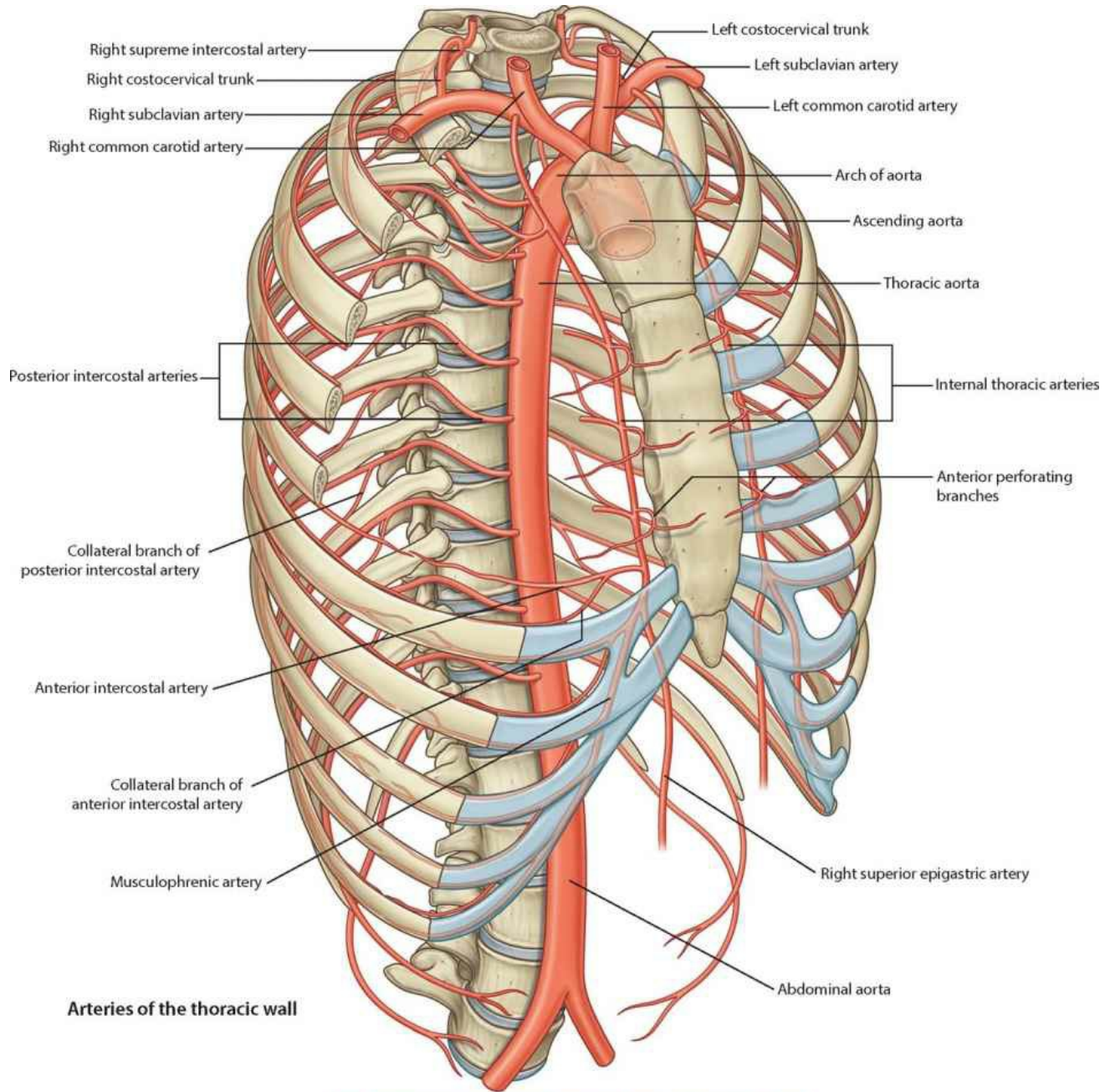
**Major structures that pass through the diaphragm**



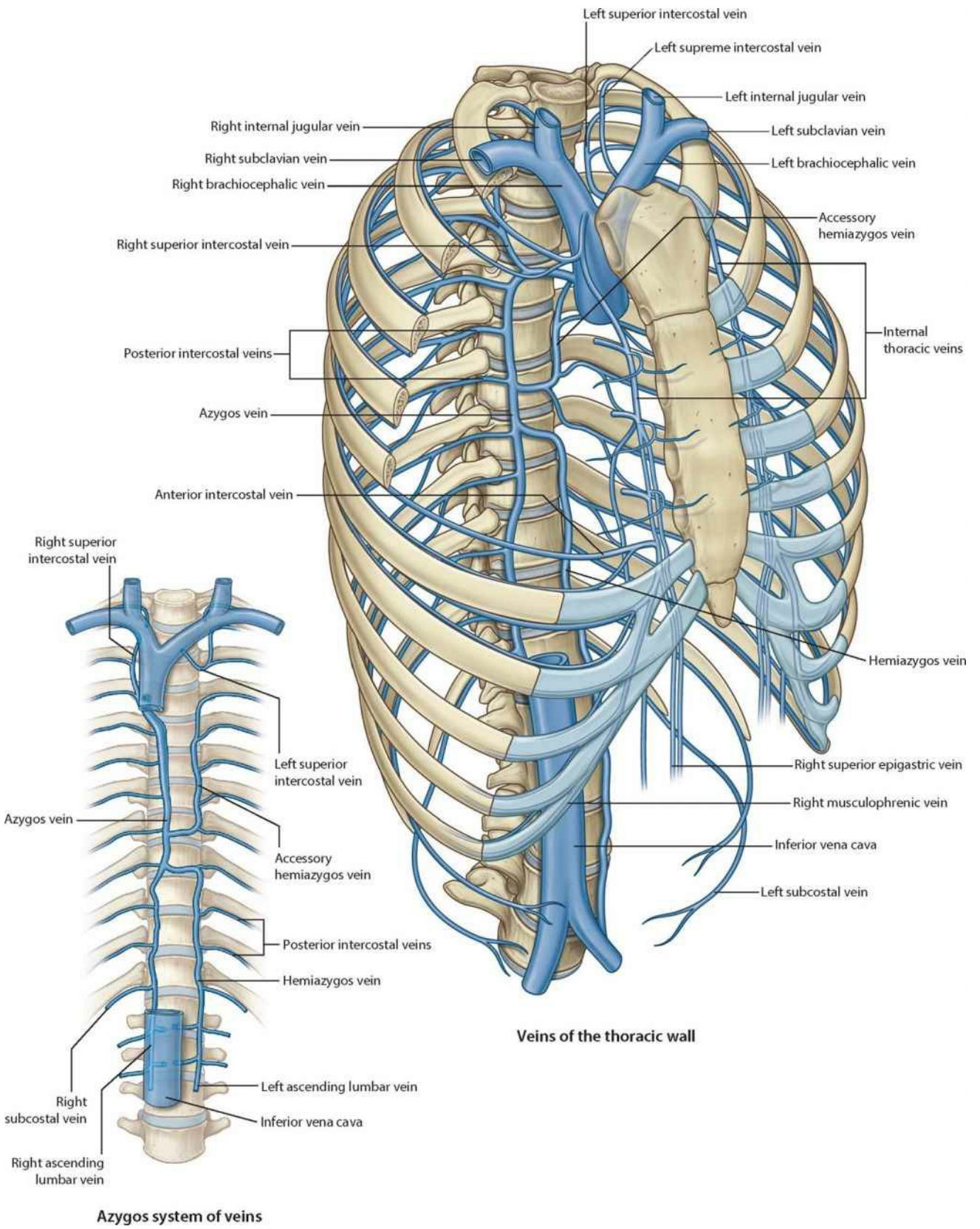
**Features of diaphragm**



# Arteries of the thoracic wall



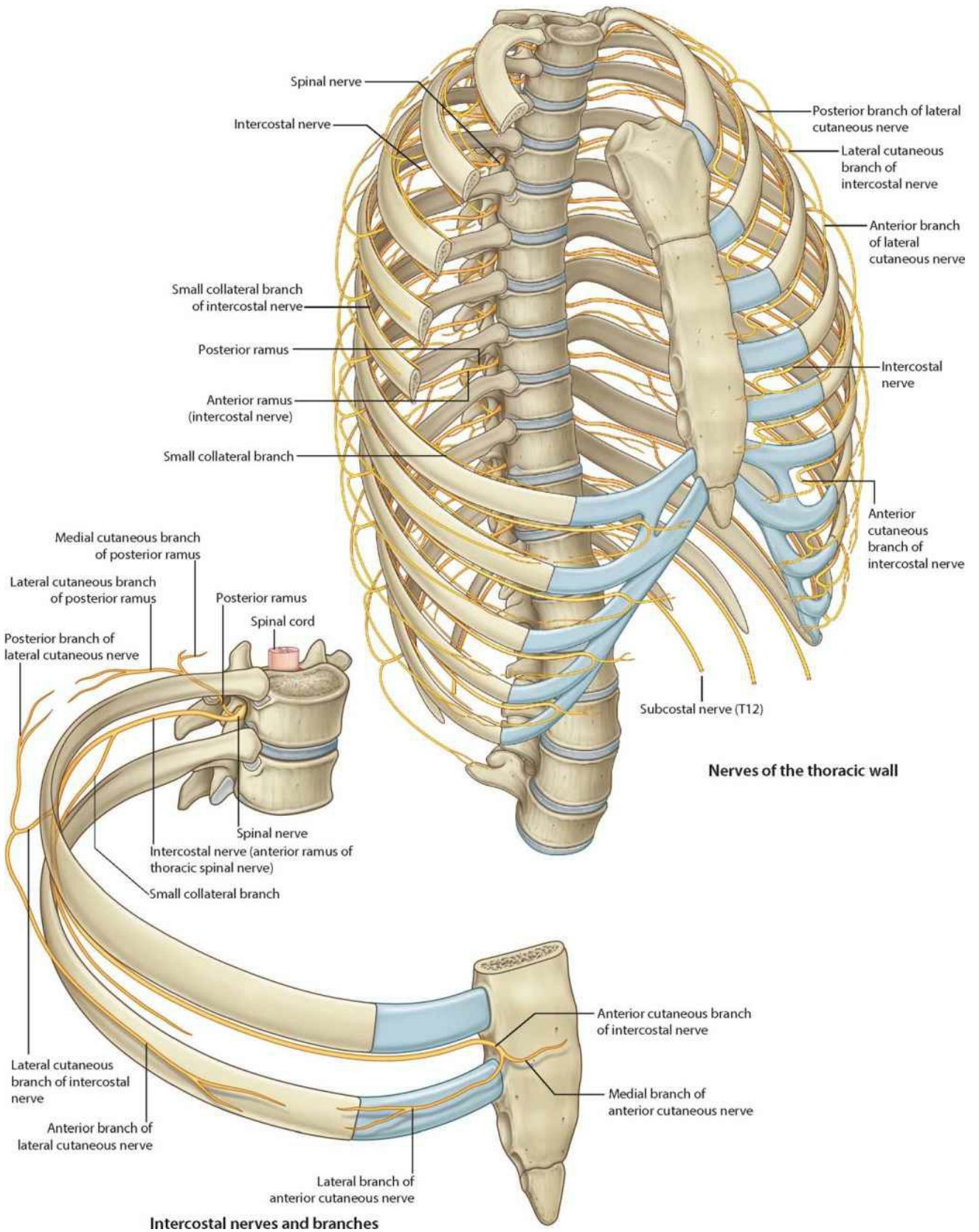
## **Veins of the thoracic wall**



**Veins of the thoracic wall**

**Azygos system of veins**

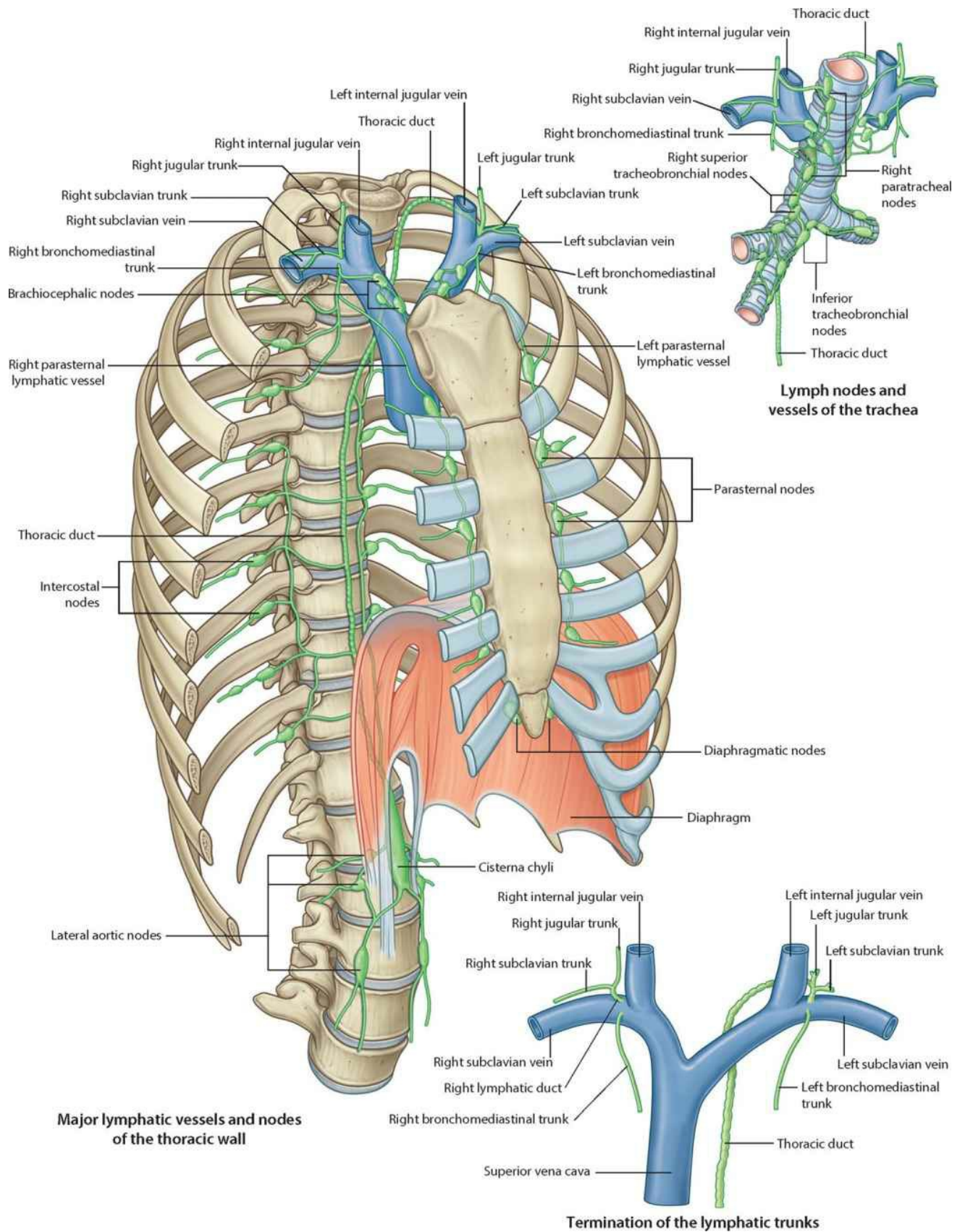
## Nerves of the thoracic wall



**Nerves of the thoracic wall**

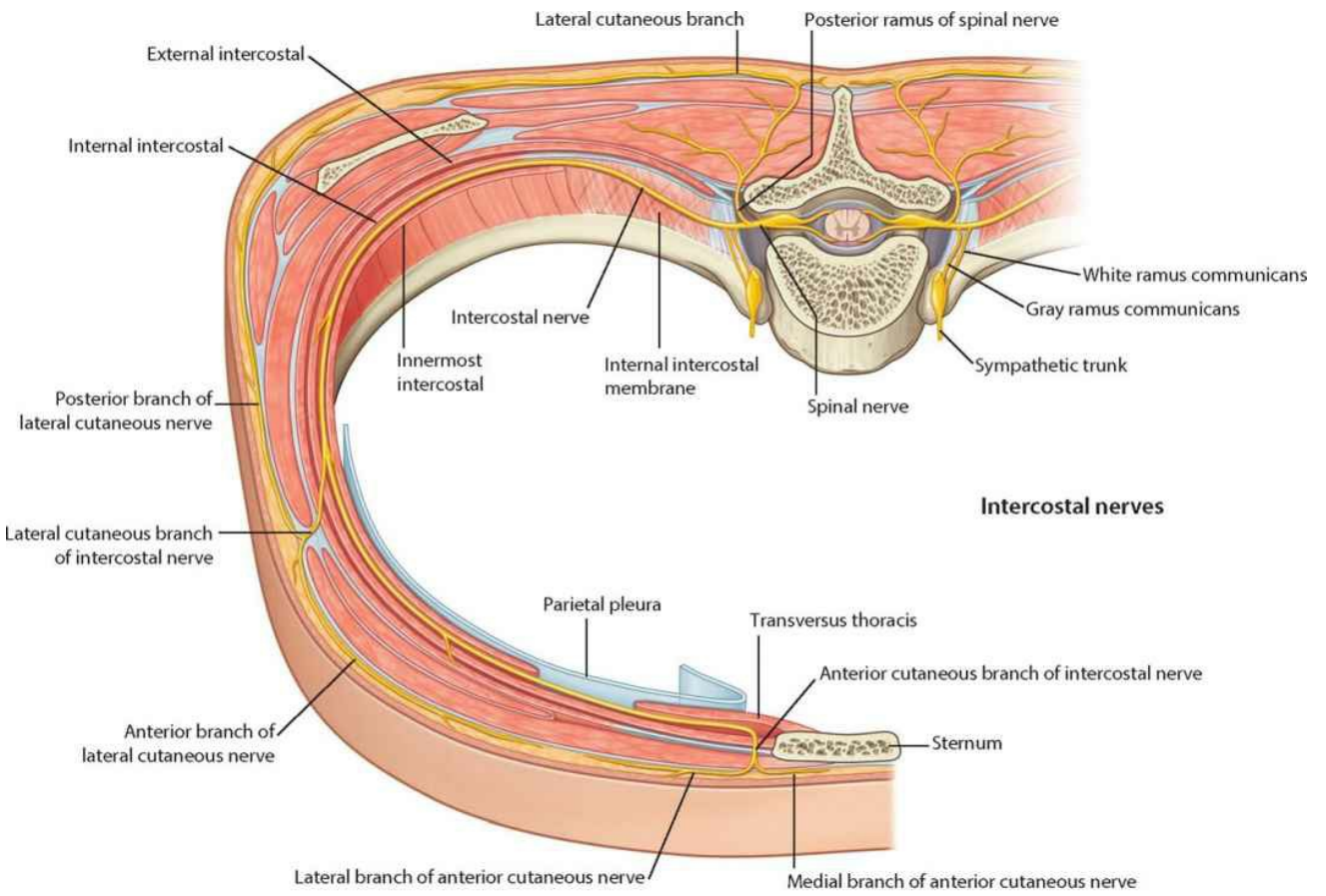
**Intercostal nerves and branches**

# Lymphatics of the thoracic wall

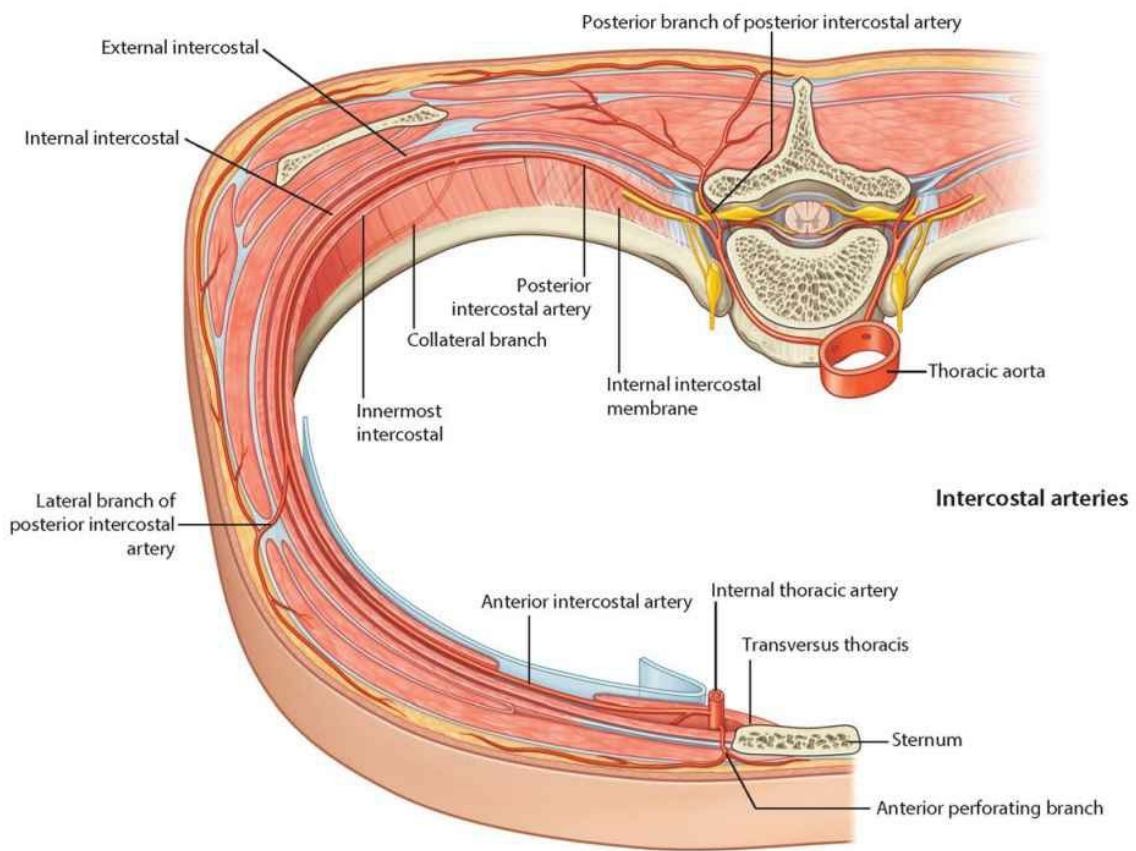




# Intercostal nerves and arteries

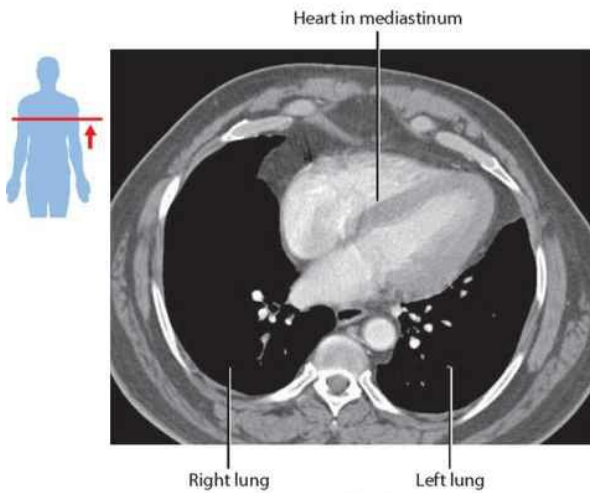
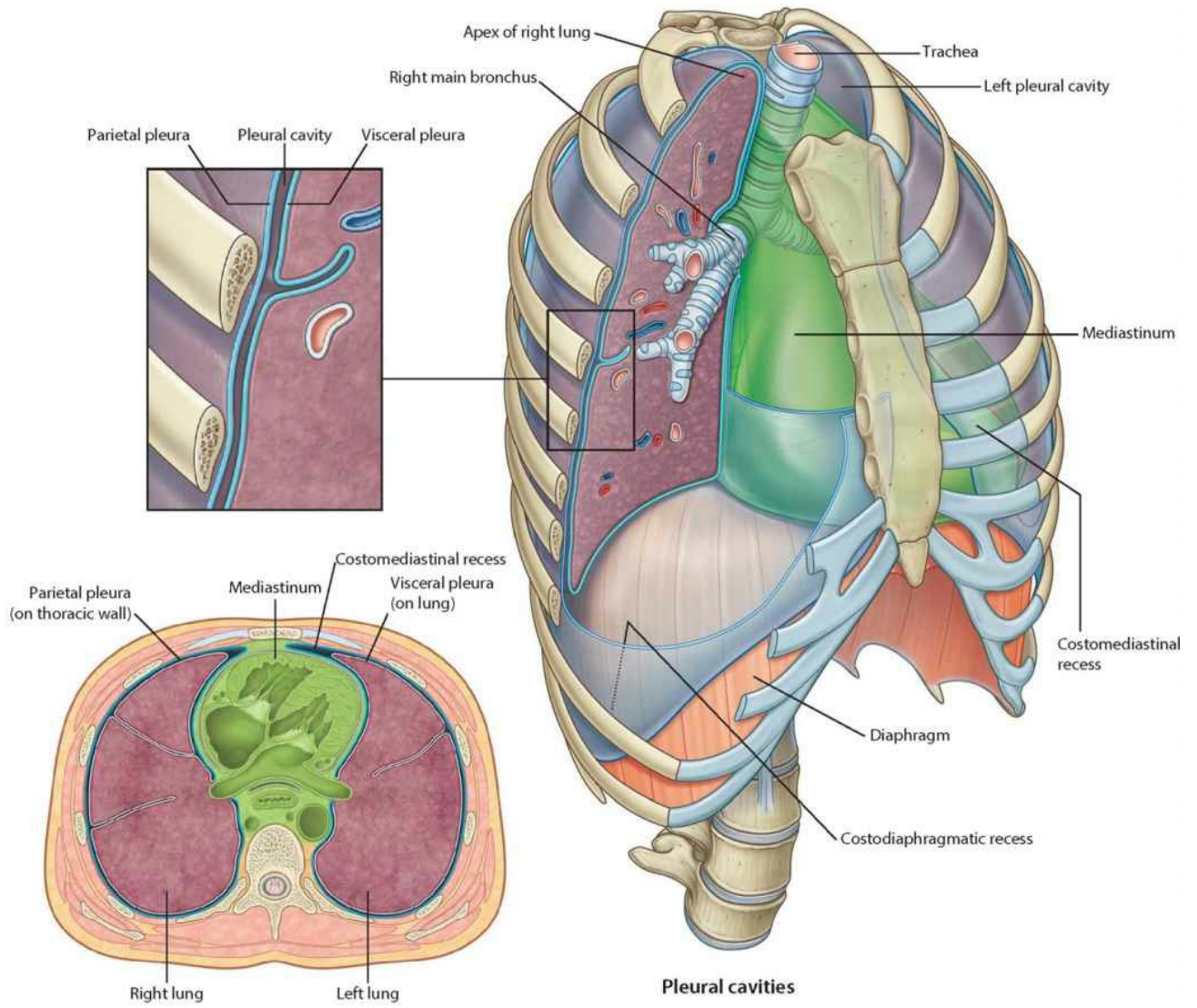


**Intercostal nerves**

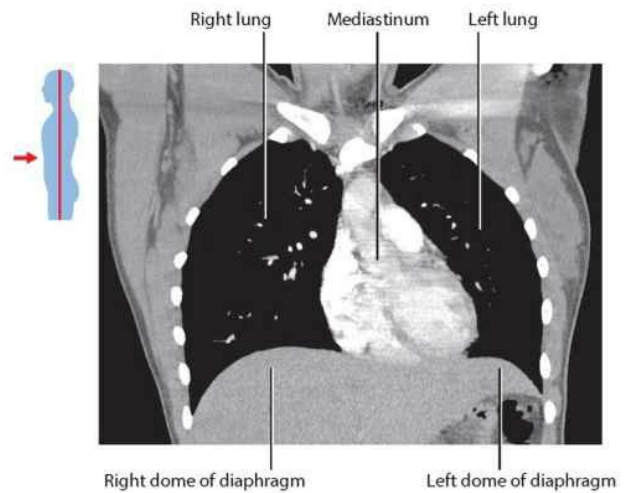


**Intercostal arteries**

# Pleural cavities and mediastinum

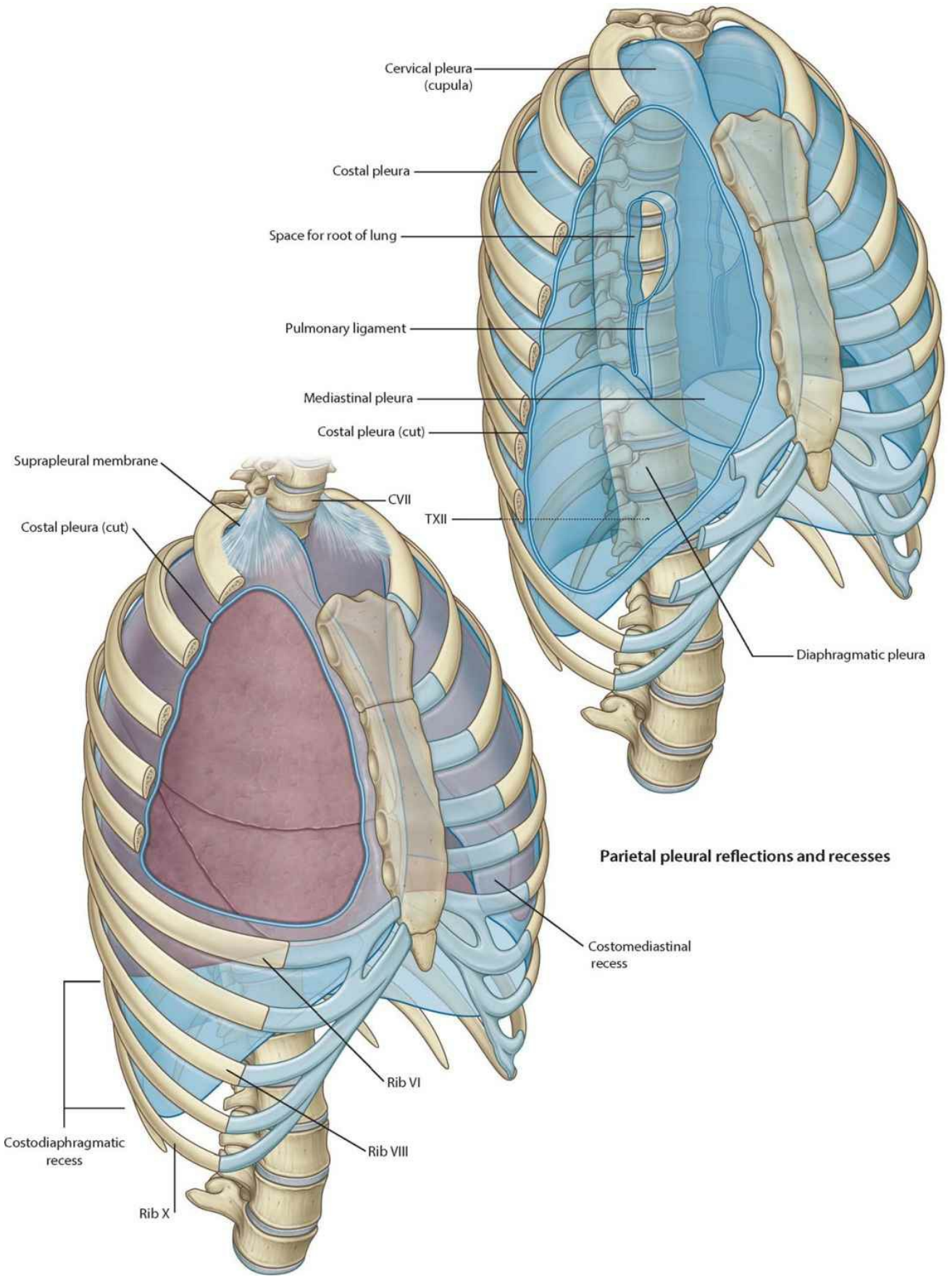


**Organization of the thoracic cavity.**  
CT image, with contrast, in axial plane

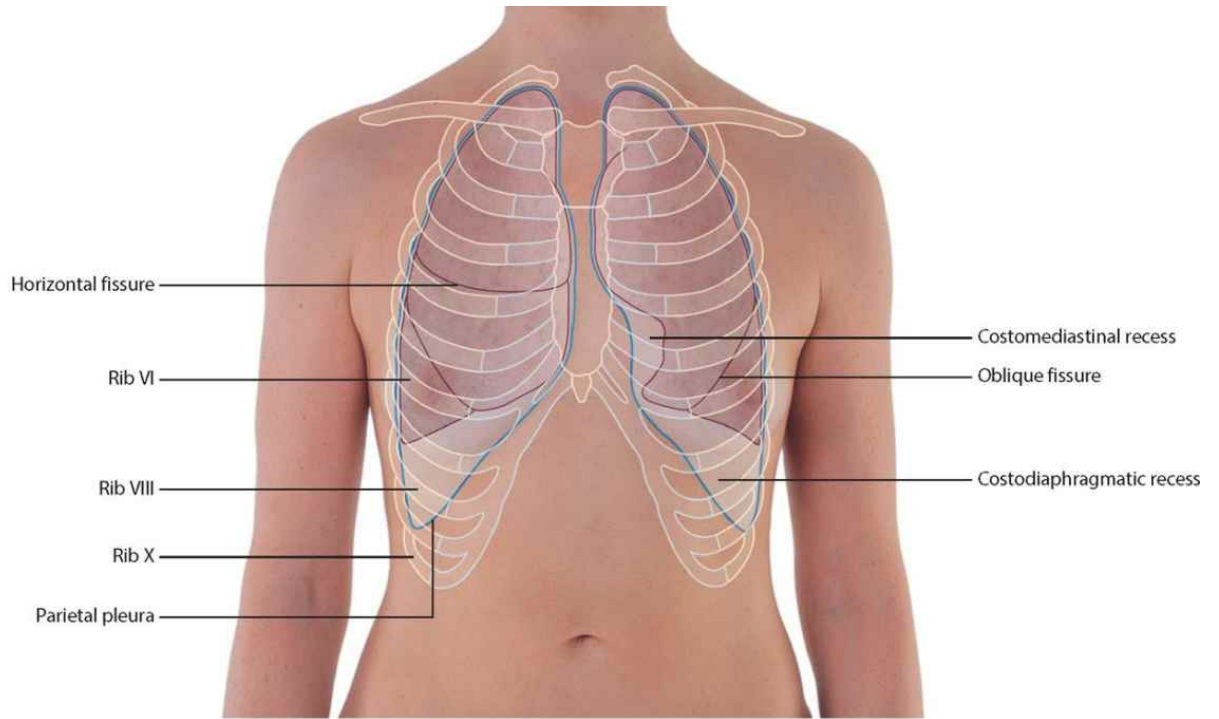


**Organization of the thoracic cavity.**  
CT image, with contrast, in coronal plane

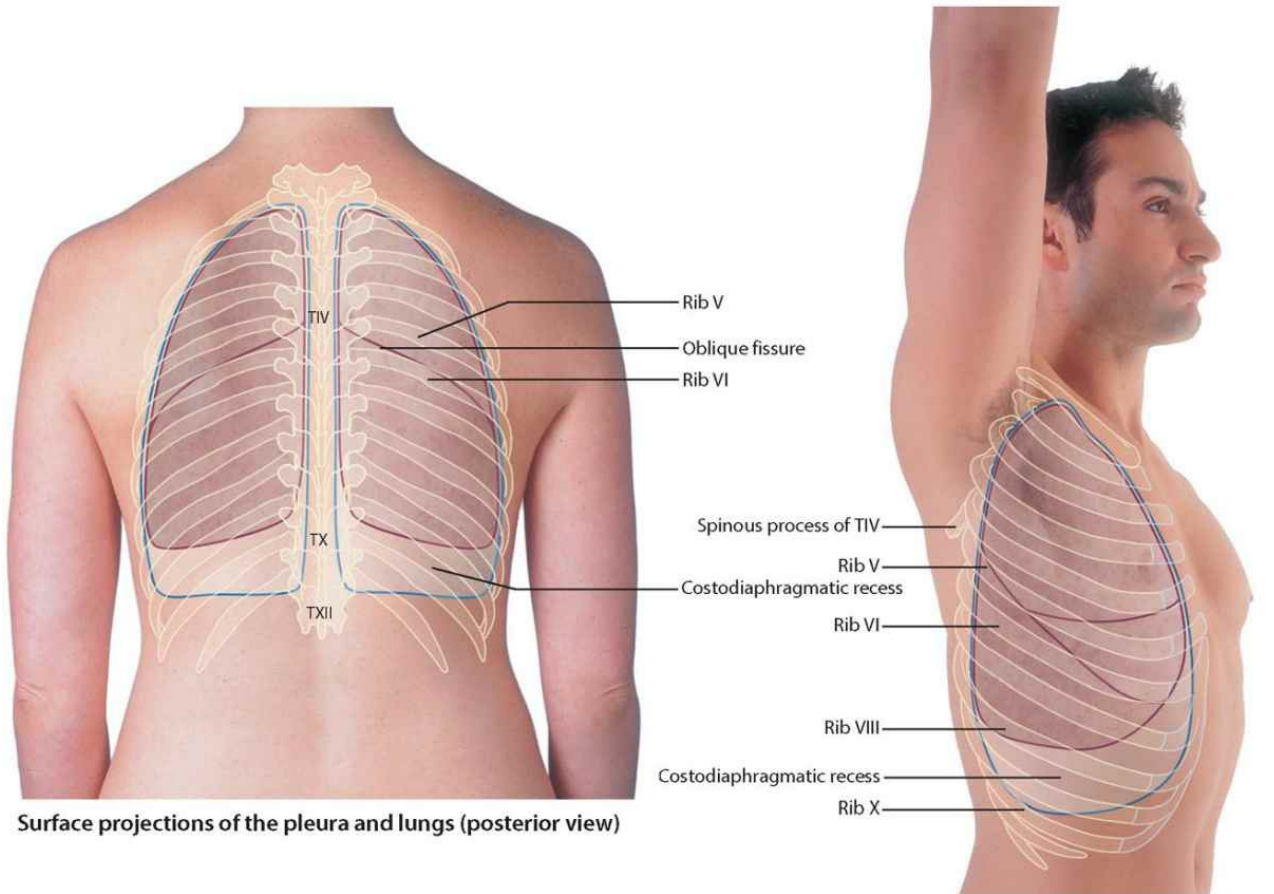
# Parietal pleura



# Surface projections of pleural recesses



Surface projections of the pleura and lungs (anterior view)

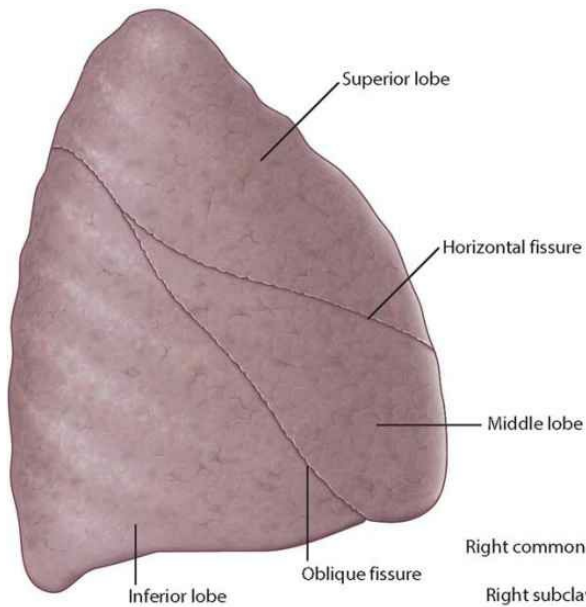


Surface projections of the pleura and lungs (posterior view)

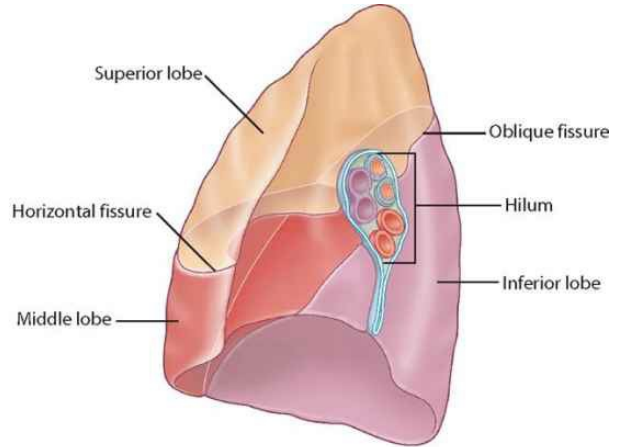
Surface projections of the pleura and right lung (lateral view)



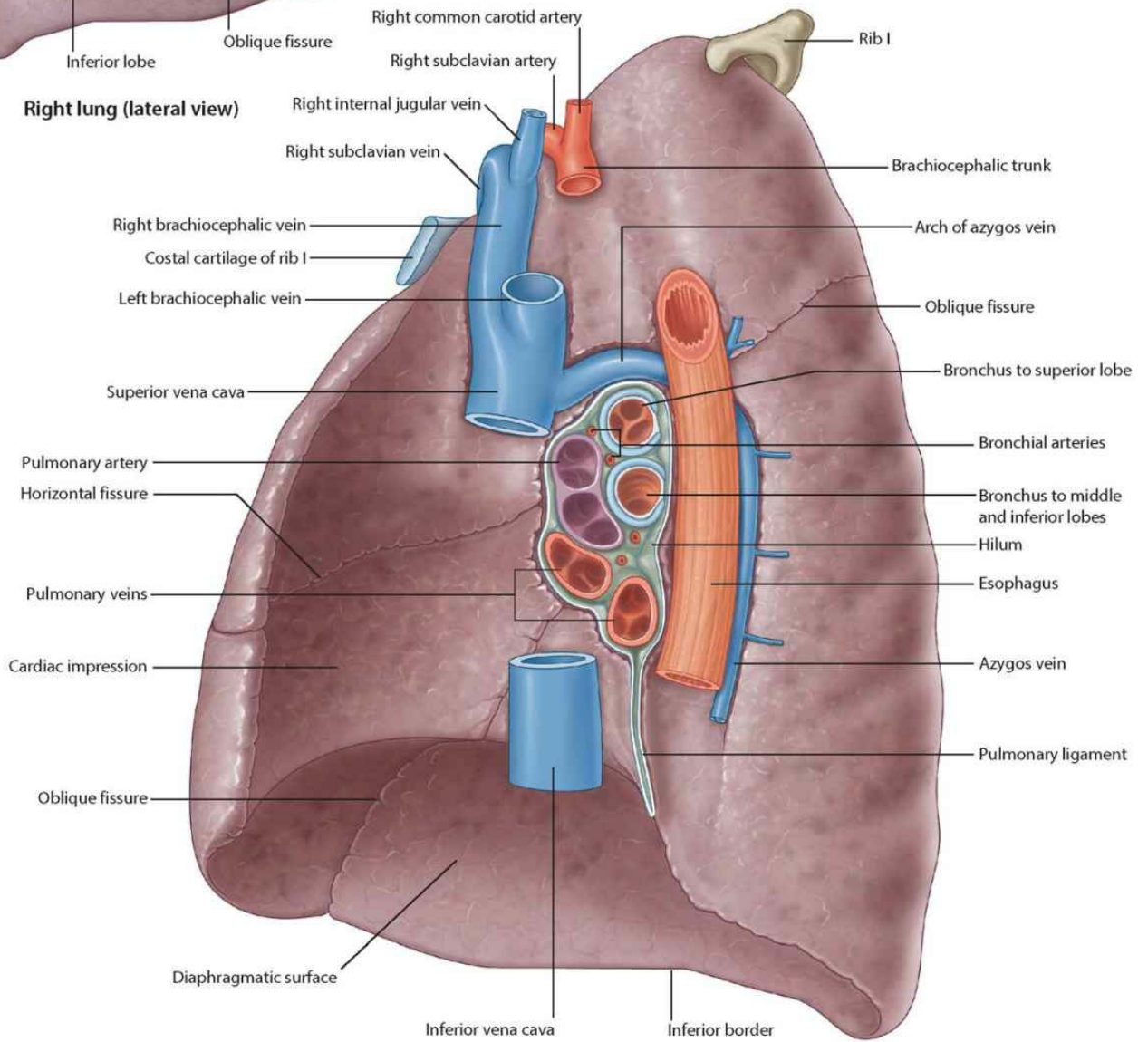
# Right lung



**Right lung (lateral view)**

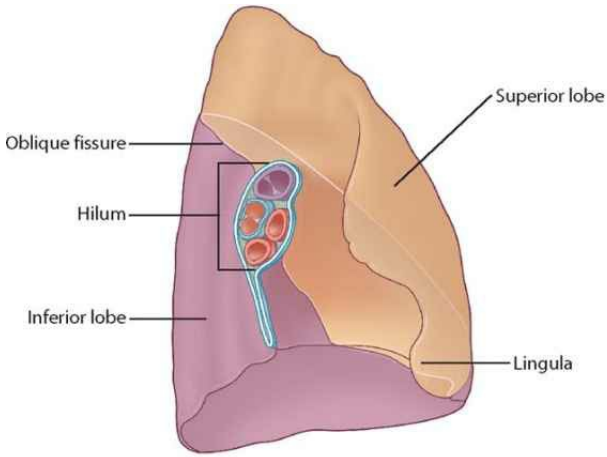


**Lobes of the right lung (anteromedial view)**

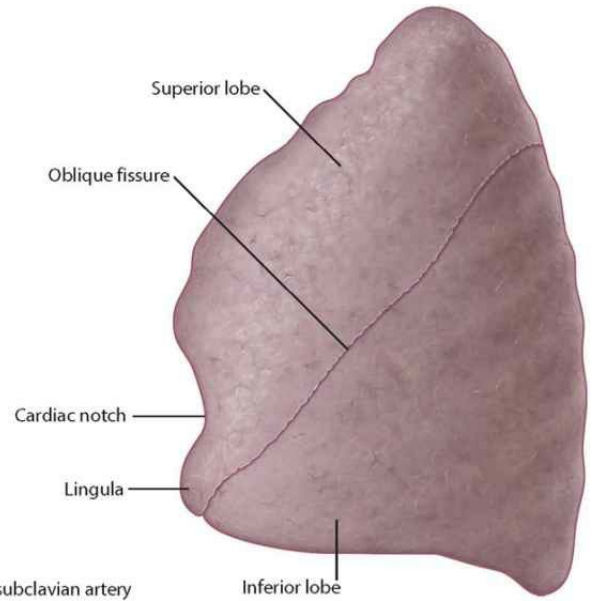


**Right lung and related structures (medial view)**

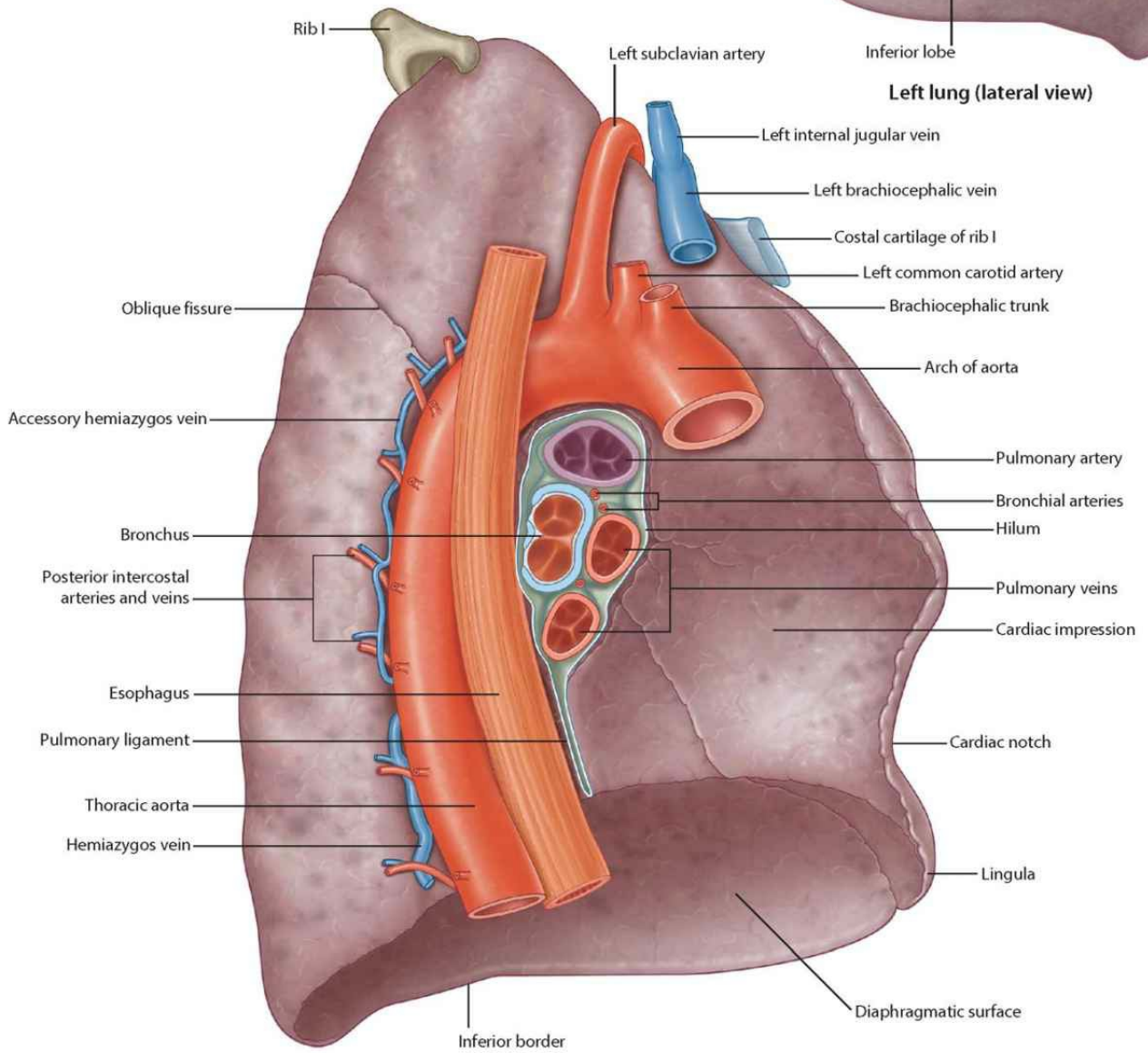
# Left lung



**Lobes of the left lung (anteromedial view)**

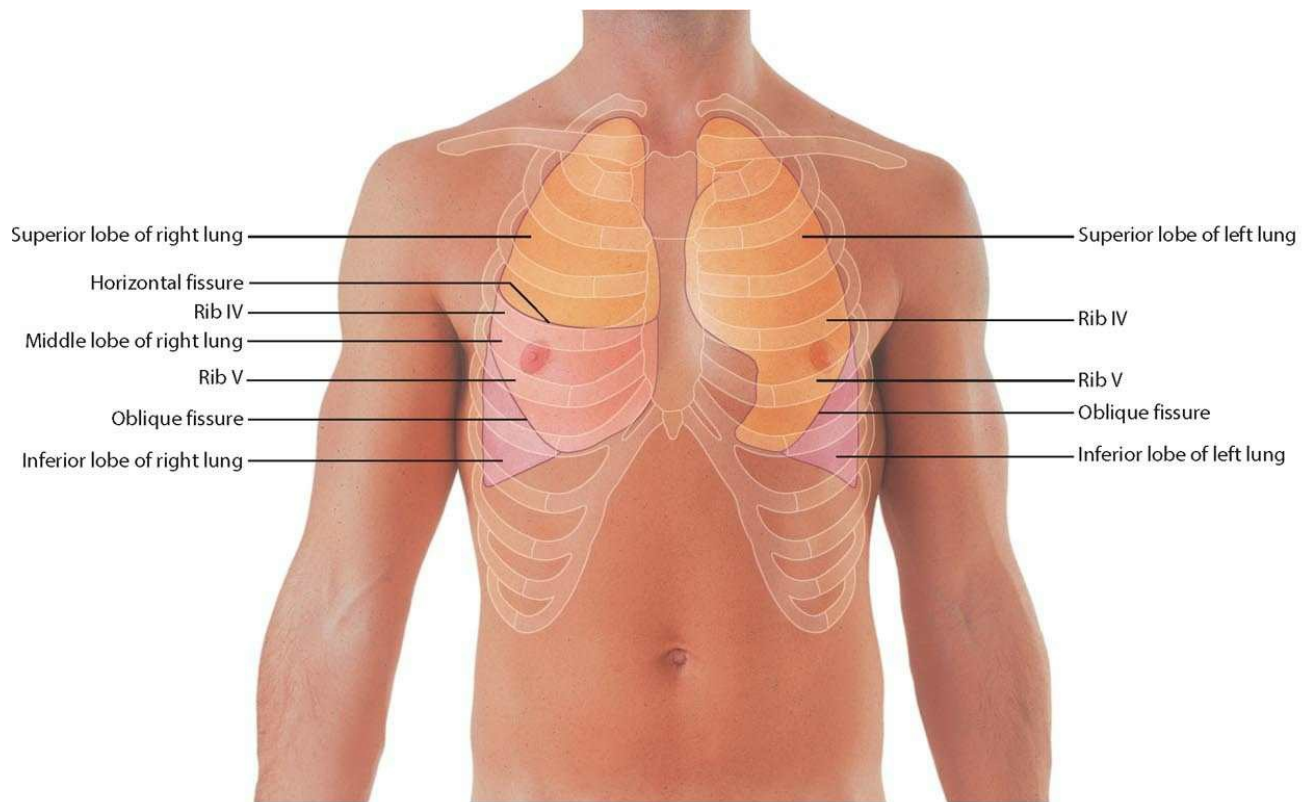


**Left lung (lateral view)**

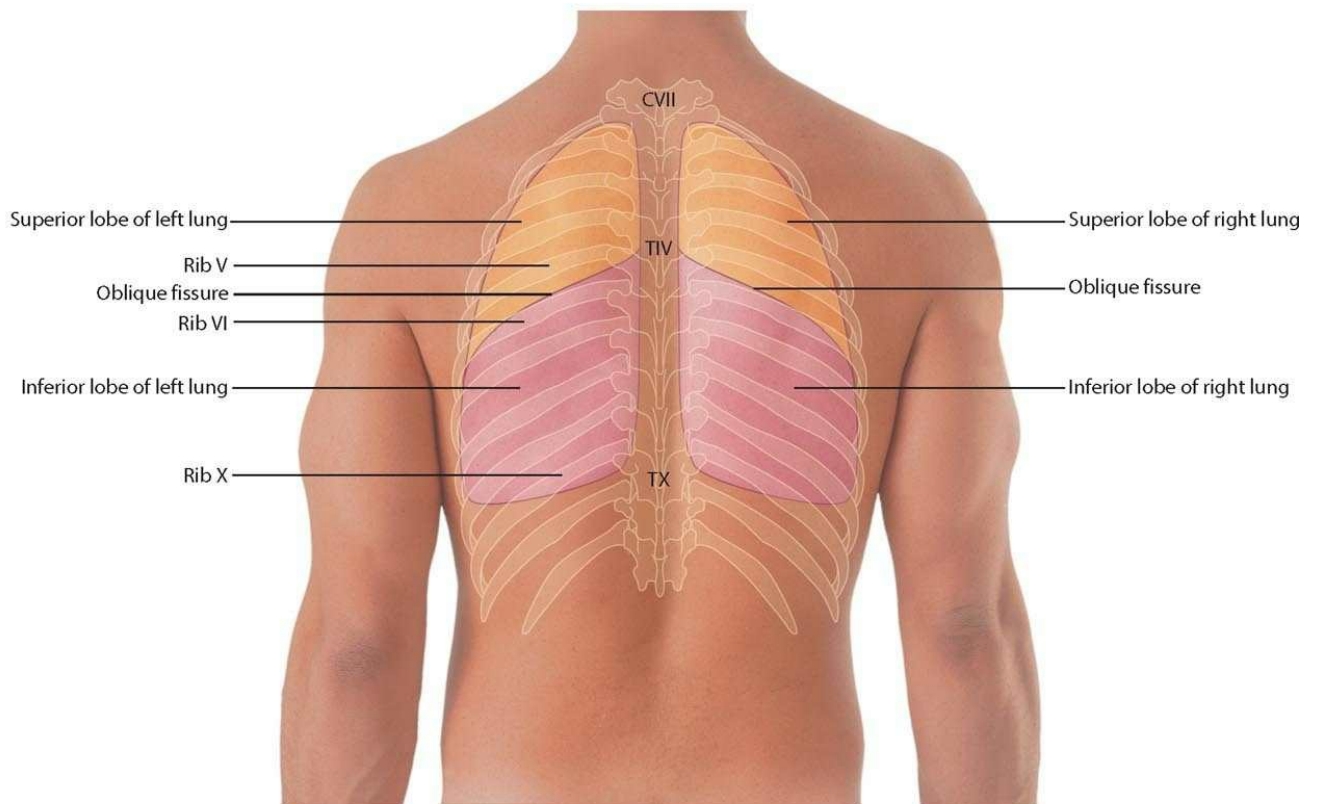


**Left lung and related structures (medial view)**

## **Lung lobes: surface relationship**

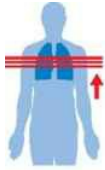


Surface projections of the lobes and fissures of the lungs (anterior view)



Surface projections of the lobes and fissures of the lungs (posterior view)

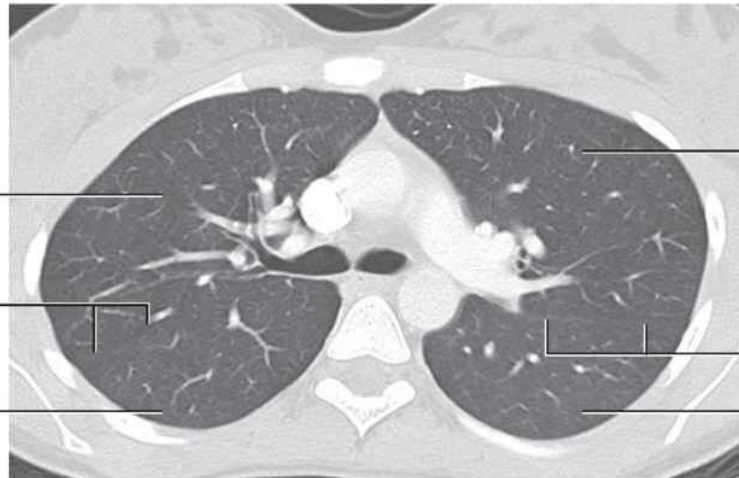# Lung lobes: imaging



Superior lobe of right lung

Oblique fissure

Inferior lobe of right lung



Superior lobe of left lung

Oblique fissure

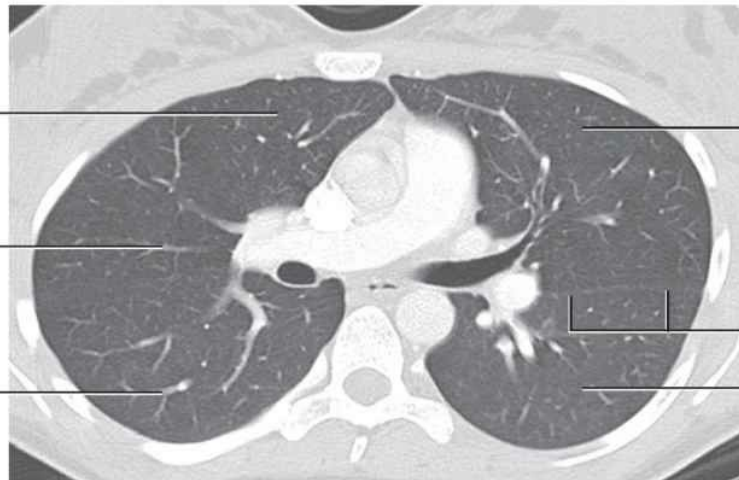
Inferior lobe of left lung

**Right lung and left lung demonstrating superior and inferior lobes. The oblique fissures are visible**  
CT image, with contrast, in axial plane

Superior lobe of right lung

Middle lobe of right lung

Inferior lobe of right lung



Superior lobe of left lung

Oblique fissure

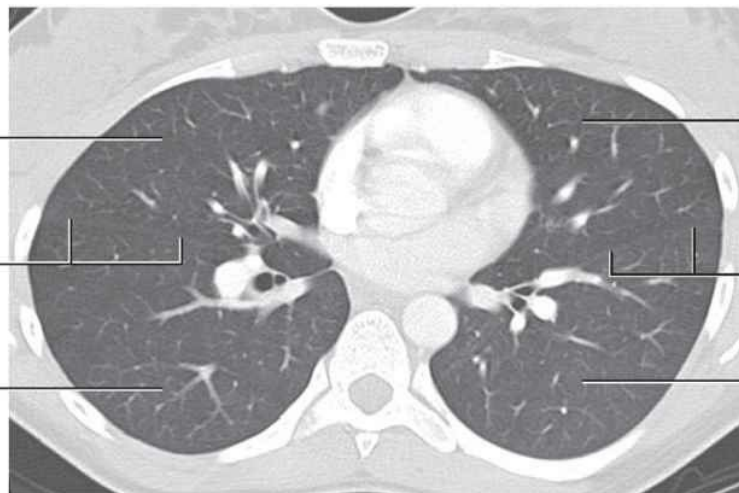
Inferior lobe of left lung

**Right lung demonstrating superior, middle, and inferior lobes and the left lung demonstrating superior and inferior lobes. The oblique fissure associated with the left lung is visible.**  
CT image, with contrast, in axial plane

Middle lobe of right lung

Oblique fissure

Inferior lobe of right lung



Superior lobe of left lung

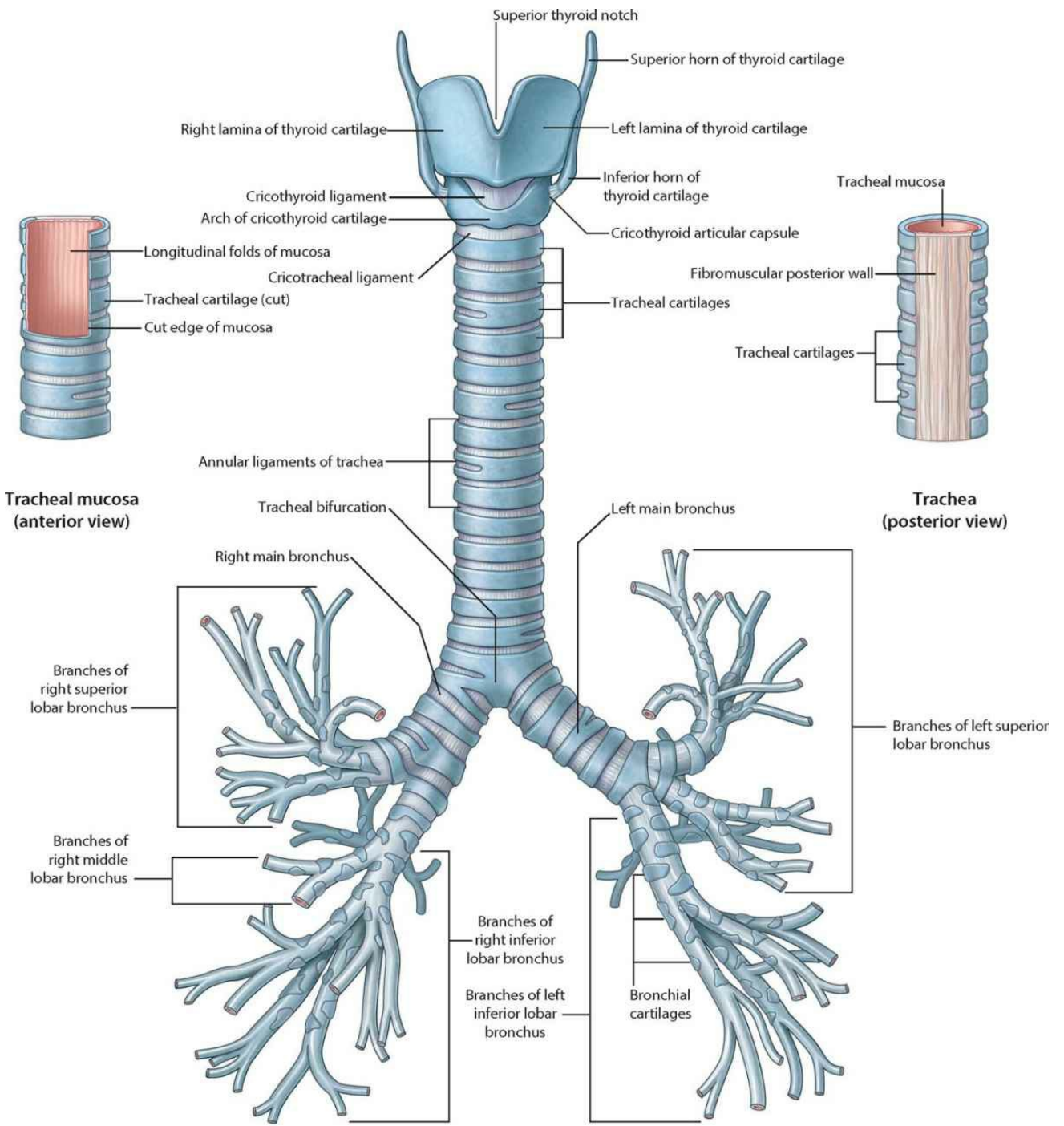
Oblique fissure

Inferior lobe of left lung

**Right lung demonstrating middle and inferior lobes and the left lung demonstrating superior and inferior lobes. The oblique fissures are visible.**  
CT image, with contrast, in axial plane



# Bronchial tree

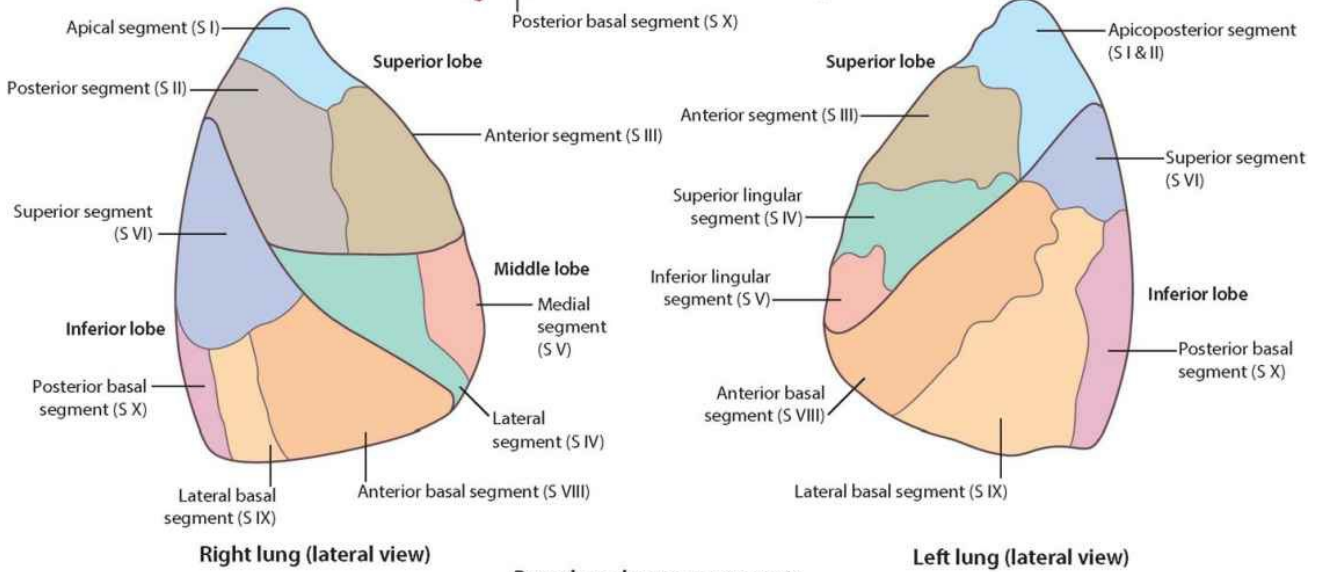
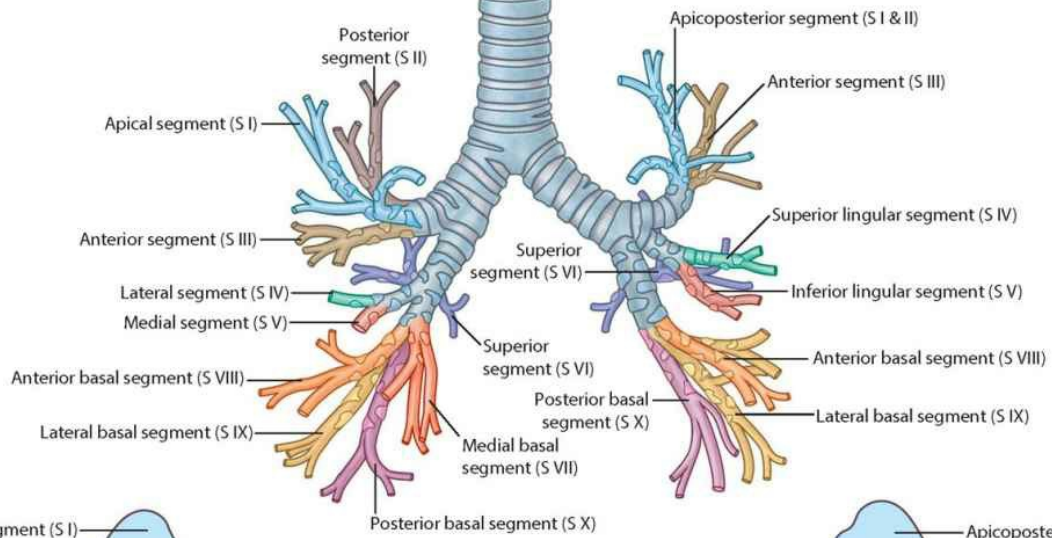
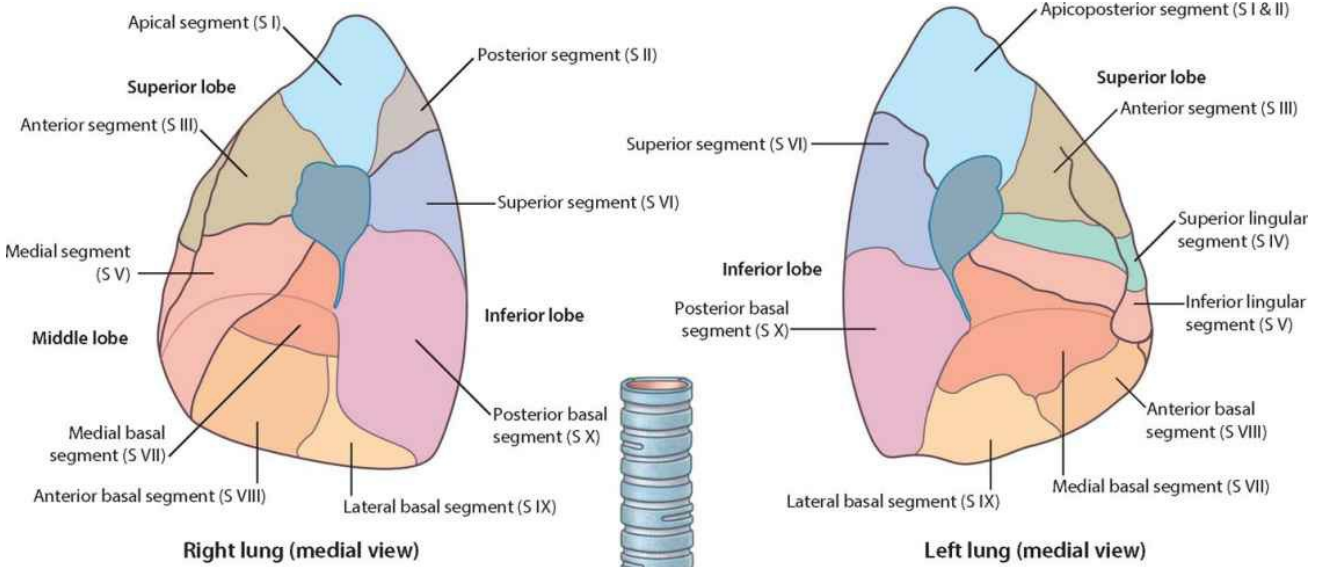


**Tracheal mucosa (anterior view)**

**Trachea (posterior view)**

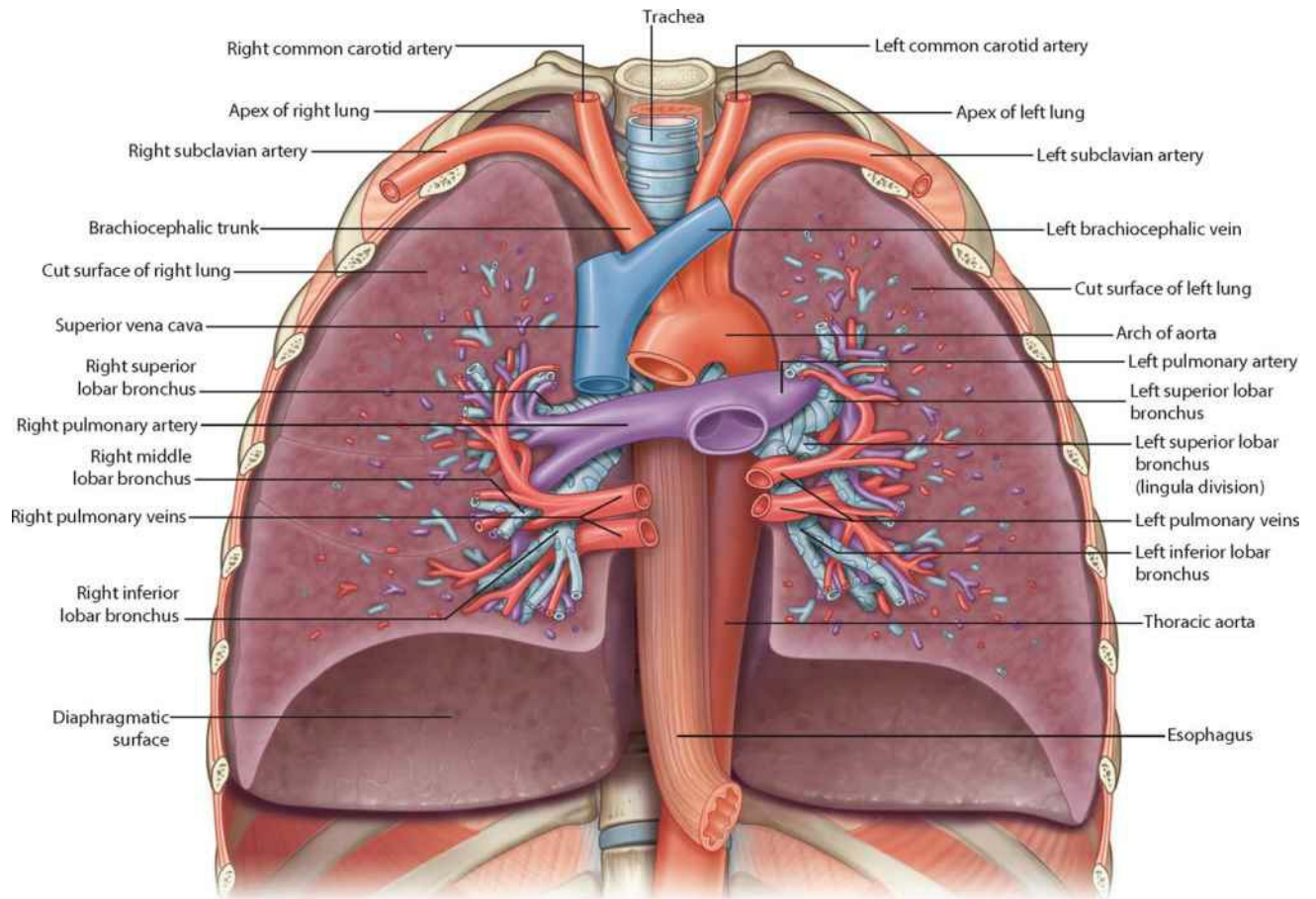
**Trachea and bronchial tree**

# Bronchopulmonary segments

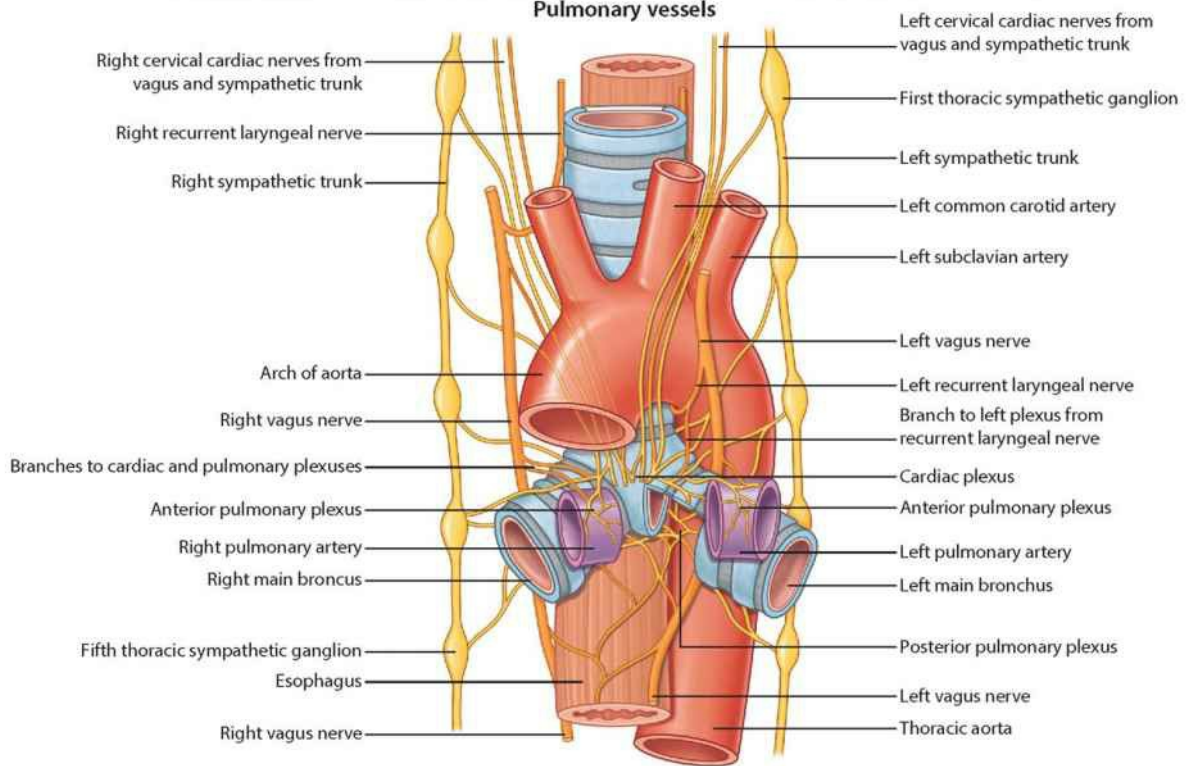


**Bronchopulmonary segments**

# Pulmonary vessels and plexus

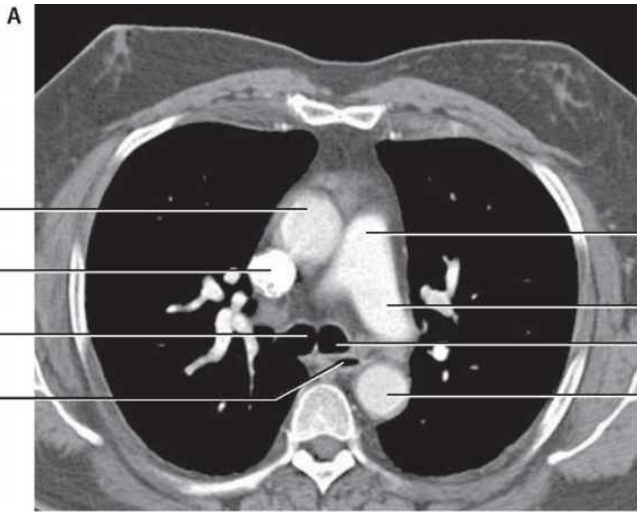



**Pulmonary vessels**

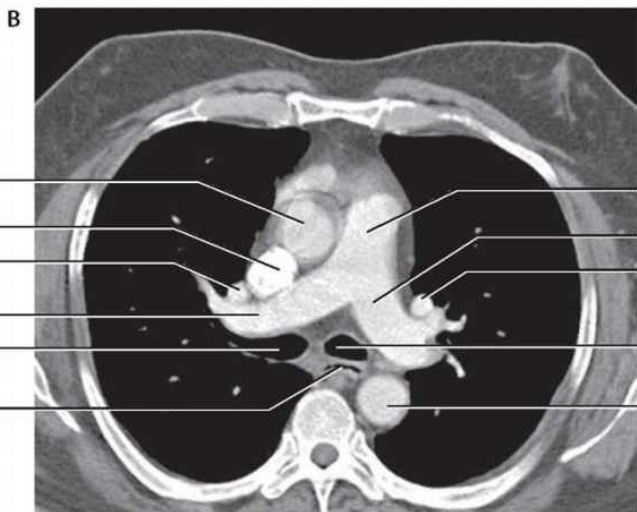
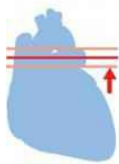


**Pulmonary plexus**

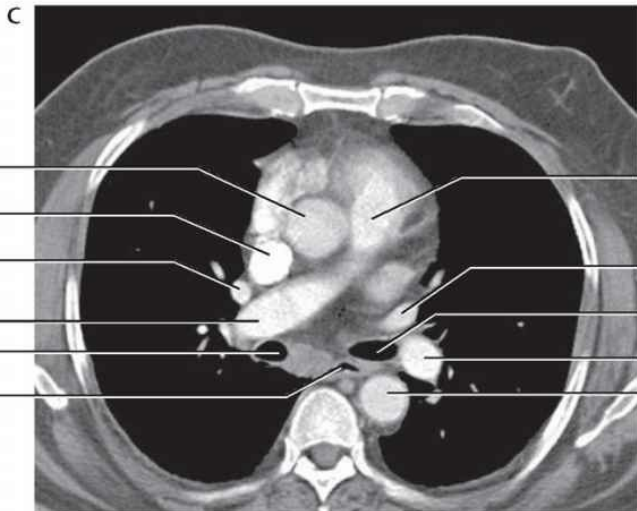
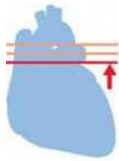
# Pulmonary vessels: imaging



- Ascending aorta
- Superior vena cava
- Right main bronchus
- Esophagus
- Pulmonary trunk
- Left pulmonary artery
- Left main bronchus
- Thoracic aorta



- Ascending aorta
- Superior vena cava
- Right superior pulmonary vein
- Right pulmonary artery
- Right main bronchus
- Esophagus
- Pulmonary trunk
- Left pulmonary artery
- Left superior pulmonary vein
- Left main bronchus
- Thoracic aorta

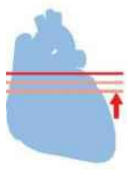


- Ascending aorta
- Superior vena cava
- Right superior pulmonary vein
- Right pulmonary artery
- Right main bronchus
- Esophagus
- Pulmonary trunk
- Left superior pulmonary vein
- Left main bronchus
- Left pulmonary artery
- Thoracic aorta

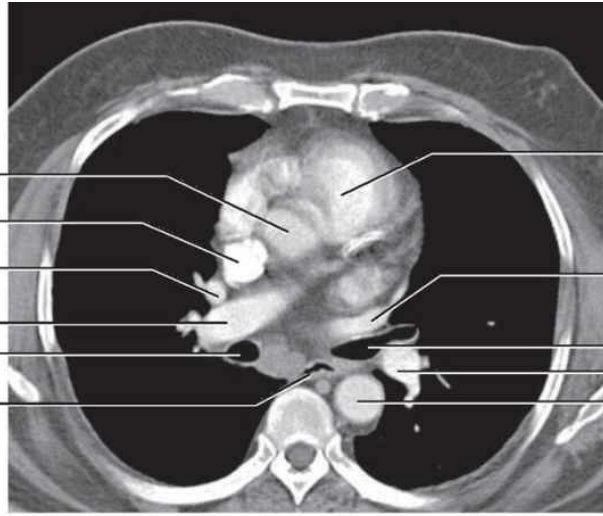
**A through C – Relationships of the pulmonary arteries, pulmonary veins, and bronchi in the mediastinum.**  
 CT images, with contrast, in axial plane



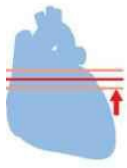




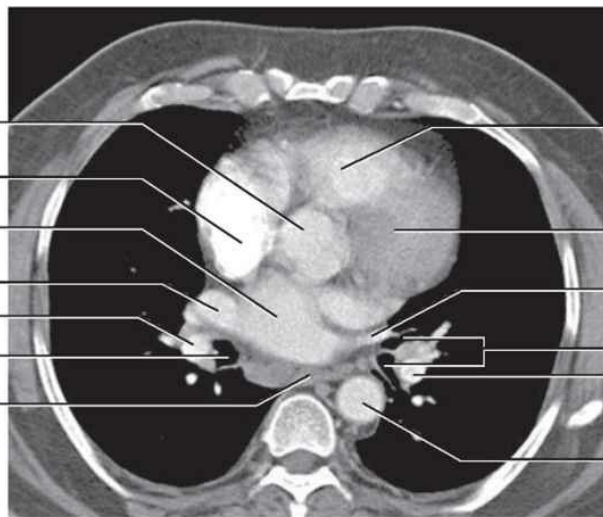D



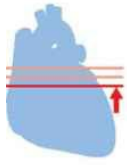
- Ascending aorta
- Superior vena cava
- Right superior pulmonary vein
- Right pulmonary artery
- Right main bronchus
- Esophagus
- Right ventricle
- Left superior pulmonary vein
- Left main bronchus
- Left pulmonary artery
- Thoracic aorta



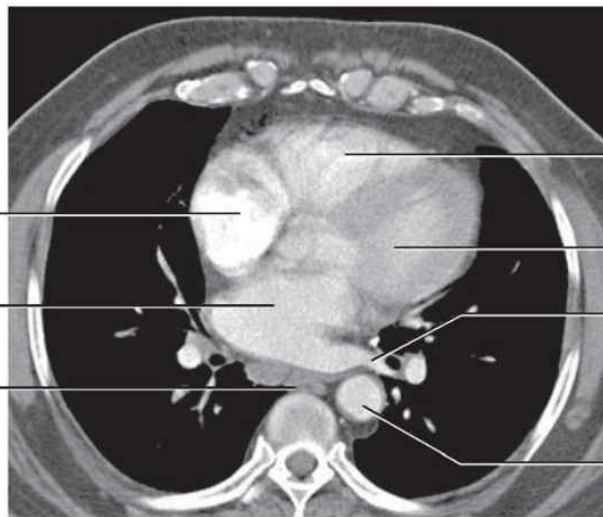
E



- Ascending aorta
- Right atrium
- Left atrium
- Right superior pulmonary vein
- Right pulmonary artery
- Right main bronchus
- Esophagus
- Right ventricle
- Left ventricle
- Left superior pulmonary vein
- Bronchi
- Left pulmonary artery
- Thoracic aorta



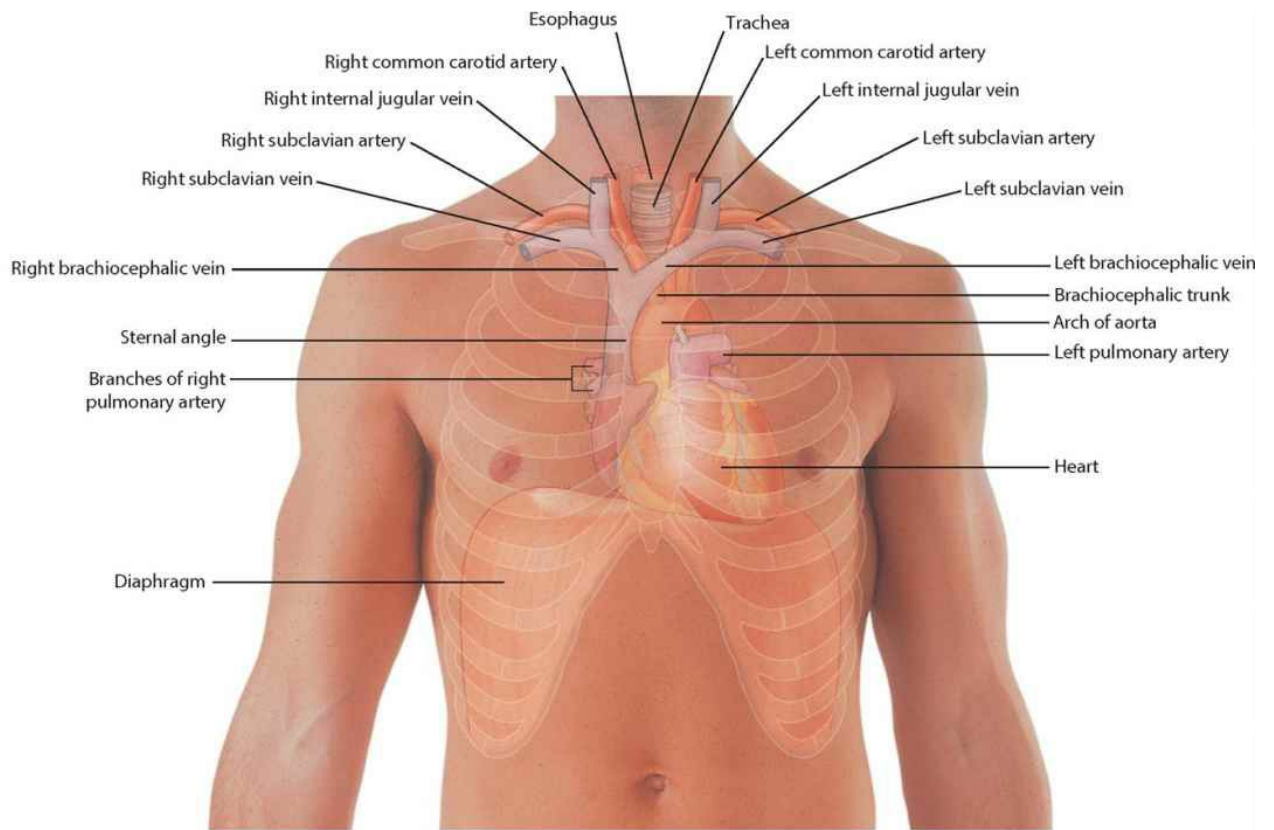
F



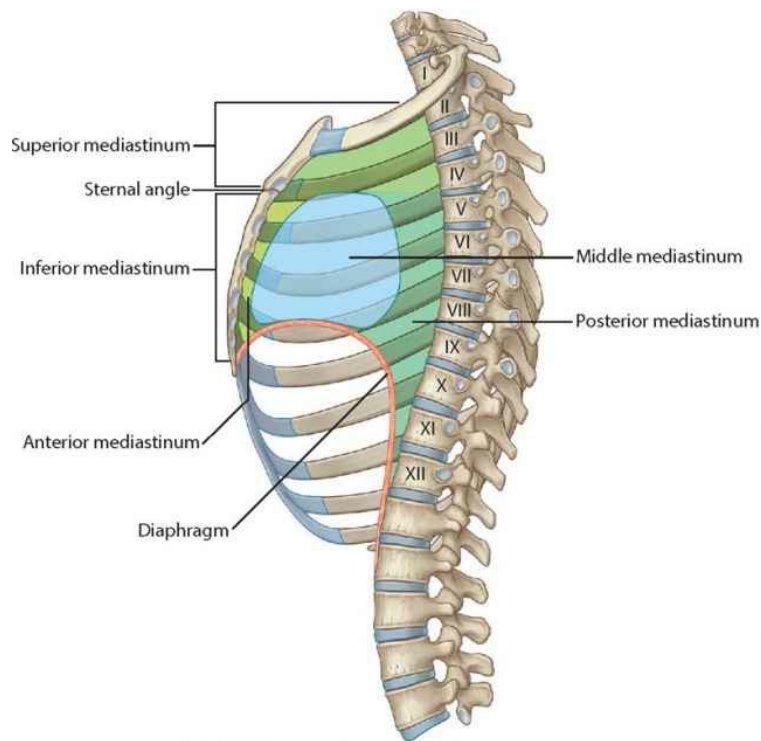
- Right atrium
- Left atrium
- Esophagus
- Right ventricle
- Left ventricle
- Left inferior pulmonary vein
- Thoracic aorta

D through F – Relationships of the pulmonary arteries, pulmonary veins, and bronchi in the mediastinum.  
CT images, with contrast, in axial plane

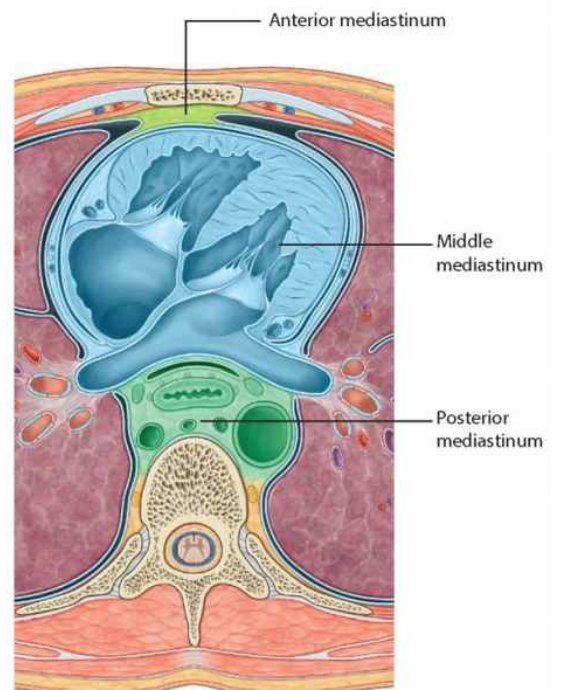
# Mediastinum



**Structures of the mediastinum as they relate to the surface**

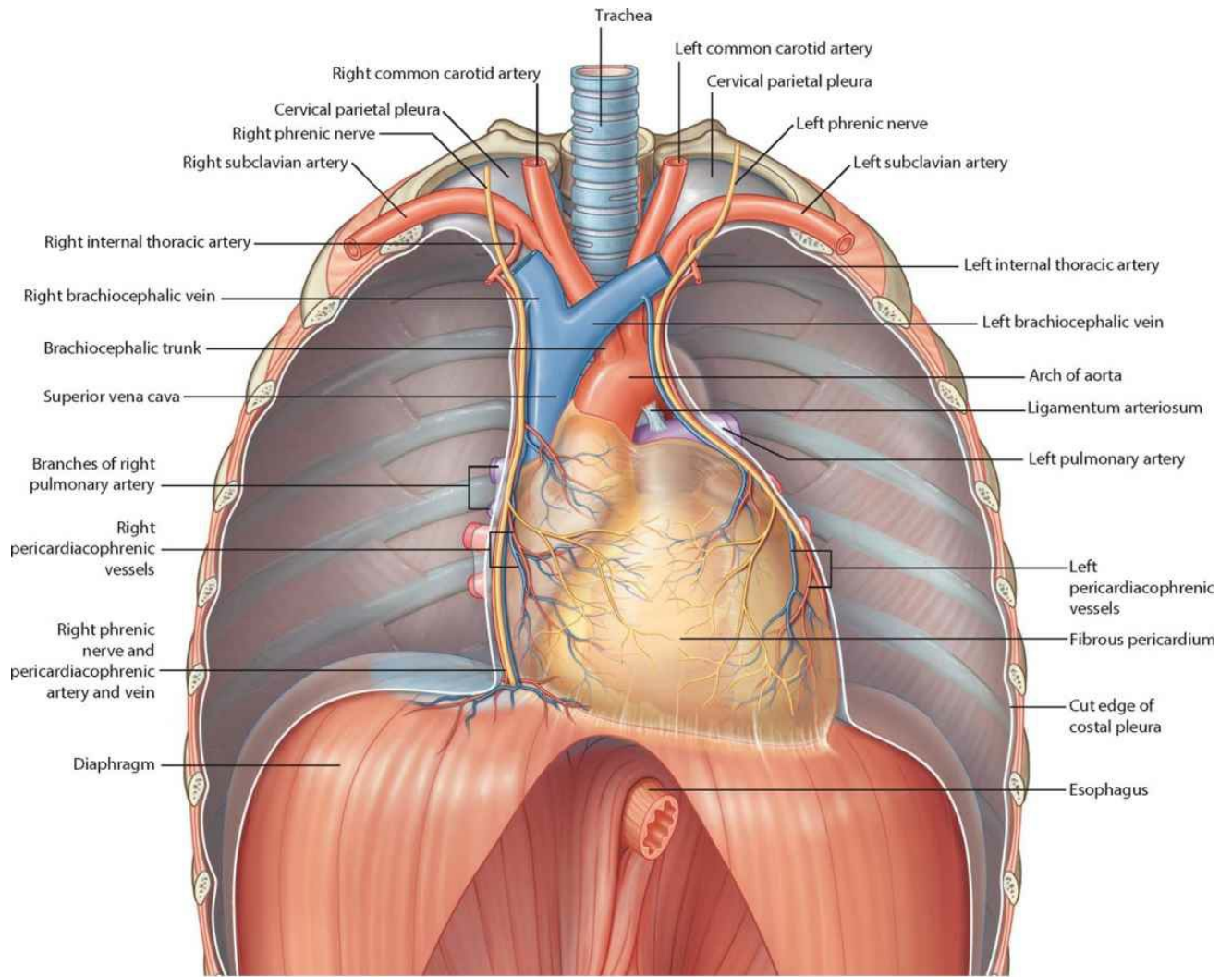


**Subdivisions of the mediastinum (sagittal section)**

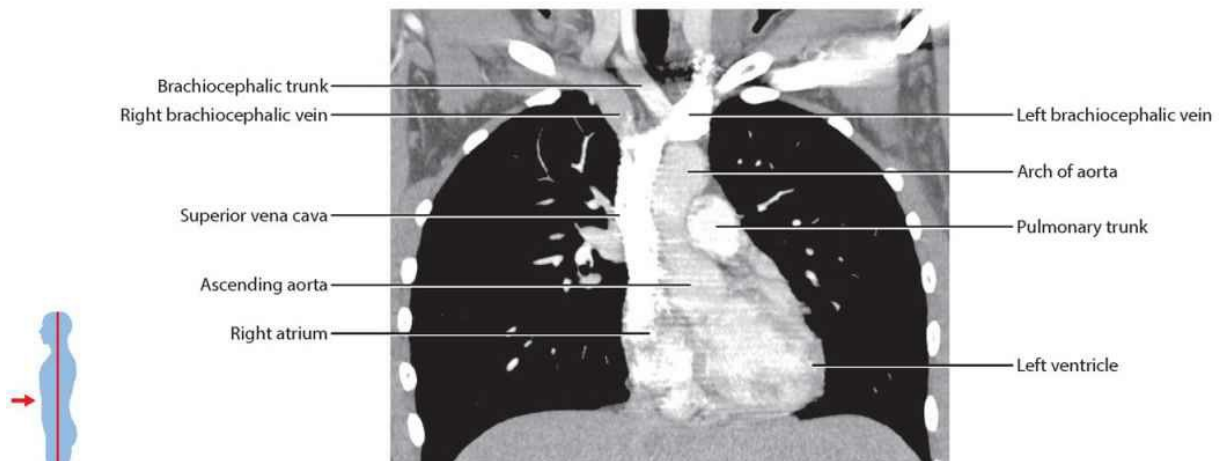


**Subdivisions of the mediastinum (transverse section)**

# Pericardium

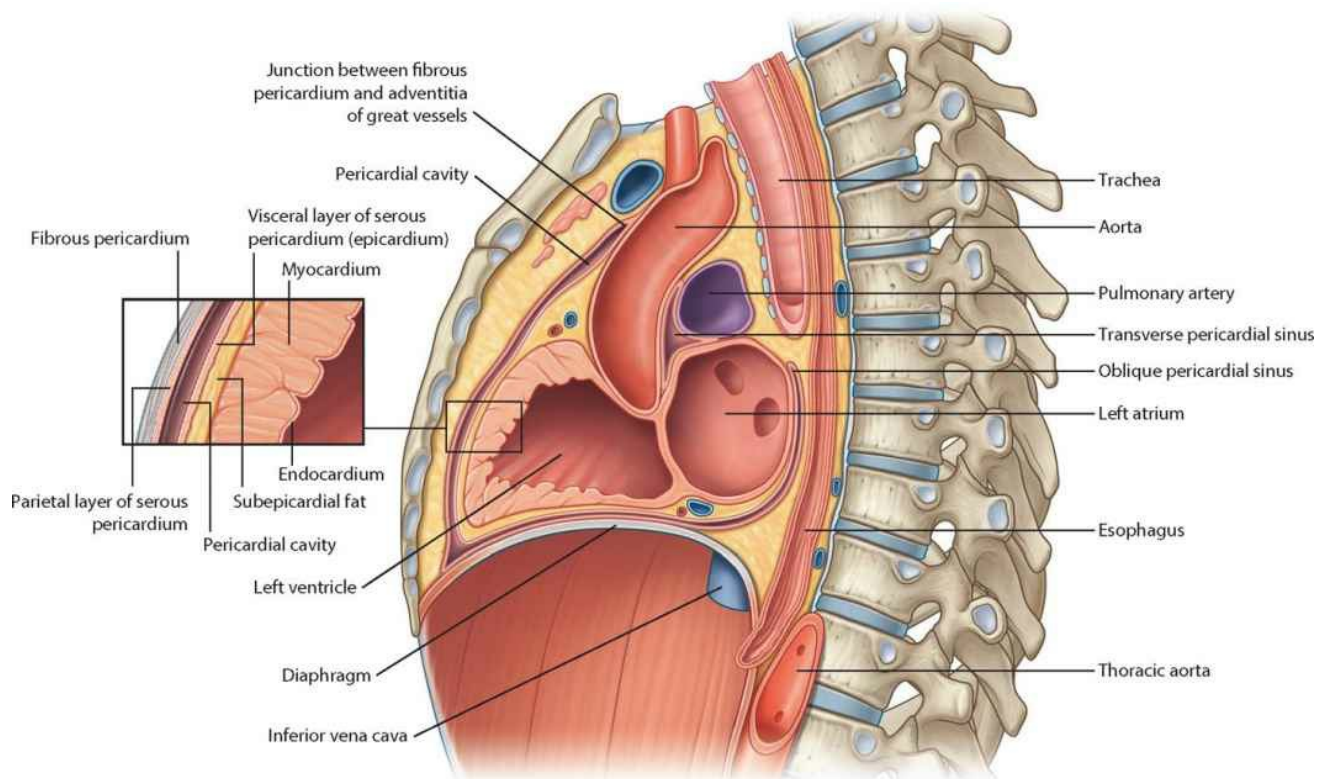


**Pericardium with nerves and vessels**

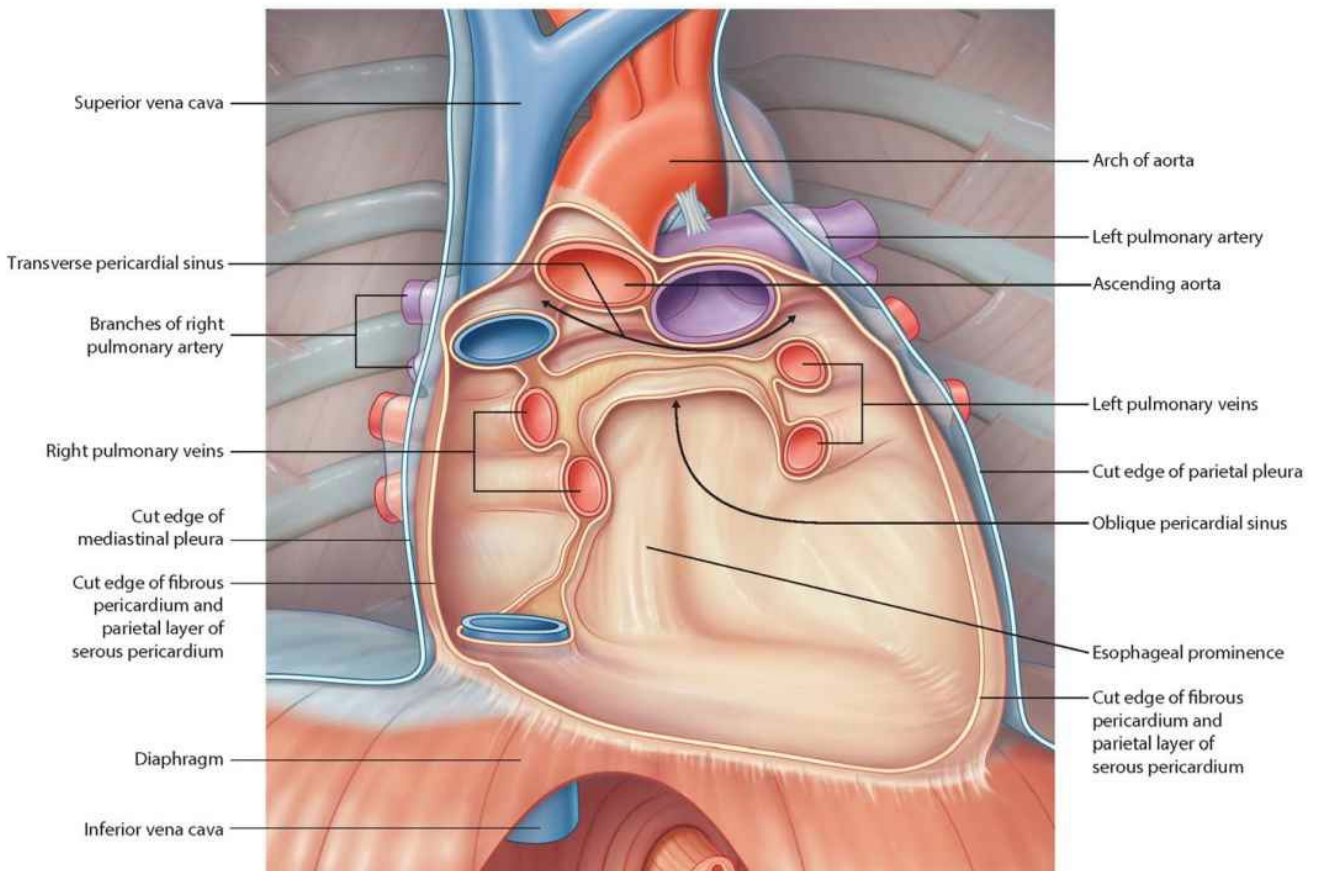


**Mediastinal structures and lungs.**  
CT image, with contrast, in coronal plane

# Pericardial layers



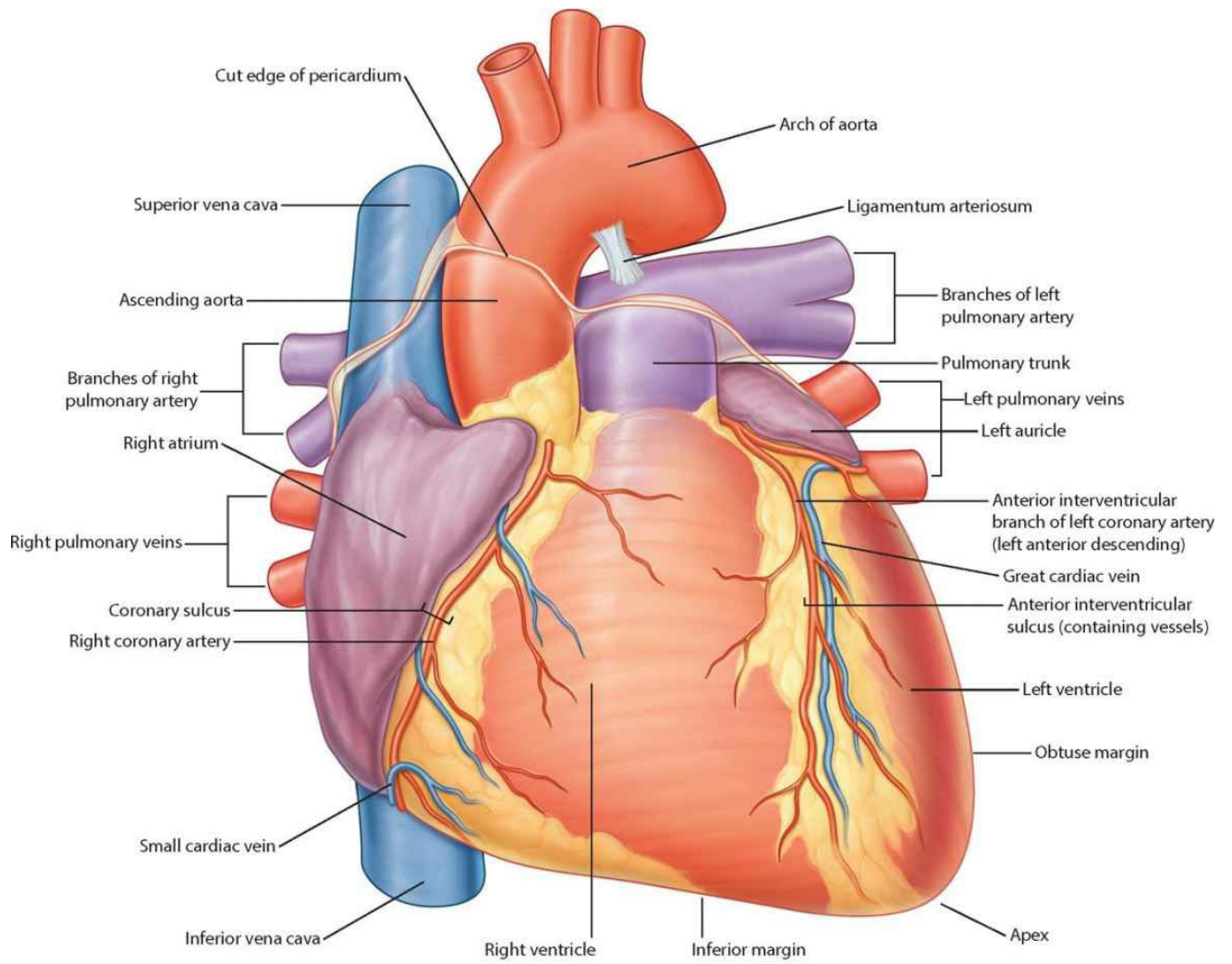
**Sagittal section of the pericardium and heart**



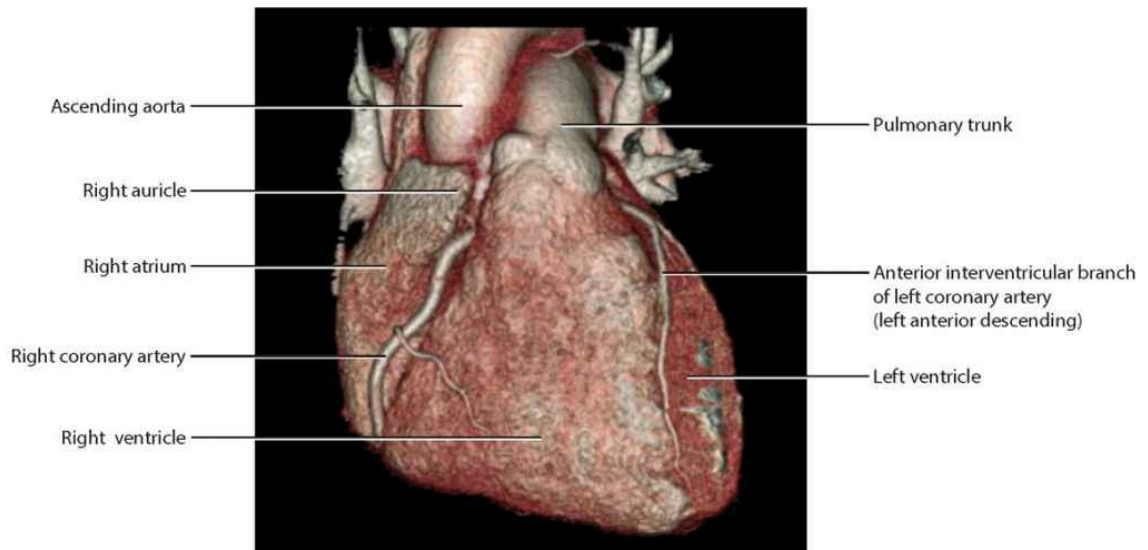
**Pericardial sac with heart removed**



## **Anterior surface of heart**



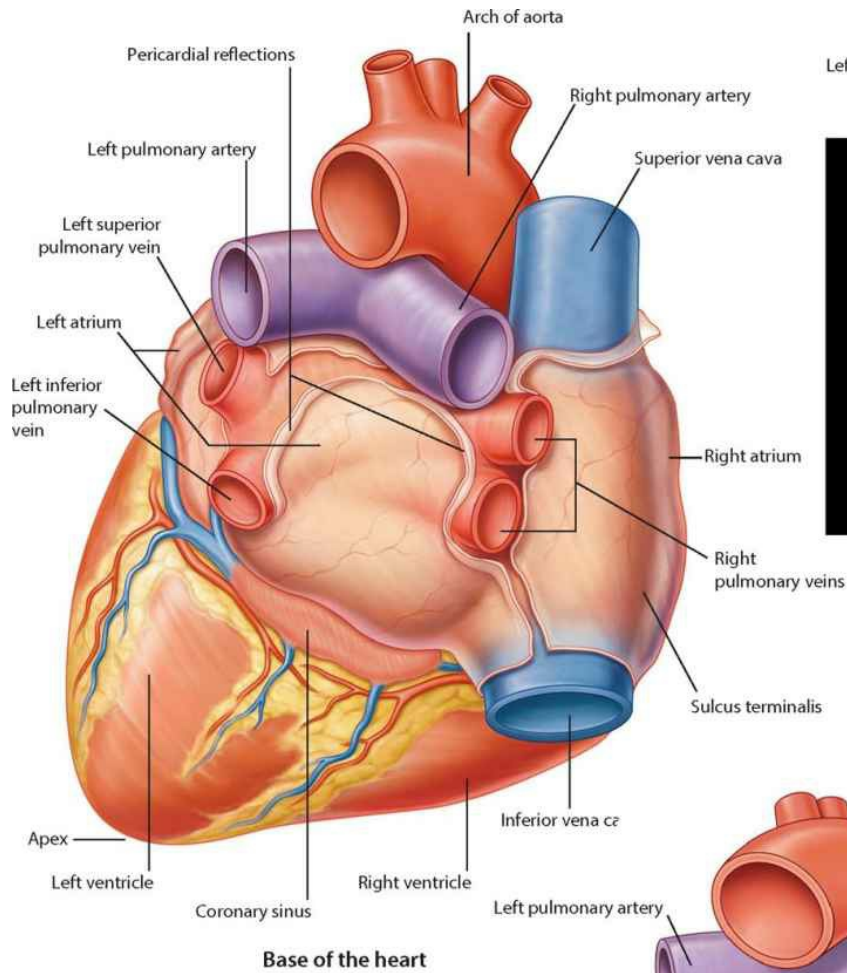
**Anterior surface of the heart**



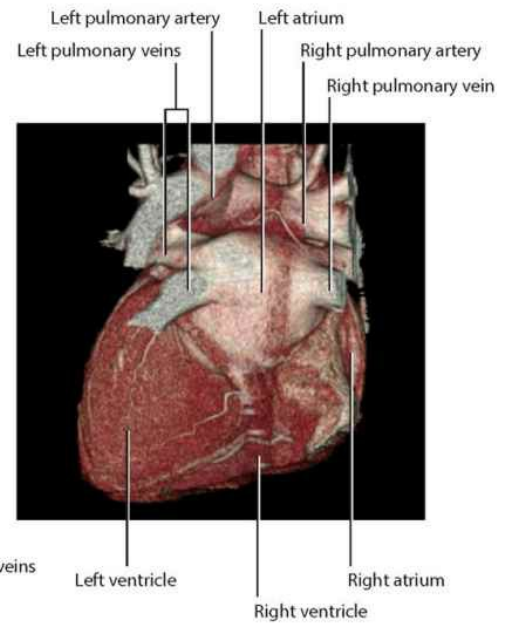
**Anterior view of the heart.**

Volume-rendered anterior view using multidetector computed tomography

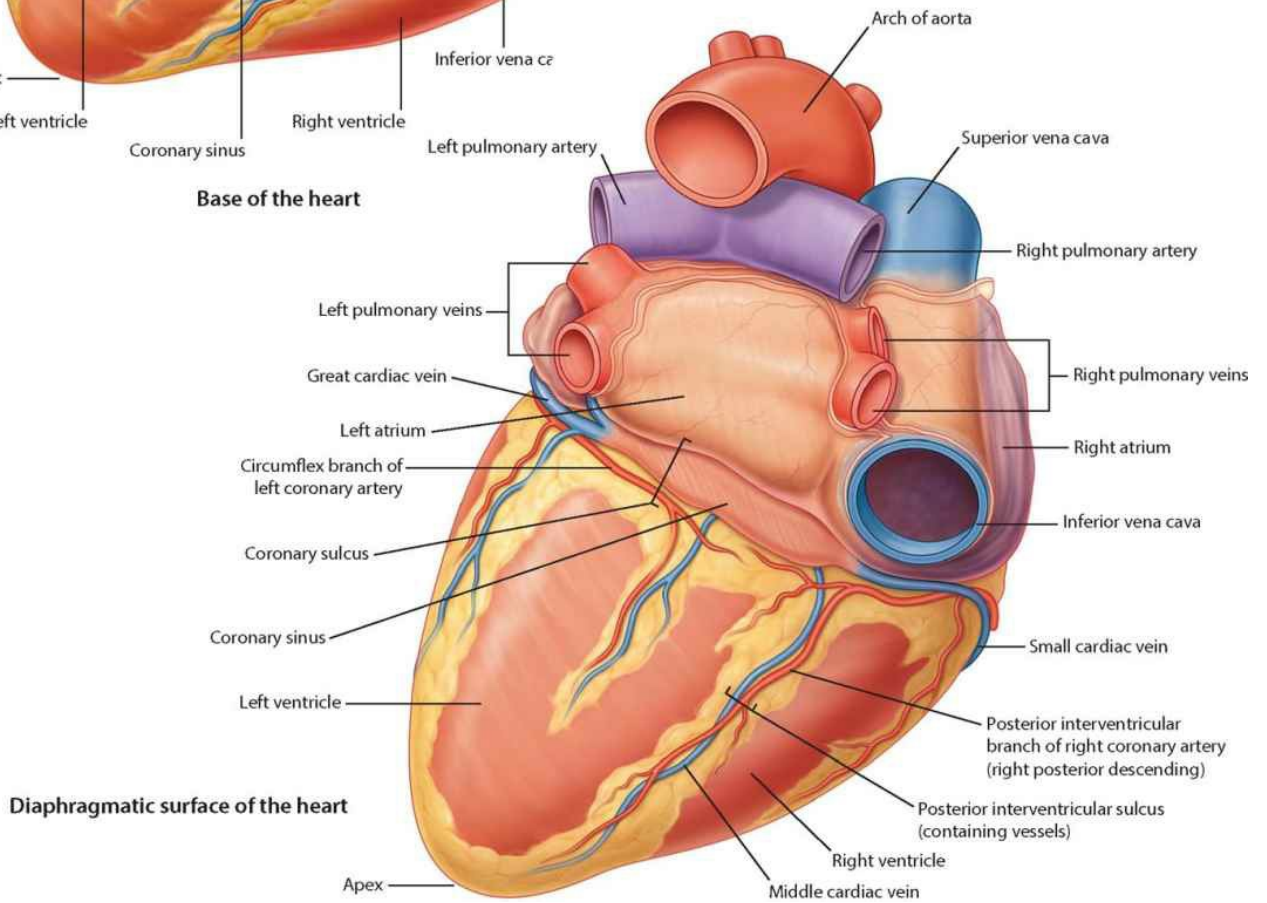
## **Base and diaphragmatic surface of heart**



**Base of the heart**

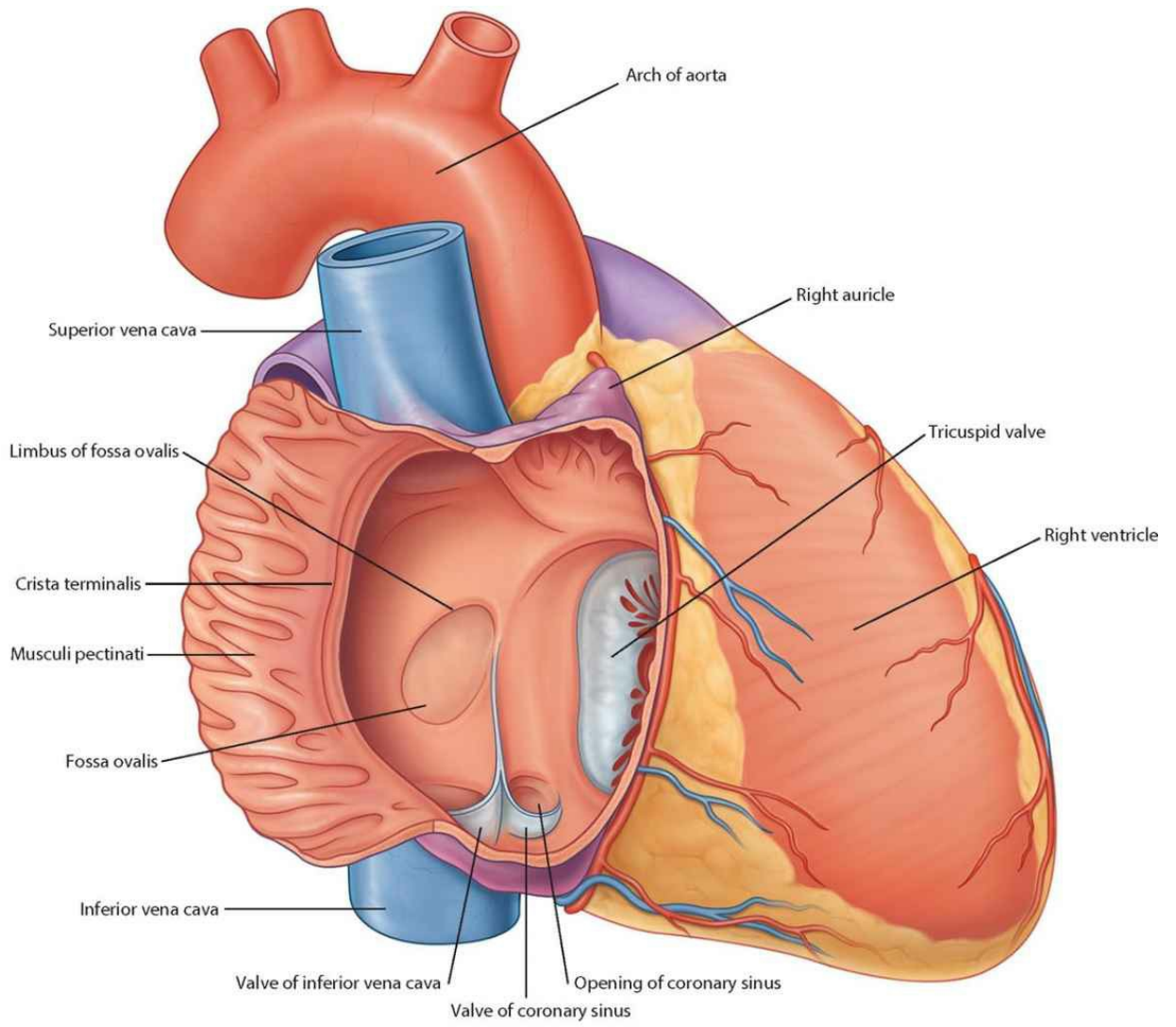


**Posterior view of the heart.**  
 Volume-rendered posterior view using multidetector computed tomography

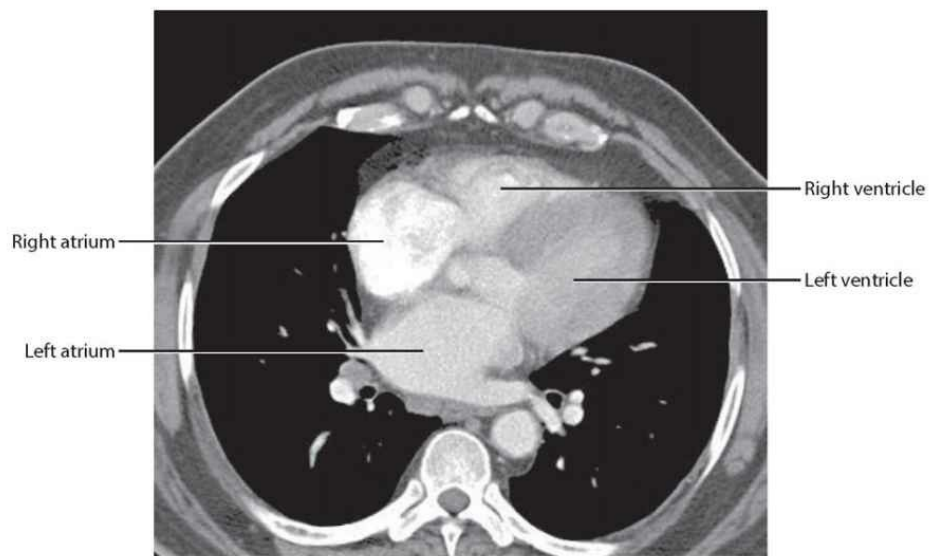


**Diaphragmatic surface of the heart**

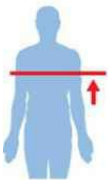
# Right atrium



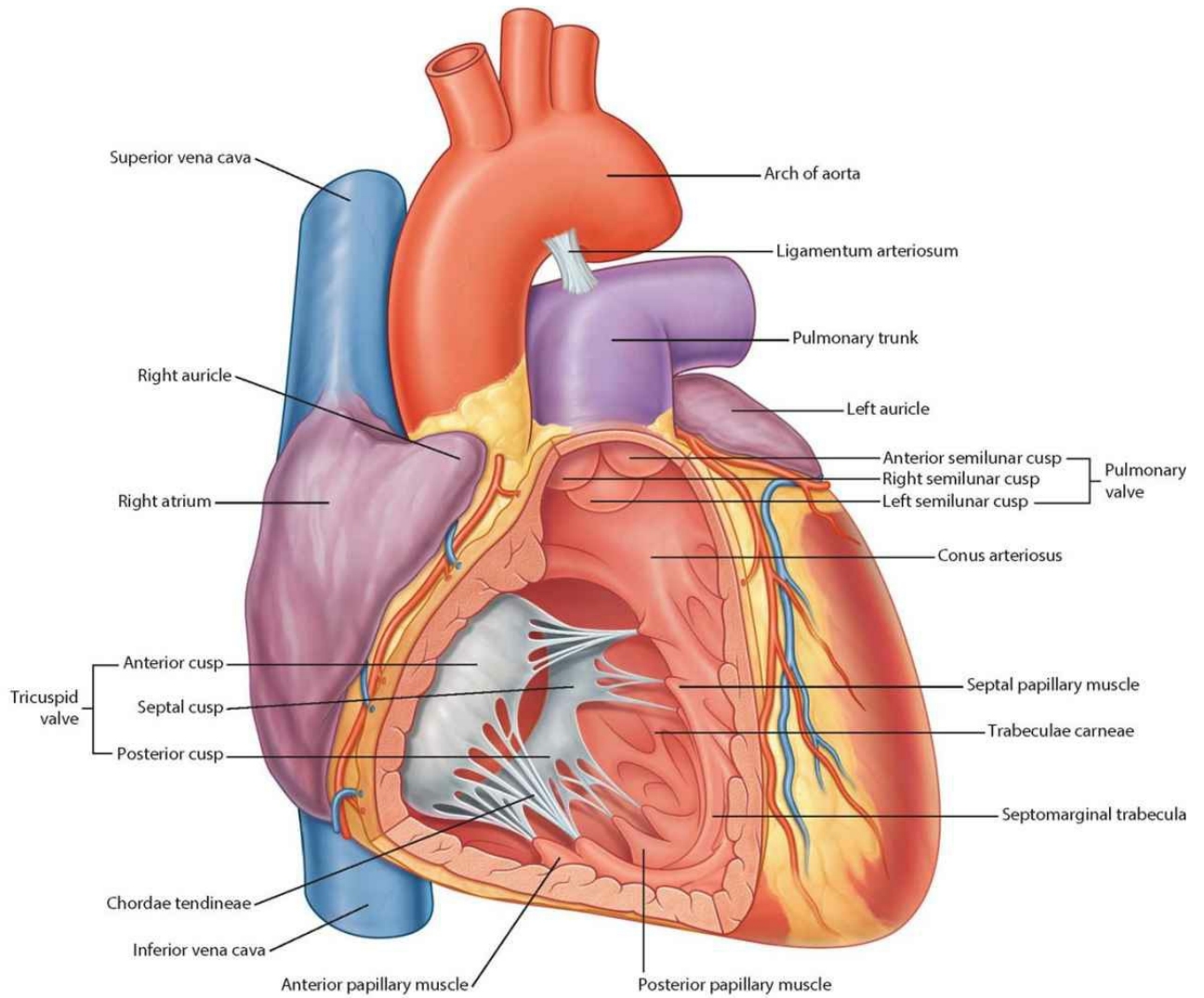
**Internal view of right atrium**



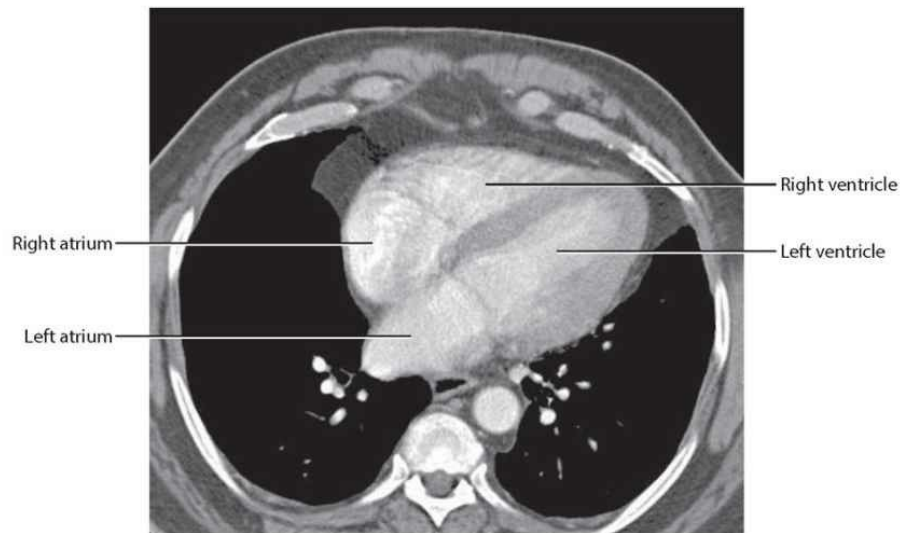
**Positioning of right atrium in relation to other cardiac chambers.**  
CT image, with contrast, in axial plane



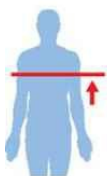
# Right ventricle



**Internal view of right ventricle**

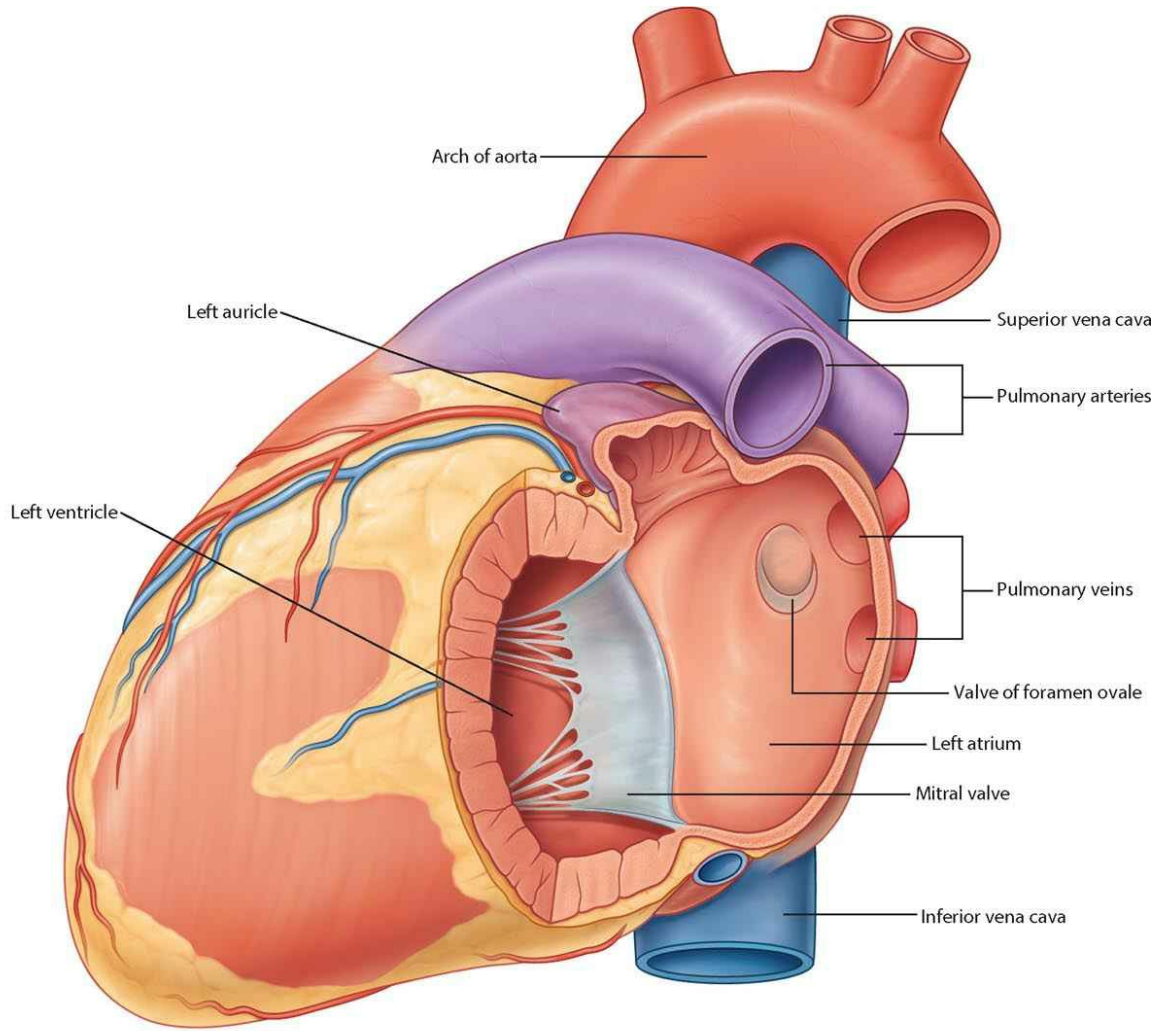


**Positioning of right ventricle in relation to other cardiac chambers.**  
CT image, with contrast, in axial plane

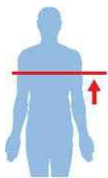
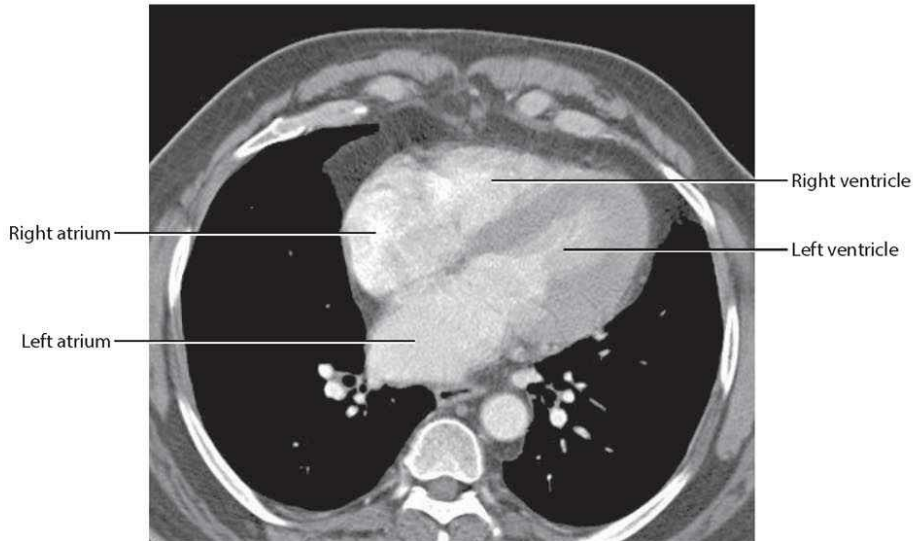




## Left atrium

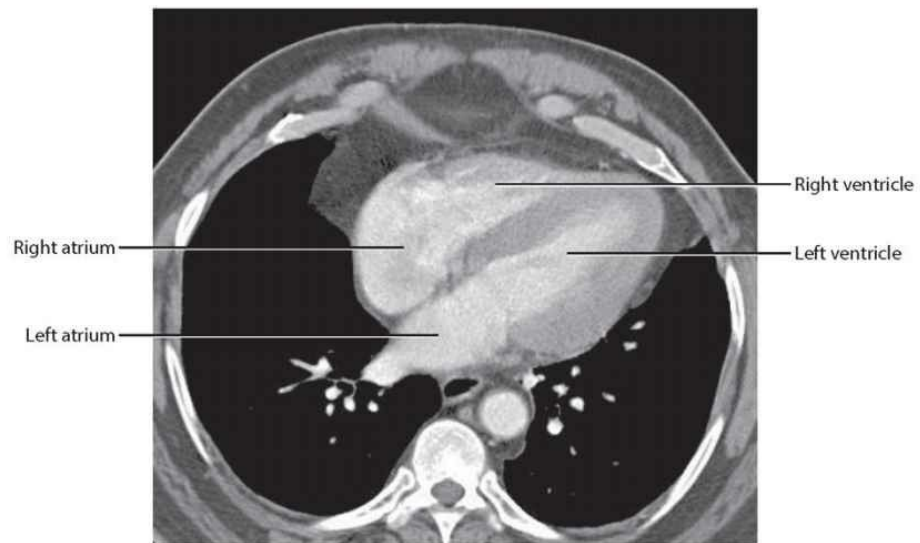
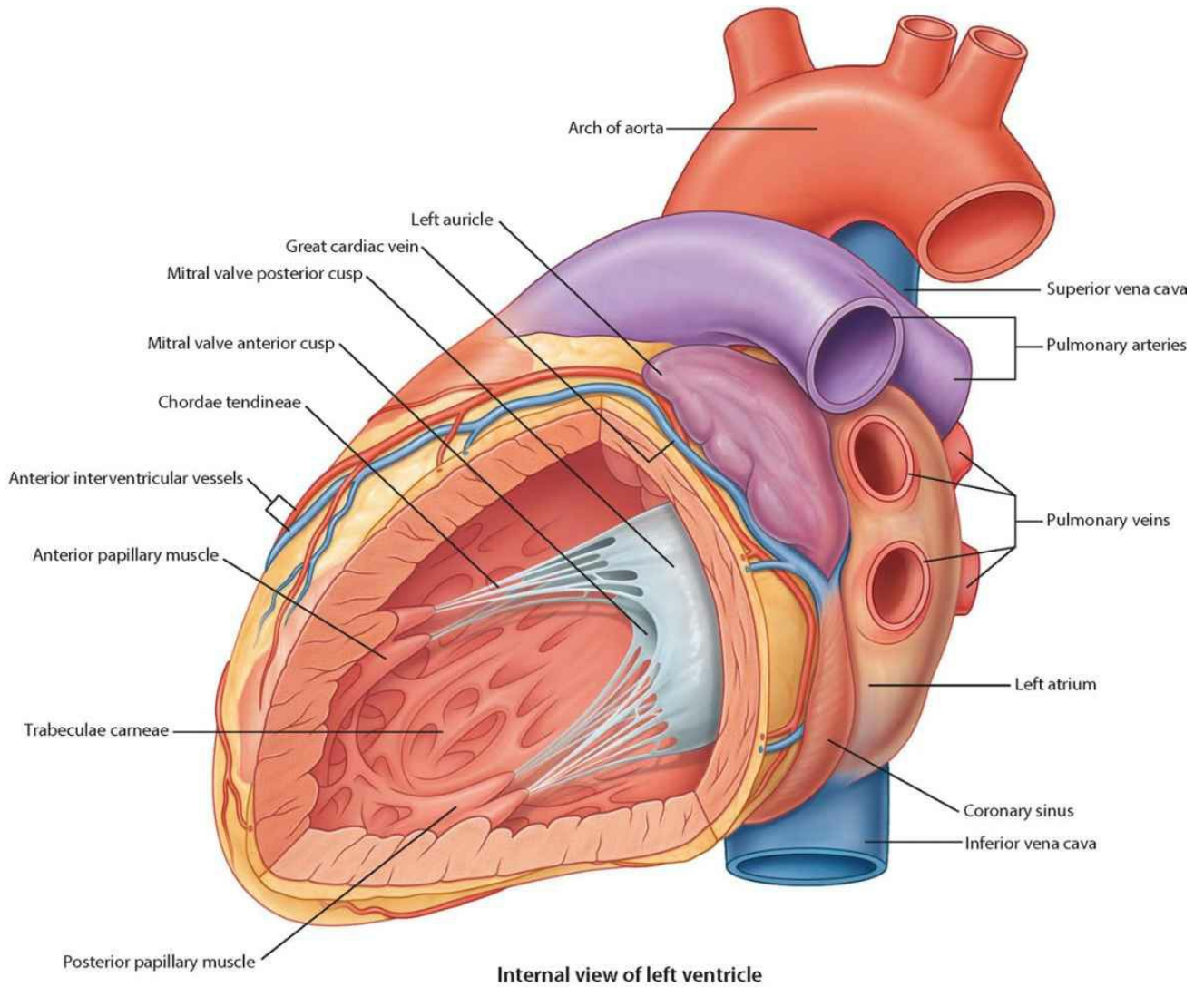


**Internal view of left atrium**

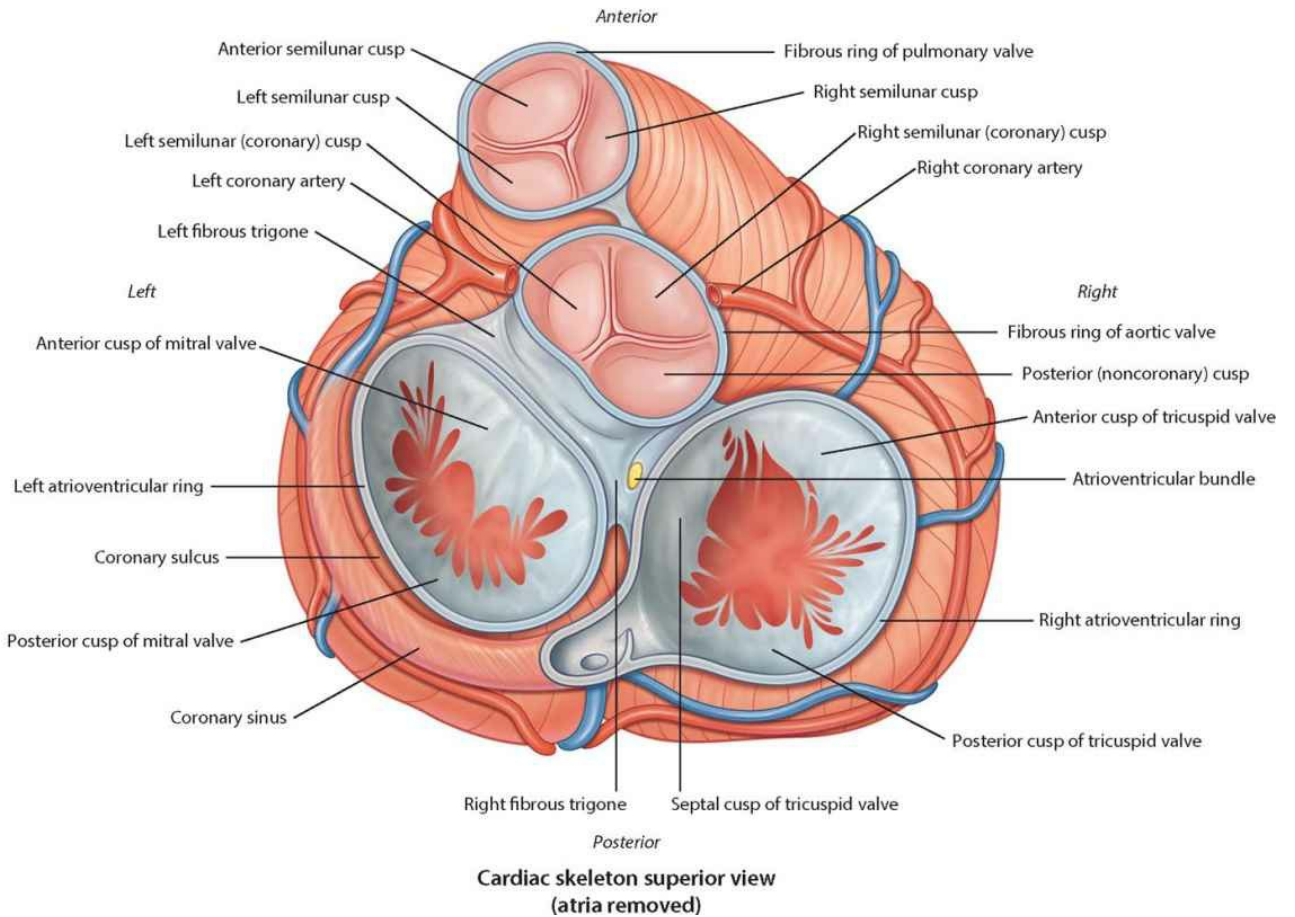
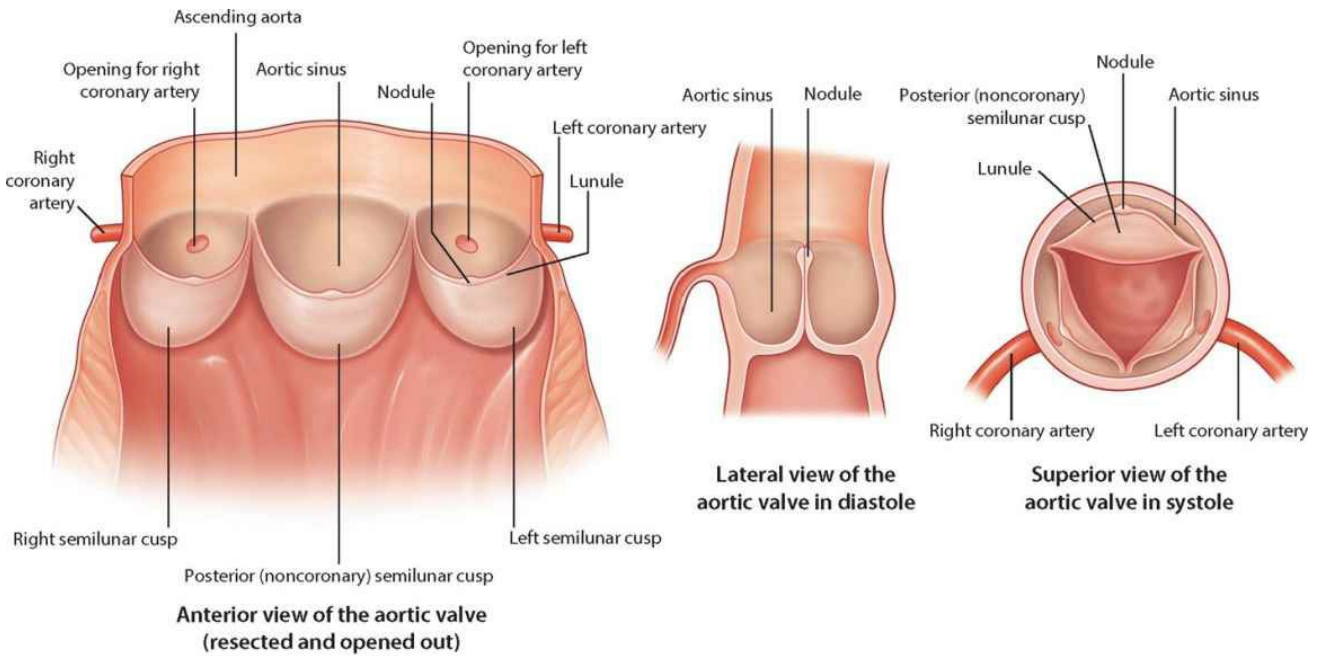


**Positioning of left atrium in relation to other cardiac chambers.**  
CT image, with contrast, in axial plane

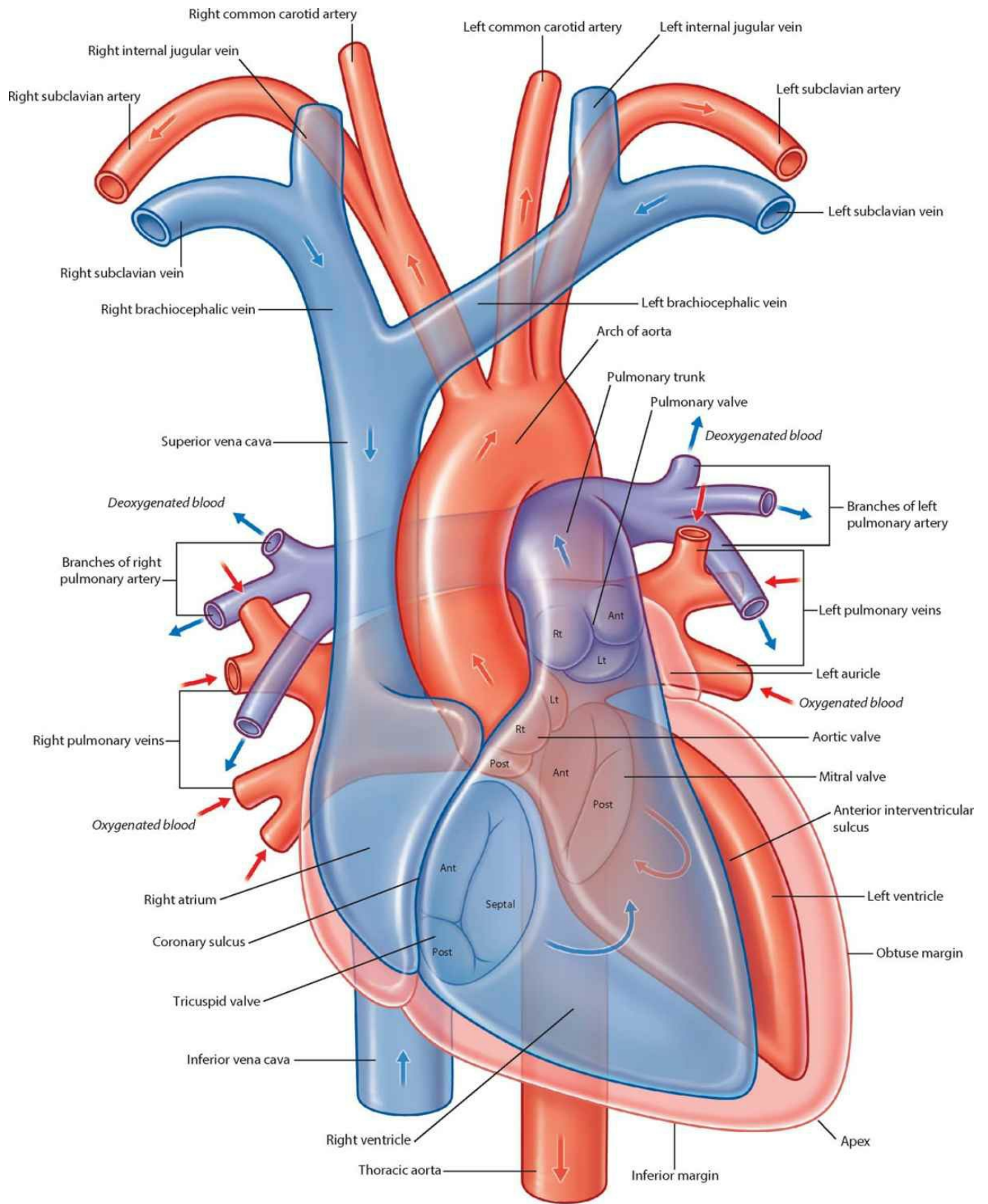
# Left ventricle



# **Aortic valve and cardiac skeleton**



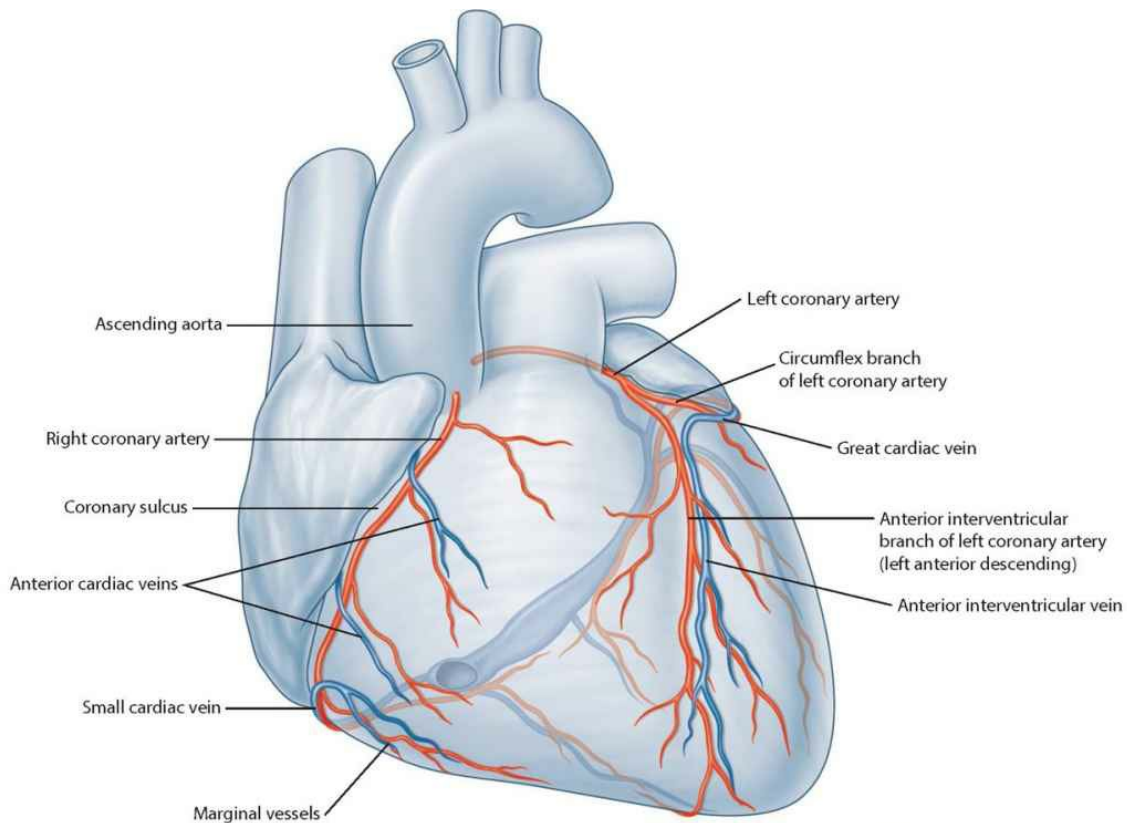
# Cardiac chambers and heart valves



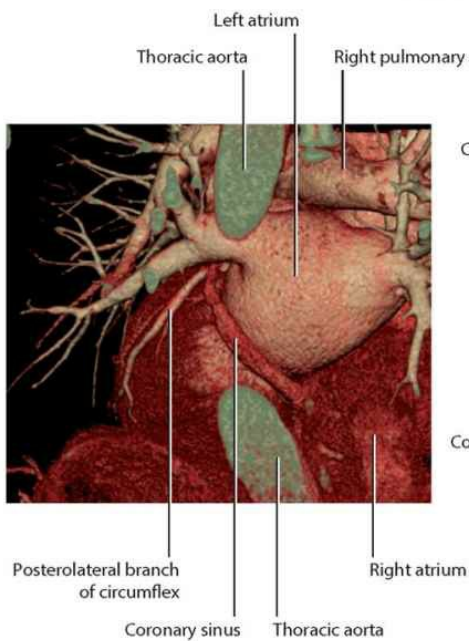
Cardiac chambers and direction of blood flow



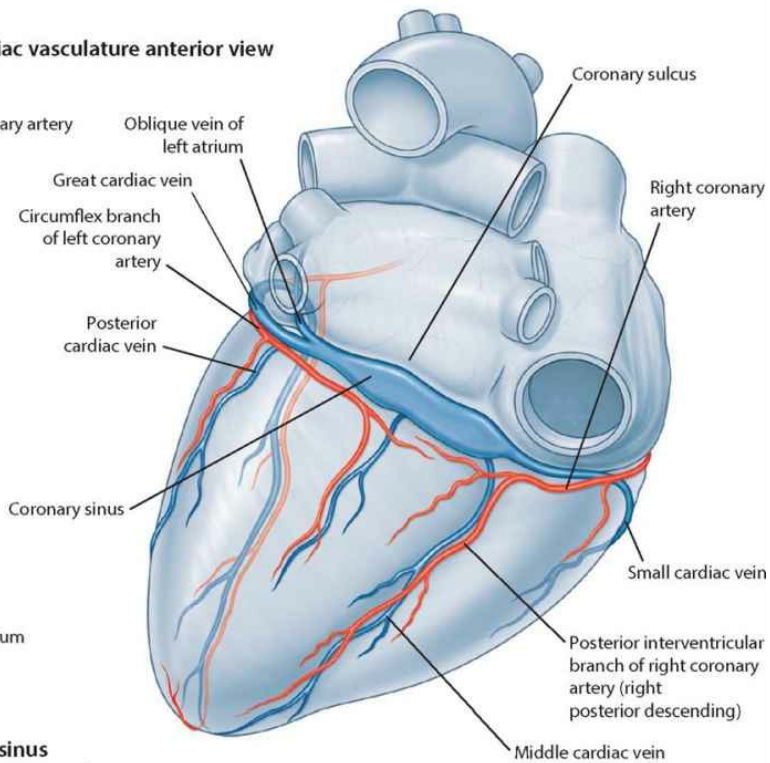
# Coronary vessels



**Cardiac vasculature anterior view**

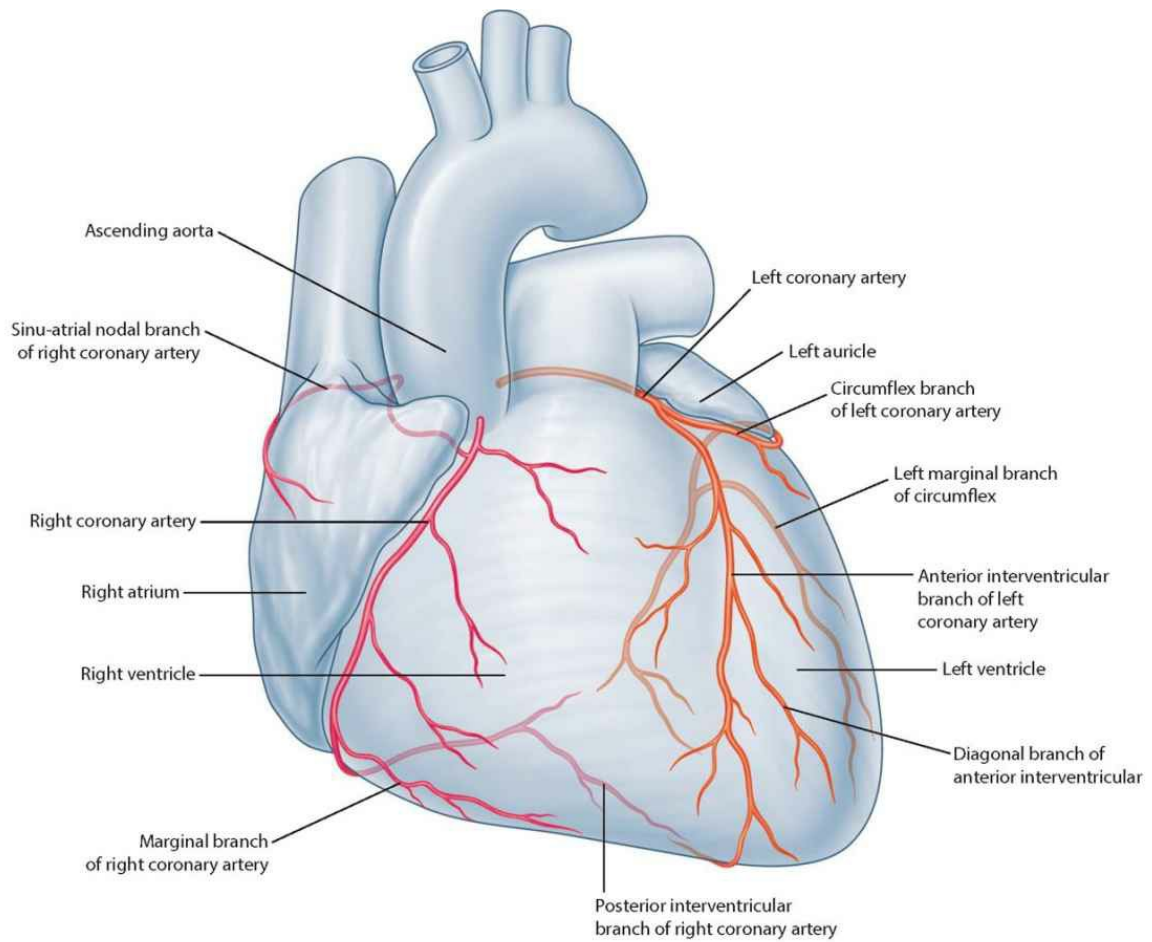


**Posterior view of the heart showing the coronary sinus**  
 Volume-rendered posterior view using multidetector computed tomography

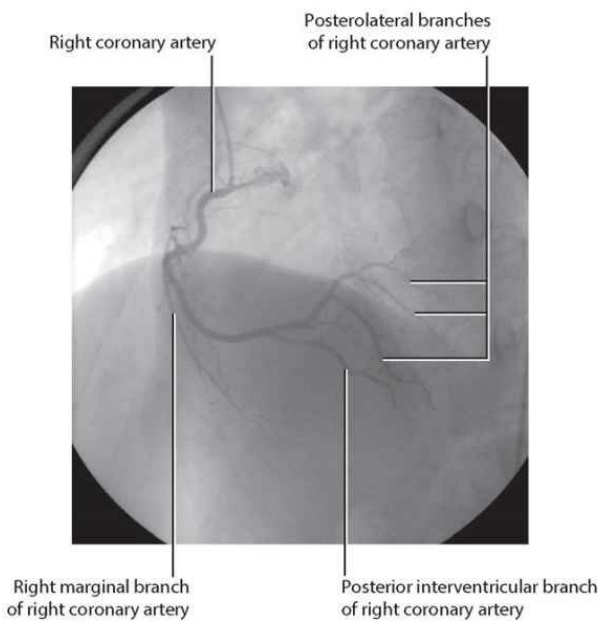


**Posteroinferior view**

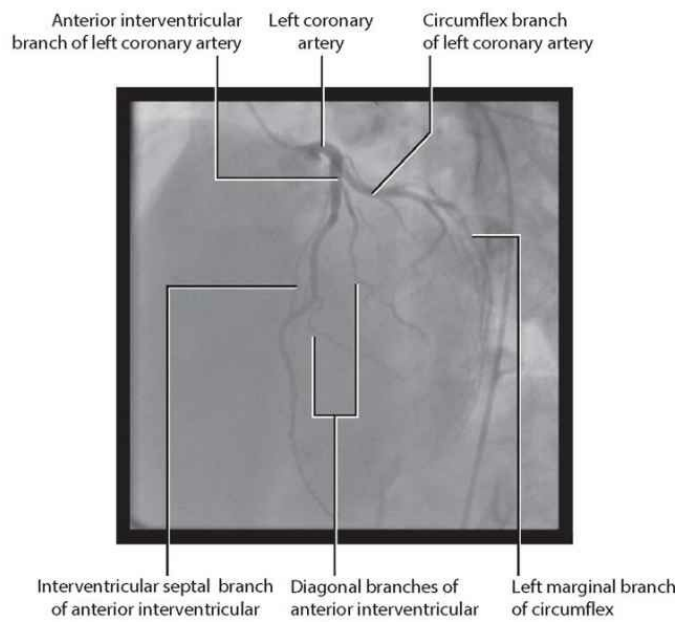
# Coronary arteries and variations



**Coronary arteries (right dominant system)**

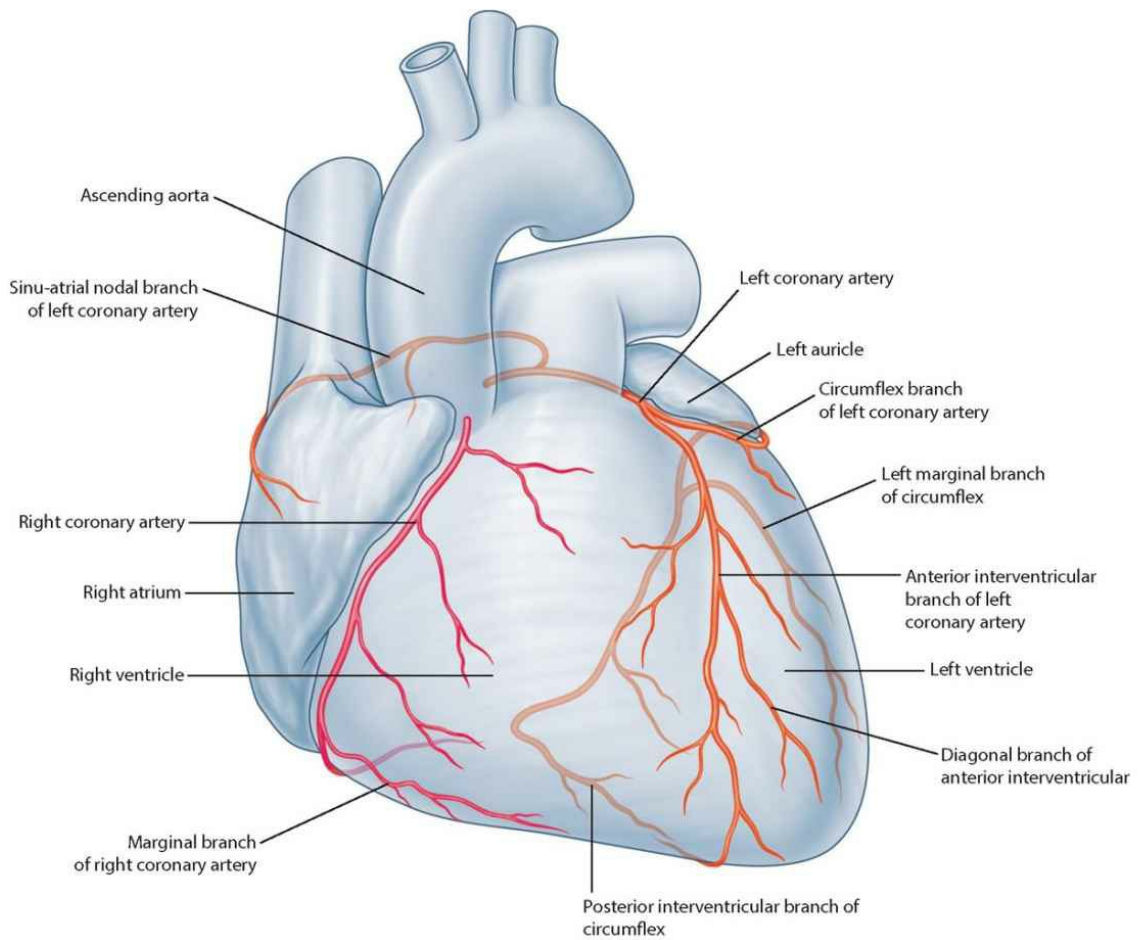


**Coronary angiography (right dominant system).**  
Left anterior oblique projection, cranial angulation, of right coronary artery

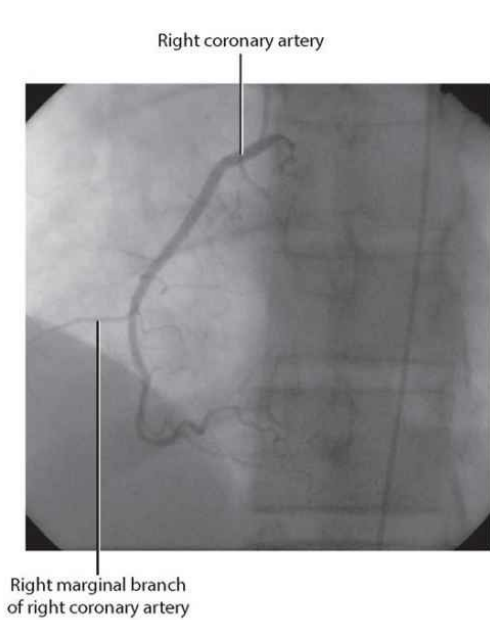


**Coronary angiography (right dominant system).**  
Left anterior oblique projection, cranial angulation, of left coronary artery

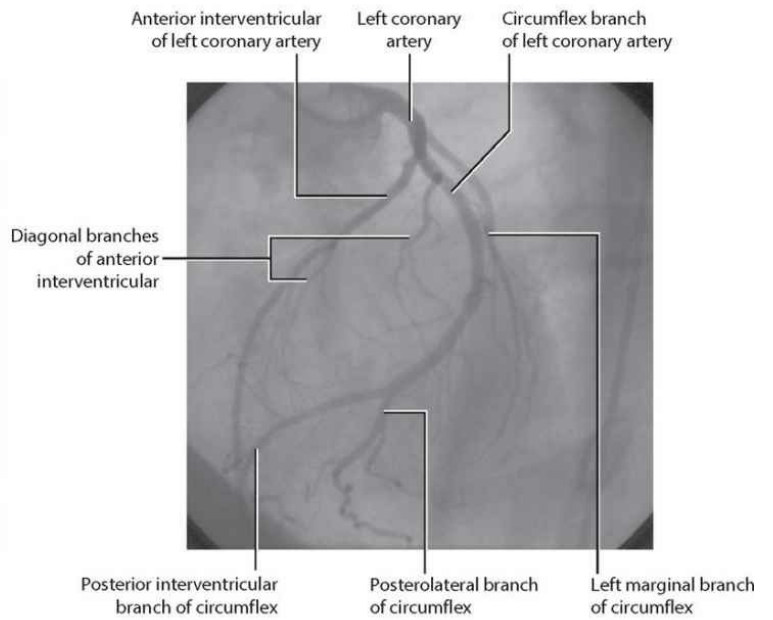




**Coronary arteries (left dominant system)**

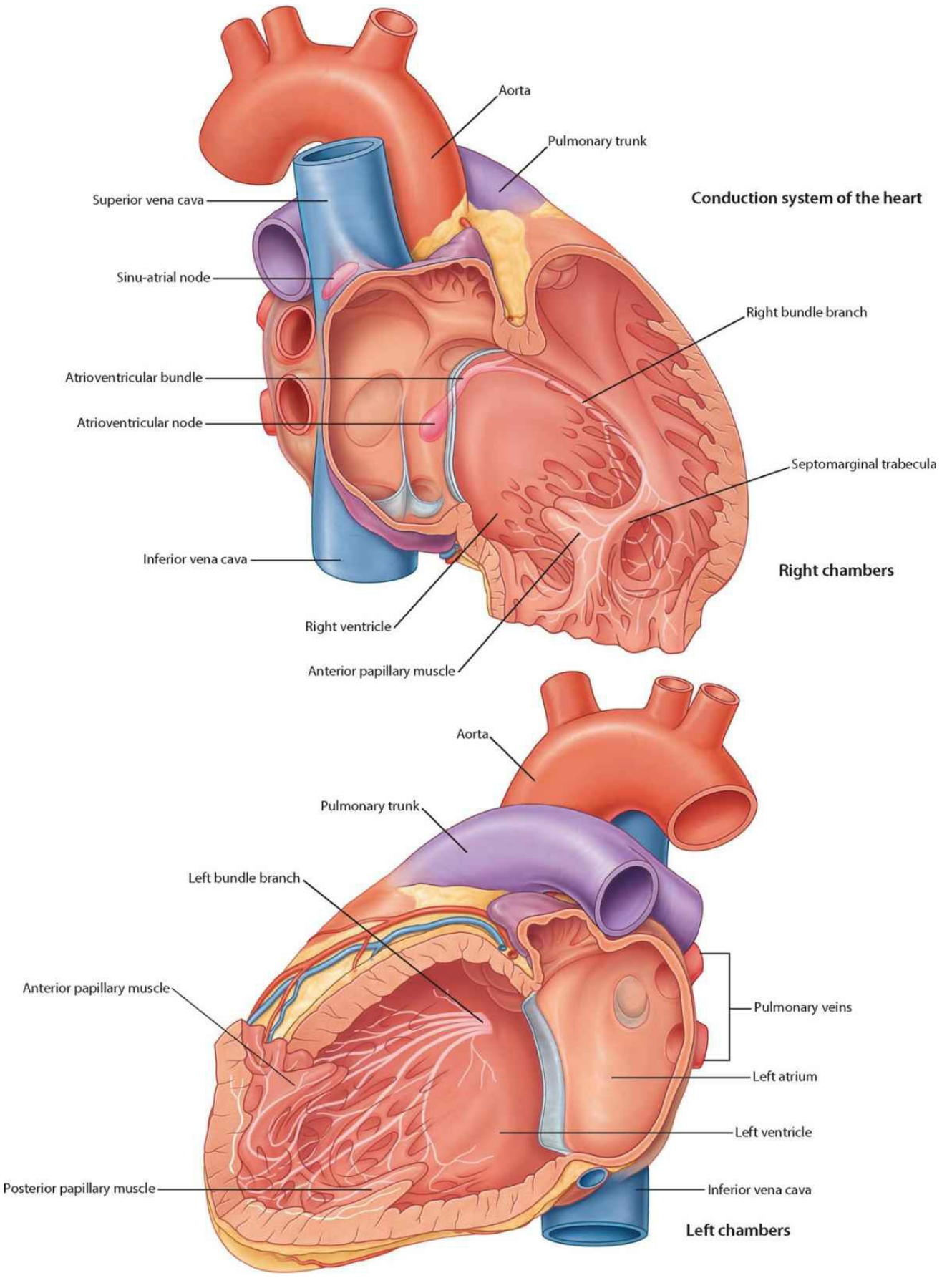


**Coronary angiography (left dominant system).**  
Left anterior oblique projection, cranial angulation, of right coronary artery



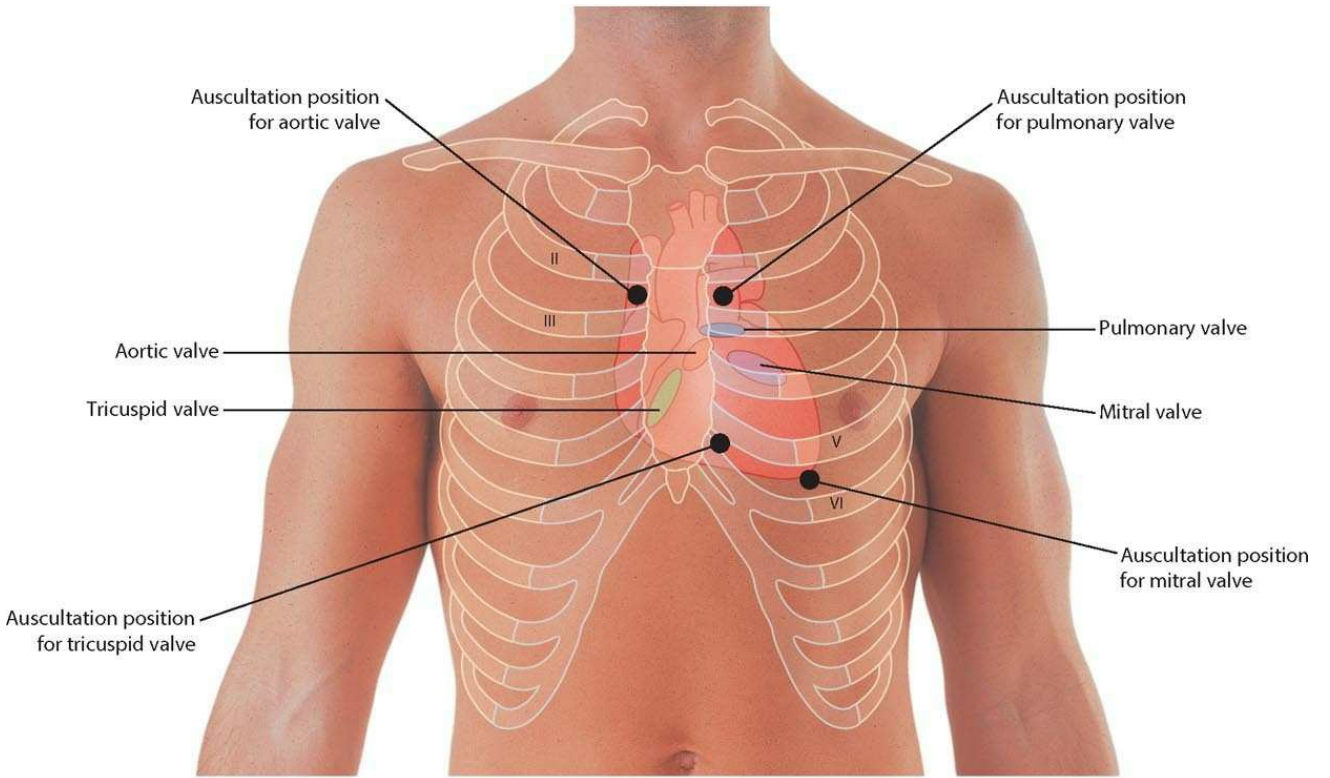
**Coronary angiography (left dominant system).**  
Left anterior oblique projection, cranial angulation, of left coronary artery

# Cardiac conduction system





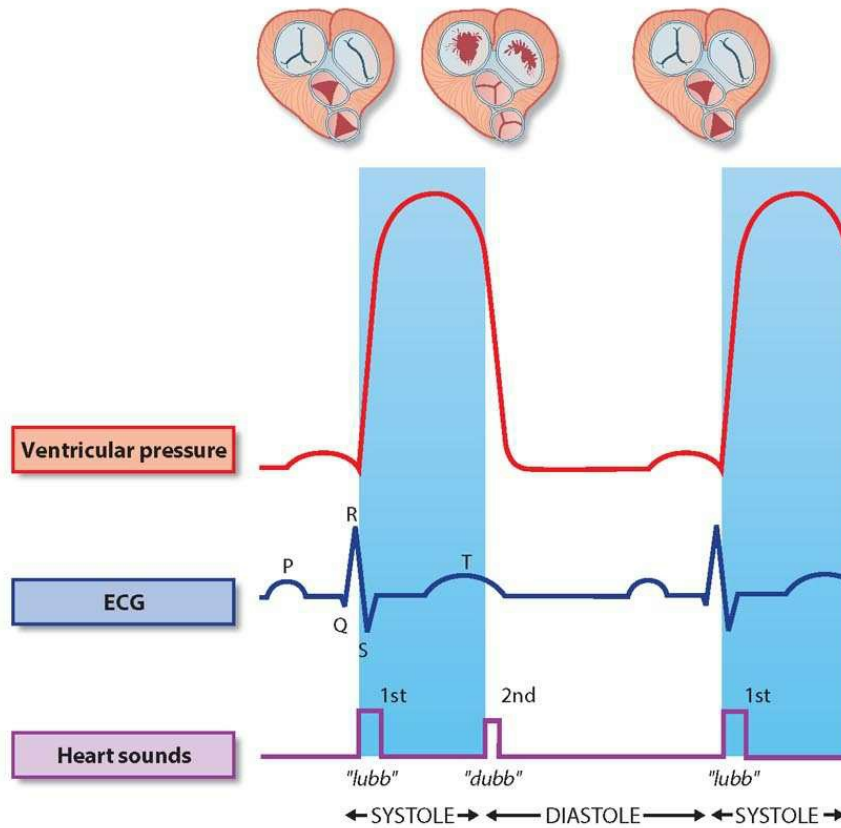
# Auscultation points and heart sounds



**Auscultation points**

Closure of mitral and tricuspid valves

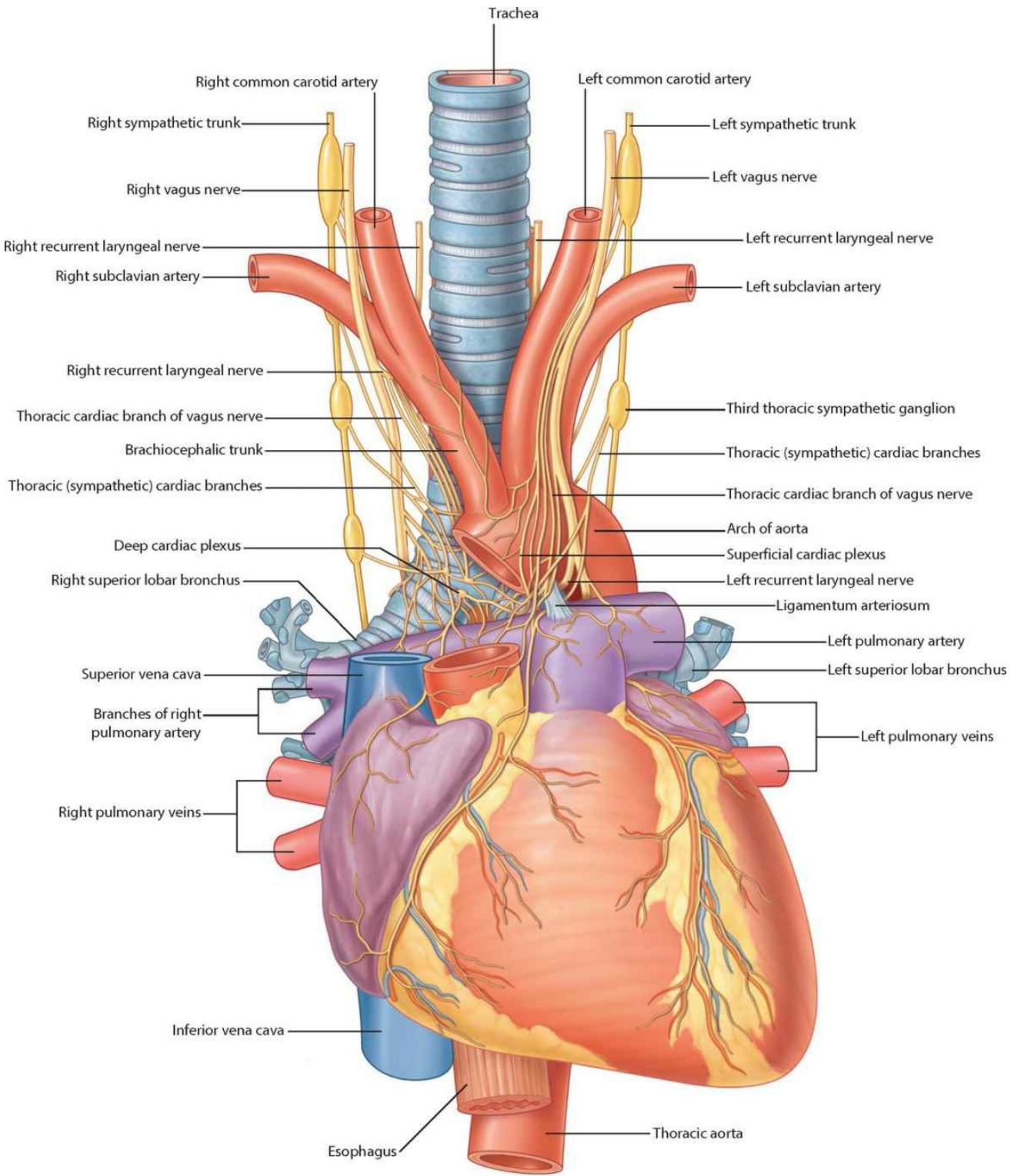
Closure of aortic and pulmonary valves



**Cardiac auscultation**

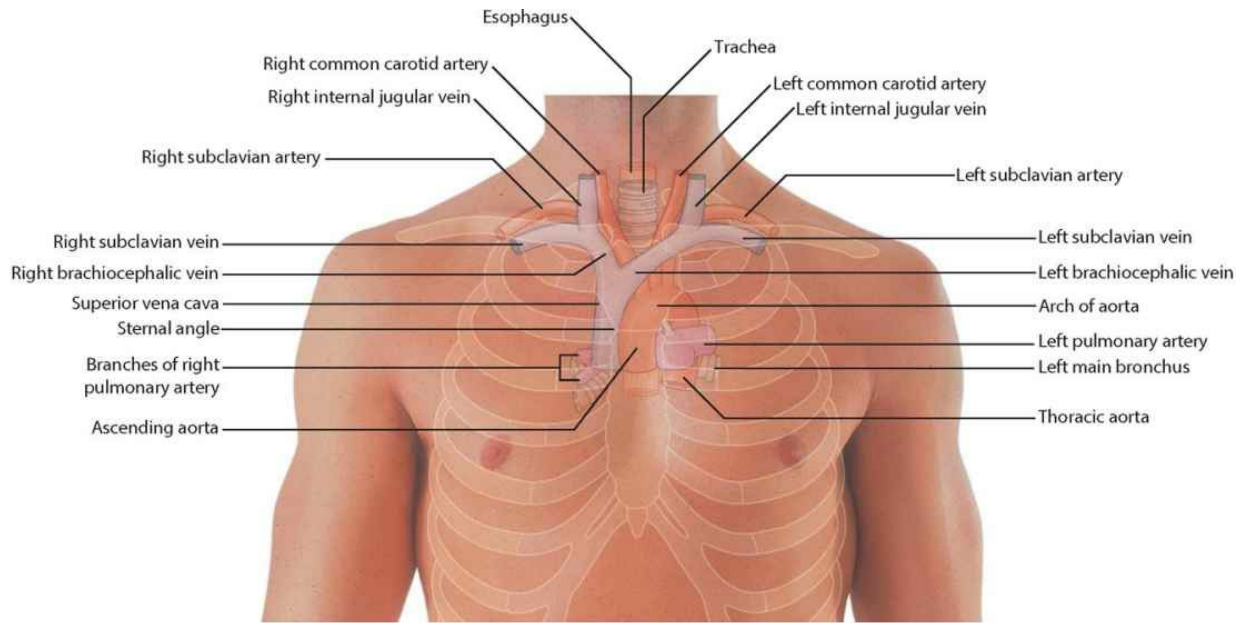


# Cardiac innervation

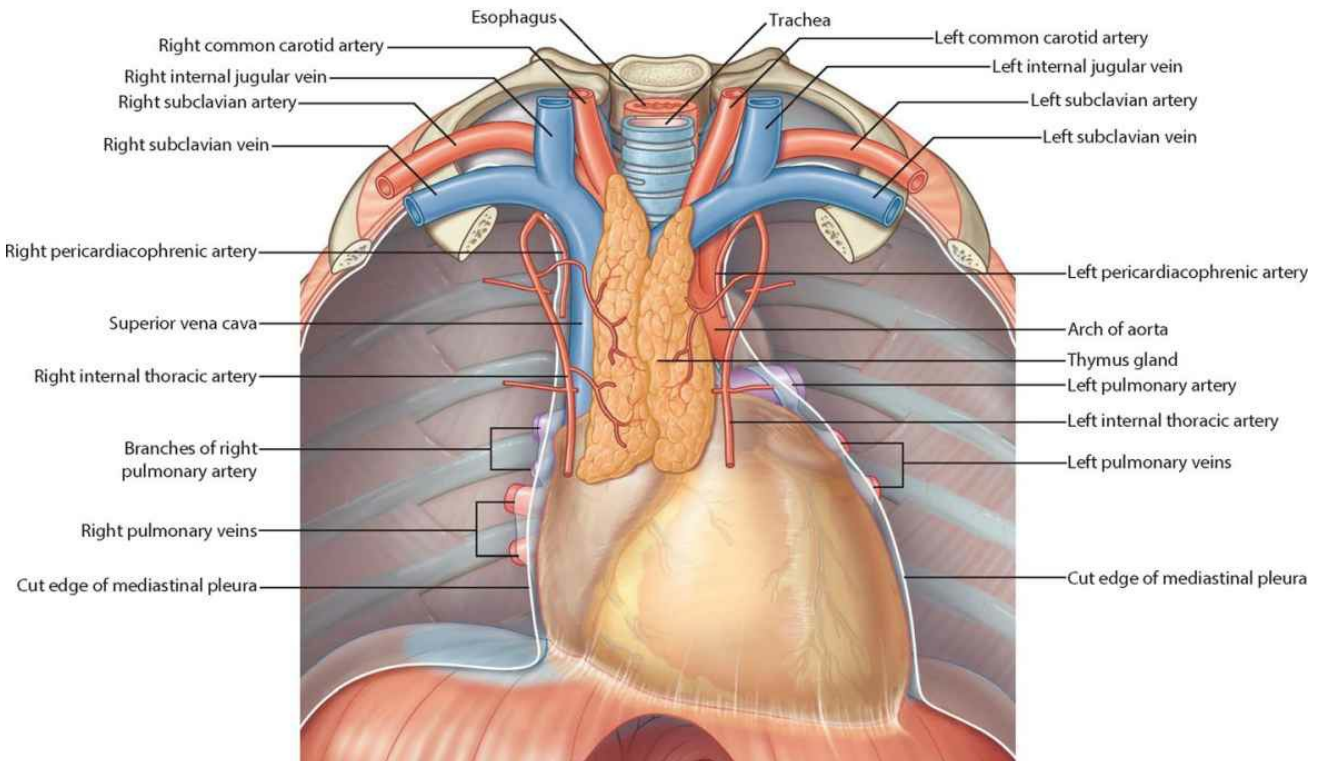


**Cardiac plexus and nerves of the heart**

## Superior mediastinum: thymus



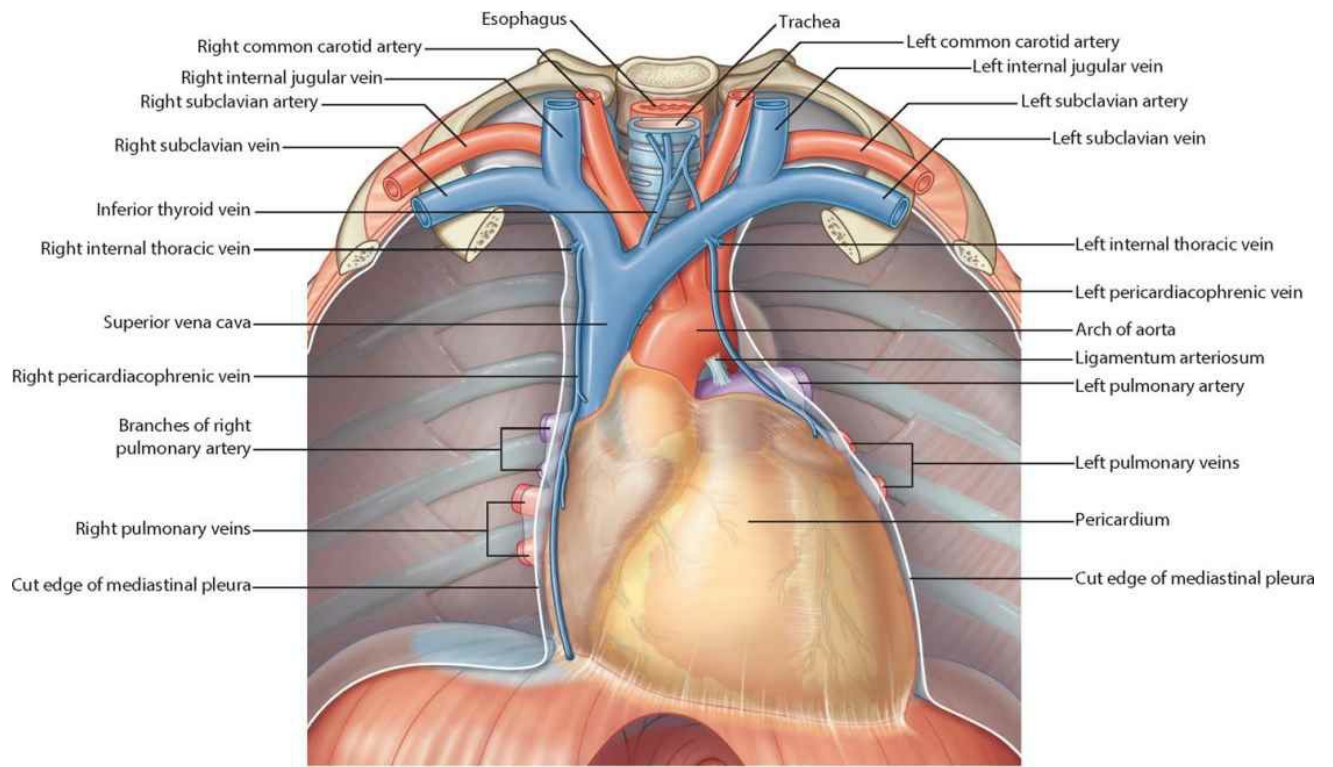
Surface projections of structures in the superior mediastinum



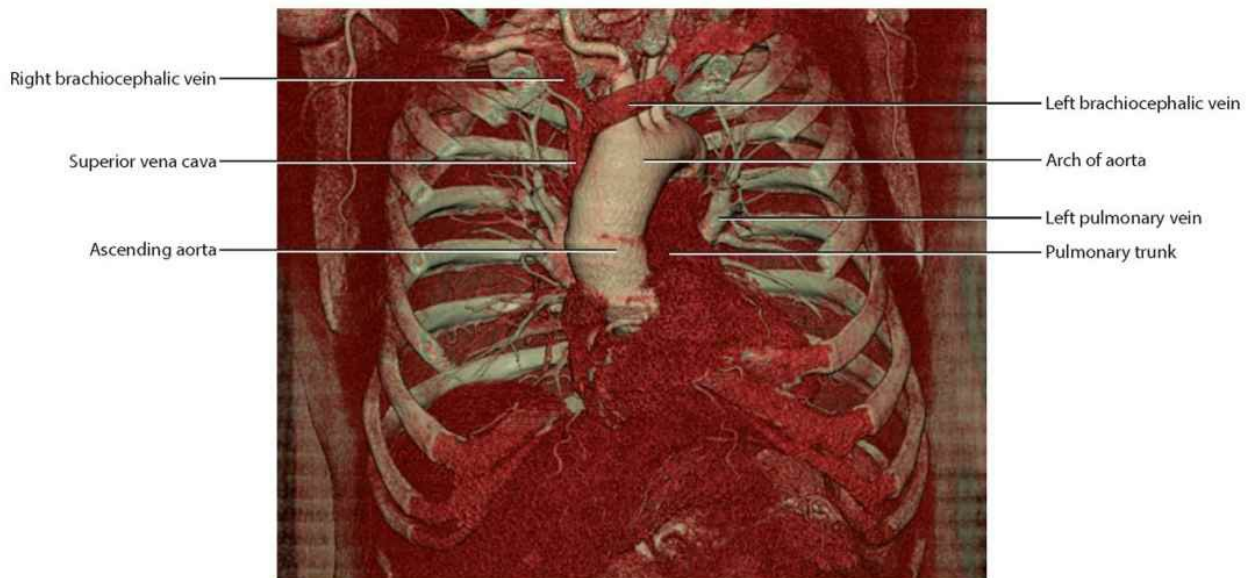
Thymus gland

# Superior mediastinum: veins and arteries



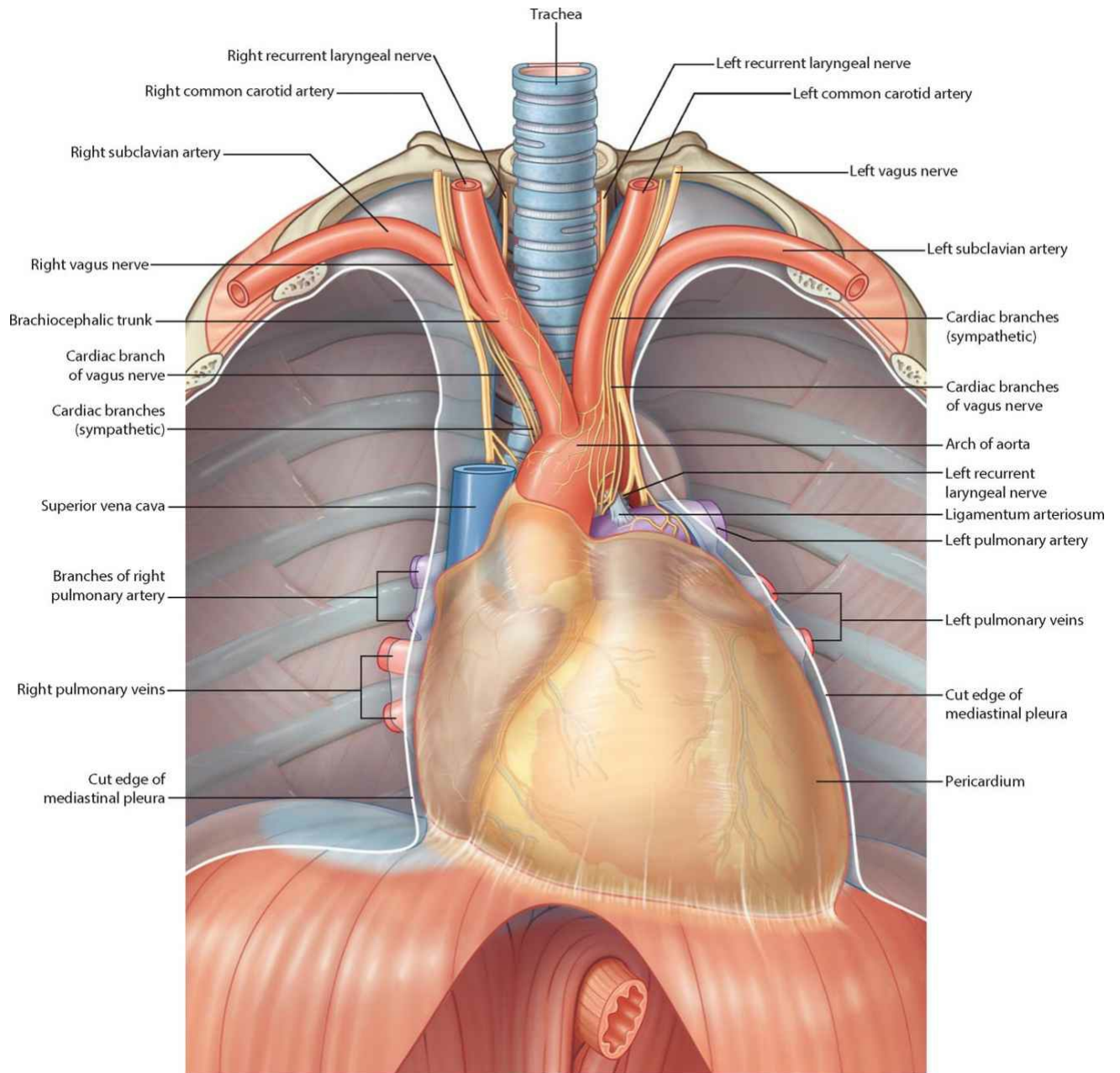


**Veins of the superior mediastinum**



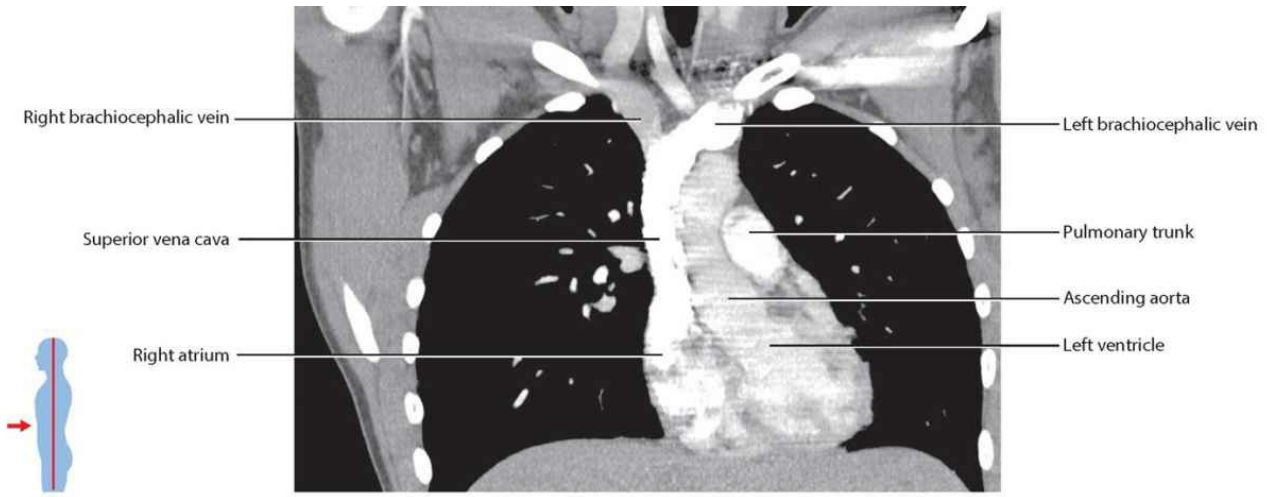
**Anterior view of the superior mediastinum showing venous and arterial channels.**  
Volume-rendered anterior view using multidetector computed tomography

# Superior mediastinum: arteries and nerves

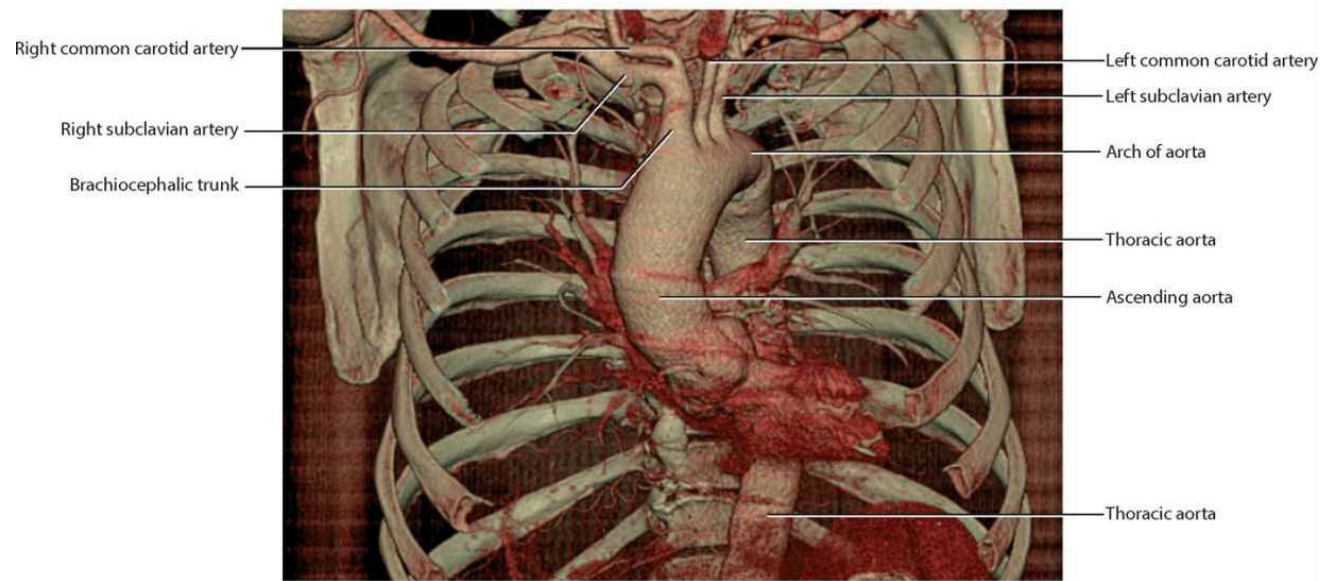


Arteries and nerves of the superior mediastinum

# Superior mediastinum: imaging

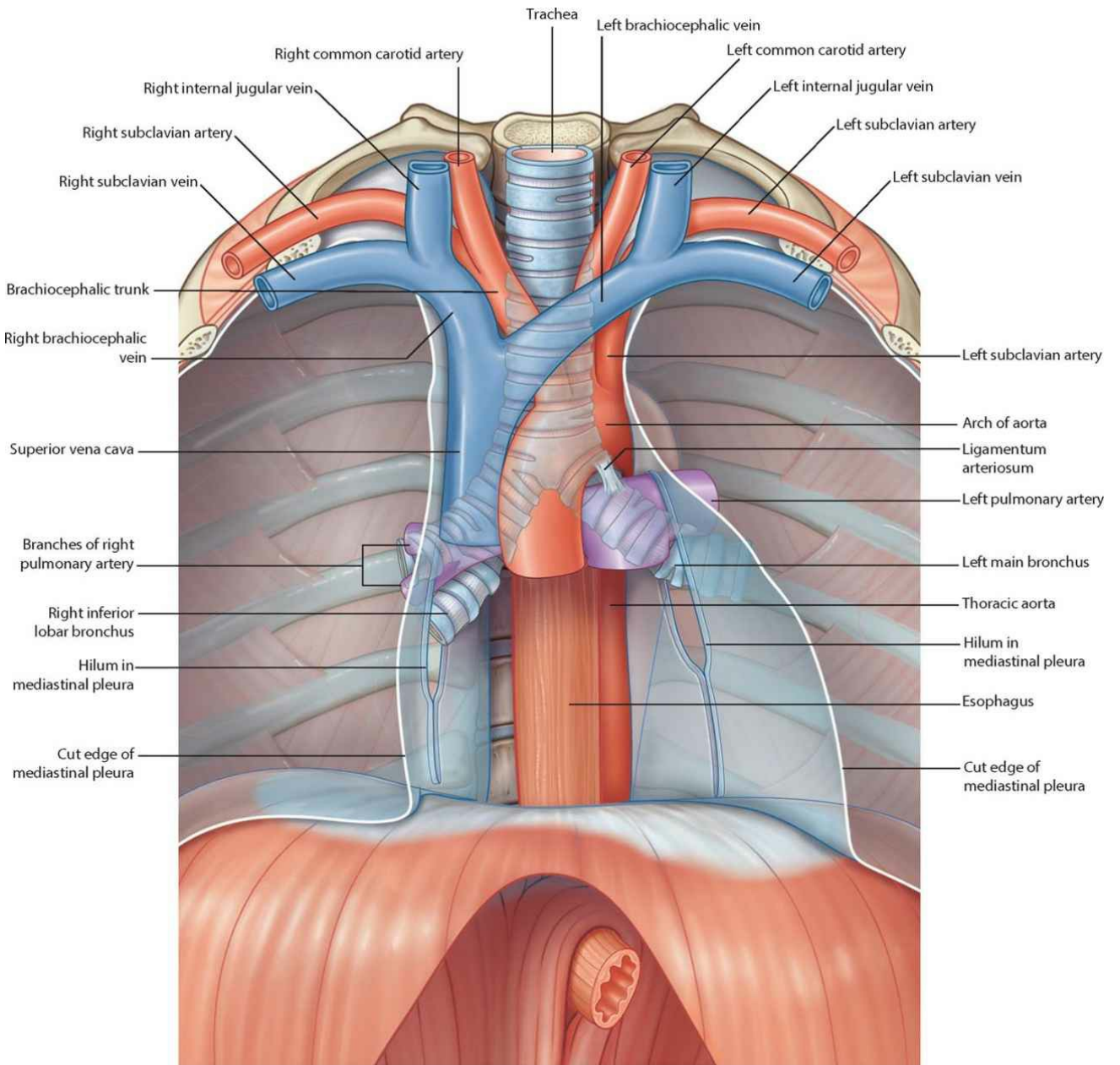


**Positioning of venous channels in the superior mediastinum.**  
 CT image, with contrast, in coronal plane



**Anterior view of the superior mediastinum with the venous channels, pulmonary trunk, and heart removed.**  
 Volume-rendered anterior view using multidetector computed tomography

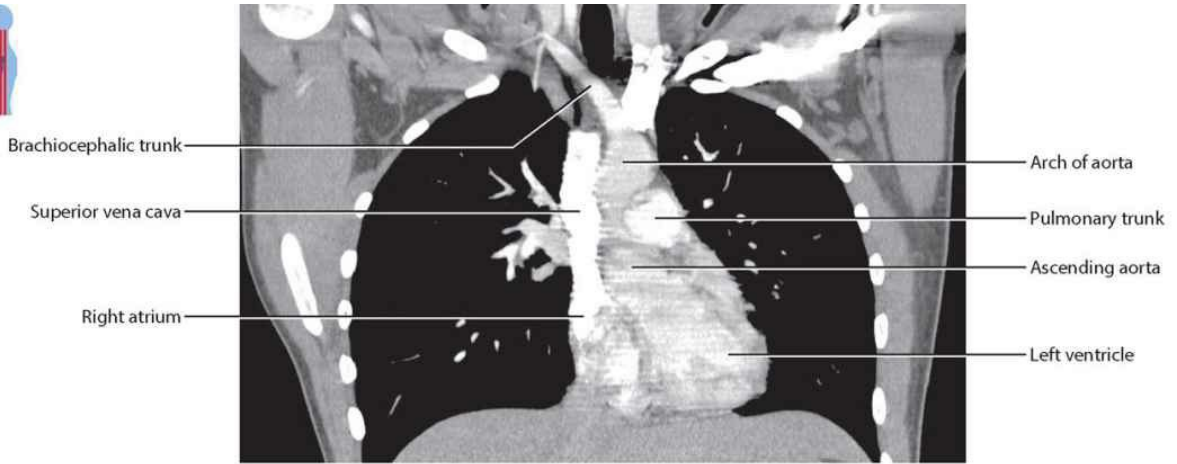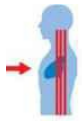
# Superior mediastinum: veins and trachea



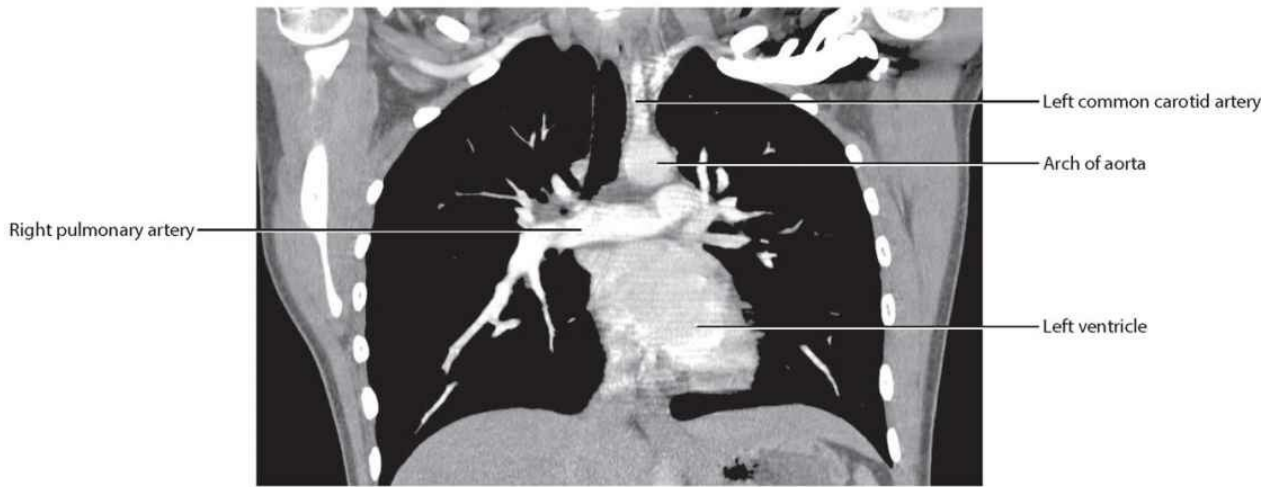
**Trachea and structures relating to it in the superior mediastinum**

# Mediastinum: imaging

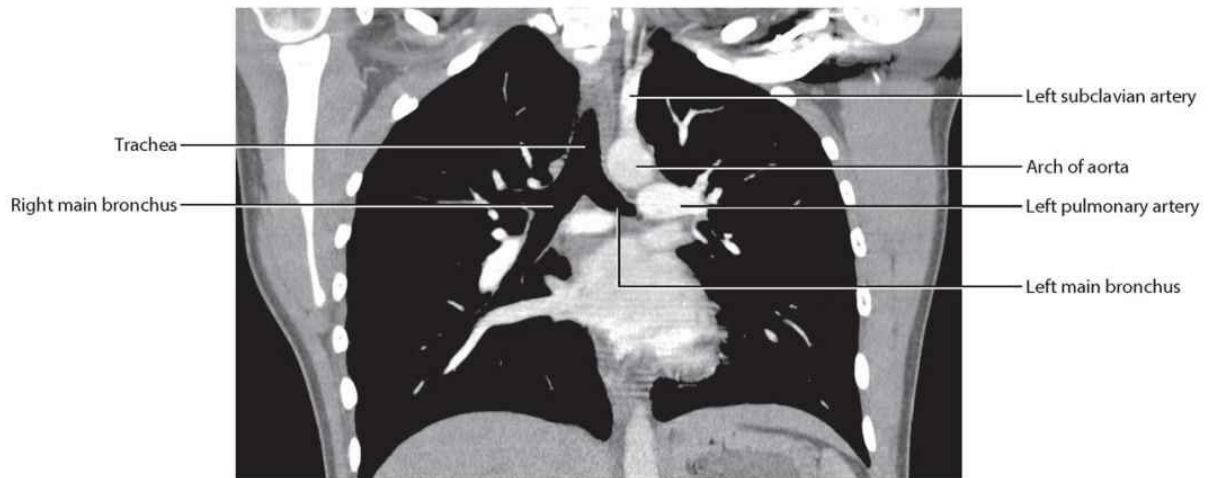




**Positioning of brachiocephalic trunk in relation to other structures in the superior mediastinum.**  
CT image, with contrast, in coronal plane

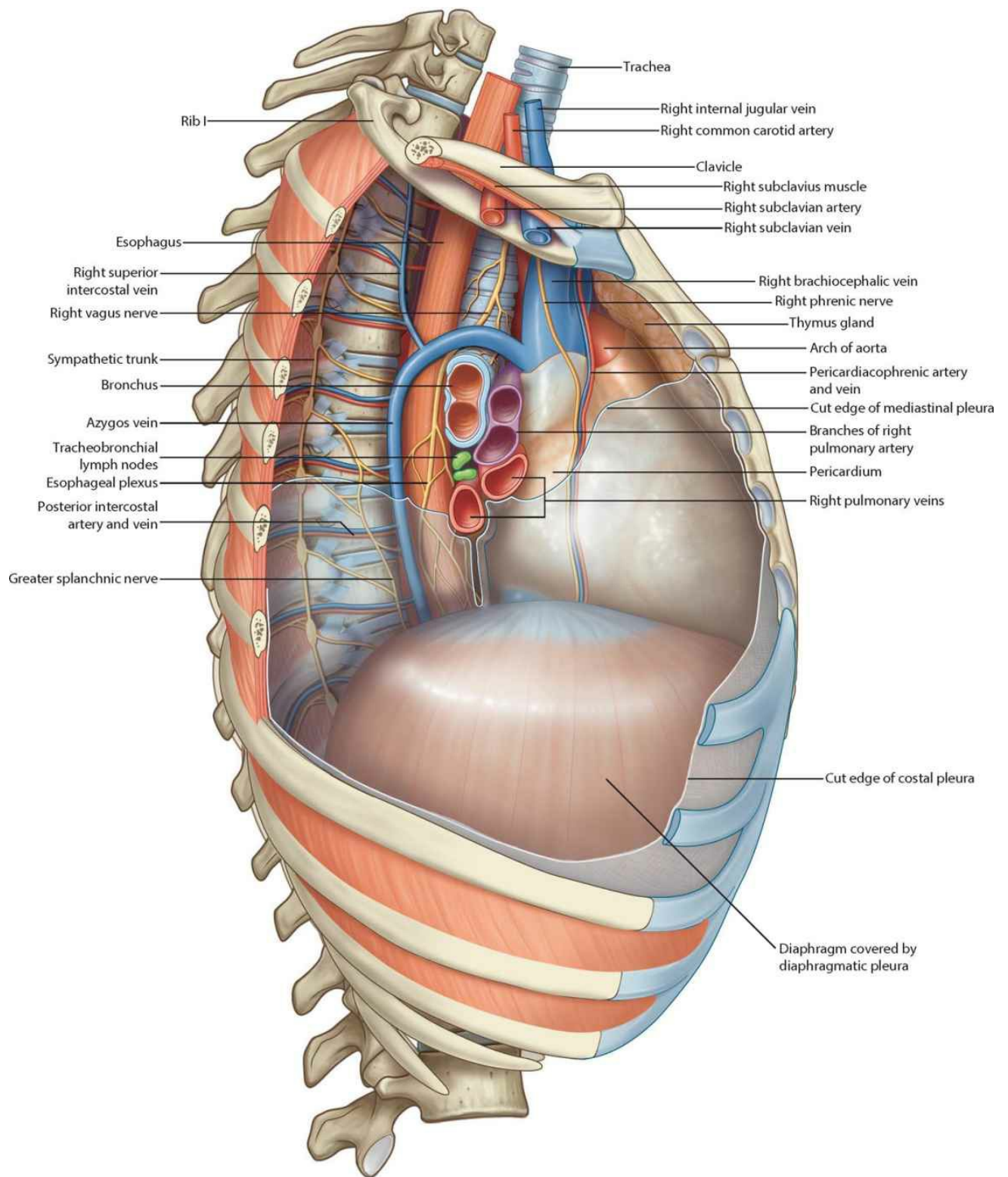


**Positioning of left common carotid artery in relation to other structures in the superior mediastinum.**  
CT image, with contrast, in coronal plane



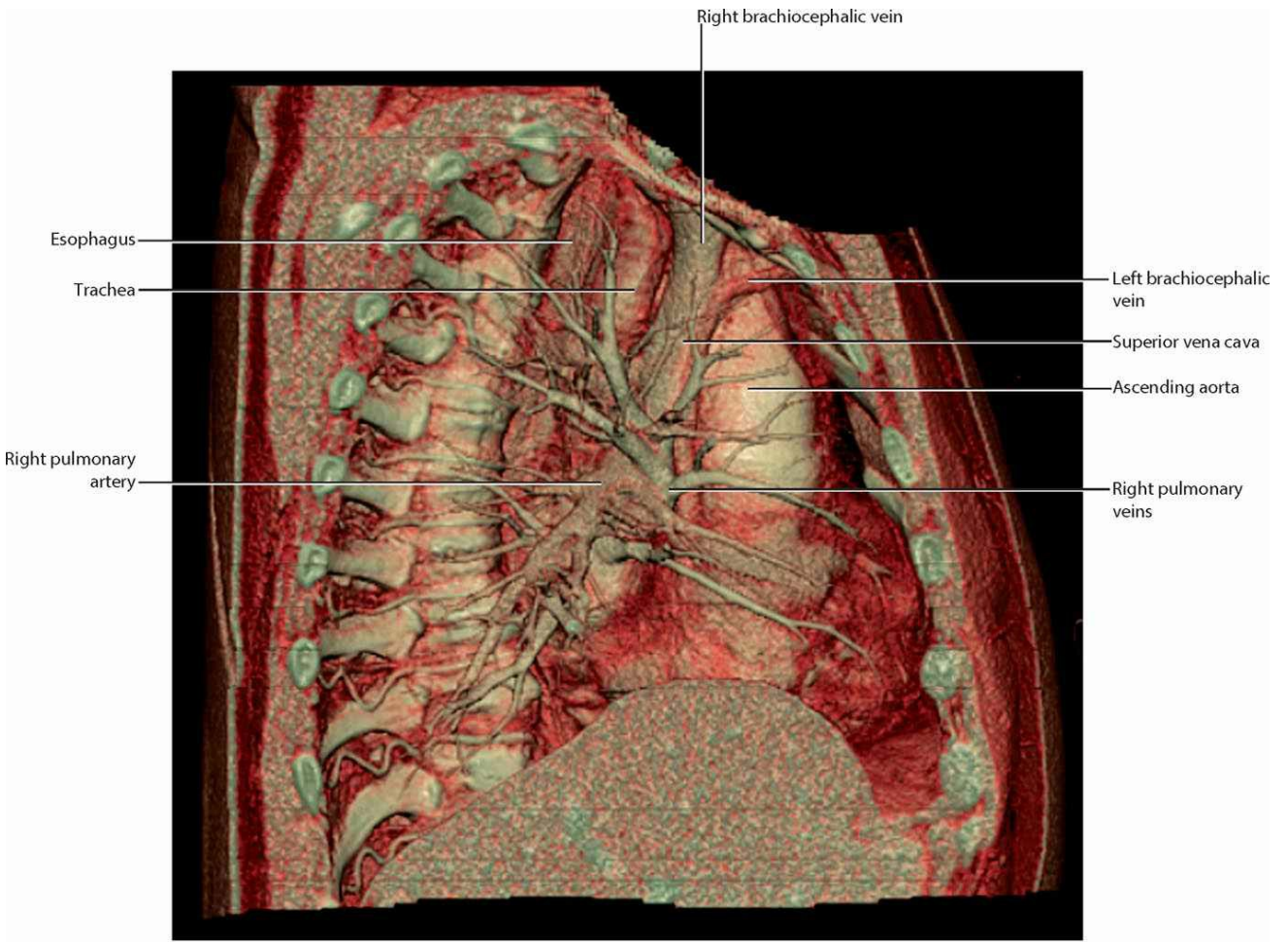
**Positioning of left subclavian artery and the bifurcation of the trachea in relation to other structures in the superior mediastinum.**  
CT image, with contrast, in coronal plane

## Mediastinum: view from right



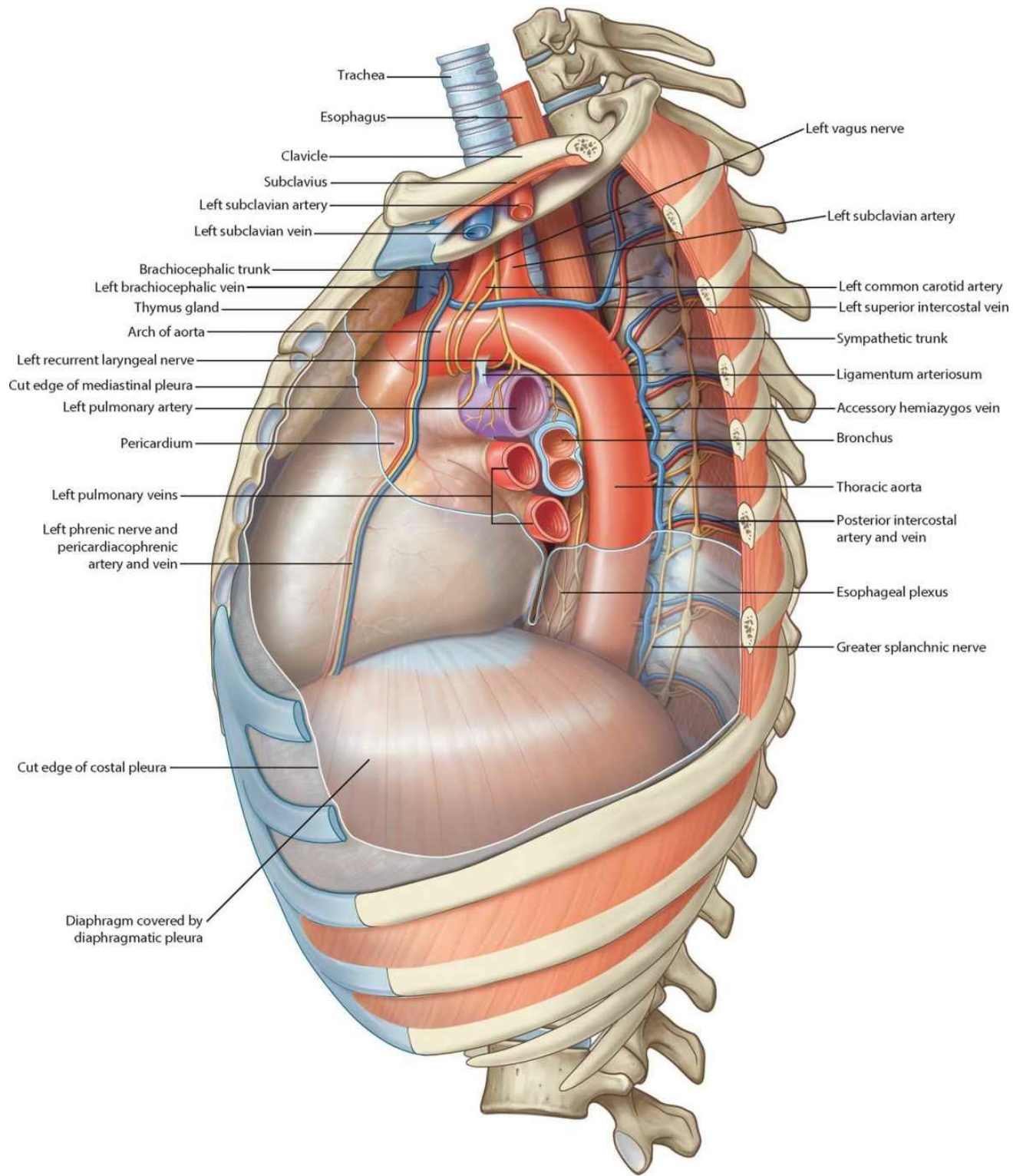
**Right side of mediastinum and right thoracic cavity**

## Mediastinum: imaging – view from right



**View of mediastinal structures from the right side of the thorax.**  
Volume-rendered lateral view from the right side using multidetector computed tomography

## Mediastinum: view from left

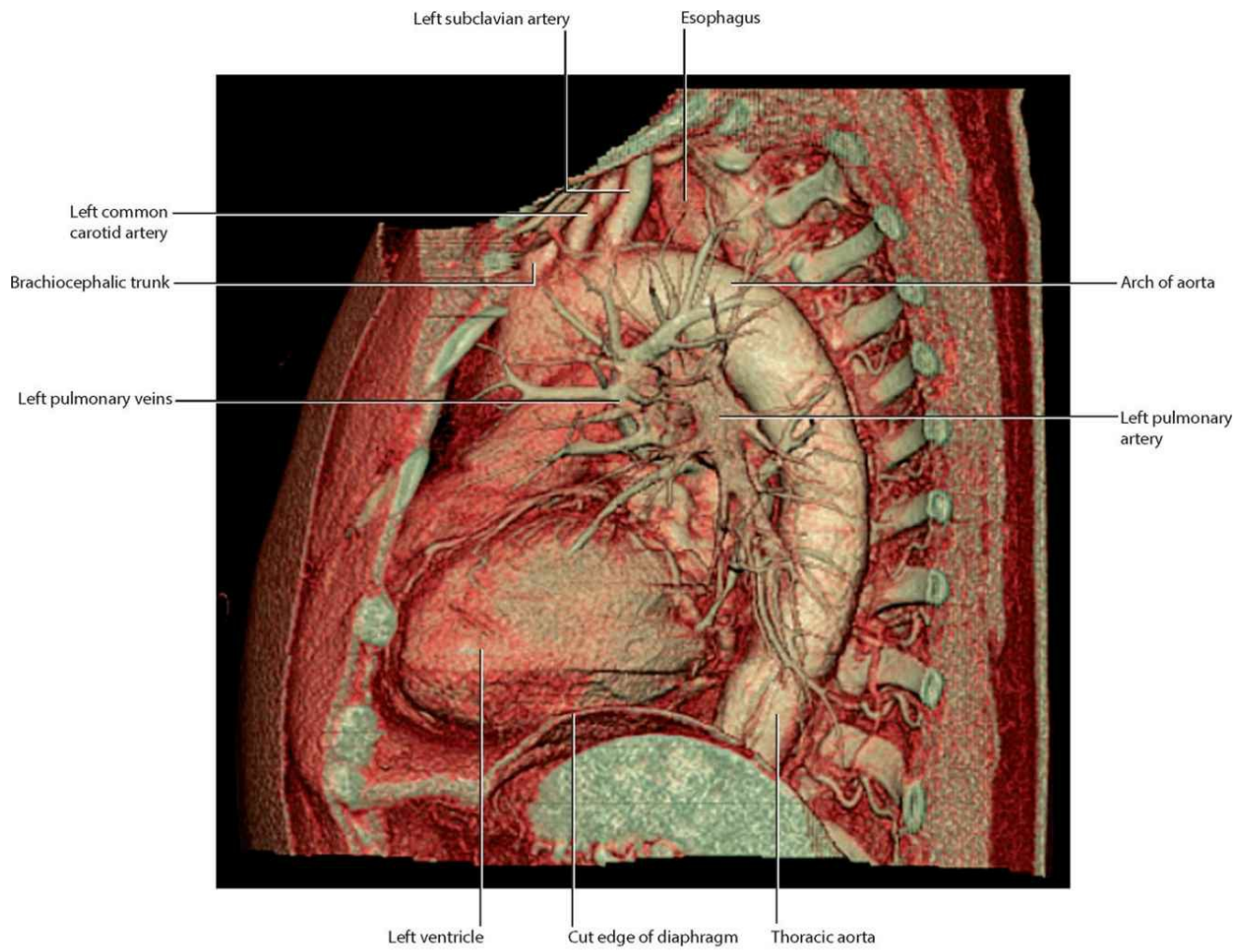


- Trachea
- Esophagus
- Clavicle
- Subclavius
- Left subclavian artery
- Left subclavian vein
- Brachiocephalic trunk
- Left brachiocephalic vein
- Thymus gland
- Arch of aorta
- Left recurrent laryngeal nerve
- Cut edge of mediastinal pleura
- Left pulmonary artery
- Pericardium
- Left pulmonary veins
- Left phrenic nerve and pericardiophrenic artery and vein
- Cut edge of costal pleura
- Diaphragm covered by diaphragmatic pleura
- Left vagus nerve
- Left subclavian artery
- Left common carotid artery
- Left superior intercostal vein
- Sympathetic trunk
- Ligamentum arteriosum
- Accessory hemiazygos vein
- Bronchus
- Thoracic aorta
- Posterior intercostal artery and vein
- Esophageal plexus
- Greater splanchnic nerve

**Left side of mediastinum and left thoracic cavity**

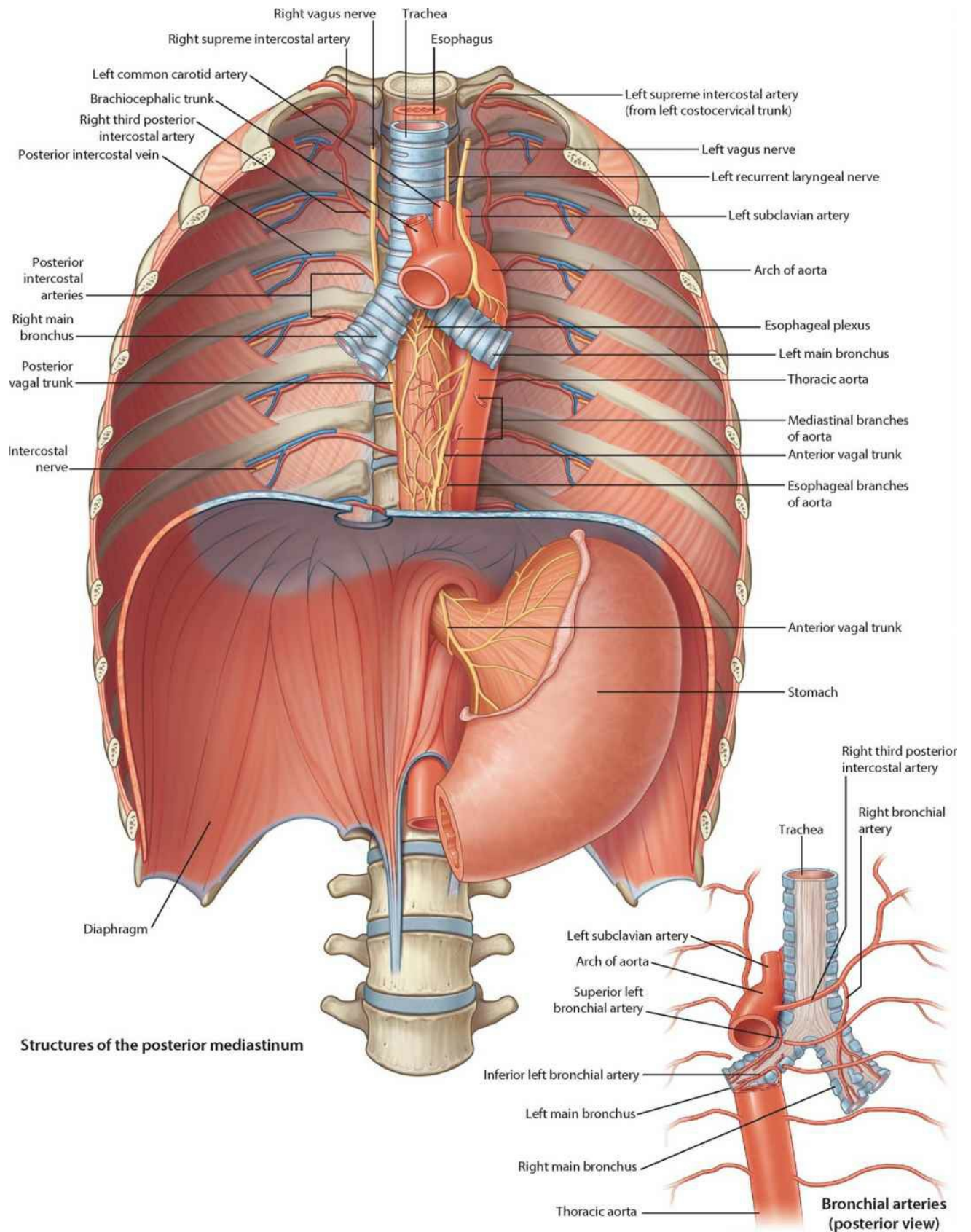
## Mediastinum: imaging – view from left





**View of mediastinal structures from the left side of the thorax.**  
Volume-rendered lateral view from the left side using multidetector computed tomography

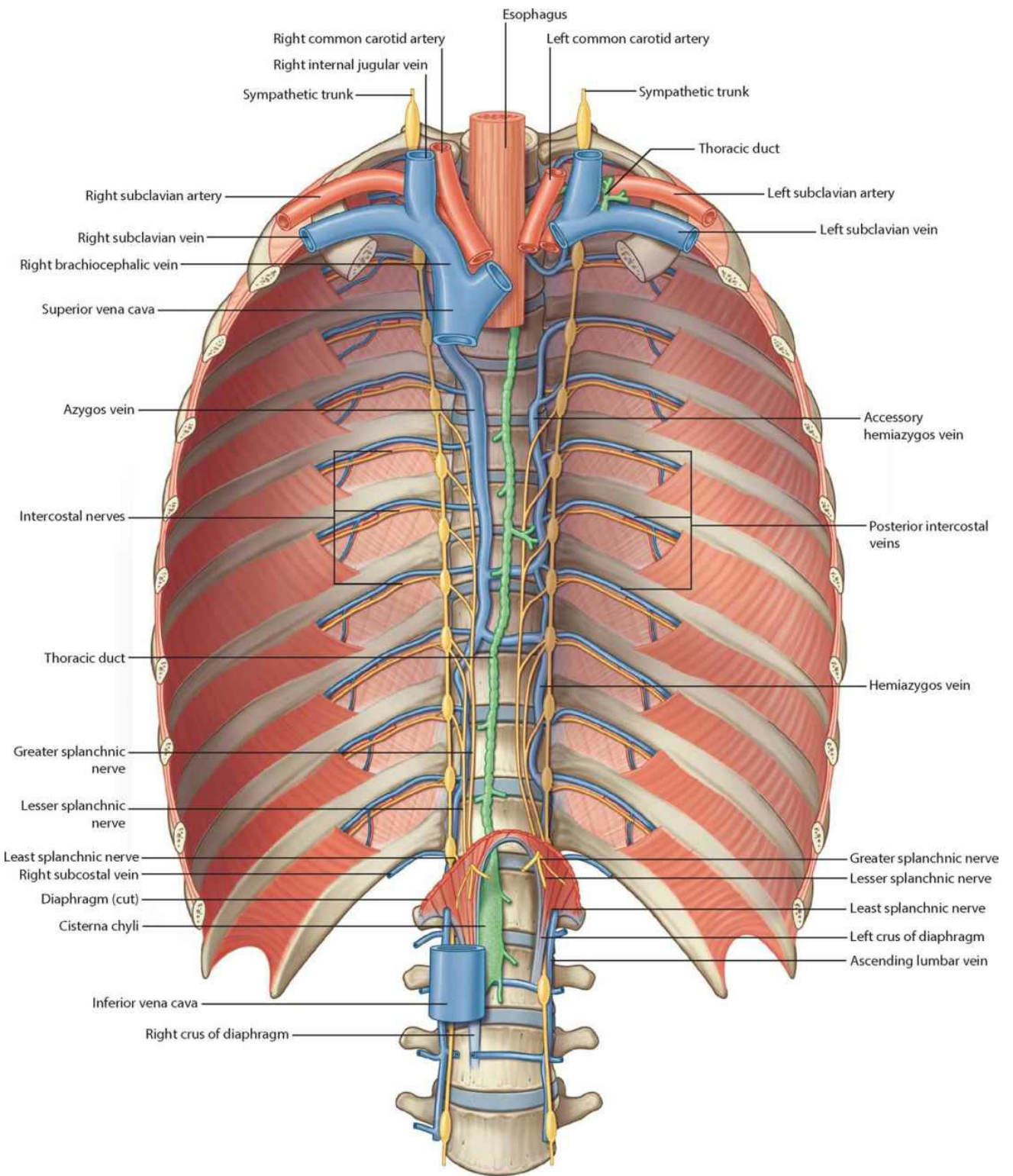
# Posterior mediastinum



**Structures of the posterior mediastinum**

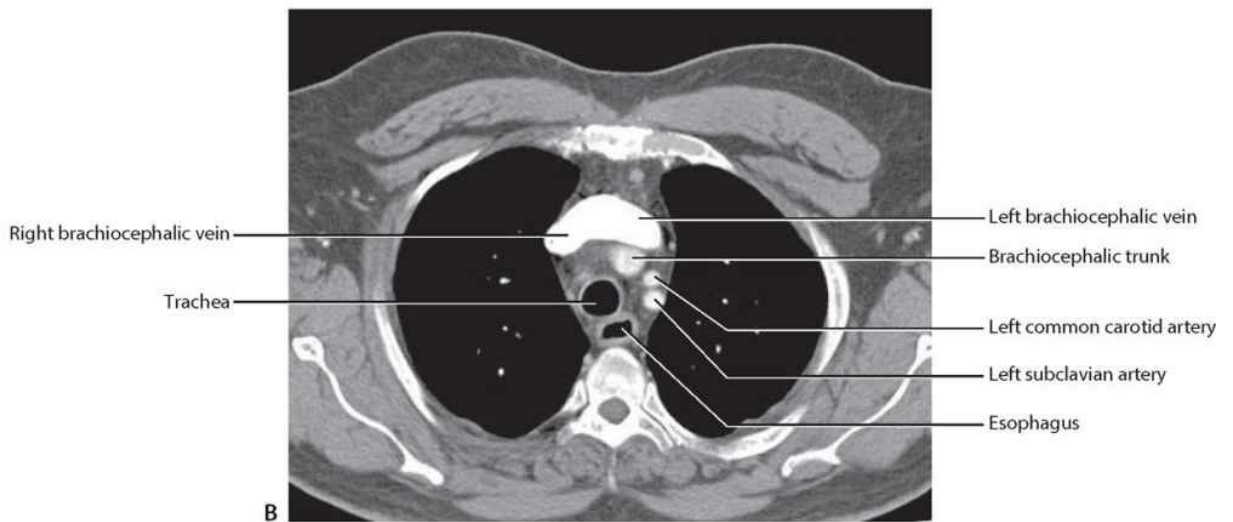
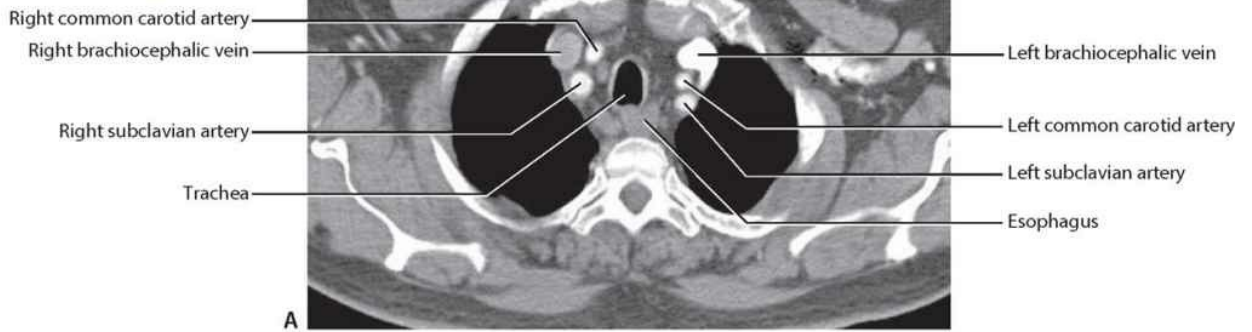
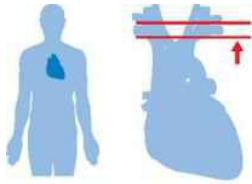
**Bronchial arteries (posterior view)**



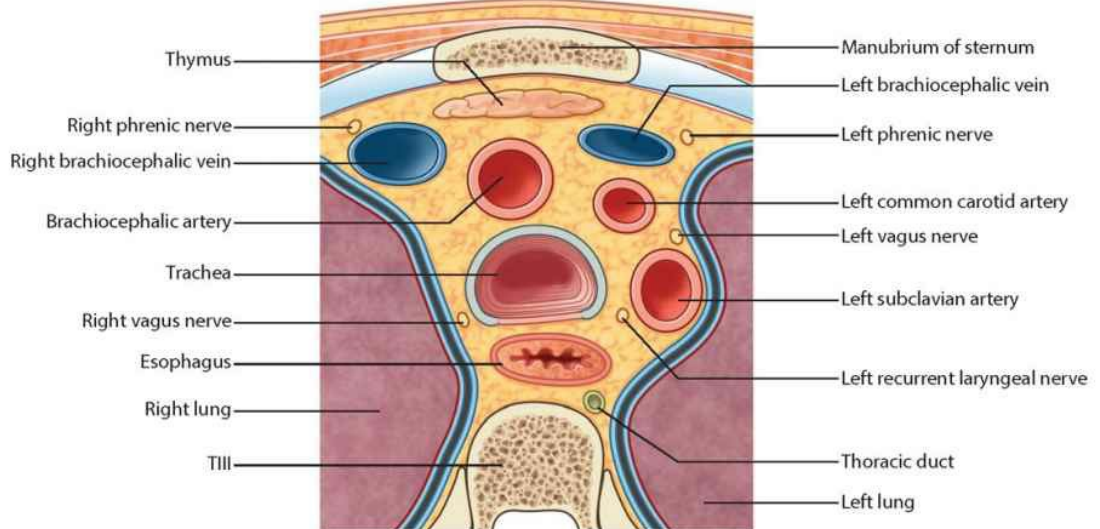


**Structures of the posterior mediastinum  
(thoracic aorta and esophagus removed)**

# Mediastinum: imaging



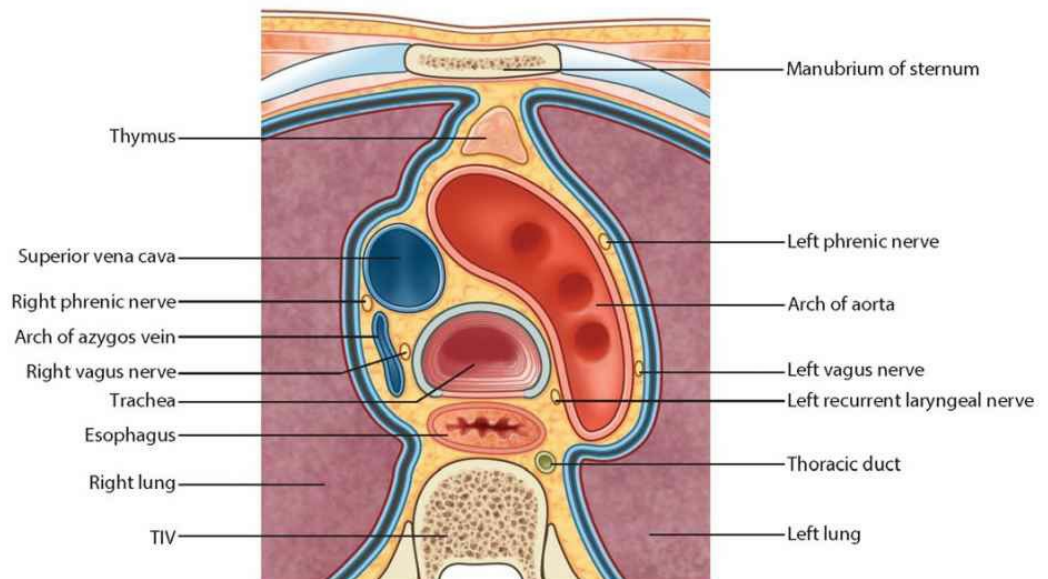
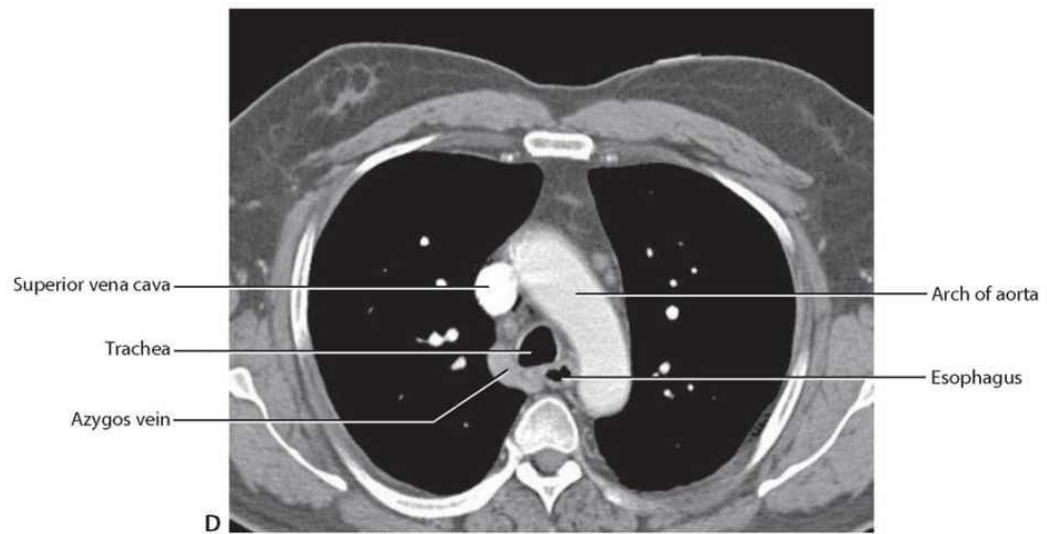
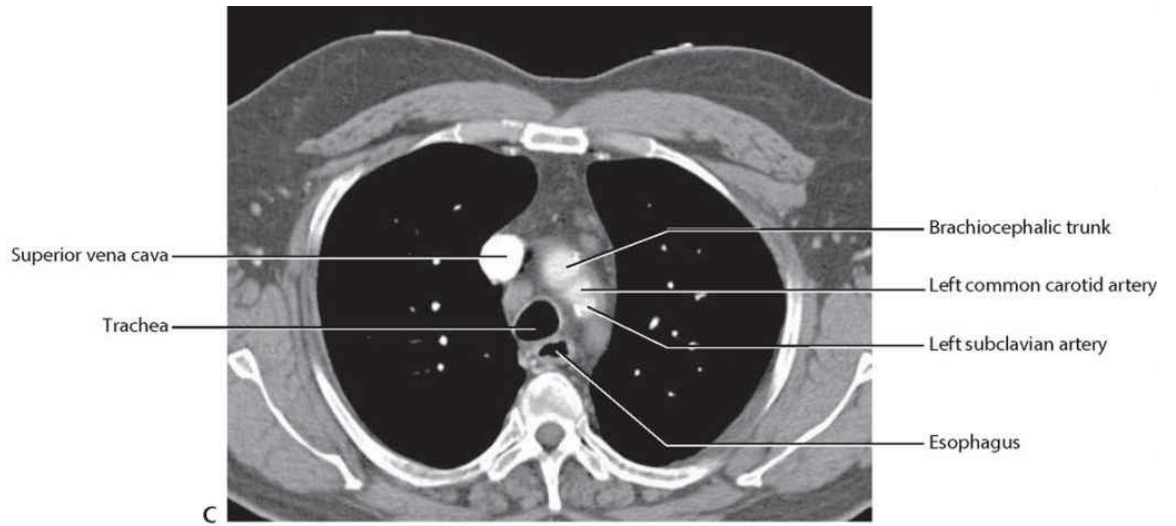
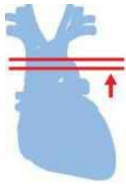
**A through I – This is a series of images that pass through the thorax from superior to inferior showing the various mediastinal structures and their relationships with each other.**  
 CT images, with contrast, in axial plane



**Transverse section through the superior mediastinum at the level of vertebra TIII**

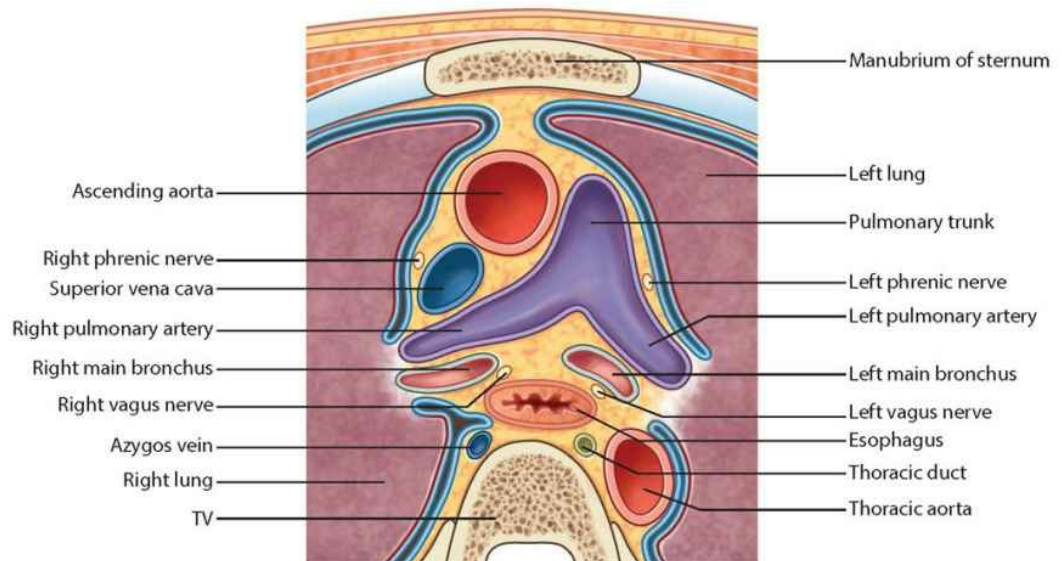
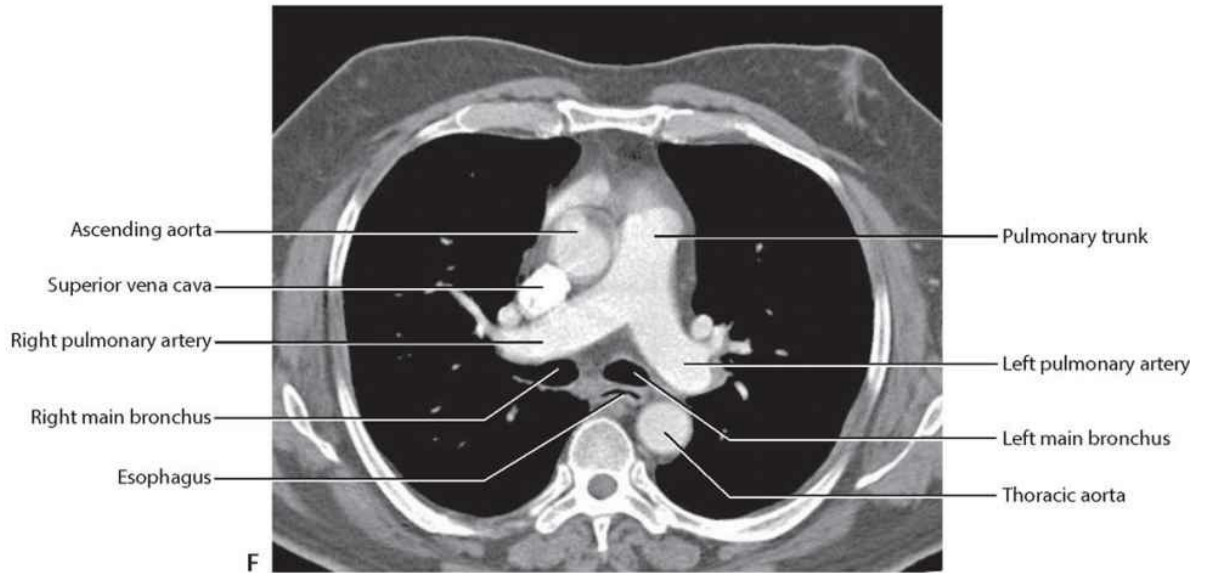
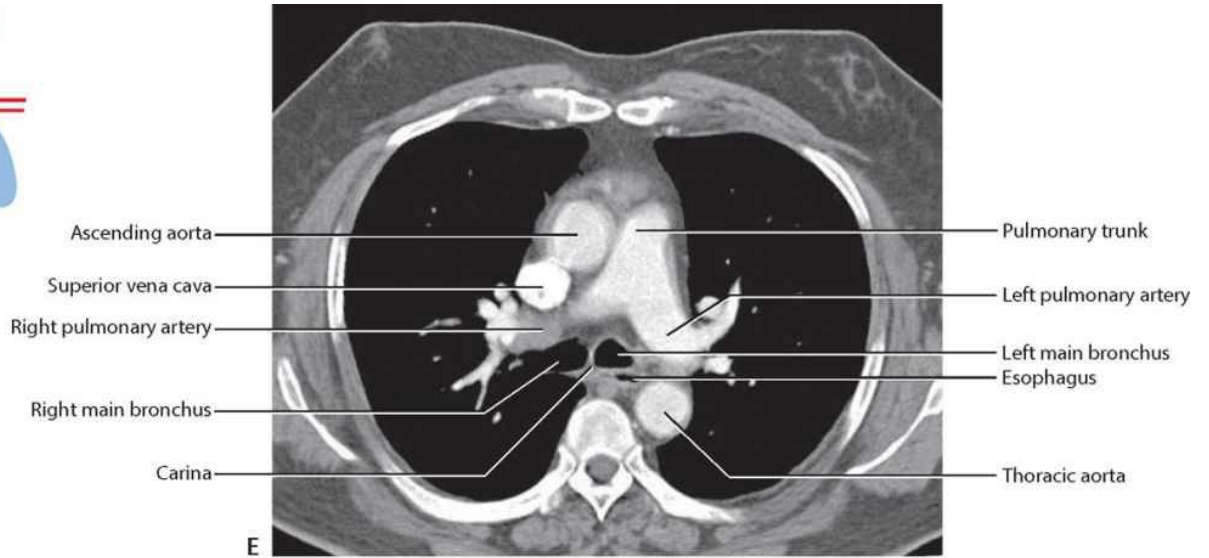
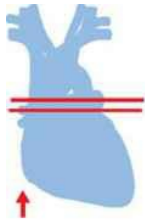





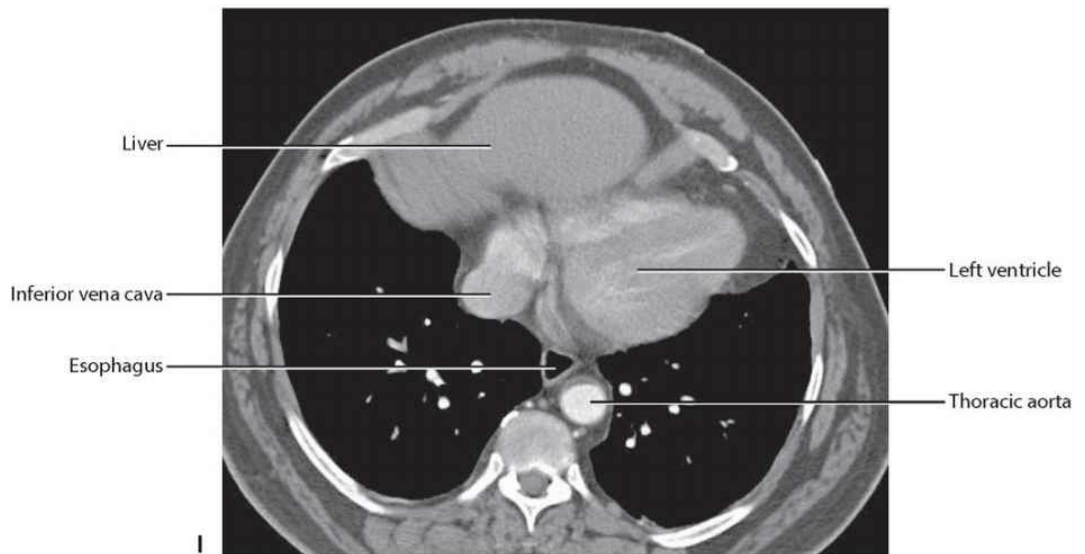
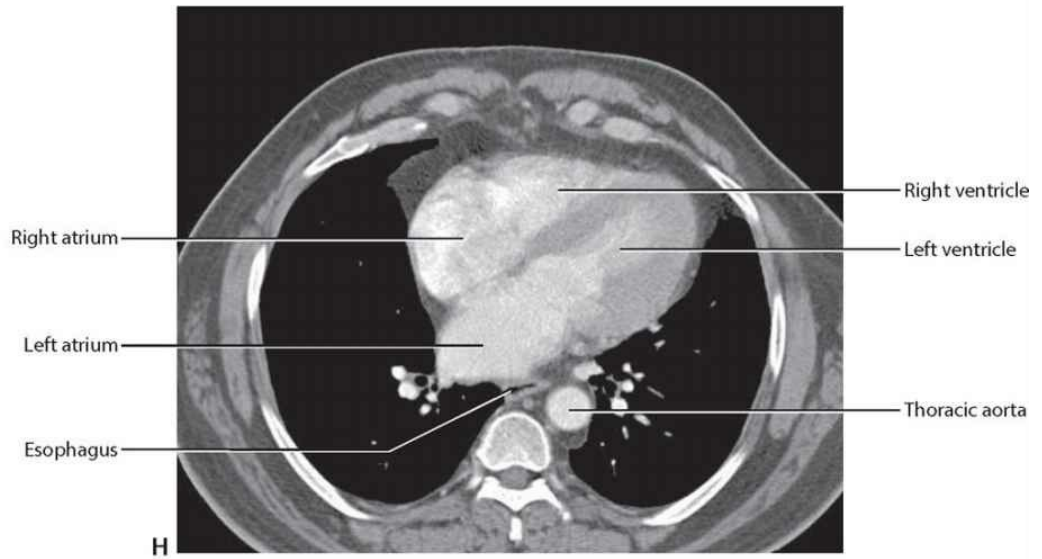
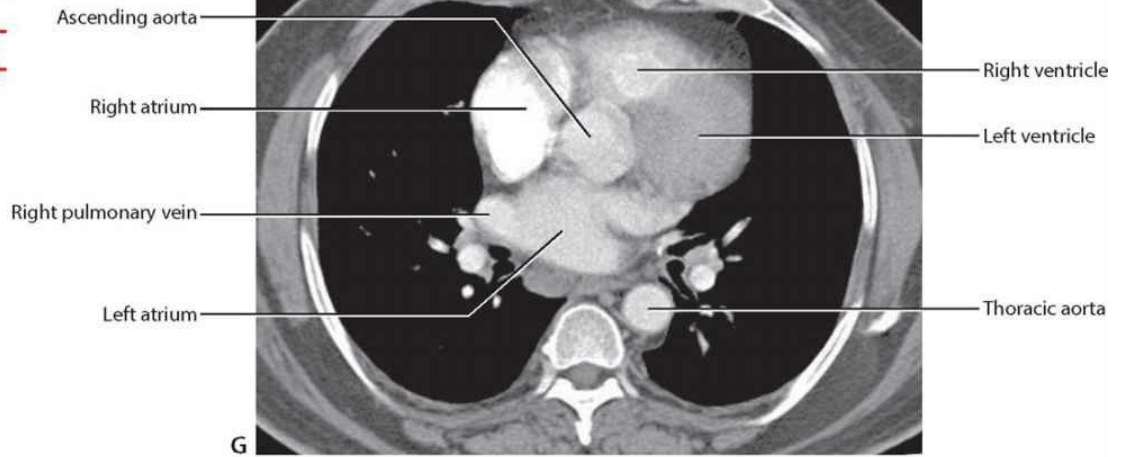
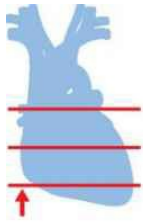
Transverse section through the superior mediastinum at the level of vertebra TIV





Transverse section through the superior mediastinum at the level of vertebra TV

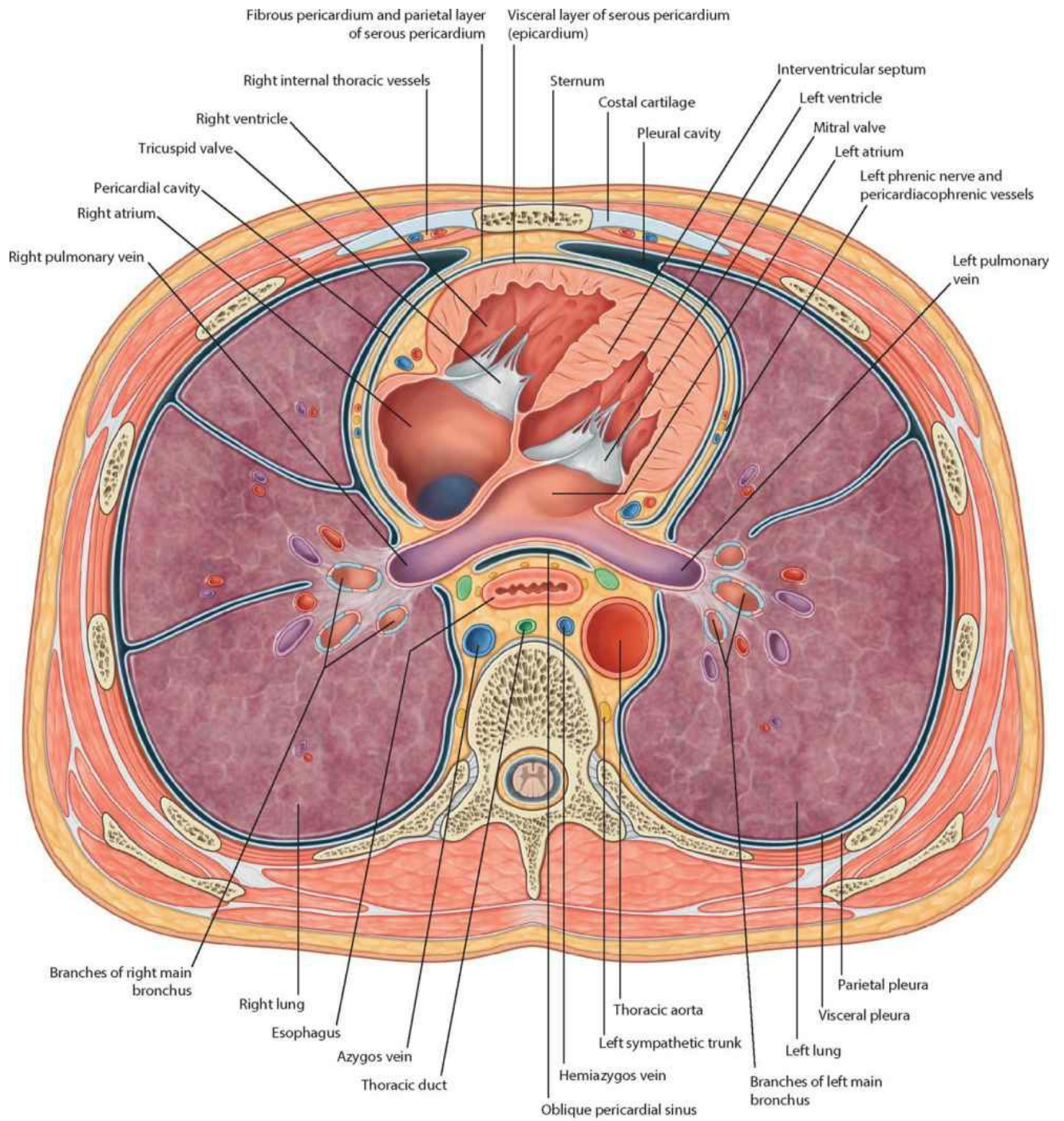




**A through I** – This is a series of images that pass through the thorax from superior to inferior showing the various mediastinal structures and their relationships with each other.  
 CT images, with contrast, in axial plane



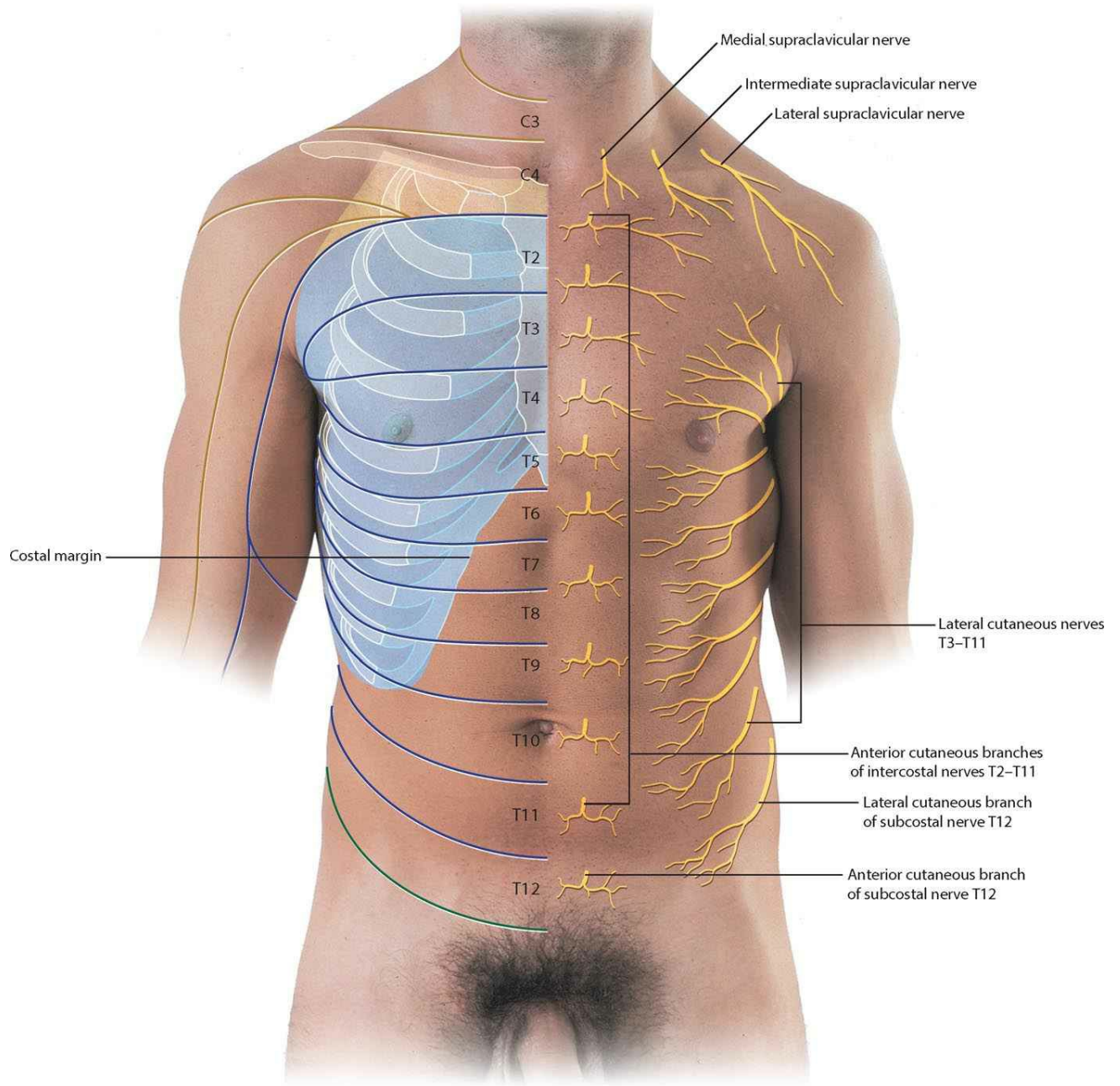
## **Transverse section: TVIII level**



**Transverse section through thorax  
 (approximately T7)**

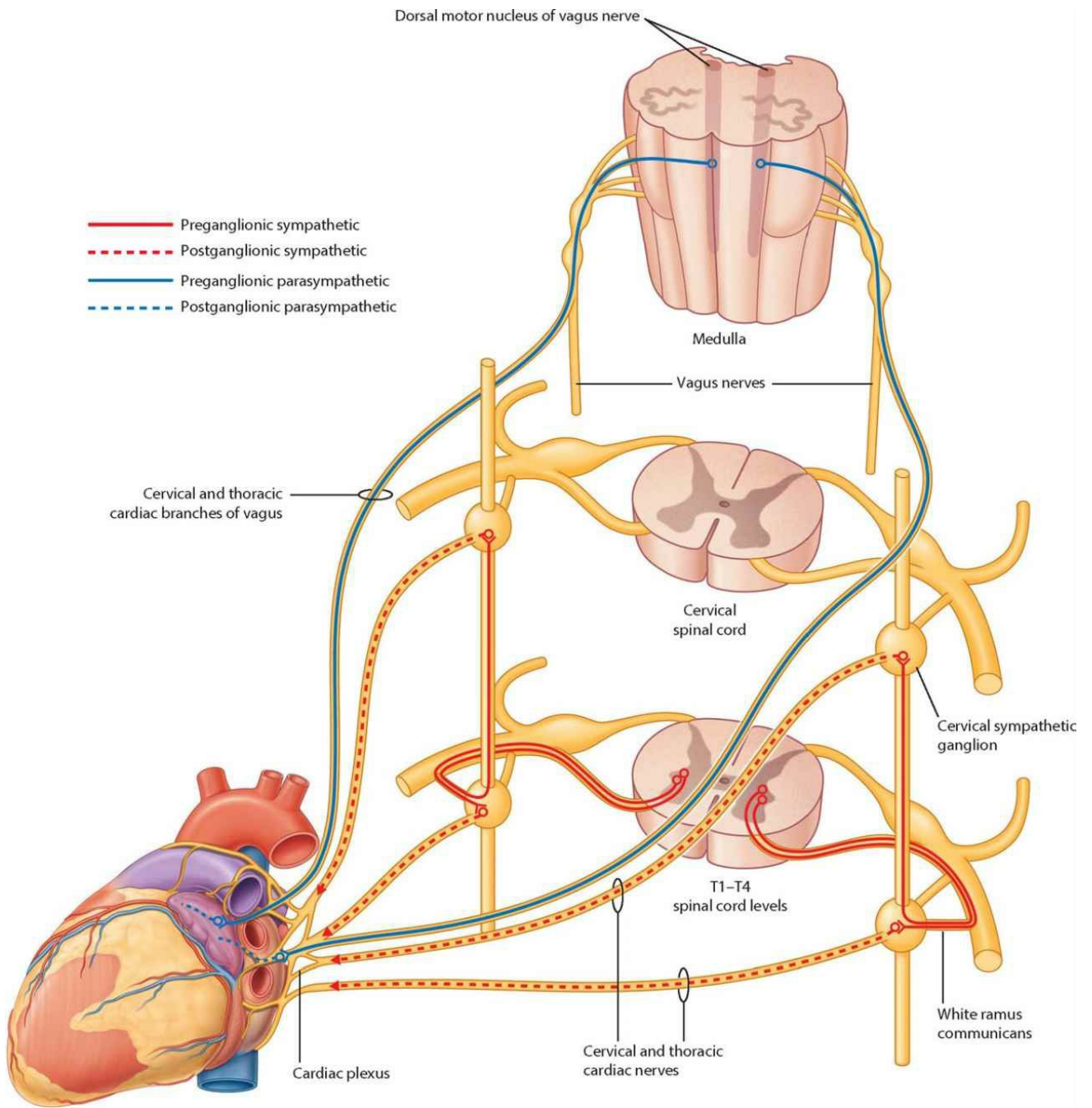


# **Dermatomes and cutaneous nerves**



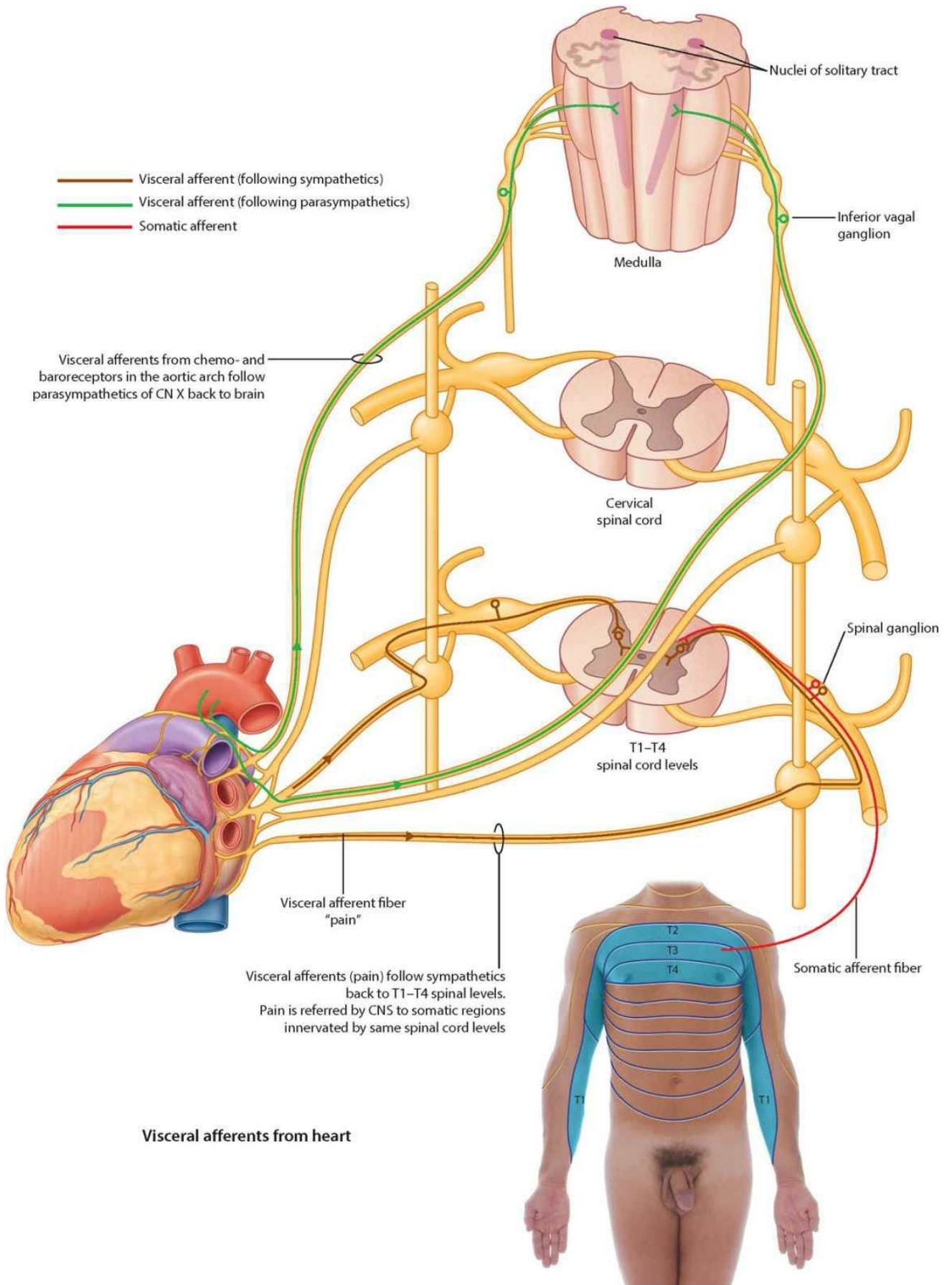
**Dermatomes and cutaneous nerves of the thoracic region**

# **Visceral efferent (motor) innervation of the heart**



**Visceral efferent (motor) innervation of the heart (sympathetic and parasympathetic)**

# Visceral afferents



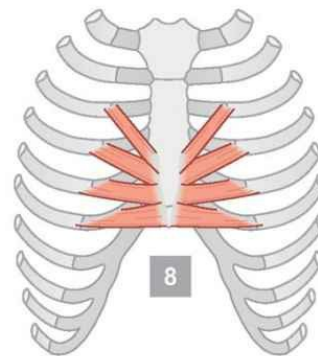
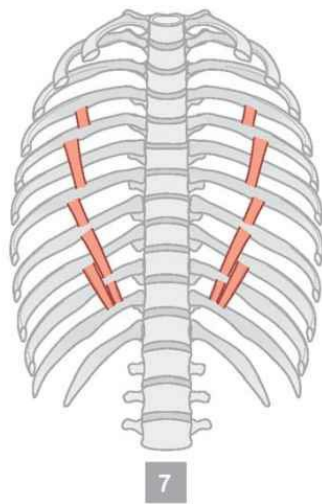
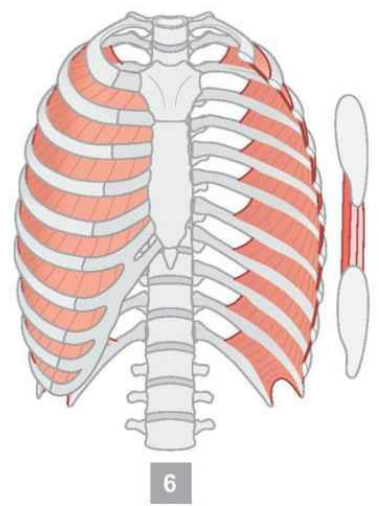
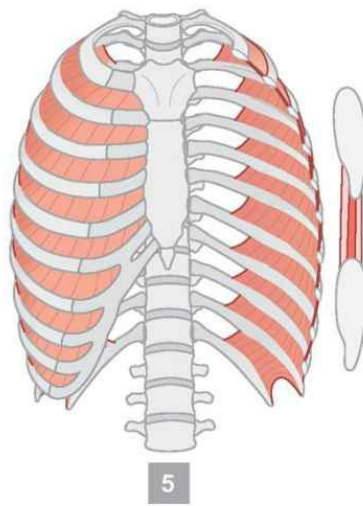
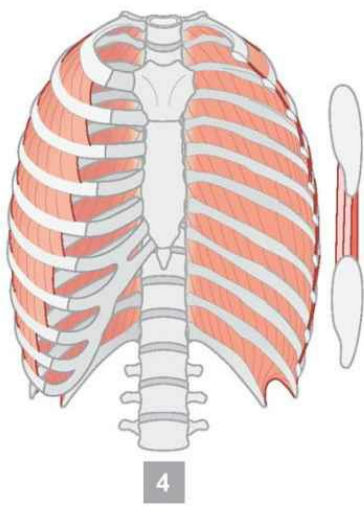
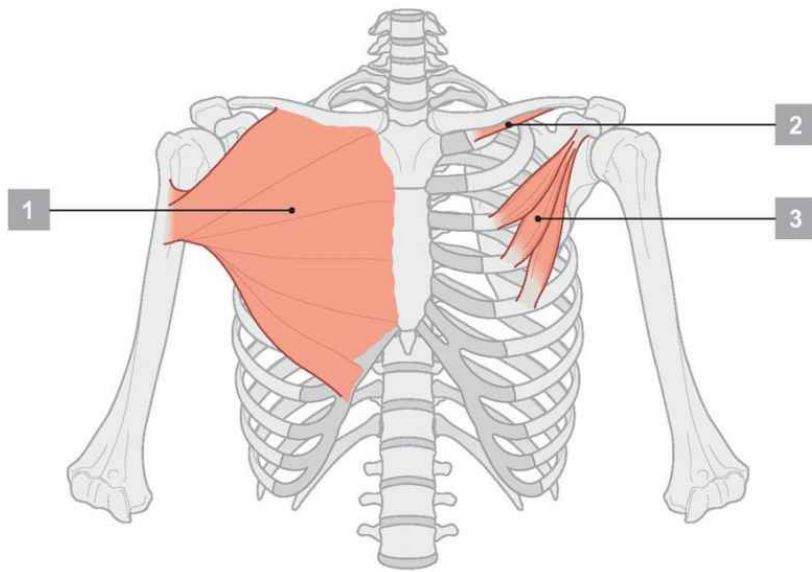
# Tables

## Muscles of the pectoral region

Muscle		Origin	Insertion	Innervation	Function
<b>Pectoralis major</b>	1	Medial half of clavicle and anterior surface of sternum, first seven costal cartilages, aponeurosis of external oblique	Lateral lip of intertubercular sulcus of humerus	Medial and lateral pectoral nerves	Adduction, medial rotation, and flexion of the humerus at the shoulder joint
<b>Subclavius</b>	2	Rib I at junction between rib and costal cartilage	Groove on inferior surface of middle third of clavicle	Nerve to subclavius	Pulls clavicle medially to stabilize sternoclavicular joint; depresses tip of shoulder
<b>Pectoralis minor</b>	3	Anterior surfaces of the third, fourth and fifth ribs, and deep fascia overlying the related intercostal spaces	Coracoid process of scapula	Medial pectoral nerves	Depresses tip of shoulder; protracts scapula

## Muscles of the thoracic wall

<b>External intercostal</b>	4	Inferior margin of rib above	Superior margin of rib below	Intercostal nerves; T1-T11	Most active during inspiration; supports intercostal space; moves ribs superiorly
<b>Internal intercostal</b>	5	Lateral edge of costal groove of rib above	Superior margin of rib below deep to the attachment of the related external intercostal	Intercostal nerves; T1-T11	Most active during expiration; supports intercostal space; moves ribs inferiorly
<b>Innermost intercostal</b>	6	Medial edge of costal groove of rib above	Internal aspect of superior margin of rib below	Intercostal nerves; T1-T11	Acts with internal intercostal muscles
<b>Subcostales</b>	7	Internal surface (near angle) of lower ribs	Internal surface of second or third rib below	Related intercostal nerves	May depress ribs
<b>Transversus thoracis</b>	8	Inferior margins and internal surfaces of costal cartilages of second to sixth ribs	Inferior aspect of deep surface of body of sternum, xiphoid process and costal cartilages ribs IV-VII	Related intercostal nerves	Depresses costal cartilages

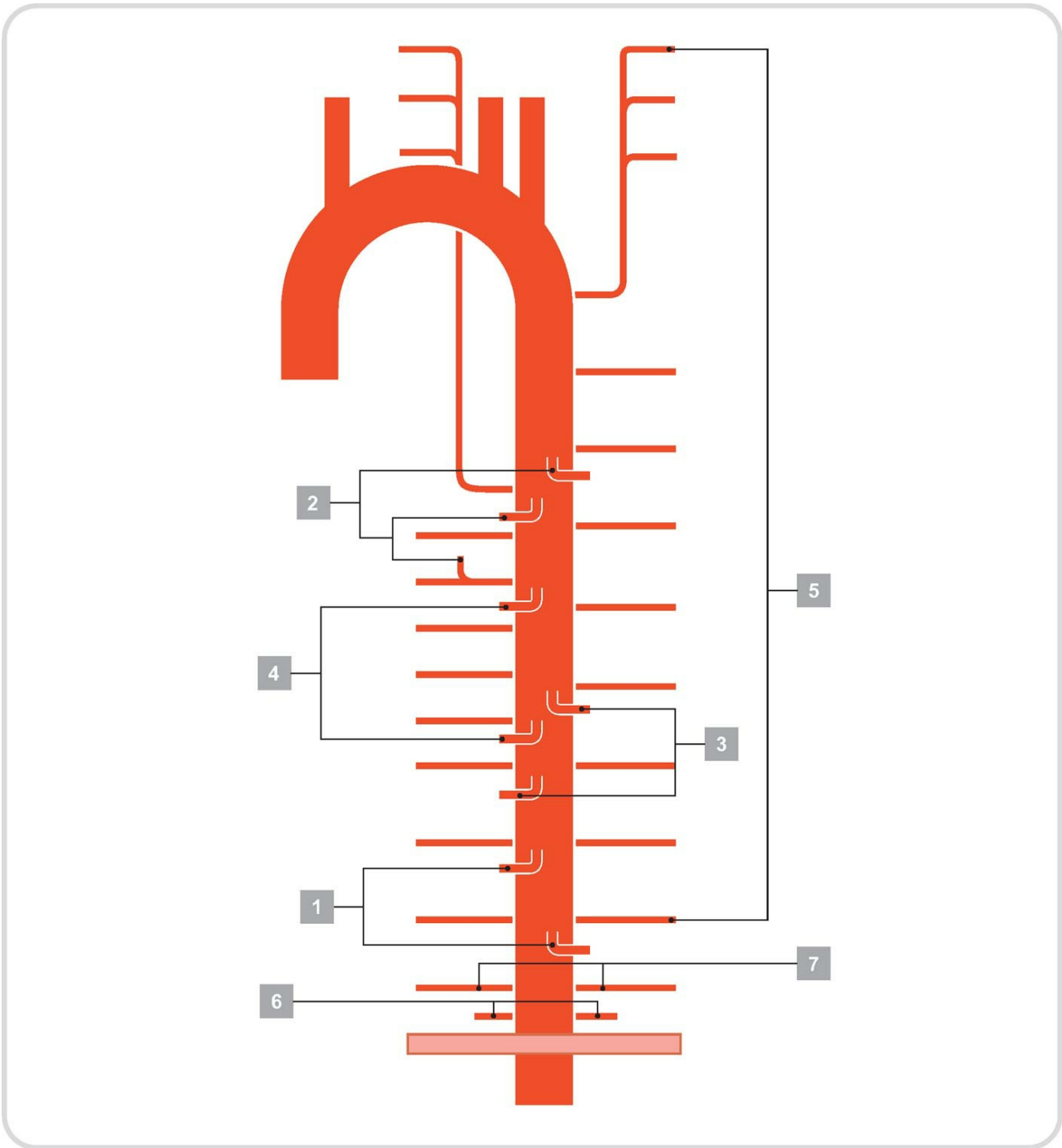




## Branches of the thoracic aorta

---

Branches		Origin and course
<b>Pericardial branches</b>	1	A few small vessels to the posterior surface of the pericardial sac
<b>Bronchial branches</b>	2	Vary in number, size, and origin – usually, two left bronchial arteries from the thoracic aorta and one right bronchial artery from the third posterior intercostal artery or the superior left bronchial artery
<b>Esophageal branches</b>	3	Four or five vessels from the anterior aspect of the thoracic aorta, which form a continuous anastomotic chain – anastomotic connections include esophageal branches of the inferior thyroid artery superiorly, and esophageal branches of the left inferior phrenic and the left gastric arteries inferiorly
<b>Mediastinal branches</b>	4	Several small branches supplying lymph nodes, vessels, nerves, and areolar tissue in the posterior mediastinum
<b>Posterior intercostal arteries</b>	5	Usually nine pairs of vessels branching from the posterior surface of the thoracic aorta – usually supply lower nine intercostal spaces (first two spaces are supplied by the supreme intercostal artery – a branch of the costocervical trunk)
<b>Superior phrenic arteries</b>	6	Small vessels from the lower part of the thoracic aorta supplying the posterior part of the superior surface of the diaphragm – they anastomose with the musculophrenic and pericardiophrenic arteries
<b>Subcostal artery</b>	7	The lowest pair of branches from the thoracic aorta located inferior to rib XII





# ABDOMEN

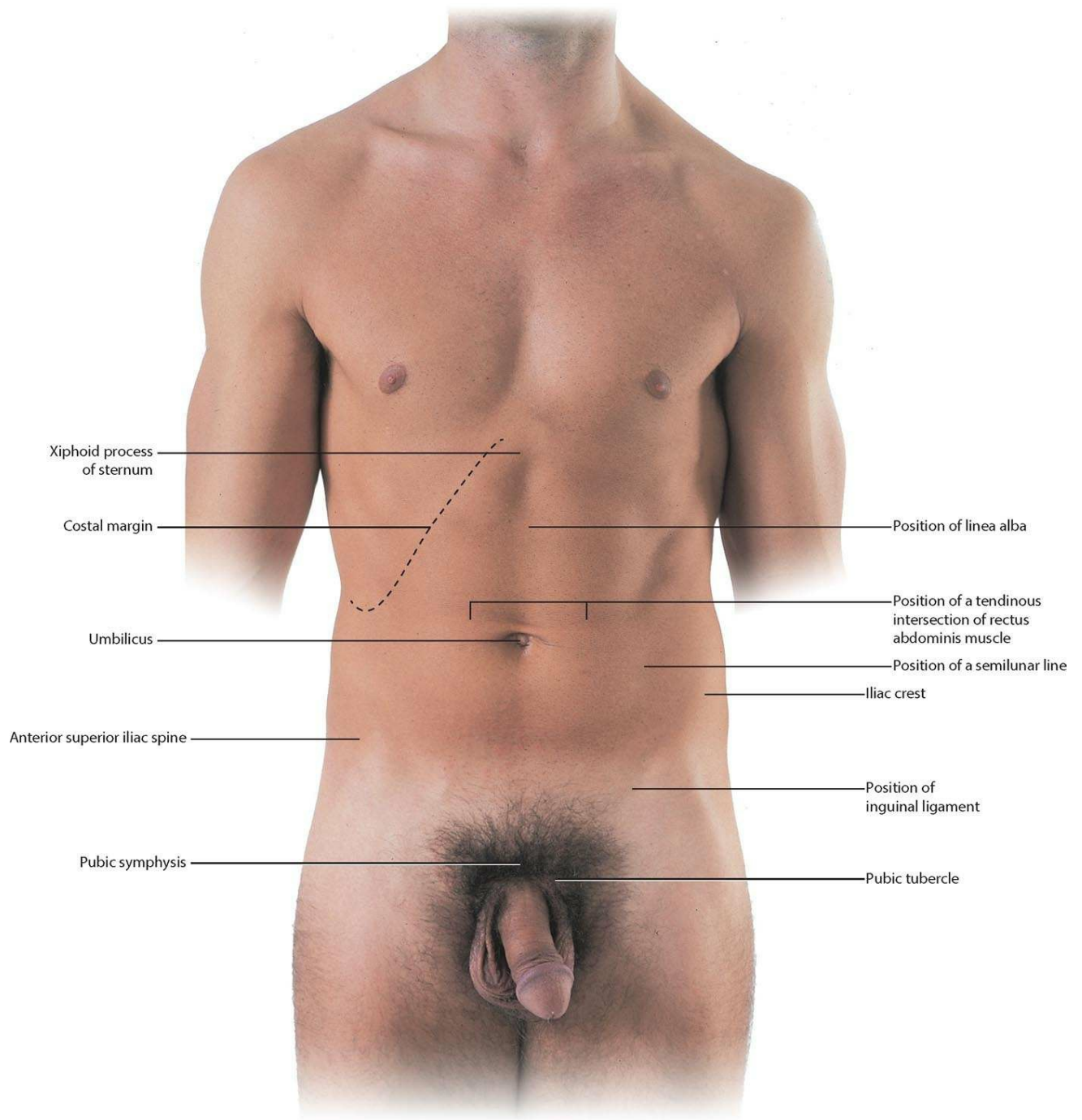
---

# CONTENTS

Surface anatomy	134
Quadrants and regions	135
Abdominal wall	136
Muscles	138
Muscles: rectus sheath	141
Vessels of the abdominal wall	142
Arteries and lymphatics of the abdominal wall	143
Nerves of the abdominal wall	144
Dermatomes and cutaneous nerves	145
Inguinal region	146
Inguinal canal in men	148
Inguinal canal in women	150
Inguinal hernias	152
Anterior abdominal wall	153
Greater omentum	154
Abdominal viscera	155
Peritoneal cavity	156
Abdominal sagittal section	157
Abdominal coronal section	158
Arterial supply of viscera	159
Stomach	160
Spleen	161
Arteries of stomach and spleen	162
Duodenum	164
Small intestine	166
Large intestine	168
Ileocecal junction	170
Gastrointestinal tract: imaging	171
Mesenteric arteries	172

Liver [174](#)  
Vessels of the liver [176](#)  
Segments of the liver [177](#)  
Pancreas and gallbladder [178](#)  
Vasculature of pancreas and duodenum [181](#)  
Venous drainage of viscera [182](#)  
Portosystemic anastomoses [184](#)  
Posterior wall [185](#)  
Vessels of the posterior wall [186](#)  
Diaphragm [187](#)  
Kidneys [188](#)  
Gross structure of kidneys [190](#)  
Kidneys: imaging [191](#)  
Renal vasculature [192](#)  
Branches of the abdominal aorta [194](#)  
Inferior vena cava [195](#)  
Abdominal aorta and inferior vena cava: imaging [196](#)  
Lumbar plexus [198](#)  
Lumbar plexus: cutaneous distribution [199](#)  
Lymphatics [200](#)  
Abdominal innervation [201](#)  
Splanchnic nerves [202](#)  
Visceral efferent (motor) innervation diagram [203](#)  
Visceral afferent (sensory) innervation and referred pain diagram [204](#)  
Kidney and ureter visceral afferent (sensory) diagram [206](#)  
Tables [208](#)

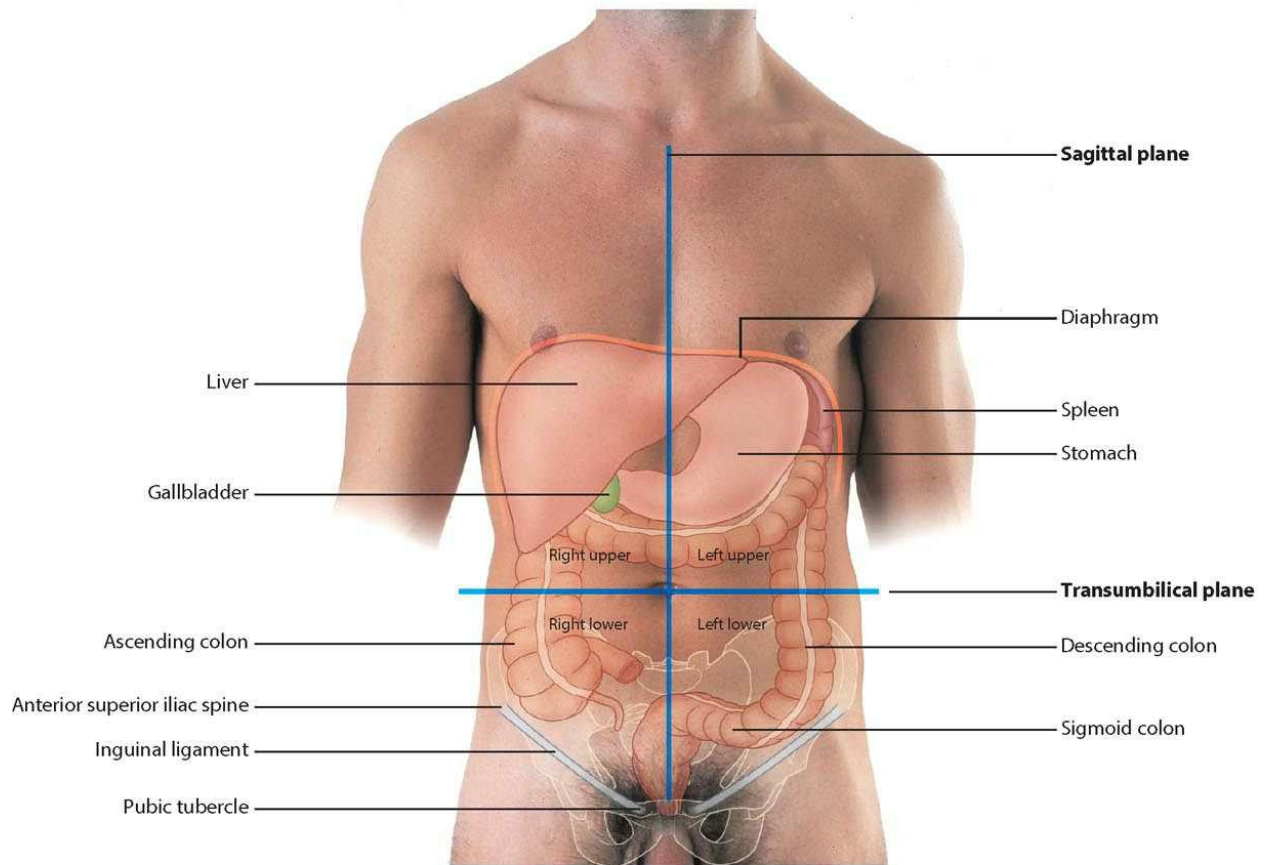
# Surface anatomy



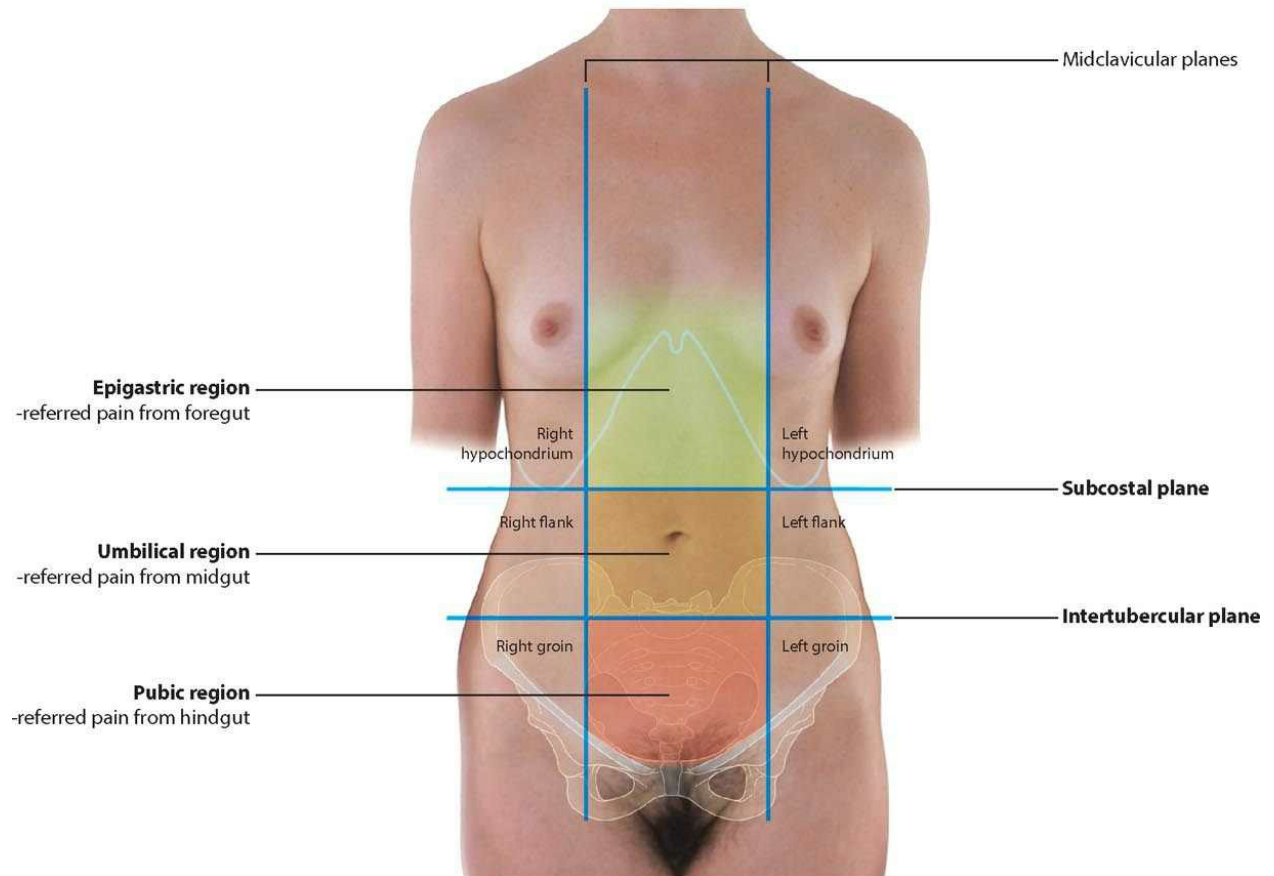
**Anterior abdominal wall surface anatomy**



# Quadrants and regions



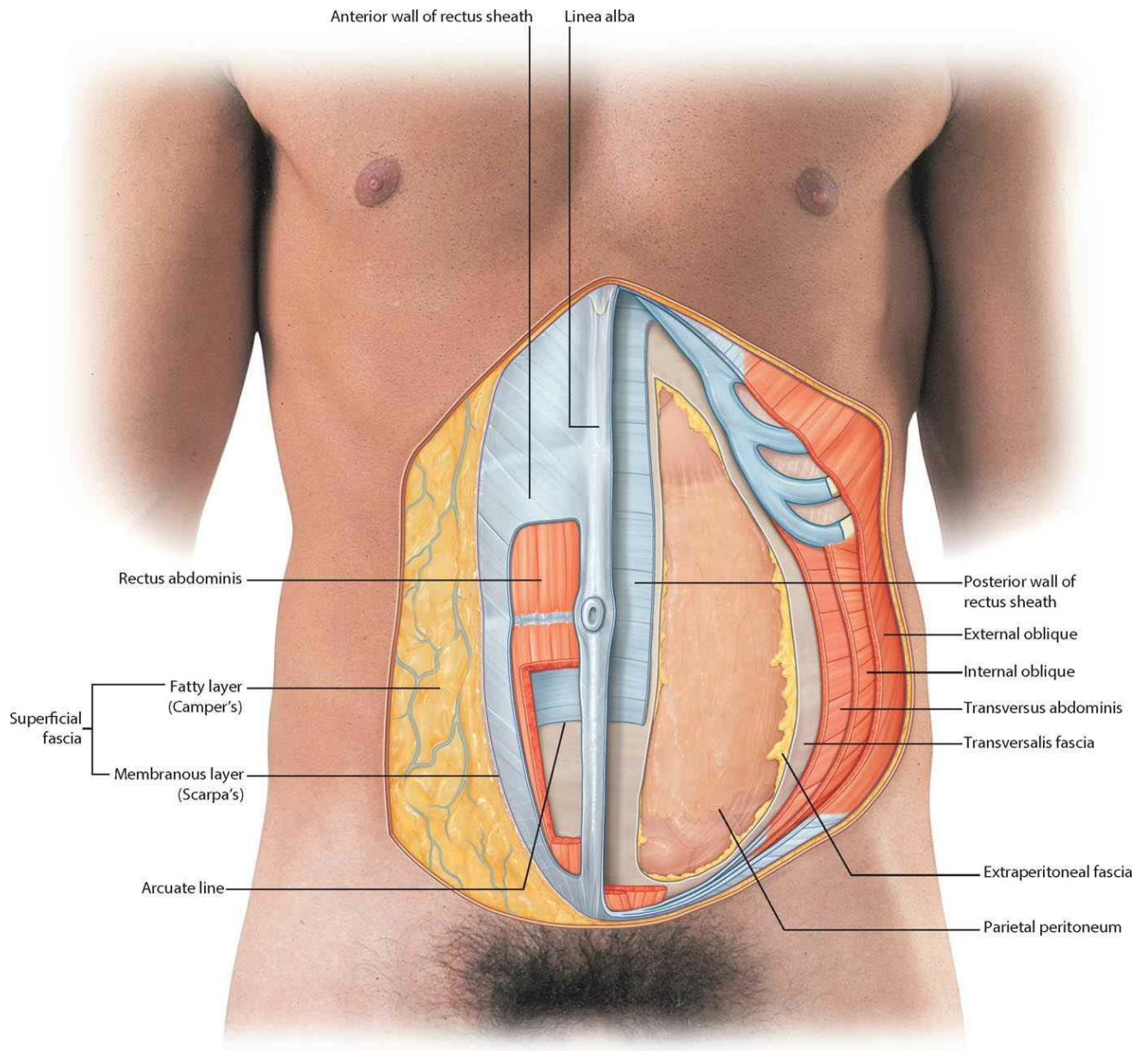
**Abdominal quadrants and the positions of major viscera**



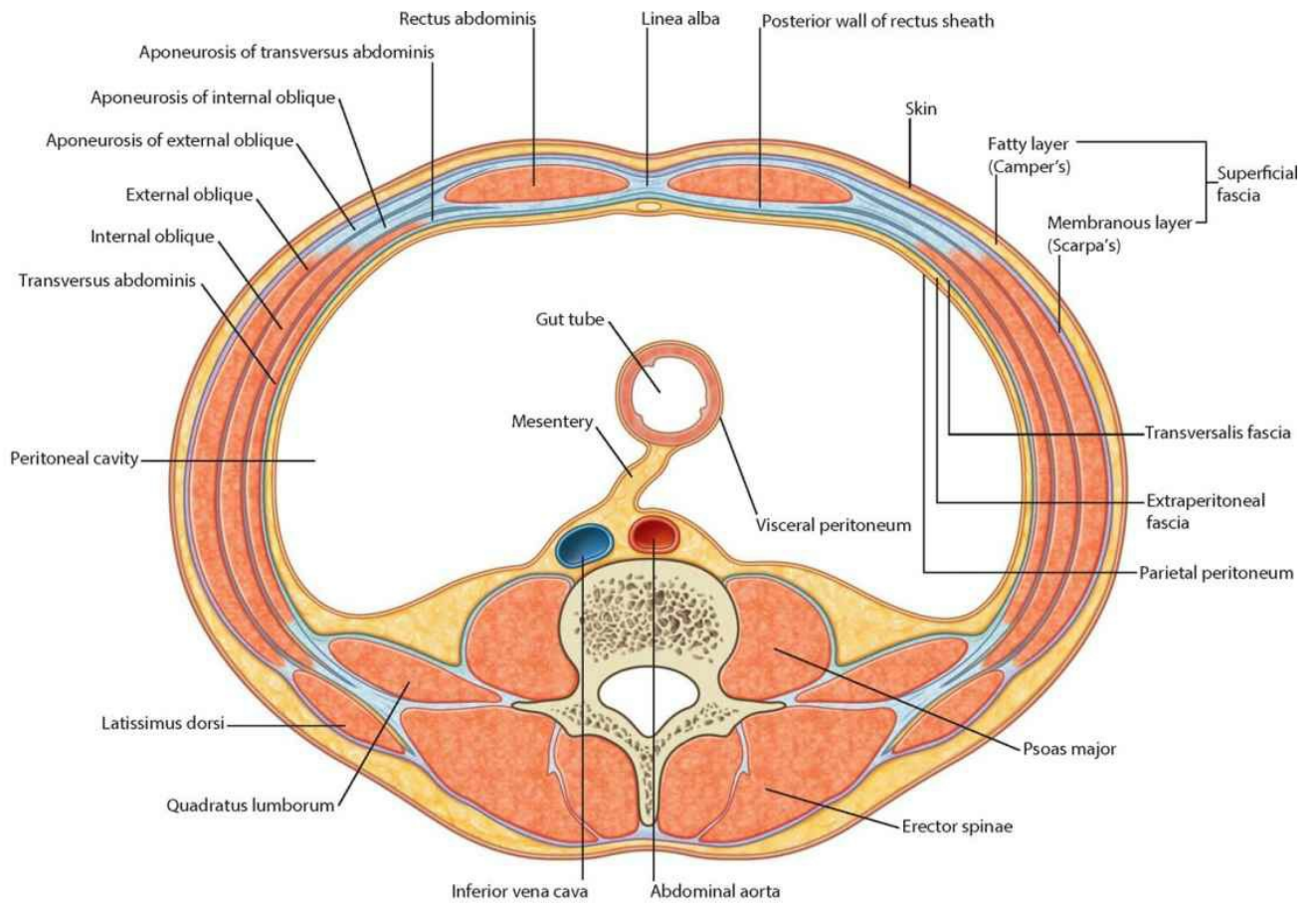
**The nine regions of the abdomen**



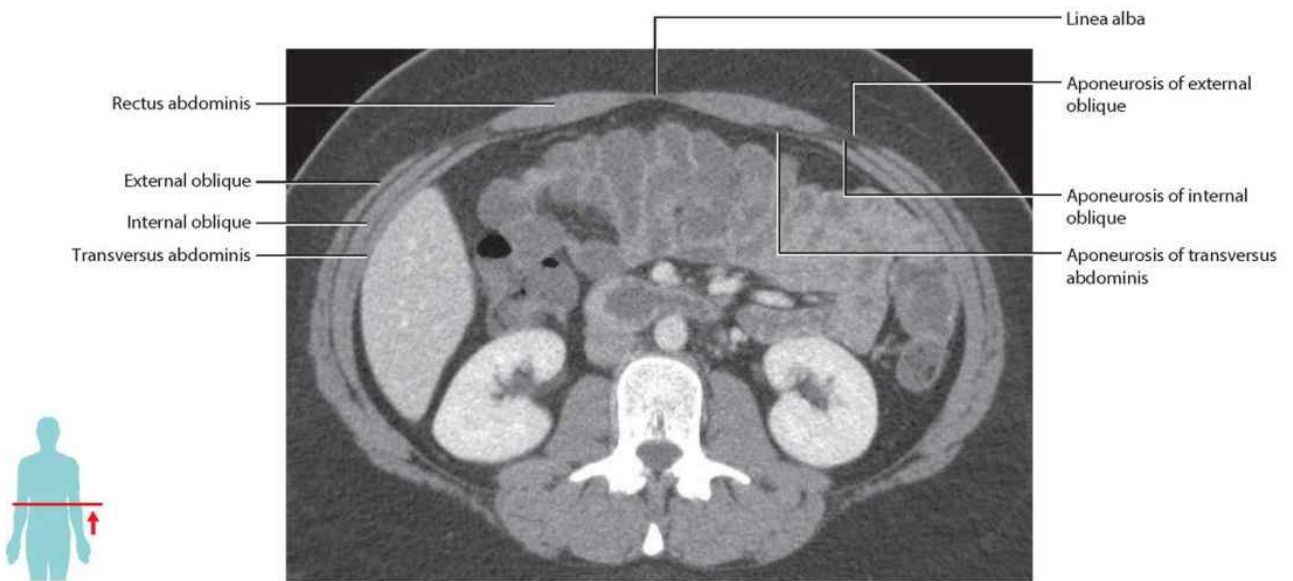
# Abdominal wall



**Layers of the abdominal wall**

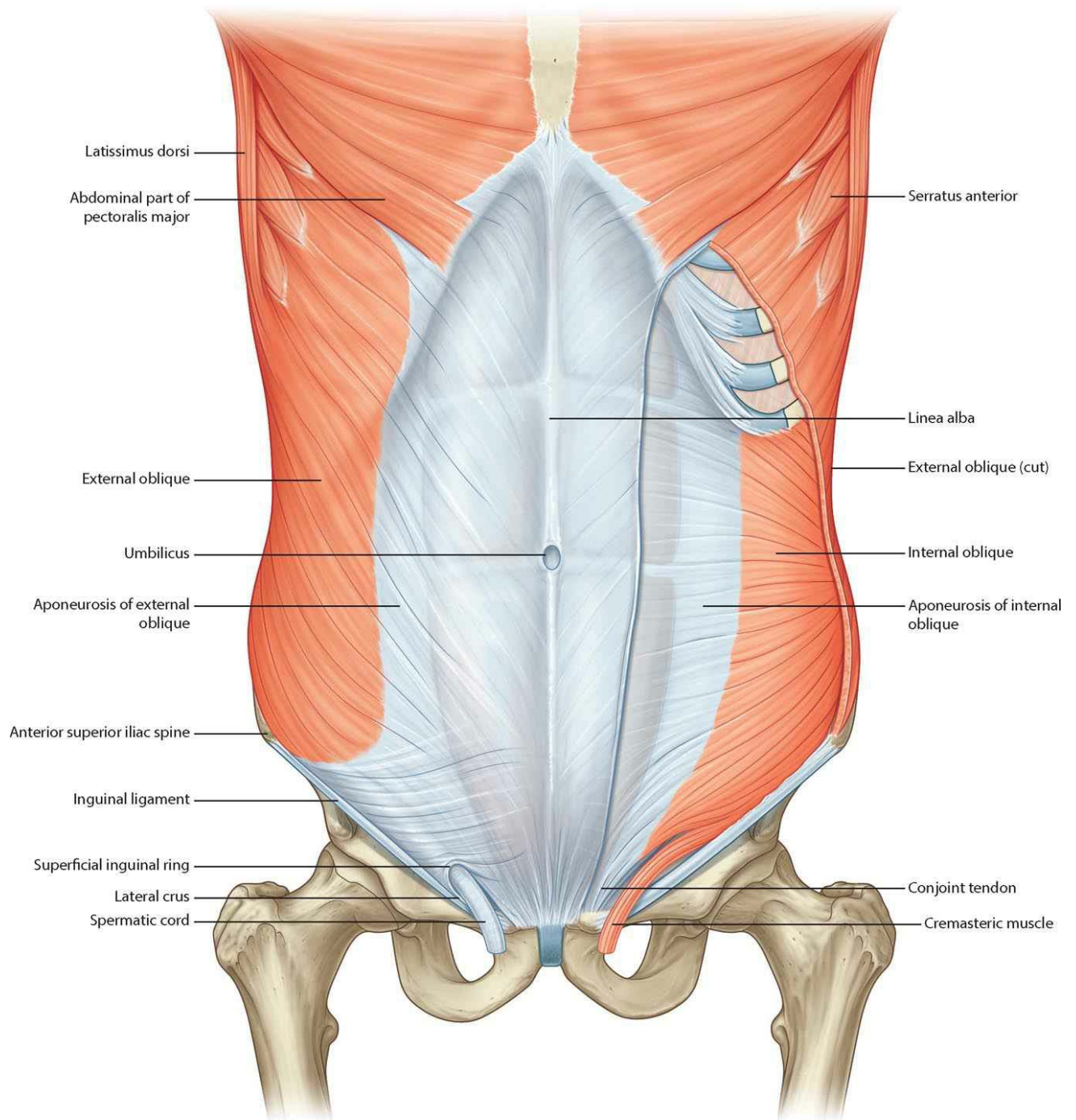


**Transverse section showing the layers of the abdominal wall (above umbilicus)**



**Layers of the abdominal wall.**  
CT image, with contrast, in axial plane

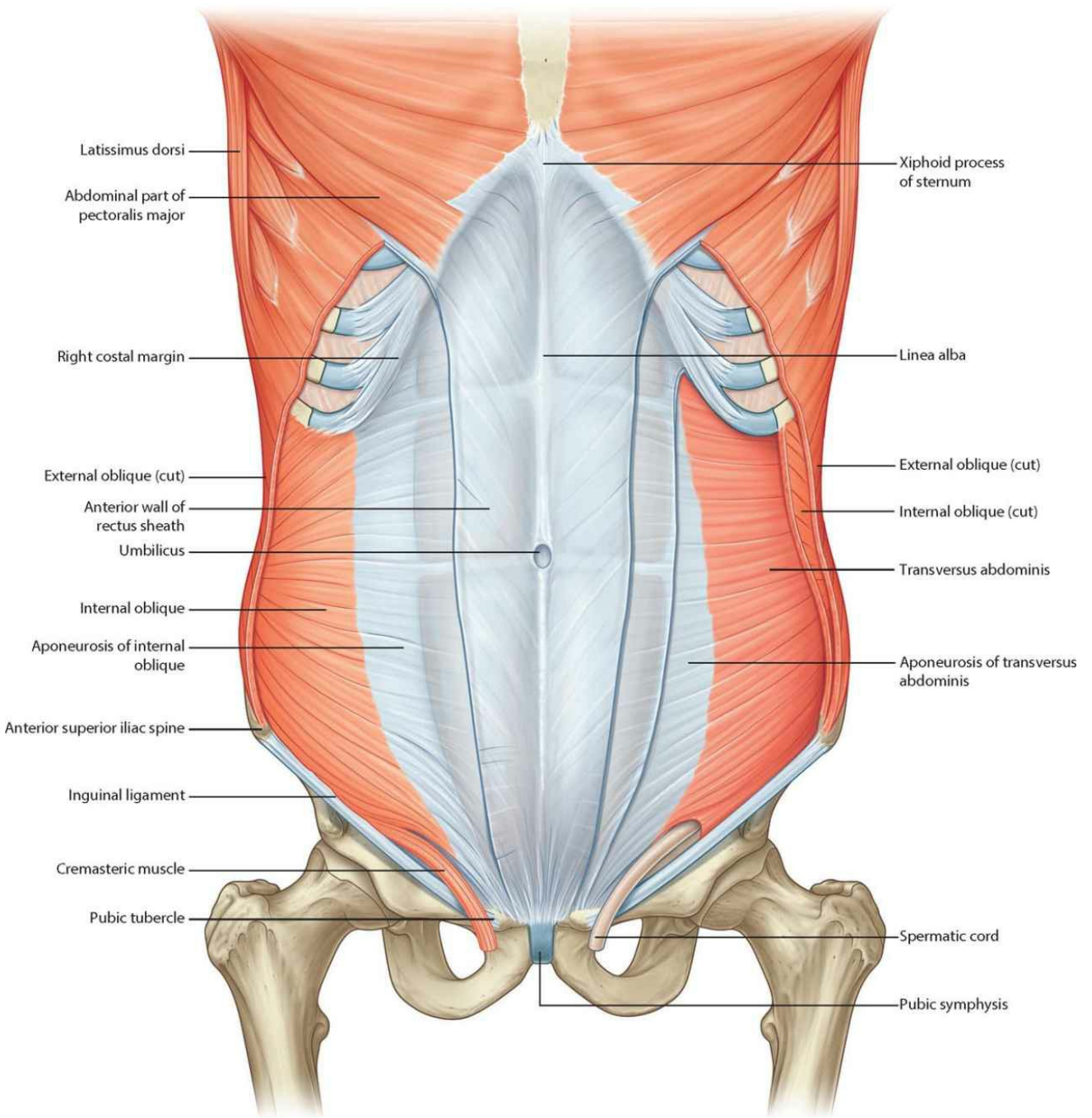
# Muscles



**External and internal oblique muscles**

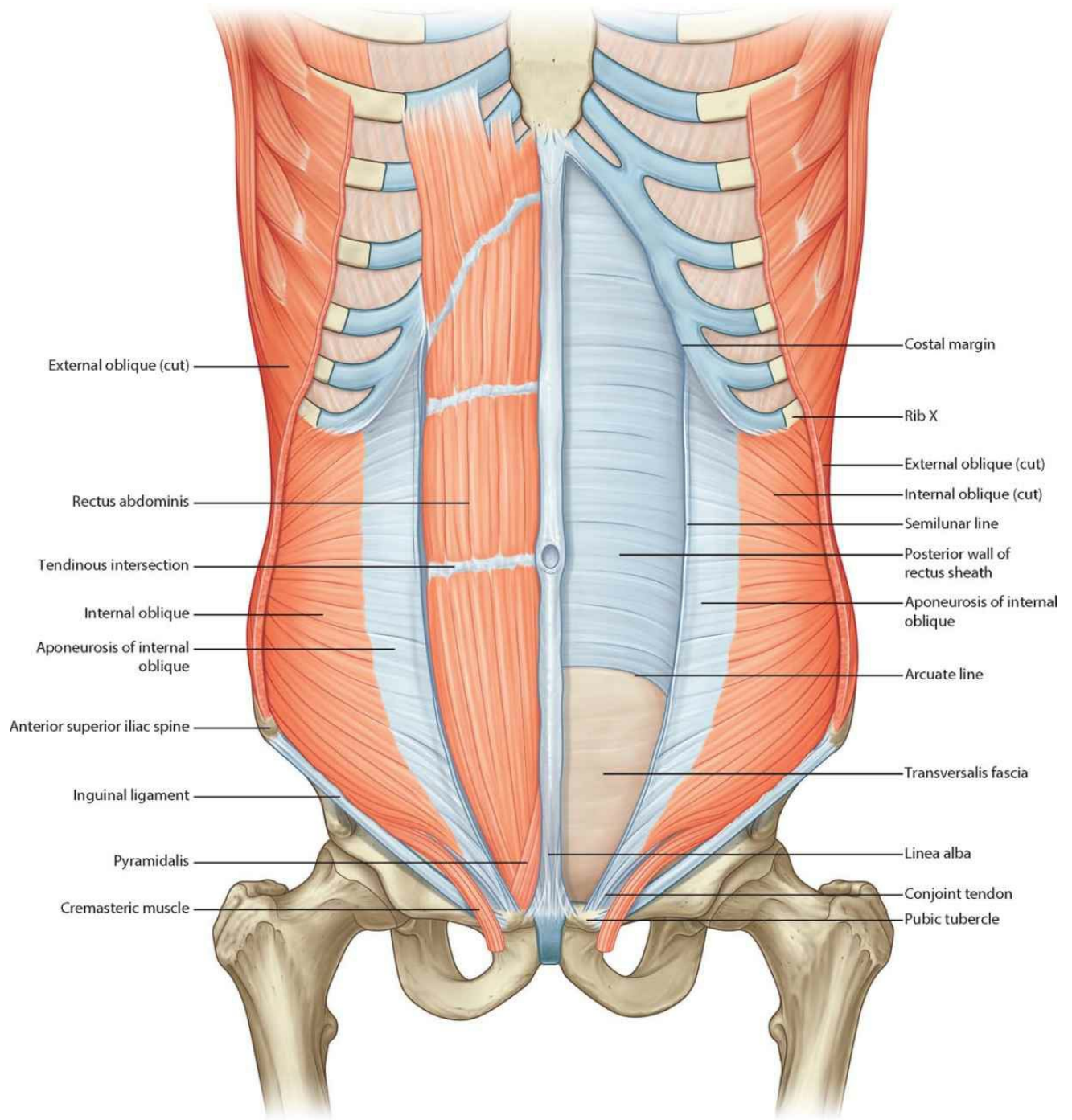






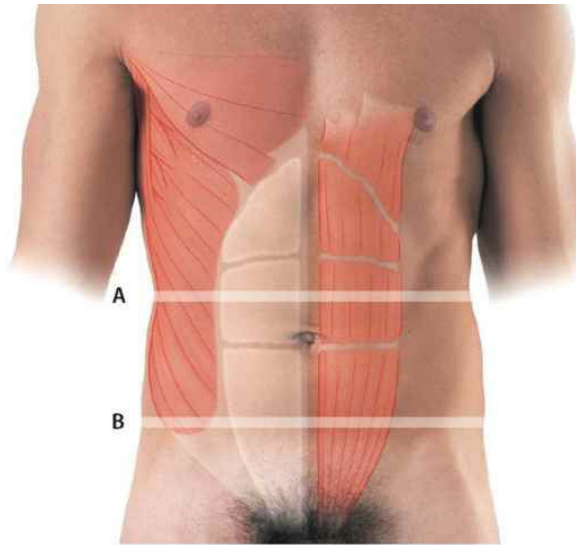
**Internal oblique and transversus abdominis muscles**





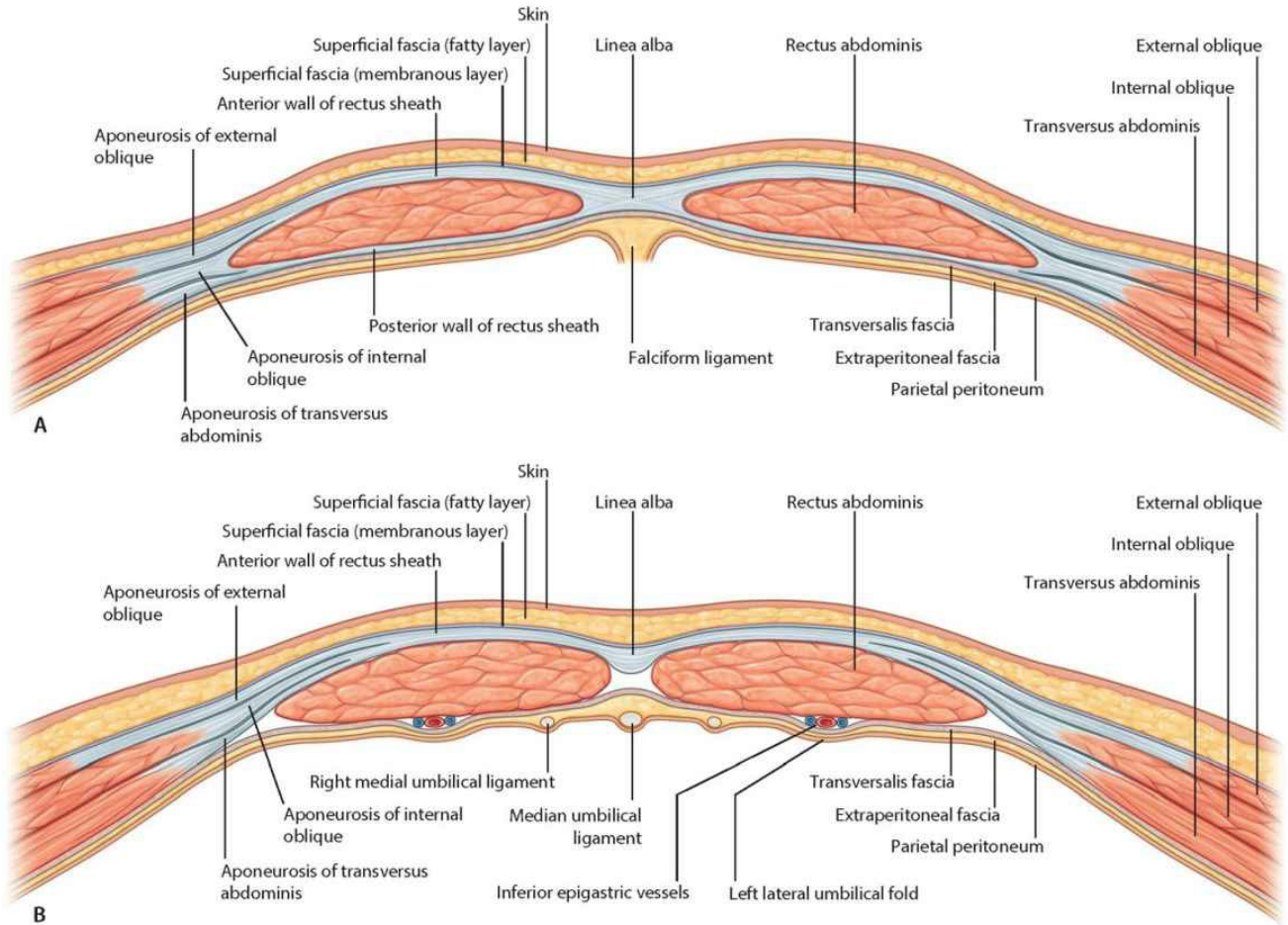
**Rectus abdominis and pyramidalis muscles**

## **Muscles: rectus sheath**

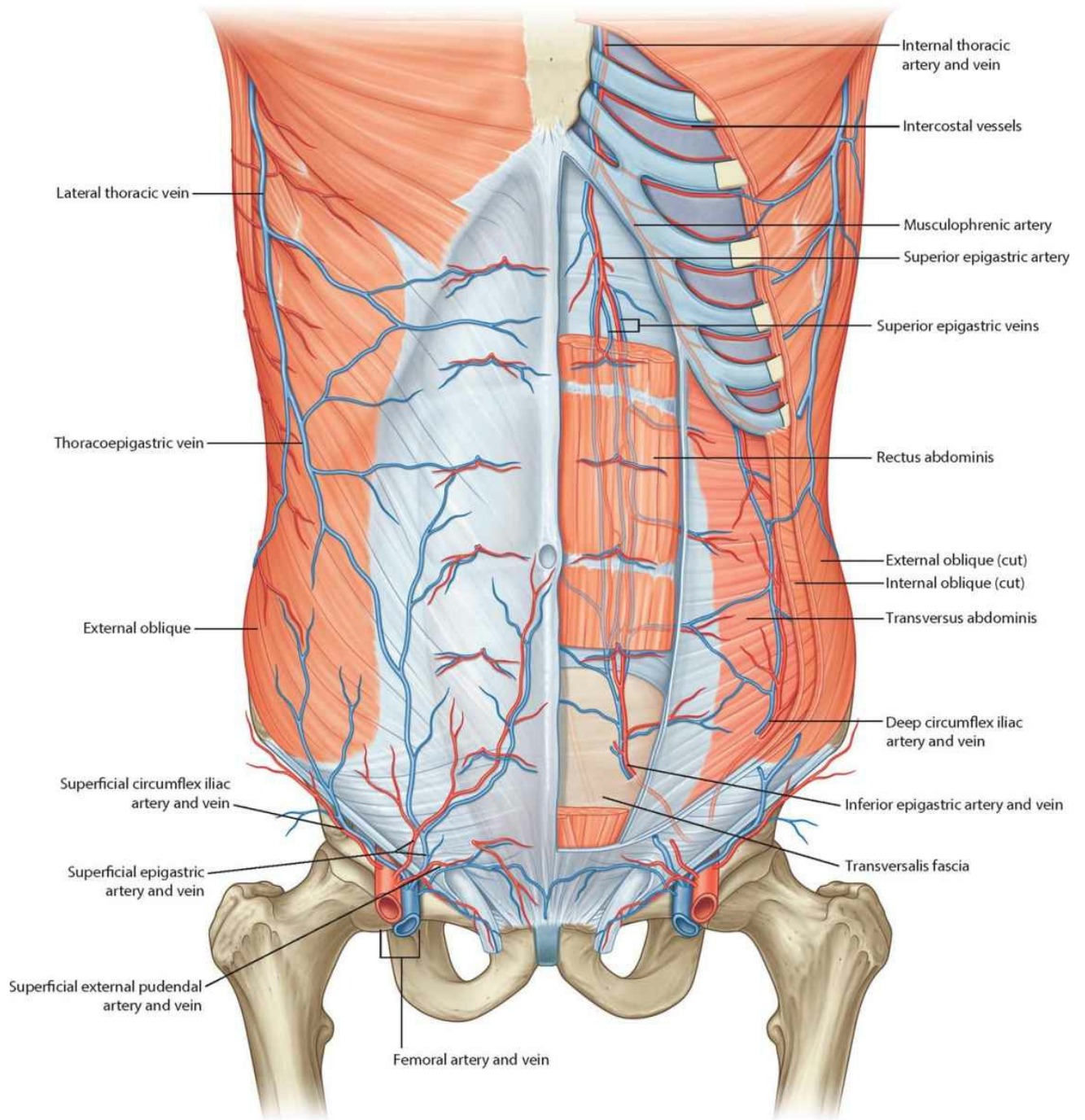


**Organization of the rectus sheath.**

- A.** Transverse section through the upper three quarters of the rectus sheath
- B.** Transverse section through the lower one quarter of the rectus sheath



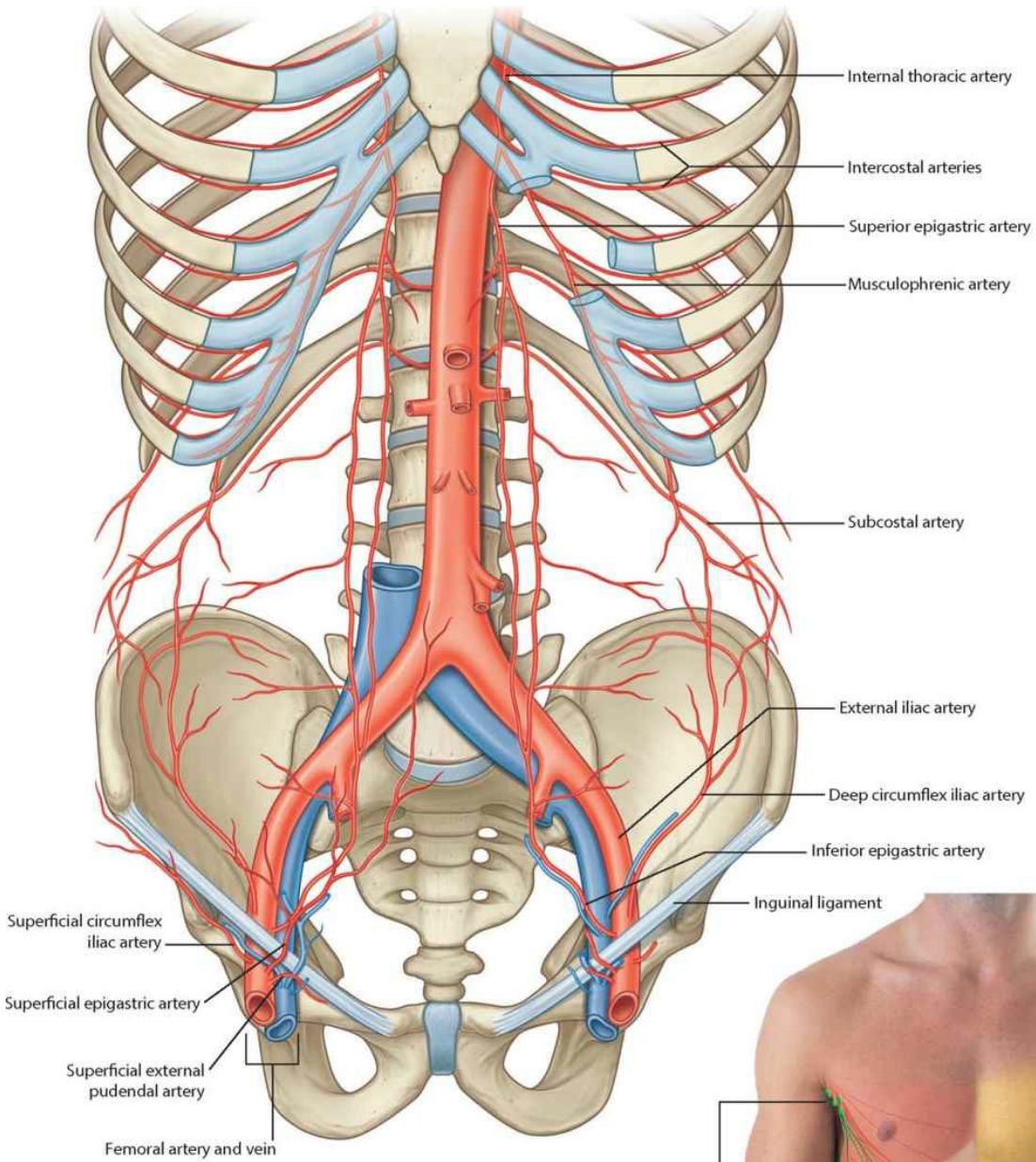
# Vessels of the abdominal wall



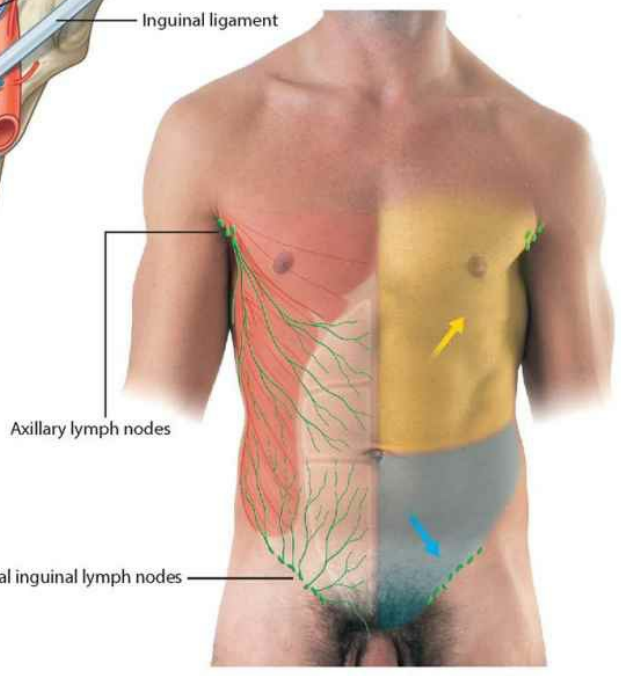
**Vasculature of the anterior abdominal wall**



# Arteries and lymphatics of the abdominal wall

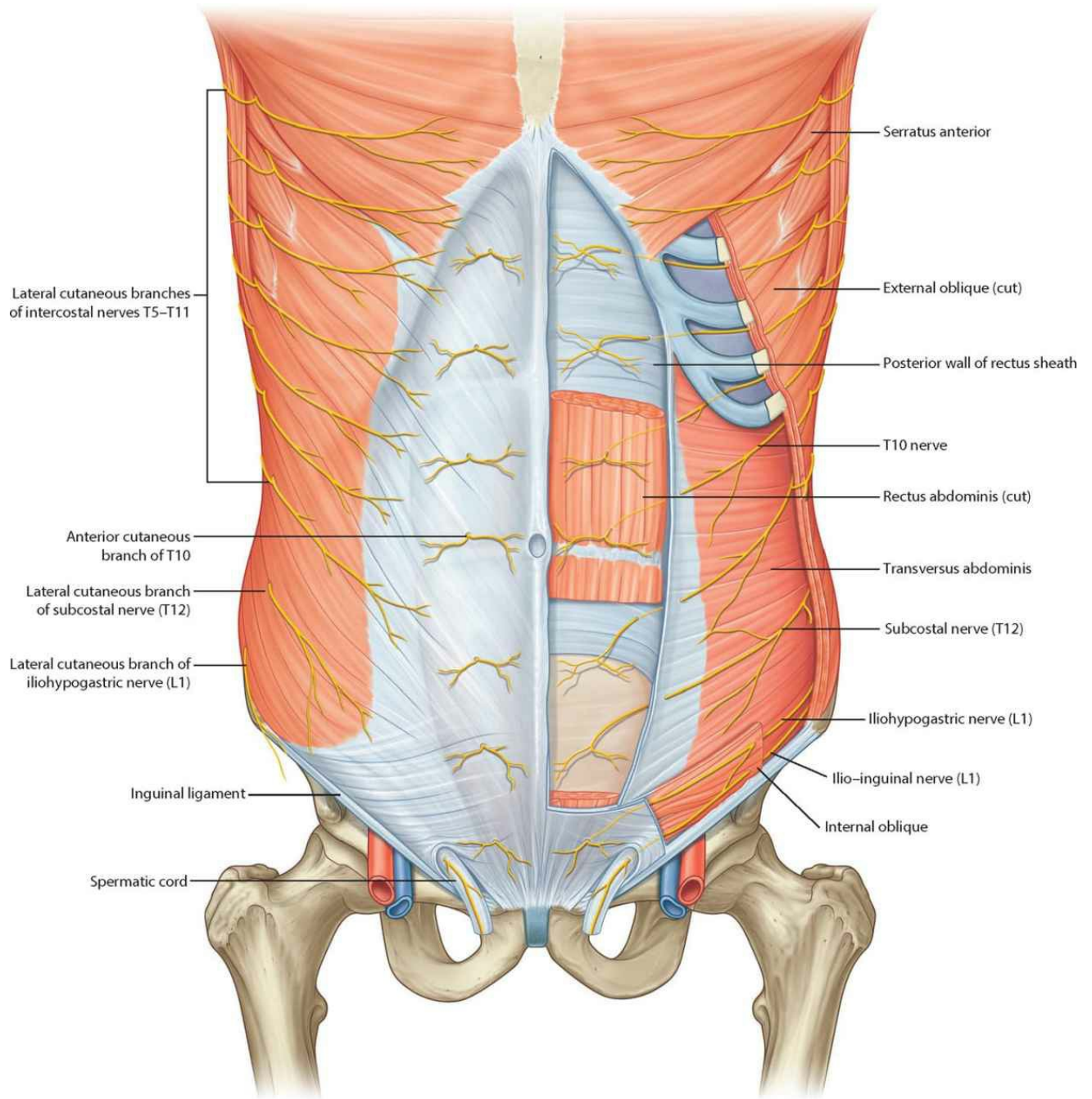


**Arteries of the anterior abdominal wall**



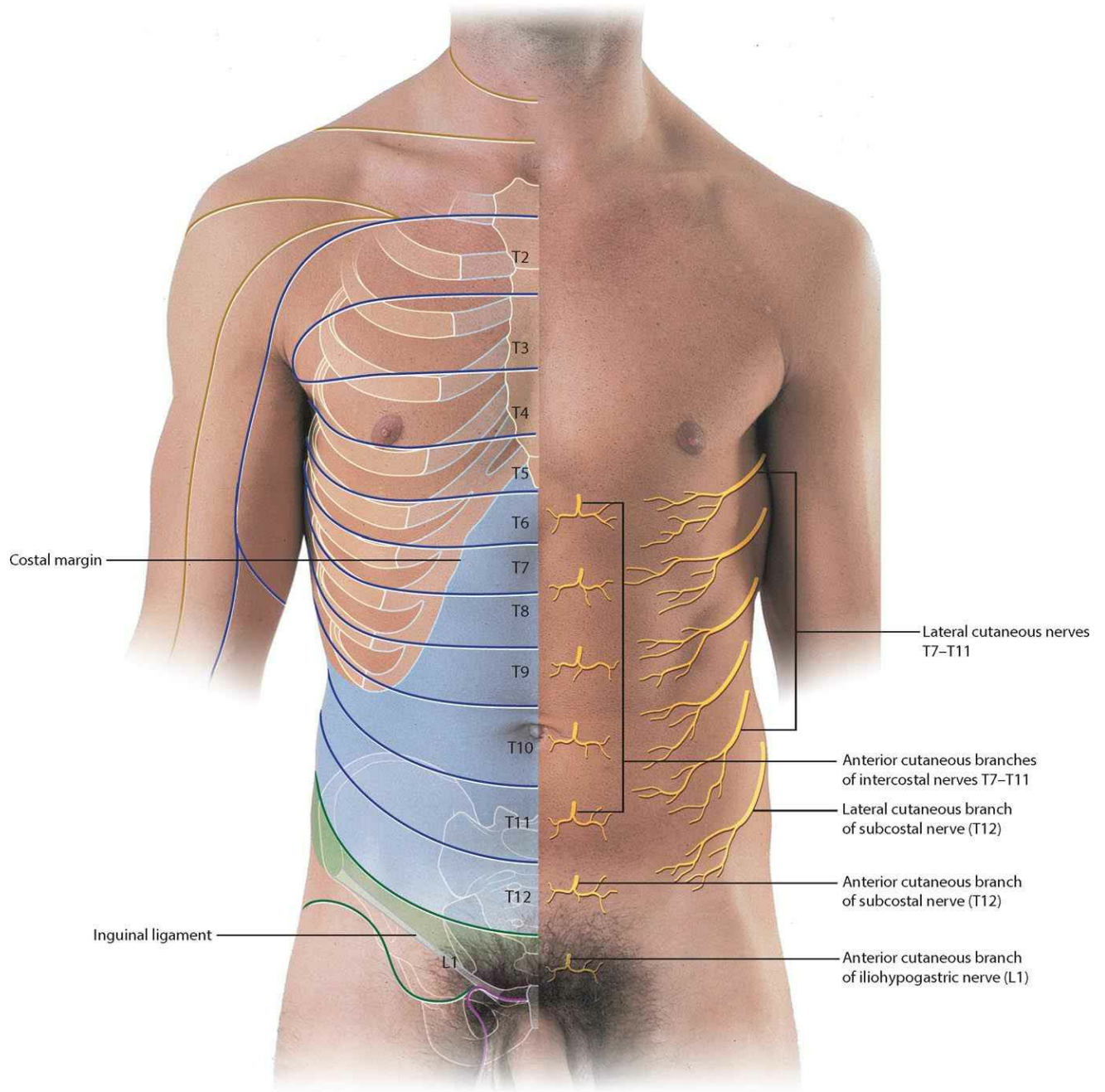
**Superficial lymphatic drainage of the anterolateral abdominal wall**

# Nerves of the abdominal wall



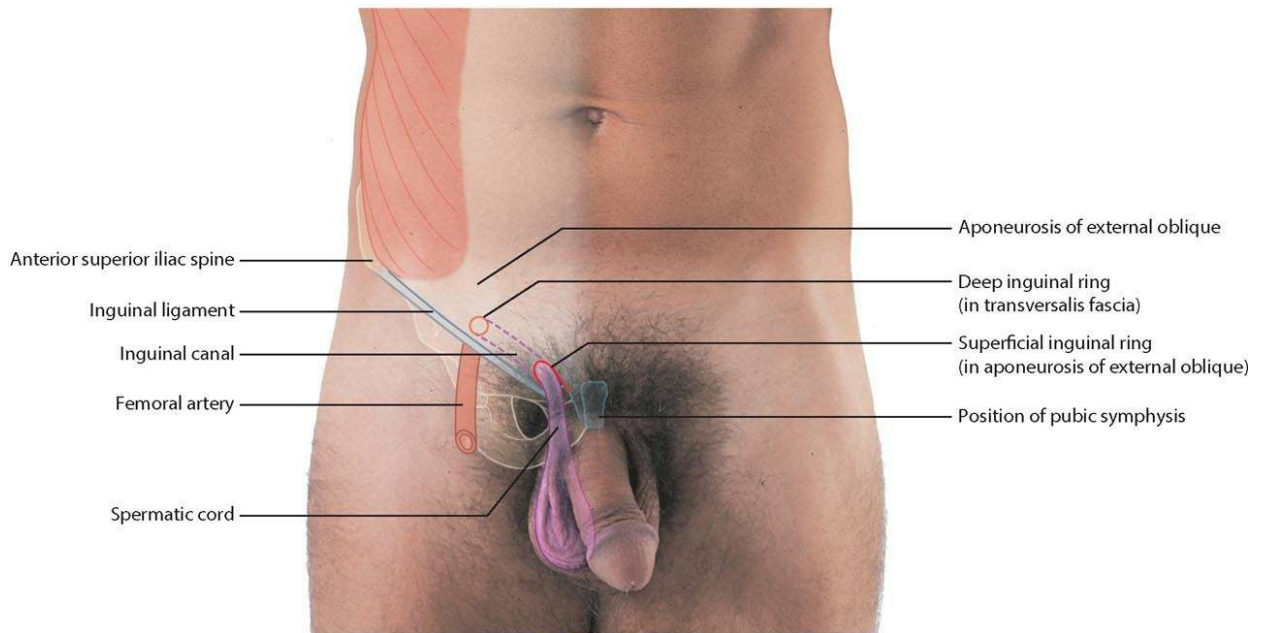
**Nerves of the anterolateral abdominal wall**

# Dermatomes and cutaneous nerves

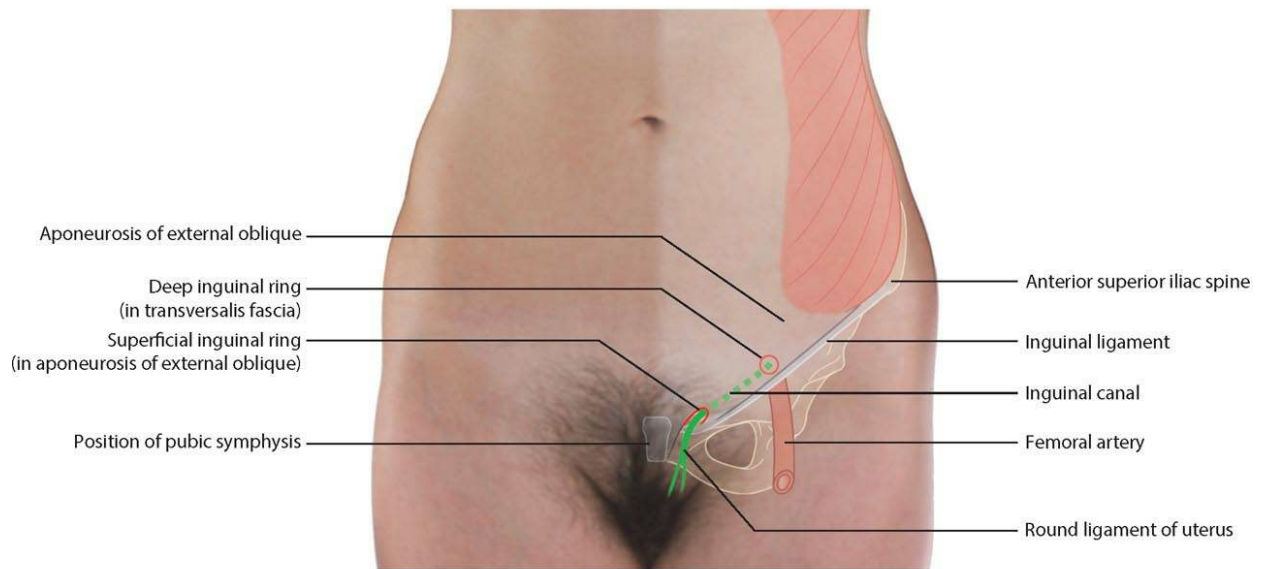


**Dermatomes and cutaneous nerves of the anterolateral abdominal wall**

# Inguinal region



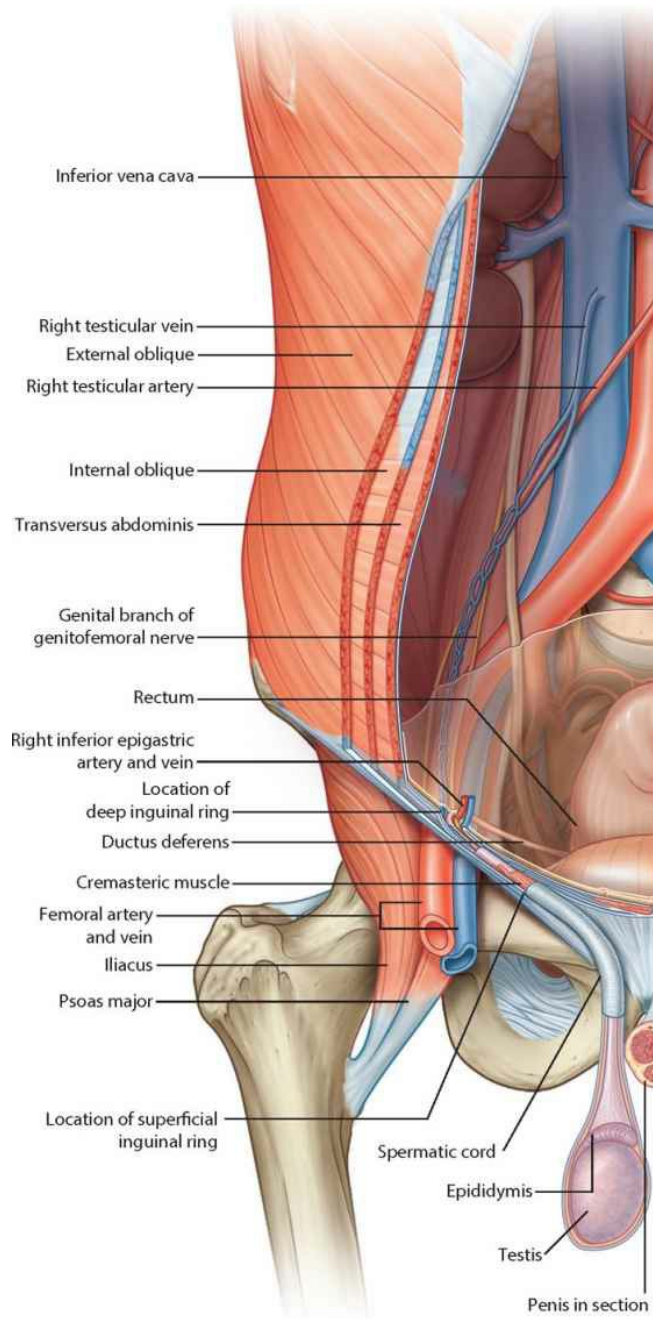
Inguinal region in a man



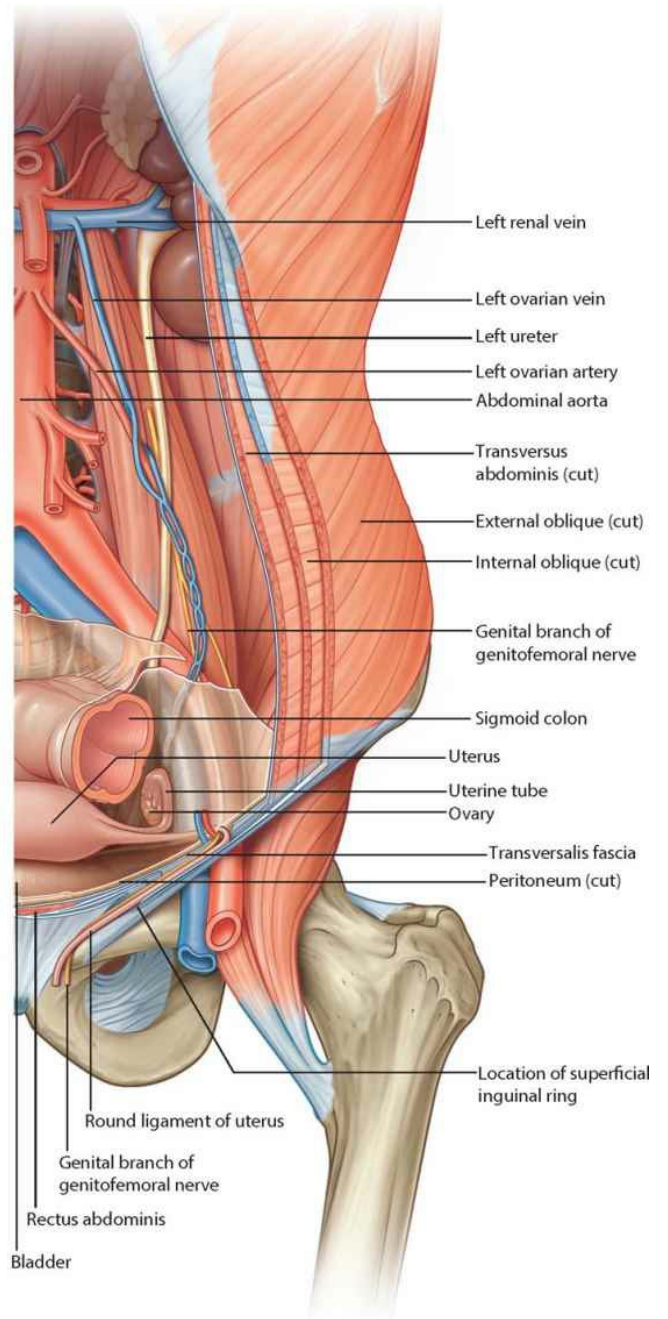
Inguinal region in a woman





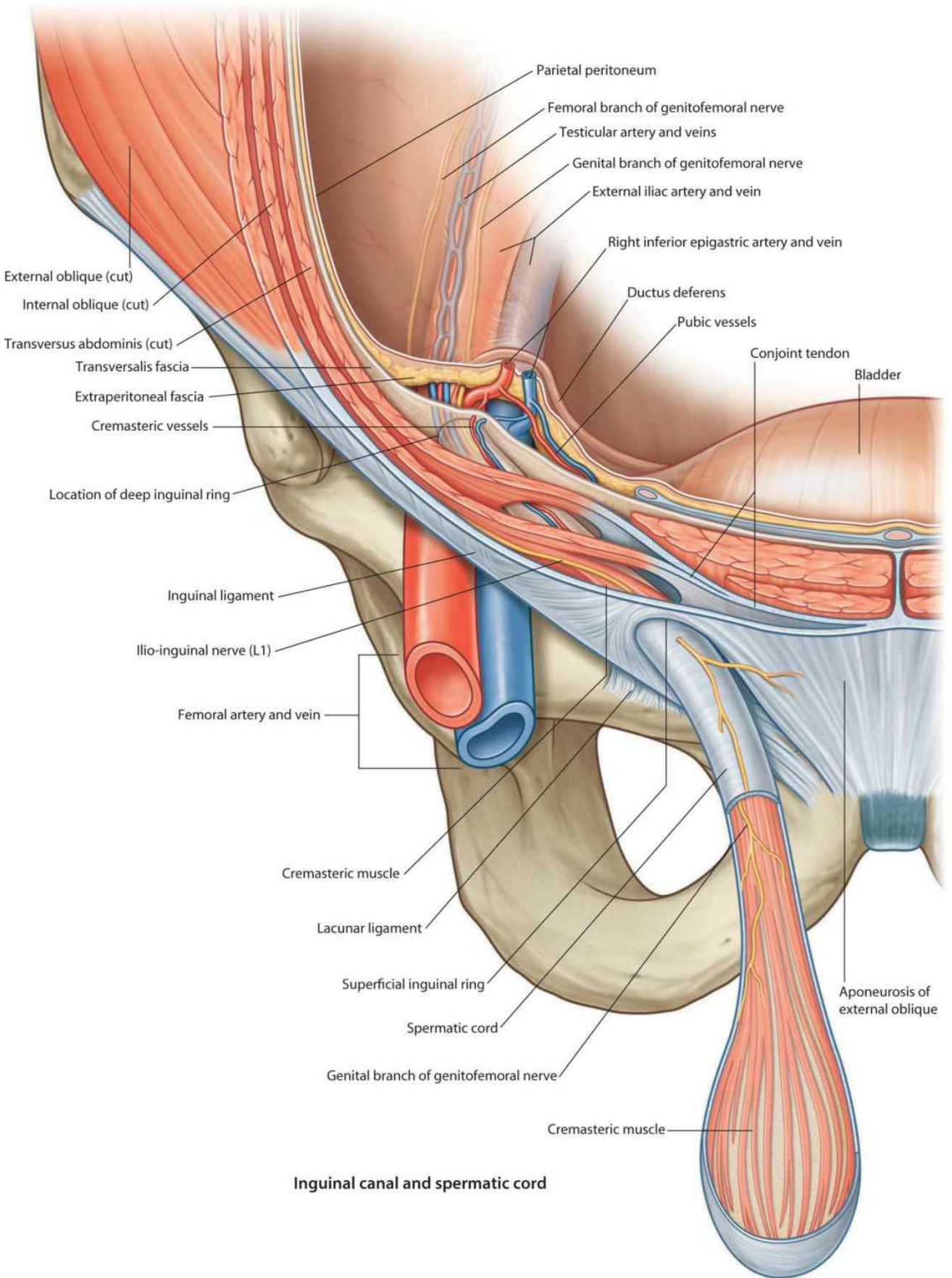


**Inguinal region in men**

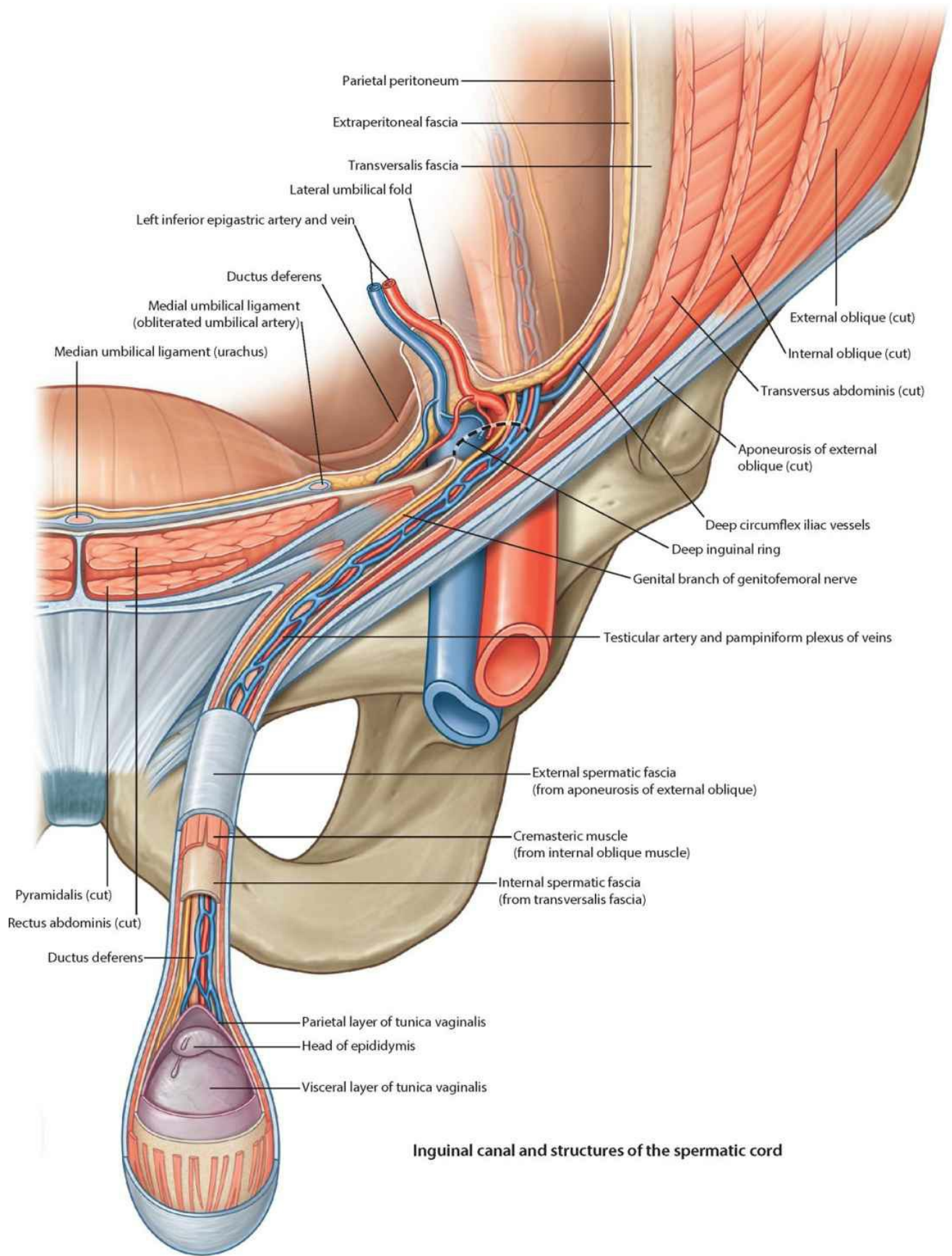


**Inguinal region in women**

# Inguinal canal in men

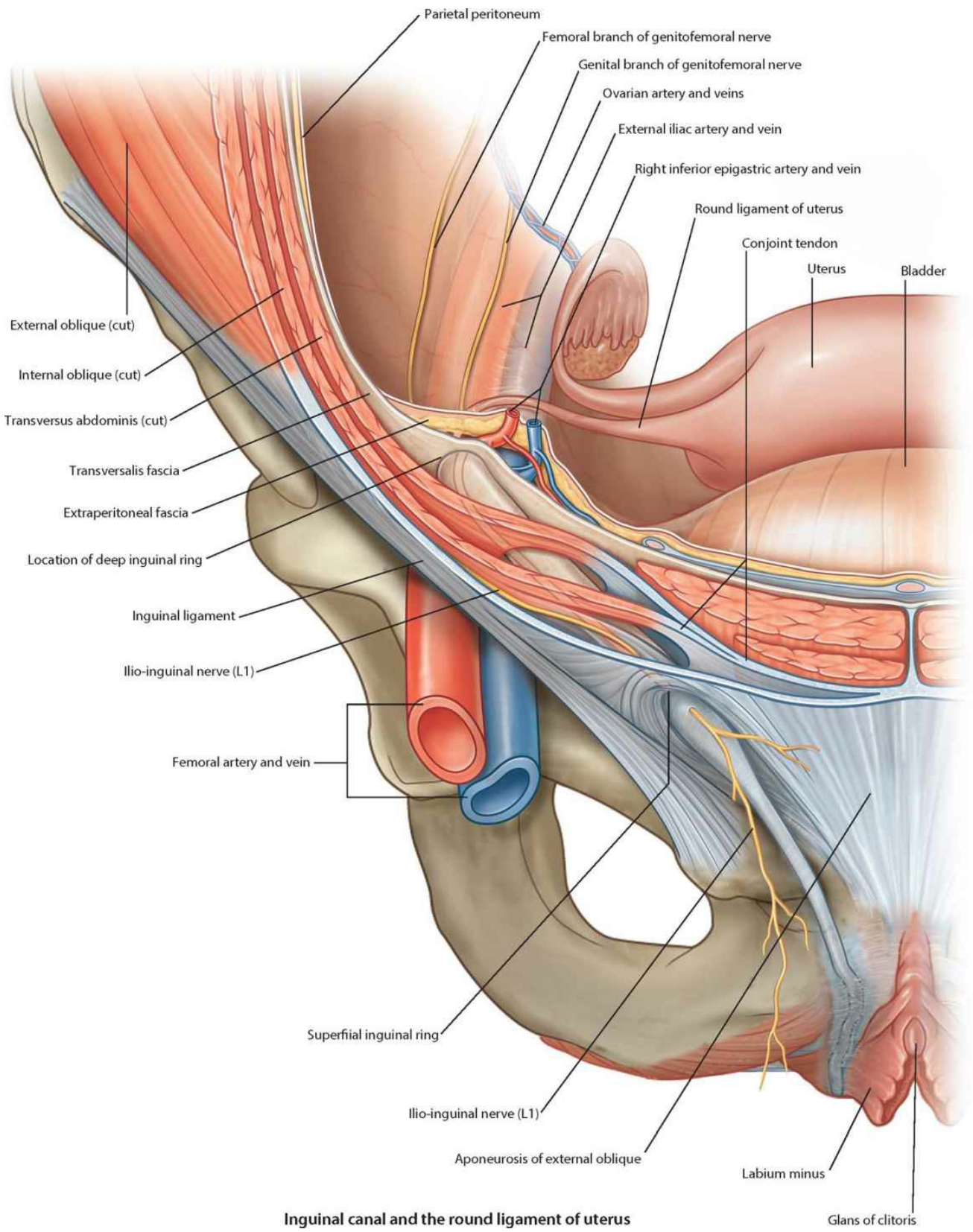






**Inguinal canal and structures of the spermatic cord**

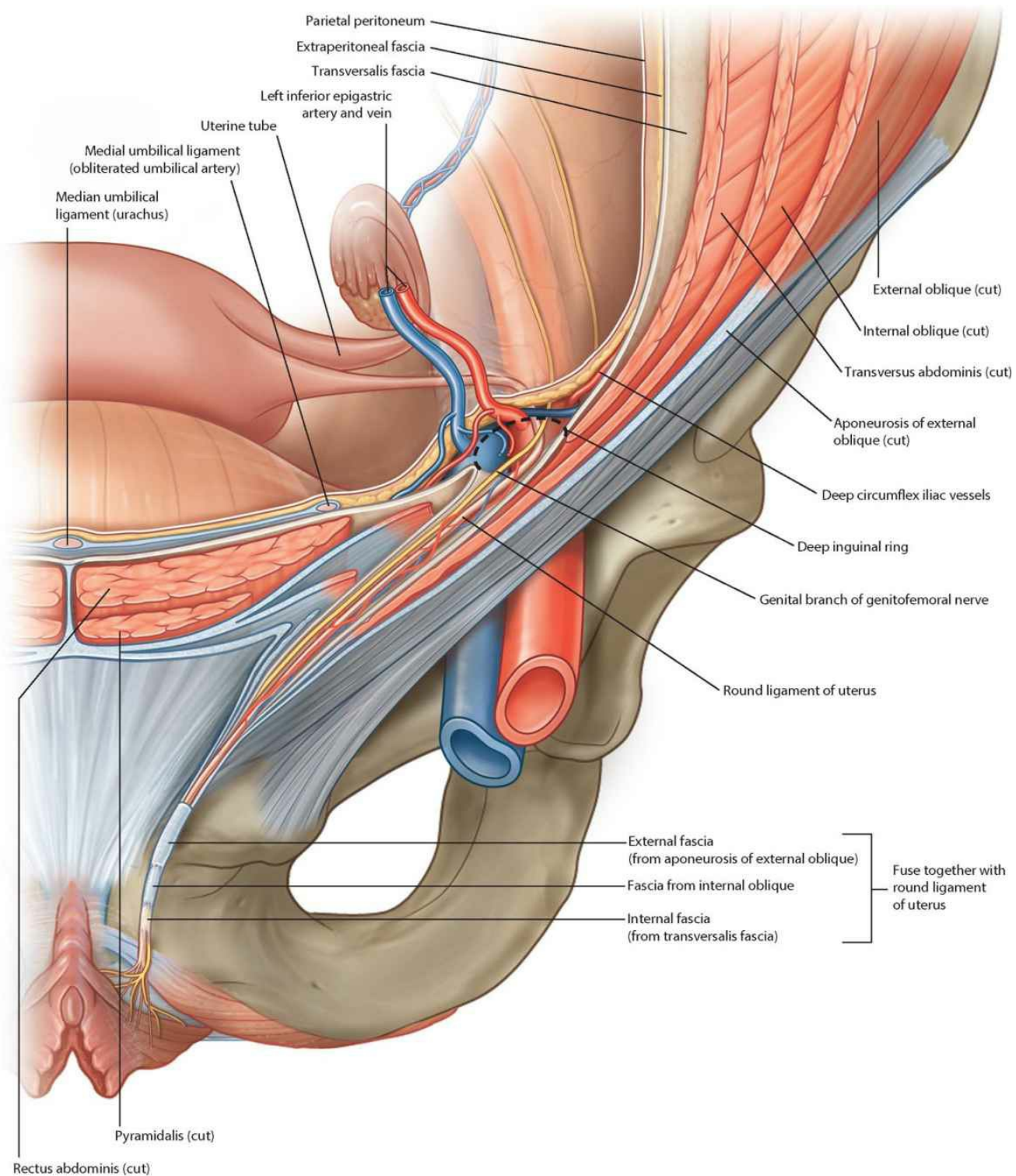
# Inguinal canal in women



**Inguinal canal and the round ligament of uterus**

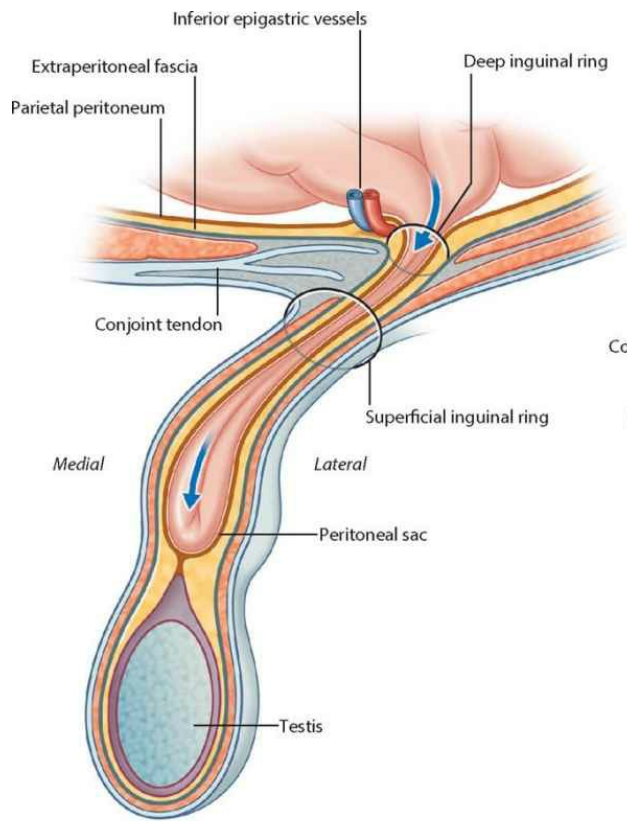




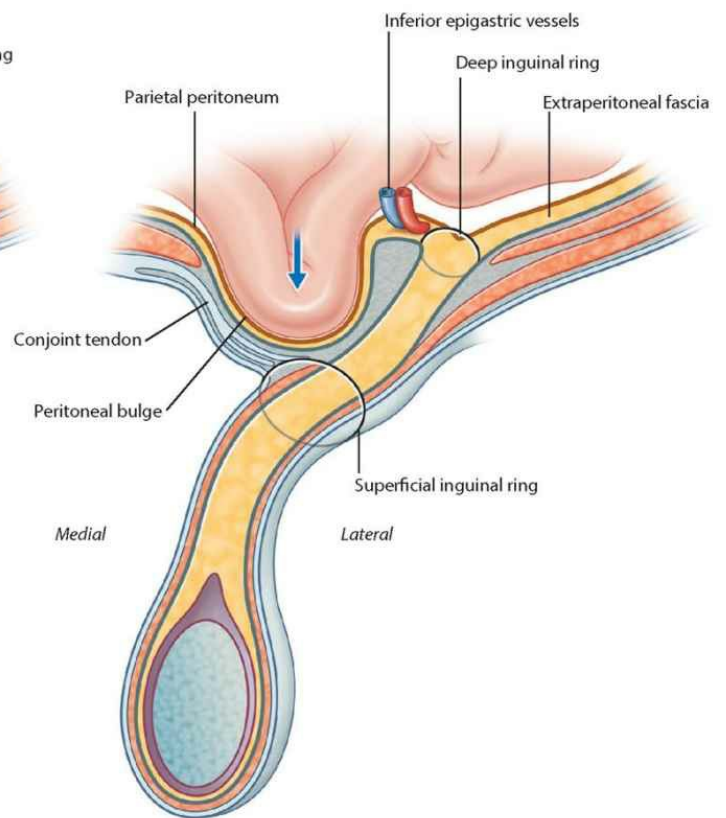


Inguinal canal and structures within

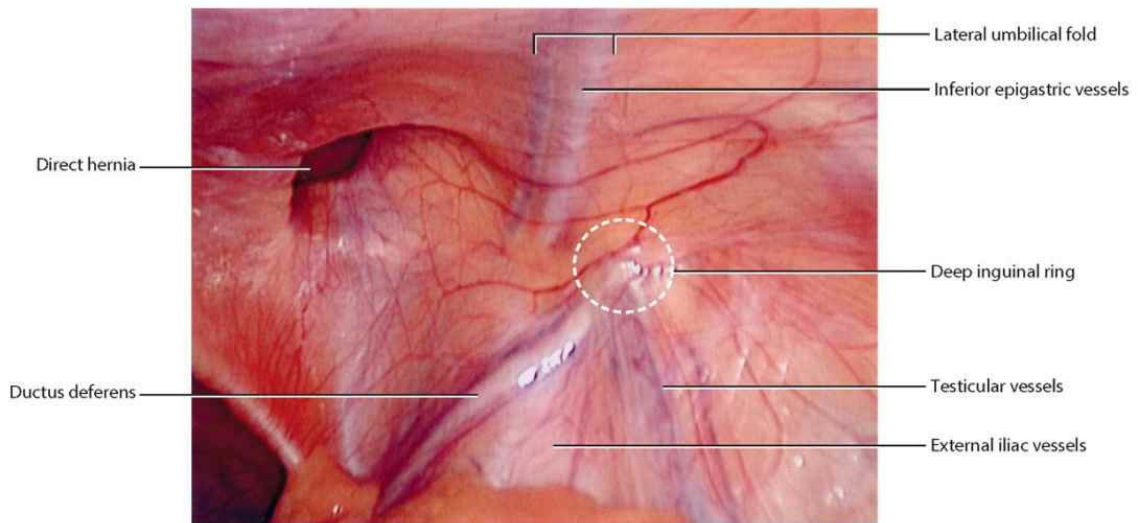
# Inguinal hernias



**Indirect inguinal hernia**



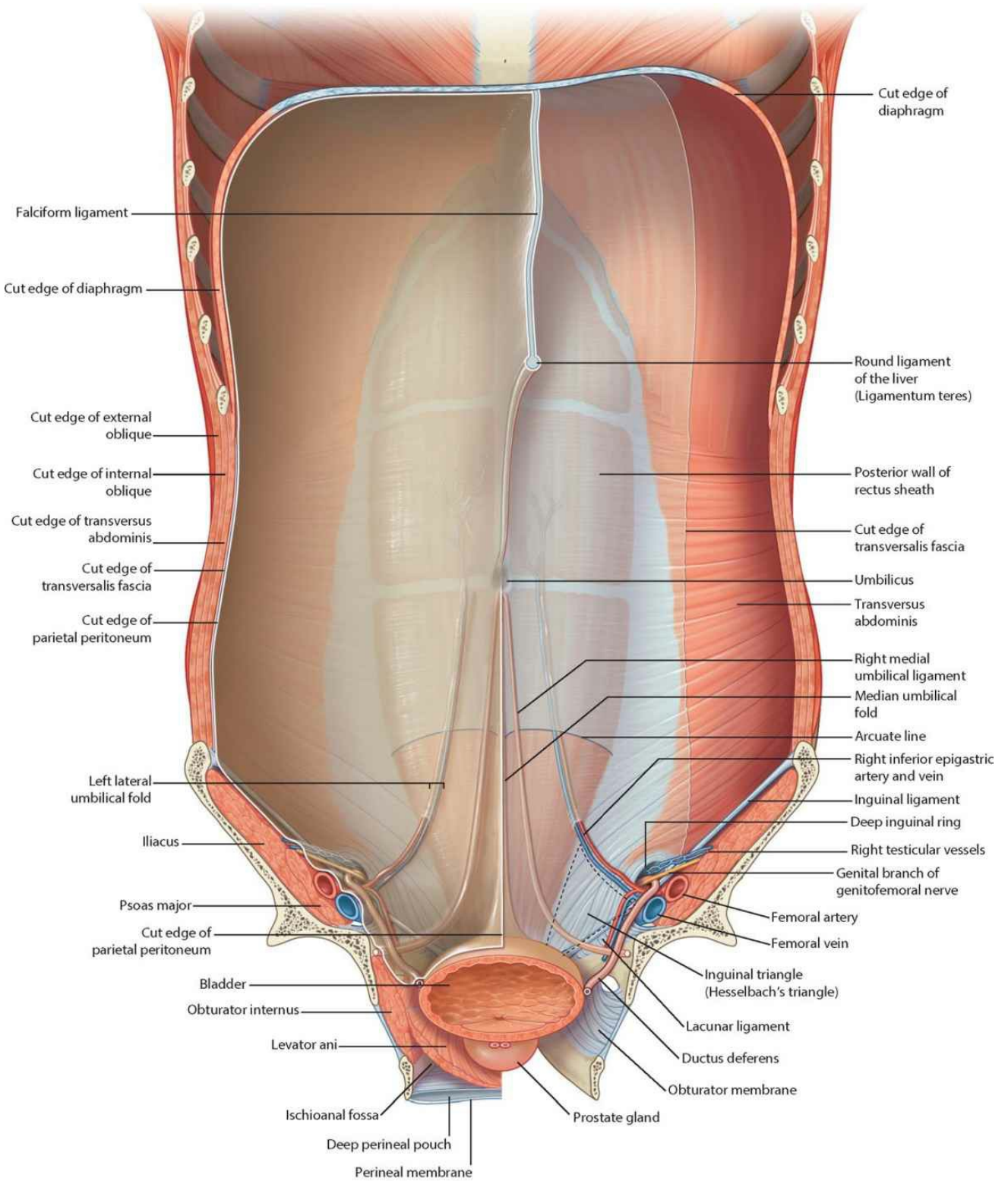
**Direct inguinal hernia**



**Right inguinal triangle.**

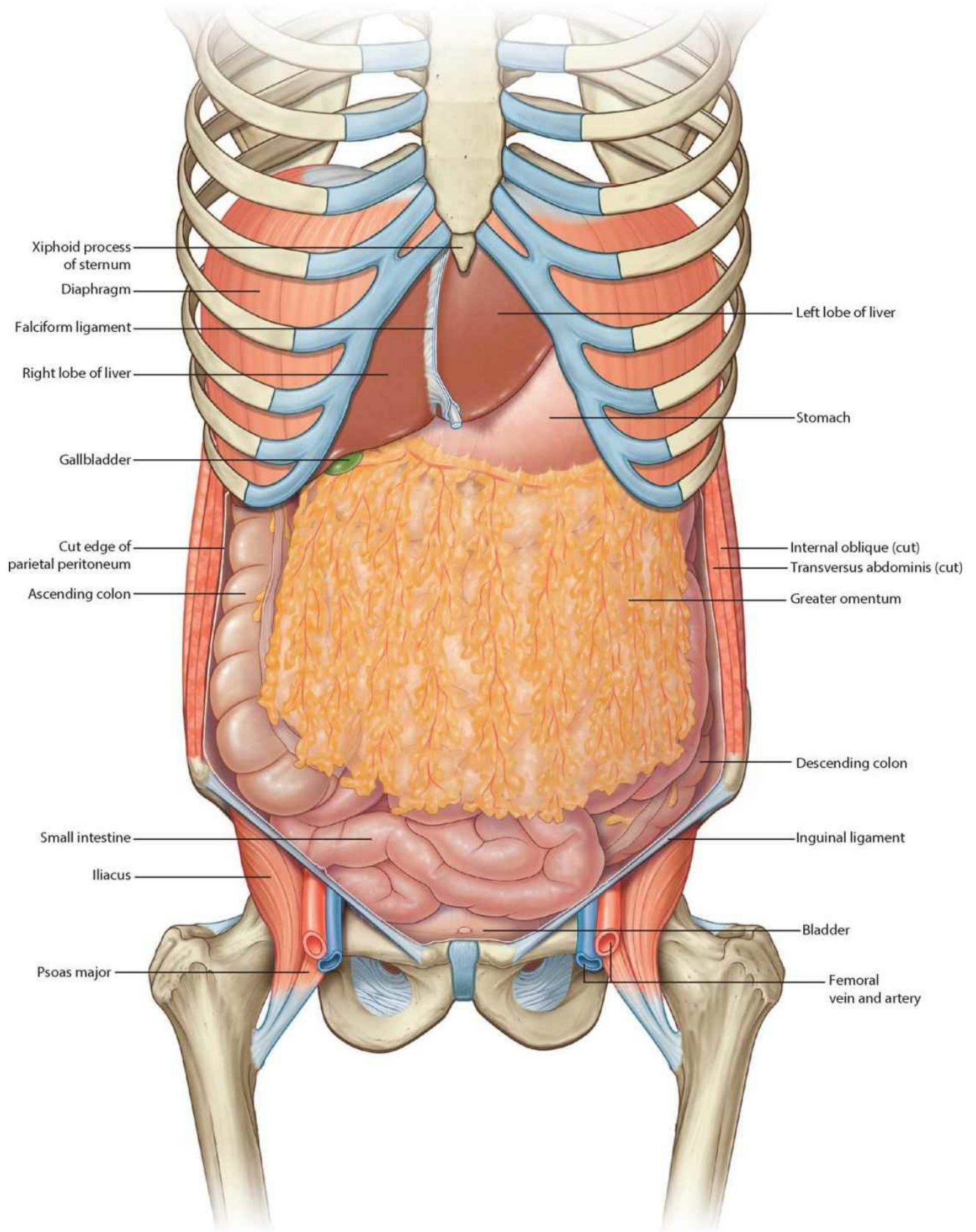
Laparoscopic view showing the parietal peritoneum still covering the area (inside the peritoneal cavity looking anteroinferior)

# Anterior abdominal wall



**Internal view of anterior abdominal wall in men**

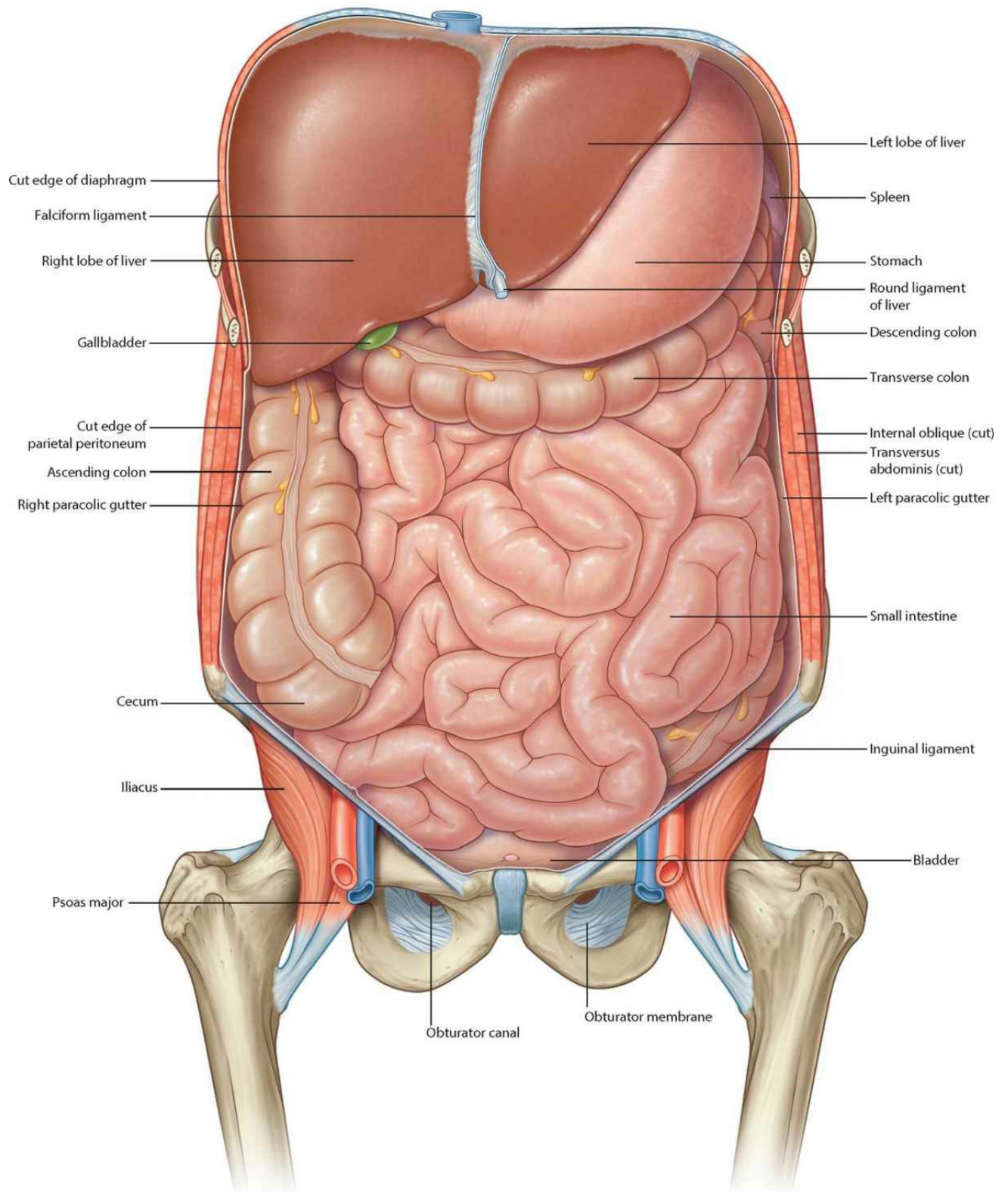
# Greater omentum



**Greater omentum**

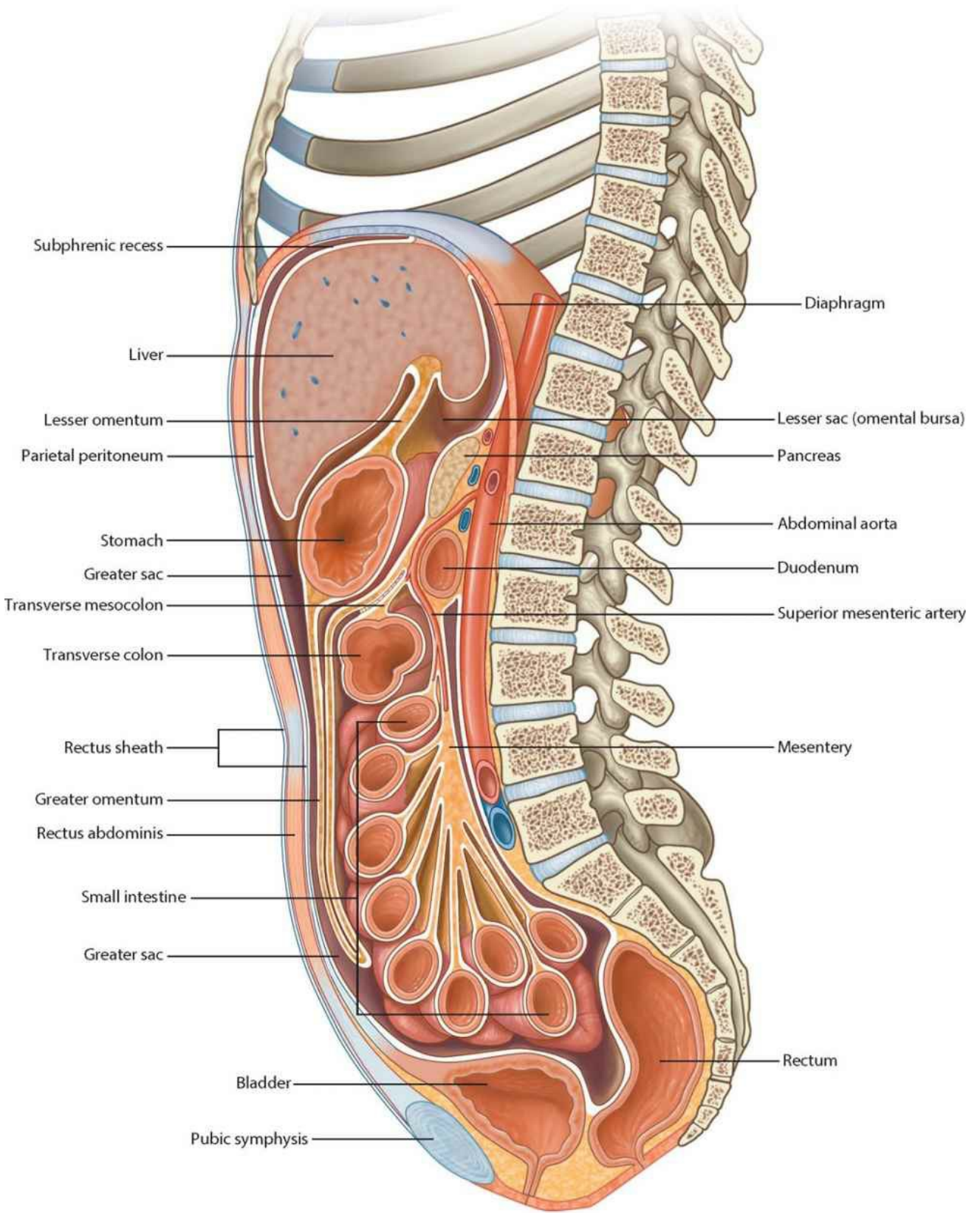


# Abdominal viscera



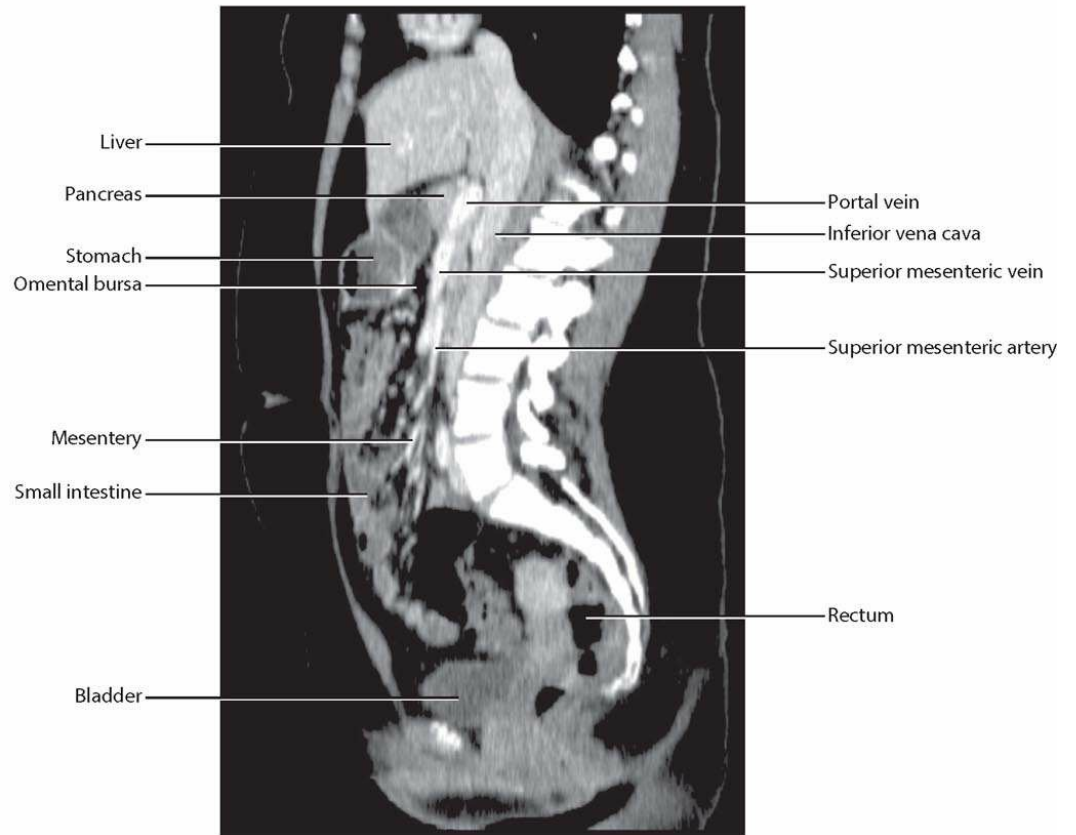
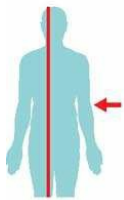
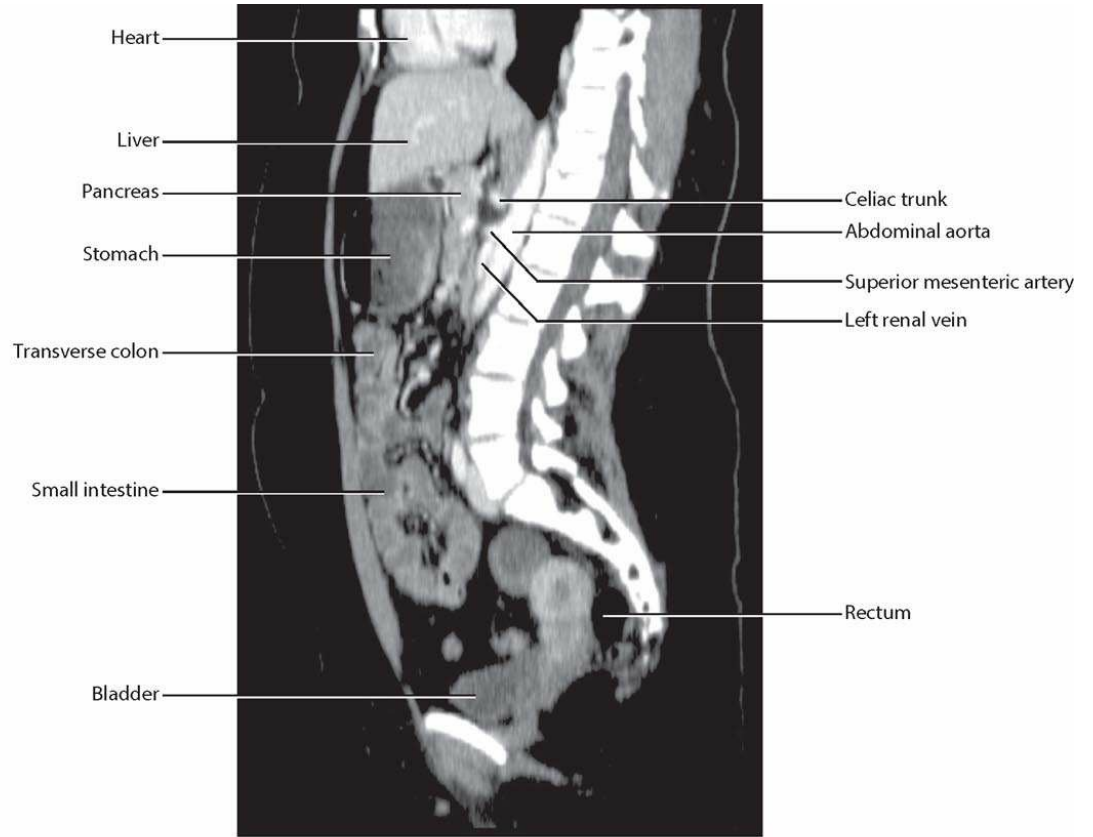
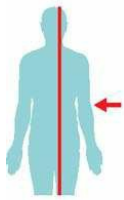
**Abdominal viscera (greater omentum removed)**

# Peritoneal cavity



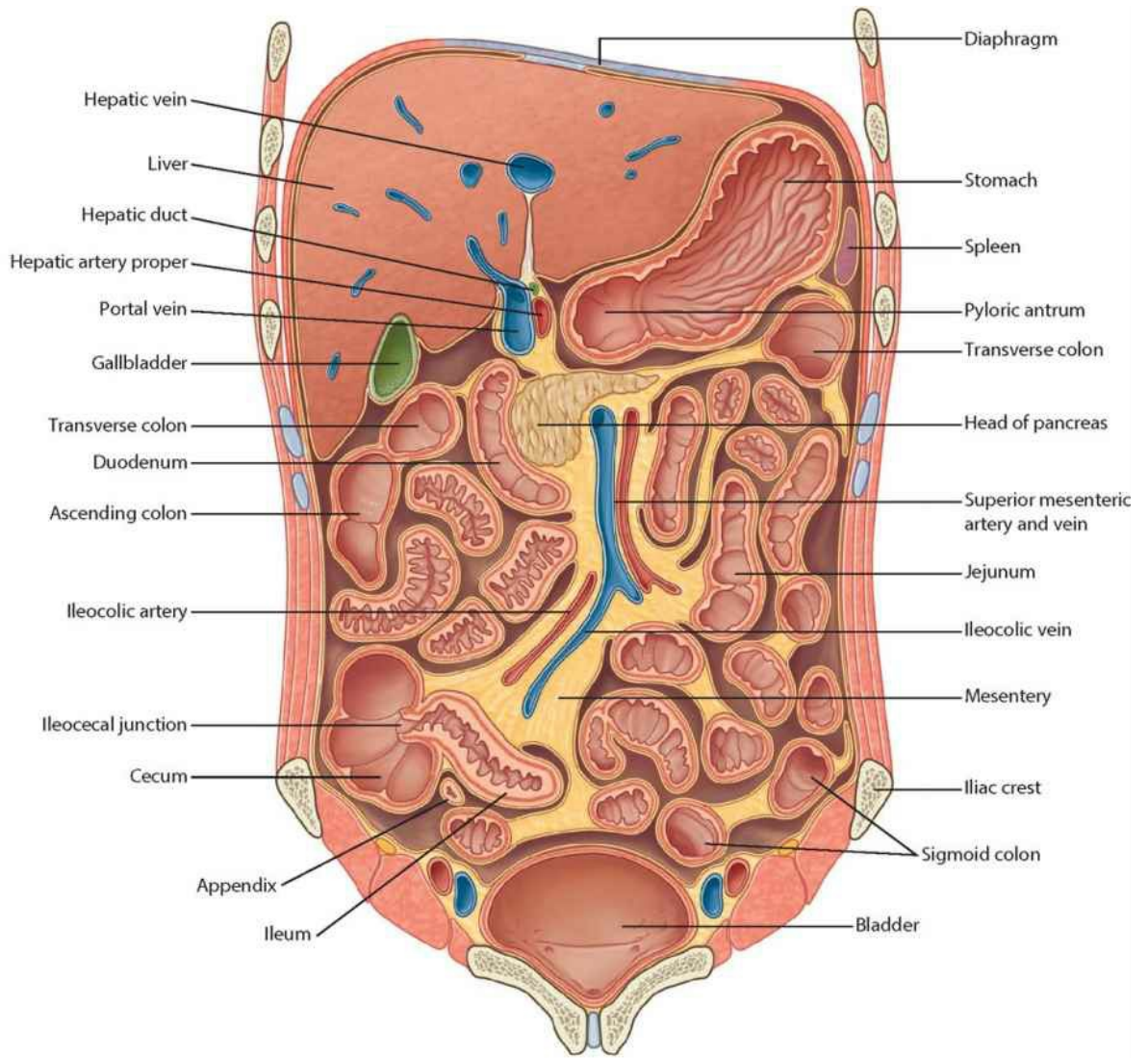
**Greater and lesser sacs of the peritoneal cavity**

# Abdominal sagittal section

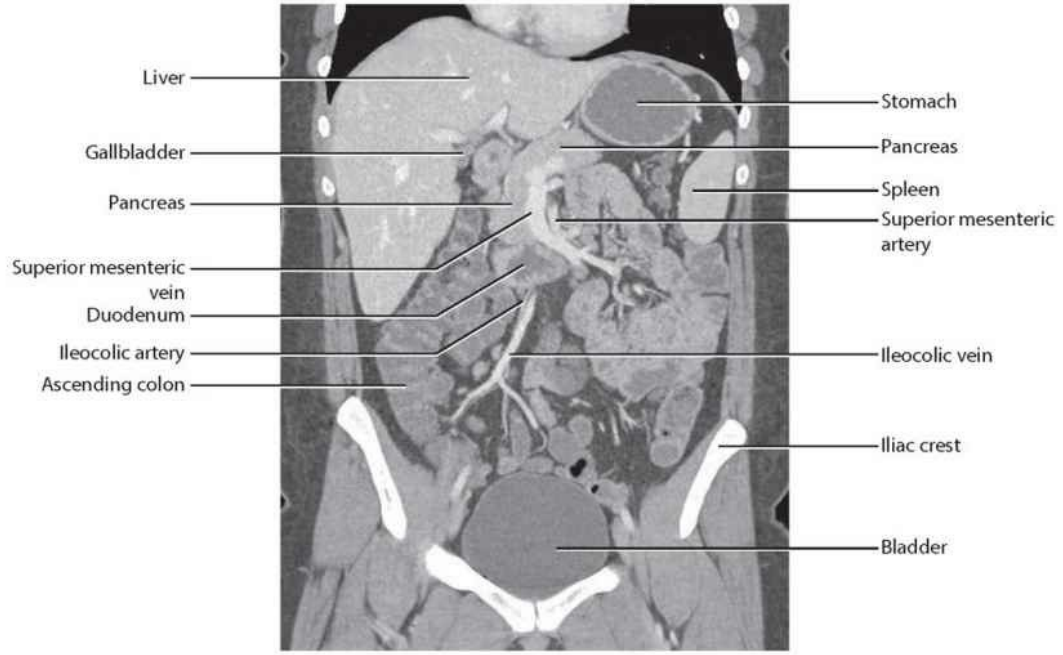
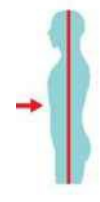


**Arrangement of abdominal contents in peritoneal cavity.**  
CT images with contrast, in sagittal plane

# Abdominal coronal section



Coronal section



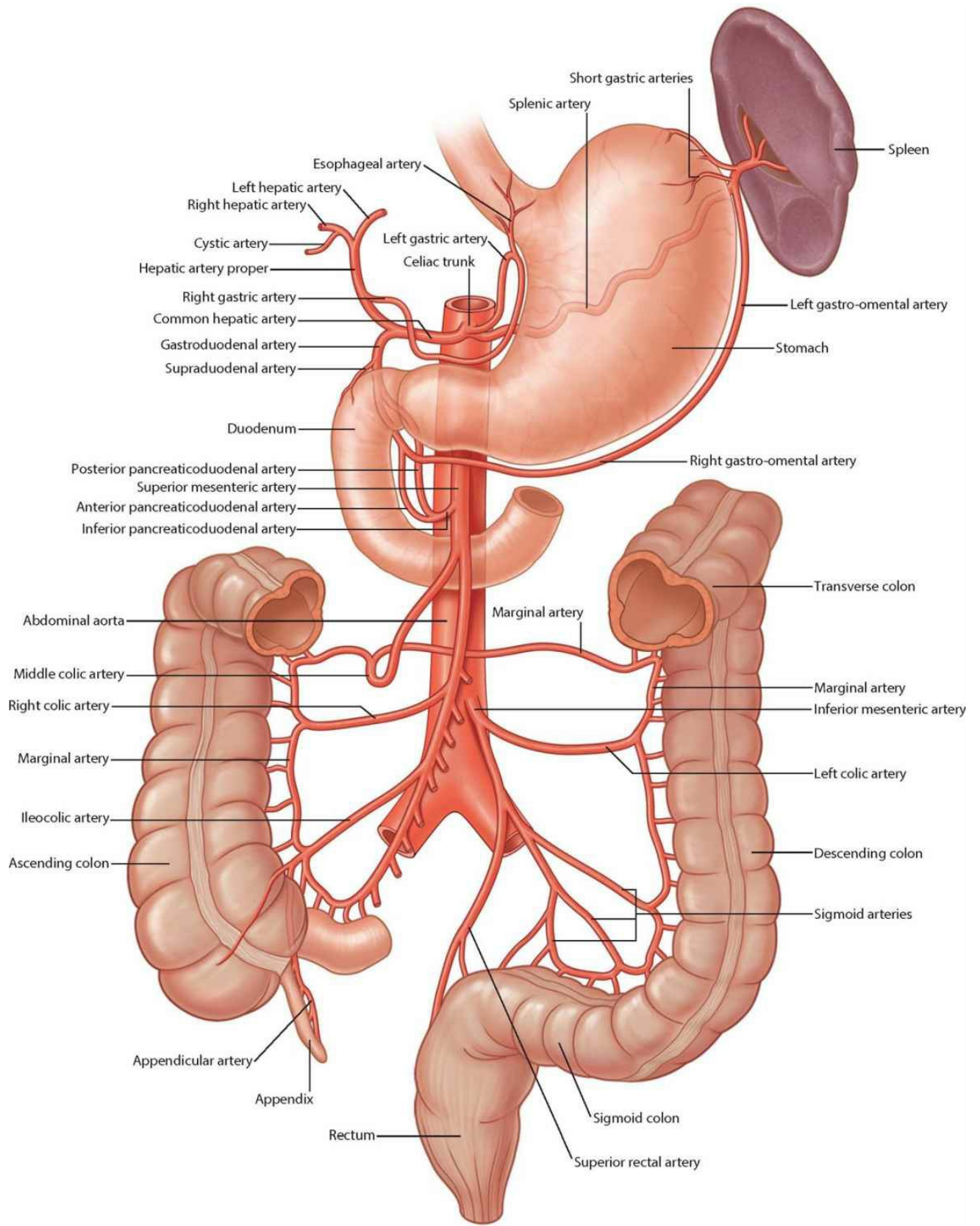
Coronal section.

CT image with contrast, in coronal plane

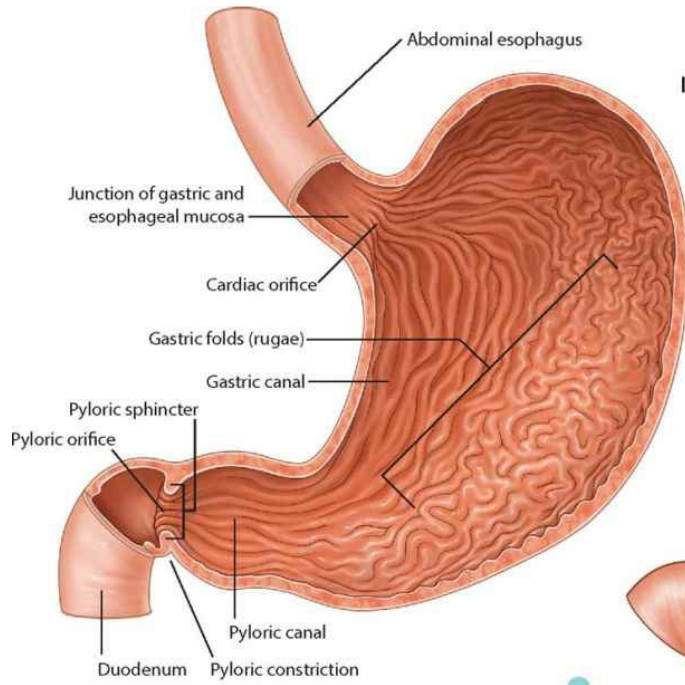




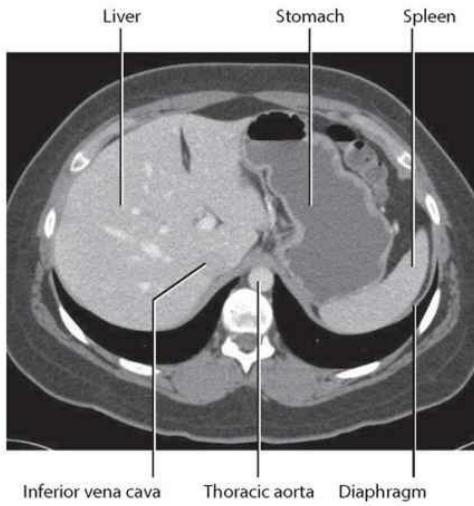
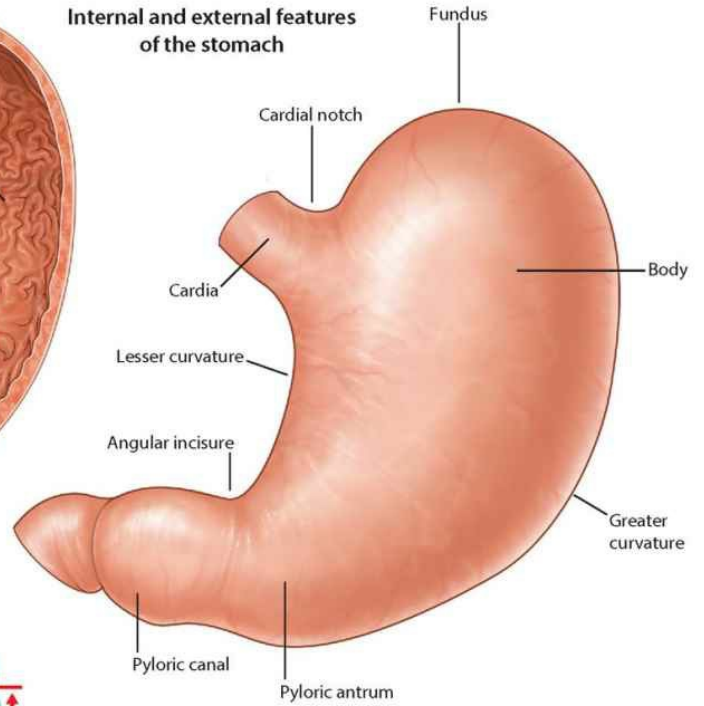
# Arterial supply of viscera



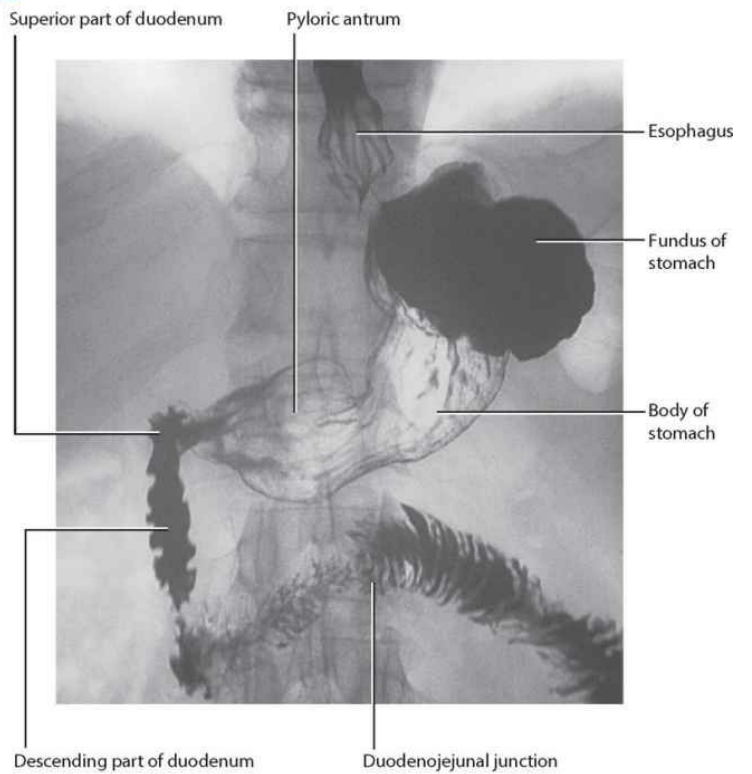
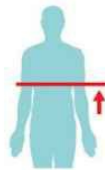
# Stomach



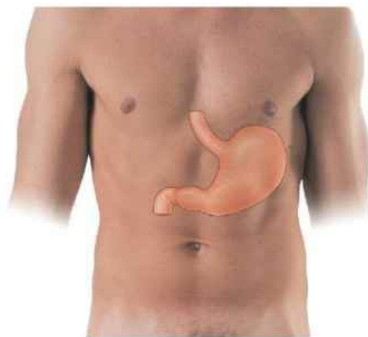**Internal and external features of the stomach**



**Positioning of the stomach.**  
 CT image, with contrast, in axial plane

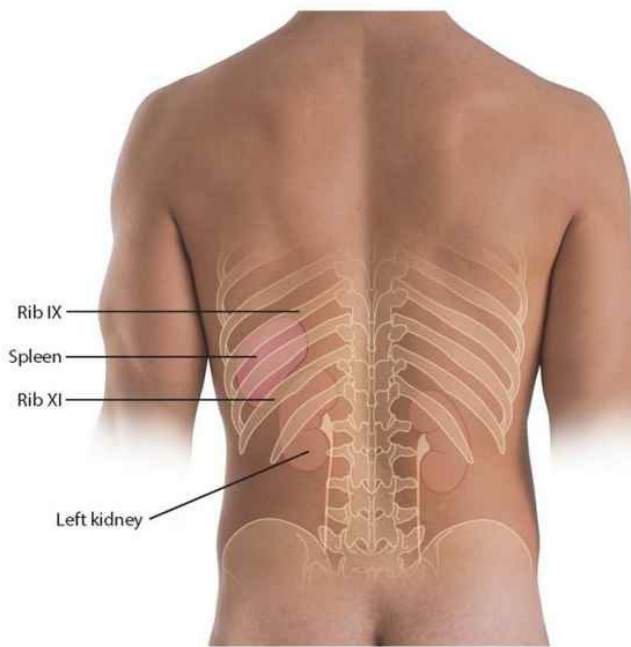


**Stomach. Double contrast radiograph using barium**

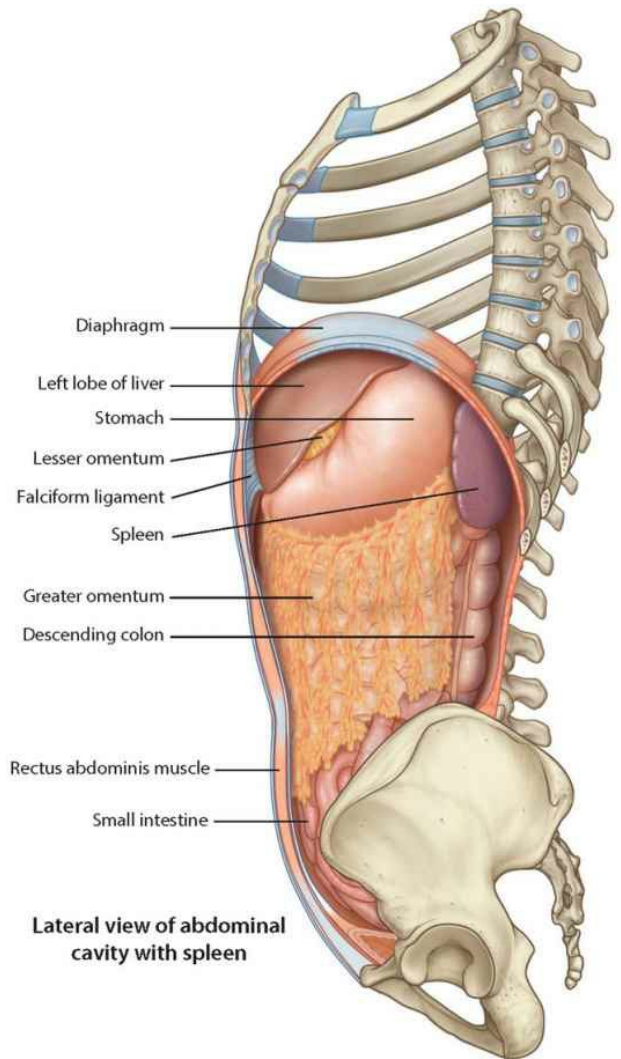


**Surface projection of the stomach**

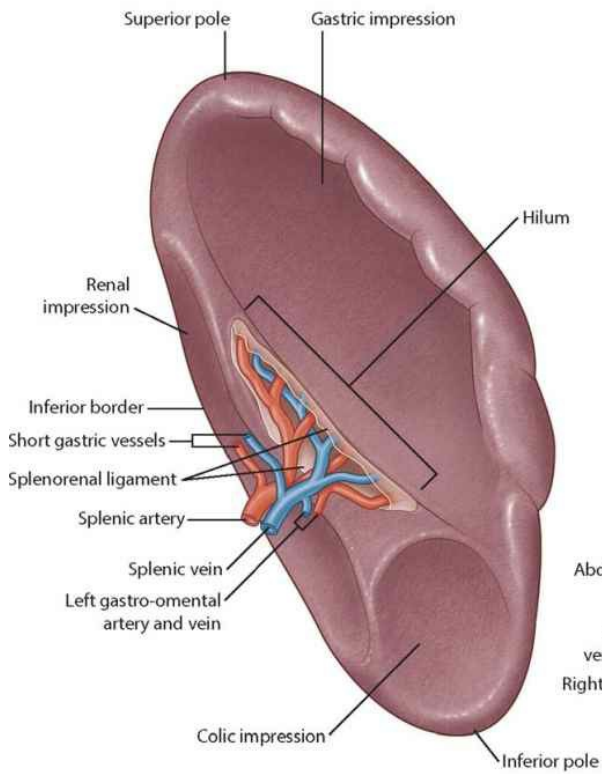
# Spleen



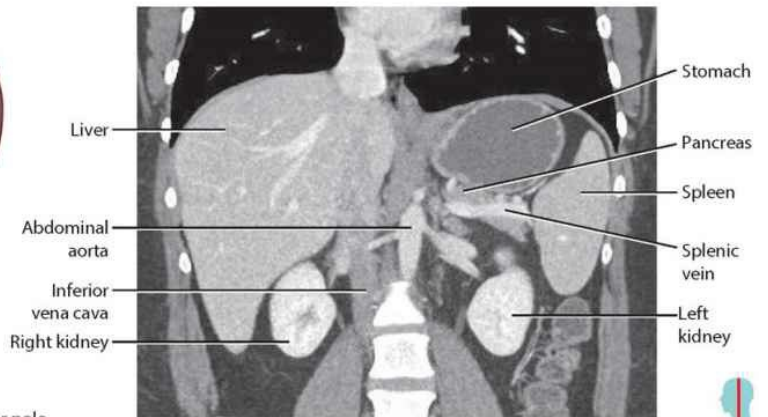
Surface projection of the spleen (posterior view)



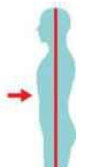
Lateral view of abdominal cavity with spleen



Surfaces and hilum of the spleen

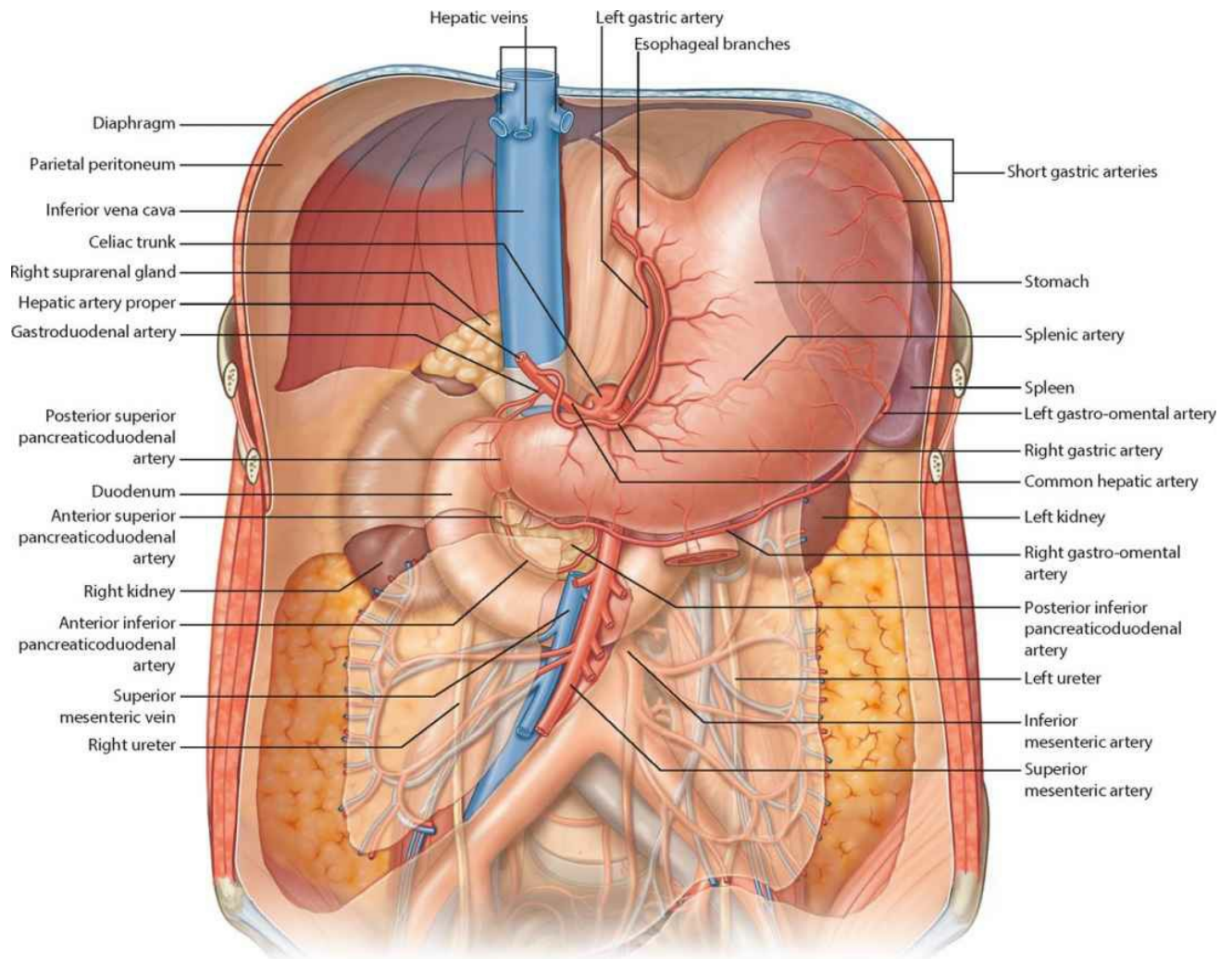


Location of the spleen. CT image, with contrast, in coronal plane

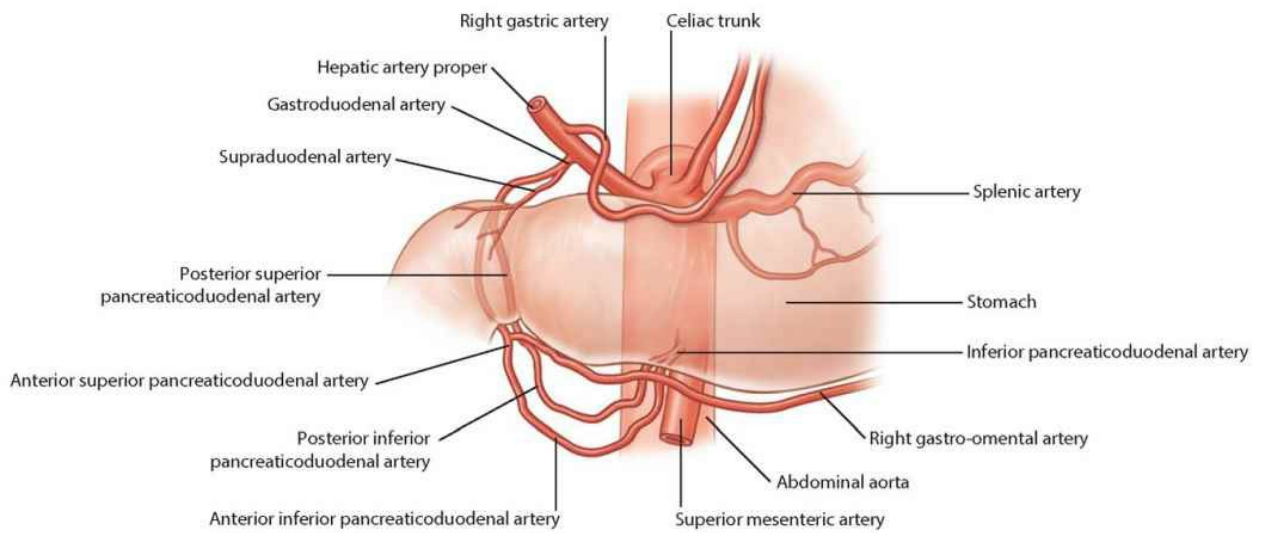


# Arteries of stomach and spleen



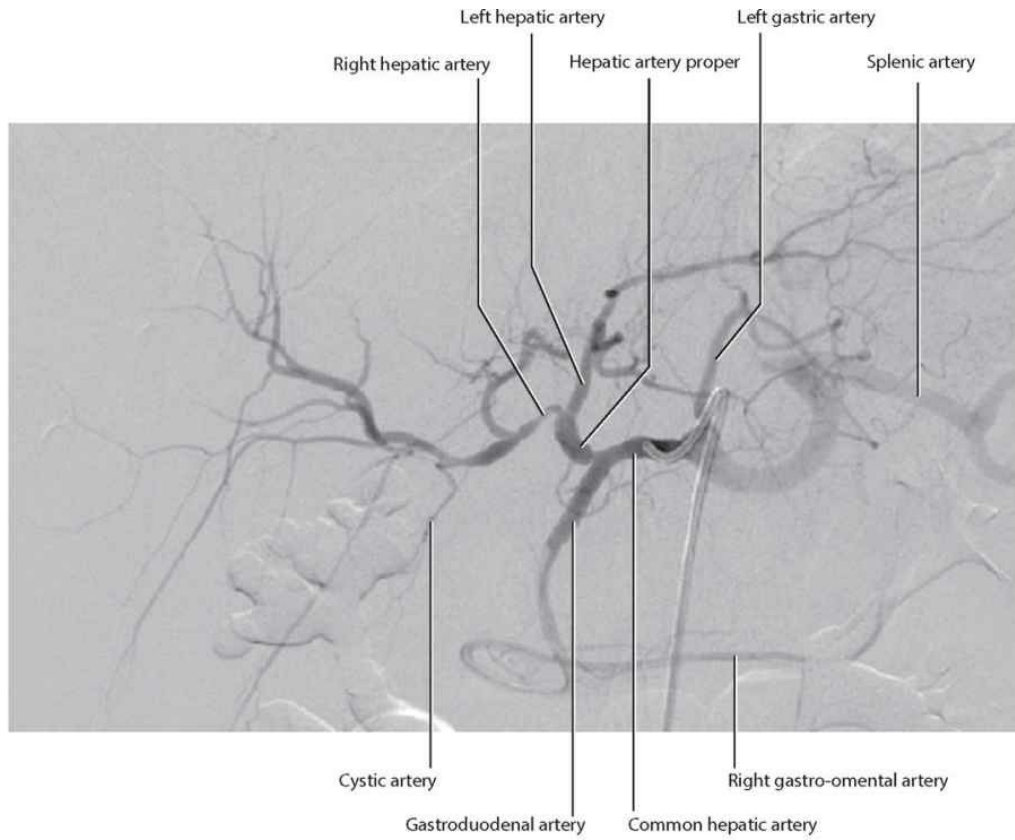


**Distribution of the celiac trunk**

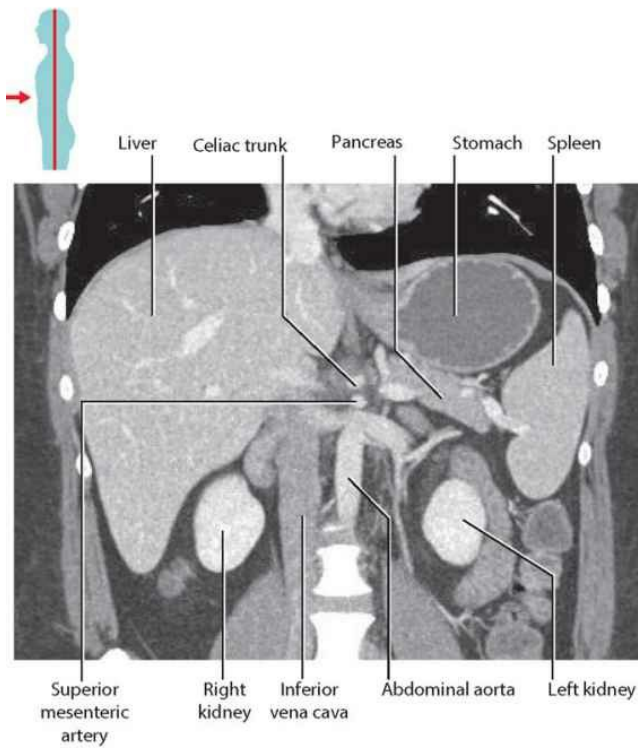


**Branches of the gastroduodenal artery**

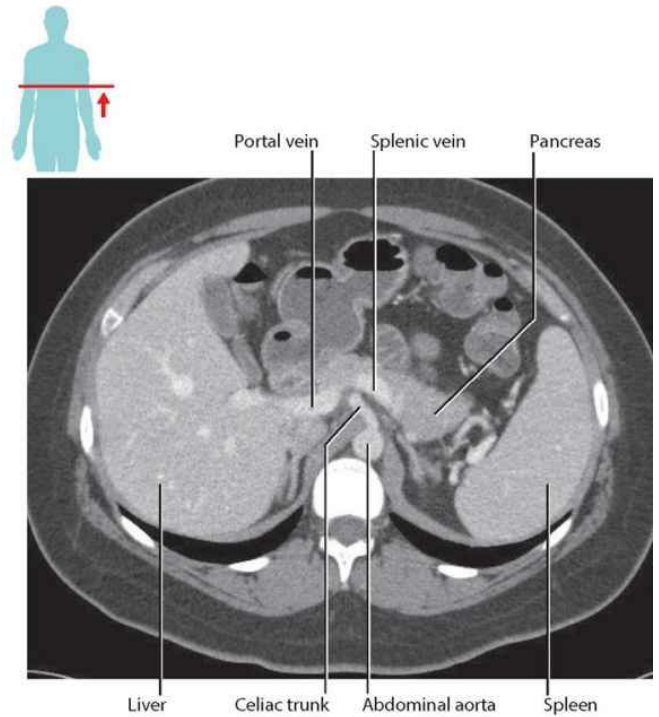




**Digital subtraction angiography of the celiac trunk and its branches**

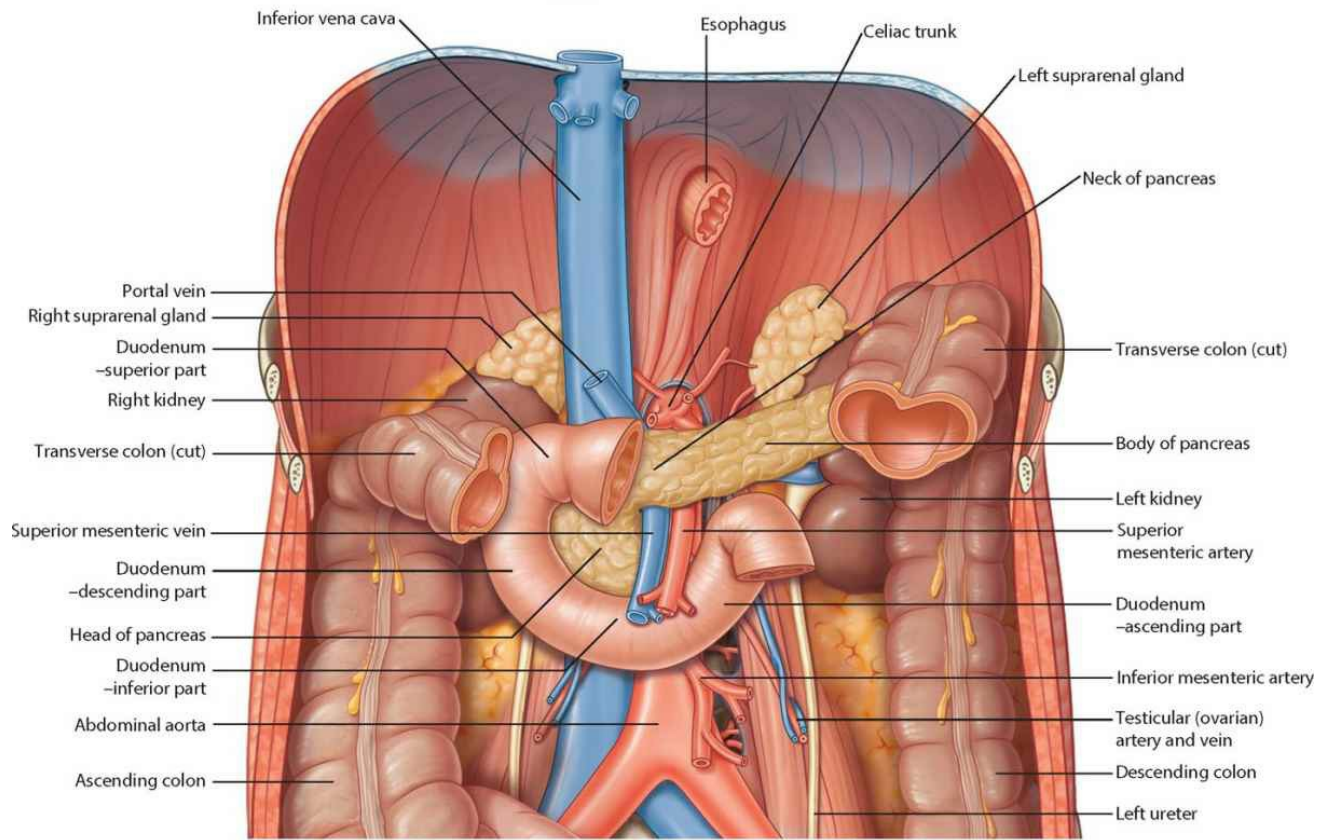


**Positioning of the celiac trunk in relation to other structures.**  
CT image, with contrast, in coronal plane

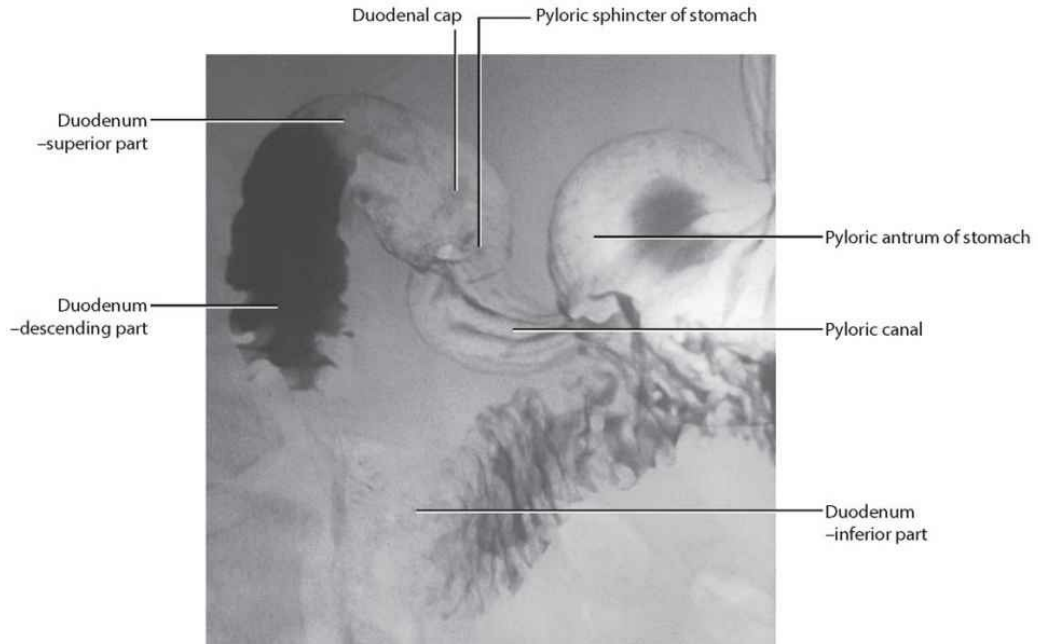


**Branching of the celiac trunk from the abdominal aorta.**  
CT image, with contrast, in axial plane

# Duodenum

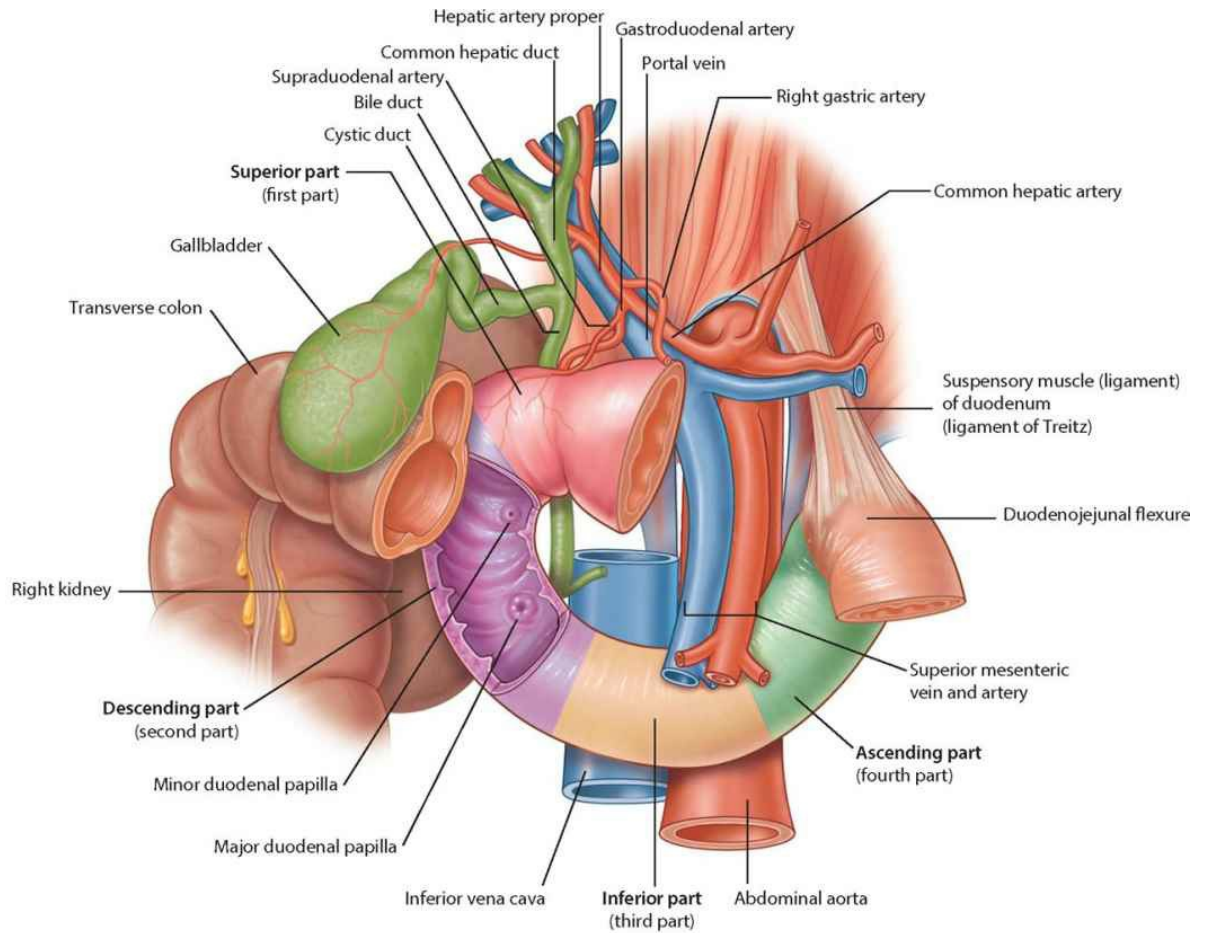


**Duodenum in situ**

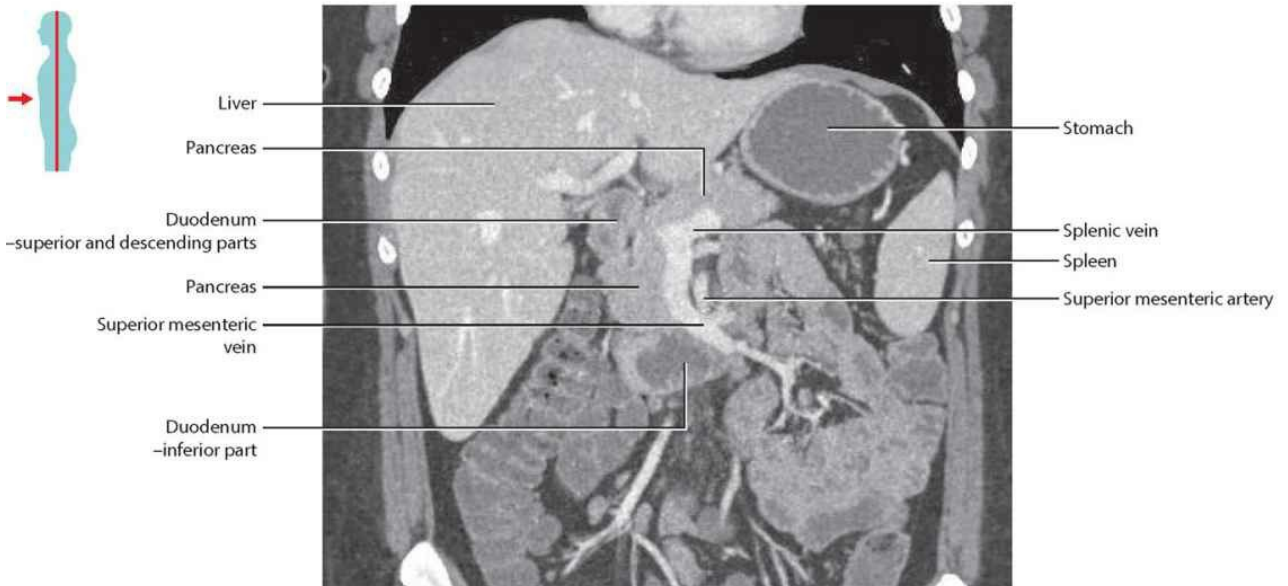

**Double contrast radiograph showing the duodenal cap**





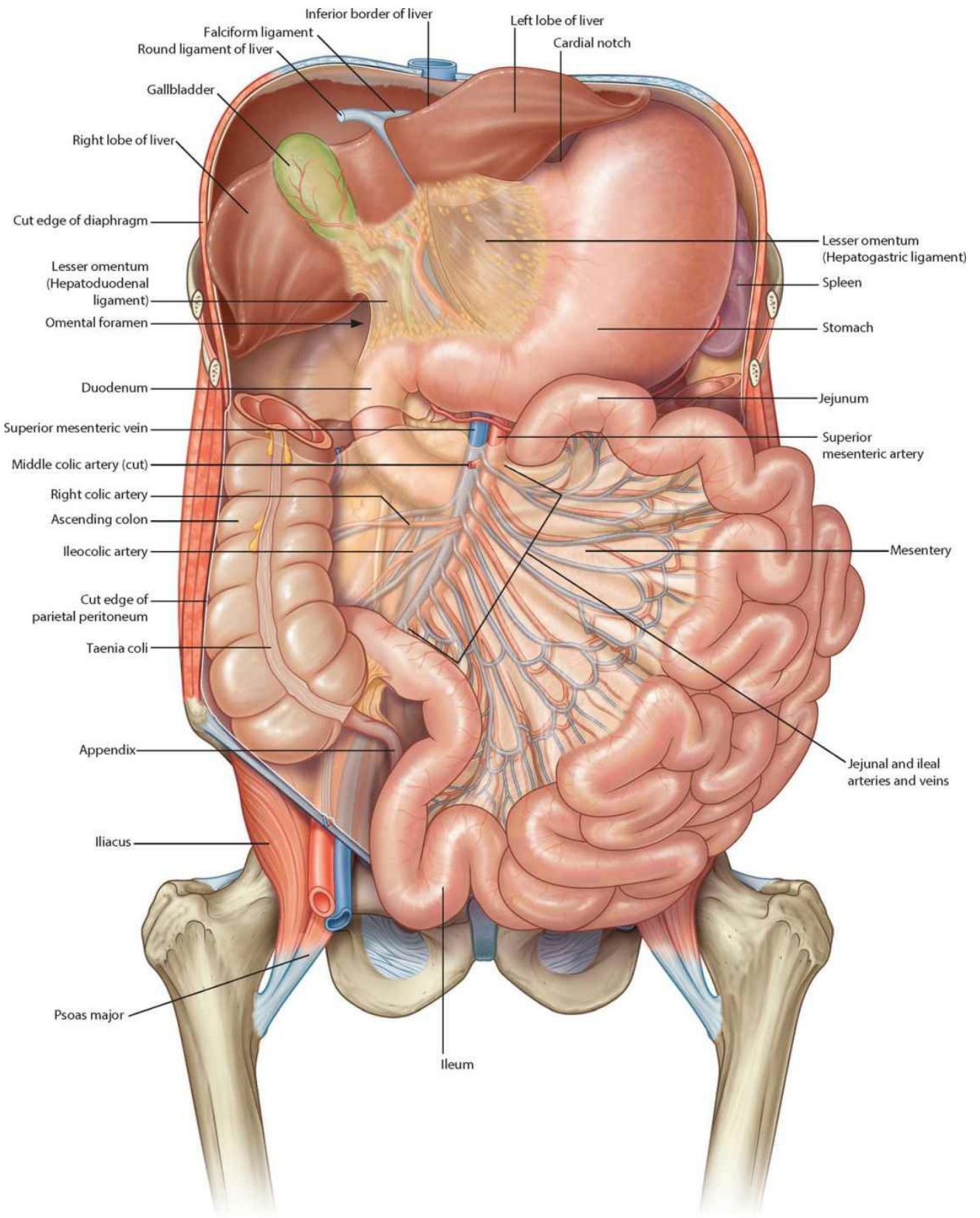
**Parts of the duodenum and related structures**



**Relationship of duodenum to structures in the vicinity.**  
CT image, with contrast, in coronal plane

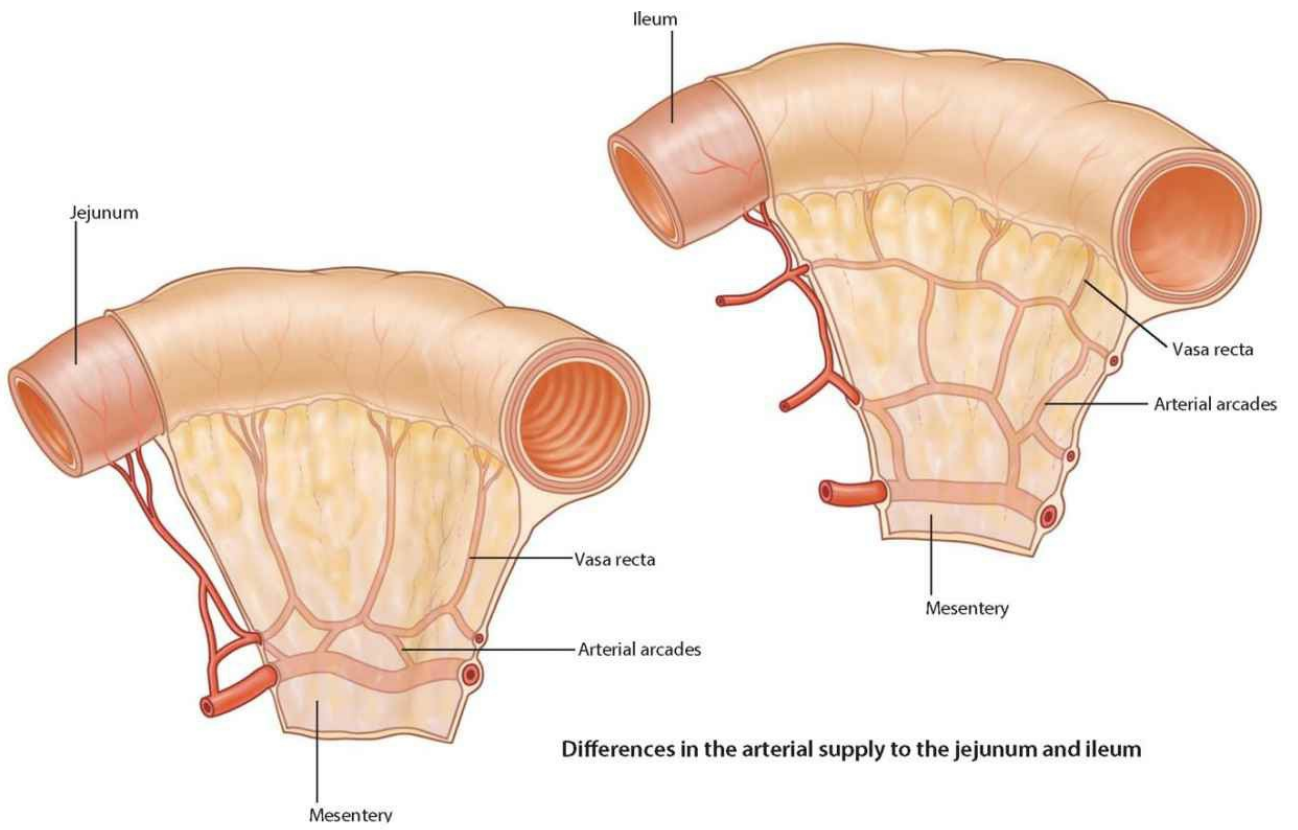
# Small intestine



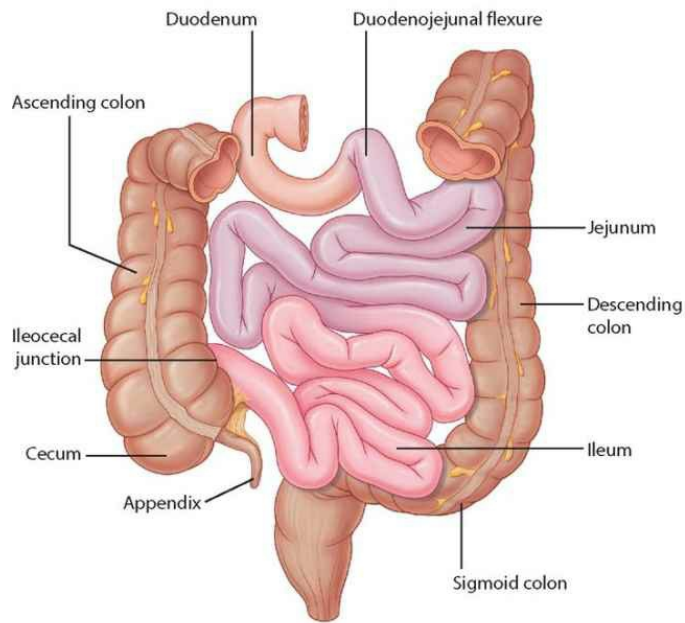


Small intestine displaced to show superior mesenteric vessels

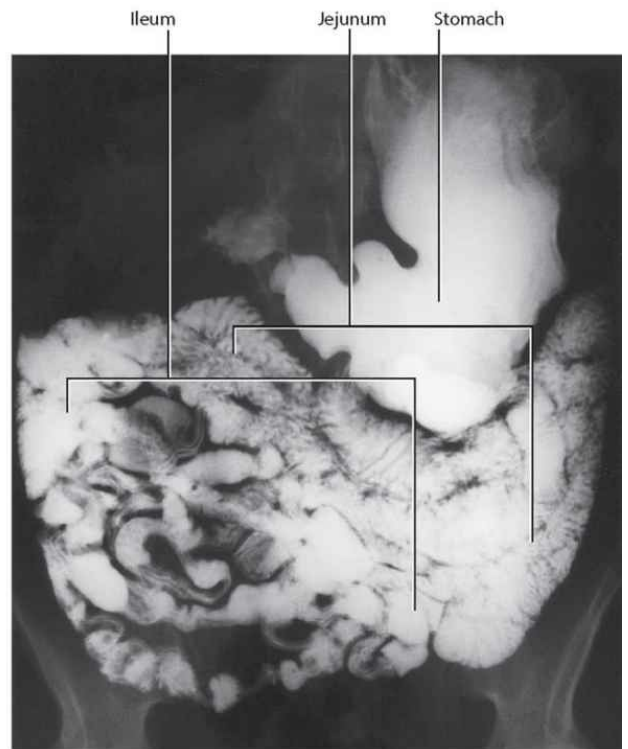




Differences in the arterial supply to the jejunum and ileum

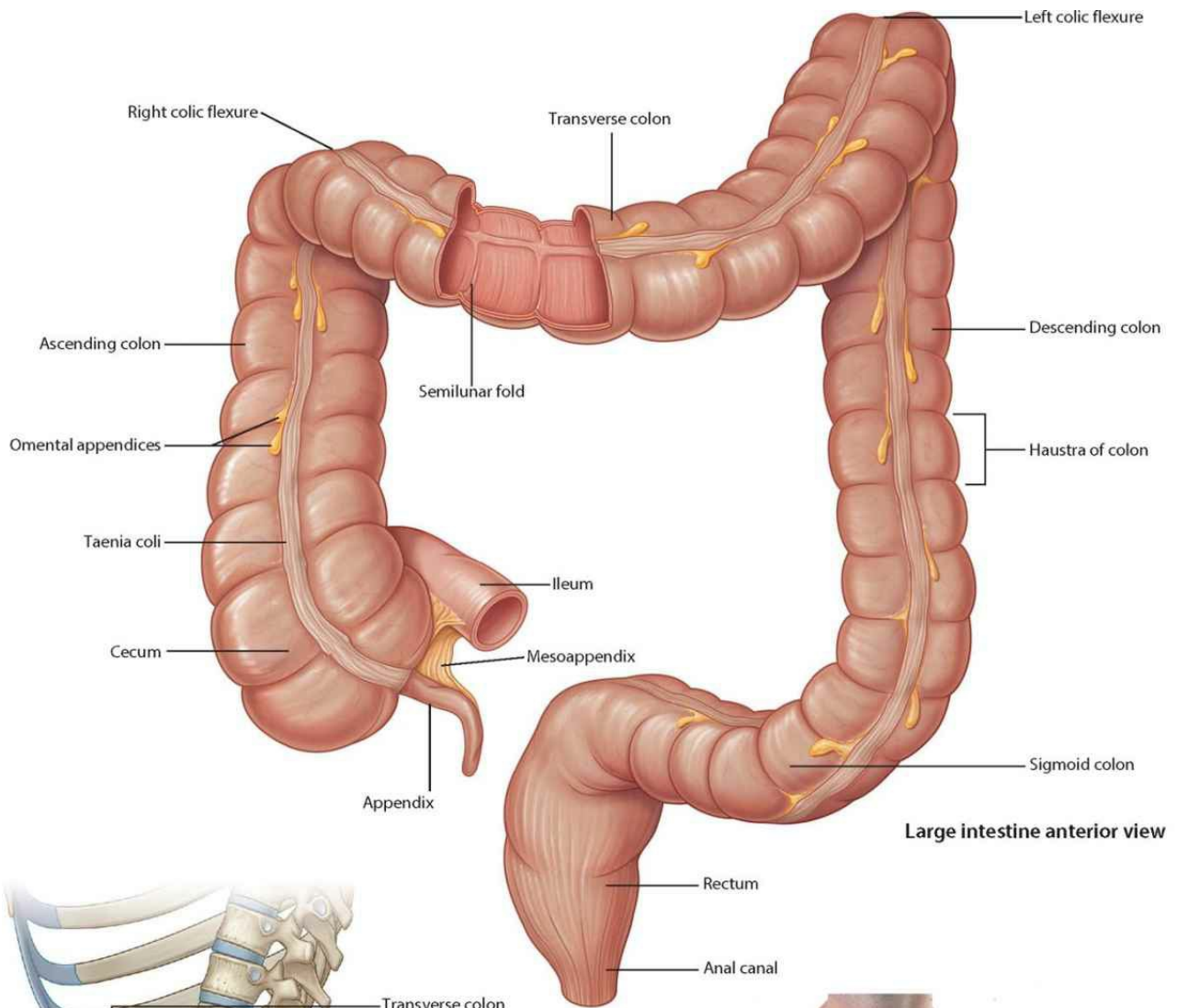


Jejunum and ileum

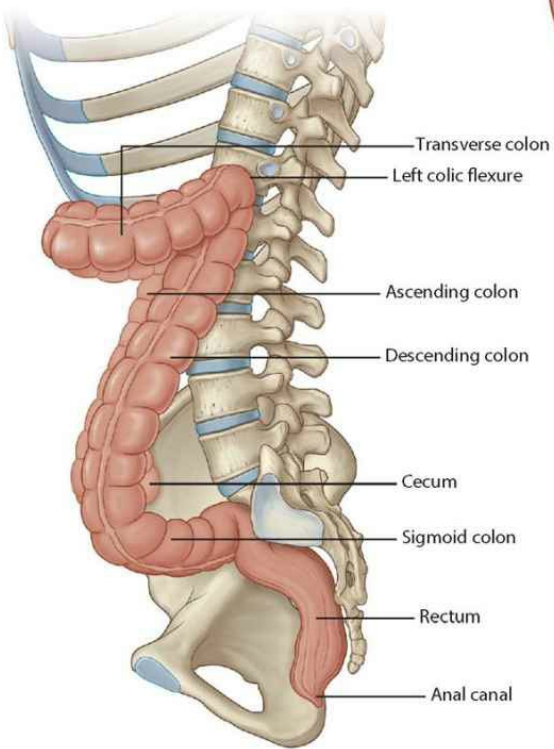


Radiograph using barium, showing jejunum and ileum

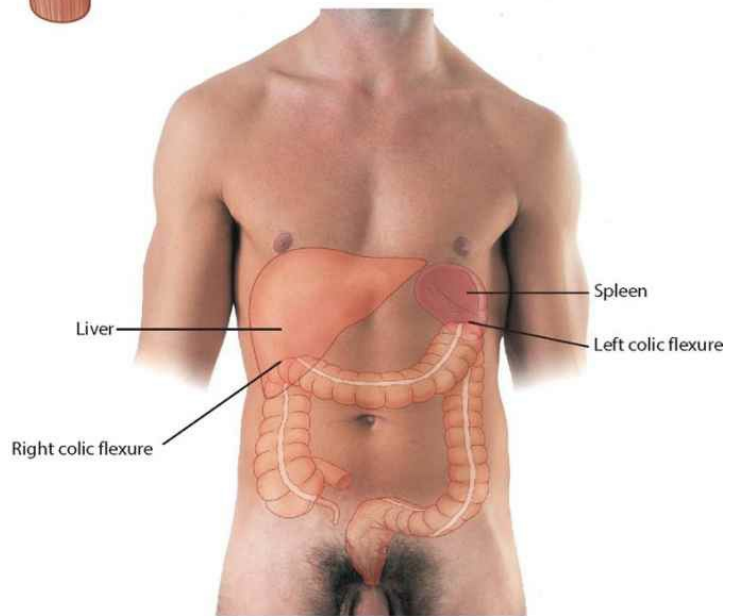
# Large intestine



**Large intestine anterior view**

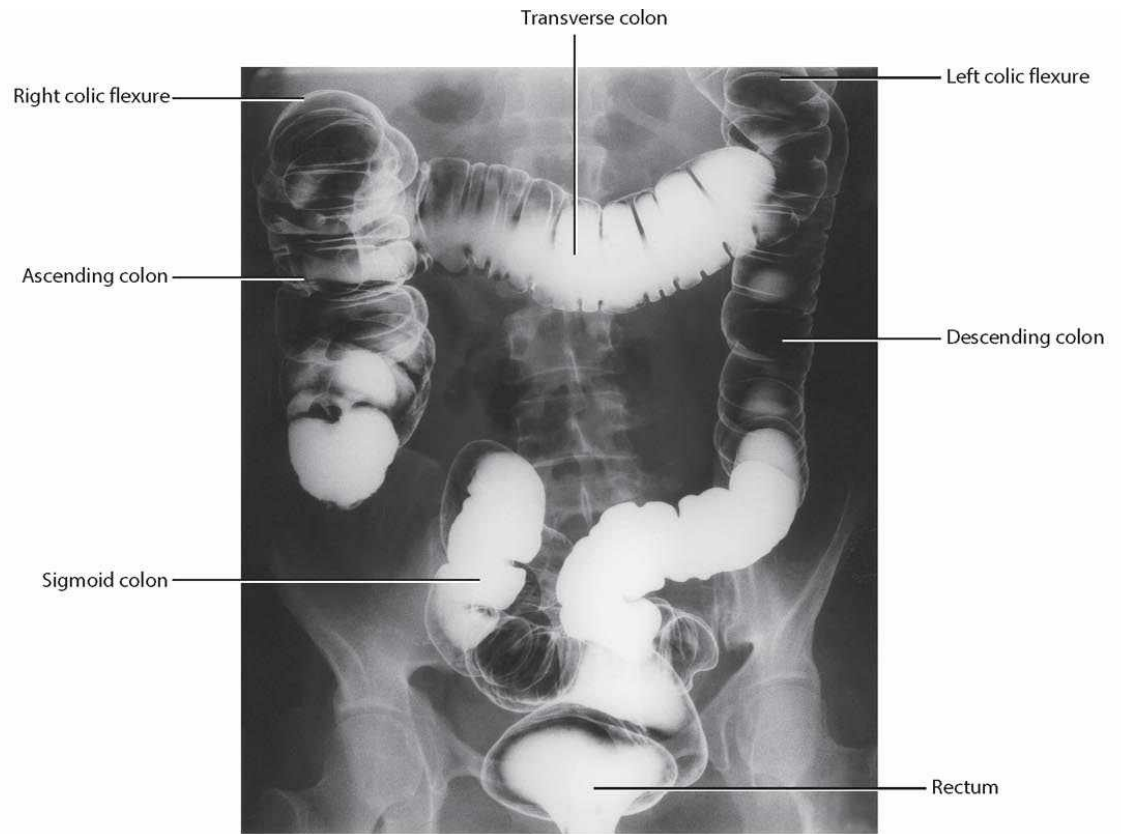


**Large intestine left lateral view**

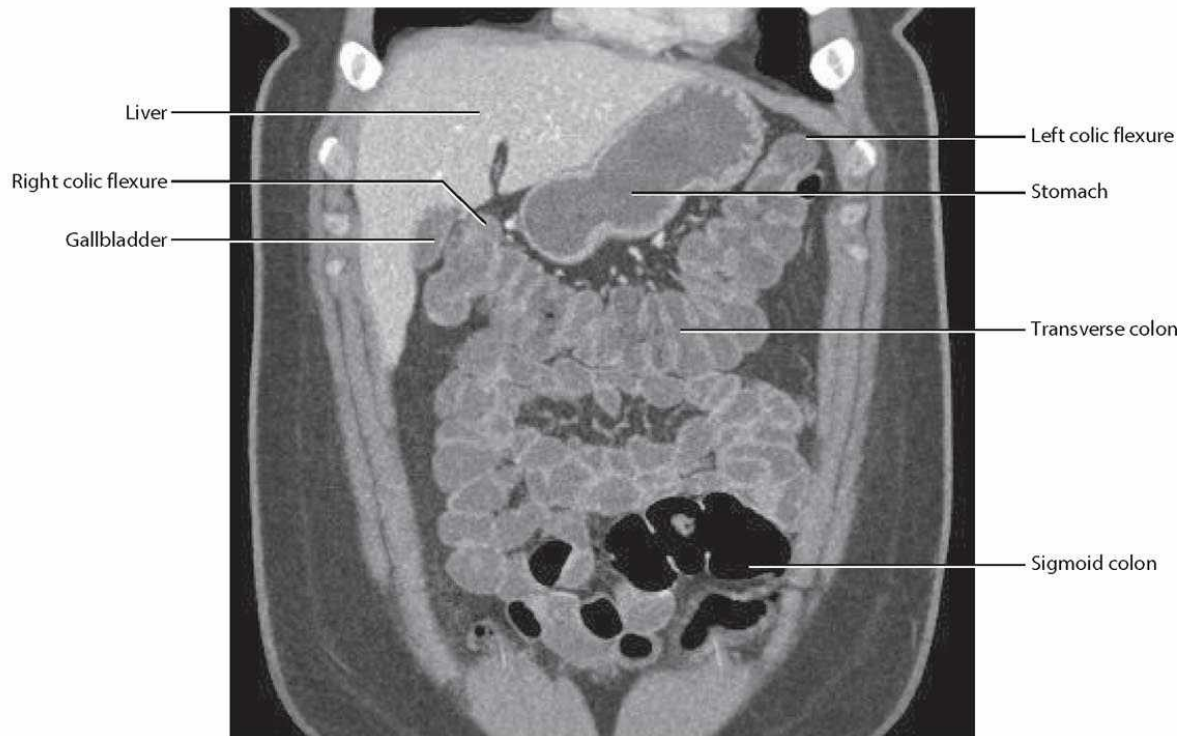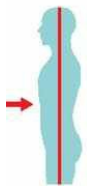


**Surface projection of the large intestine**





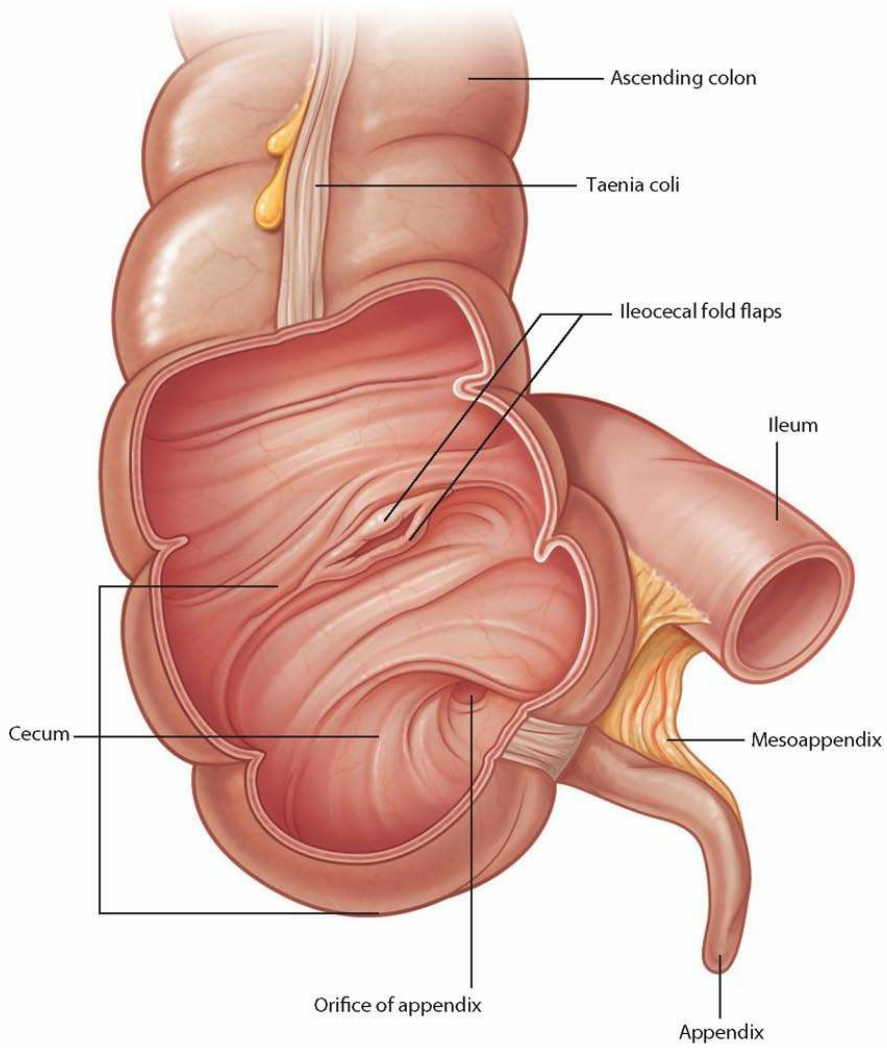
Radiograph using barium showing the large intestine



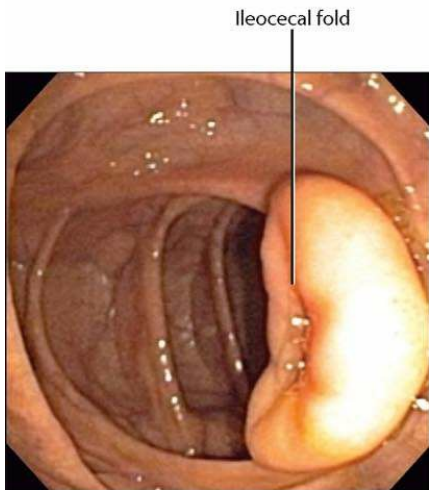
Transverse colon showing right and left colic flexures.  
CT image, with contrast, in coronal plane

# Ileocecal junction

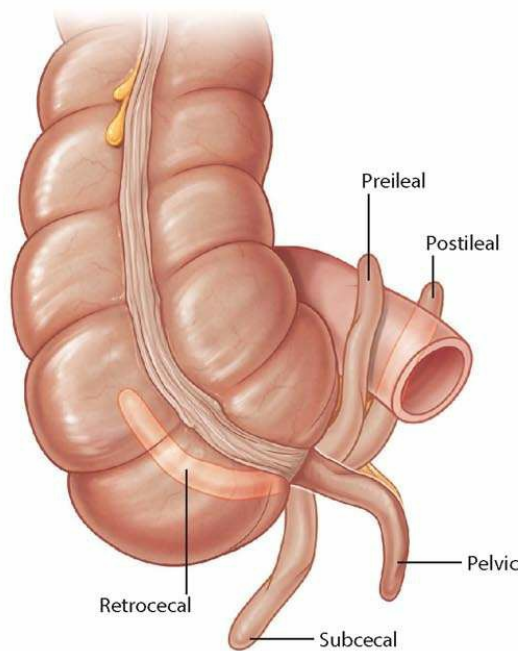




**Ileocecal junction**



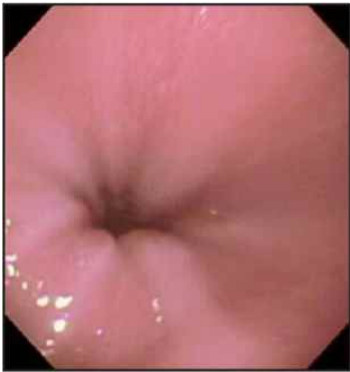**Colonoscopy showing ileocecal fold**



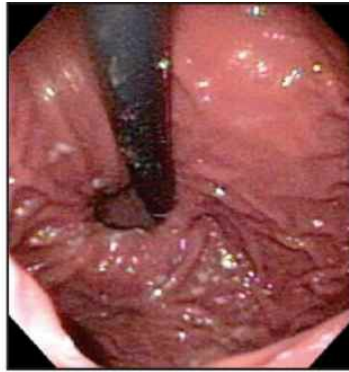
**Positions of the appendix**



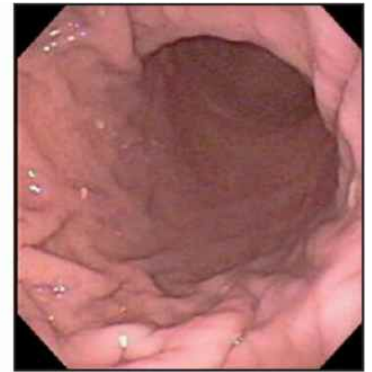# Gastrointestinal tract: imaging



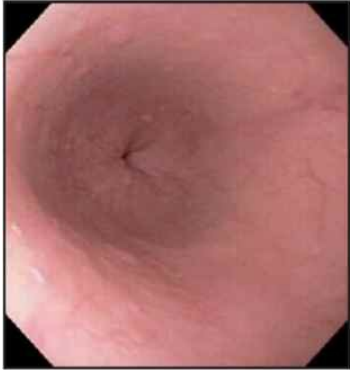A



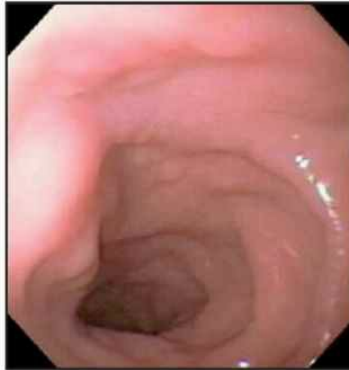B



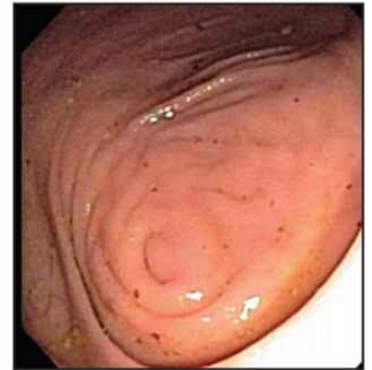
C



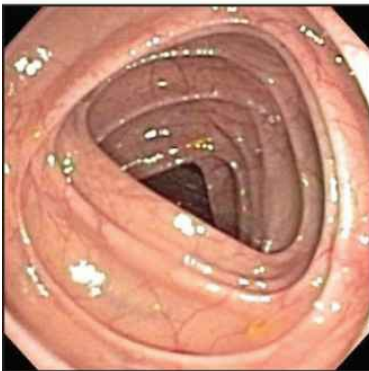D



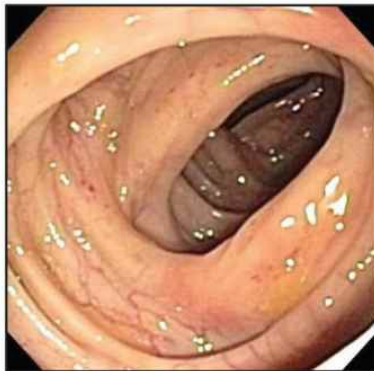
E



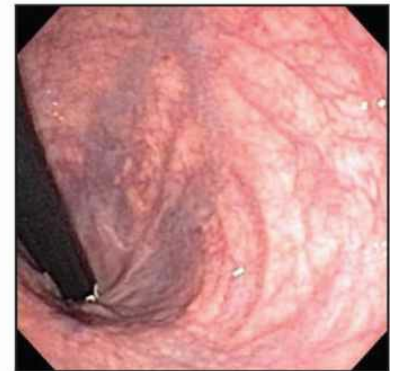F



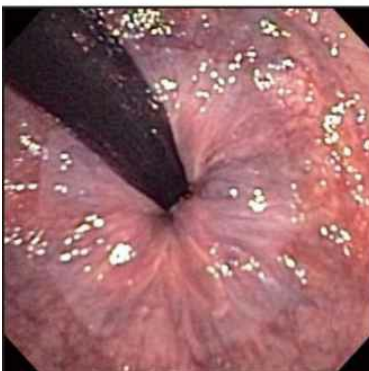G



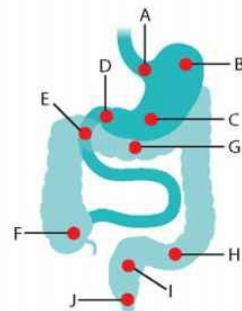
H



I



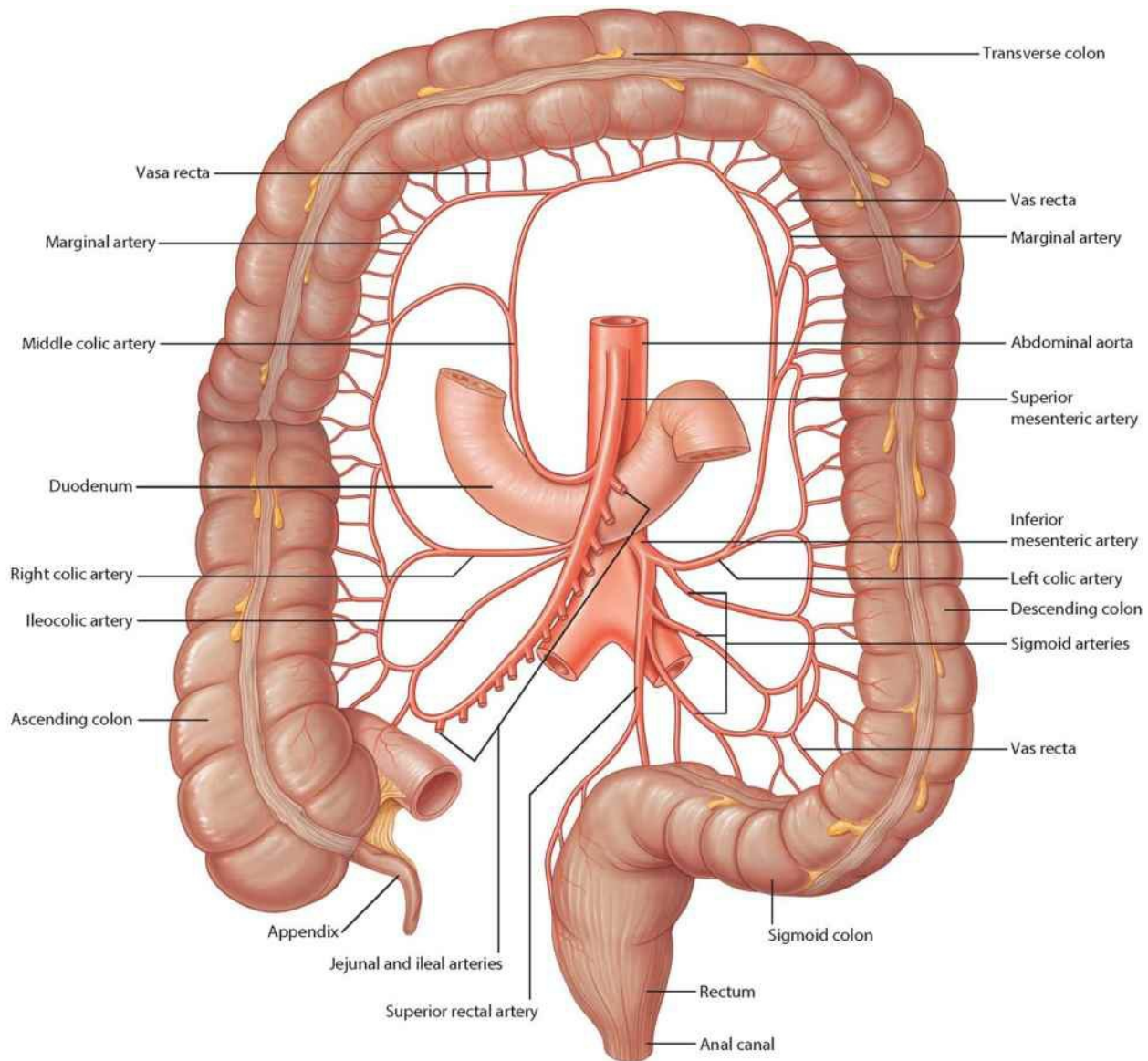
J



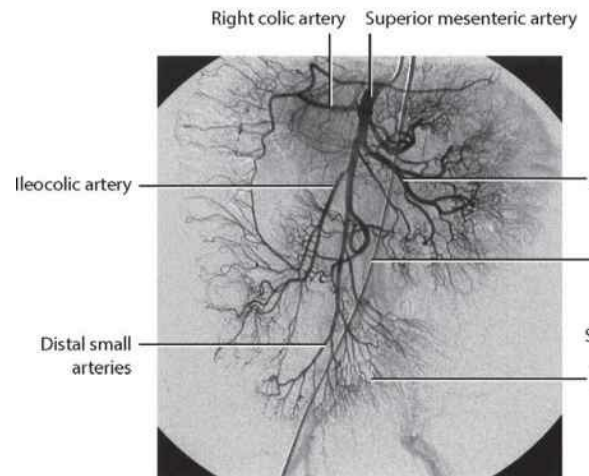
**Endoscopy and colonoscopy showing different parts of the gastrointestinal tract.**

- A. Gastroesophageal junction
- B. Cardiac orifice and fundus of stomach-retroflexed view
- C. Body of stomach
- D. Pylorus of stomach and pyloric sphincter
- E. Duodenum
- F. Cecum showing appendiceal opening.
- G. Transverse colon
- H. Sigmoid colon
- I. Rectum-retroflexed view
- J. Pectinate line

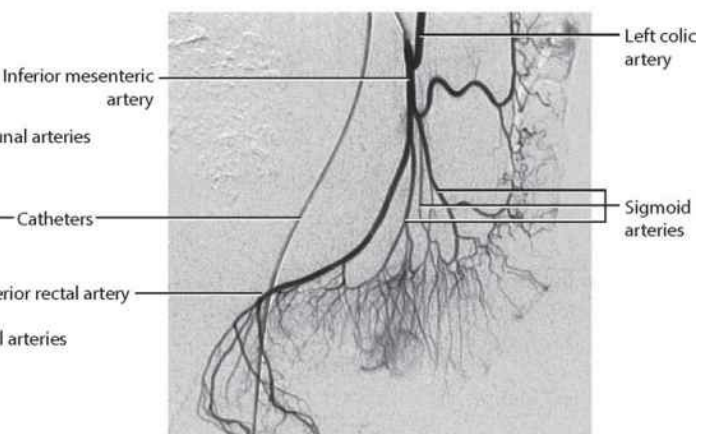
# Mesenteric arteries



**Superior and inferior mesenteric arteries**

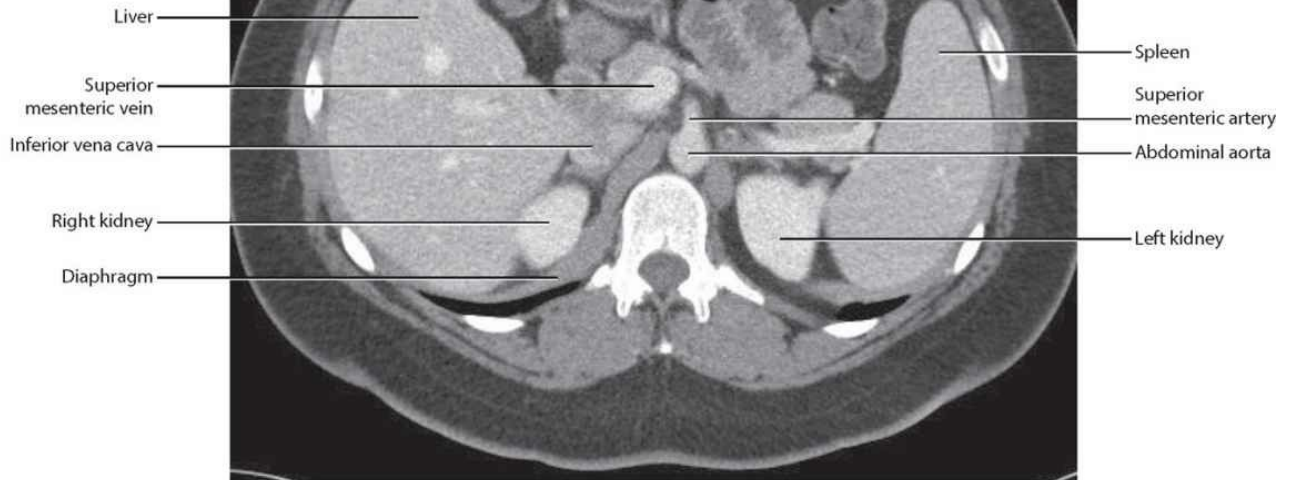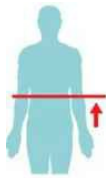


**Digital subtraction angiography of the superior mesenteric artery and its branches**

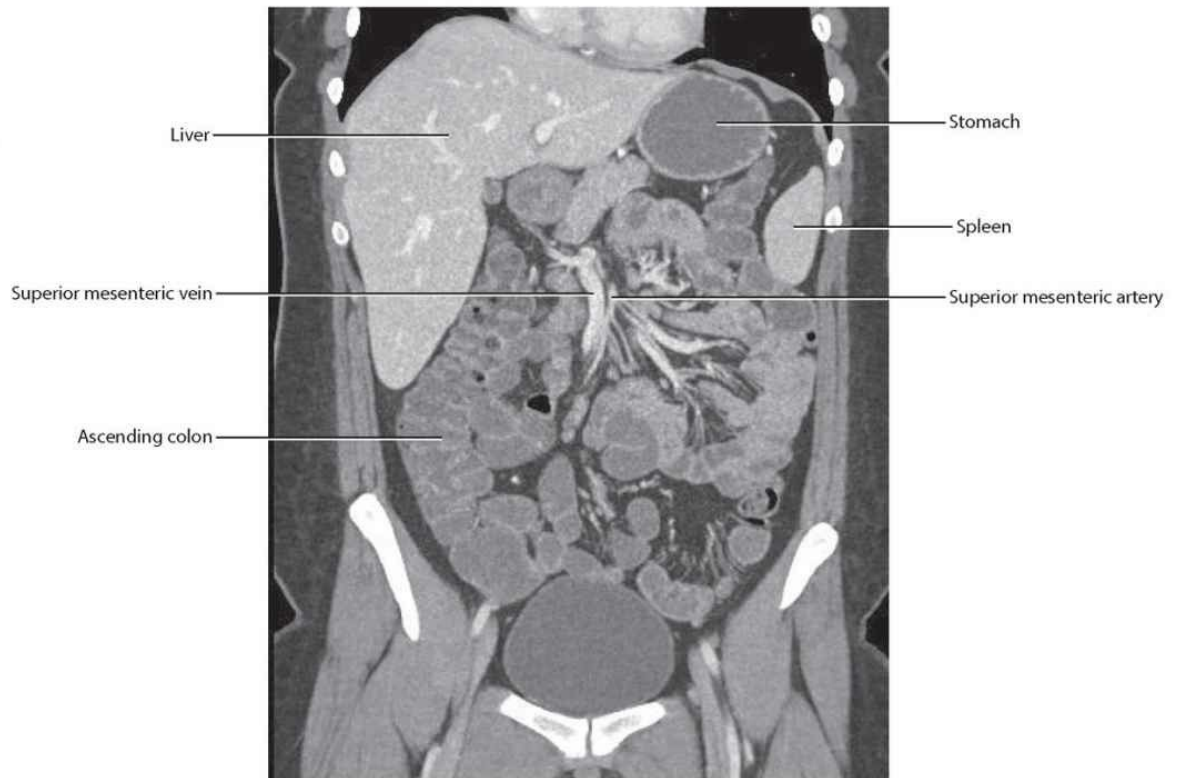
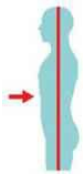


**Digital subtraction angiography of the inferior mesenteric artery and its branches**





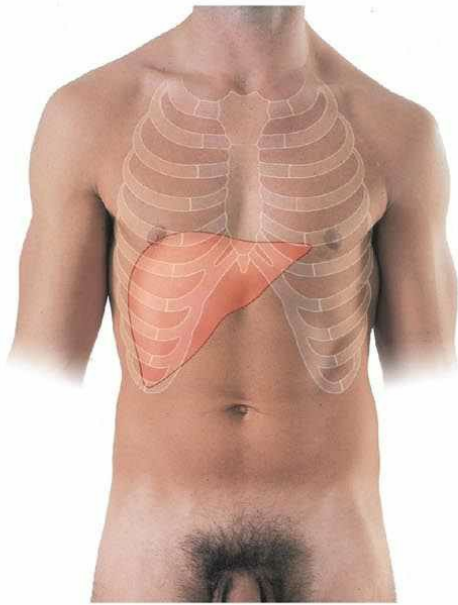
**Branching of the superior mesenteric artery from the abdominal aorta.**  
CT image, with contrast, in axial plane



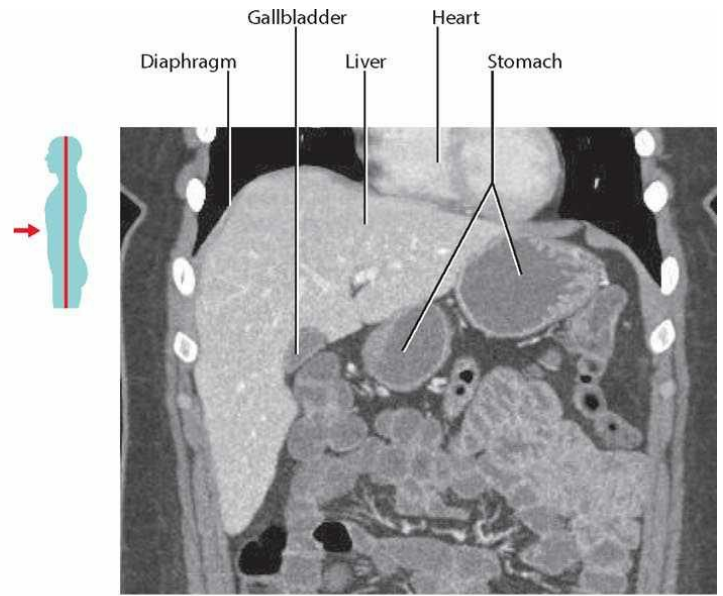
**Positioning of the superior mesenteric artery in relation to other structures.**  
CT image, with contrast, in coronal plane



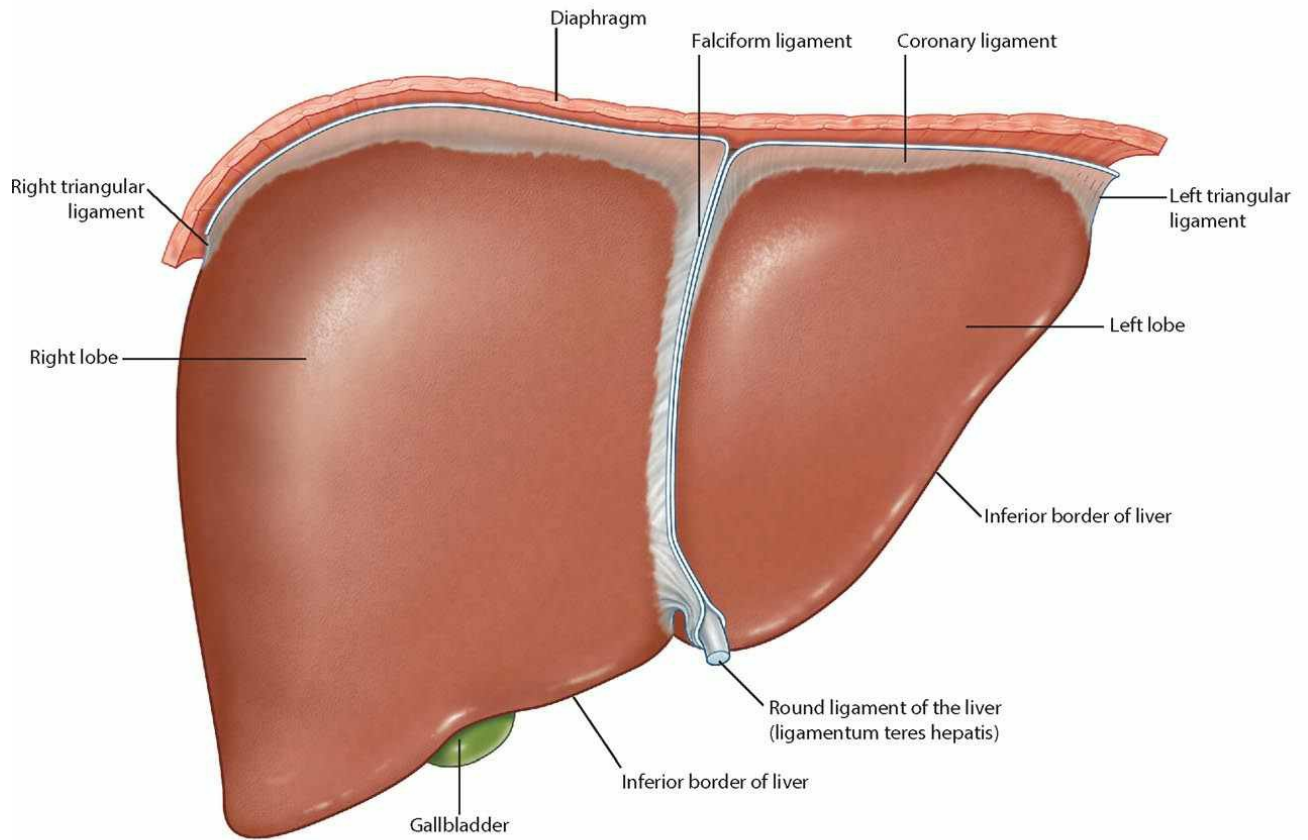
# Liver



Surface projection of the liver anterior view

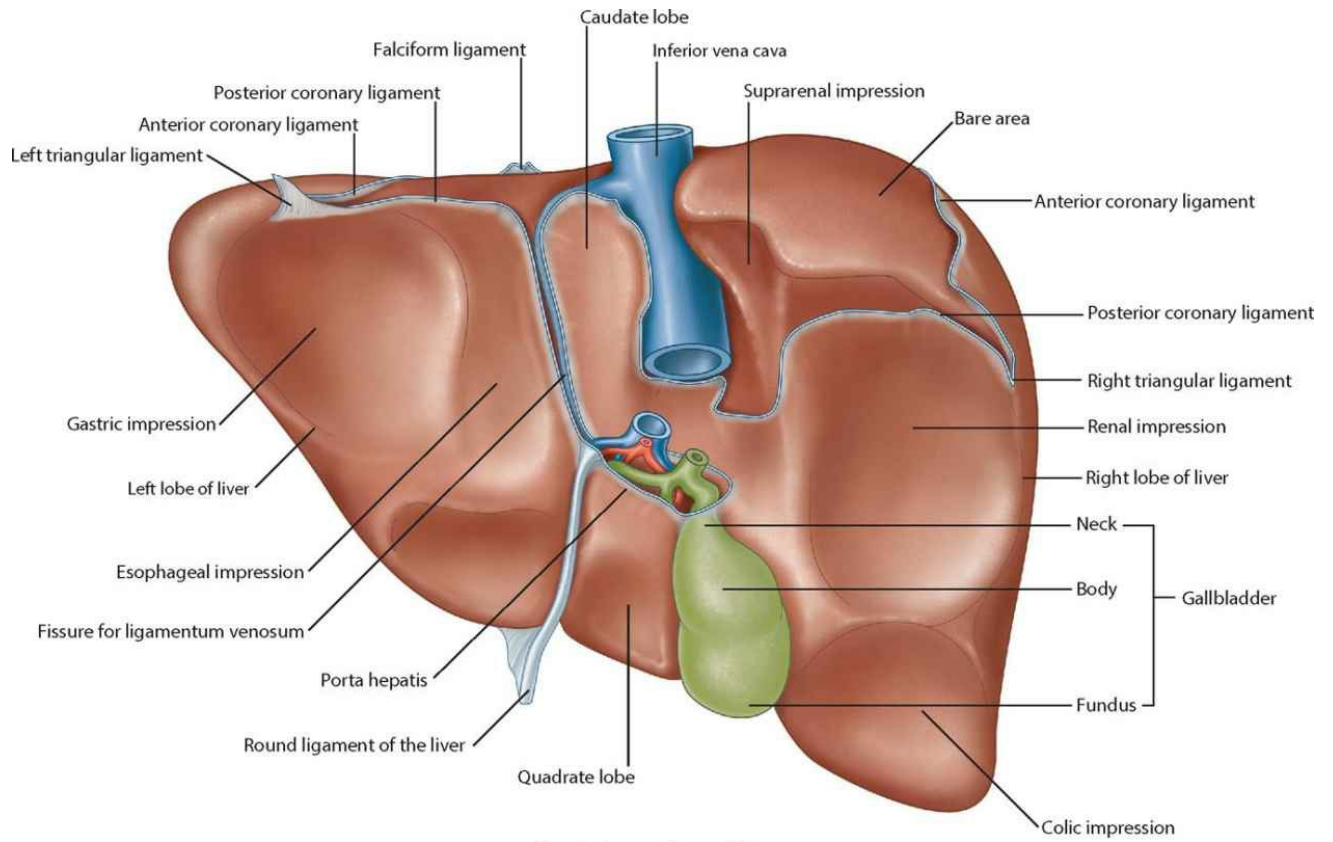


Location of the liver.  
CT image, with contrast, in coronal plane

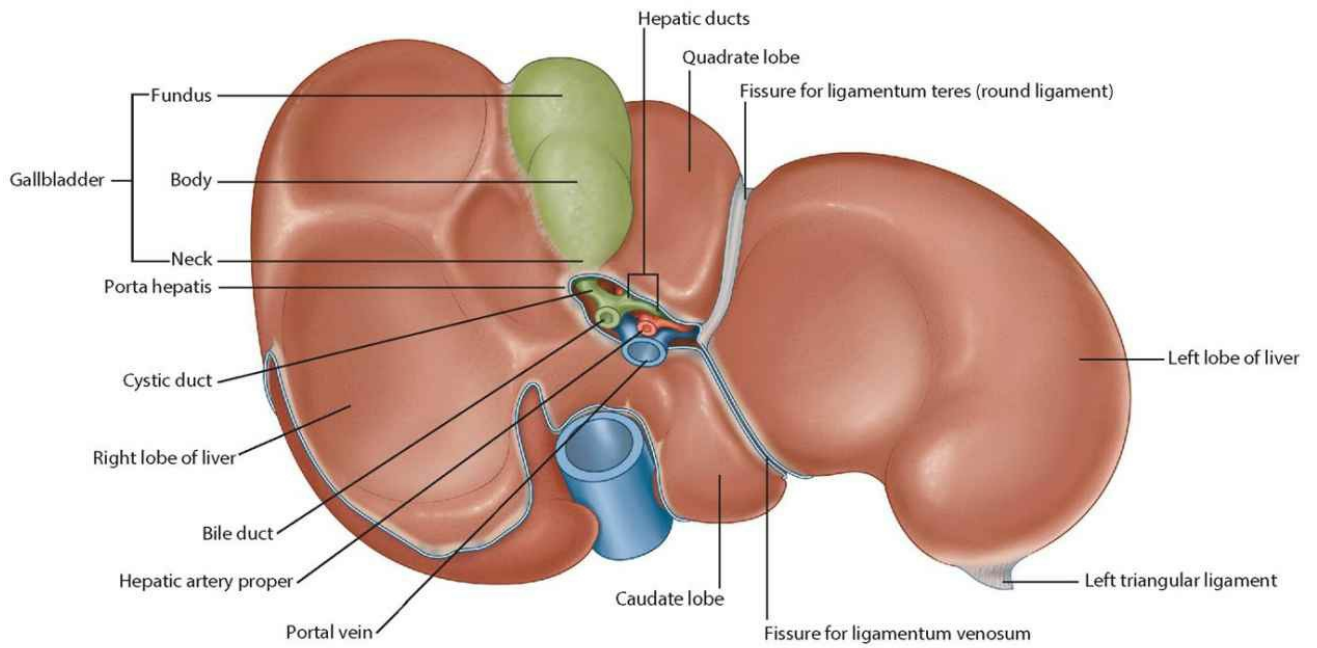


Anterior surface of liver



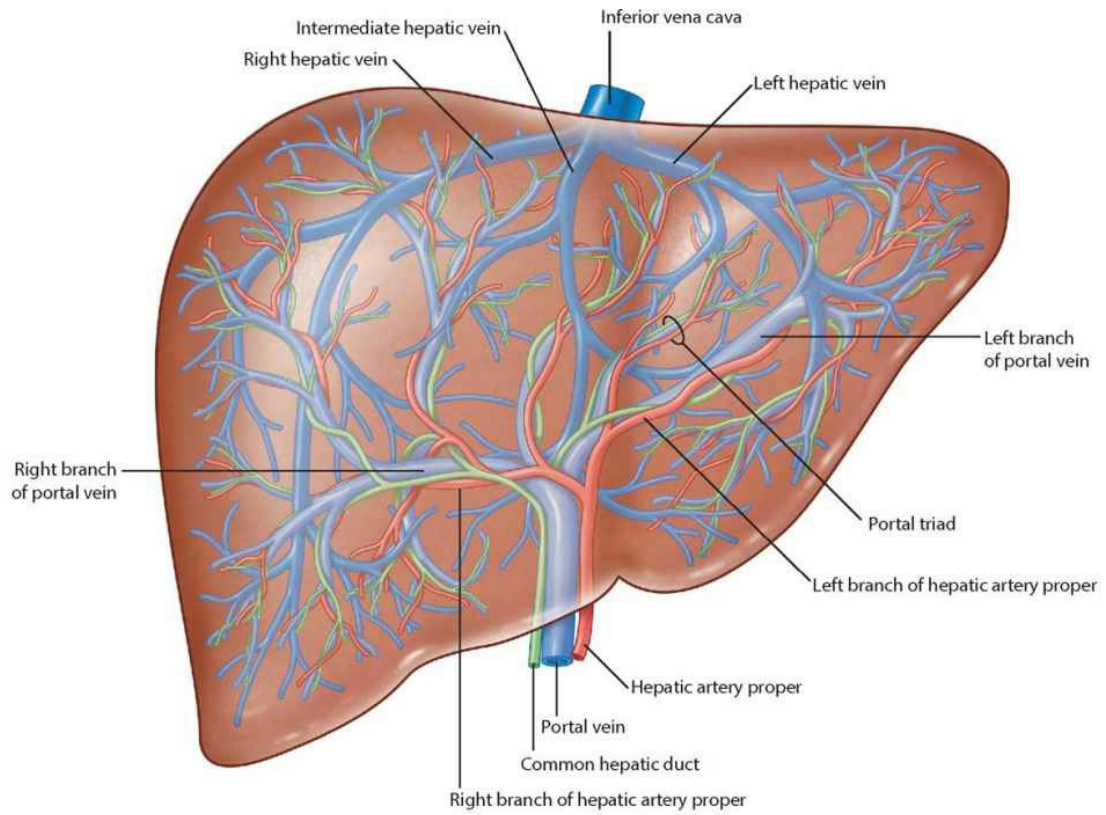


Posterior surface of liver

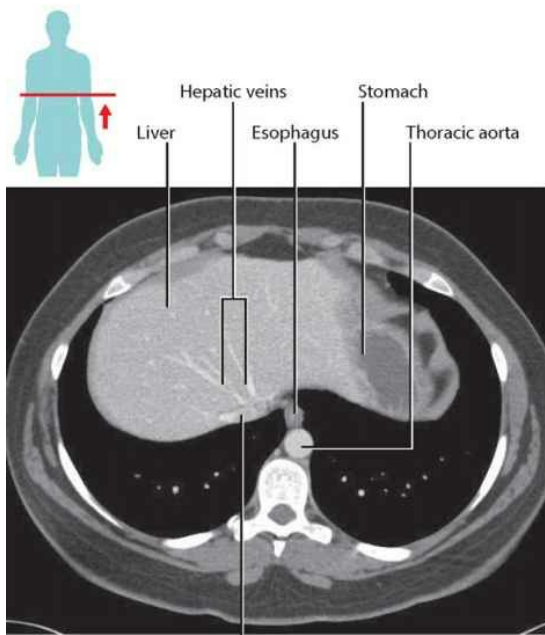


Visceral surface of liver

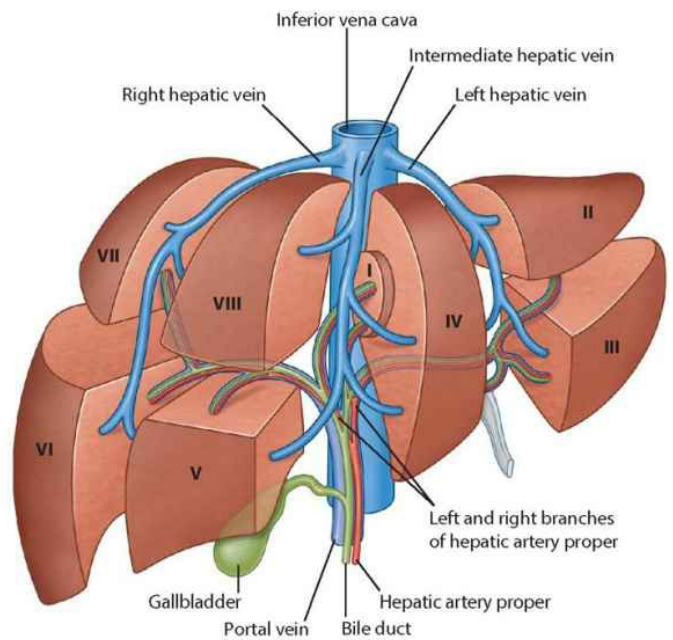
# Vessels of the liver



Anterior surface of liver with hepatic veins, portal vein, and associated vessels

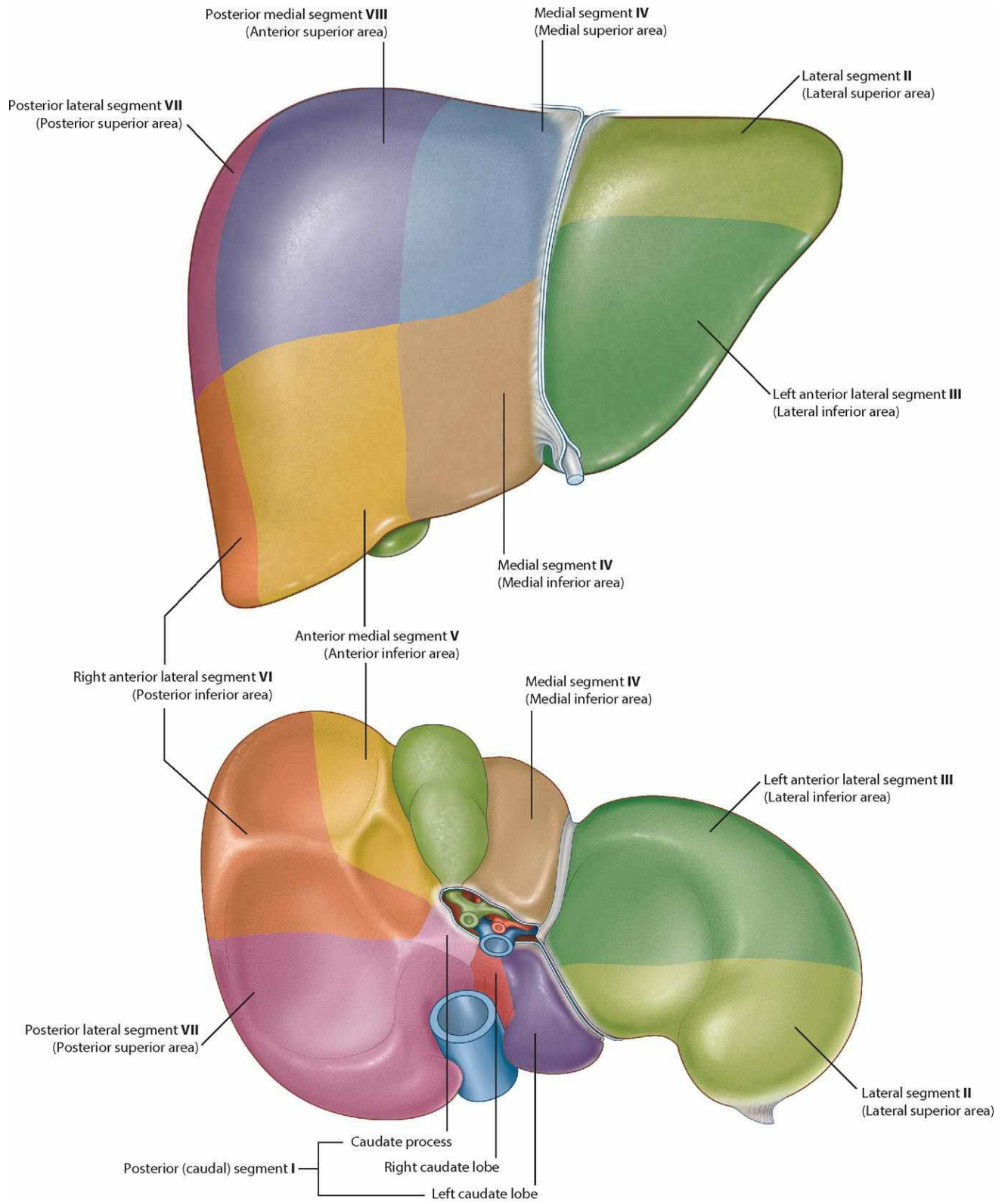


Hepatic veins entering the inferior vena cava in the substance of the liver.  
CT image, with contrast, in axial plane



Arrangement of the hepatic venous segments

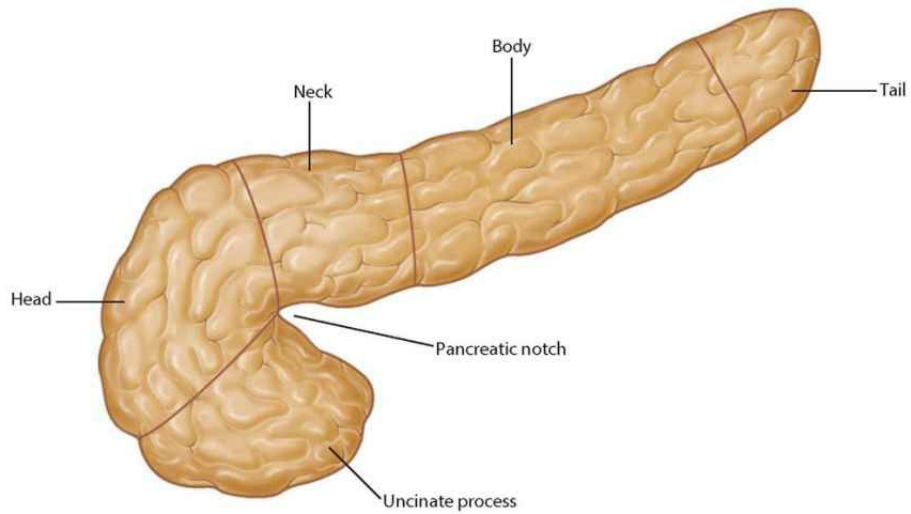
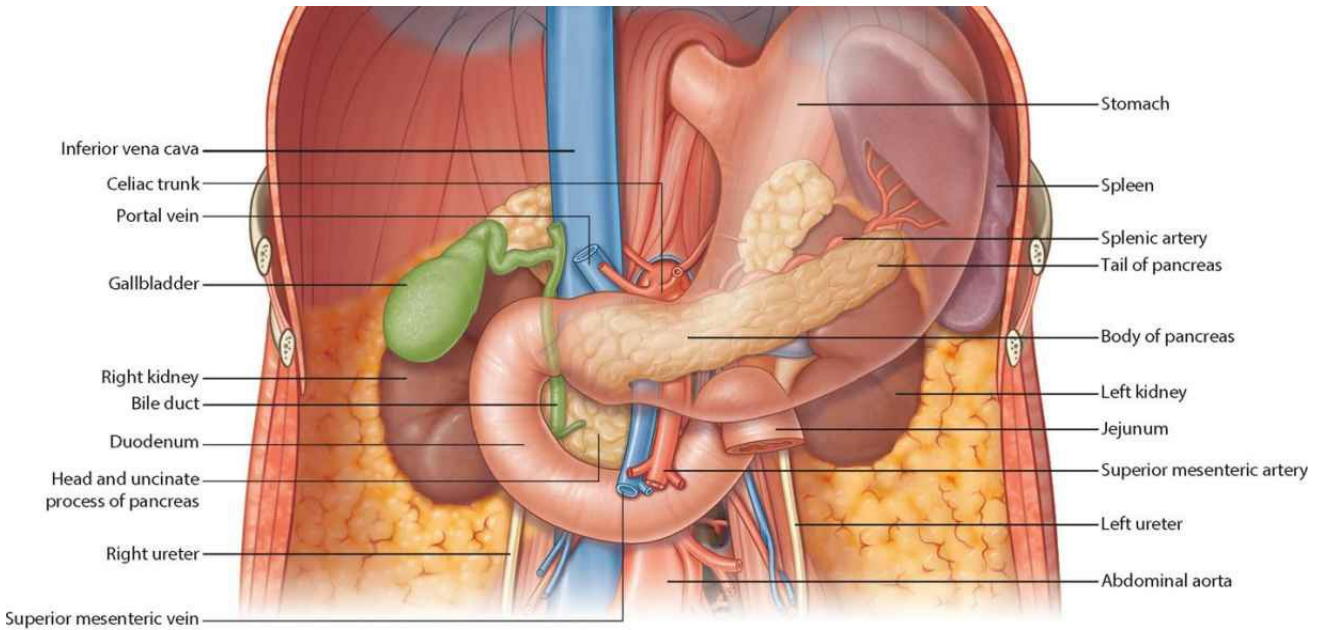
# Segments of the liver



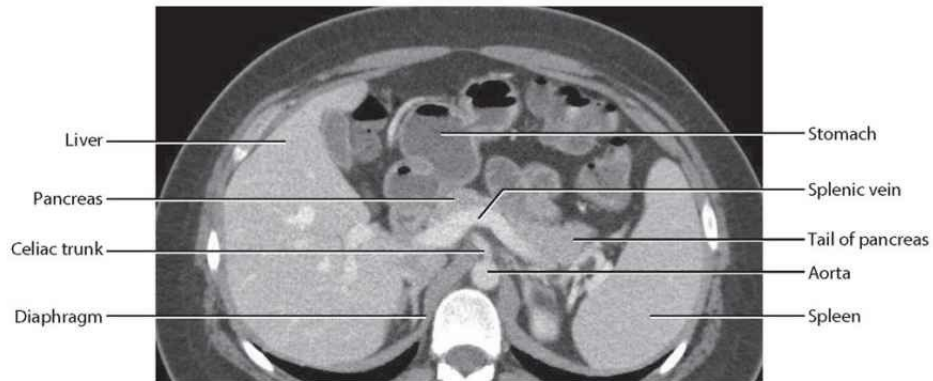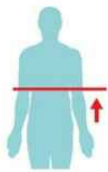
Segments of the liver shown on anterior and visceral surfaces



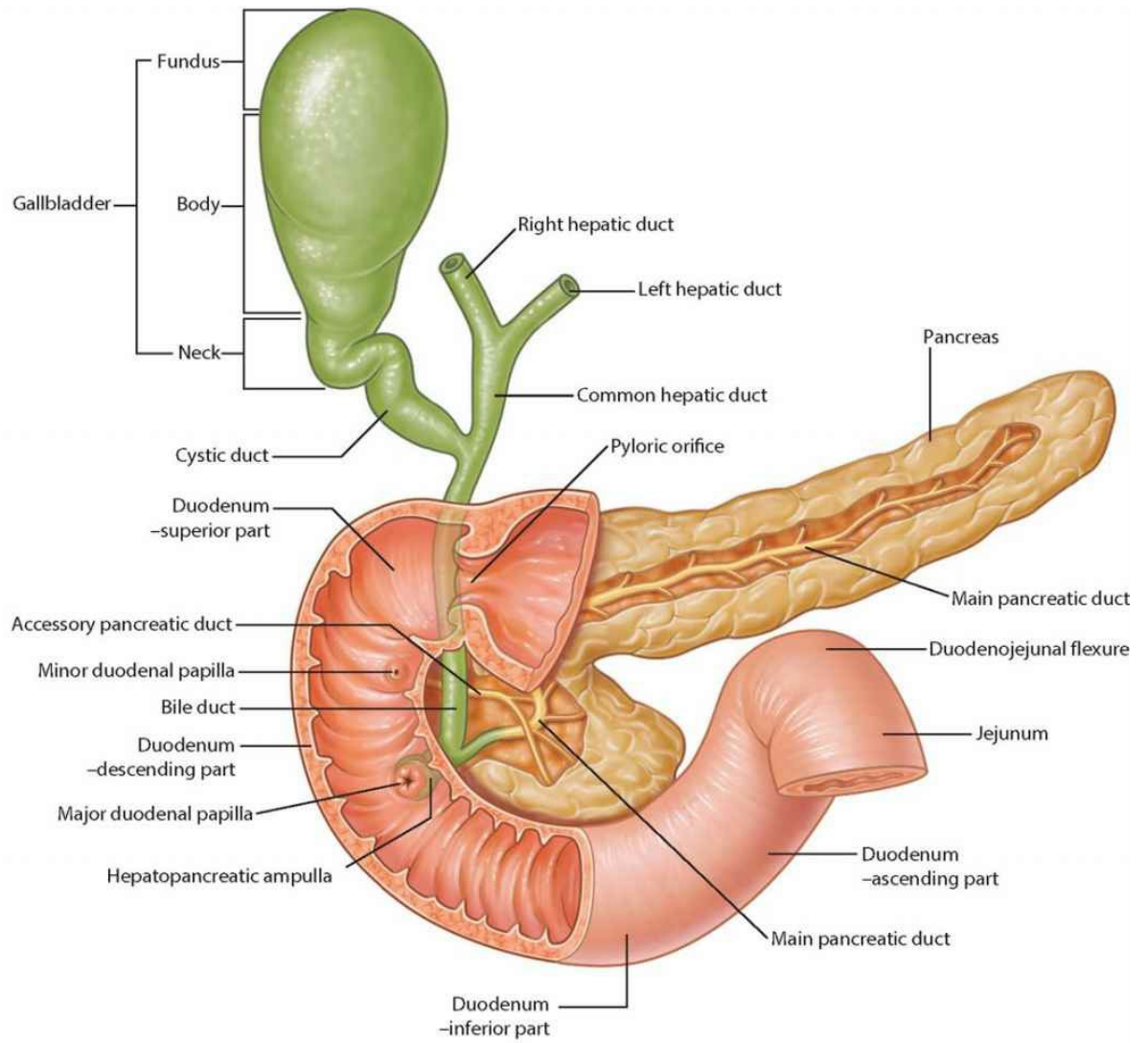
# Pancreas and gallbladder



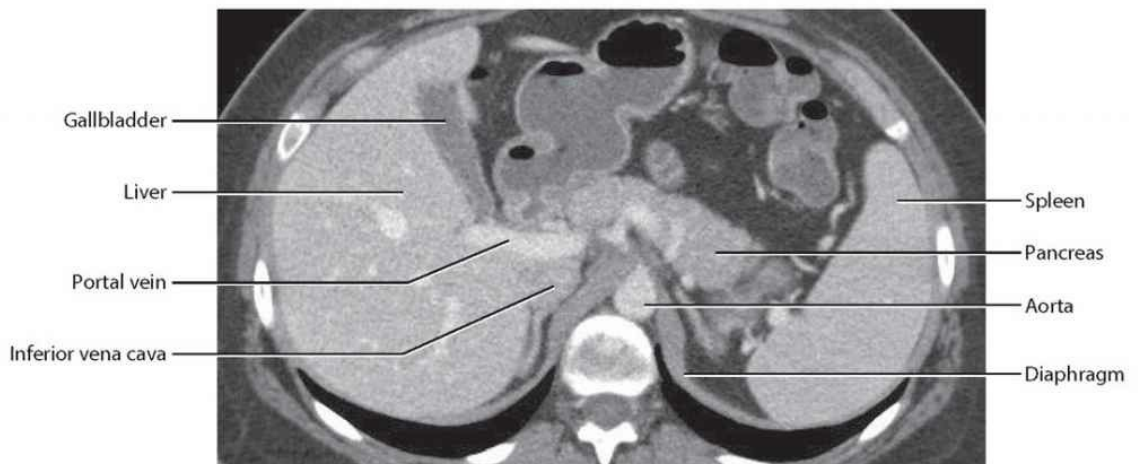
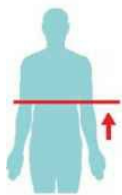
**Anterior surface of the pancreas**



**Pancreas.**  
CT image, with contrast, in axial plane

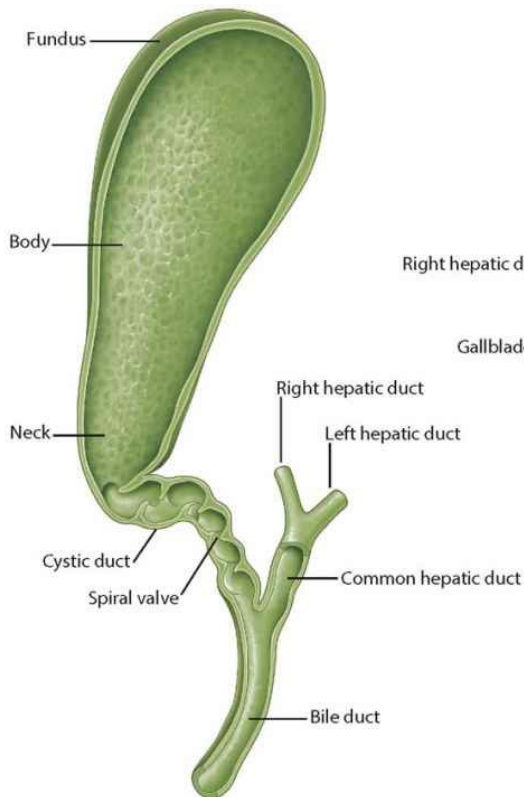


**Bile and pancreatic ducts**

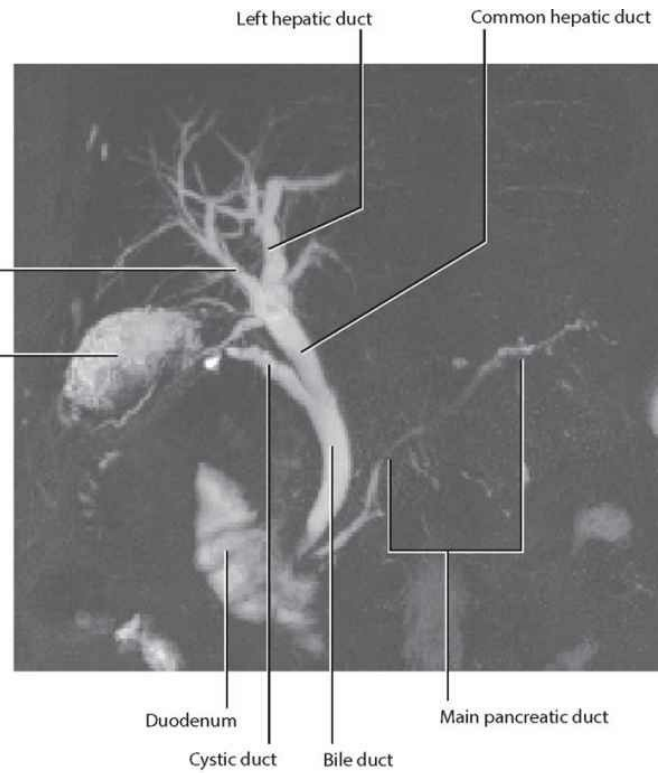

**Positioning of the gallbladder in relation to other structures.**  
CT image, with contrast, in axial plane

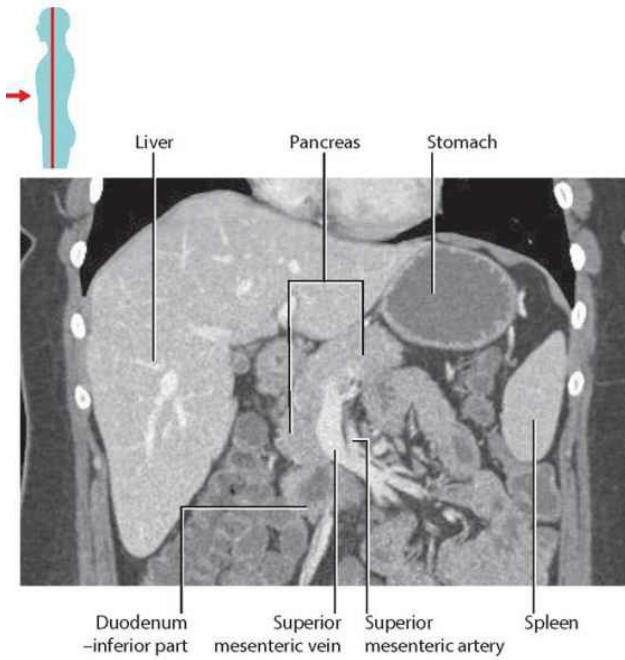




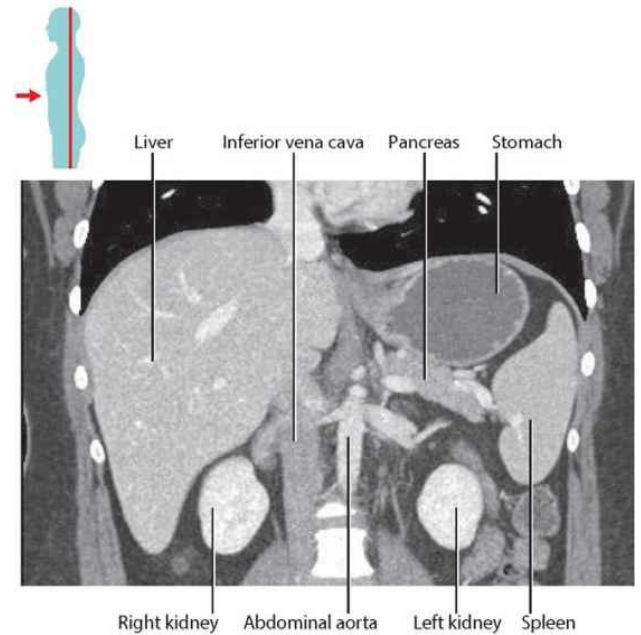
Section through gallbladder and bile ducts



**Bile duct system.**  
Percutaneous transhepatic cholangiogram

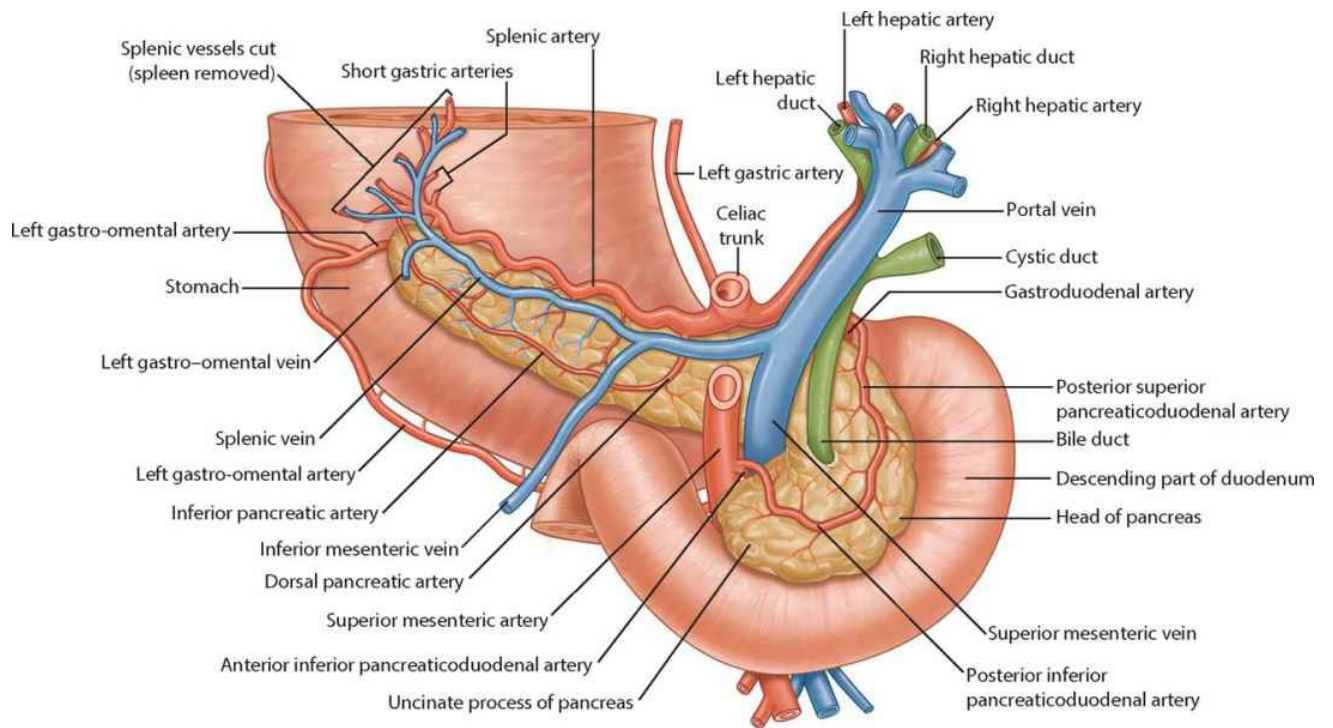


**Positioning of the pancreas in relation to other structures.**  
CT image, with contrast, in coronal plane

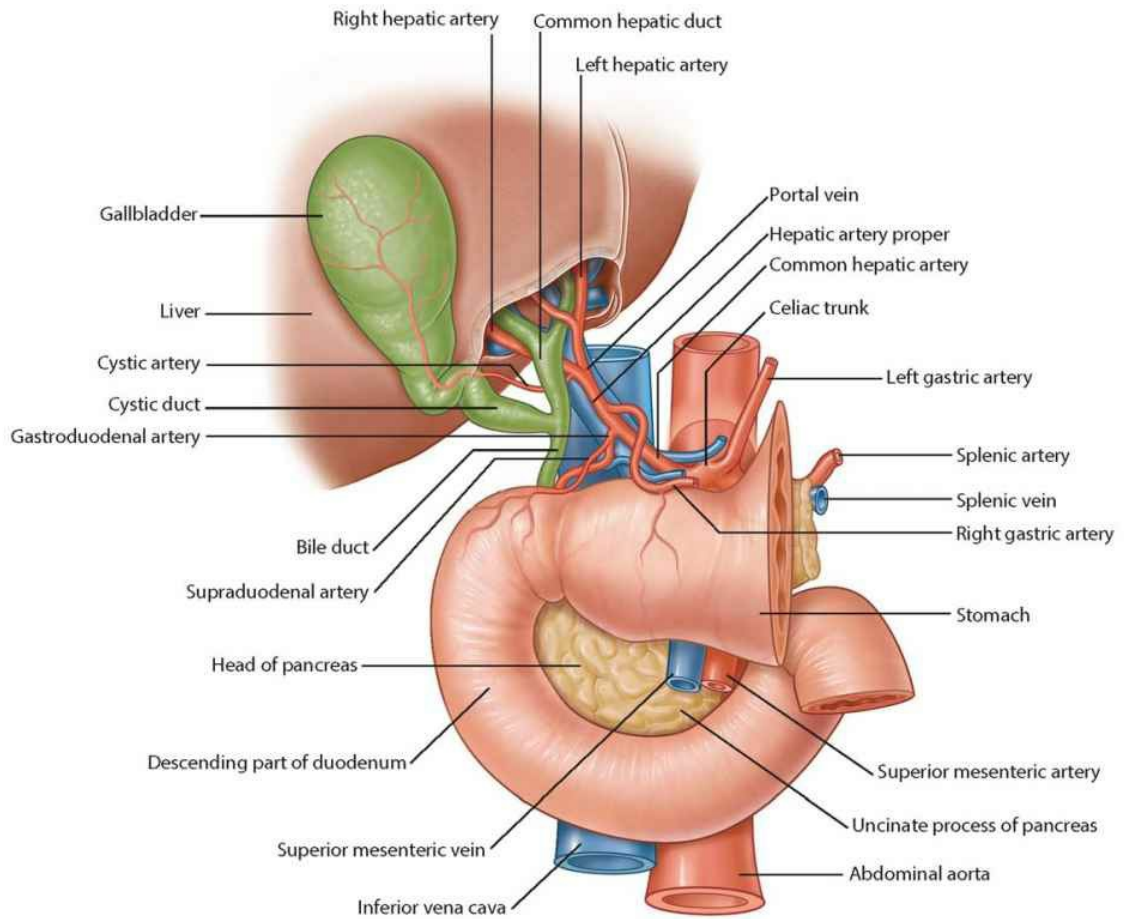


**Relationship of pancreas to the stomach and spleen.**  
CT image, with contrast, in coronal plane

# Vasculature of pancreas and duodenum



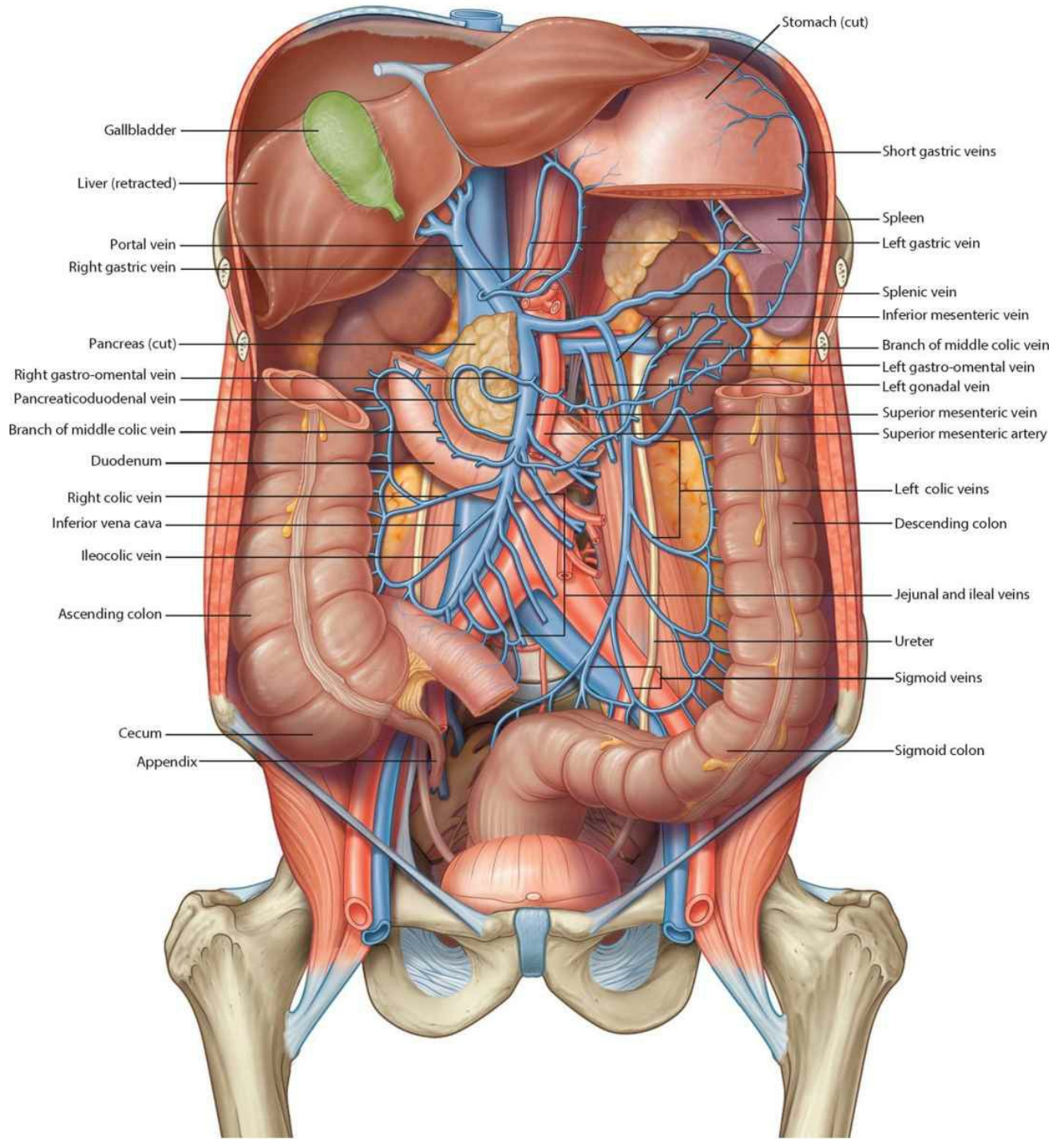
**Vasculature of the pancreas posterior view**



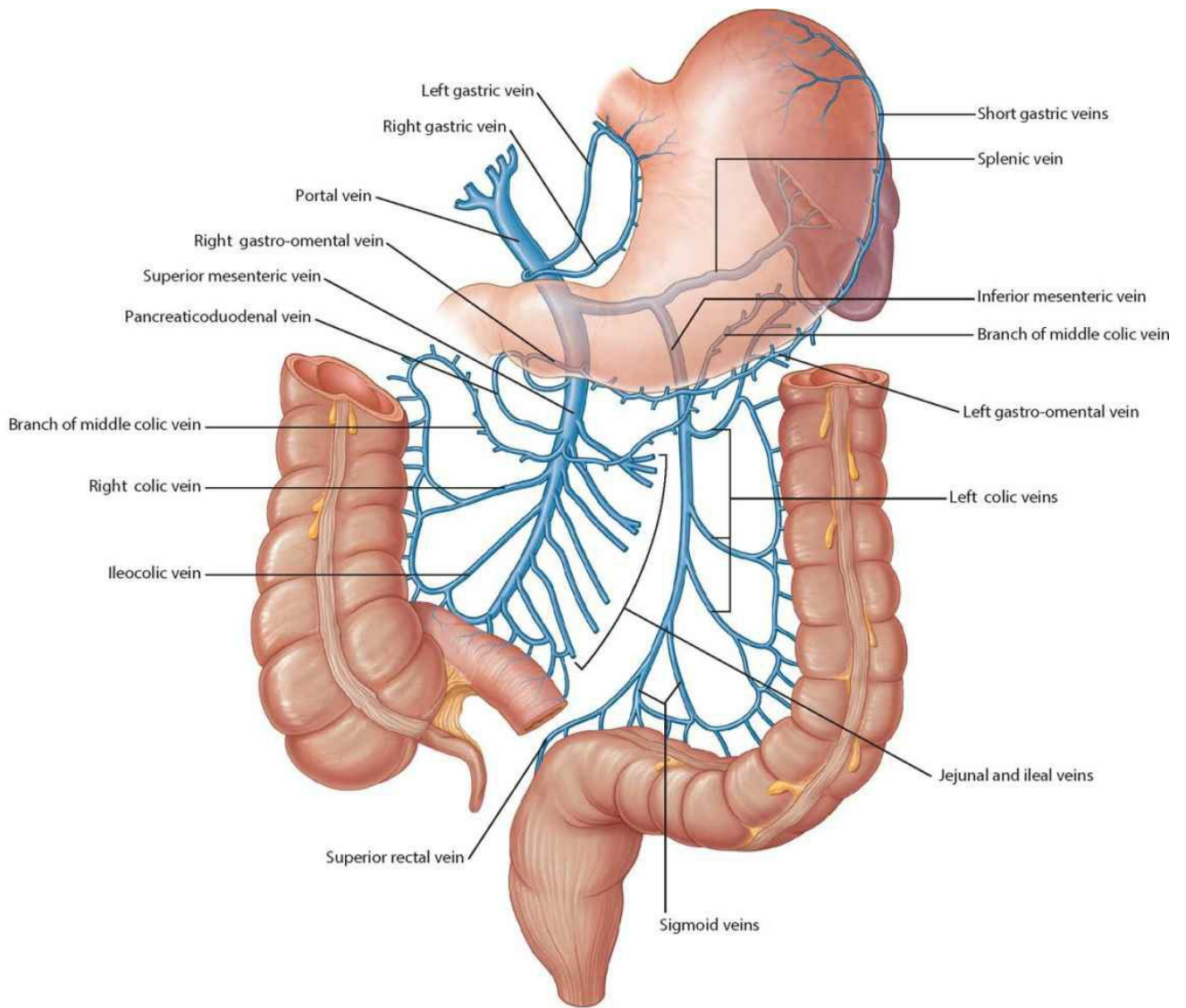
**Distribution of the common hepatic artery**

# **Venous drainage of viscera**

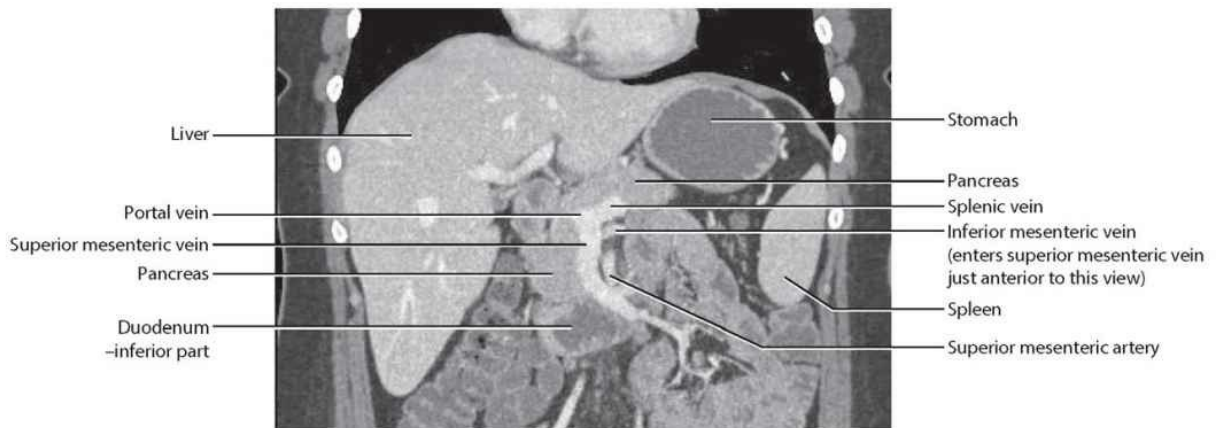
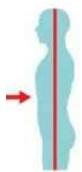




**Venous drainage of the abdominal portion of the gastrointestinal tract in situ**

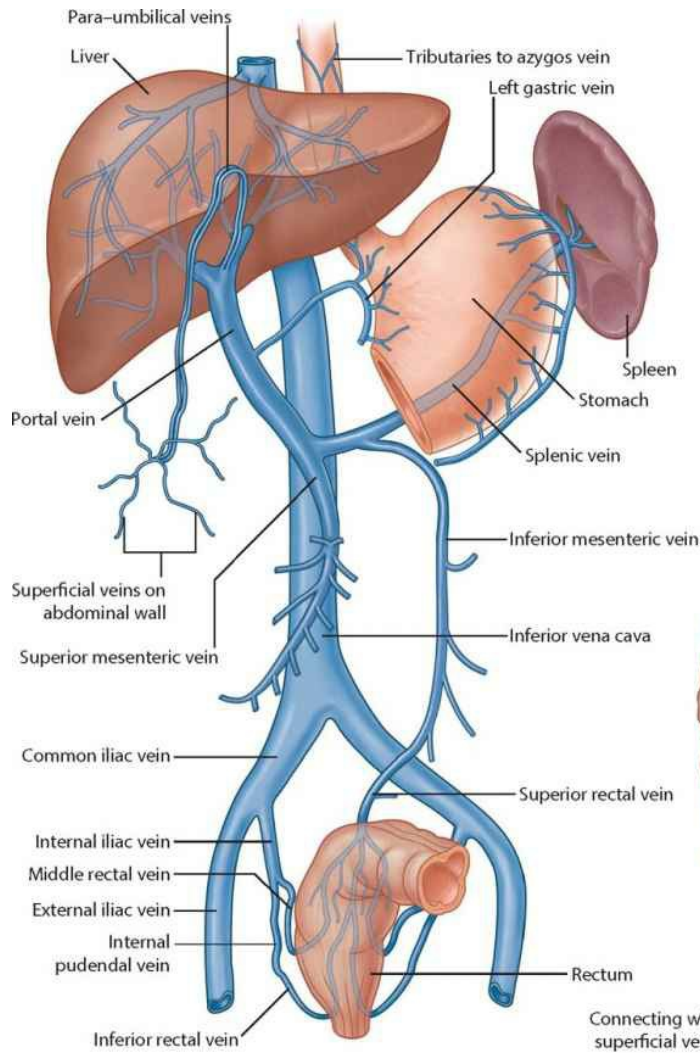


**Venous drainage of the abdominal portion of the gastrointestinal tract**



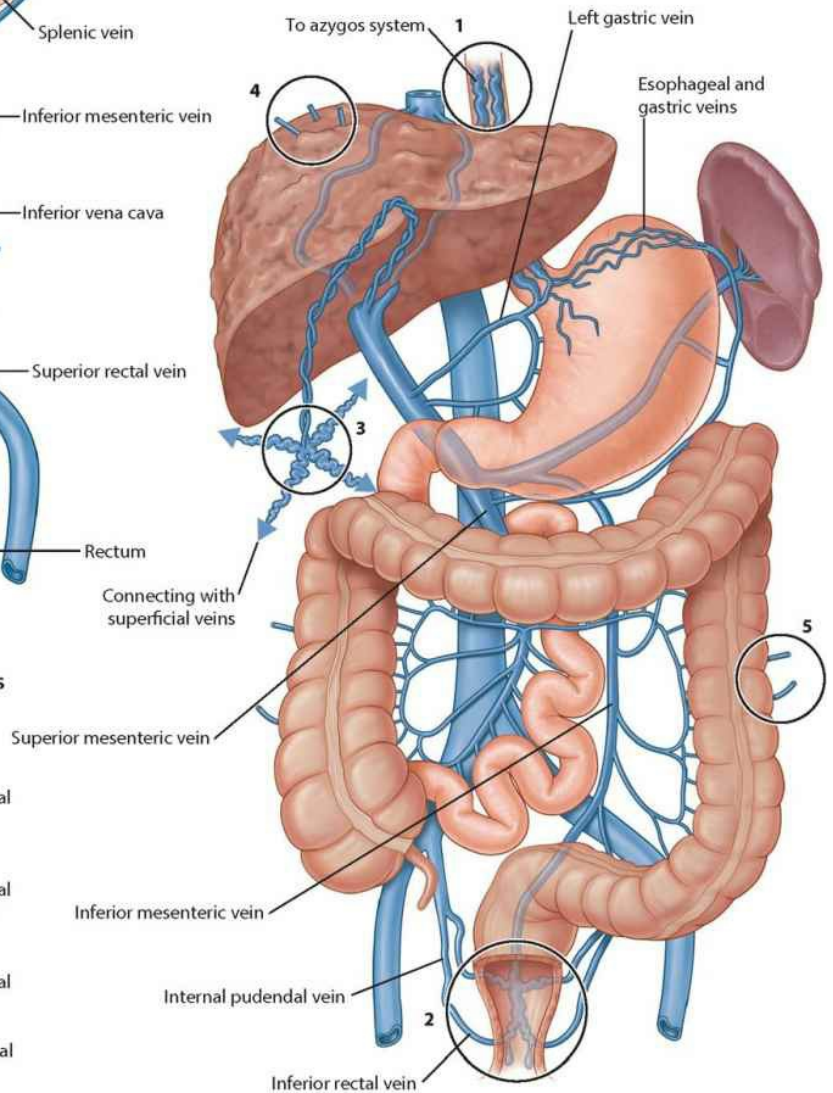
**Formation of the portal vein.**  
CT image, with contrast, in coronal plane

# Portosystemic anastomoses



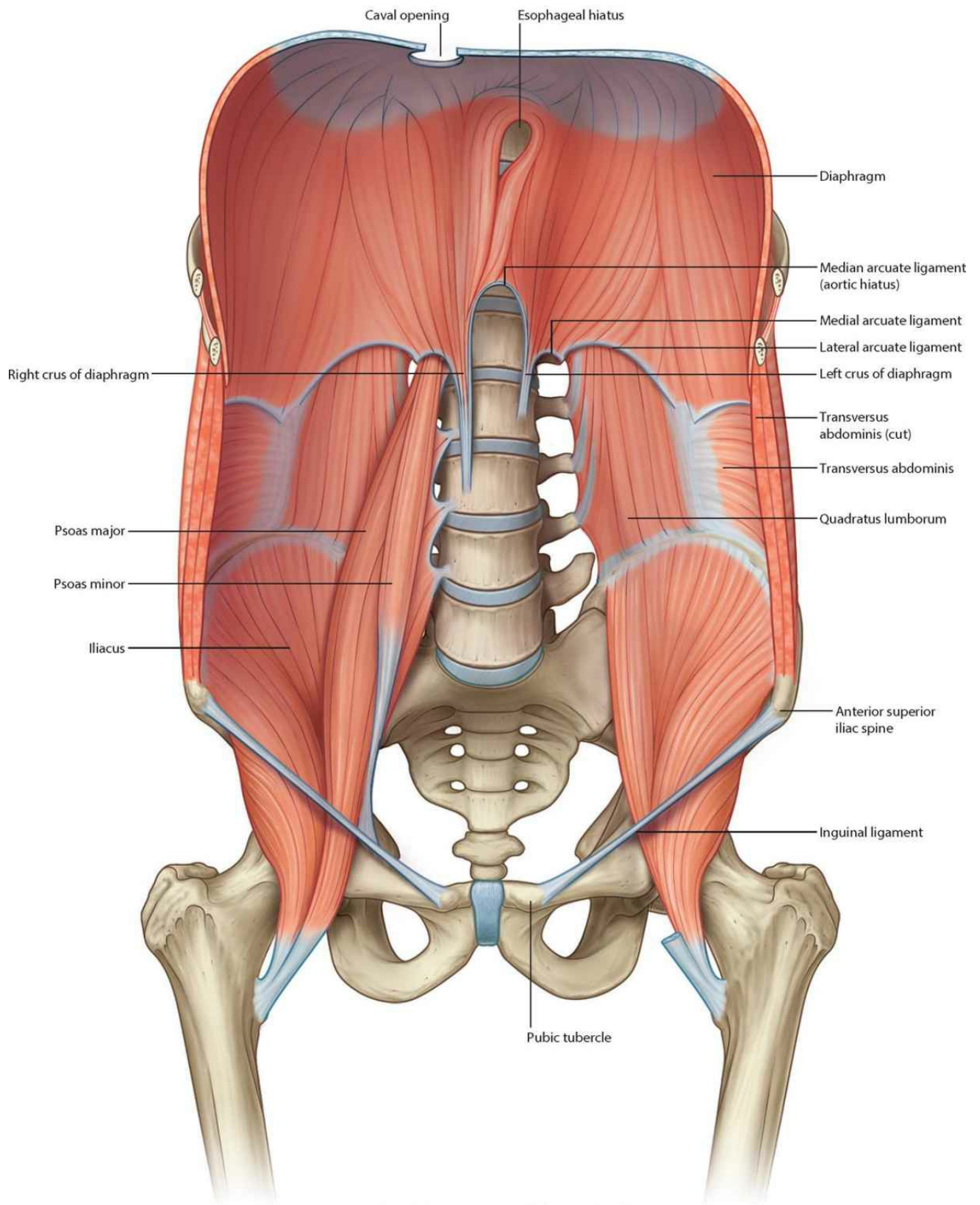
**Portosystemic anastomoses**

- 1 Esophageal varices: swollen connections between systemic and portal systems at inferior end of esophagus
- 2 Varices at the anorectal junction: swelling connections between systemic and portal systems at inferior end of rectum and anal canal
- 3 Caput medusae: swollen connections between systemic and portal systems around umbilicus
- 4 Swollen connections between systemic and portal systems at bare area of liver
- 5 Swollen connections between veins associated with retroperitoneal parts of the gastro-intestinal tract and the body wall



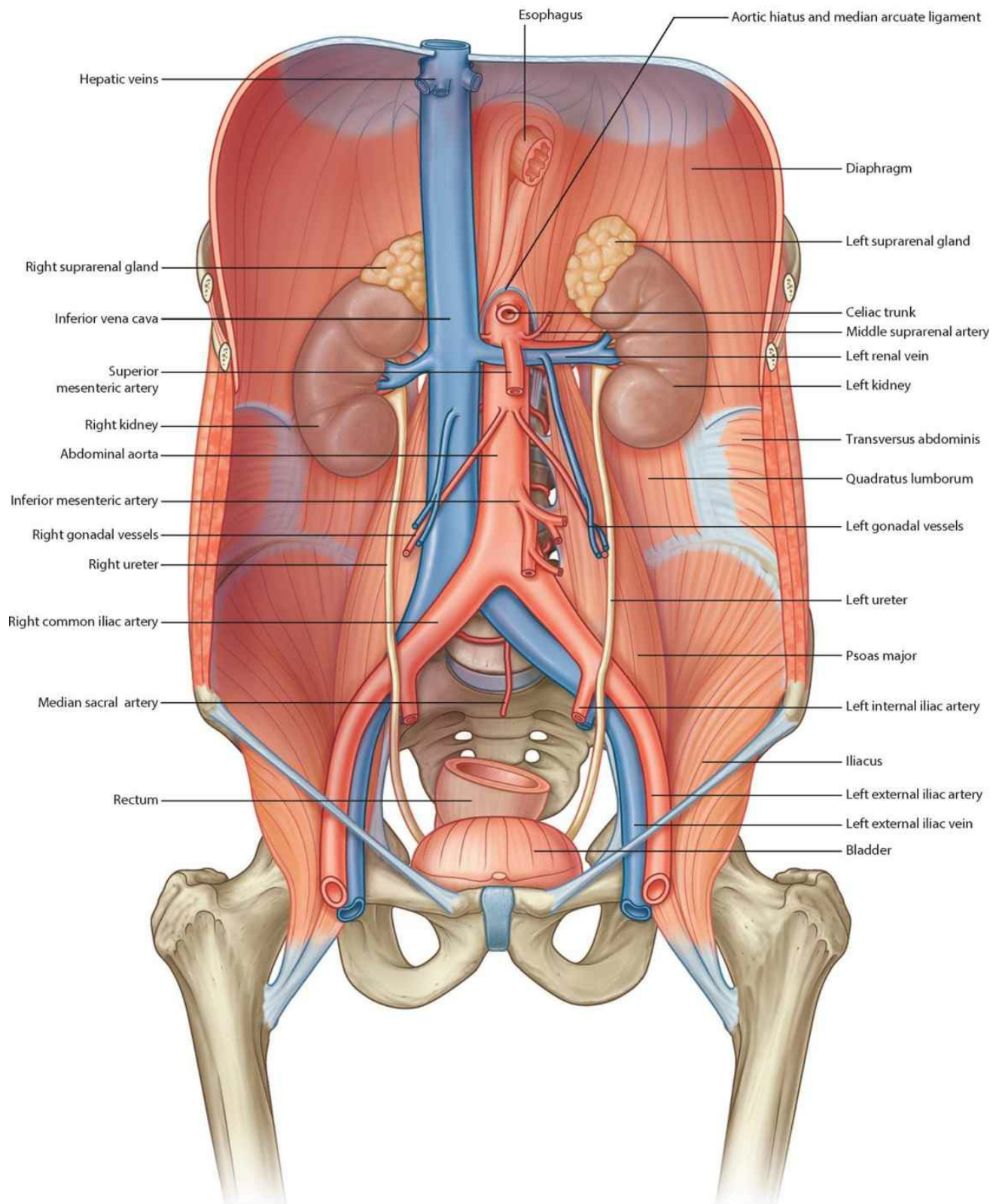
**Venous enlargement in portal hypertension(varices)**

## Posterior wall



**Muscles of the posterior abdominal wall**

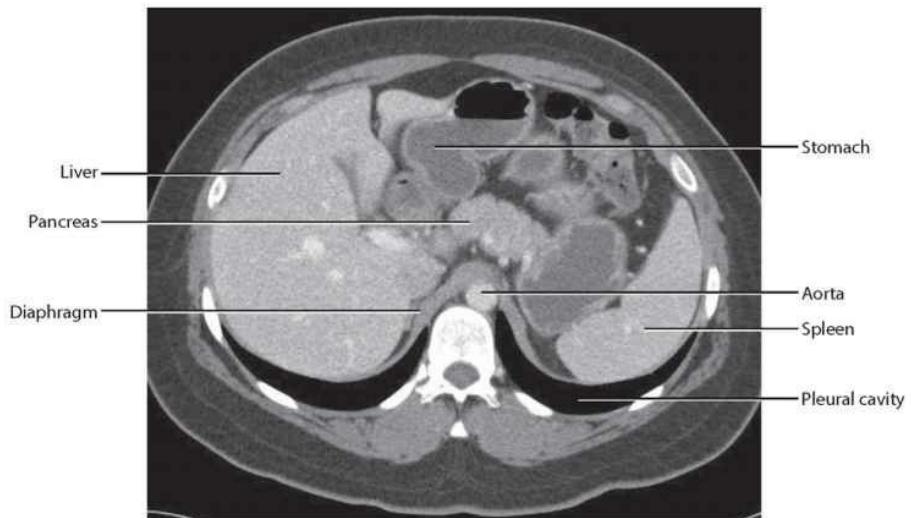
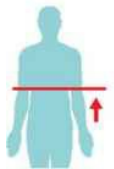
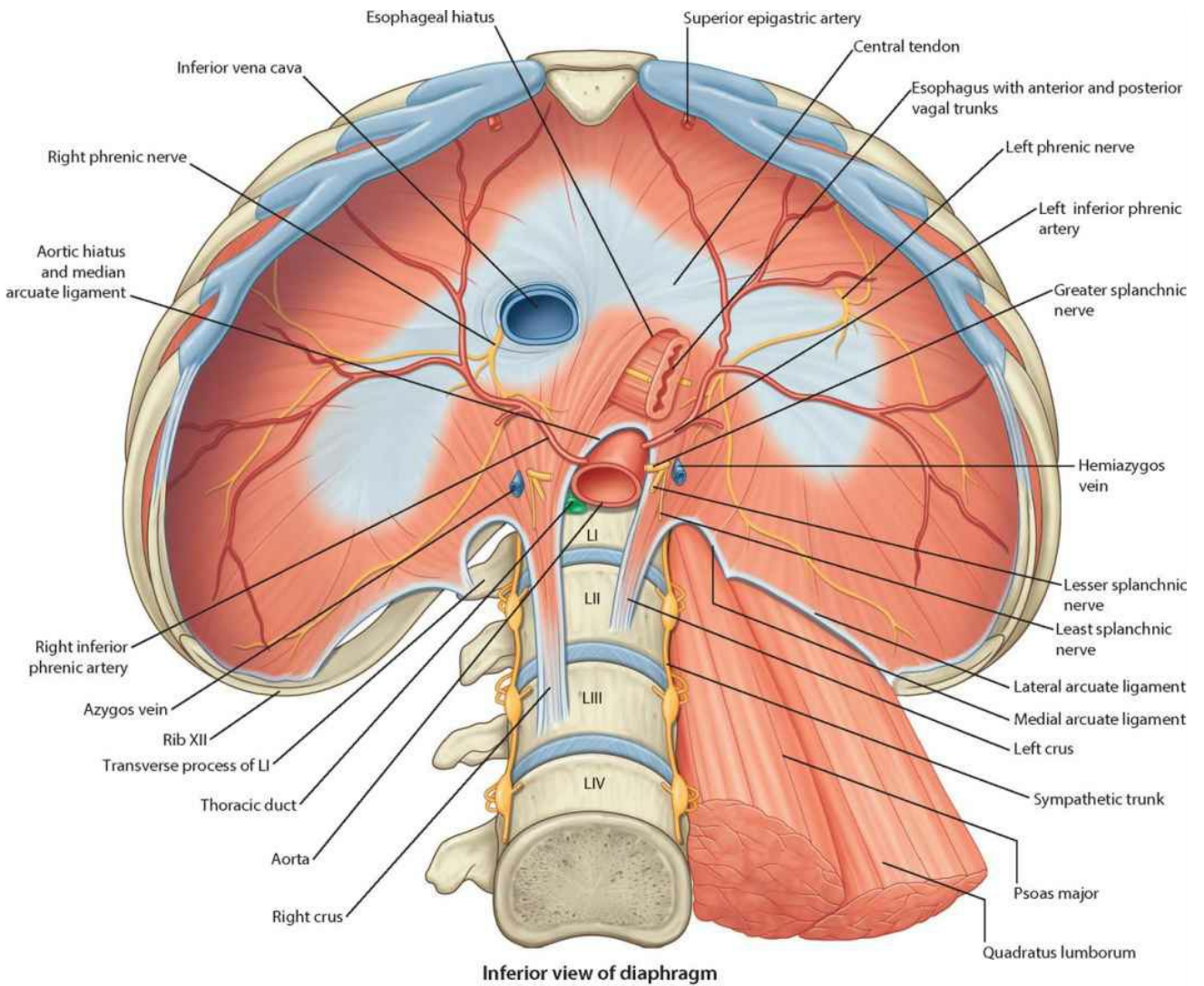
## **Vessels of the posterior wall**



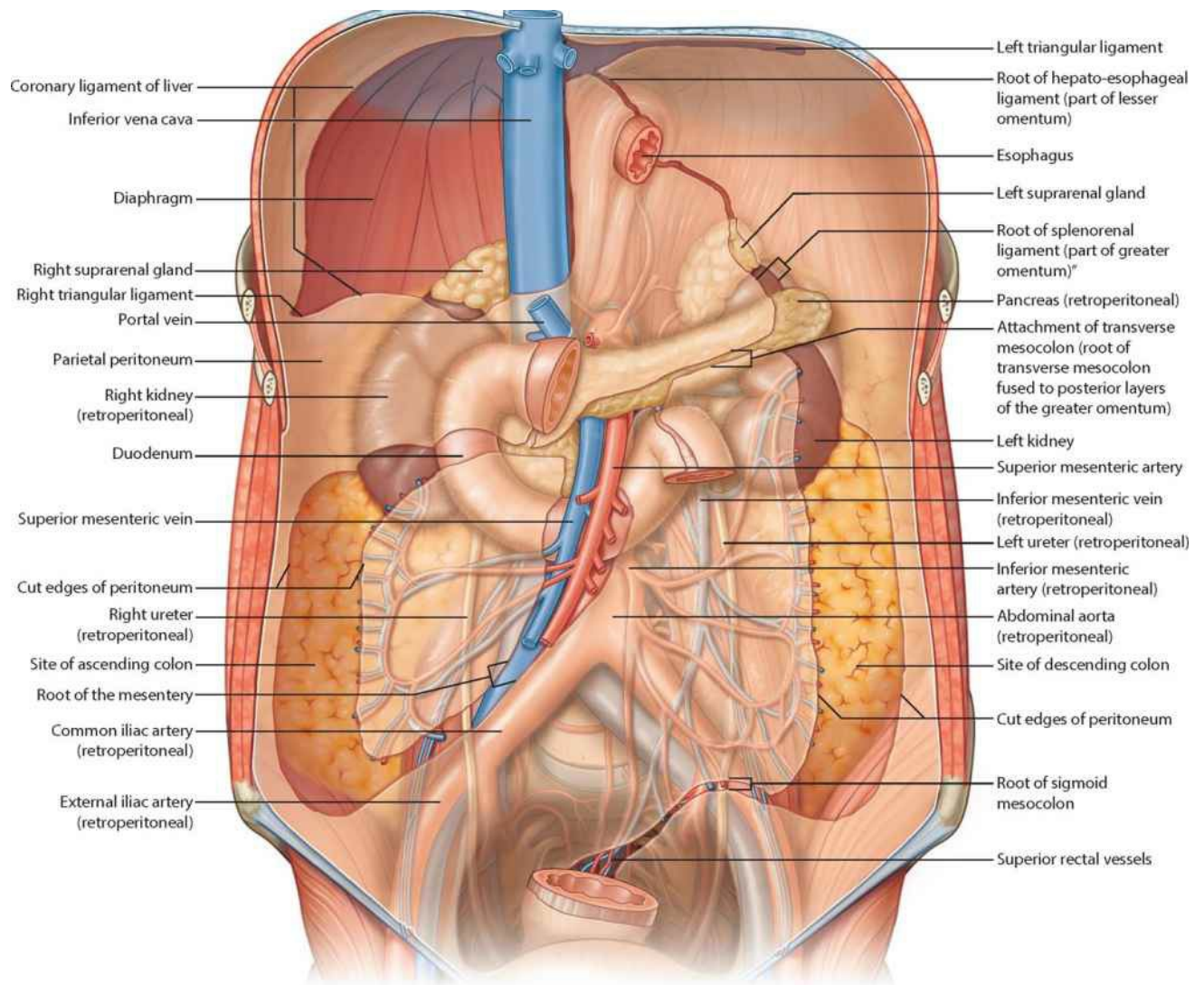
Vessels and their relationship to the posterior abdominal wall



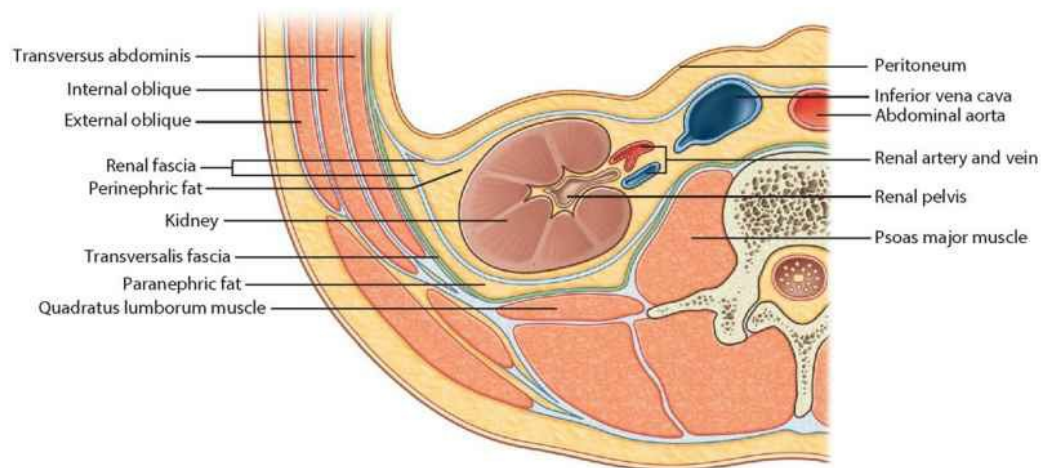
# Diaphragm



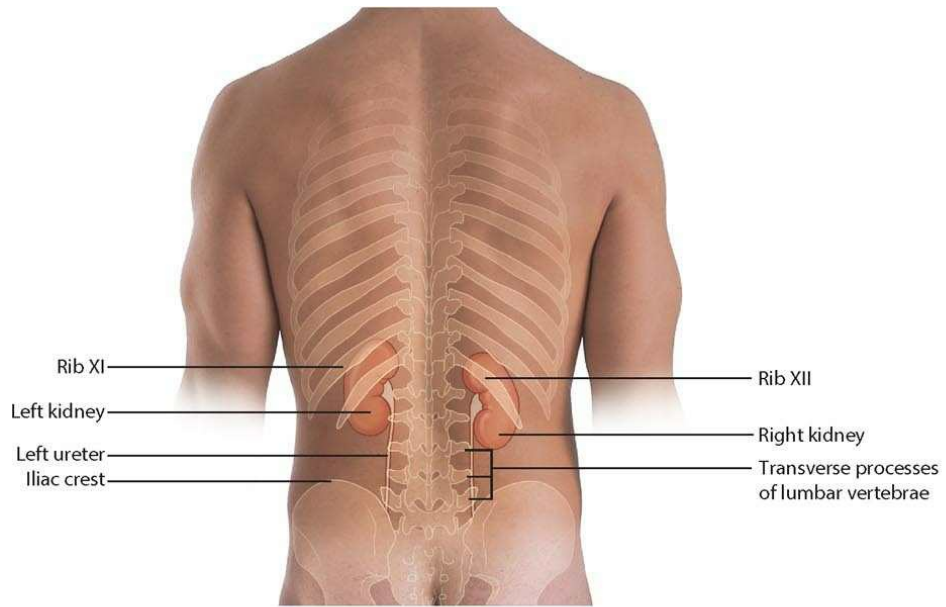
# Kidneys



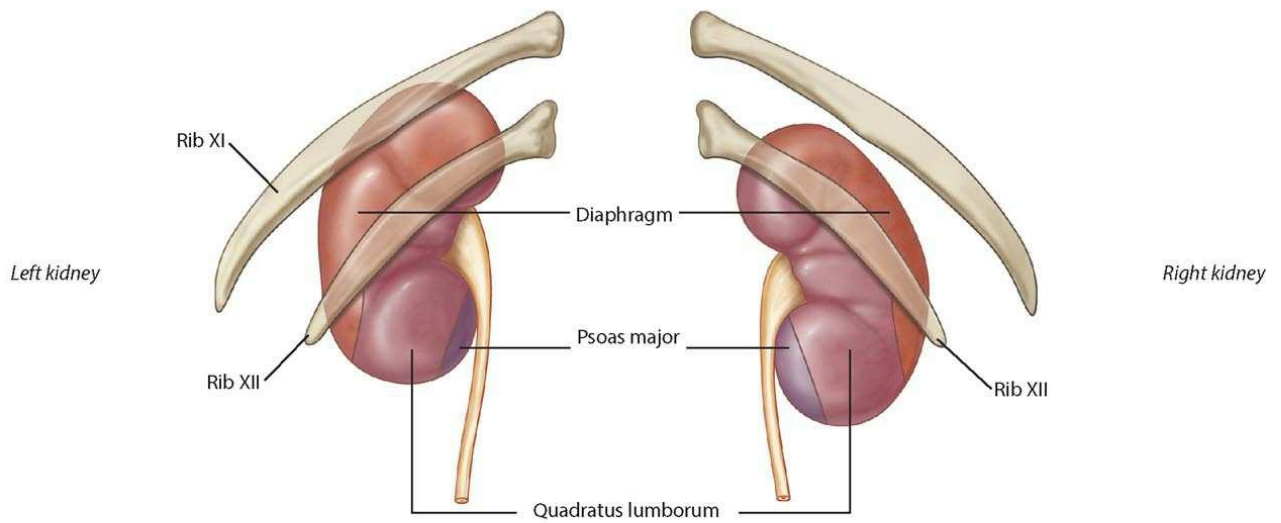
**Peritoneum and the retroperitoneal position of the kidneys**



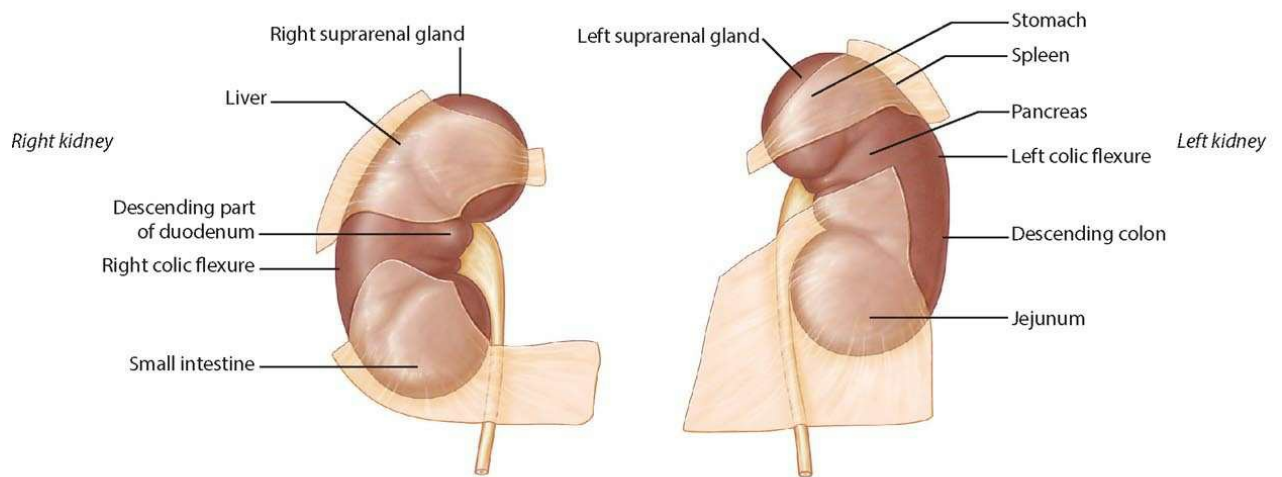
**Organization of fat and fascia surrounding the kidneys**



Surface projection of the kidneys and ureters (posterior view)



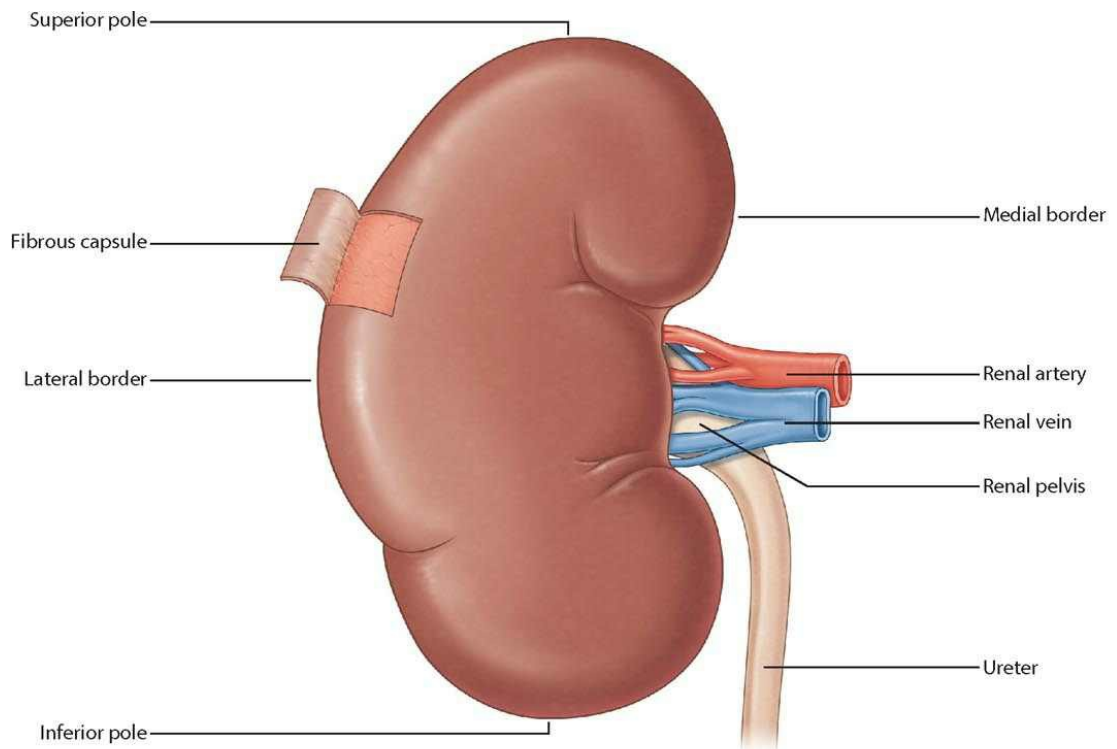
Structures related to the posterior surface of each kidney



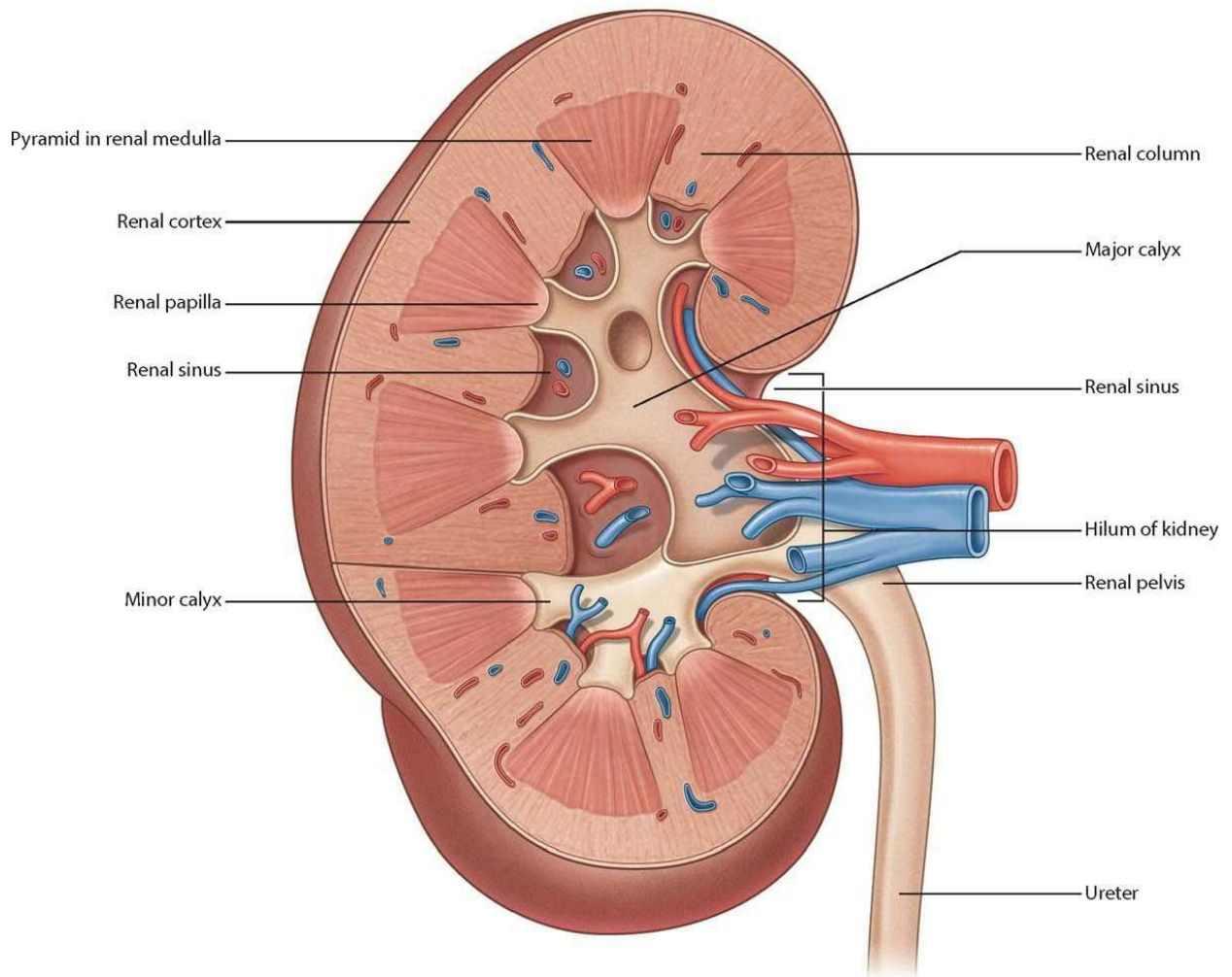
Structures related to the anterior surface of each kidney



# Gross structure of kidneys



**Anterior surface of right kidney**

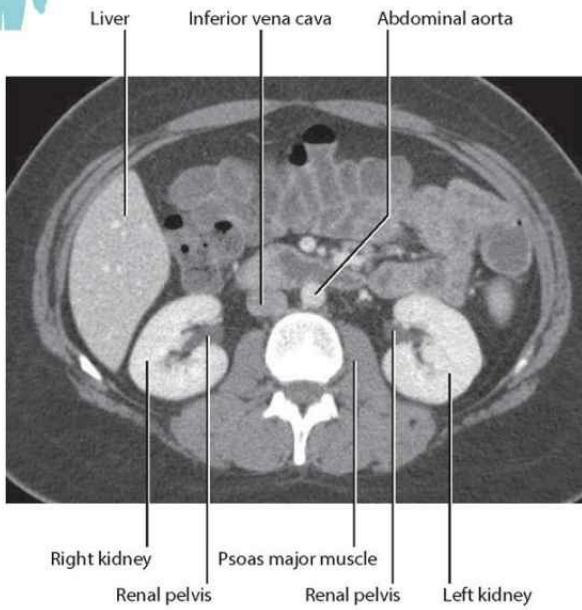
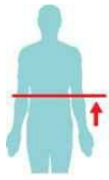


**Internal structure of the right kidney**

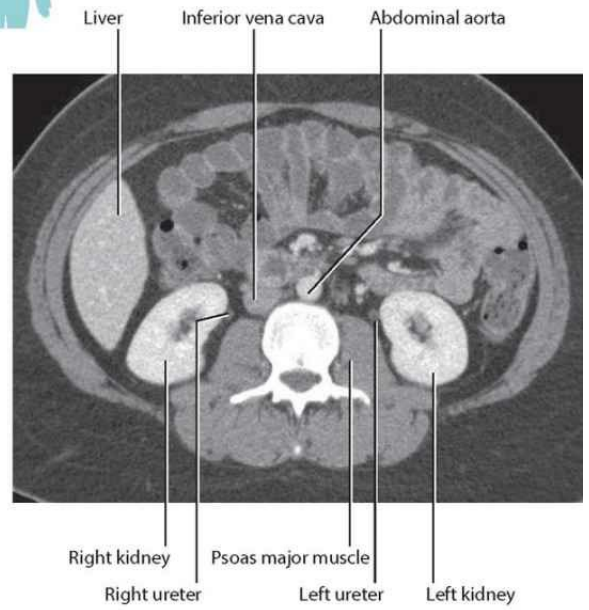
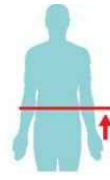




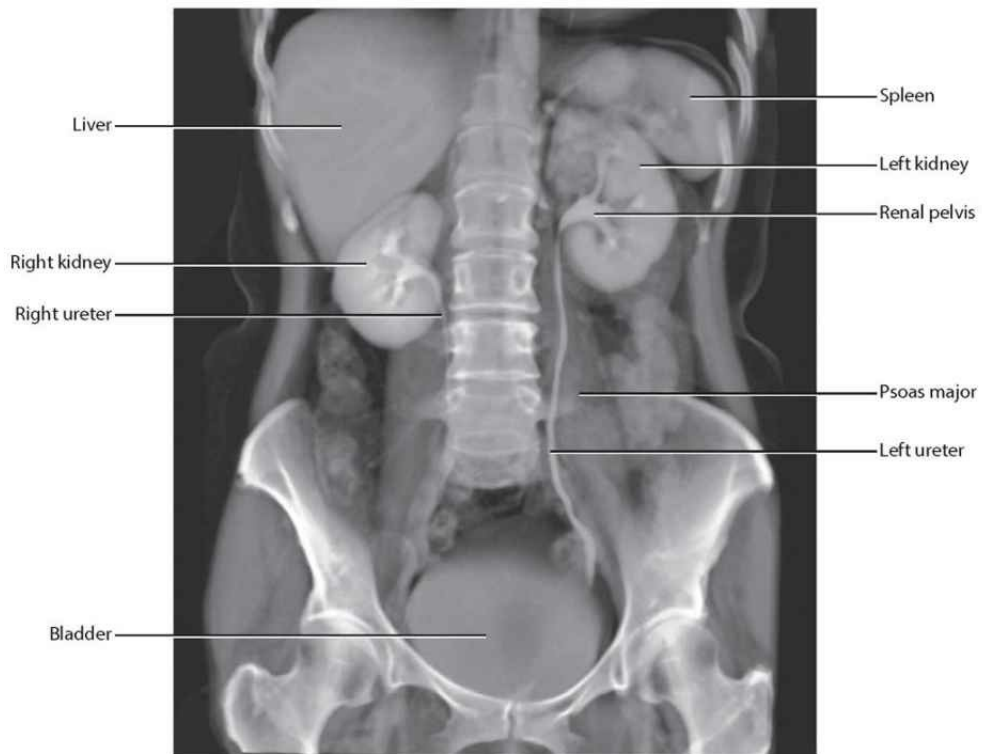
# Kidneys: imaging



**Renal pelvis.**  
CT image, with contrast, in axial plane

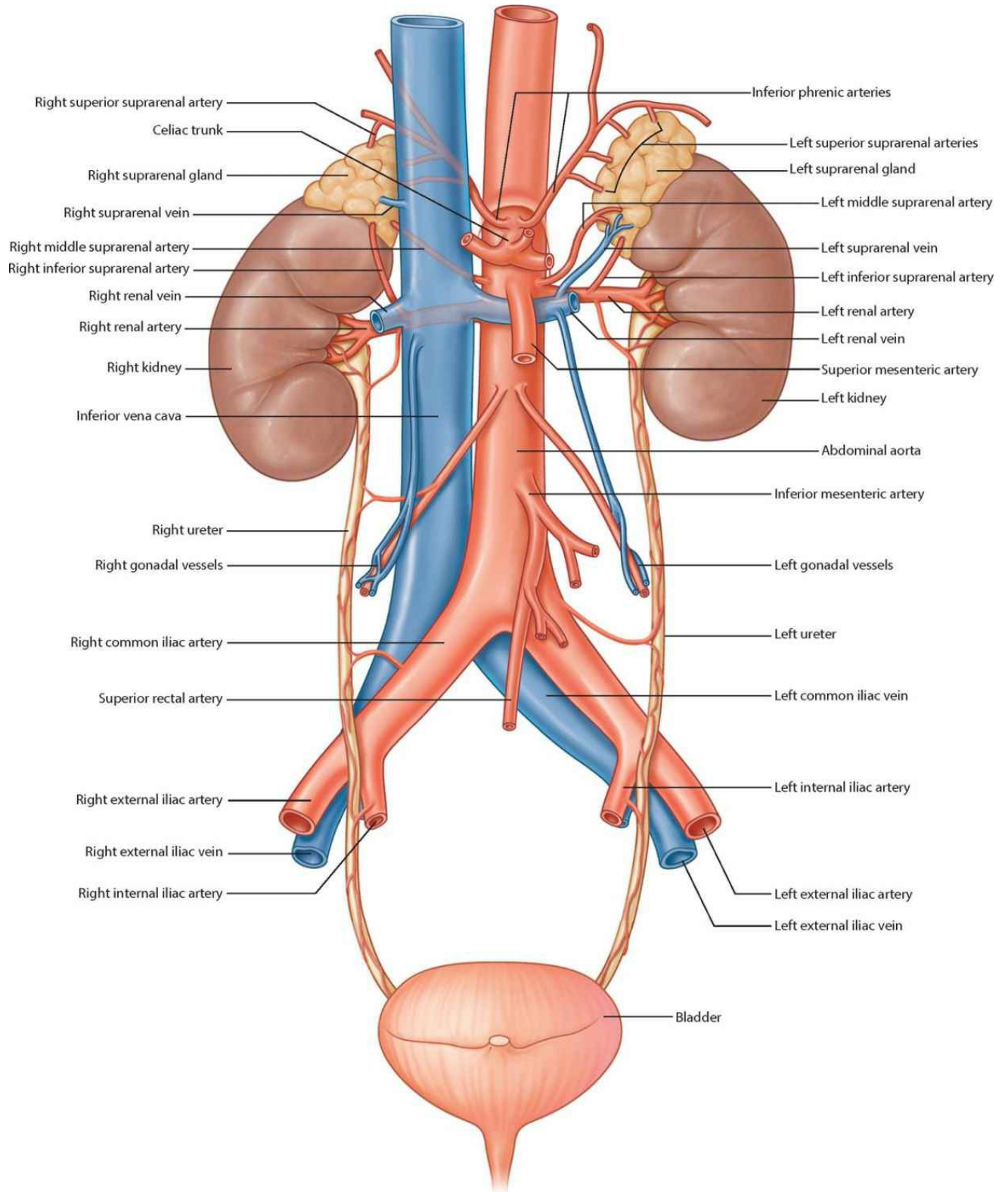


**Location of ureters.**  
CT image, with contrast, in axial plane

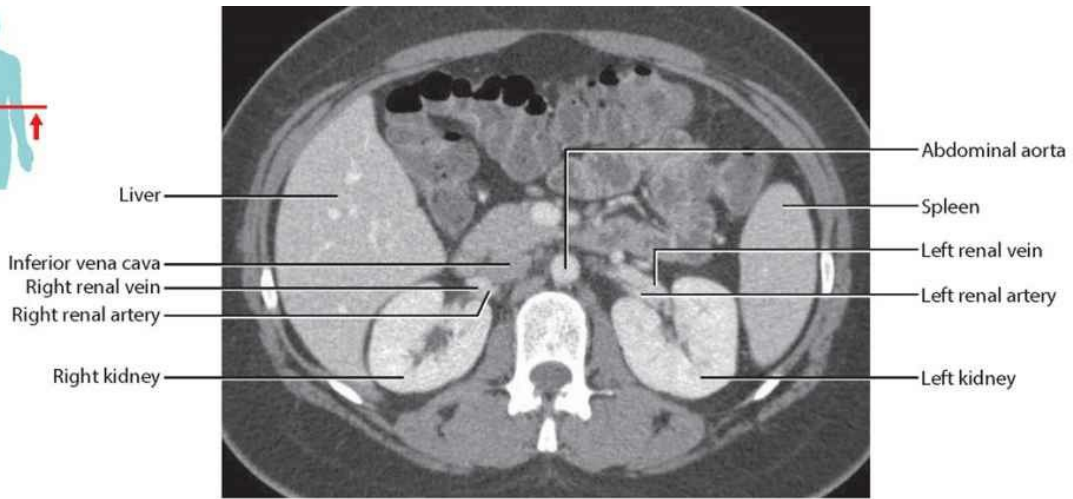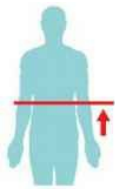


**Pathway of ureter in relation to other structures.**  
Coronal view of 3-D urogram using multidetector computed tomography

# Renal vasculature

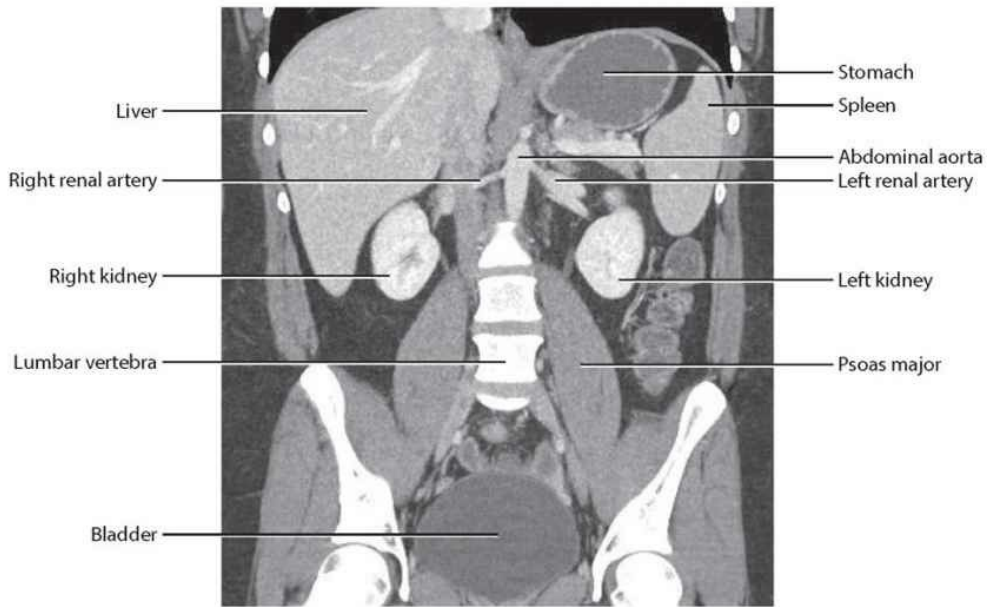
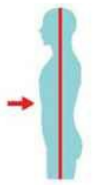


**Vasculature relating to kidneys, suprarenal glands, and ureters**



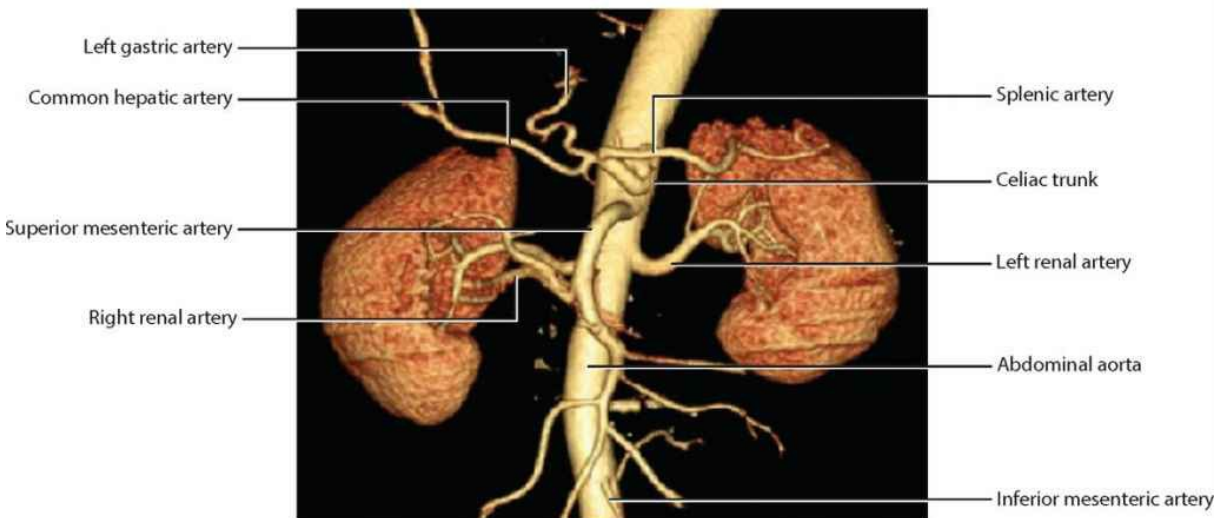**Renal vasculature.**

CT image, with contrast, in axial plane



**Renal arteries.**

CT image, with contrast, in coronal plane



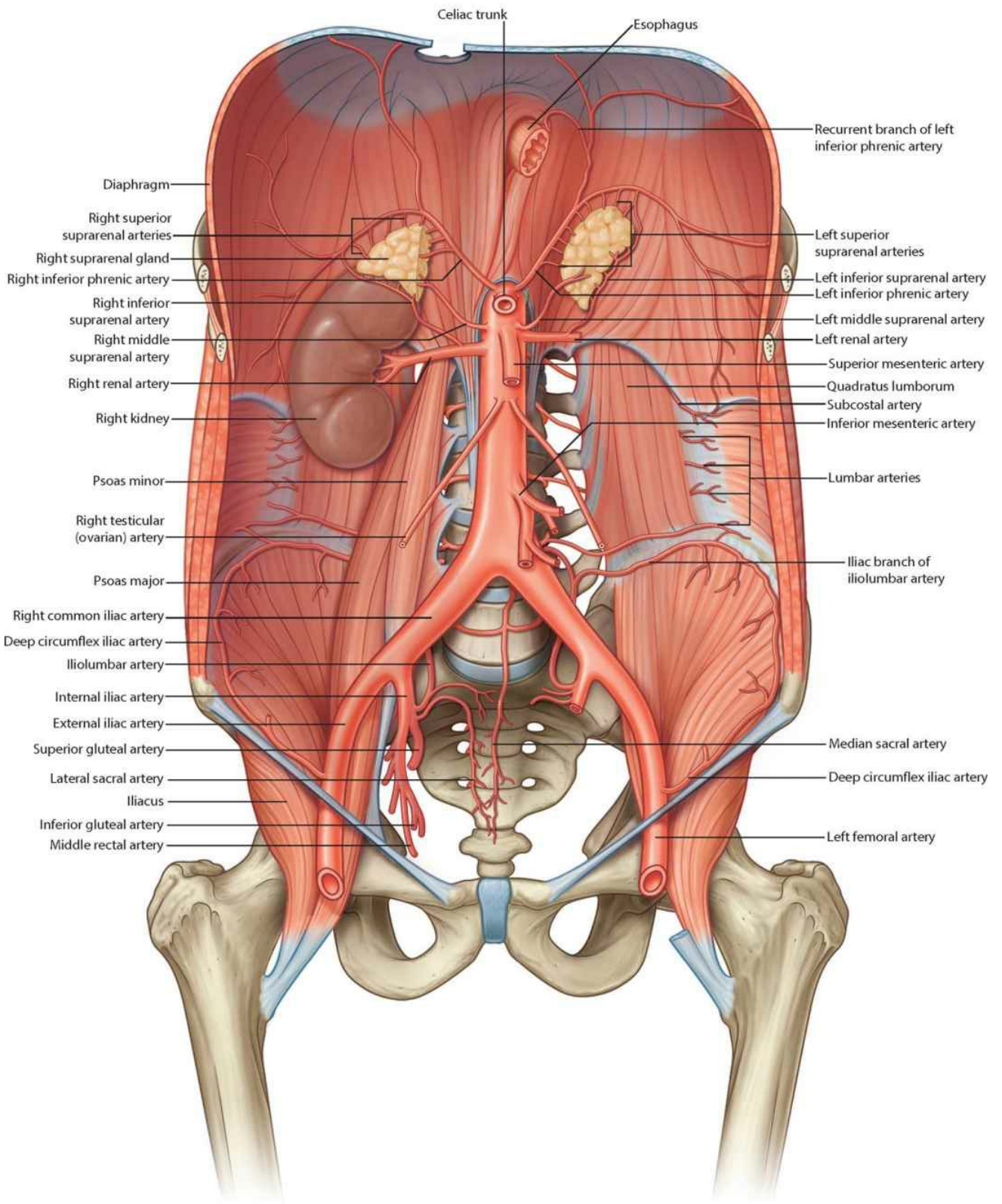
**Renal arteries.**

Volume-rendered anterior view using multidetector computer tomography



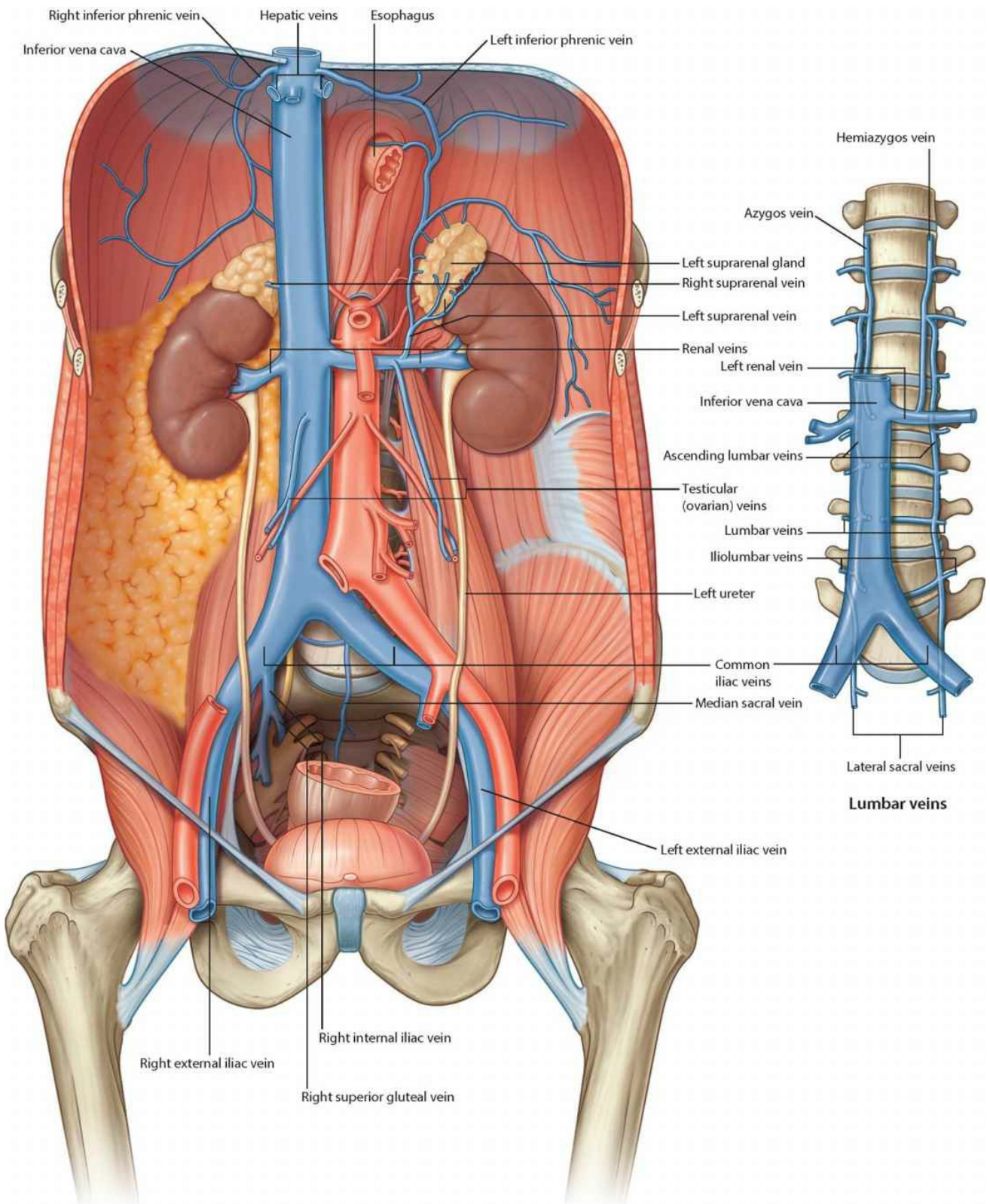
## **Branches of the abdominal aorta**





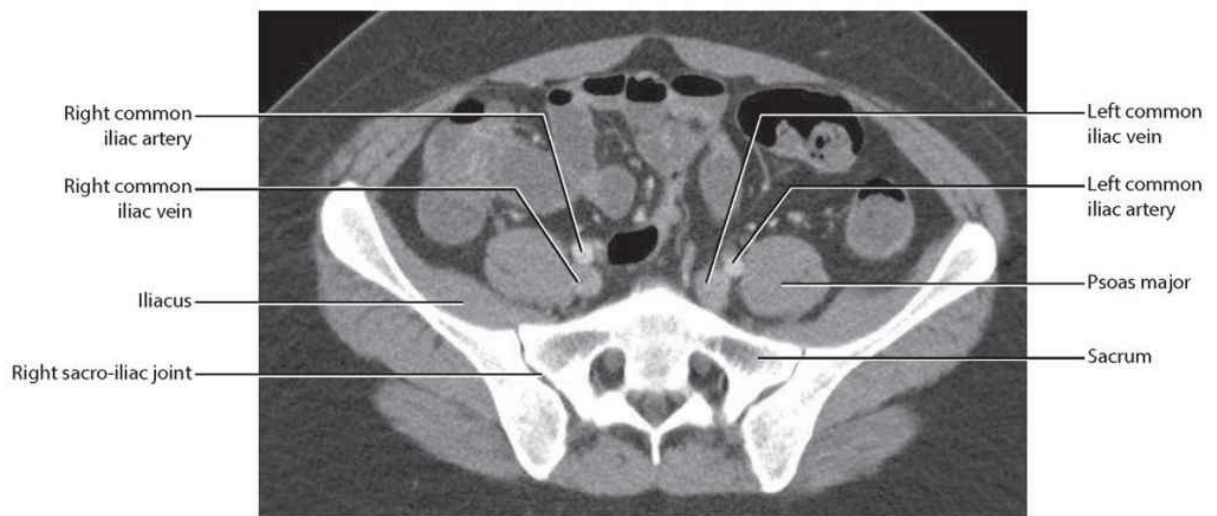
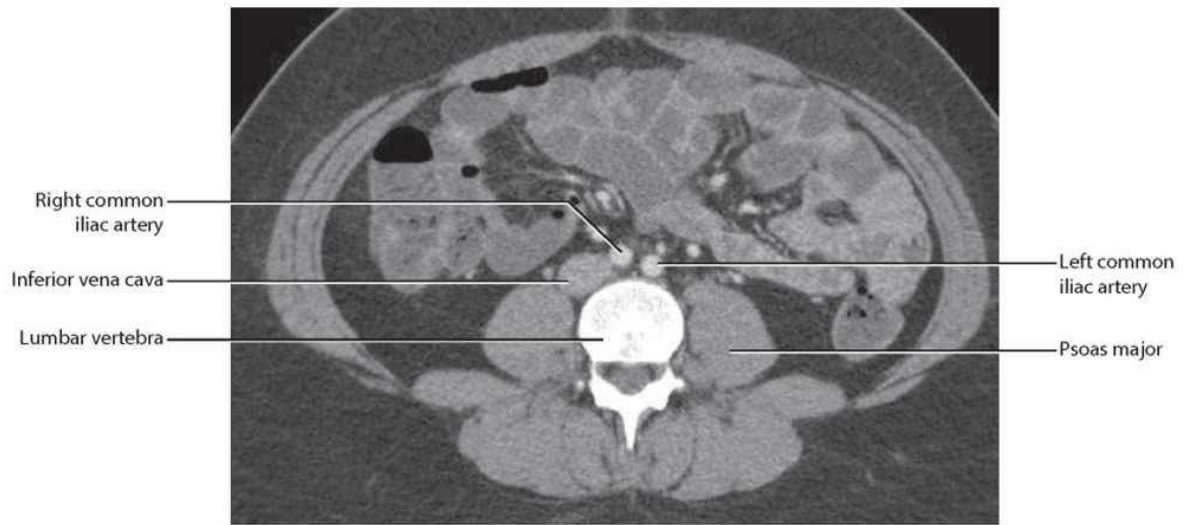
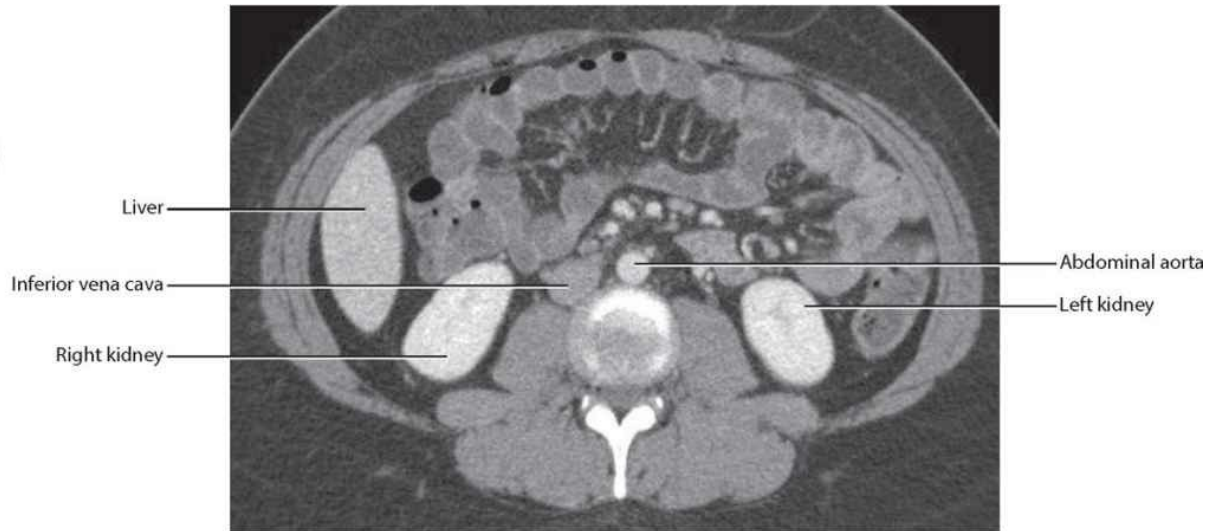
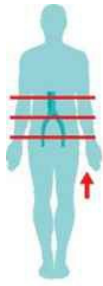
**Abdominal aorta and branches**

# Inferior vena cava



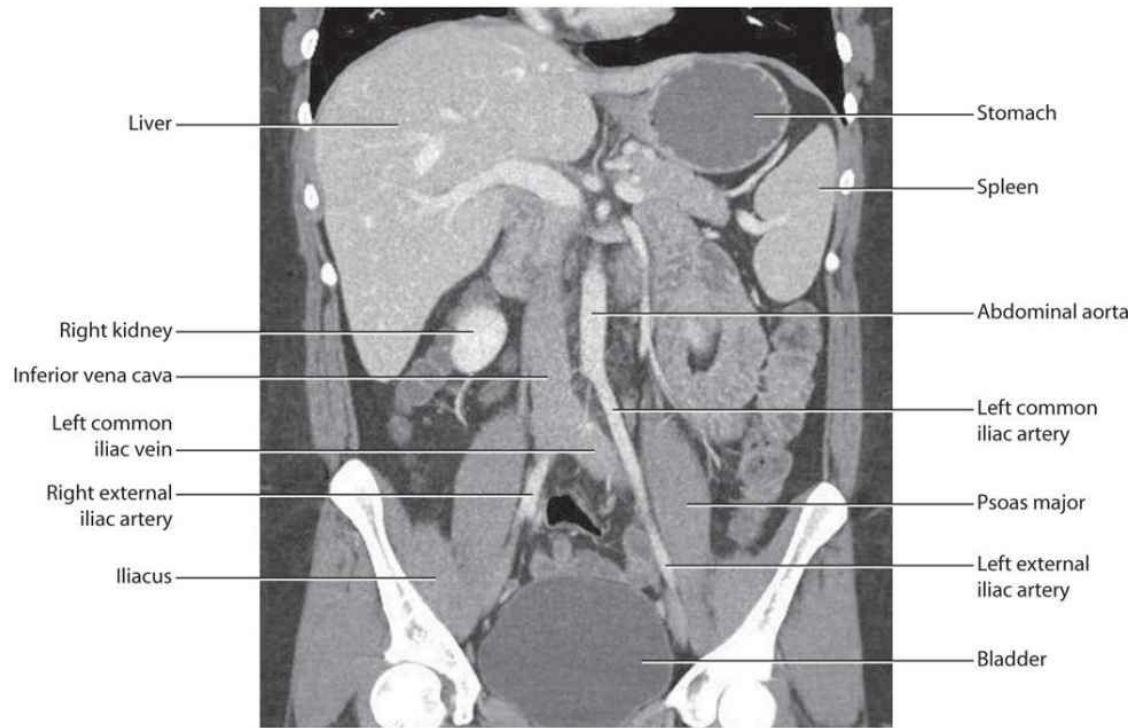
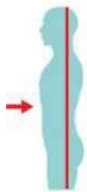
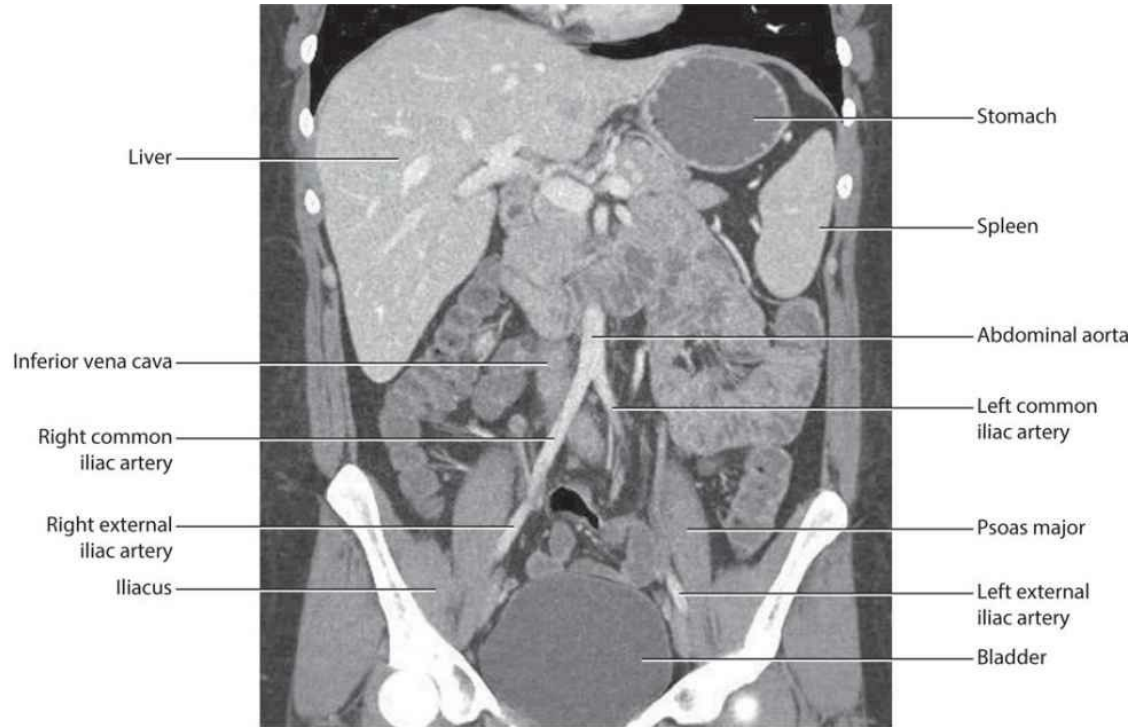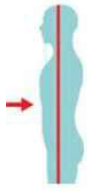
Inferior vena cava and tributaries

# Abdominal aorta and inferior vena cava: imaging



**Abdominal aorta and inferior vena cava.**  
 CT images, with contrast, in axial plane



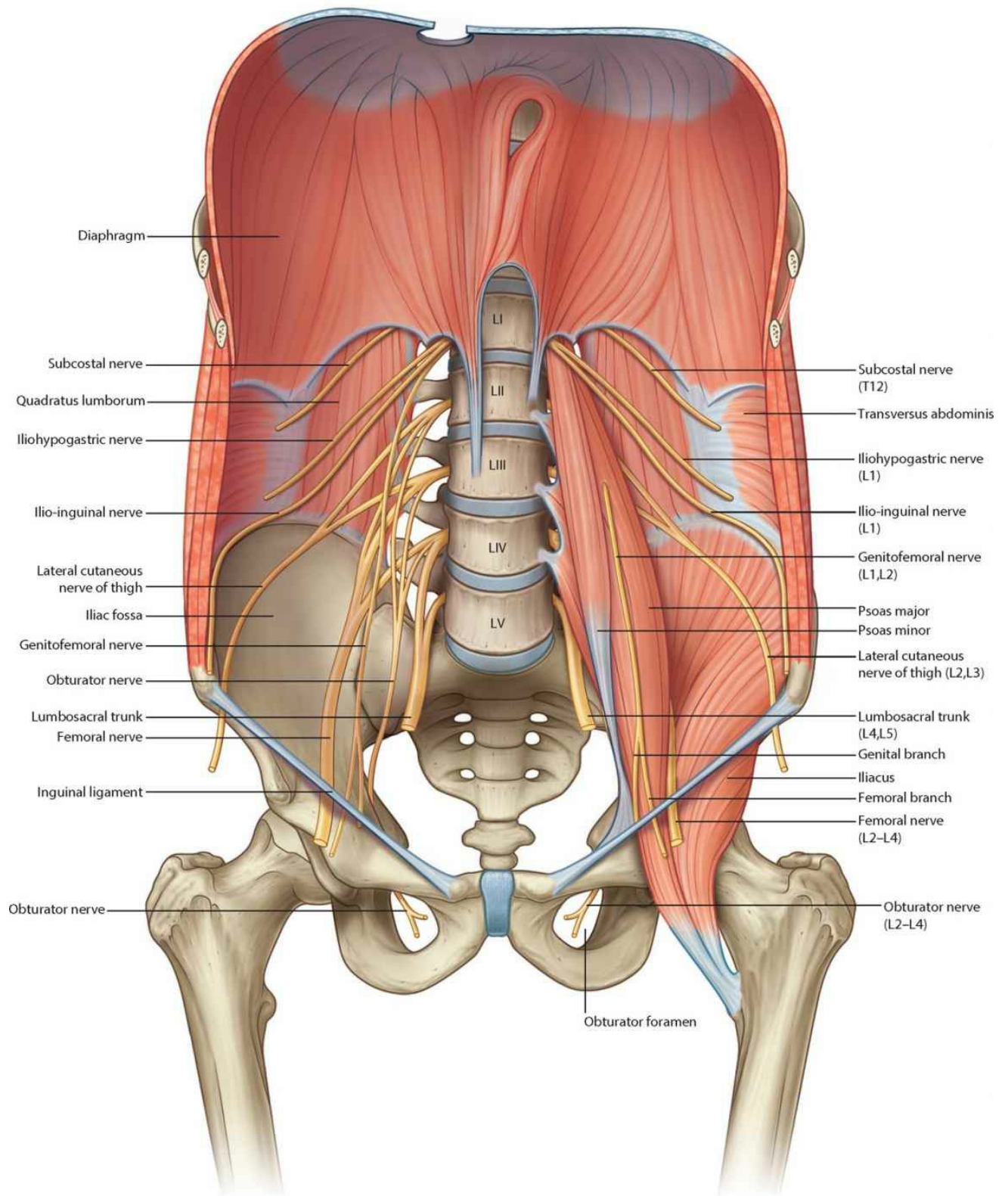


**Positioning of the abdominal aorta and inferior vena cava in relation to other structures.**

CT images, with contrast, in coronal plane

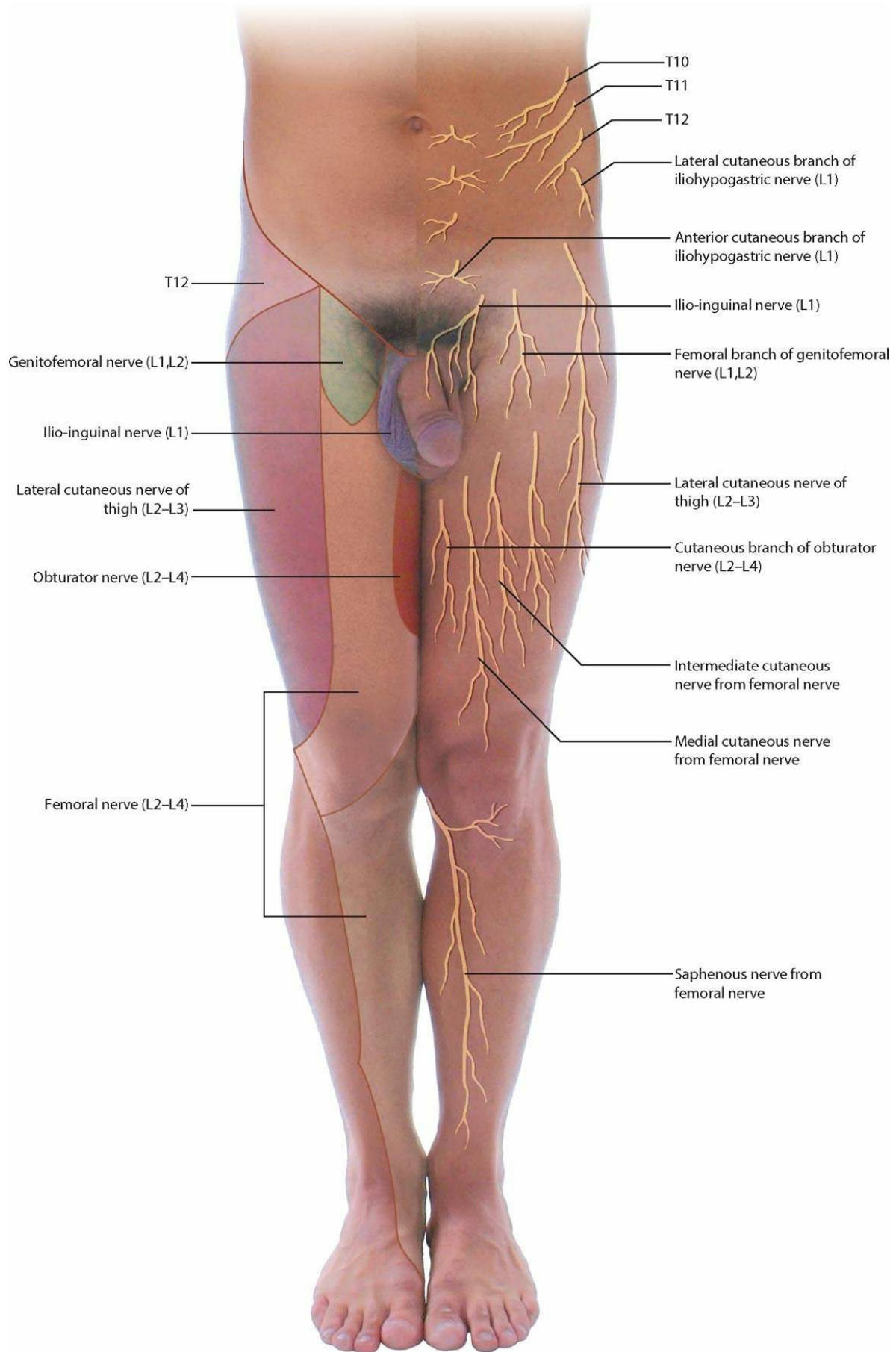
# Lumbar plexus





**Lumbar plexus**

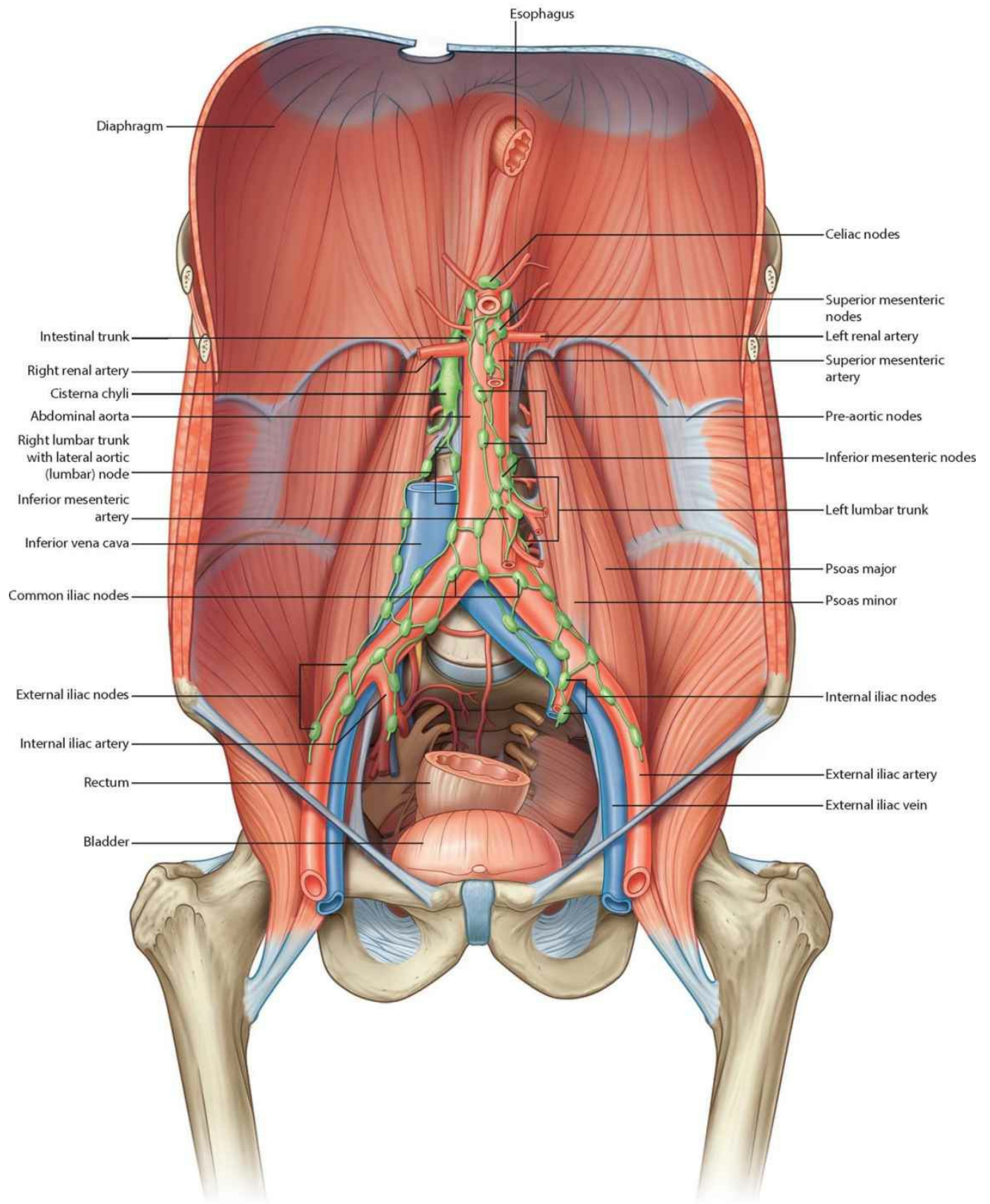
## **Lumbar plexus: cutaneous distribution**



Cutaneous distribution of the nerves from the lumbar plexus

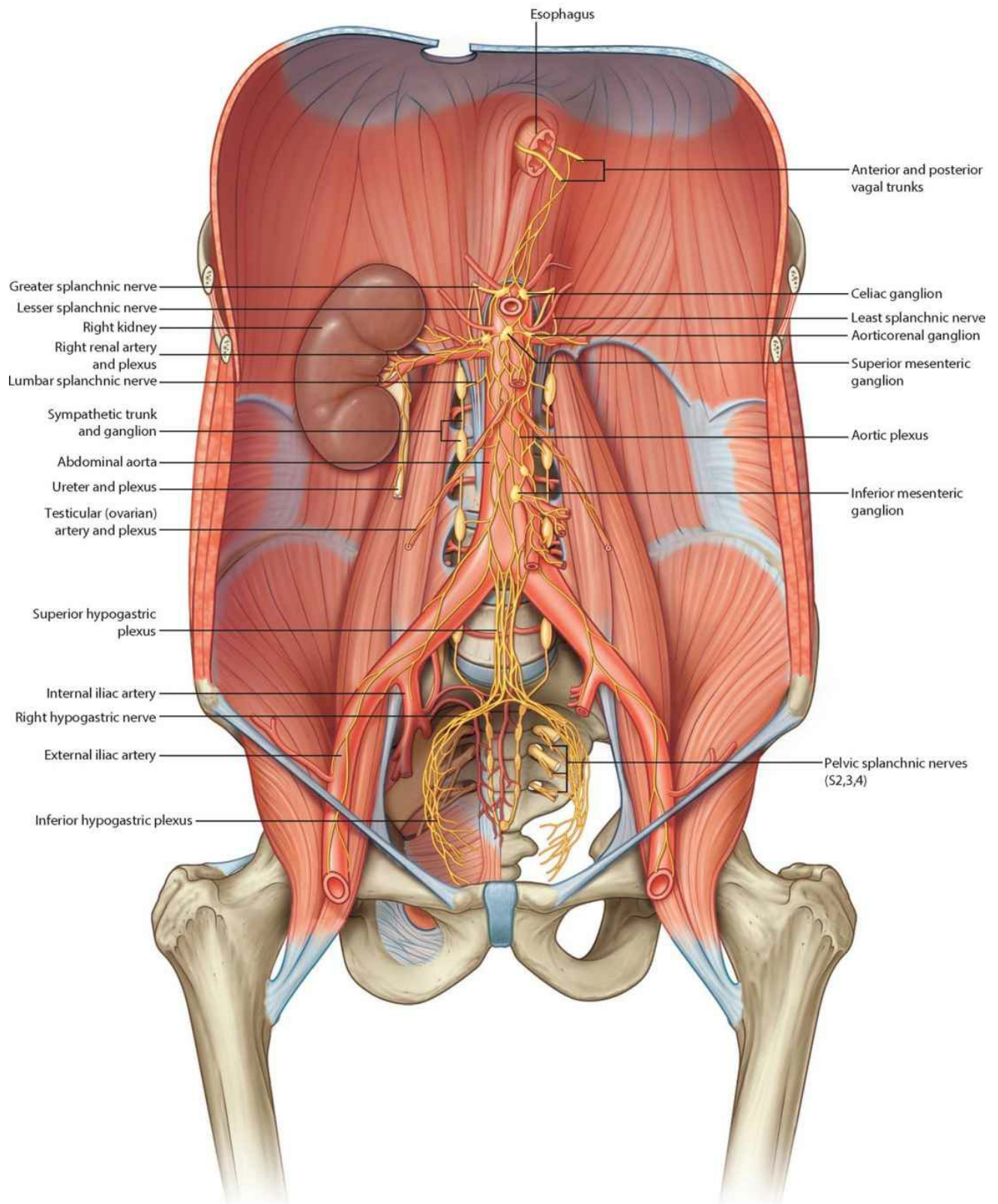


# Lymphatics



**Abdominal lymphatics**

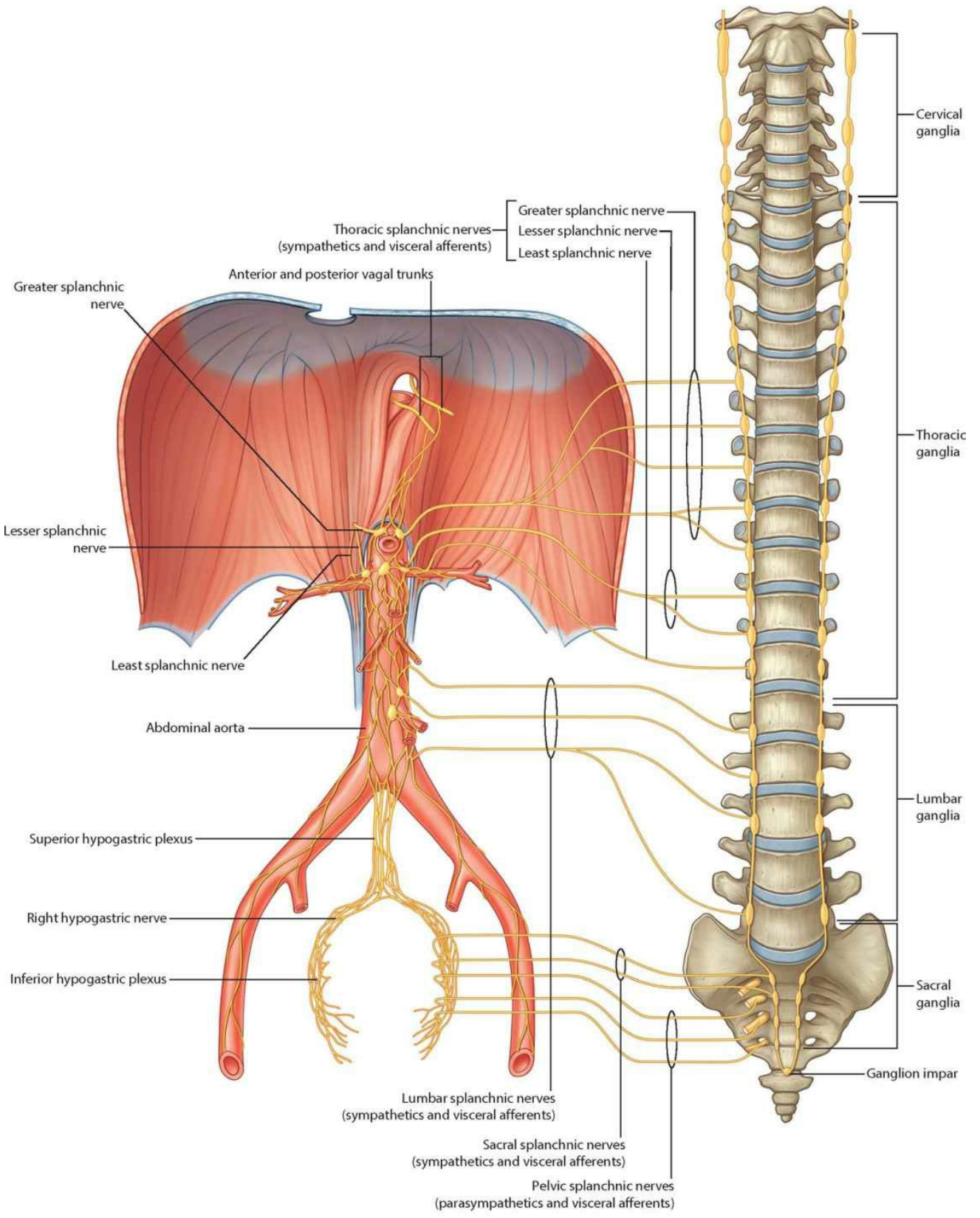
# Abdominal innervation



Prevertebral plexuses and ganglia with sympathetic trunks

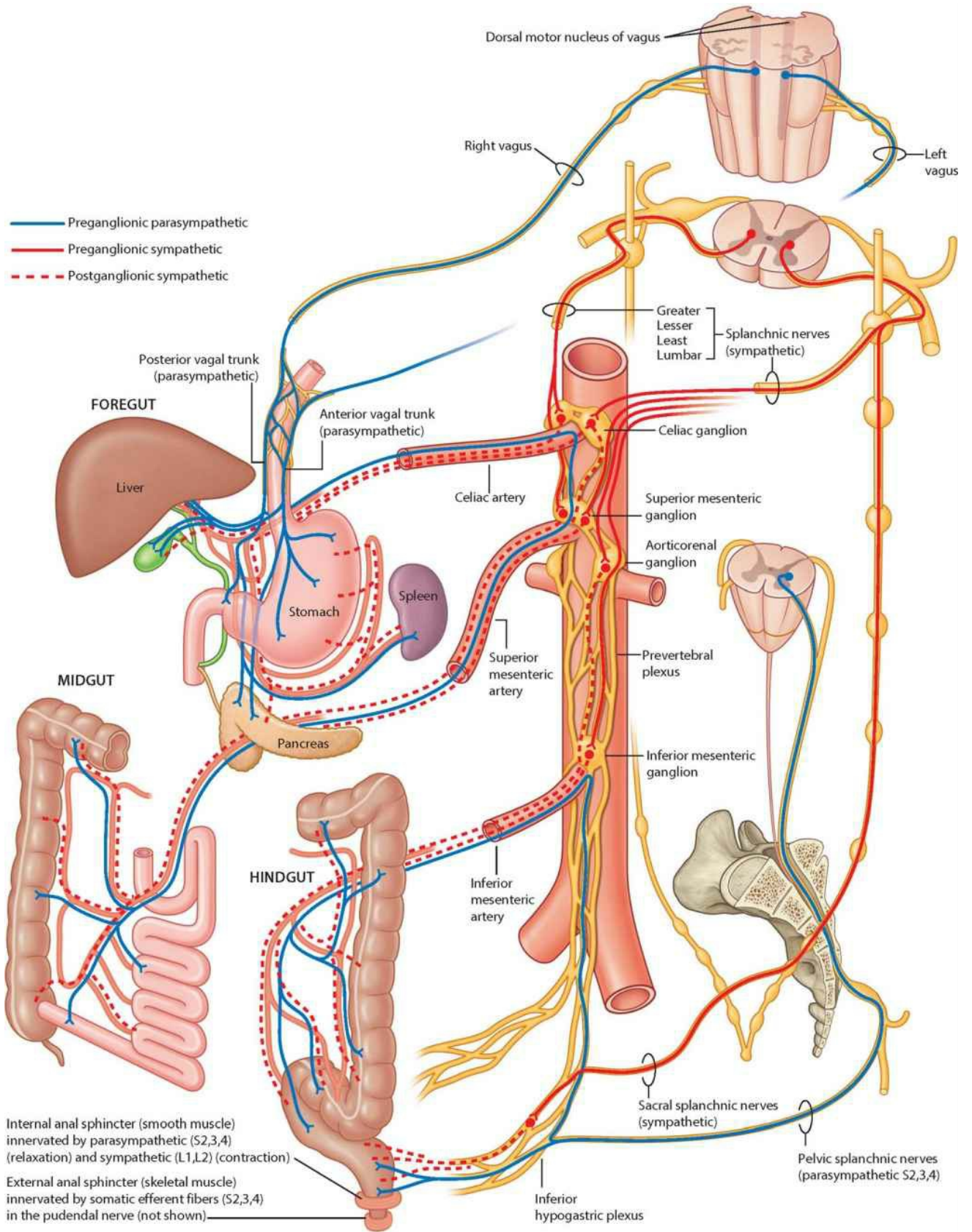


# Splanchnic nerves

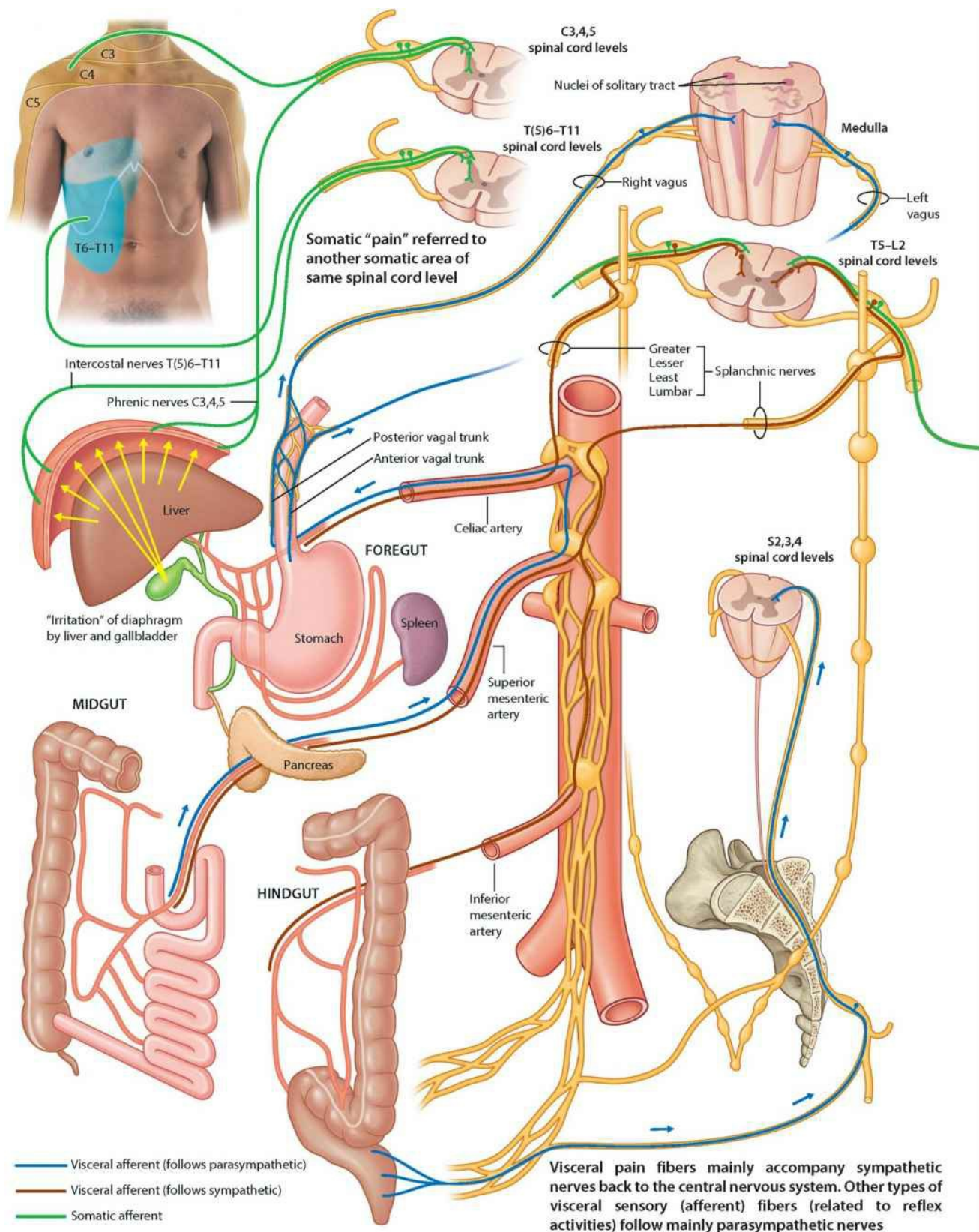


**Splanchnic nerves**

# Visceral efferent (motor) innervation diagram



# Visceral afferent (sensory) innervation and referred pain diagram

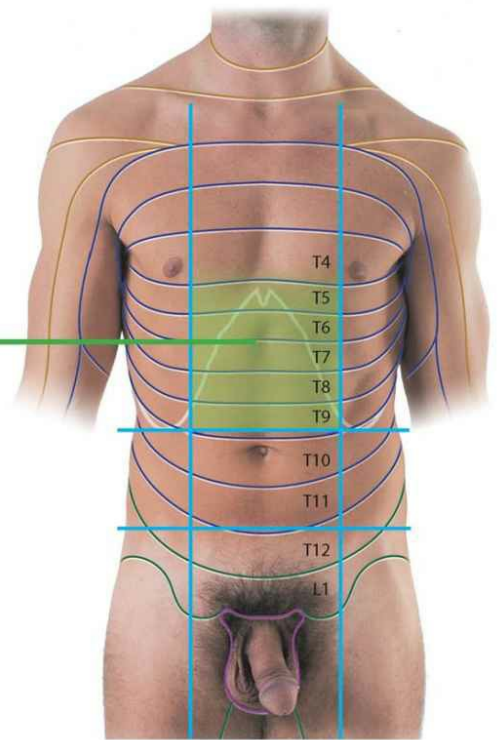


— Visceral afferent (follows parasympathetic)  
 — Visceral afferent (follows sympathetic)  
 — Somatic afferent

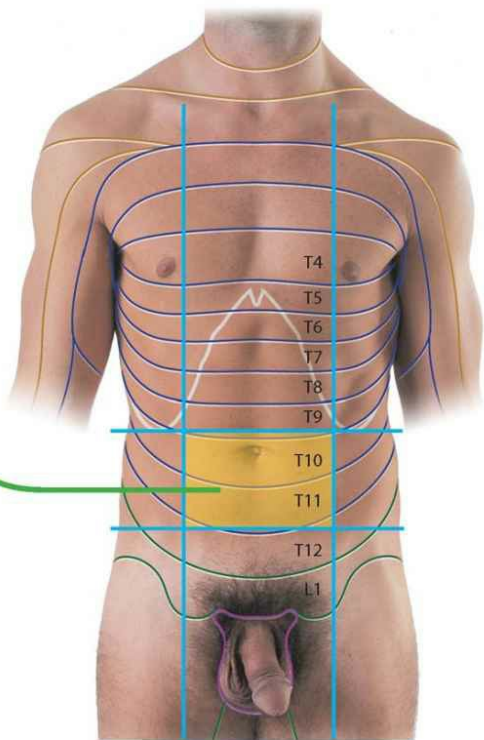
Visceral pain fibers mainly accompany sympathetic nerves back to the central nervous system. Other types of visceral sensory (afferent) fibers (related to reflex activities) follow mainly parasympathetic nerves



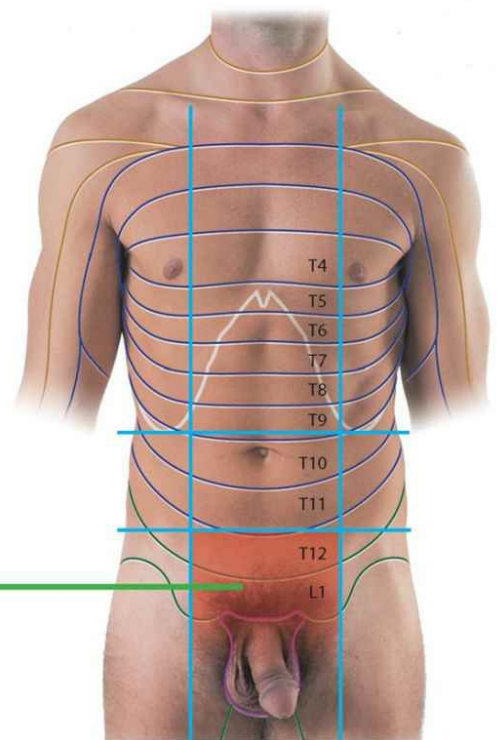
Visceral "pain" referred to somatic area innervated by same spinal cord level



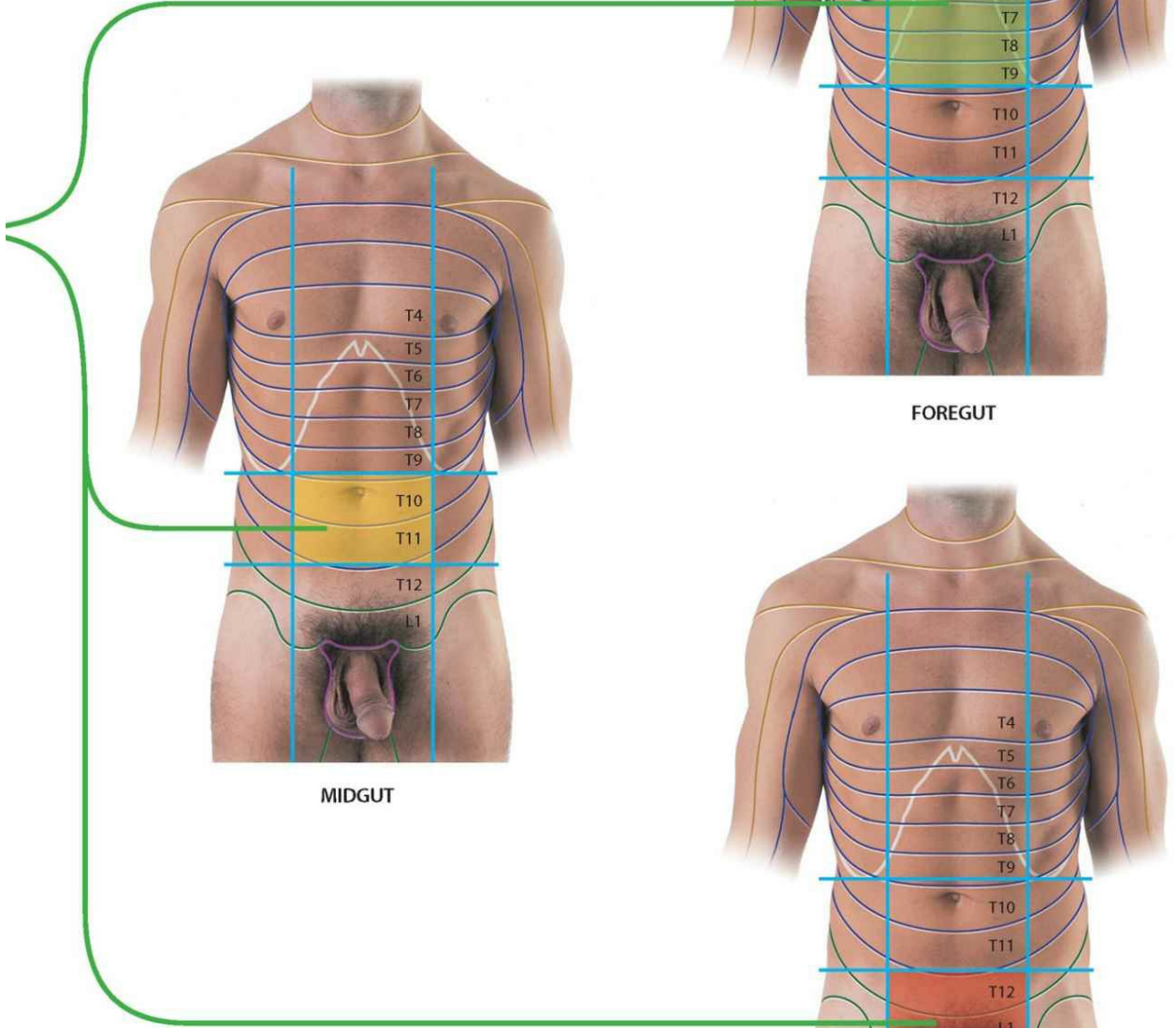
FOREGUT



MIDGUT

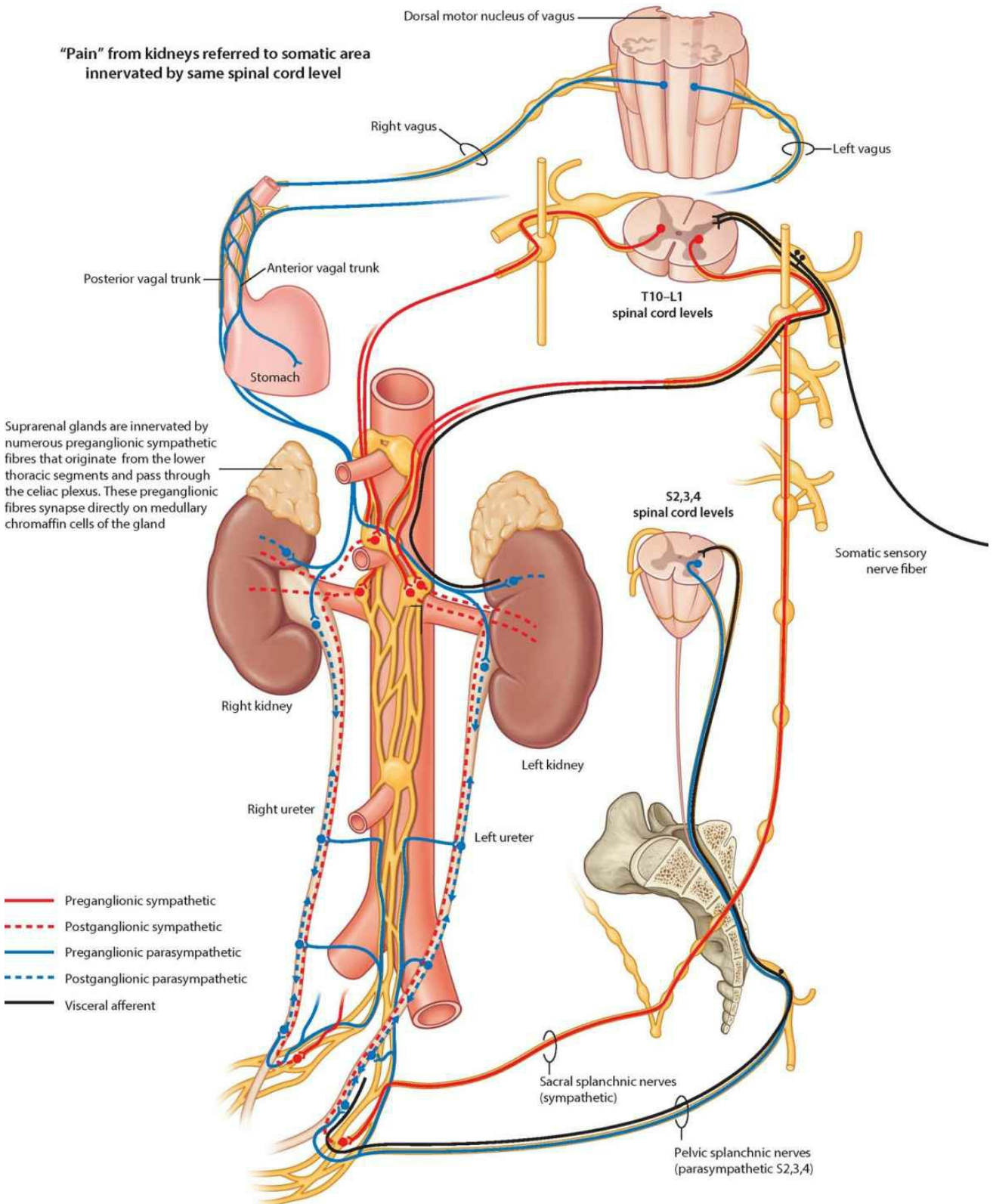


HINDGUT

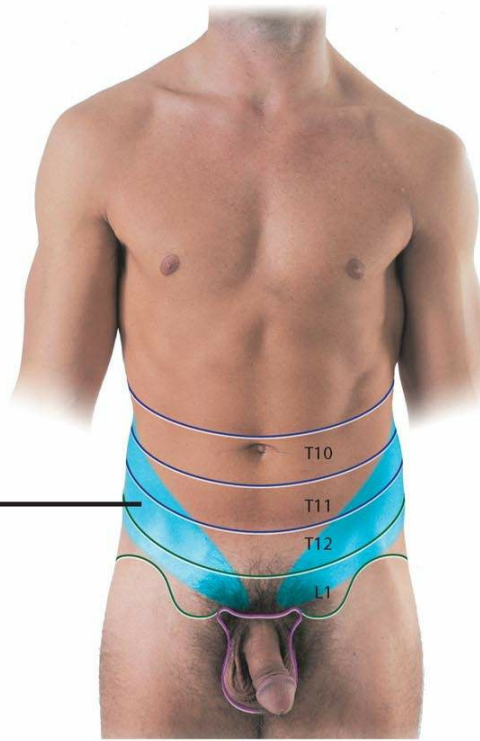




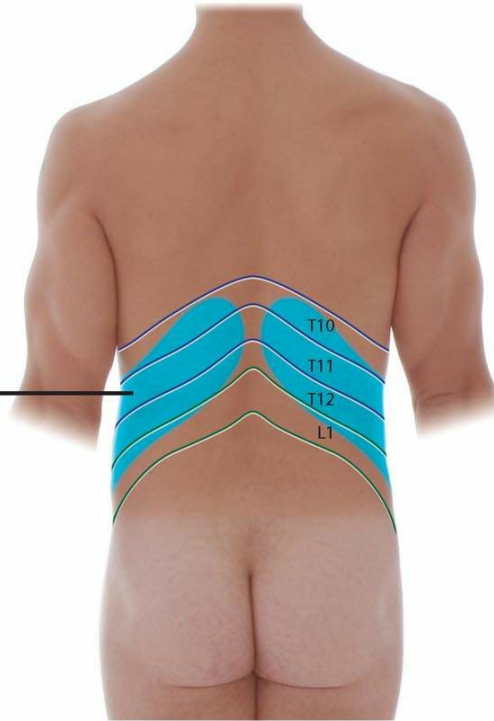# Kidney and ureter visceral afferent (sensory) diagram







**T10-L1 dermatomes**



Pain fibers mainly follow sympathetic nerves to the central nervous system (CNS). This pain is 'referred' by the CNS to the somatic area innervated by the same spinal levels. Other types of visceral afferent (sensory) fibers (related to reflex activities) follow mainly parasympathetic nerves

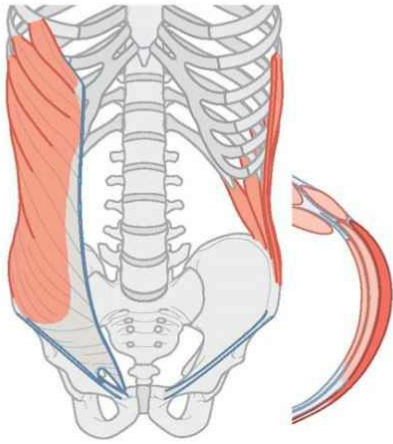
# Tables

## Abdominal wall muscles

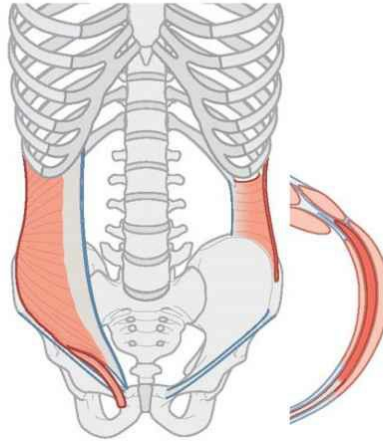
Muscle		Origin	Insertion	Innervation	Function
<b>External oblique</b>	1	Muscular slips from the outer surfaces of the lower eight ribs (ribs V to XII)	Lateral lip of iliac crest; aponeurosis ending in midline raphe (linea alba)	Anterior rami of lower six thoracic spinal nerves (T7 to T12)	Compress abdominal contents; both muscles flex trunk; each muscle bends trunk to same side, turning anterior part of abdomen to opposite side
<b>Internal oblique</b>	2	Thoracolumbar fascia; iliac crest between origins of external and transversus; lateral two-thirds of inguinal ligament	Inferior border of the lower three or four ribs; aponeurosis ending in linea alba; pubic crest and pectineal line	Anterior rami of lower six thoracic spinal nerves (T7 to T12) and L1	Compress abdominal contents; both muscles flex trunk; each muscle bends trunk and turns anterior part of abdomen to same side
<b>Transversus abdominis</b>	3	Thoracolumbar fascia; medial lip of iliac crest; lateral one-third of inguinal ligament; costal cartilages lower six ribs (ribs VII to XII)	Aponeurosis ending in linea alba; pubic crest and pectineal line	Anterior rami of lower six thoracic spinal nerves (T7 to T12) and L1	Compress abdominal contents
<b>Rectus abdominis</b>	4	Pubic crest, pubic tubercle, and pubic symphysis	Costal cartilages of ribs V to VII; xiphoid process	Anterior rami of lower seven thoracic spinal nerves (T7 to T12)	Compress abdominal contents; flex vertebral column; tense abdominal wall
<b>Pyramidalis</b>	5	Front of pubis and pubic symphysis	Into linea alba	Anterior ramus of T12	Tenses the linea alba

## Posterior abdominal wall muscles

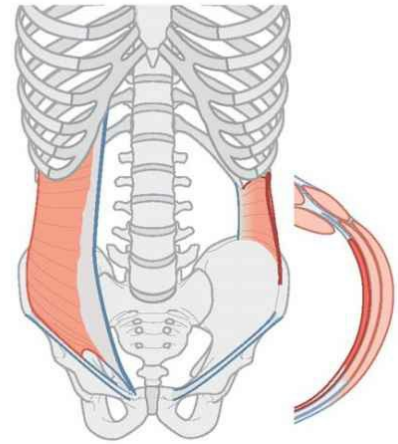
<b>Psoas major</b>	6	Lateral surface of bodies of TXII and LI to LV vertebrae, transverse processes of the lumbar vertebrae, and the intervertebral discs between TXII and LI to LV vertebrae	Lesser trochanter of the femur	Anterior rami of L1 to L3	Flexion of thigh at hip joint
<b>Psoas minor</b>	7	Lateral surface of bodies of TXII and LI vertebrae and intervening intervertebral disc	Pectineal line of the pelvic brim and iliopubic eminence	Anterior rami of L1	Weak flexion of lumbar vertebral column
<b>Quadratus lumborum</b>	8	Transverse process of LV vertebra, iliolumbar ligament, and iliac crest	Transverse processes of LI to LIV vertebrae and inferior border of rib XII	Anterior rami of T12 and L1 to L4	Depress and stabilize rib XII and some lateral bending of trunk
<b>Iliacus</b>	9	Upper two-thirds of iliac fossa, anterior sacro-iliac and iliolumbar ligaments, and upper lateral surface of sacrum	Lesser trochanter of femur	Femoral nerve (L2 to L4)	Flexion of thigh at hip joint



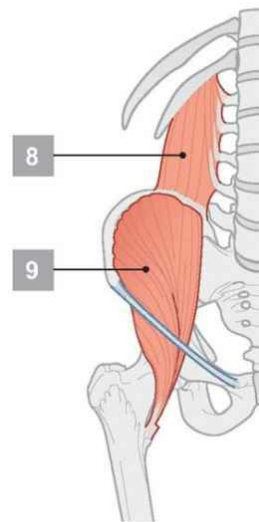
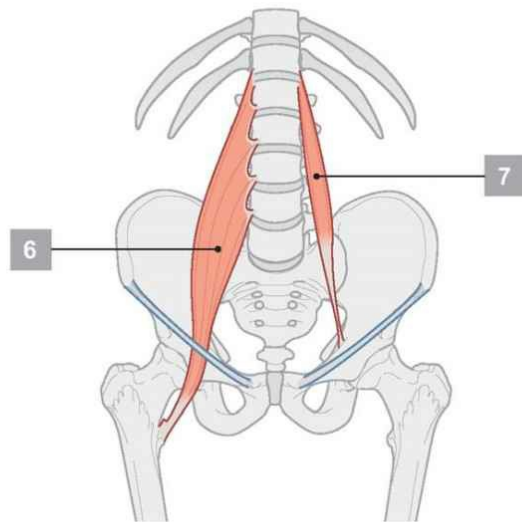
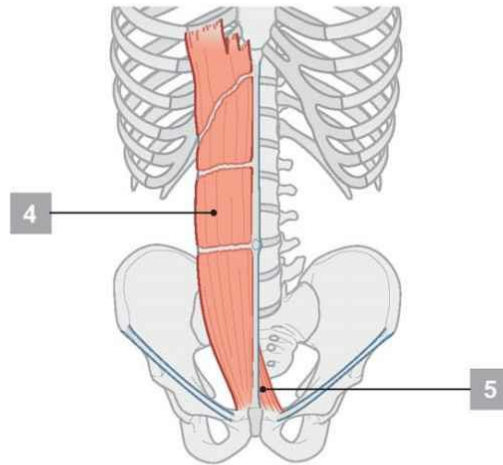
1



2



3

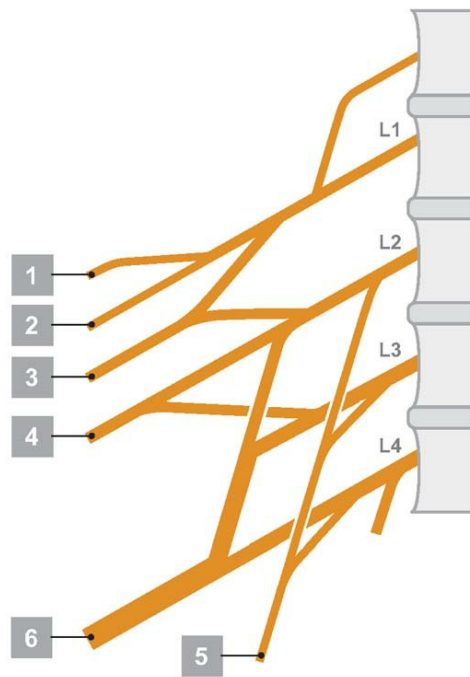
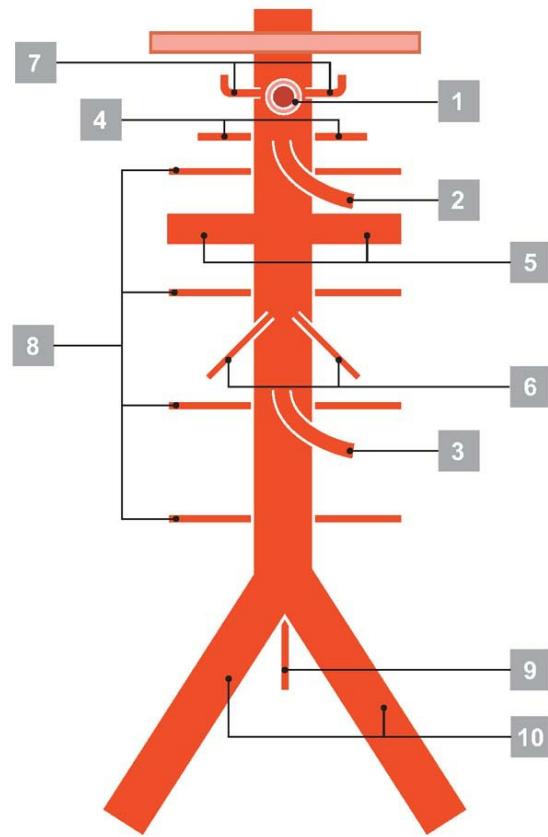


## Branches of the abdominal aorta

Artery		Branch	Origin	Parts supplied
Celiac trunk	1	Anterior	Immediately inferior to the aortic hiatus of the diaphragm	Abdominal foregut
Superior mesenteric artery	2	Anterior	Immediately inferior to the celiac trunk	Abdominal midgut
Inferior mesenteric artery	3	Anterior	Inferior to the renal arteries	Abdominal hindgut
Middle suprarenal arteries	4	Lateral	Immediately superior to the renal arteries	Suprarenal glands
Renal arteries	5	Lateral	Immediately inferior to the superior mesenteric artery	Kidneys
Testicular or ovarian arteries	6	Paired anterior	Inferior to the renal arteries	Testes in male and ovaries in female
Inferior phrenic arteries	7	Lateral	Immediately inferior to the aortic hiatus	Diaphragm
Lumbar arteries	8	Posterior	Usually four pairs	Posterior abdominal wall and spinal cord
Median sacral artery	9	Posterior	Just superior to the aortic bifurcation, passes inferiorly across lumbar vertebrae, sacrum, and coccyx	
Common iliac arteries	10	Terminal	Bifurcation usually occurs at the level of LIV vertebra	

## Branches of the lumbar plexus

Branch		Origin	Spinal segments	Function: motor	Function: sensory
Iliohypogastric	1	Anterior ramus L1	L1	Internal oblique and transversus abdominis	Posterolateral gluteal skin and skin in pubic region
Ilio-inguinal	2	Anterior ramus L1	L1	Internal oblique and transversus abdominis	Skin in the upper medial thigh, and either the skin over the root of the penis and anterior scrotum or the mons pubis and labium majus
Genitofemoral	3	Anterior rami L1 and L2	L1, L2	Genital branch—male cremasteric muscle	Genital branch—skin of anterior scrotum or skin of mons pubis and labium majus; femoral branch—skin of upper anterior thigh
Lateral cutaneous nerve of thigh	4	Anterior rami L2 and L3	L2, L3		Skin on anterior and lateral thigh to the knee
Obturator	5	Anterior rami L2 to L4	L2 to L4	Obturator externus, pectineus, and muscles in medial compartment of thigh	Skin on medial aspect of the thigh
Femoral	6	Anterior rami L2 to L4	L2 to L4	Iliacus, pectineus, and muscles in anterior compartment of thigh	Skin on anterior thigh and medial surface of leg







# PELVIS AND PERINEUM

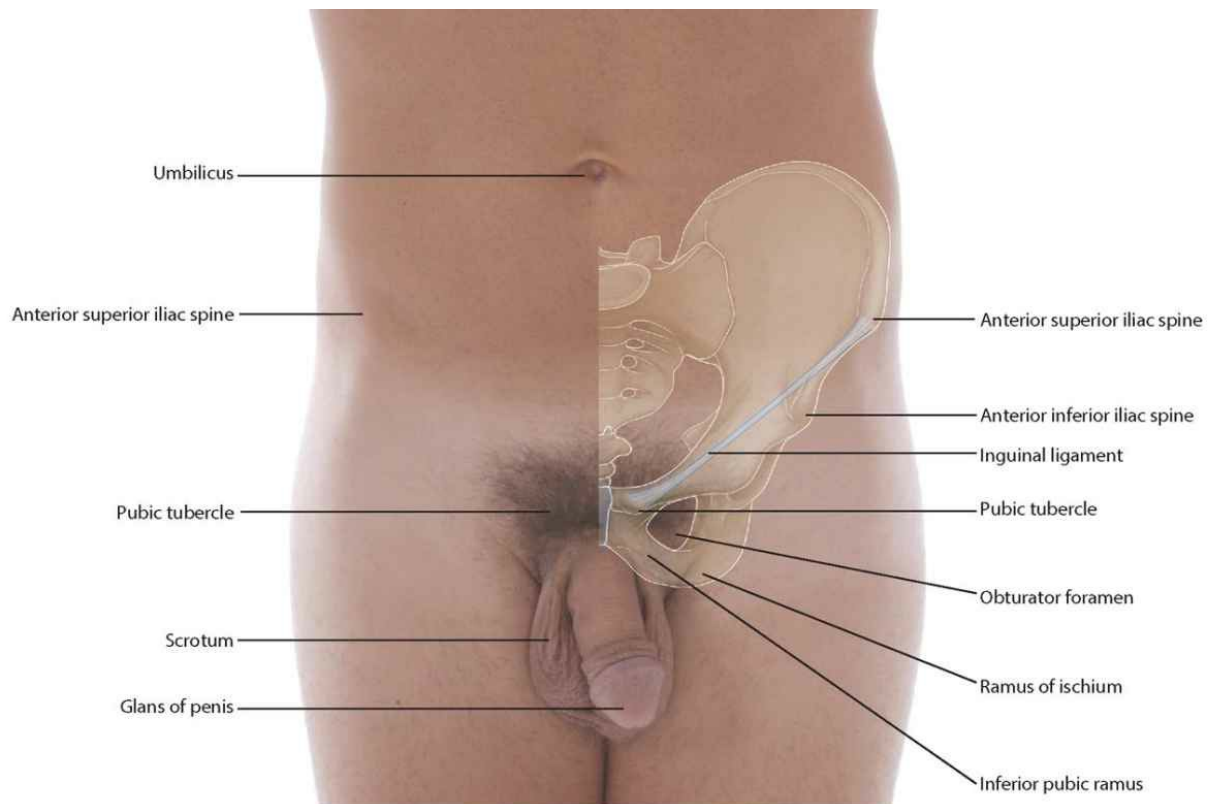
---

# CONTENTS

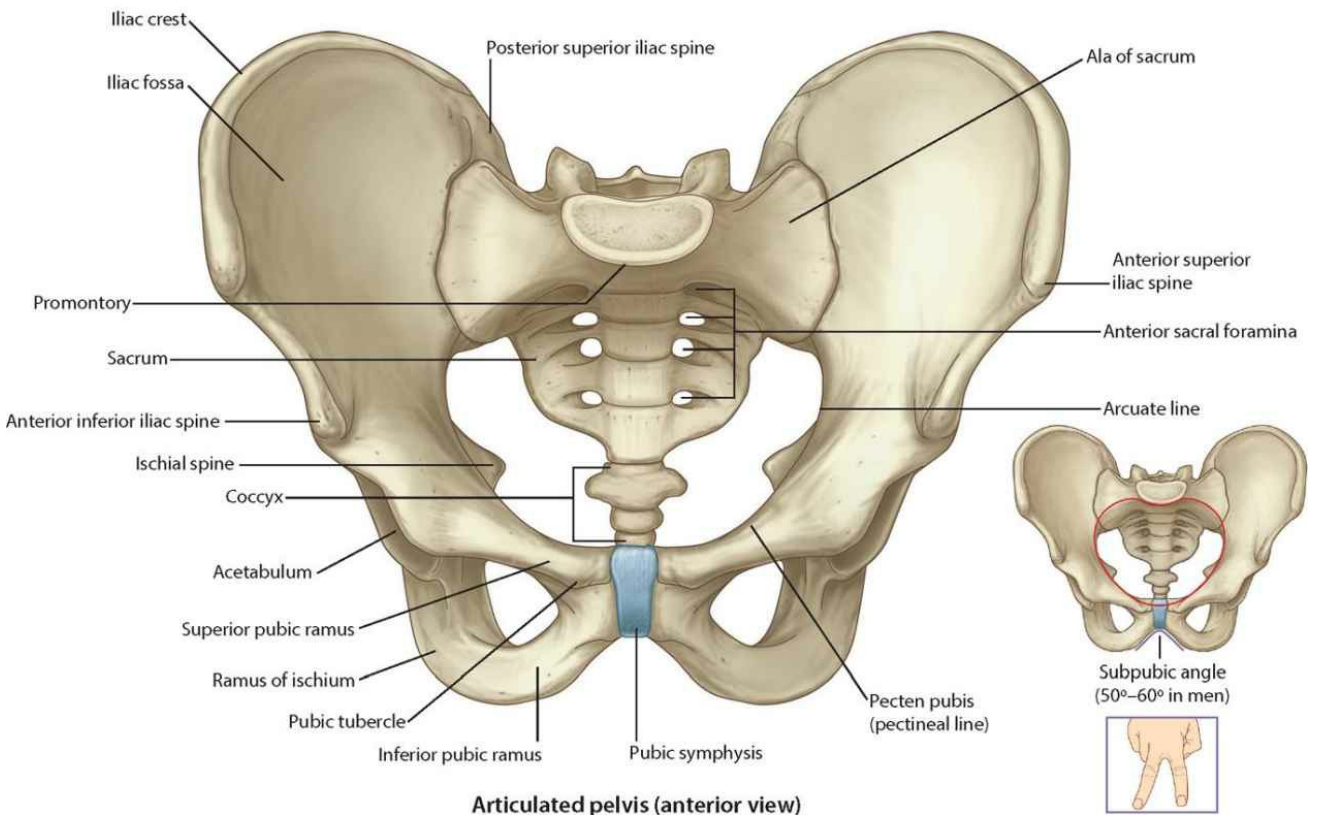
Surface anatomy and articulated pelvis in men	214
Surface anatomy and articulated pelvis in women	216
Pelvic girdle	218
Pelvic girdle: imaging	219
Lumbosacral joint	220
Sacro-iliac joint	221
Pelvic inlet and outlet	222
Orientation of pelvic girdle and pelvic brim	223
Pelvic viscera and perineum in men	224
Pelvic viscera and perineum in men: imaging	225
Pelvic viscera and perineum in women	226
Pelvic viscera and perineum in women: imaging	227
Lateral wall of pelvic cavity	228
Floor of pelvic cavity: pelvic diaphragm	229
Rectum and bladder in situ	232
Rectum	233
Bladder in men	234
Bladder in women	235
Reproductive system in men	236
Prostate	237
Prostate and seminal vesicles	239
Scrotum	240
Testes	241
Penis	242
Reproductive system in women	243
Uterus and ovaries	244
Uterus	245
Uterus: imaging	246
Pelvic fascia	247

Arterial supply of pelvis **248**  
Venous drainage of pelvis **249**  
Vasculature of the pelvic viscera **250**  
Vasculature of uterus **251**  
Venous drainage of prostate and penis **252**  
Venous drainage of rectum **253**  
Sacral and coccygeal nerve plexuses **254**  
Pelvic nerve plexus **255**  
Hypogastric plexus **256**  
Surface anatomy of the perineum **257**  
Borders and ceiling of the perineum **260**  
Deep pouch and perineal membrane **261**  
Muscles and erectile tissues in men **262**  
Erectile tissue in men: imaging **263**  
Muscles and erectile tissues in women **264**  
Erectile tissue in women: imaging **265**  
Internal pudendal artery and vein **266**  
Pudendal nerve **267**  
Vasculature of perineum **268**  
Nerves of perineum **269**  
Lymphatics of pelvis and perineum in men **270**  
Lymphatics of pelvis and perineum in women **271**  
Lymphatics **272**  
Dermatomes **273**  
Innervation of reproductive system in men **274**  
Innervation of reproductive system in women **275**  
Innervation of bladder **276**  
Pelvic cavity imaging in men **277**  
Pelvic cavity imaging in women **280**  
Tables **286**

# Surface anatomy and articulated pelvis in men

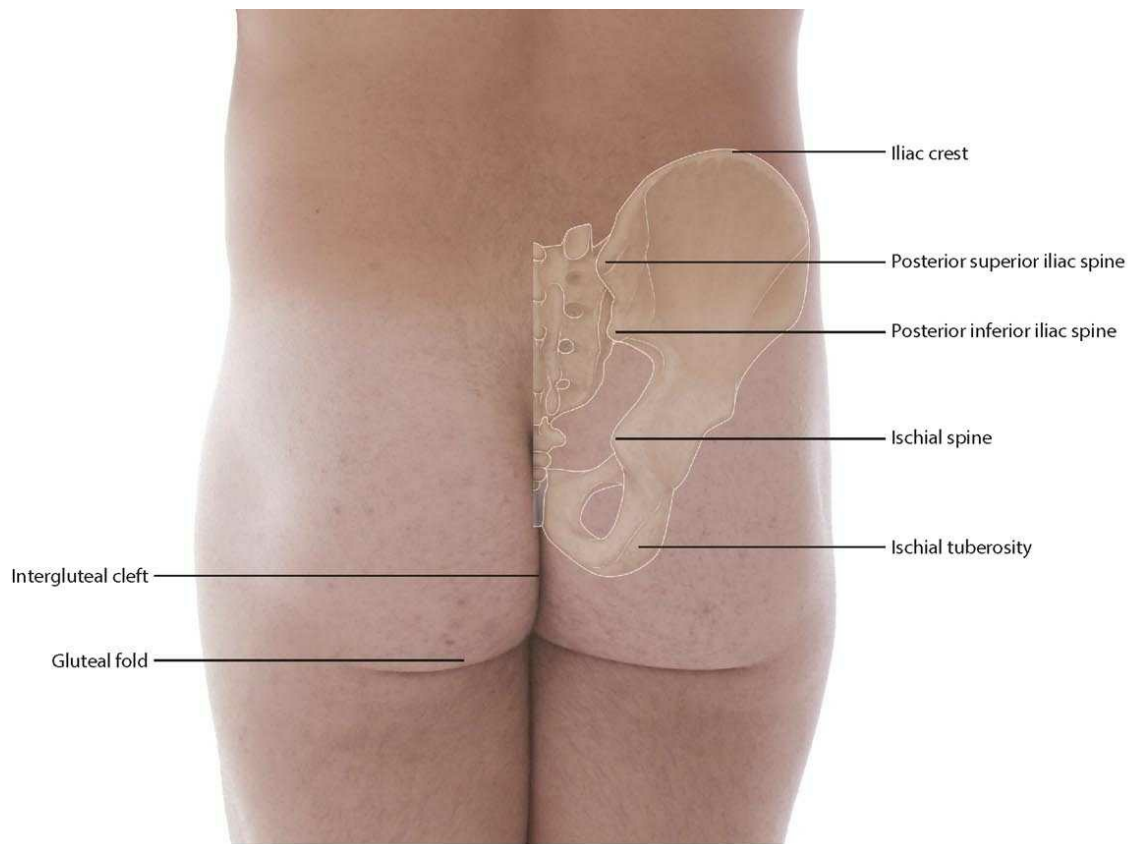


Surface anatomy with bones (anterior view)

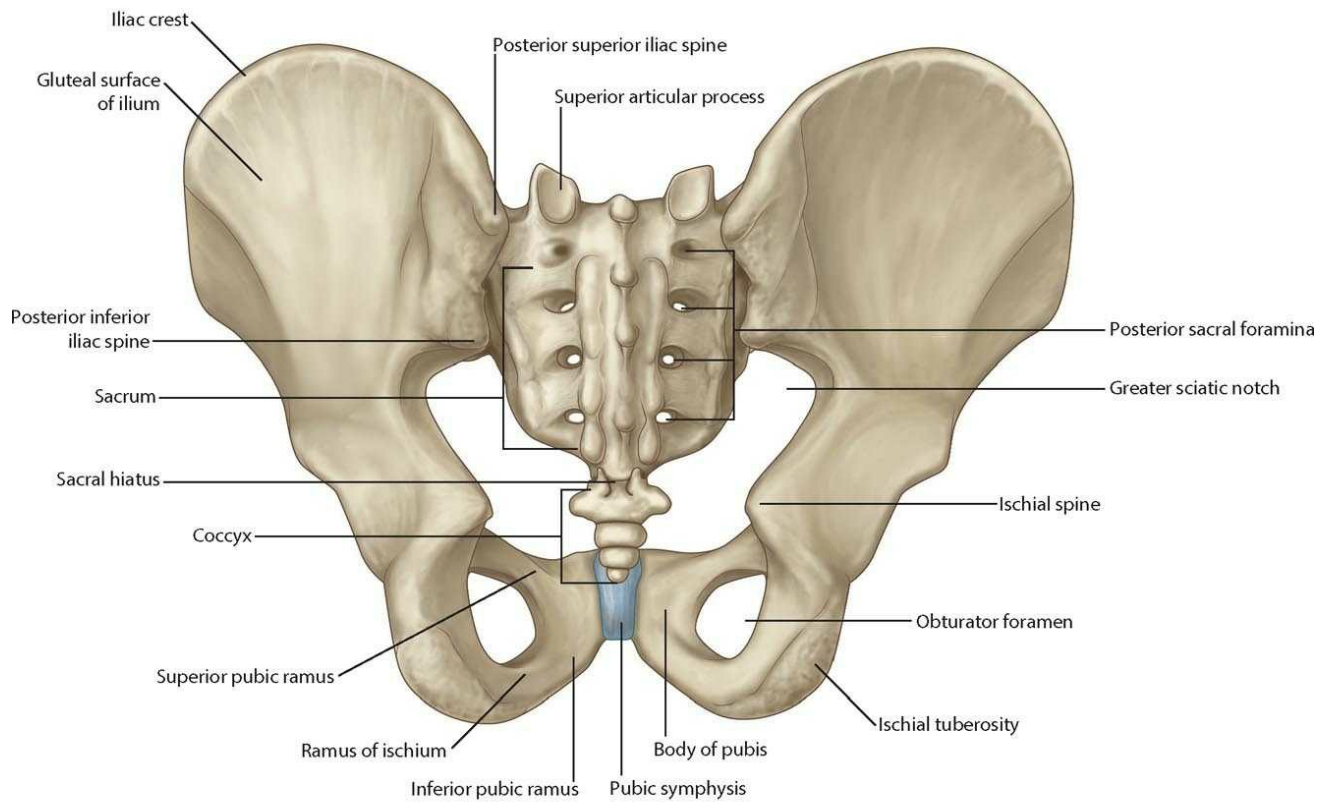


Articulated pelvis (anterior view)





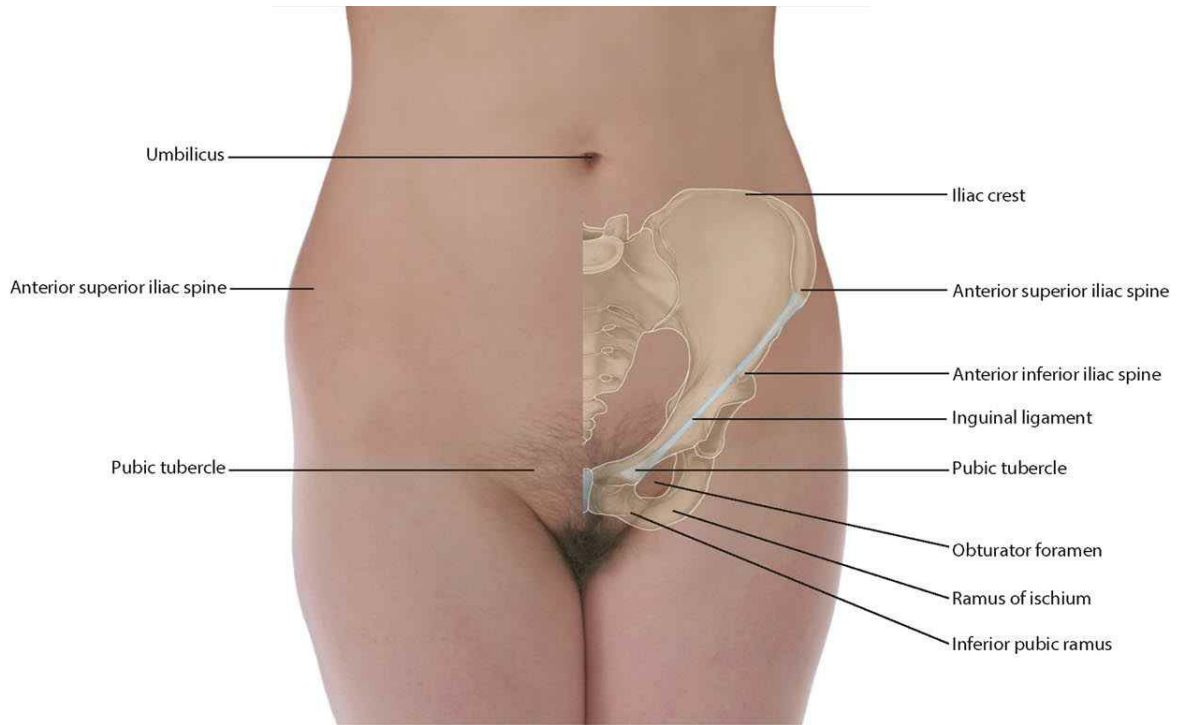
**Surface anatomy with bones (posterior view)**



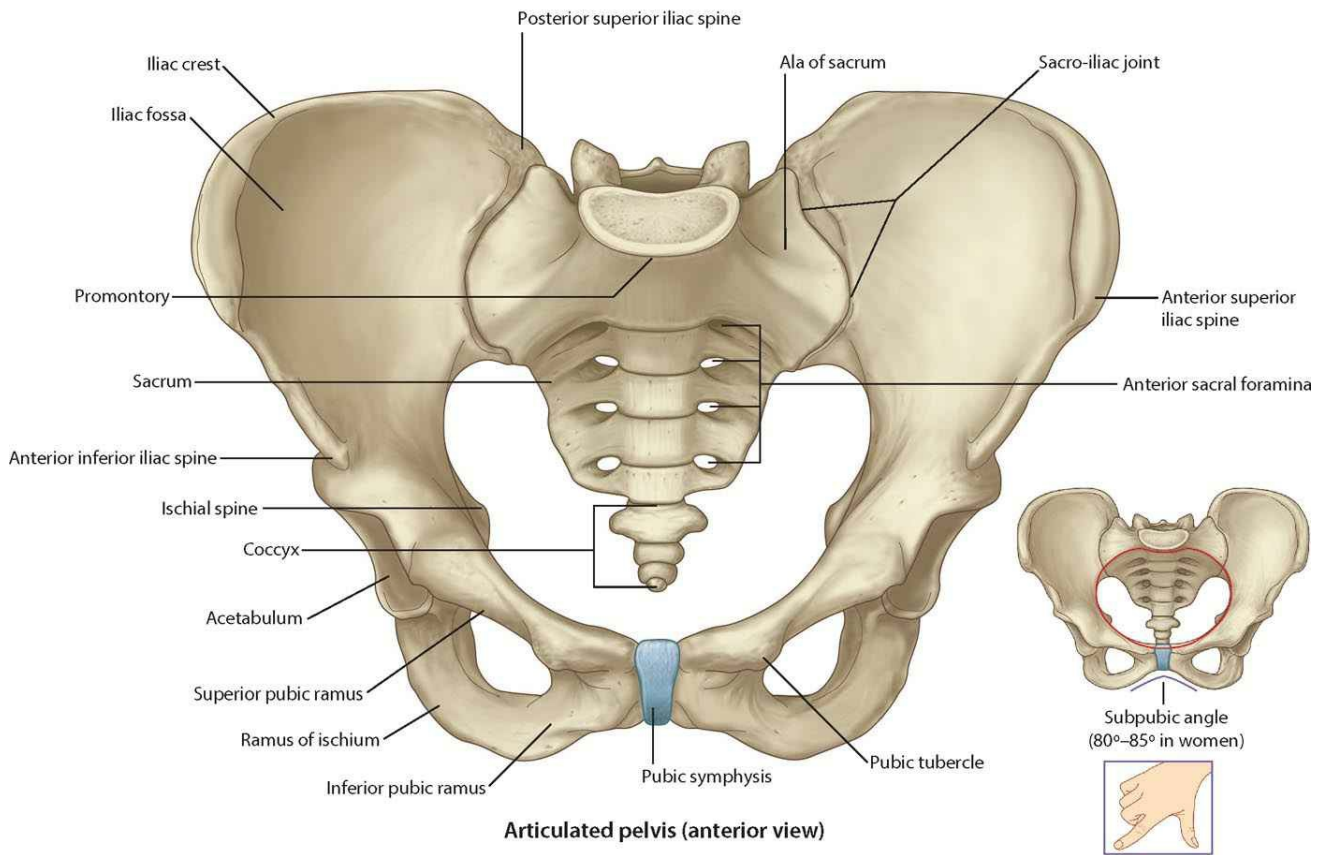
**Articulated pelvis (posterior view)**



# Surface anatomy and articulated pelvis in women

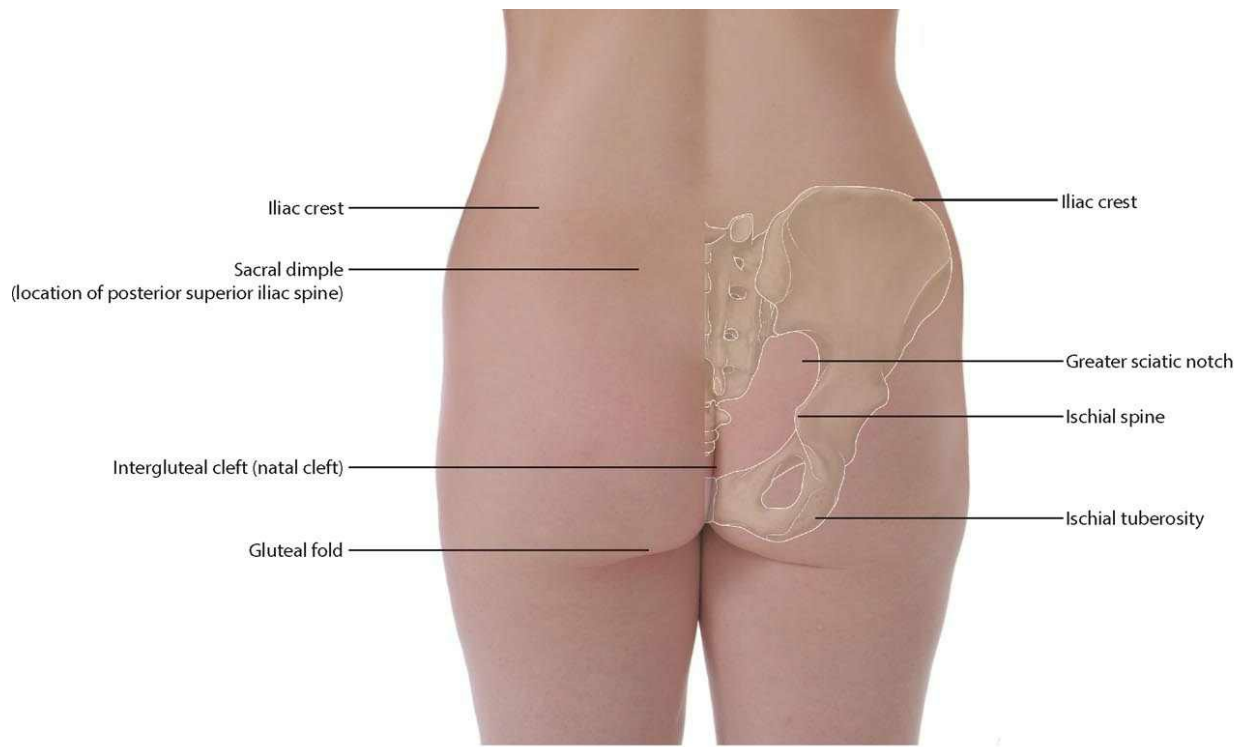


Surface anatomy with bones (anterior view)

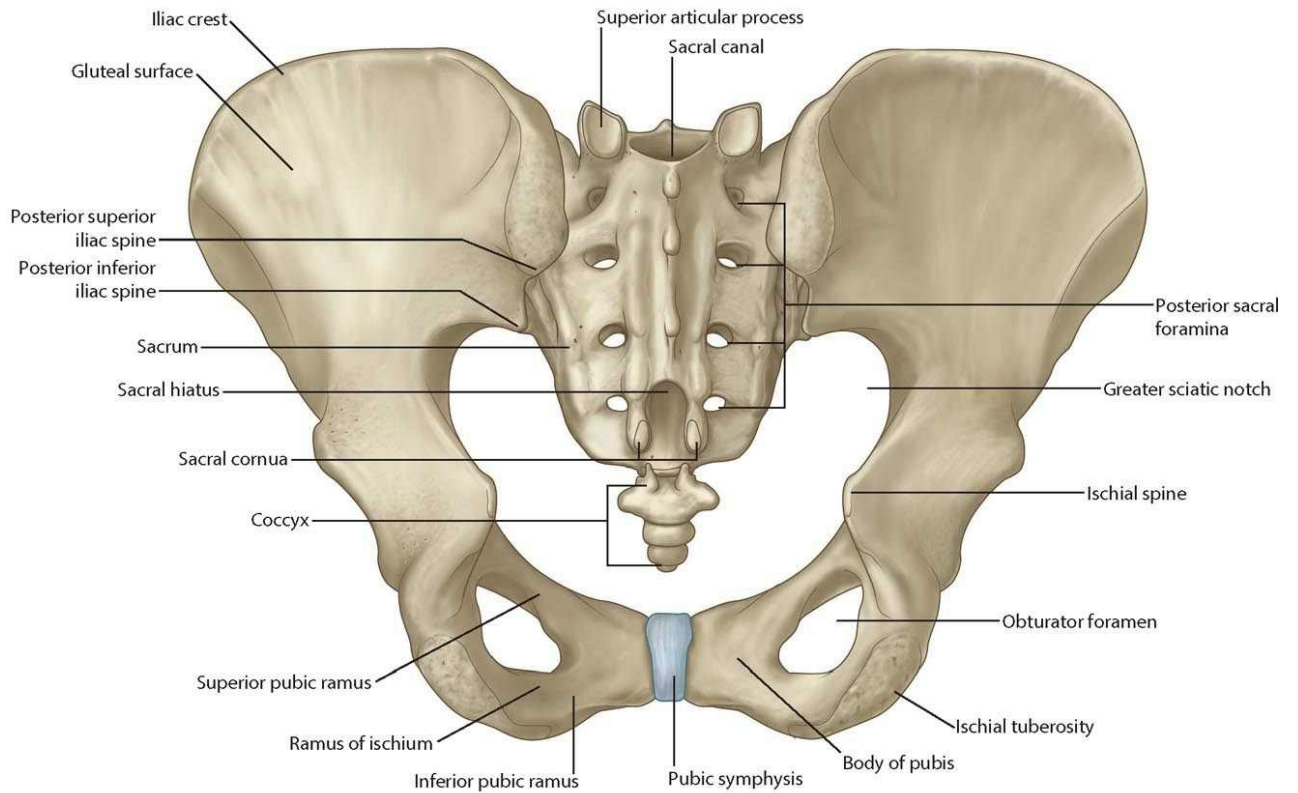


Articulated pelvis (anterior view)



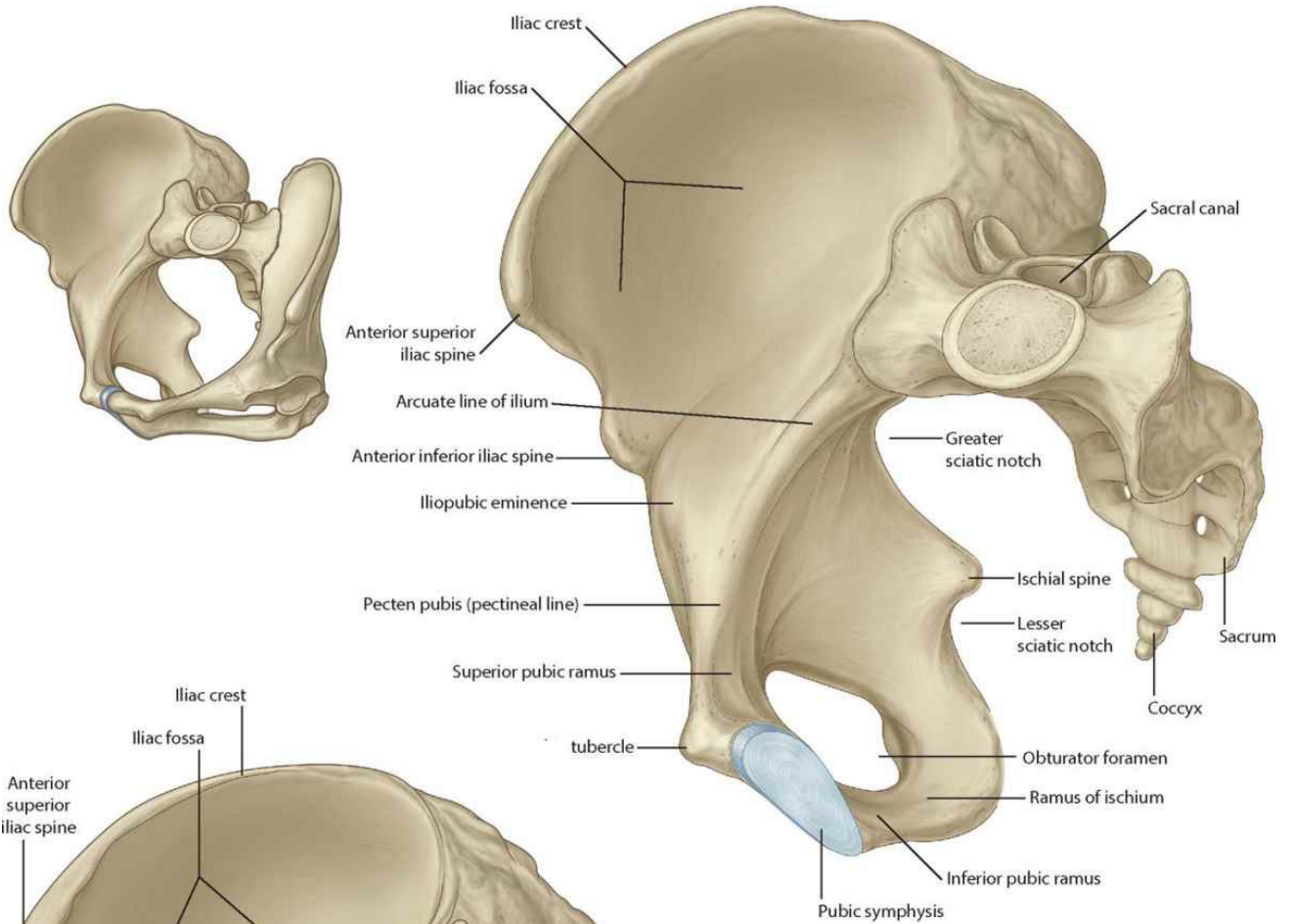


**Surface anatomy with bones (posterior view)**

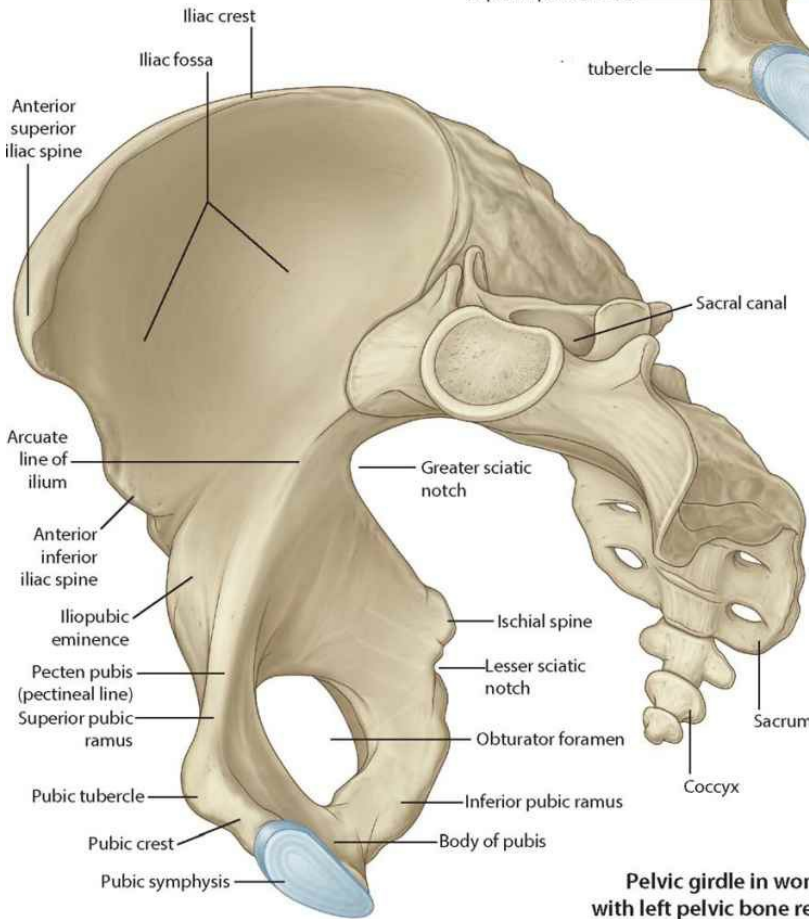


**Articulated pelvis (posterior view)**

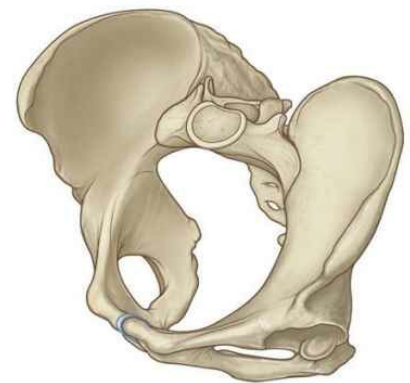# Pelvic girdle



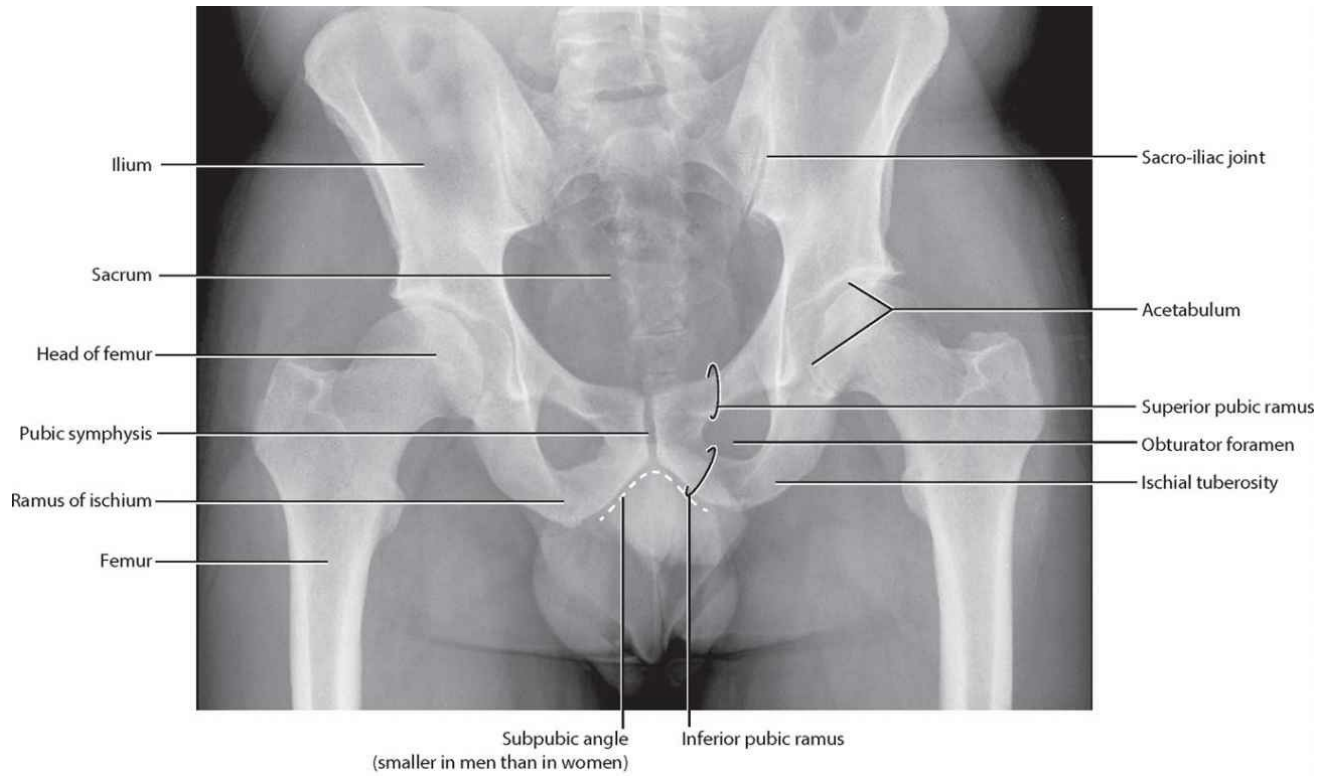
**Pelvic girdle in men  
with left pelvic bone removed  
(anterolateral superior view)**



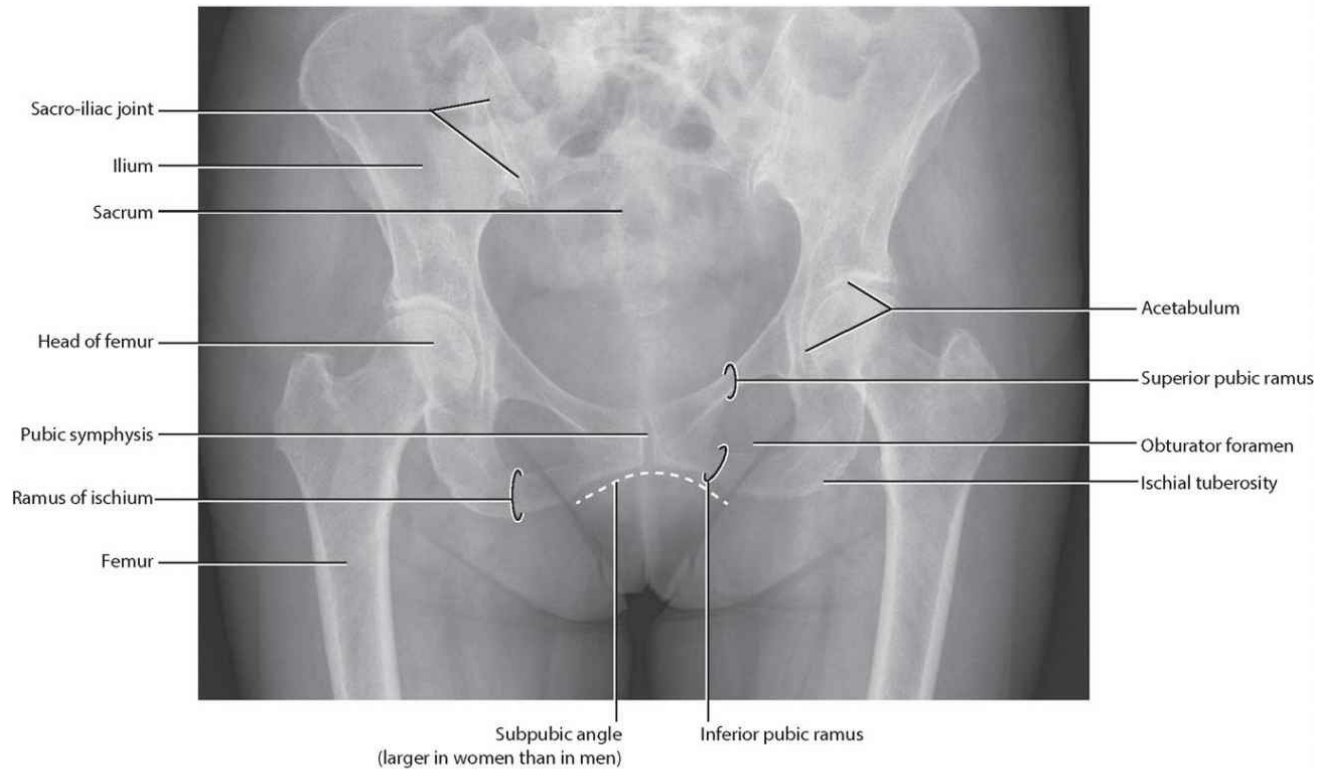
**Pelvic girdle in women  
with left pelvic bone removed  
(anterolateral superior view)**



# Pelvic girdle: imaging



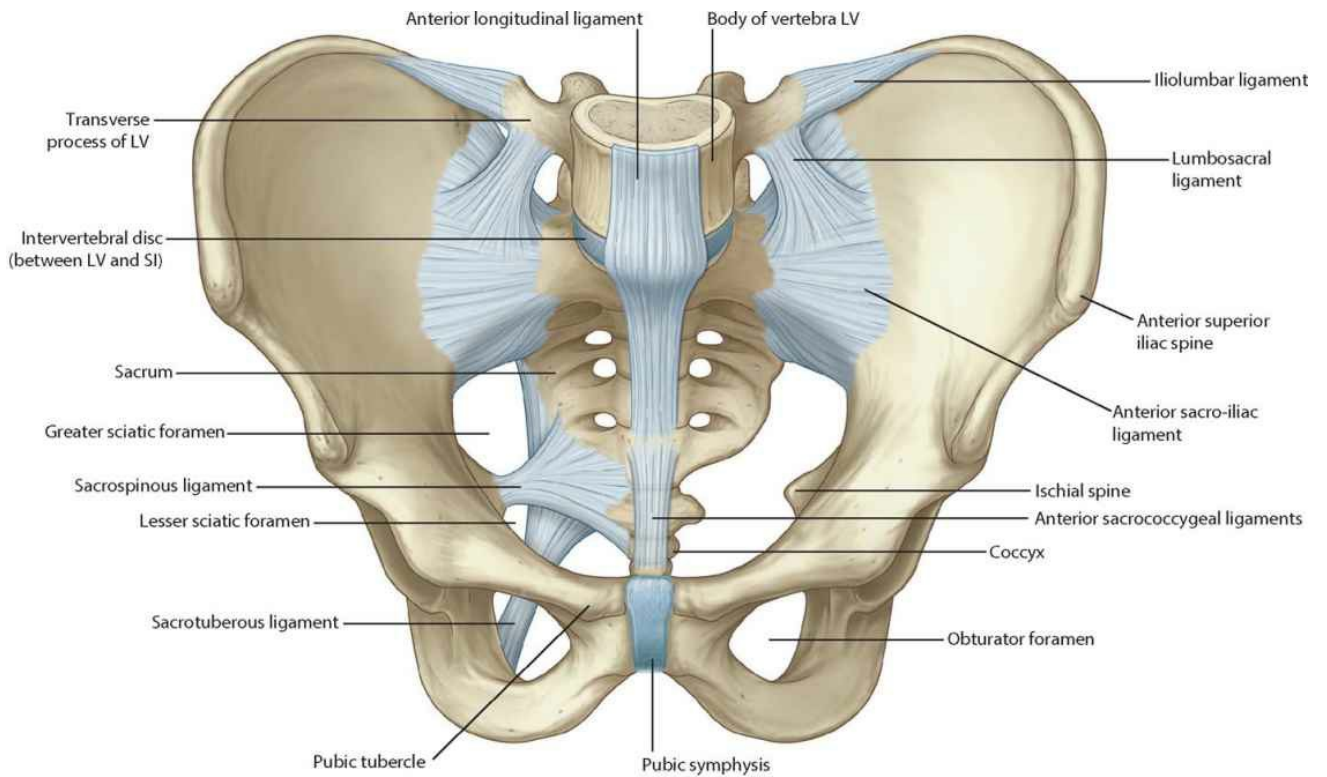
**Male bony pelvis.**  
Radiograph, anterior-posterior view



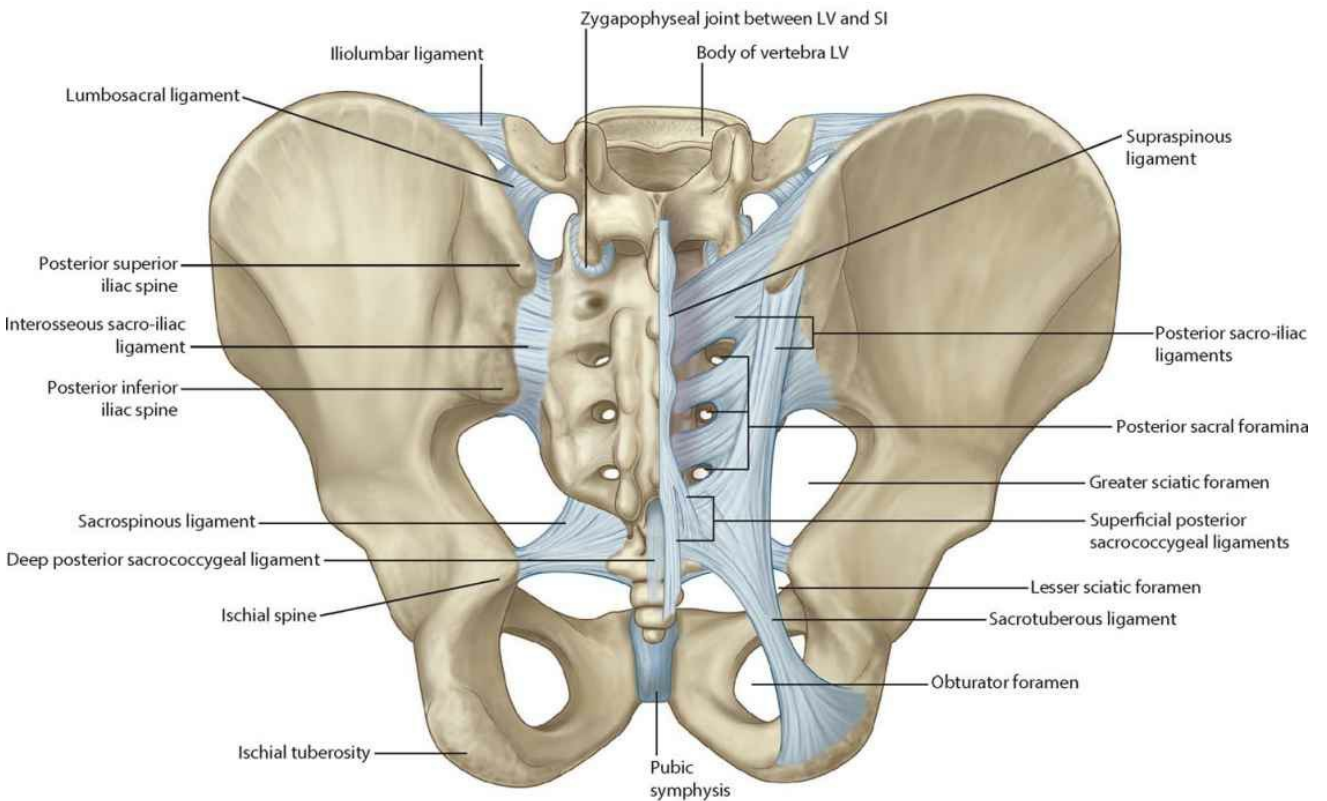
**Female bony pelvis.**  
Radiograph, anterior-posterior view



# Lumbosacral joint

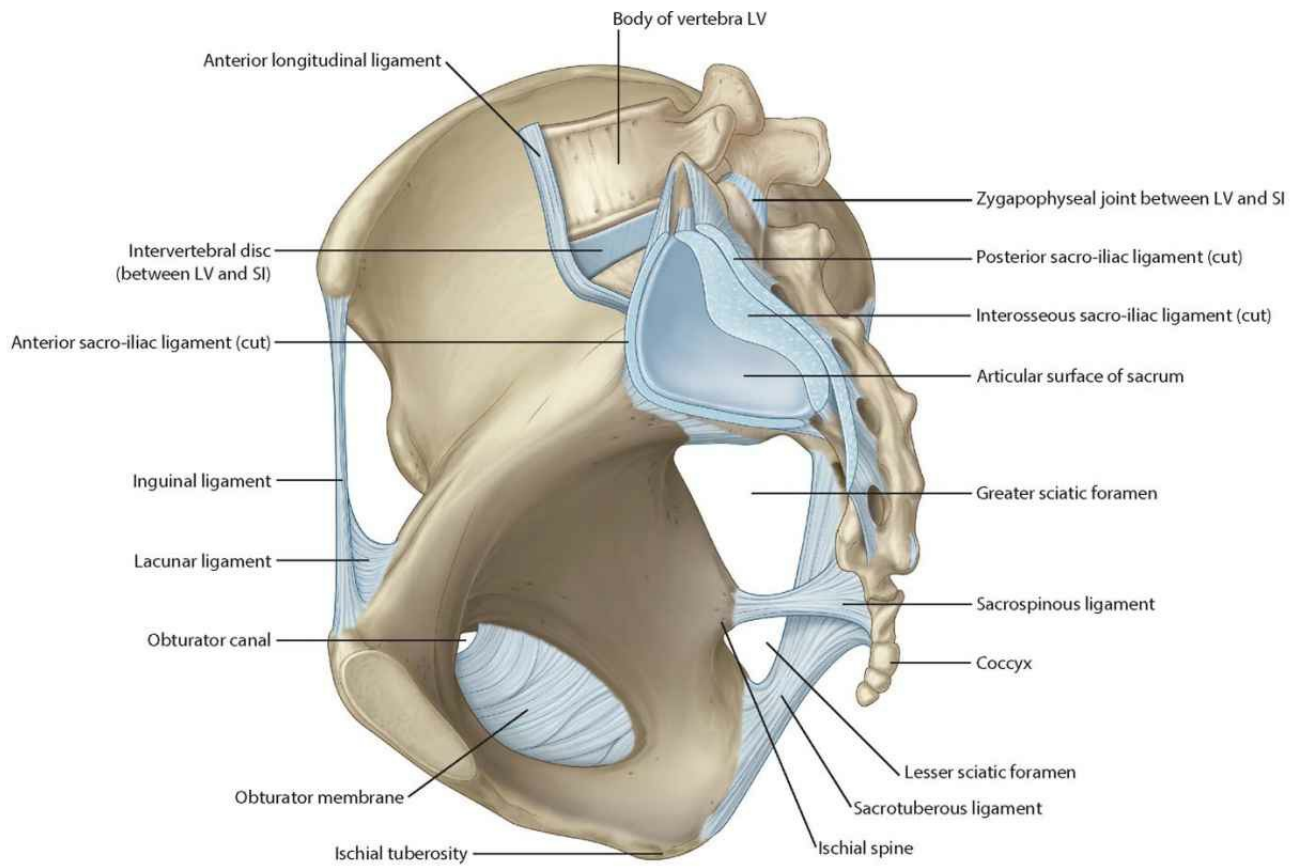


**Lumbosacral joints and associated ligaments (anterior view)**

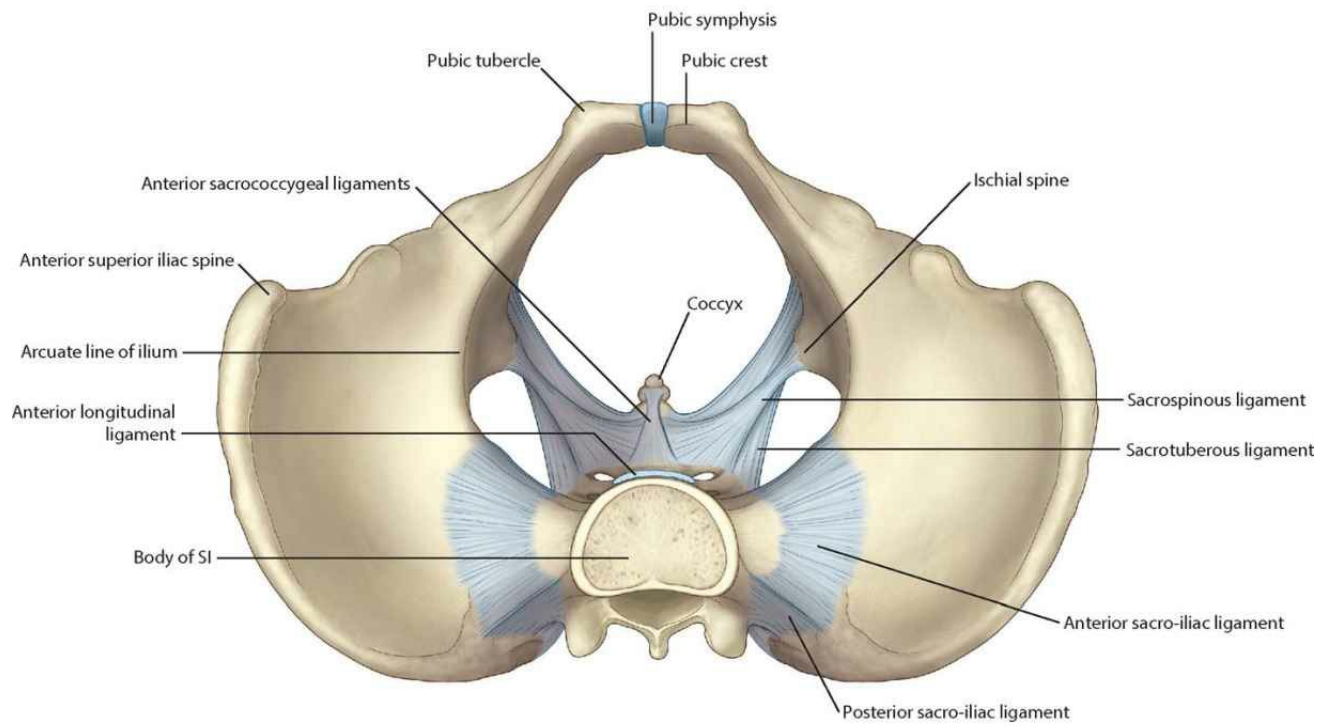


**Lumbosacral joints and associated ligaments (posterior view)**

# Sacro-iliac joint

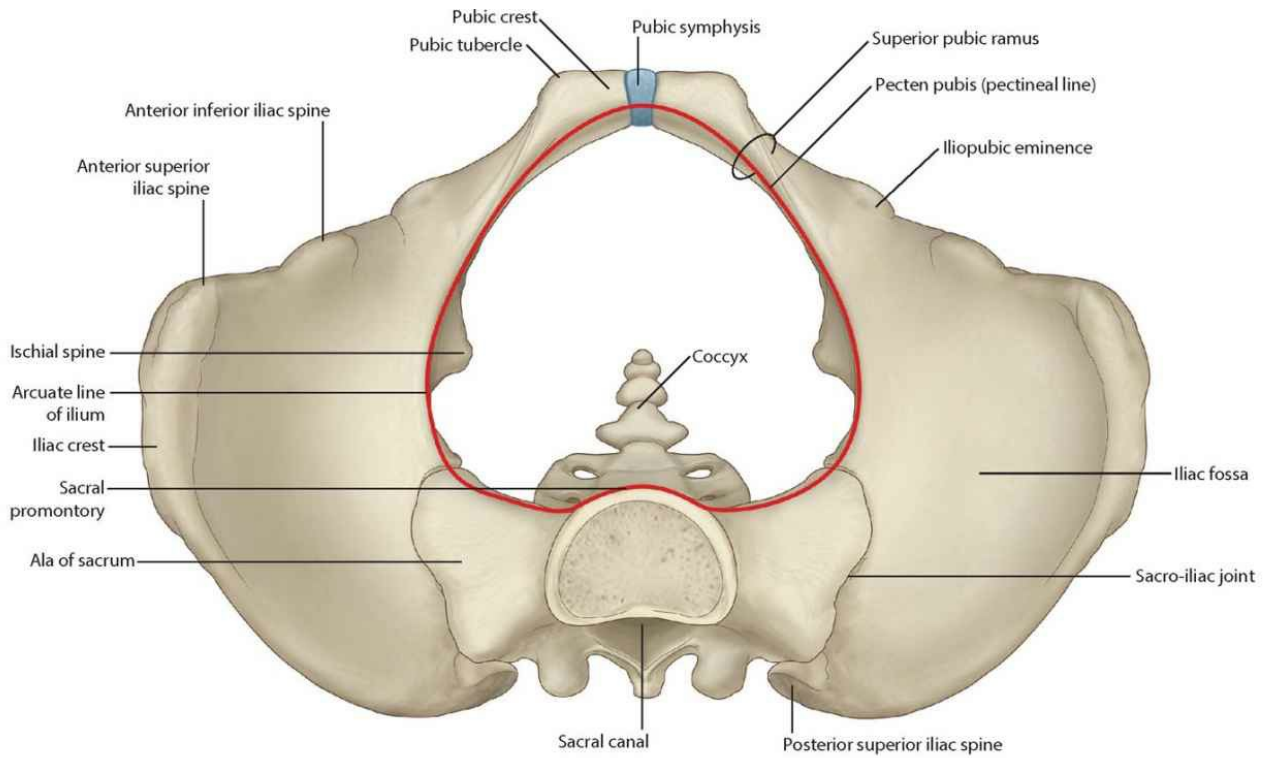


**Sacro-iliac joints and associated ligaments (lateral view with left pelvic bone removed)**

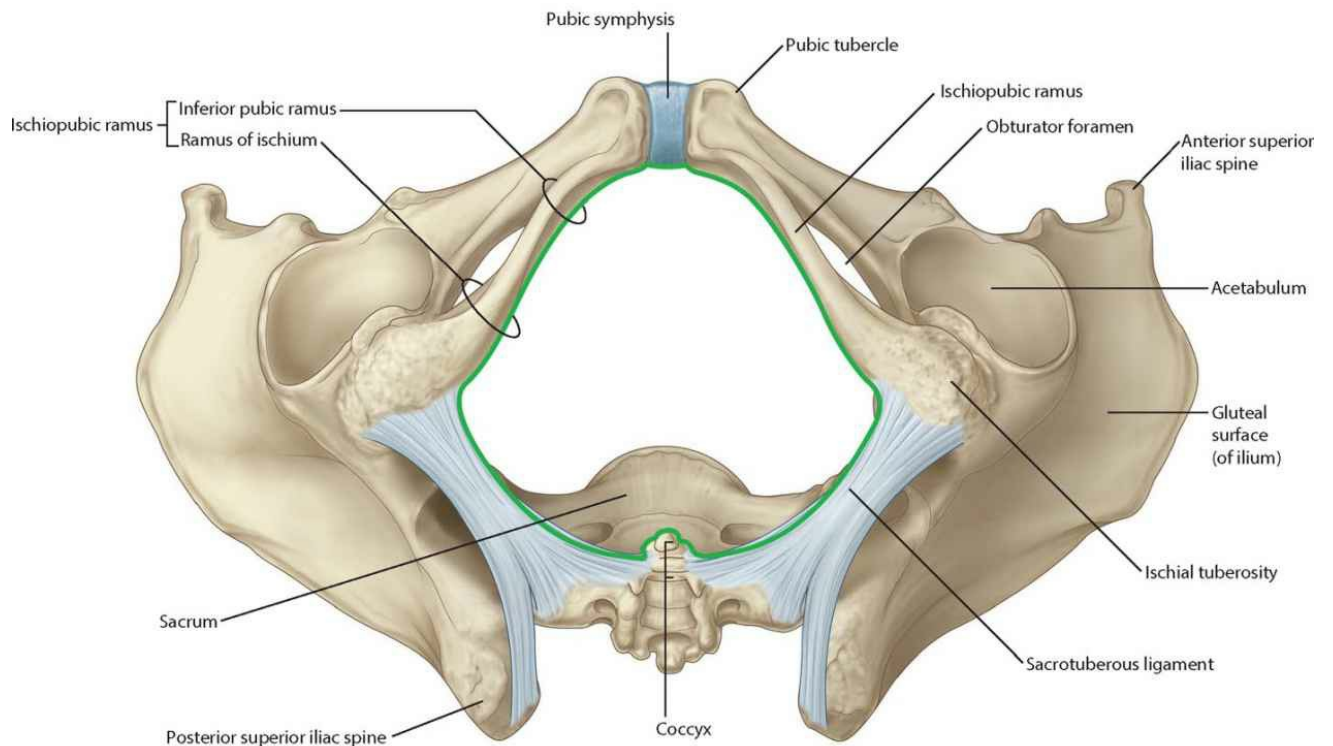


**Sacro-iliac joints (anterosuperior view)**

## **Pelvic inlet and outlet**

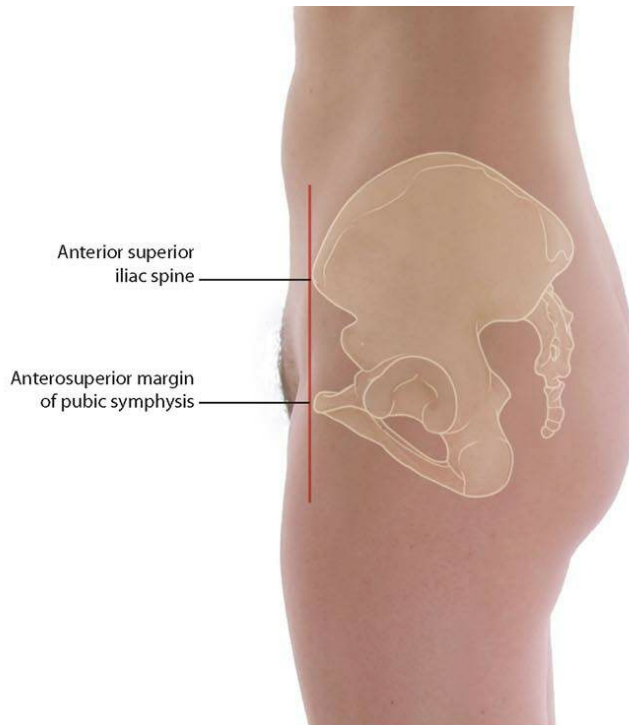

**Pelvic inlet (shown in red; anterosuperior view)**

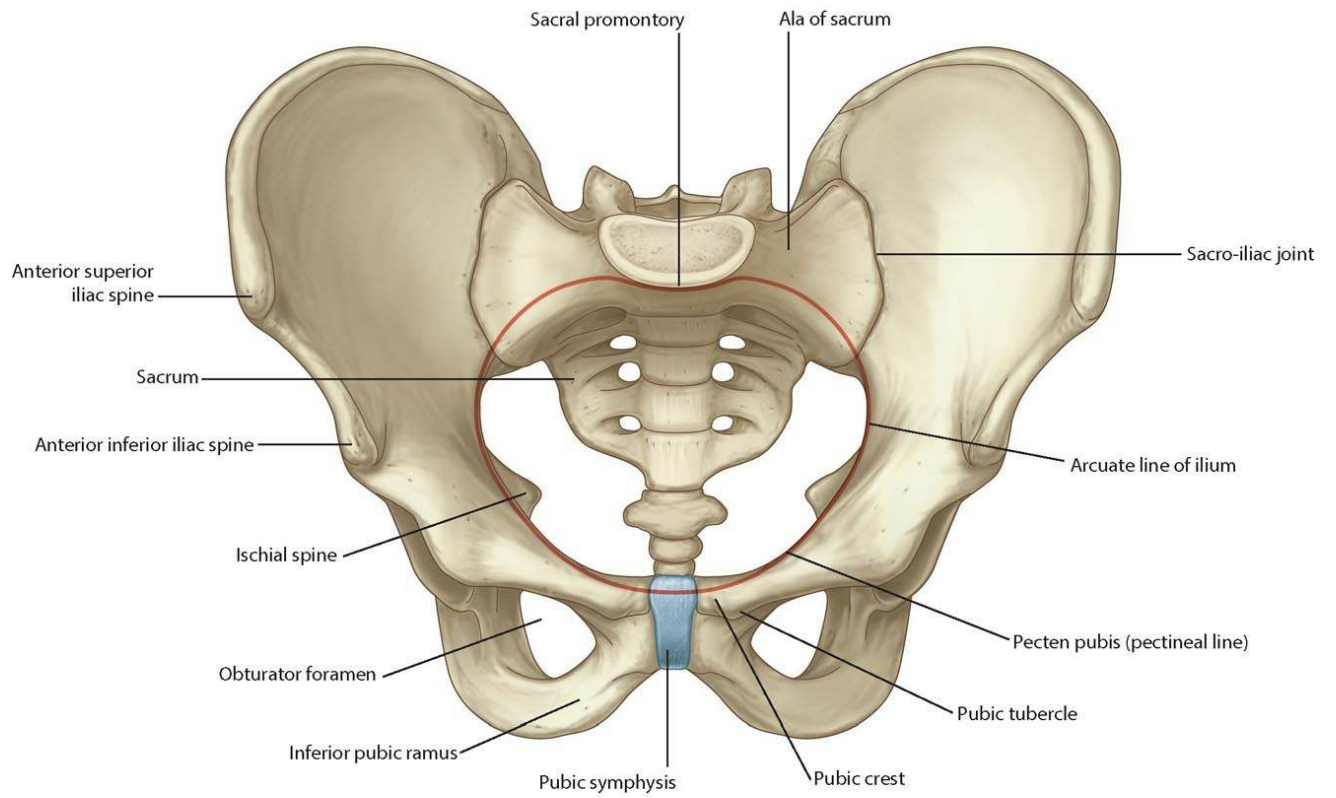


**Pelvic outlet (shown in green; anteroinferior view)**

## Orientation of pelvic girdle and pelvic brim



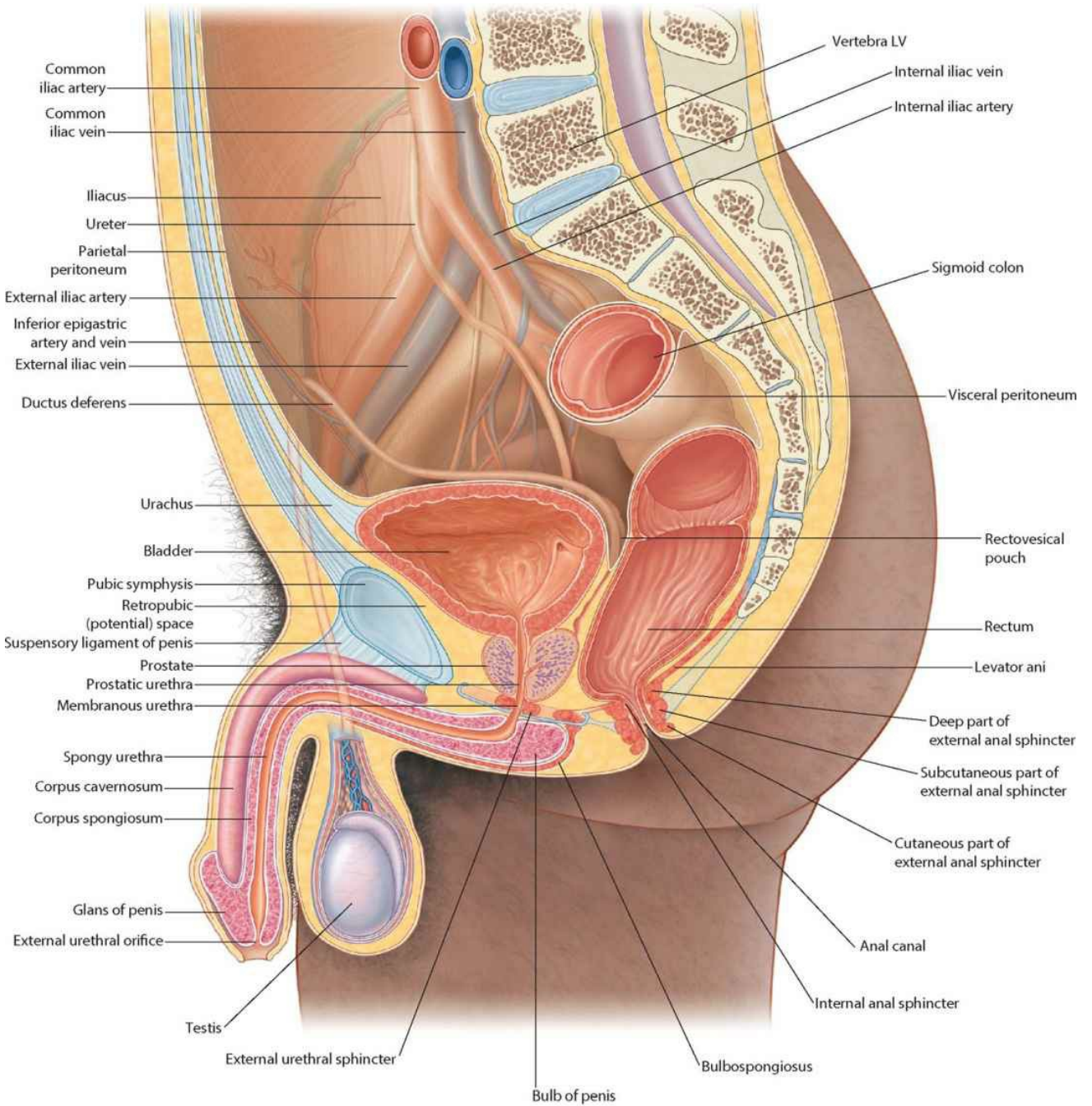
Pelvic orientation in anatomical position (lateral view)



Pelvic inlet (shown in red; anterior view)

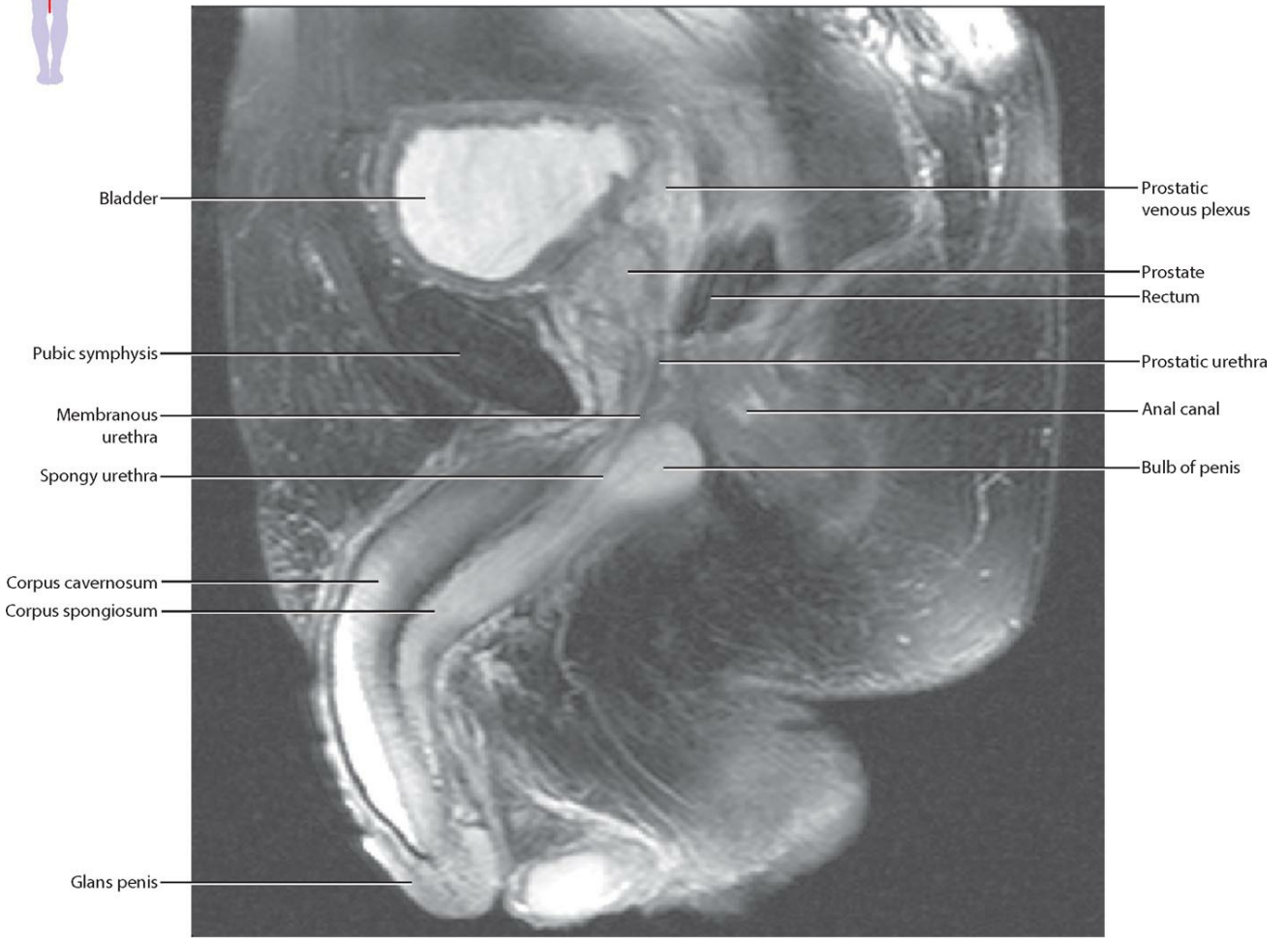
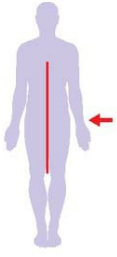


# **Pelvic viscera and perineum in men**



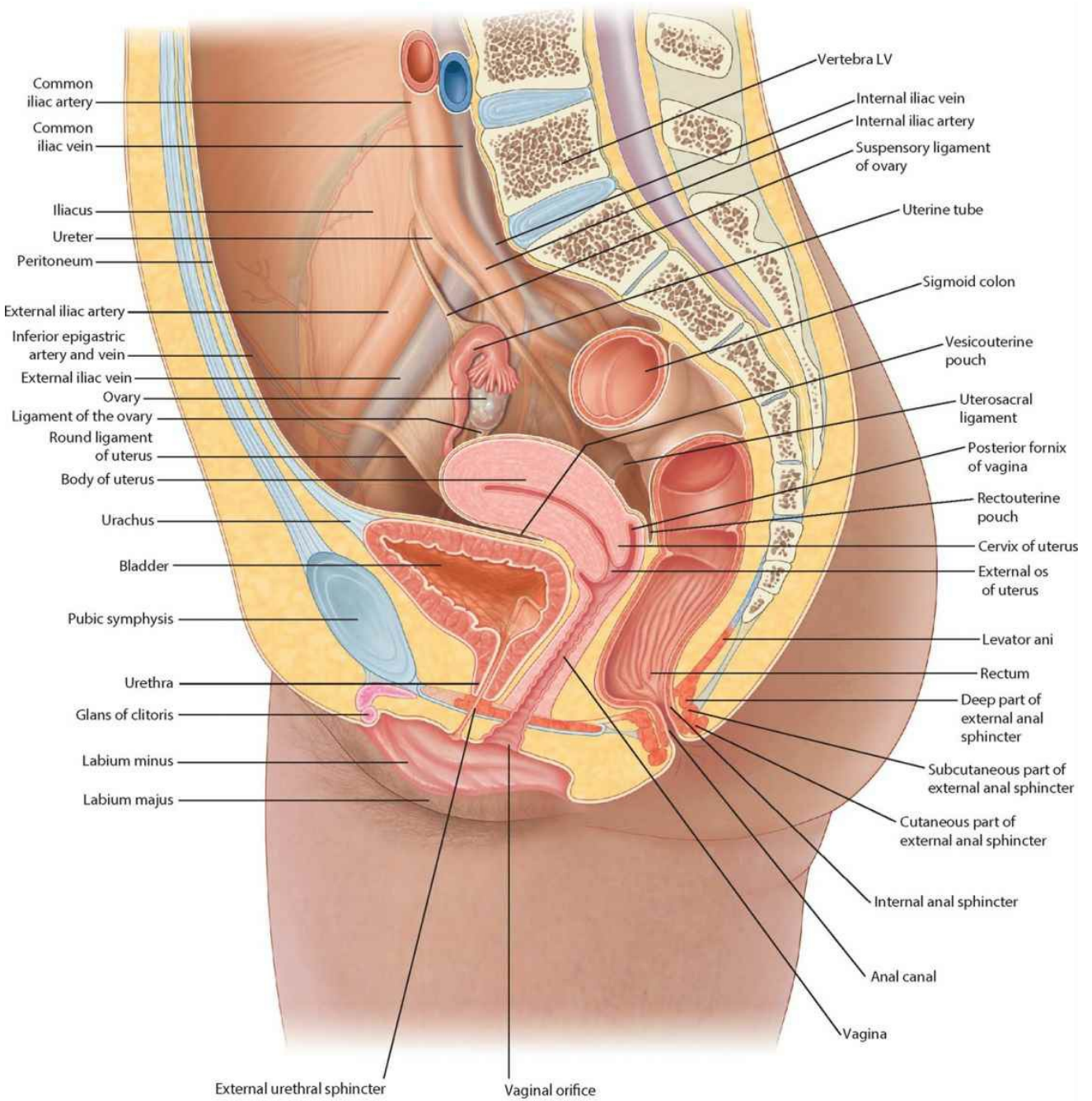
**Pelvic viscera and perineum in men *in situ* (sagittal section)**

# **Pelvic viscera and perineum in men: imaging**



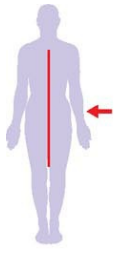
**Pelvic viscera in men.**  
T2-weighted MR image in sagittal plane

# **Pelvic viscera and perineum in women**



**Pelvic viscera and perineum in women *in situ* (sagittal section)**

# **Pelvic viscera and perineum in women: imaging**



Sacral promontory

Small intestine

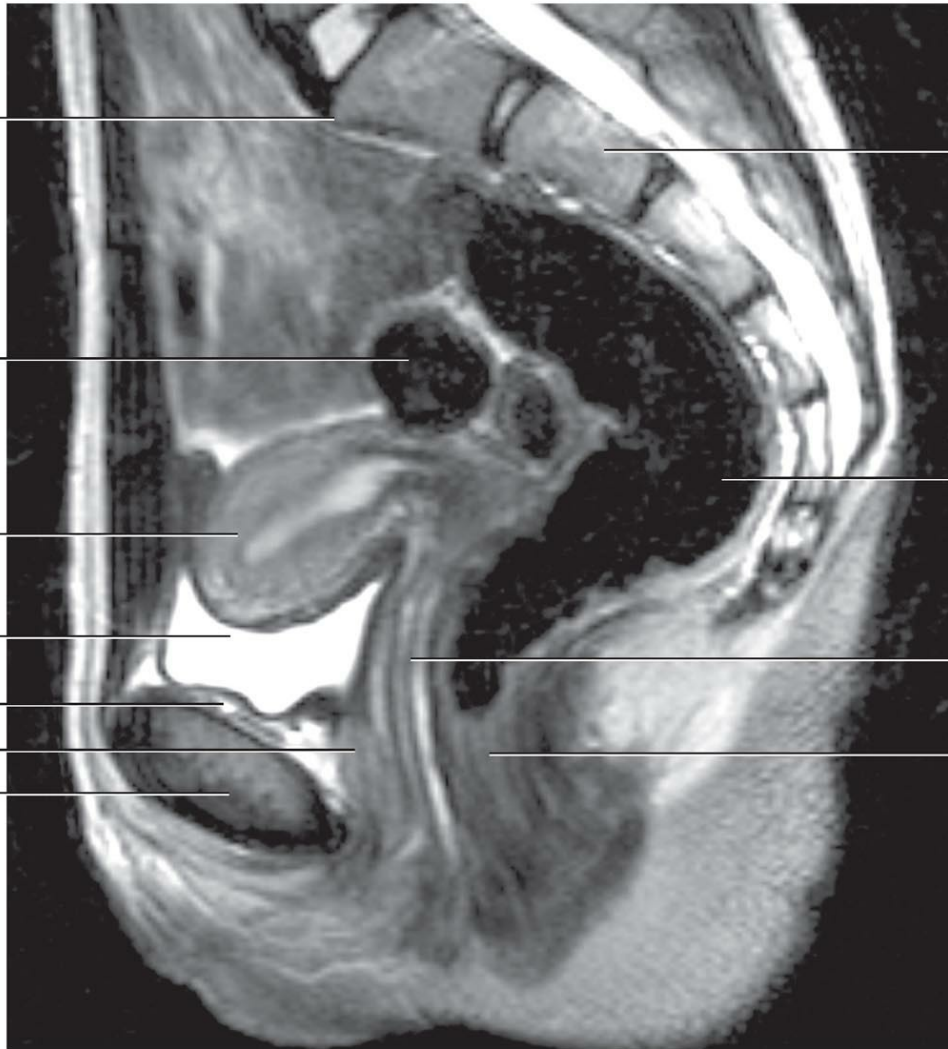Uterus

Bladder

Retropubic  
(potential) space

Urethra

Pubic symphysis



Vertebra SII

Rectum

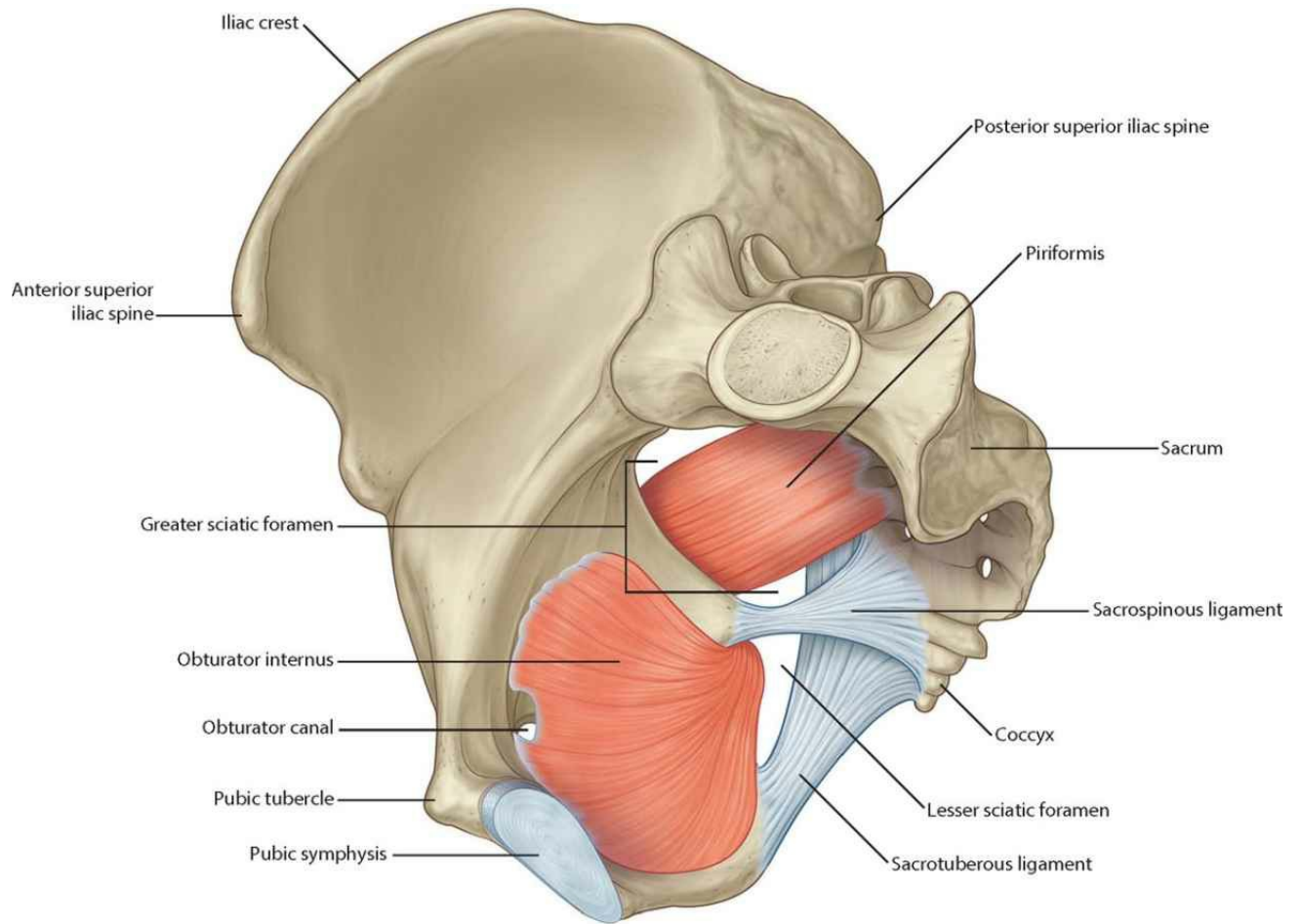
Vagina

Anal canal

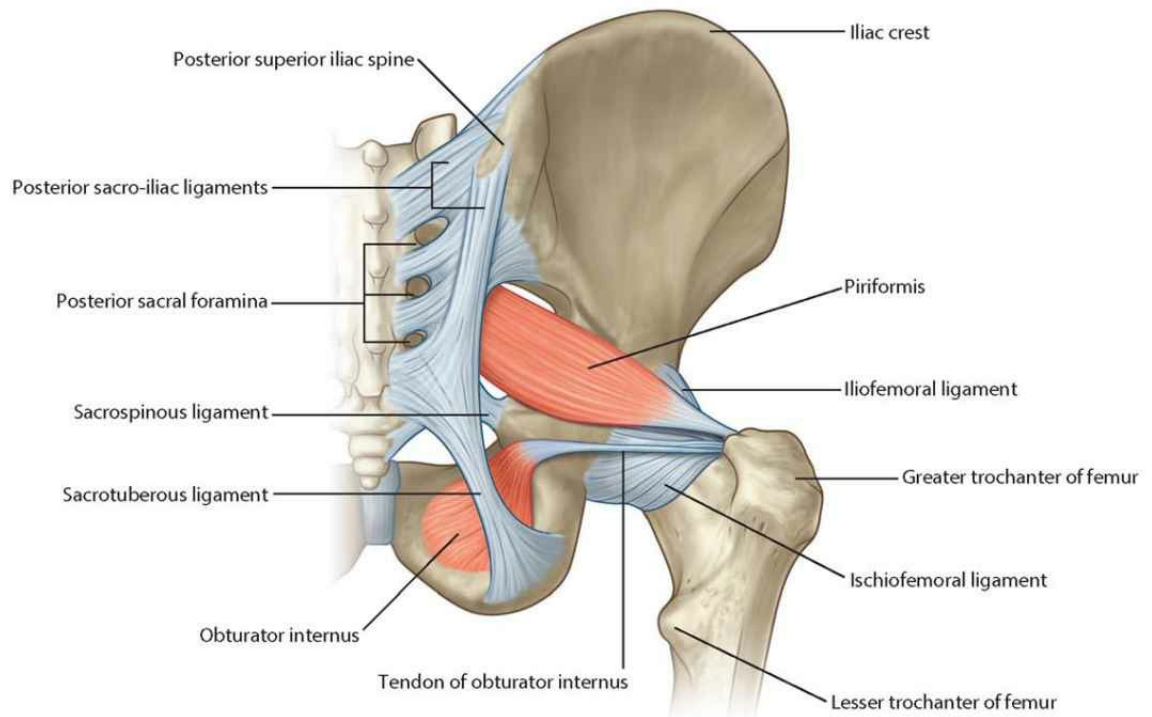
**Pelvic viscera in women.**  
T2-weighted MR image in sagittal plane



## Lateral wall of pelvic cavity



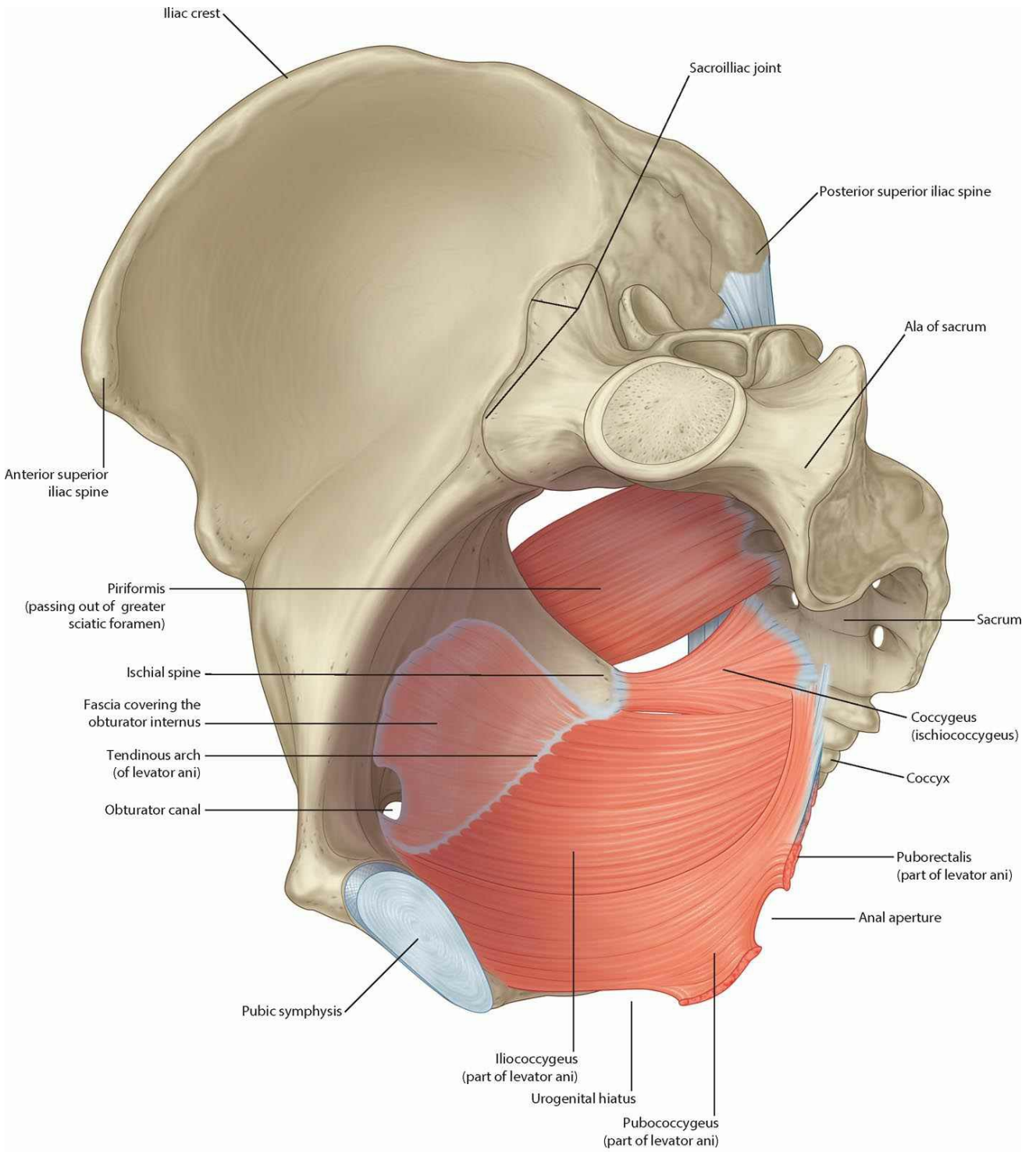
**Obturator internus and piriformis muscles (oblique medial view)**



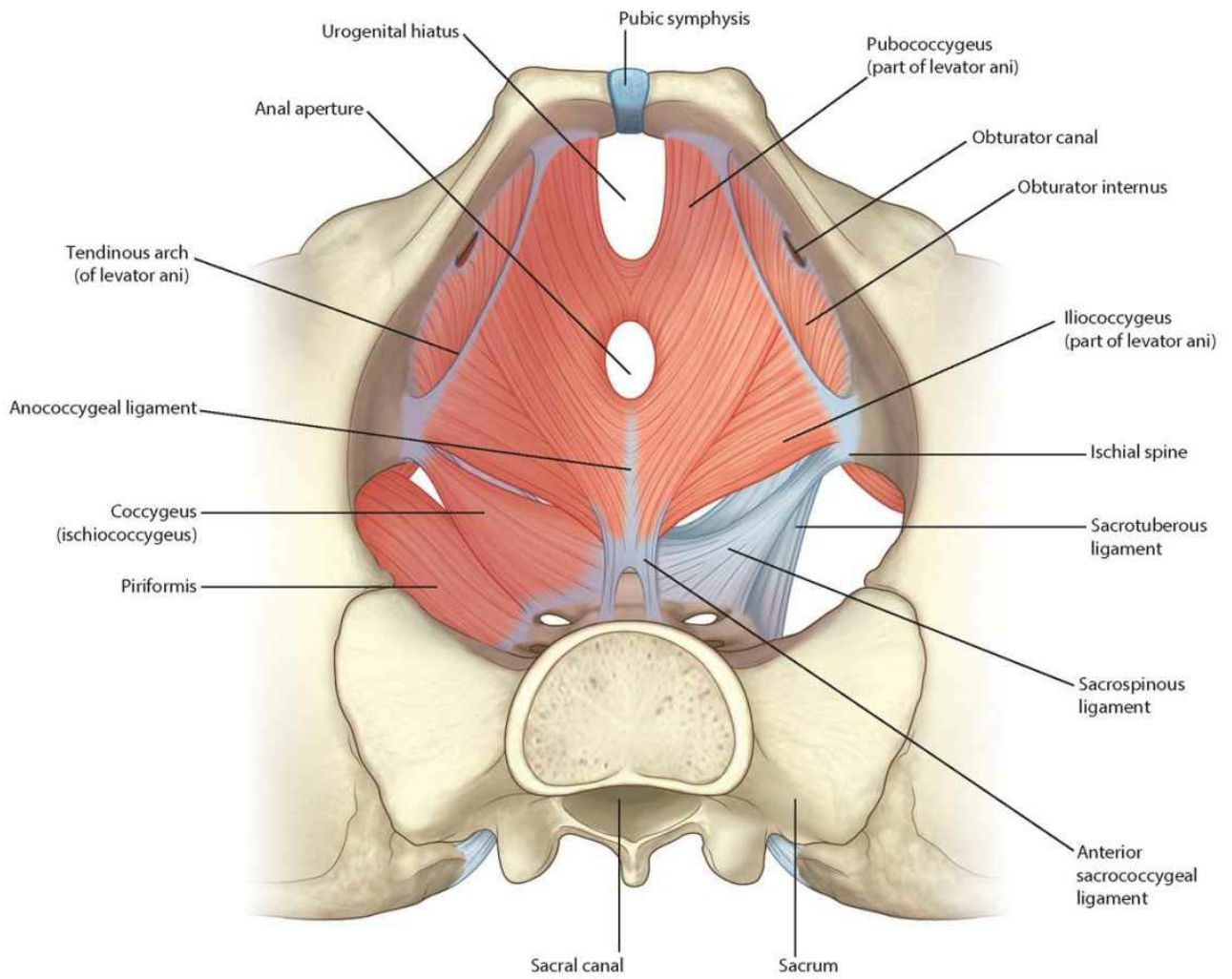
**Obturator internus and piriformis muscles (posterior view)**



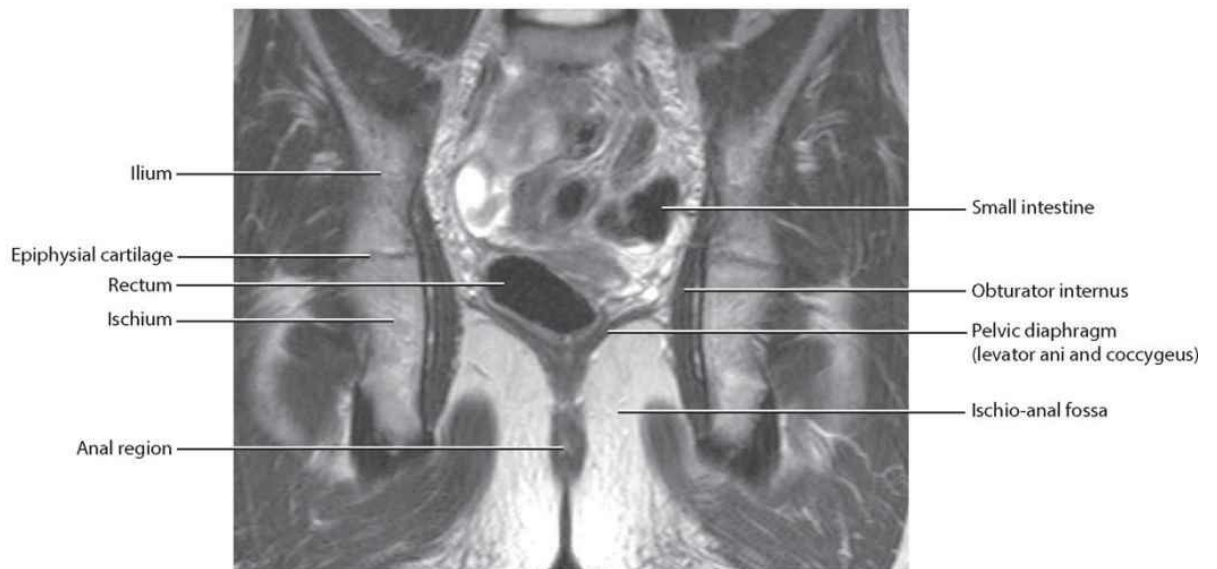
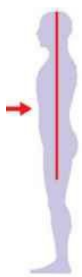
**Floor of pelvic cavity: pelvic diaphragm**



Levator ani and coccygeus (ischiococcygeus) muscles (oblique sagittal view)



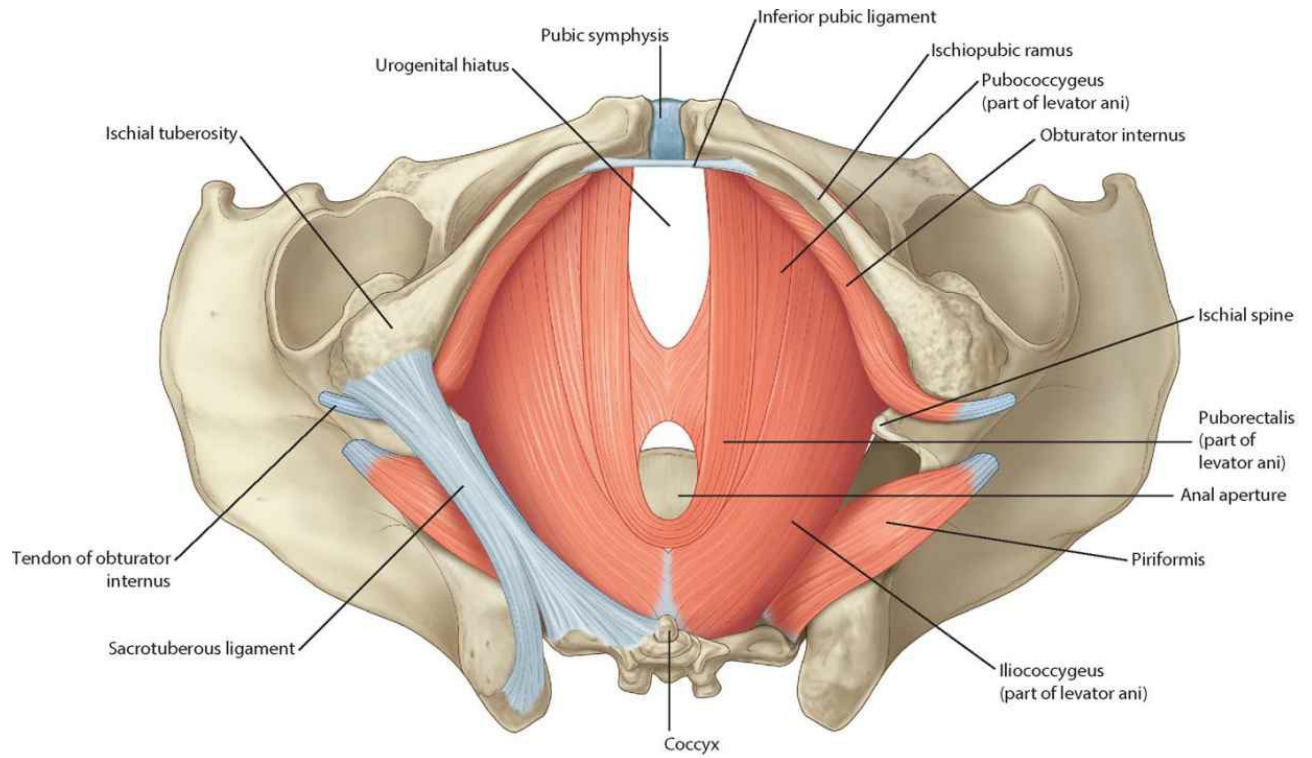
**Levator ani and coccygeus (ischiococcygeus) muscles (anterosuperior view)**



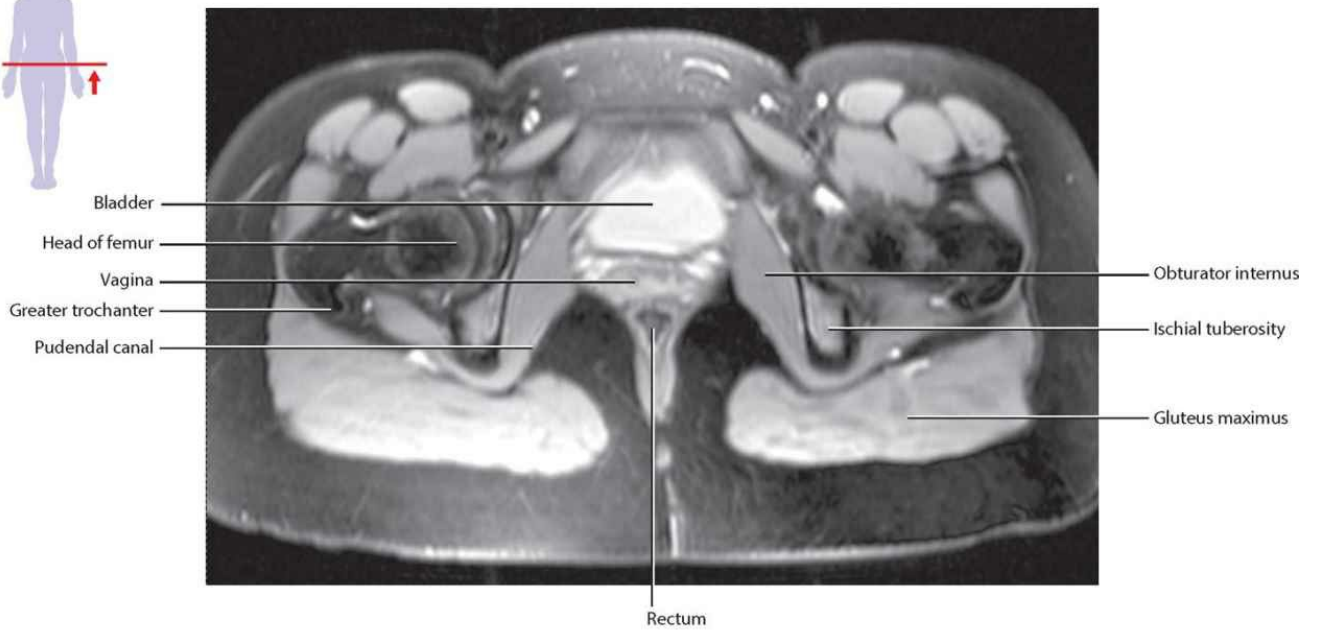
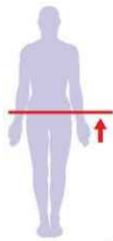
**Pelvic diaphragm in relation to other structures in the pelvic cavity and perineum.**

T2-weighted MR image in coronal plane





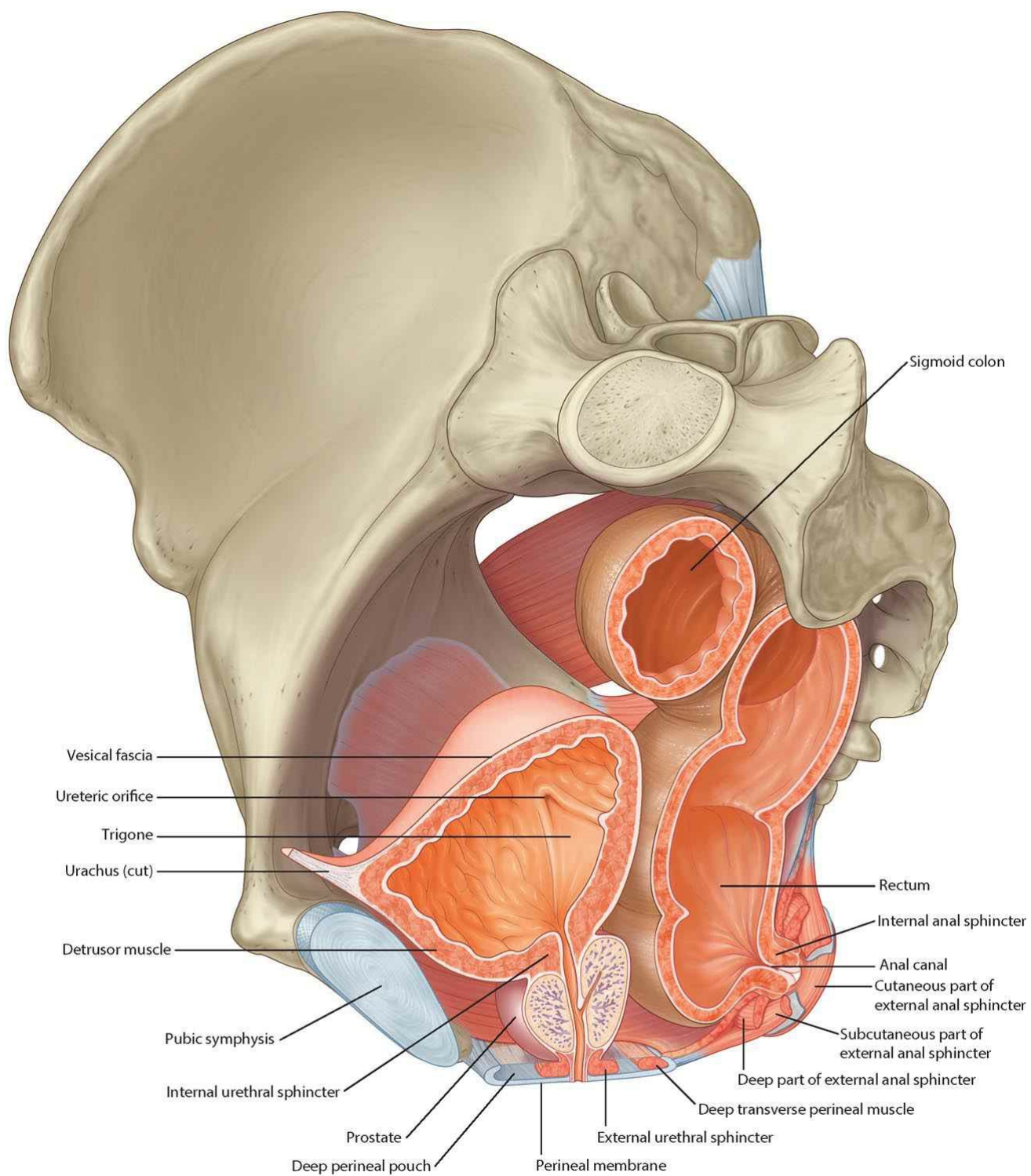
**Levator ani muscle (inferior view)**



**Obturator internus muscle and its relationship to other pelvic structures.**  
T2-weighted MR image in axial plane

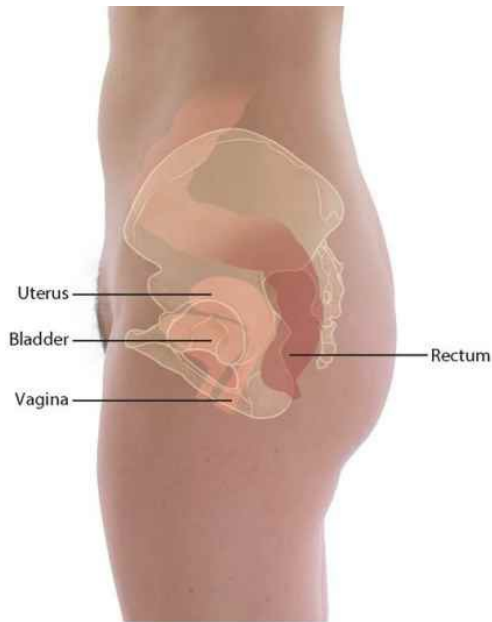


## Rectum and bladder in situ

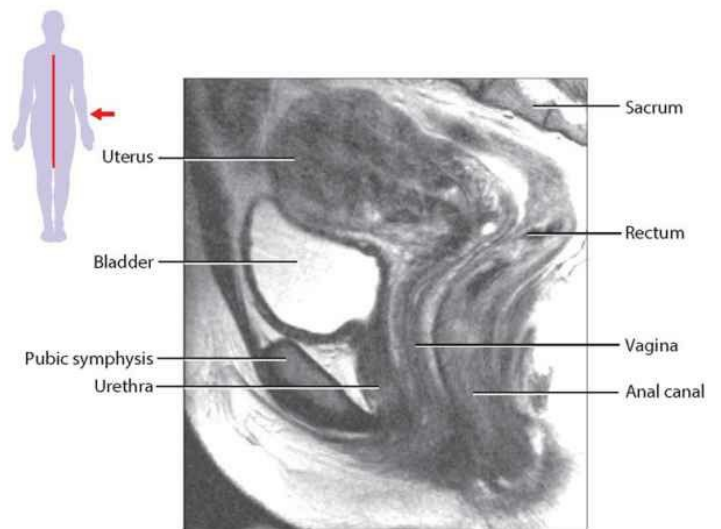


**Bladder, prostate, and rectum within pelvic cavity in men (oblique sagittal view)**

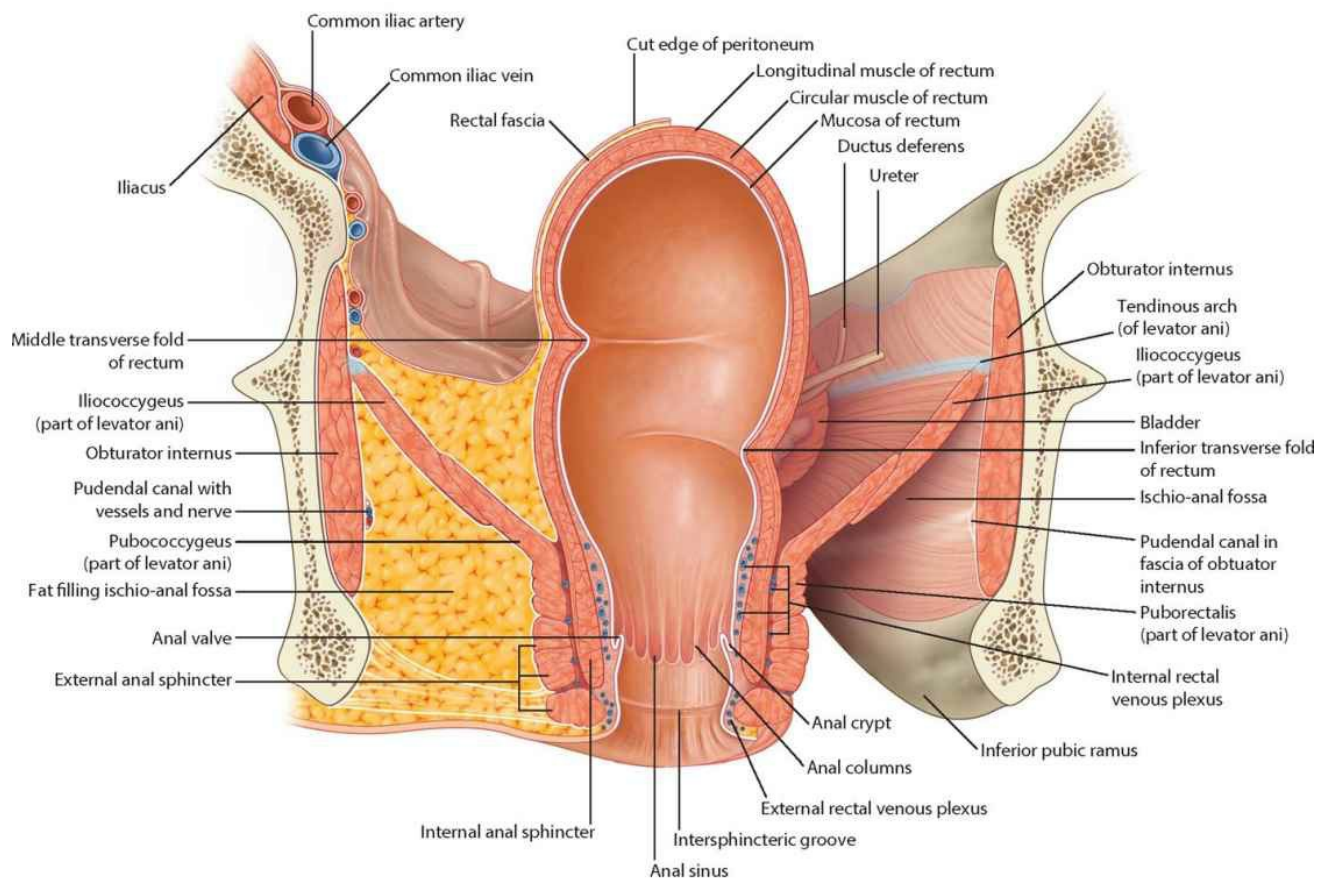
# Rectum



Surface projection of the rectum in women

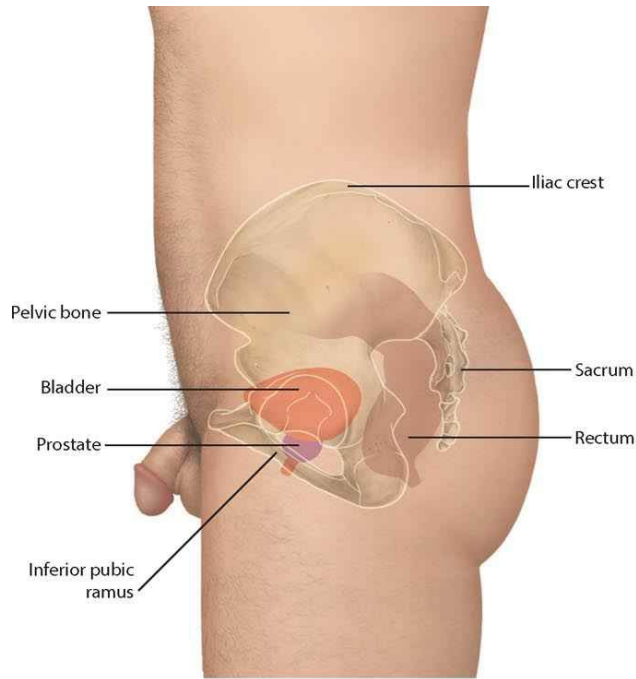


Positioning of the rectum and anal canal in relation to the other female pelvic viscera.  
T2-weighted MR image in sagittal plane

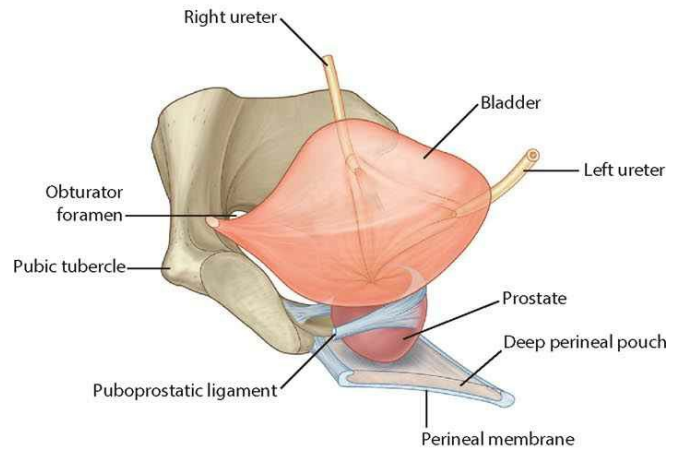


Coronal section through rectum and anal canal (posterior view)

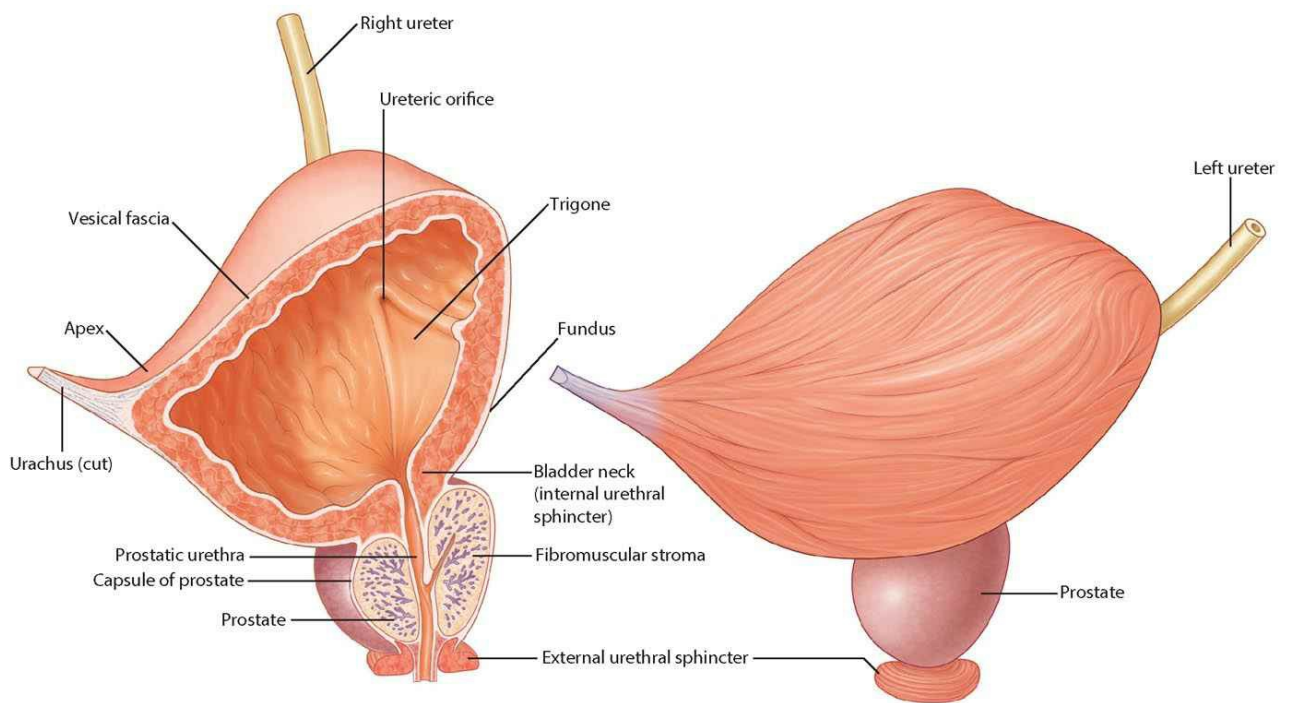
# Bladder in men



Surface projection of the bladder in men (lateral view)

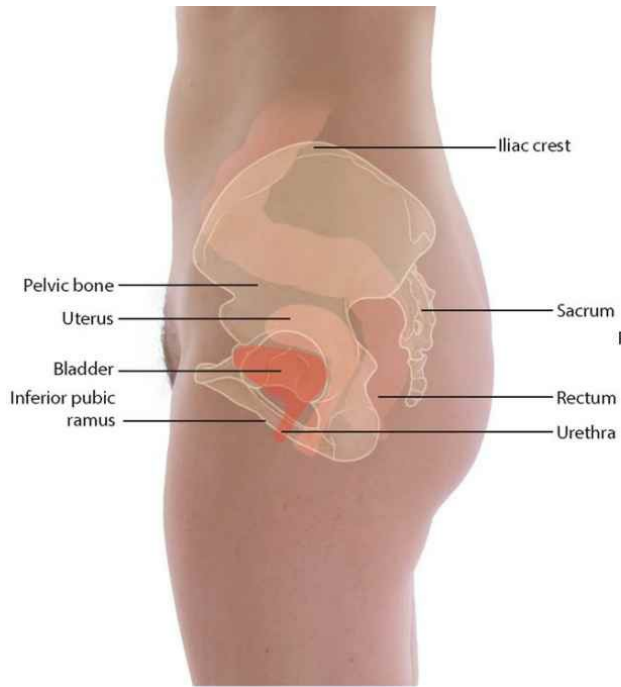

Puboprostatic ligament

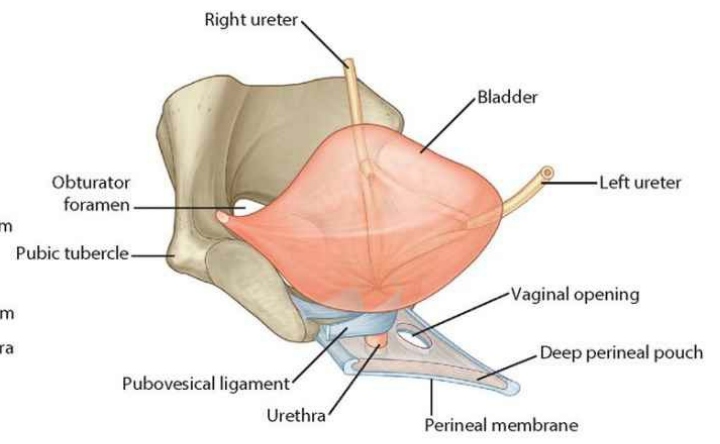


Urinary bladder in men

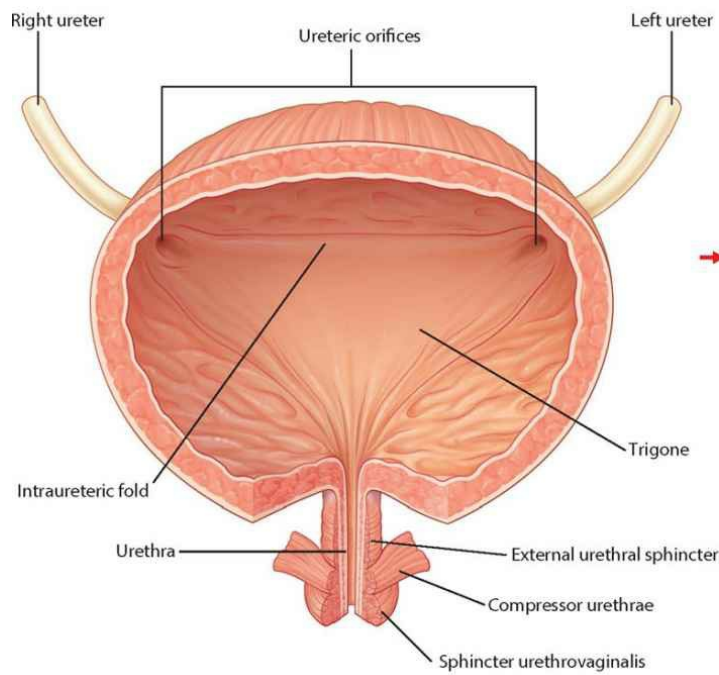
# Bladder in women



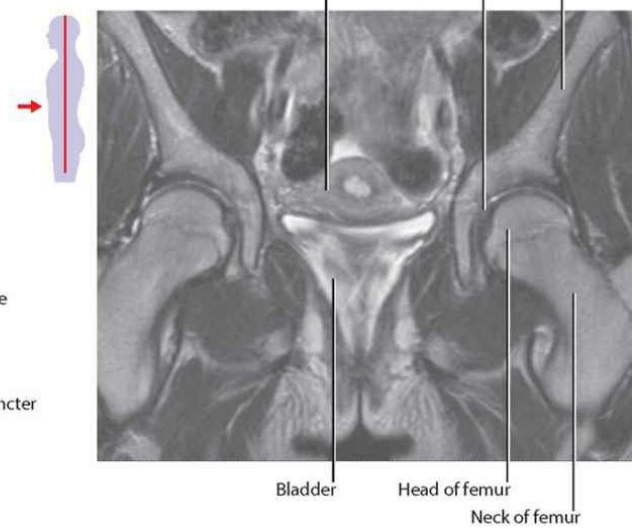
Surface projection of the bladder in women (lateral view)



Pubovesical ligament



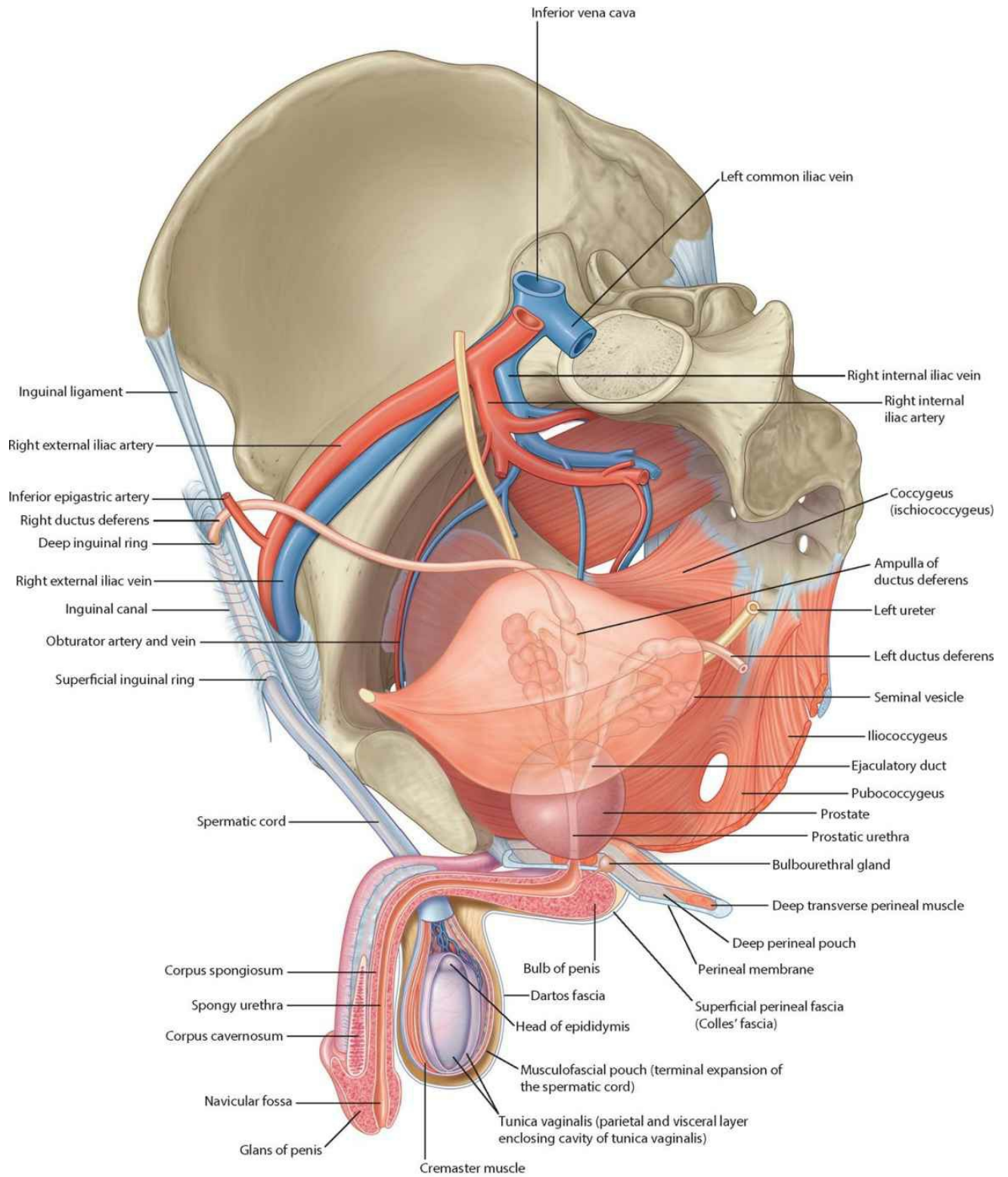
Urinary bladder and urethral sphincter muscles in women (anterior view of posterior wall)



Appearance and positioning of the bladder in relation to other structures in the female pelvic cavity. T2-weighted MR image in coronal plane

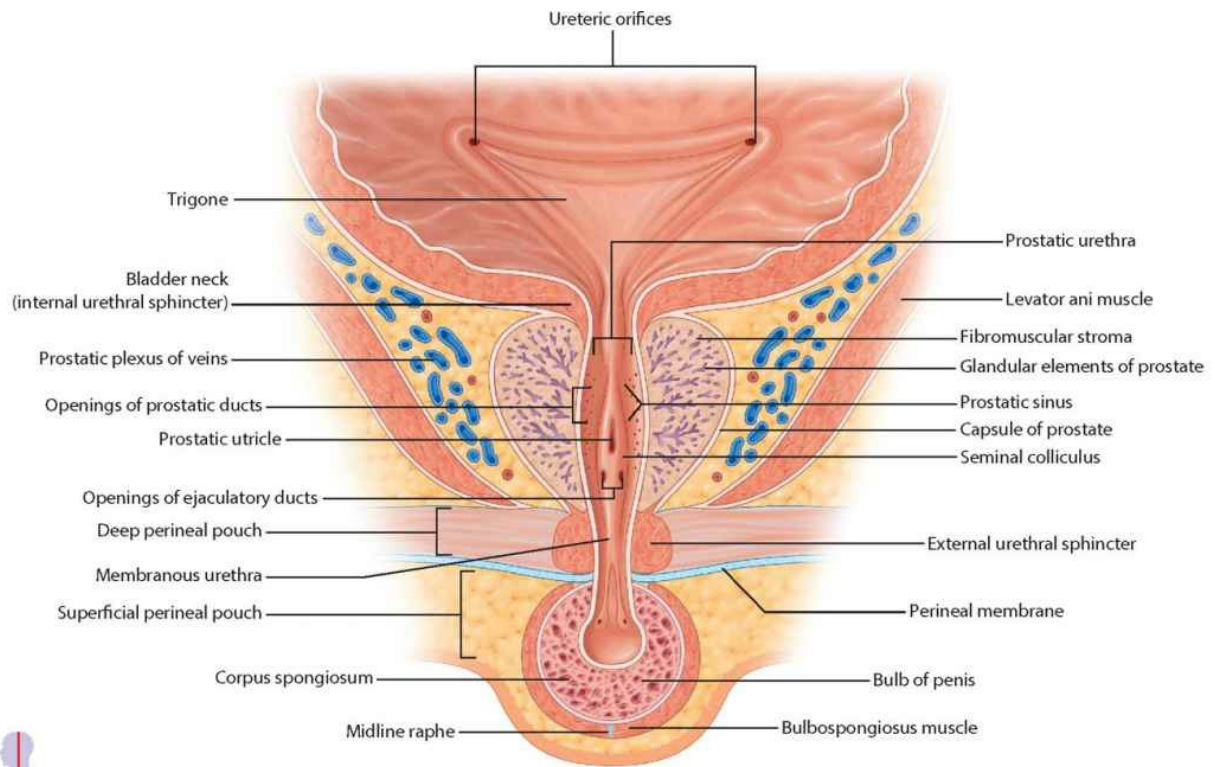


# Reproductive system in men

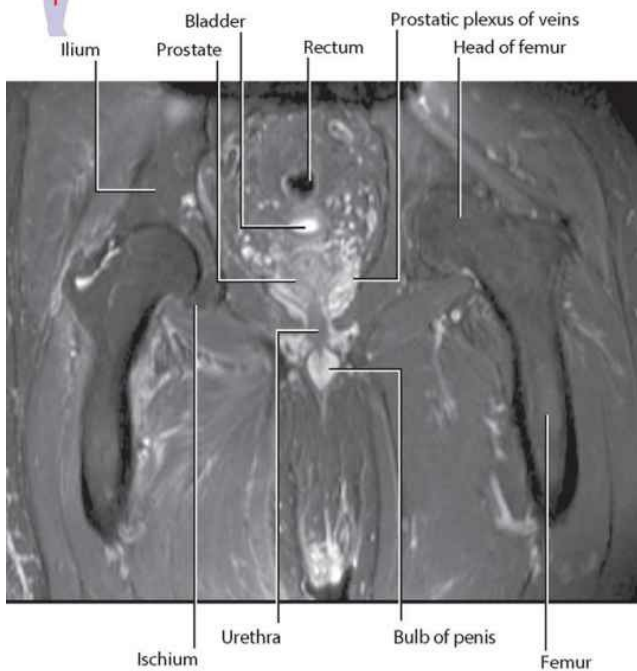
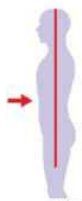


**Reproductive system in men (oblique sagittal view)**

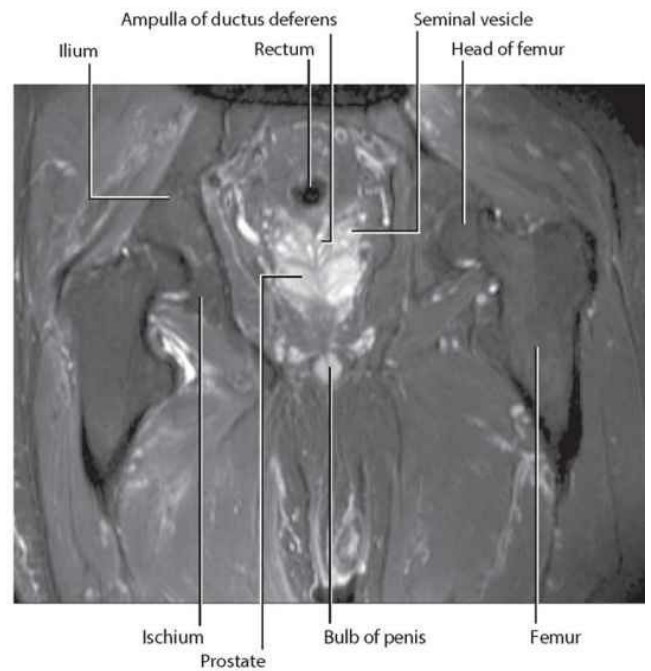
# Prostate



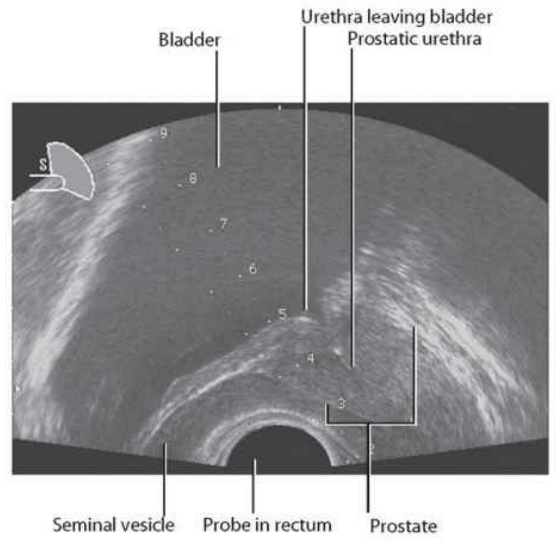
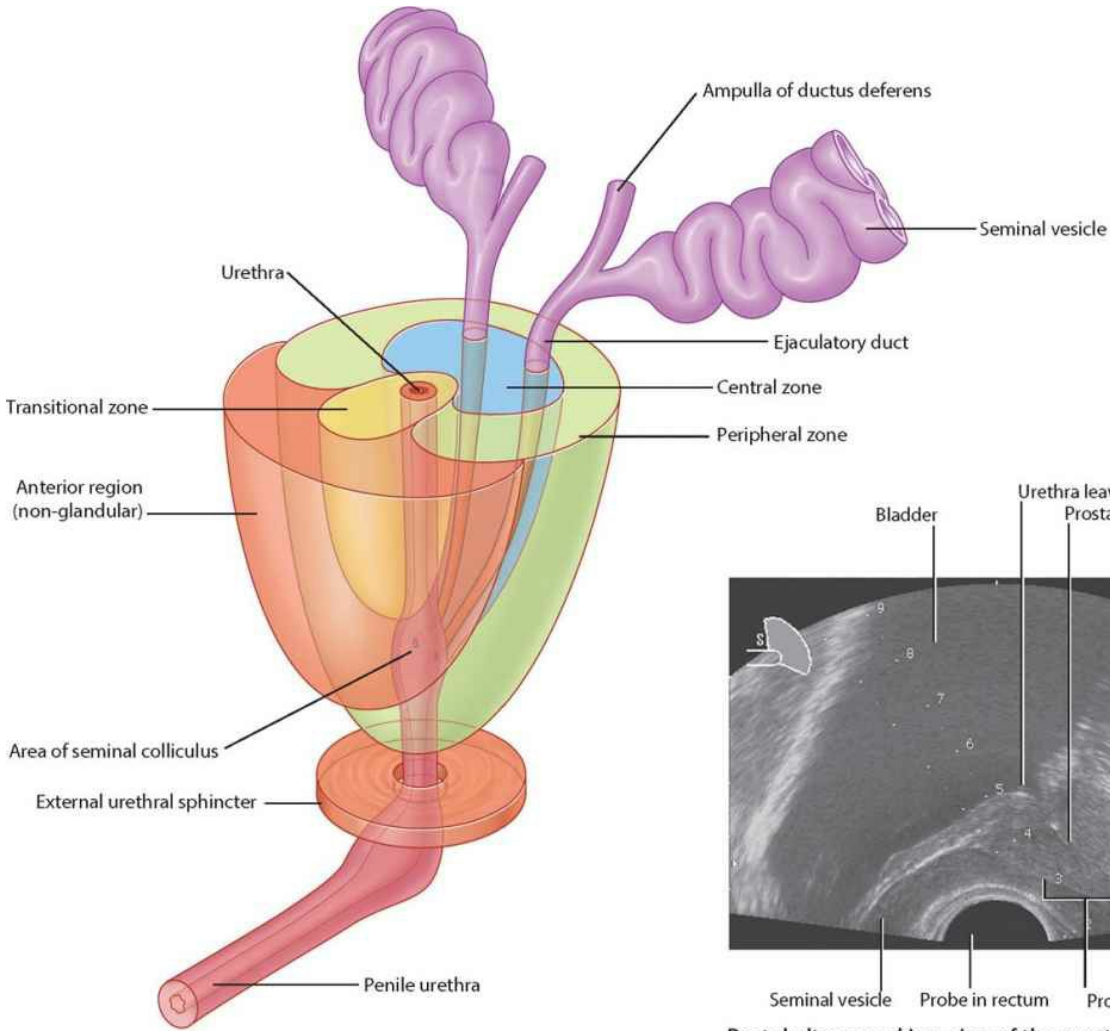
**Coronal section through bladder and prostate (anterior view)**



**Appearance and positioning of bladder and prostate in relation to other structures in the male pelvis and perineum.**  
T2-weighted MR image in coronal plane

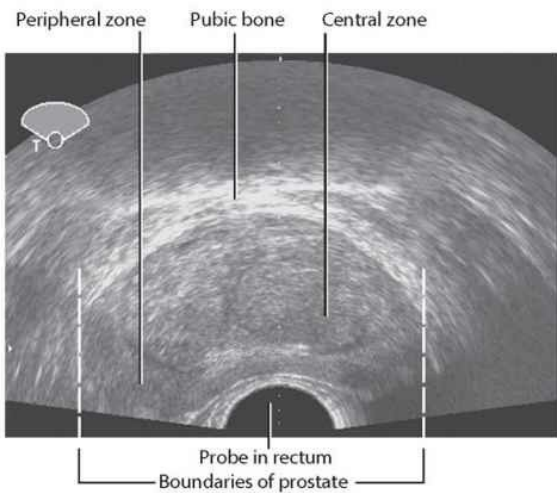


**Appearance and positioning of ductus deferens, and seminal vesicles in relation to other structures in the male pelvis and perineum.**  
T2-weighted MR image in coronal plane

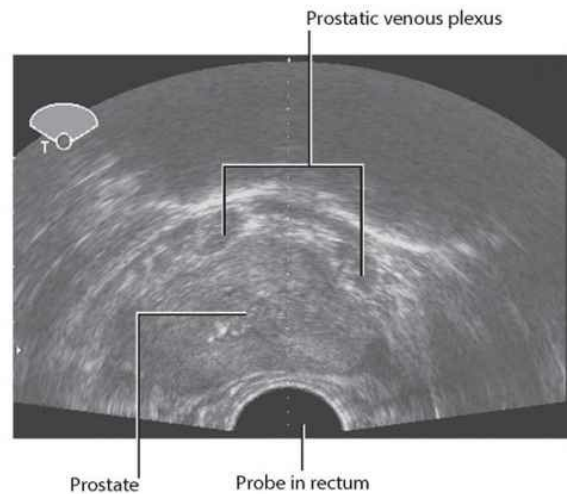


Rectal ultrasound imaging of the prostate, bladder, and seminal vesicle. Sagittal view also showing the urethra

**Zonal anatomy of the prostate gland.**  
**Most carcinomas originate in the peripheral zone.**  
**Benign prostatic hypertrophy (BPH) affects mainly the transitional zone**

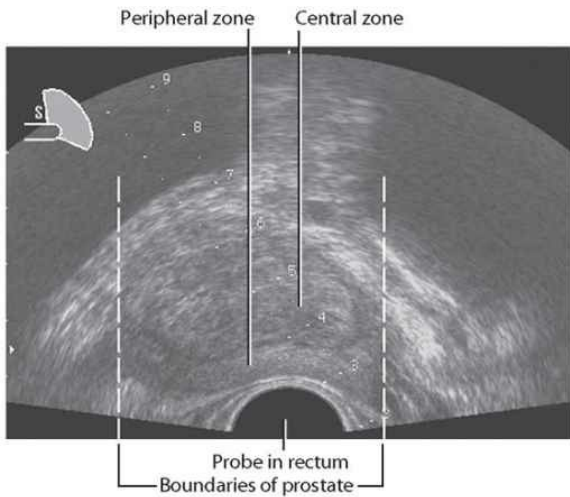


Rectal ultrasound imaging of the prostate. Axial view showing the central and peripheral zones

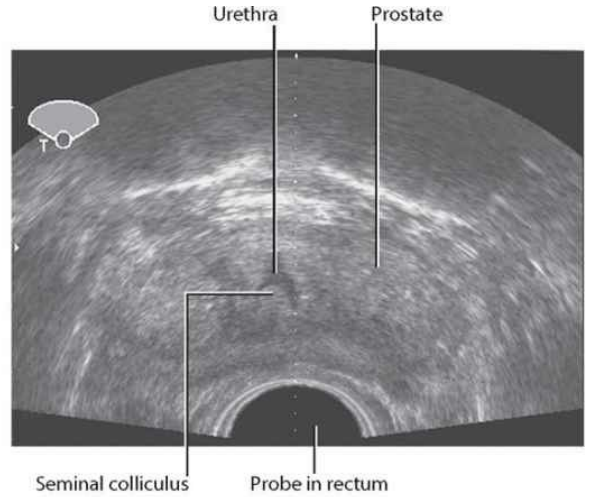


Rectal ultrasound imaging of the prostate. Axial view showing the surrounding plexus of veins

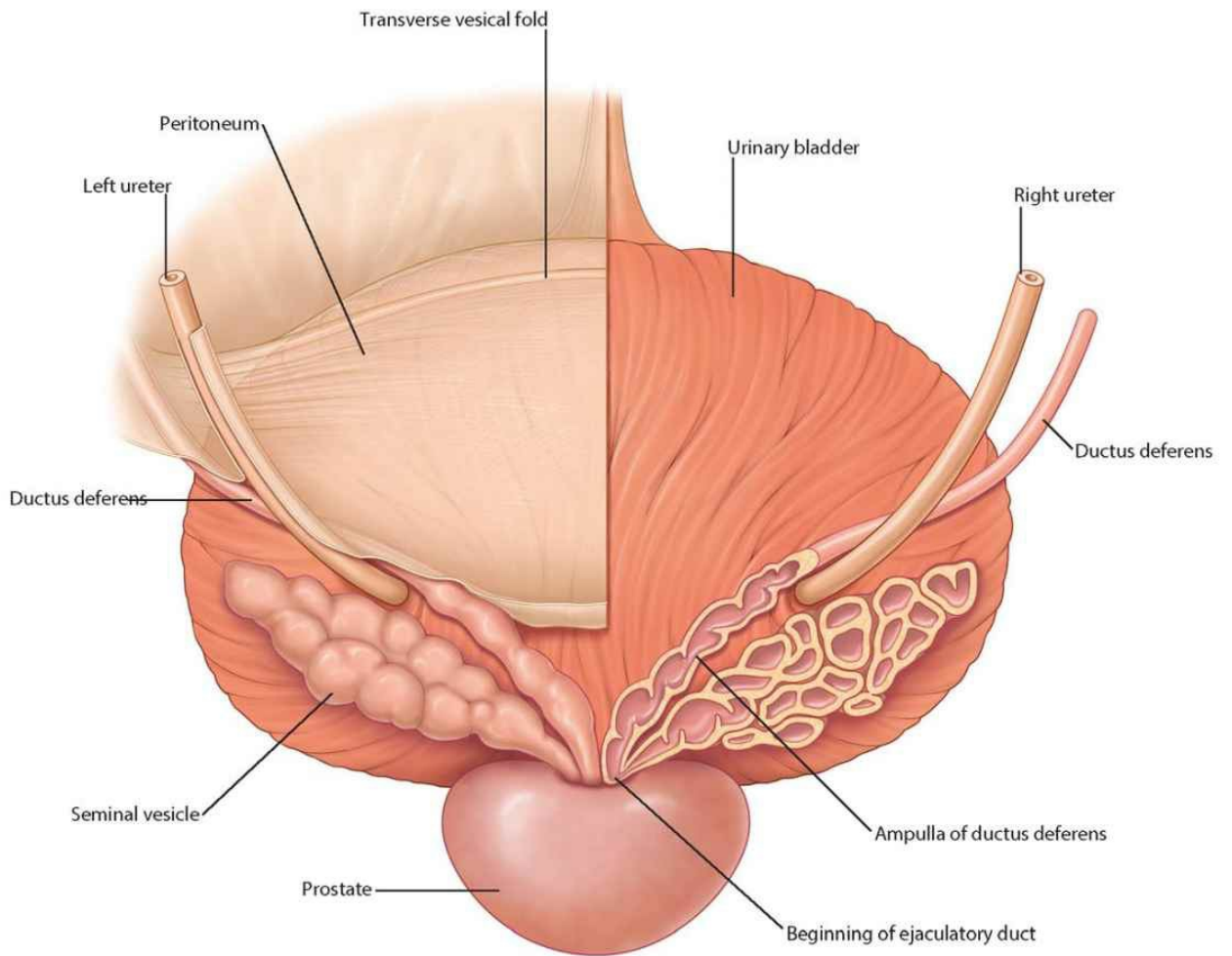
# Prostate and seminal vesicles



**Rectal ultrasound imaging of the prostate.**  
Sagittal view showing the central and peripheral zones



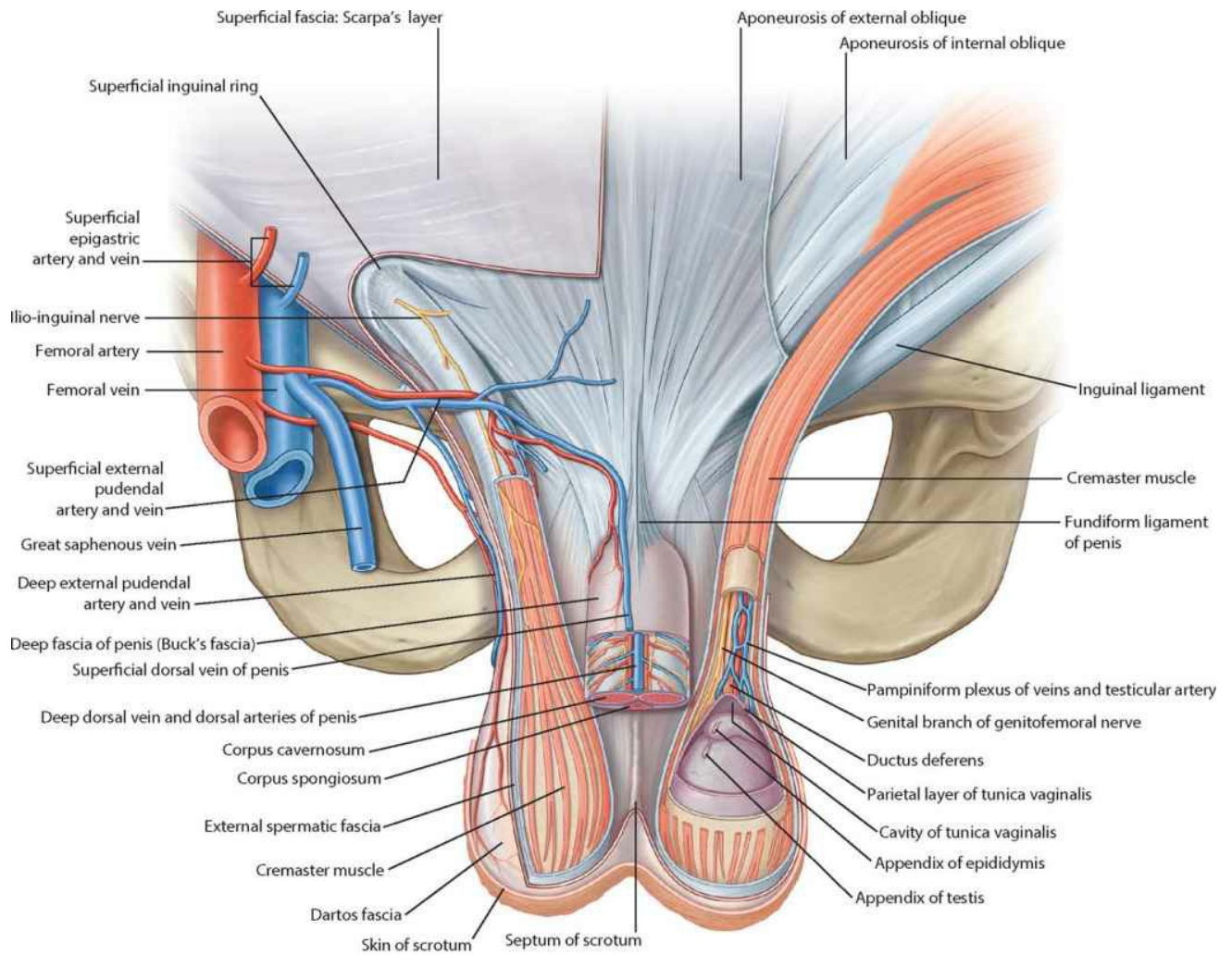
**Rectal ultrasound imaging of the prostate.**  
Axial view showing the urethra and seminal colliculus



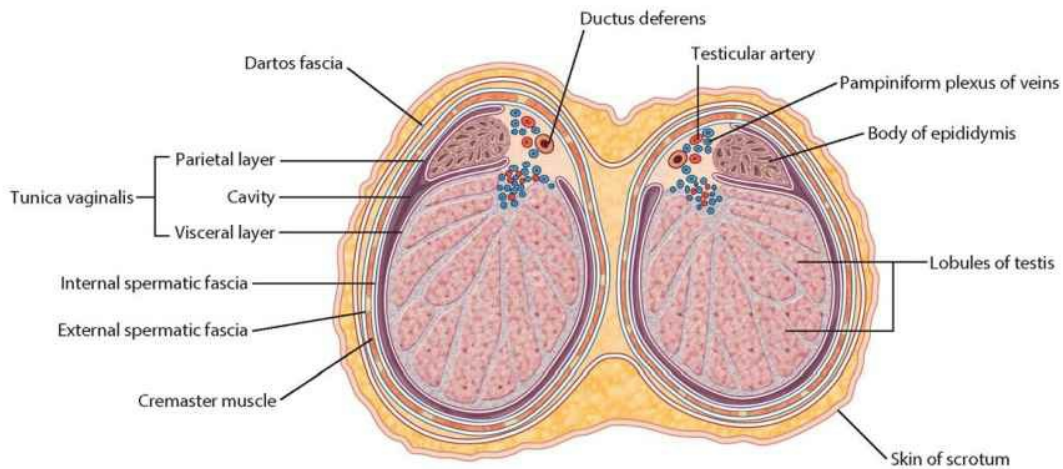
**Bladder and prostate (posterior view)**

# Scrotum



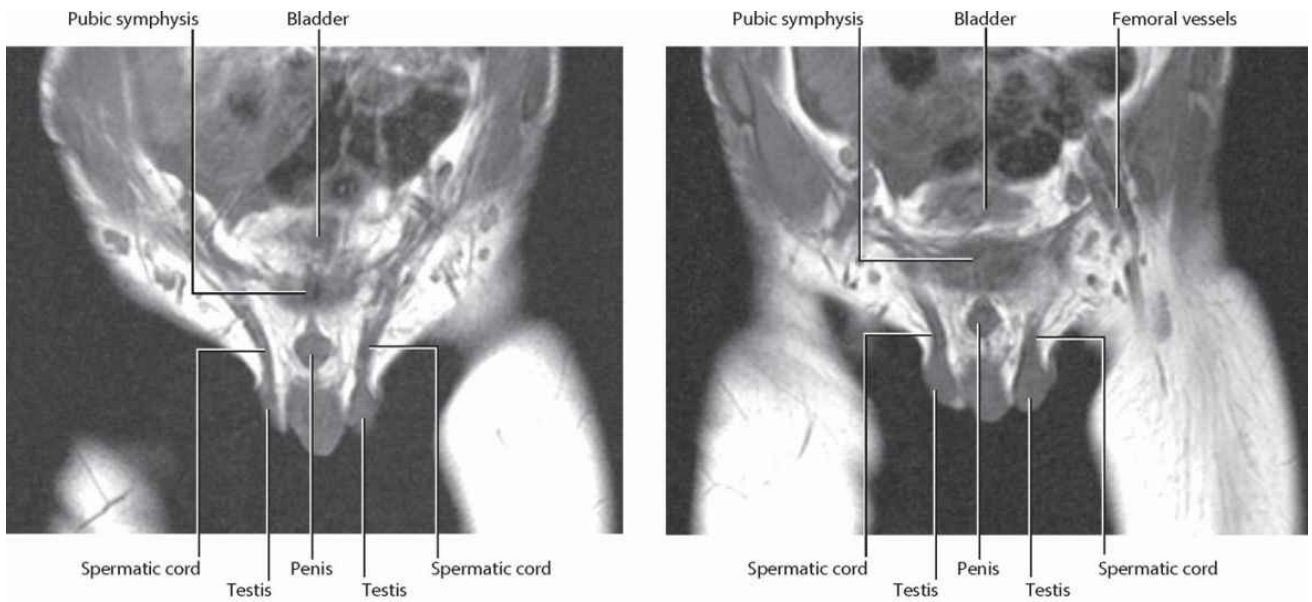


**Contents of the scrotum (anterior view)**

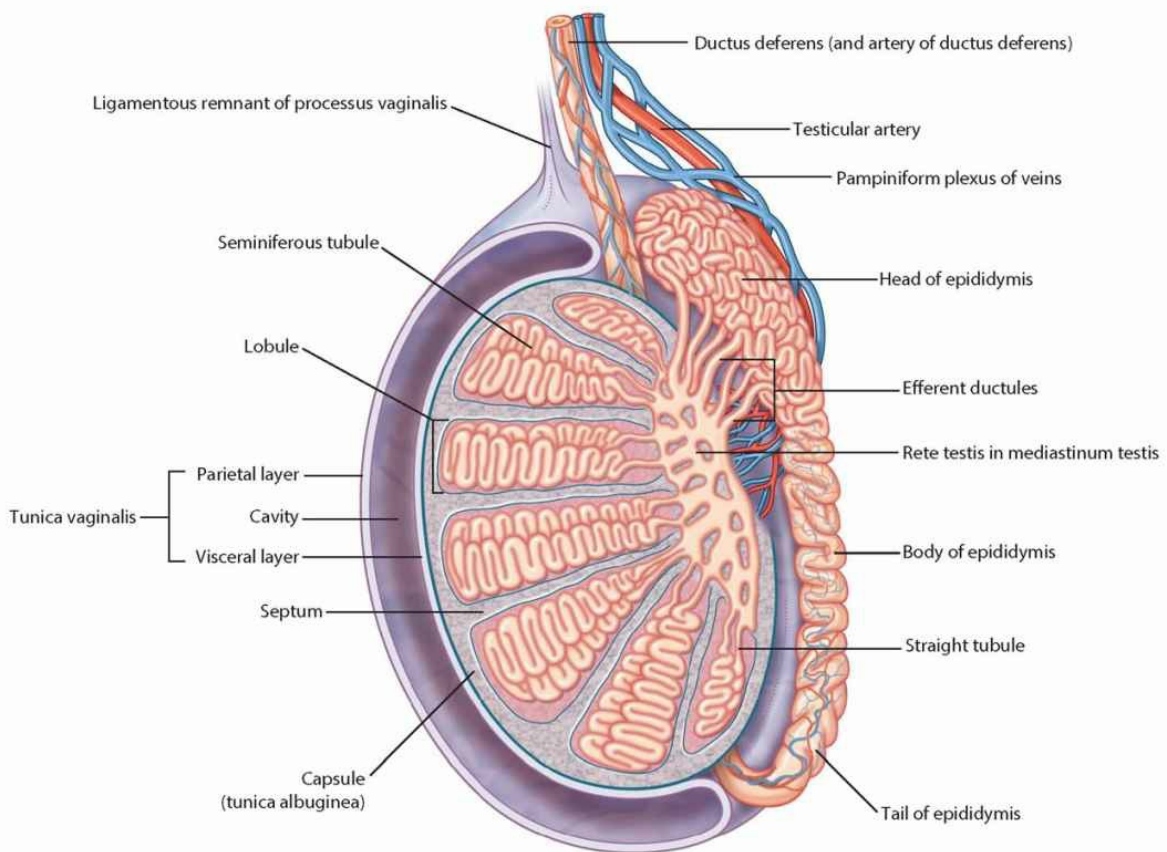


**Transverse section through the scrotum and testes**

# Testes

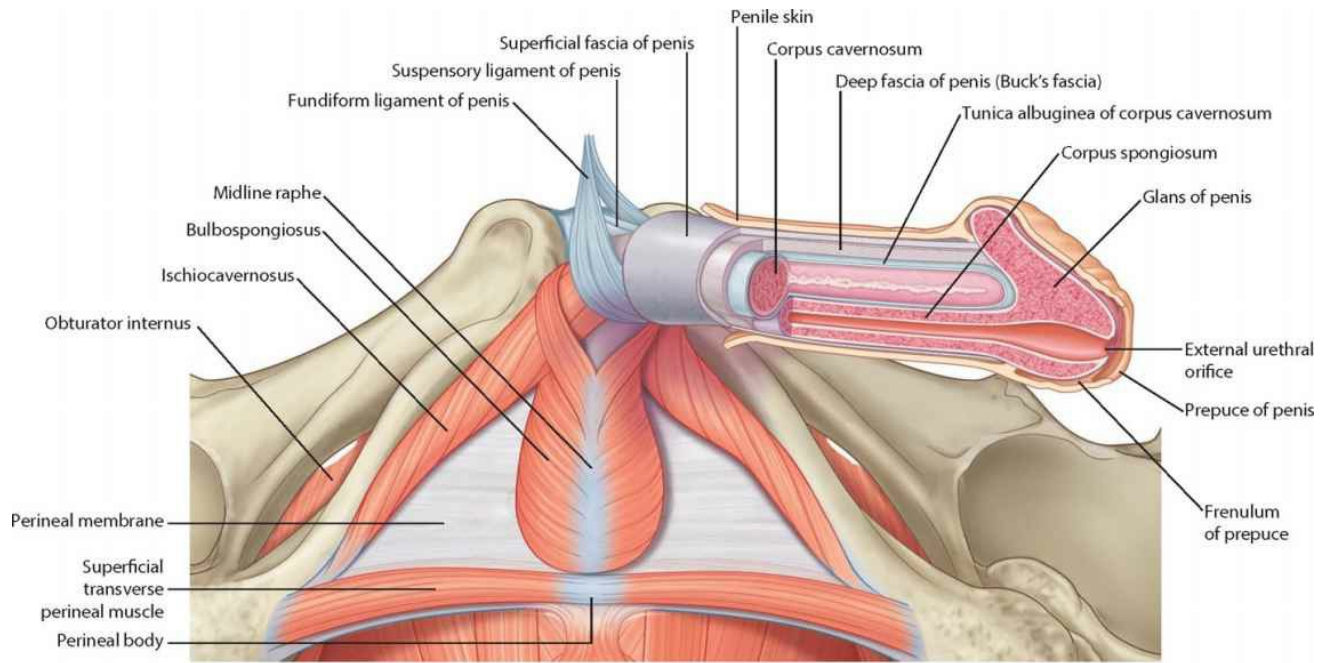


**Spermatic cord appearance and positioning in a young male.**  
T1-weighted MR images in coronal plane

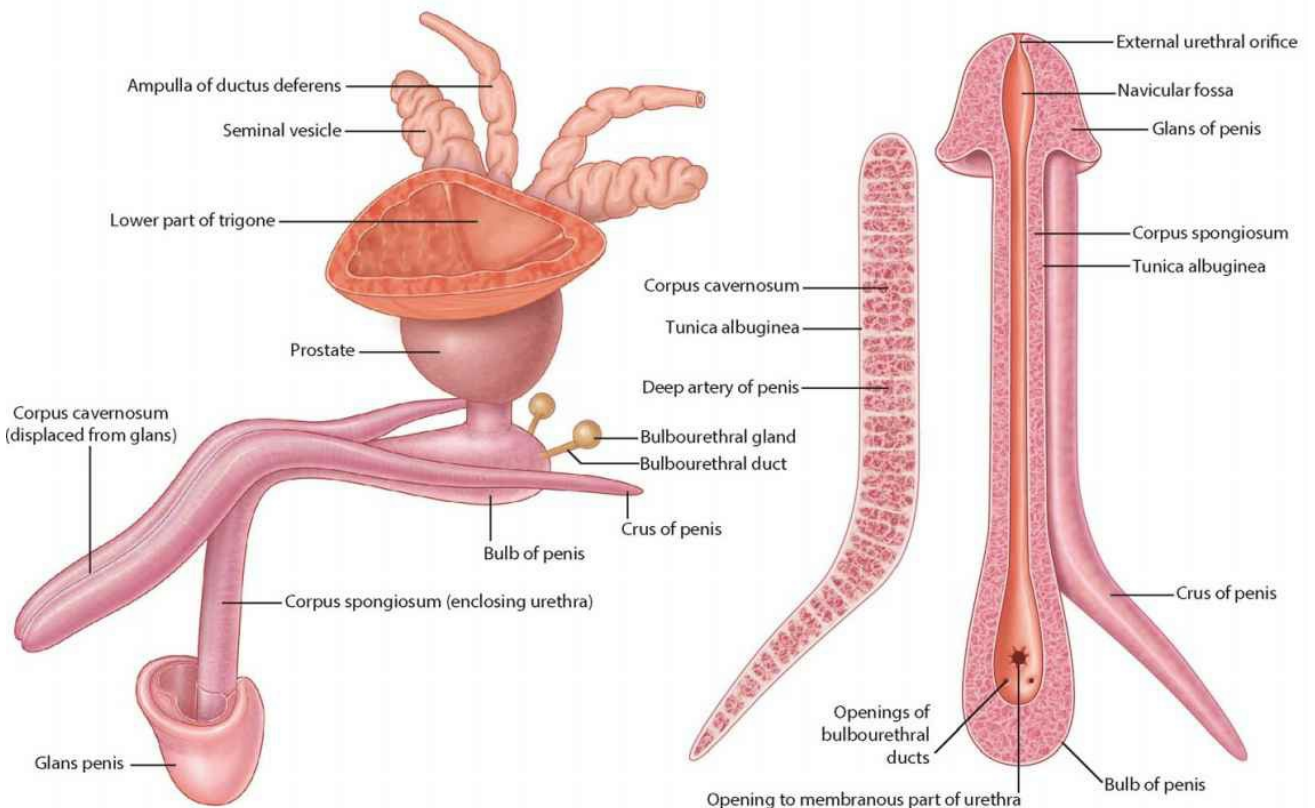


**Testis and surrounding structures**

# Penis



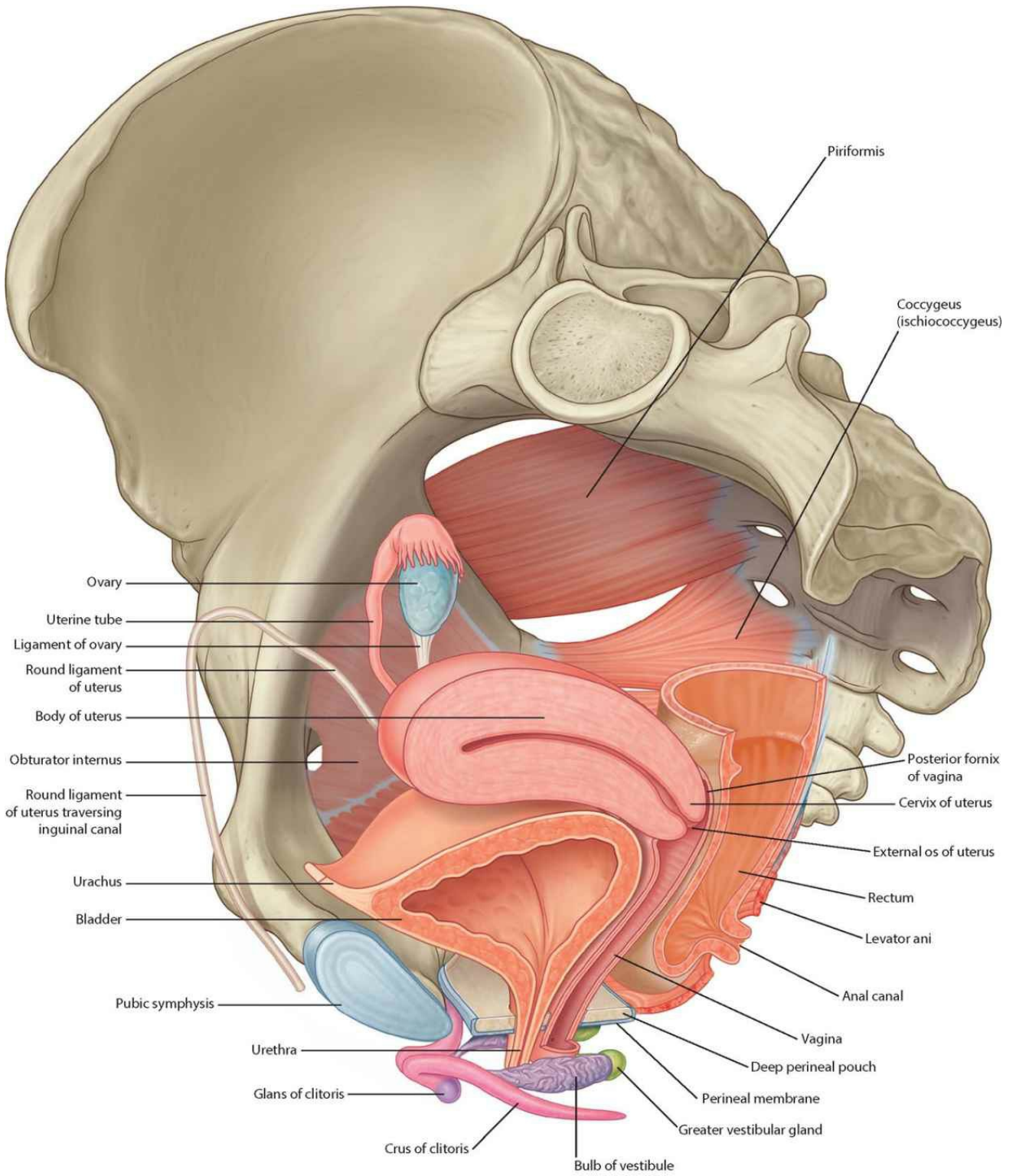
Structure of the penis



Structure of the penis

Roof of spongy urethra (inferior view)

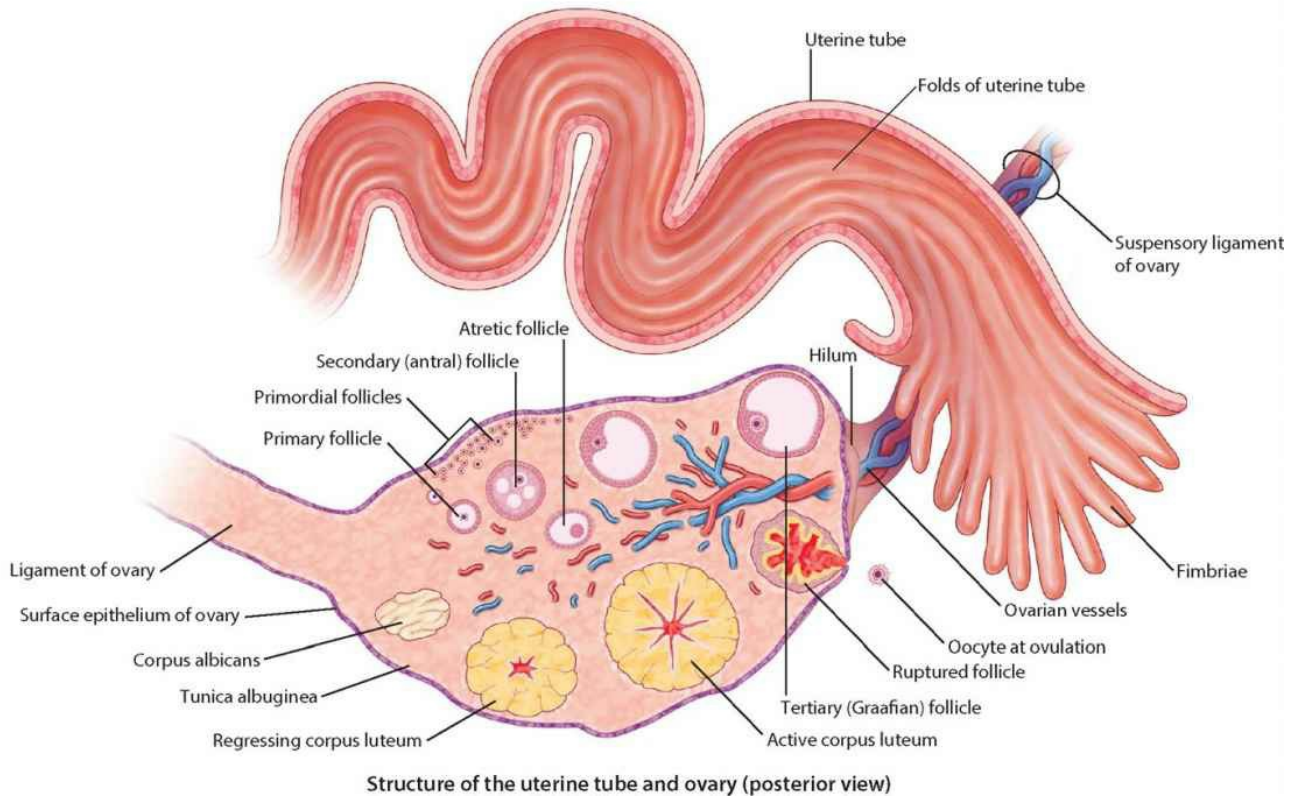
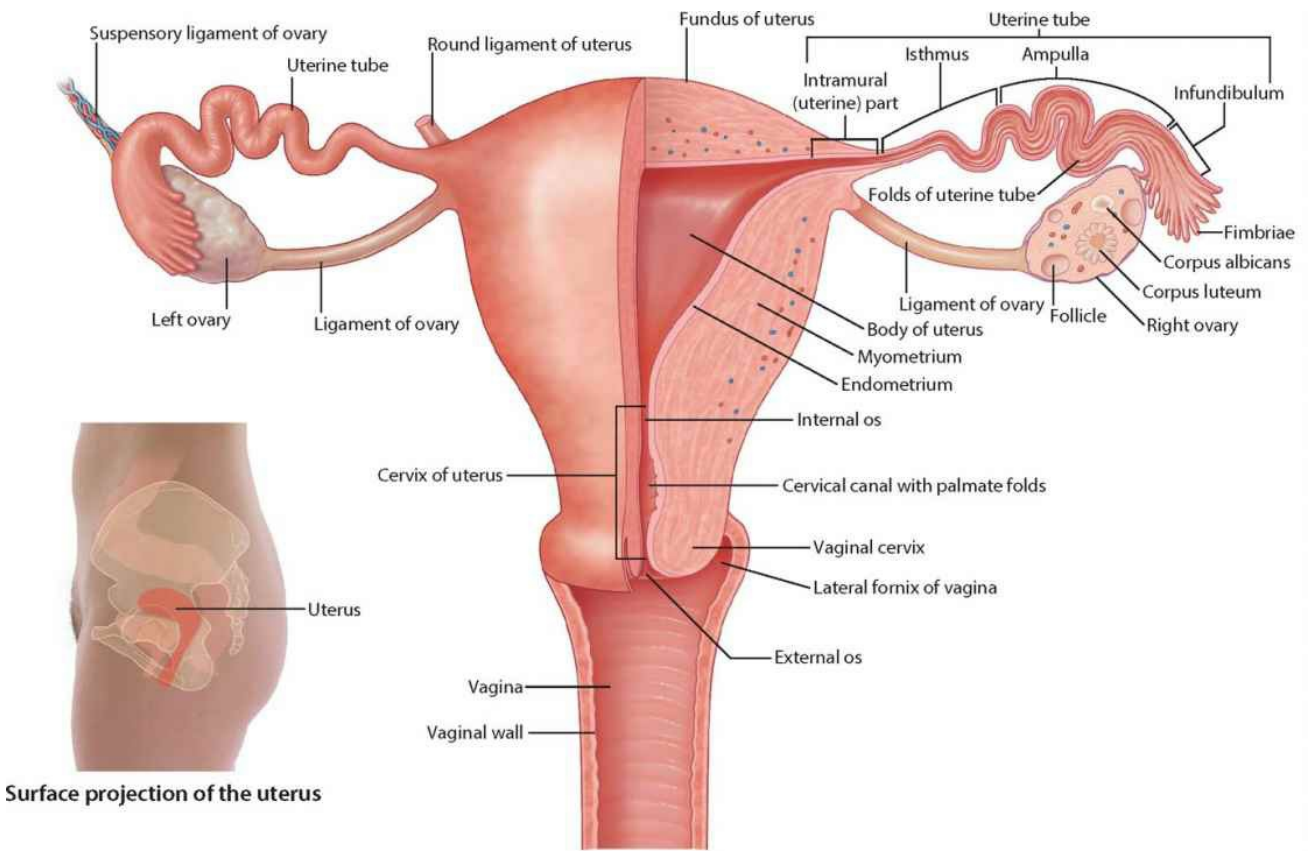
# Reproductive system in women



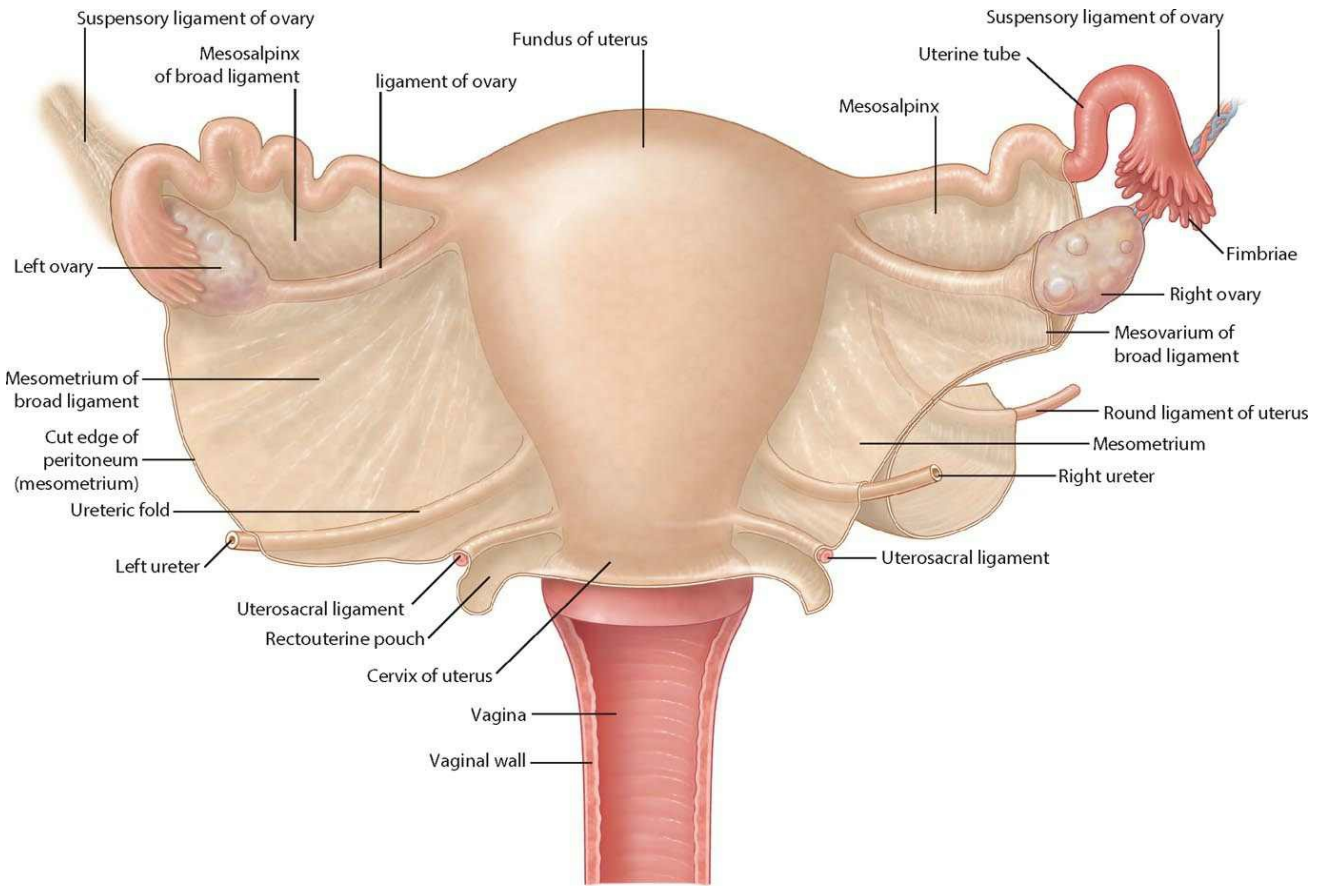
Reproductive system in women (oblique sagittal view)

## Uterus and ovaries

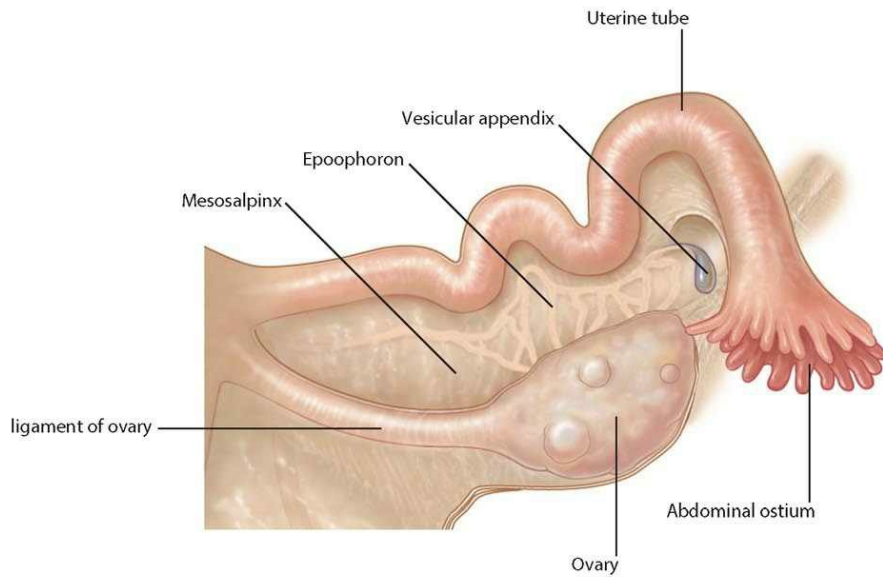




# Uterus

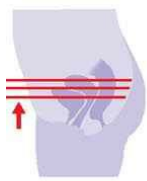

Uterus and broad ligament (posterior view)

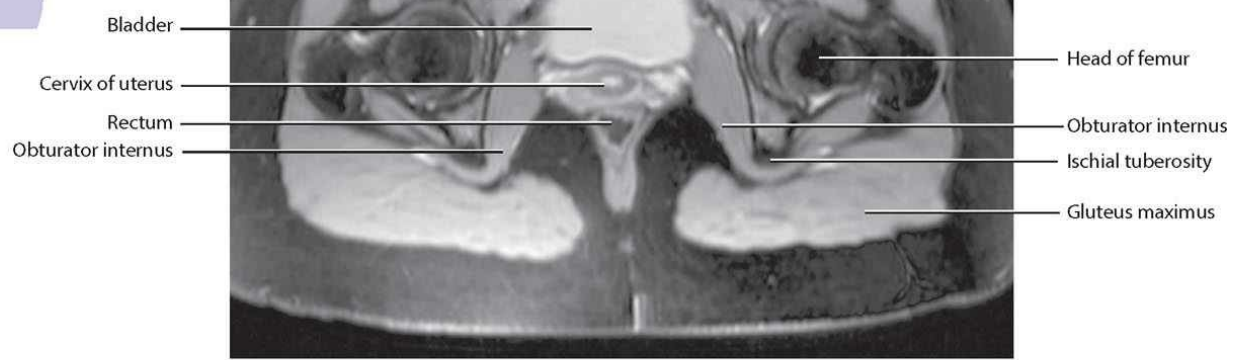


Uterine tube and ovary (posterior view)

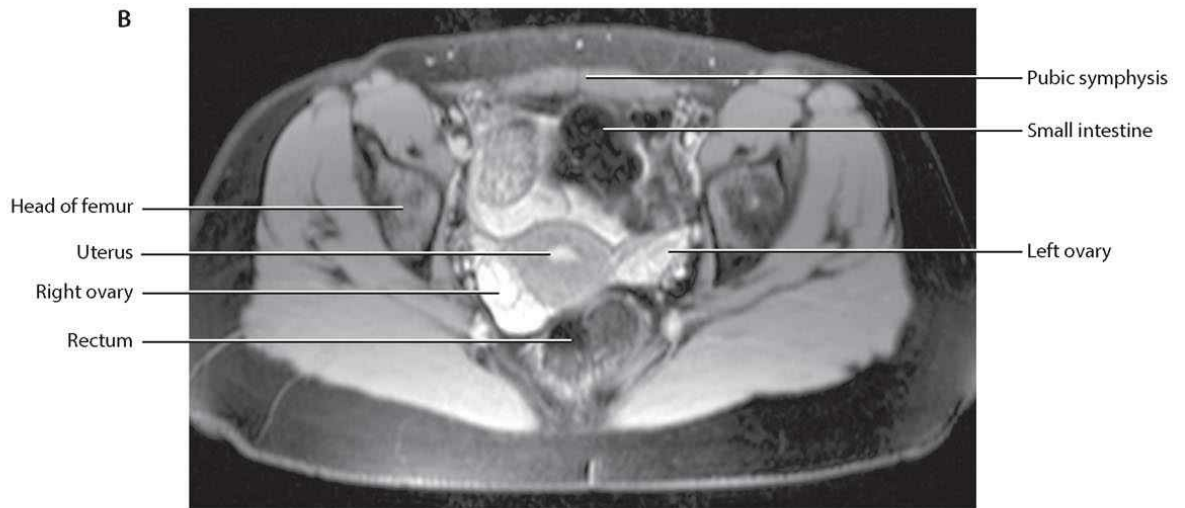
# Uterus: imaging



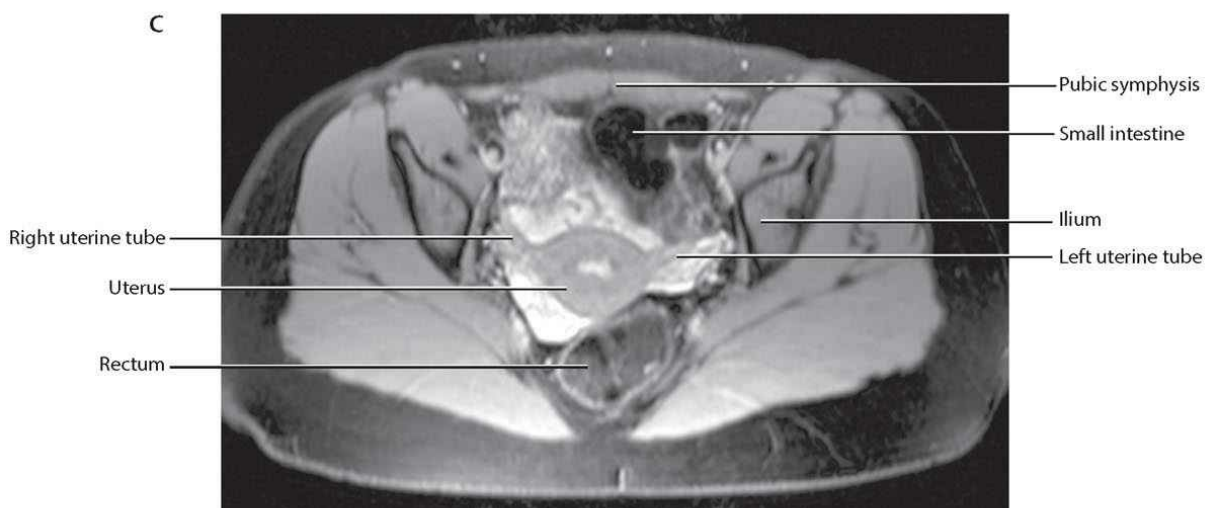
A



B



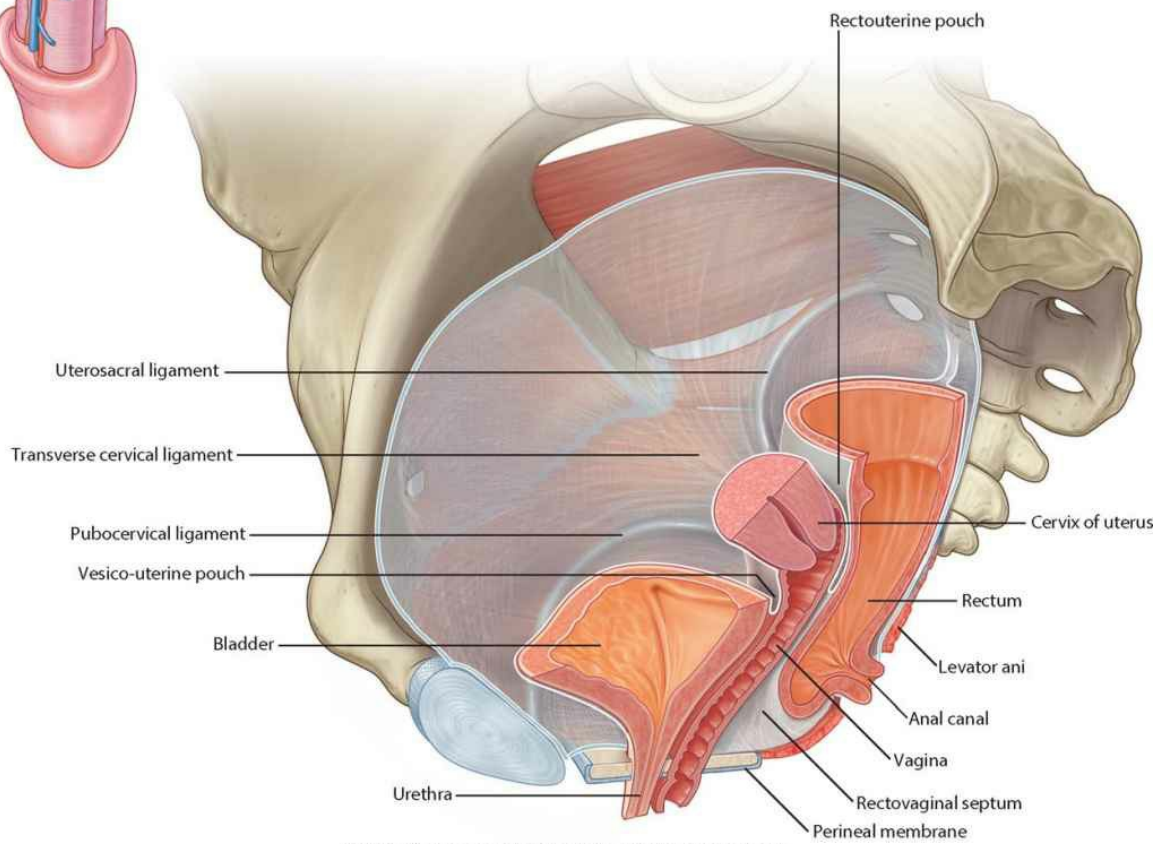
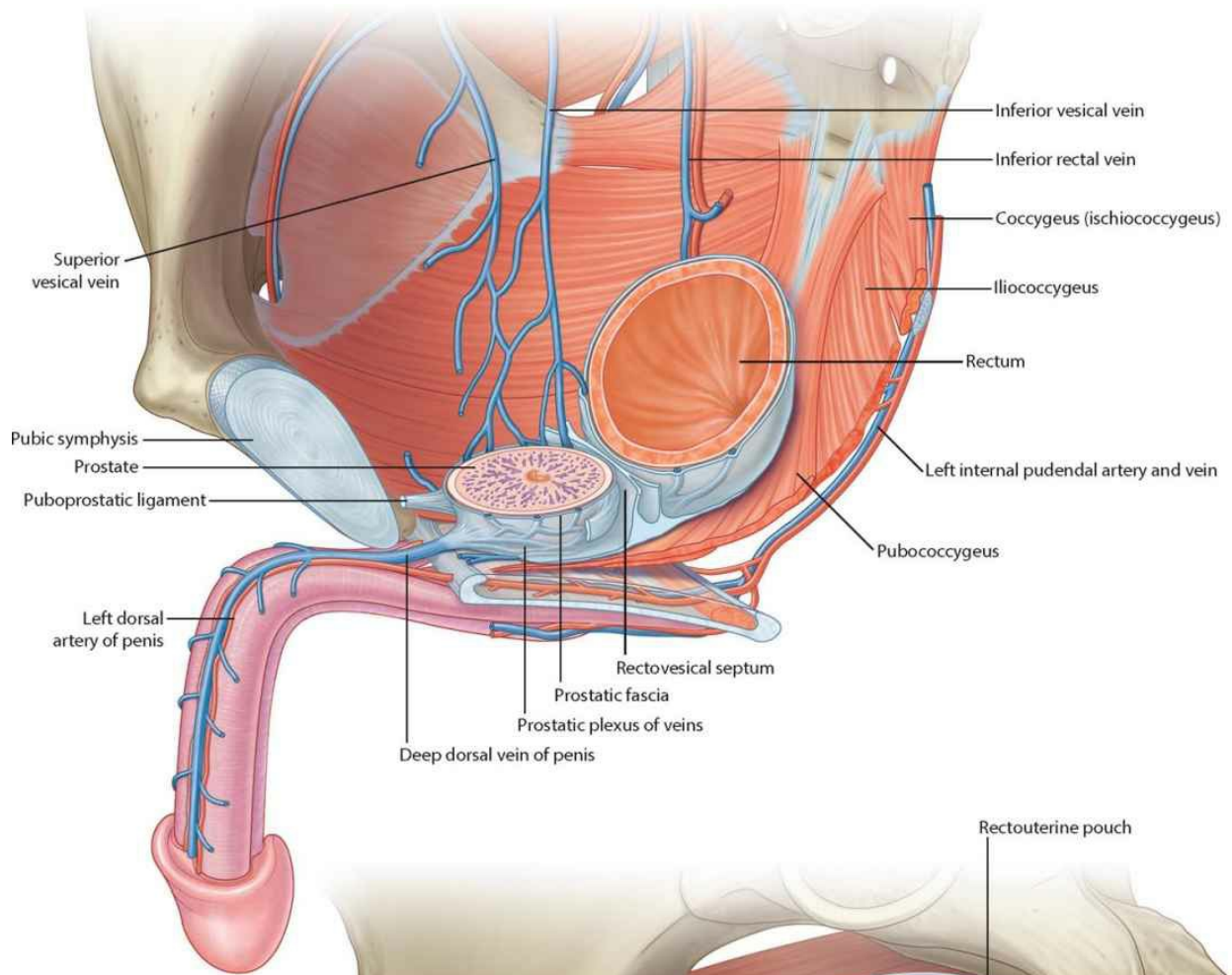
C



**Appearance of cervix of uterus, uterus, ovaries, and uterine tubes in relation to other pelvic structures.**  
T2-weighted MR images in axial plane



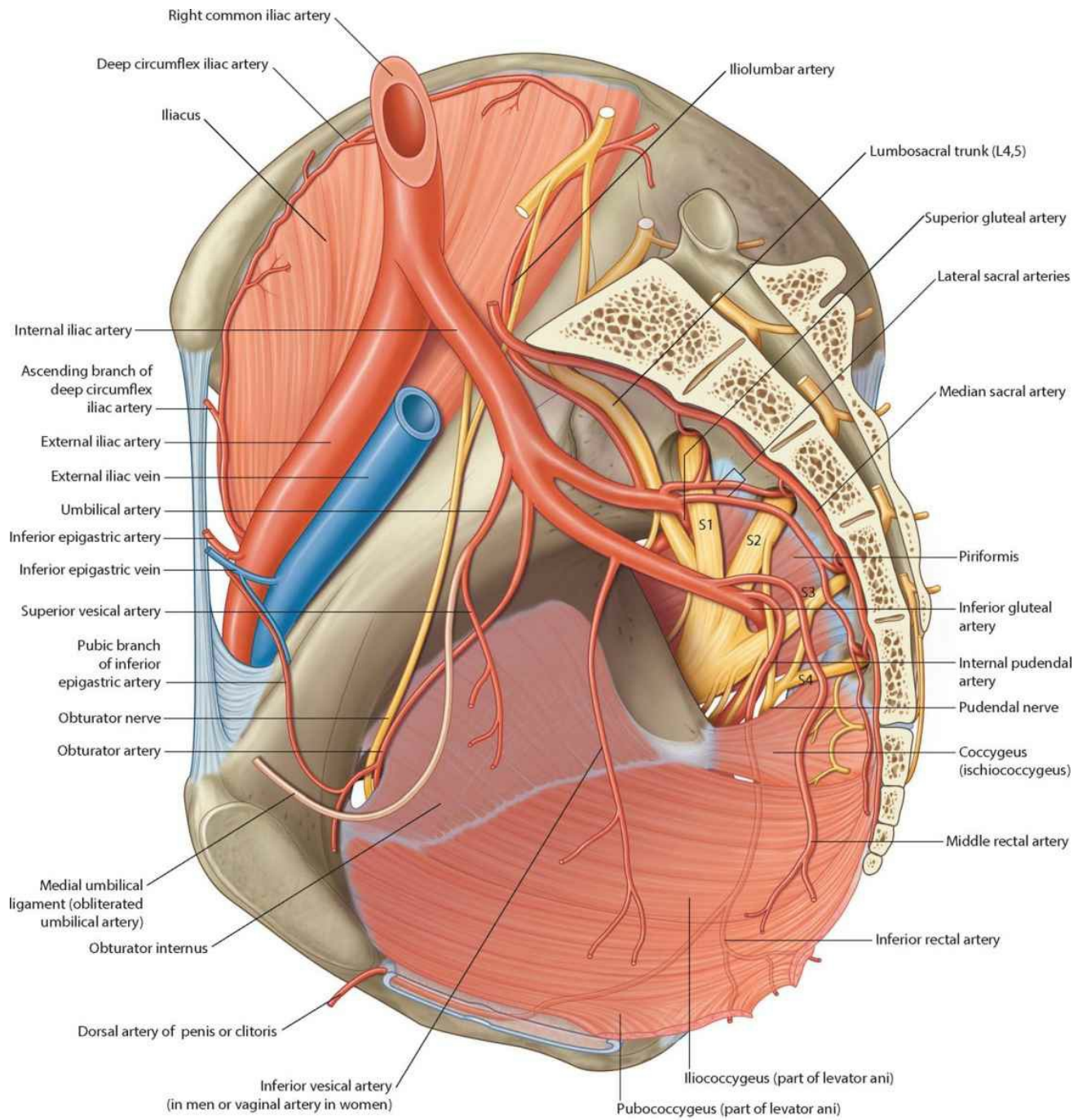
# Pelvic fascia



**Pelvic fascia and related structures in women**

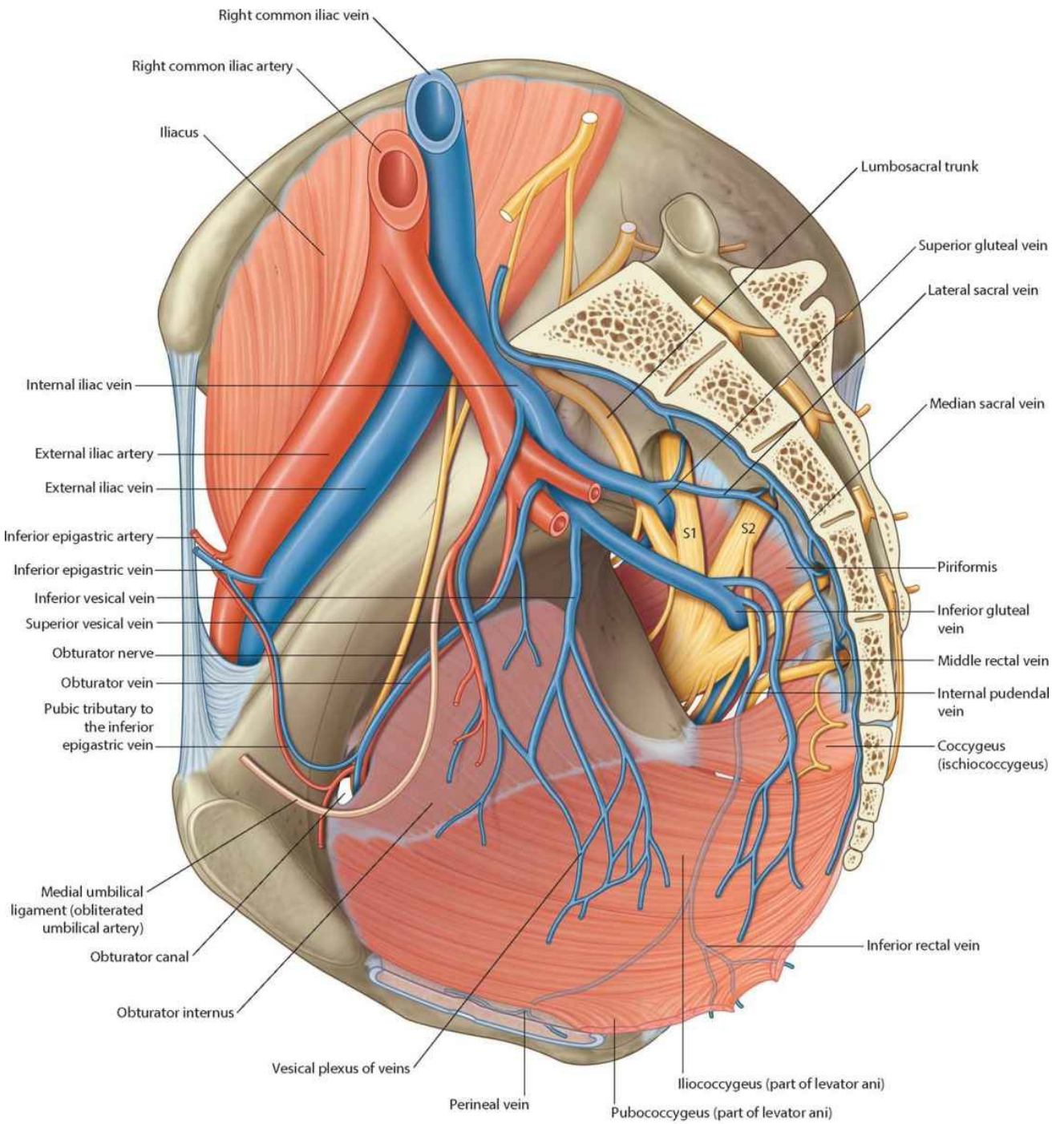


## Arterial supply of pelvis



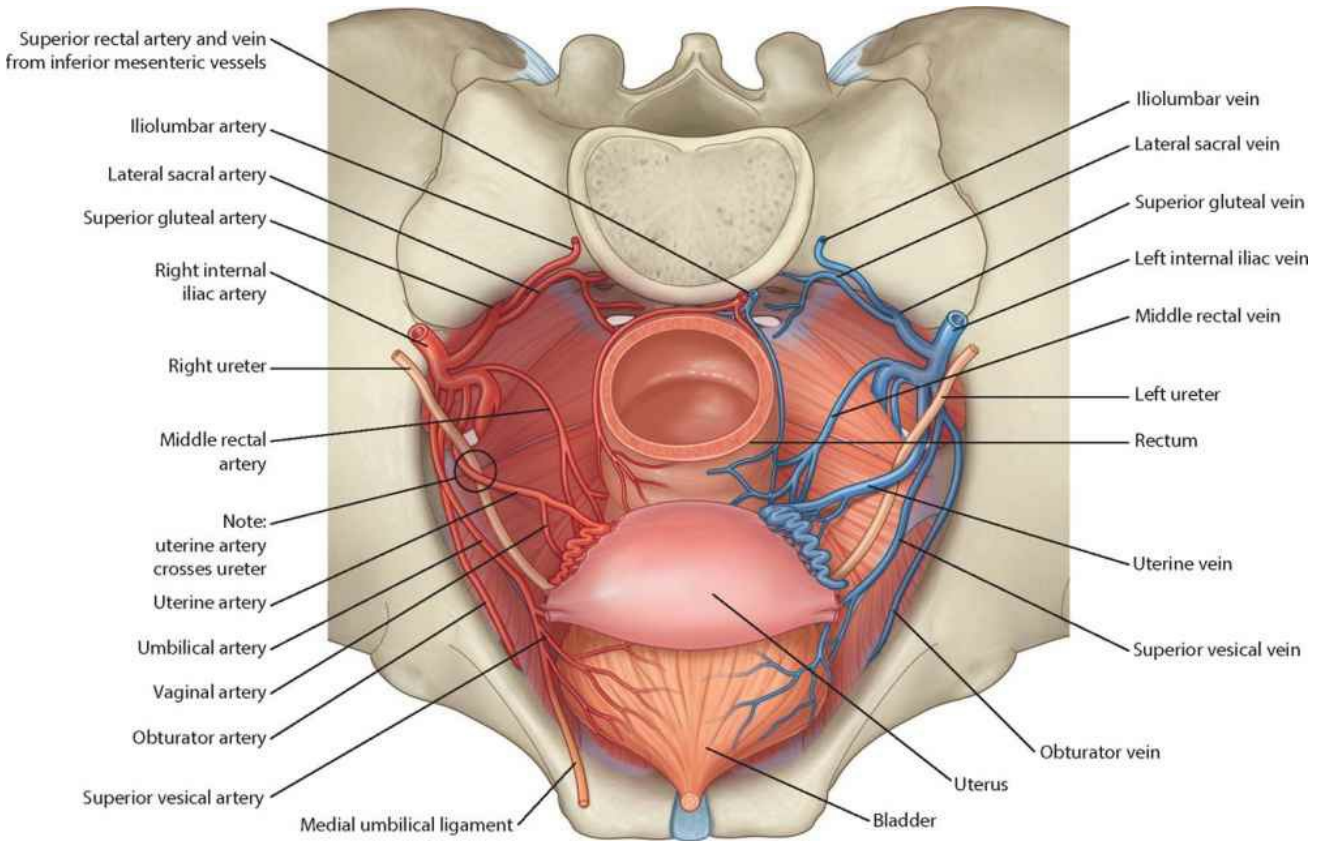
**Arterial supply to the pelvis  
(right side sagittal view)**

# **Venous drainage of pelvis**

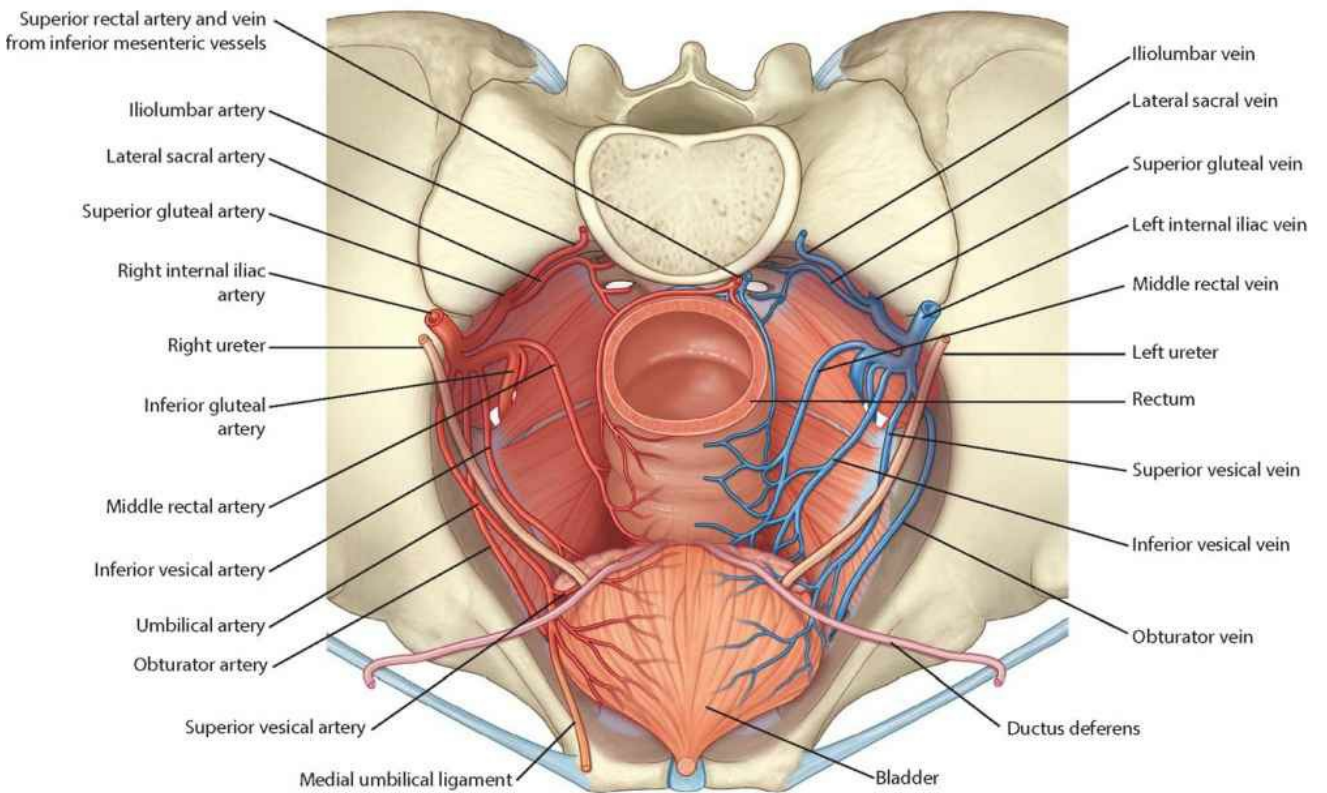


**Veins of the pelvis  
(right side sagittal view)**

# Vasculature of the pelvic viscera

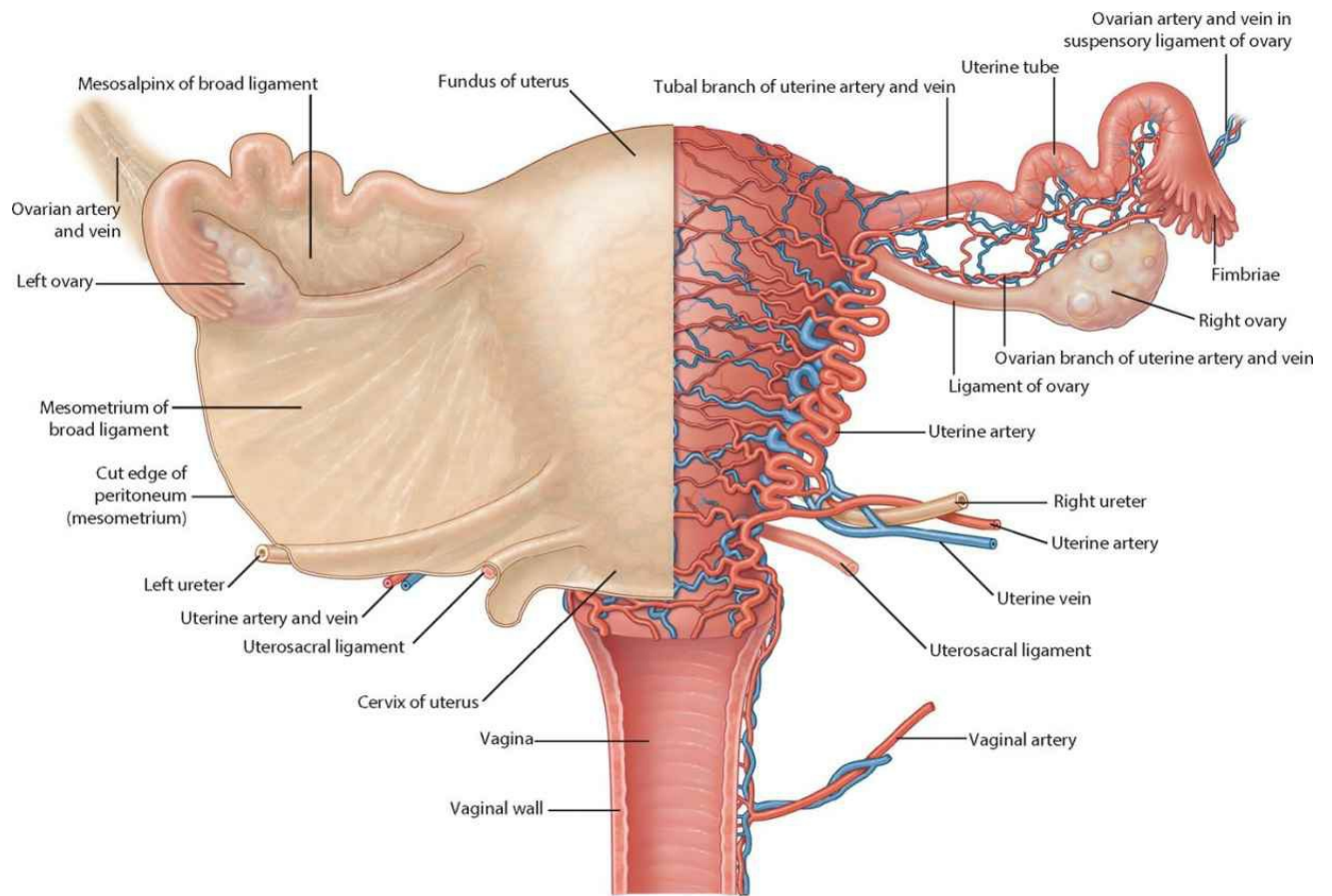


**Vasculature of the pelvic viscera in women (superior view)**

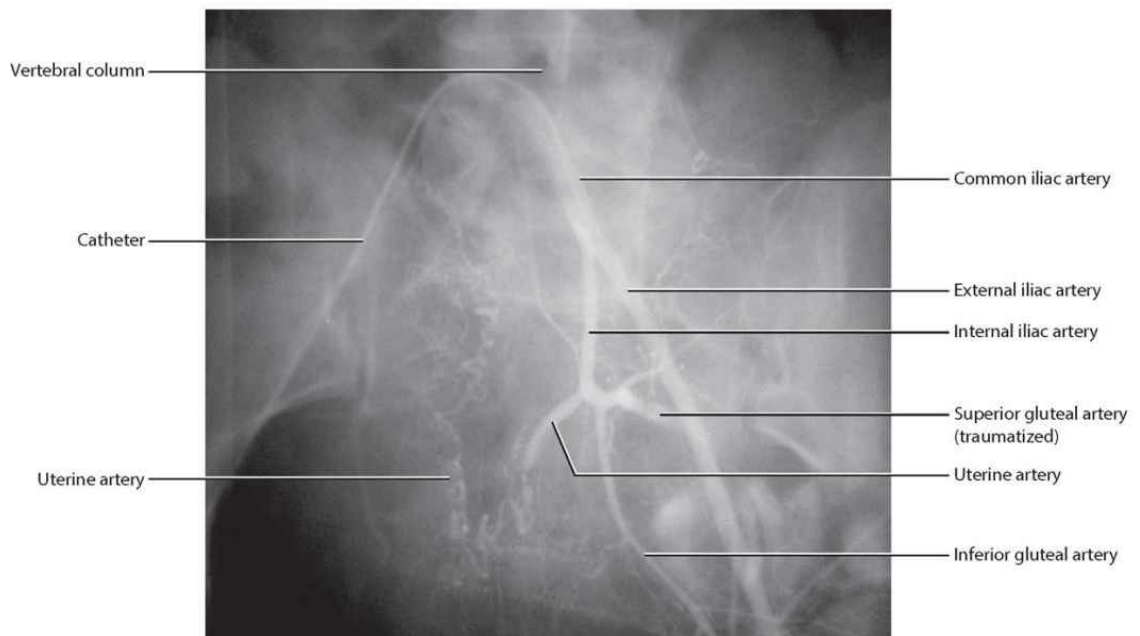


**Vasculature of the pelvic viscera in men (superior view)**

# Vasculature of uterus



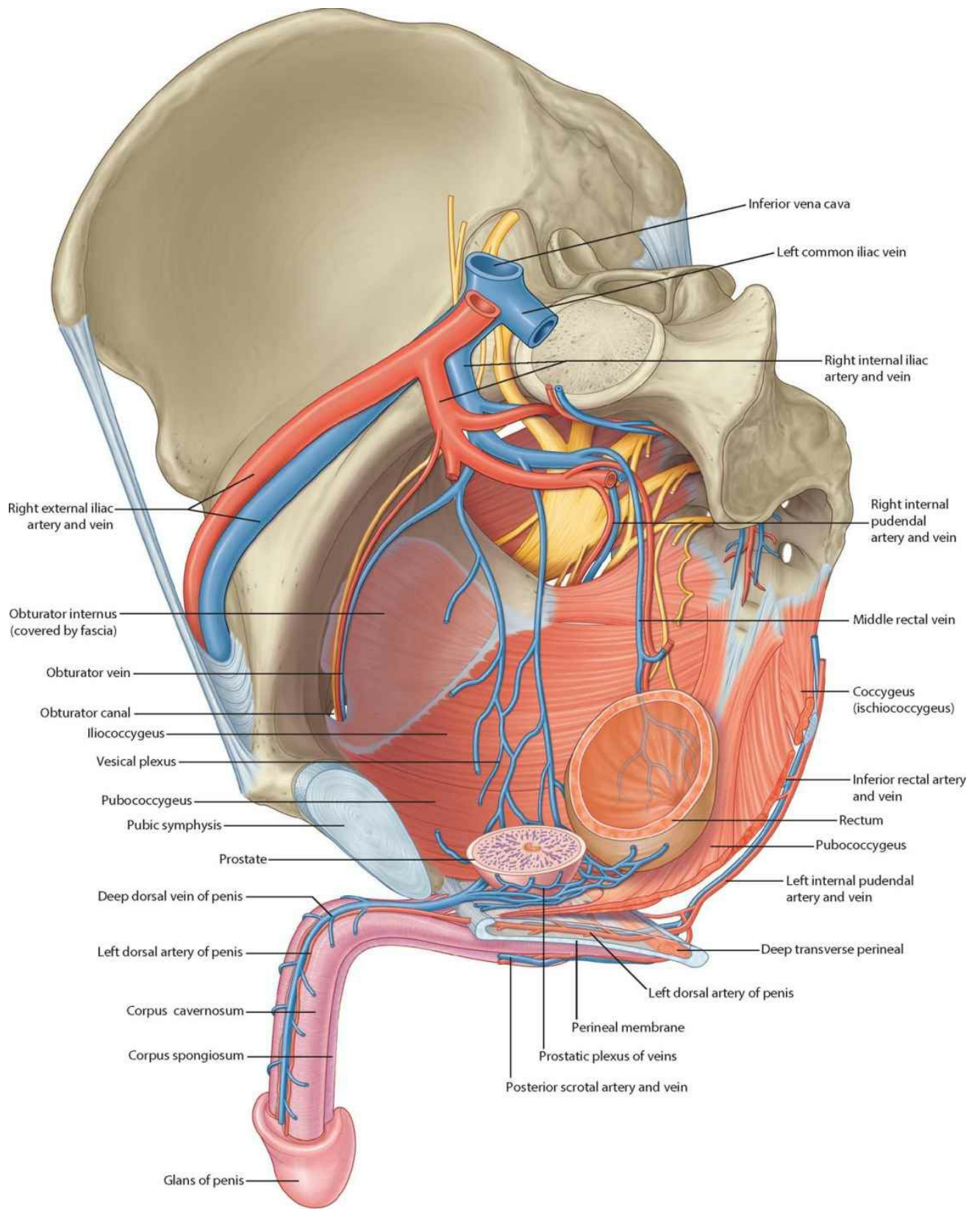
**Vascular supply to uterus (posterior view)**



**Vascular supply to uterus.  
Angiogram**

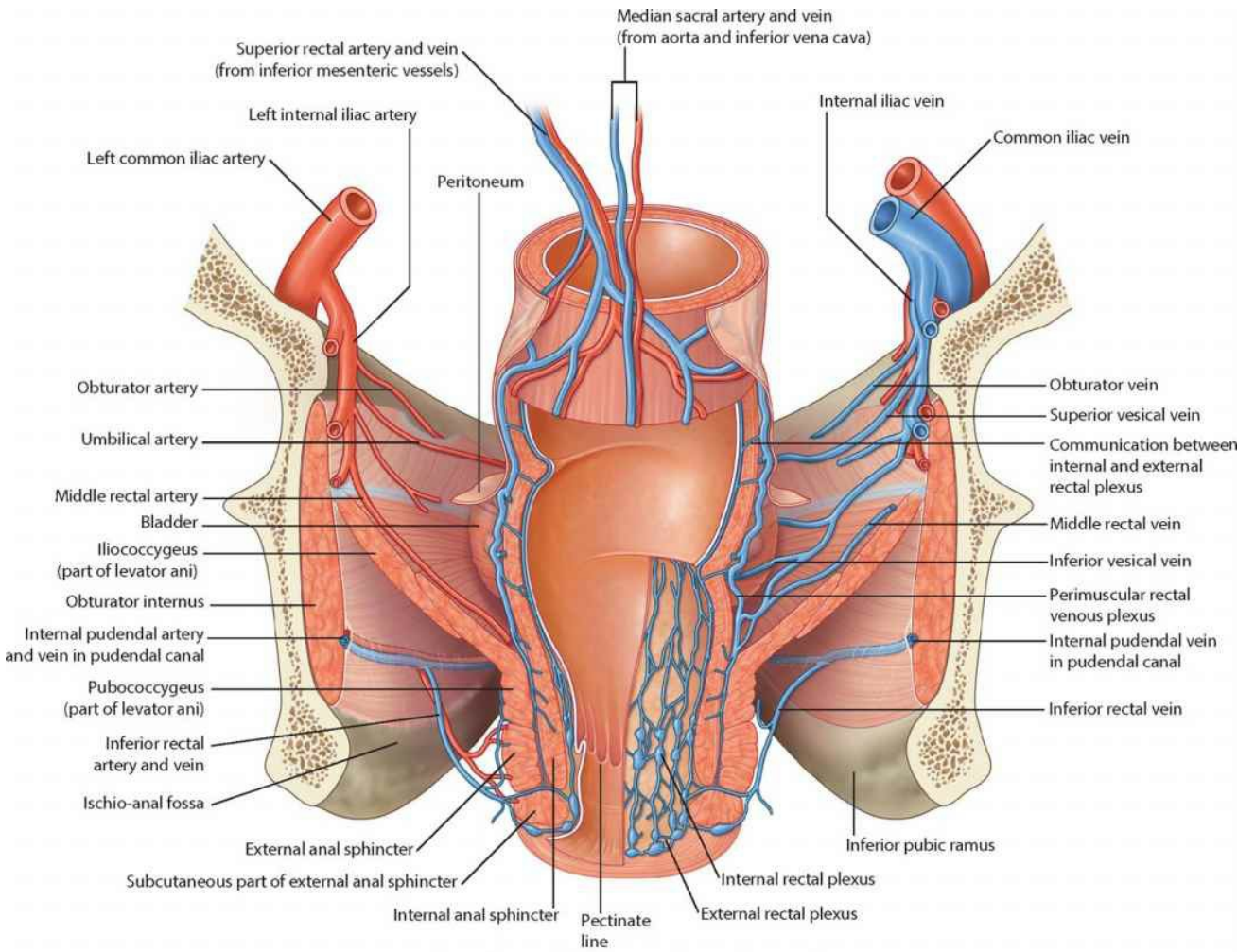


# **Venous drainage of prostate and penis**

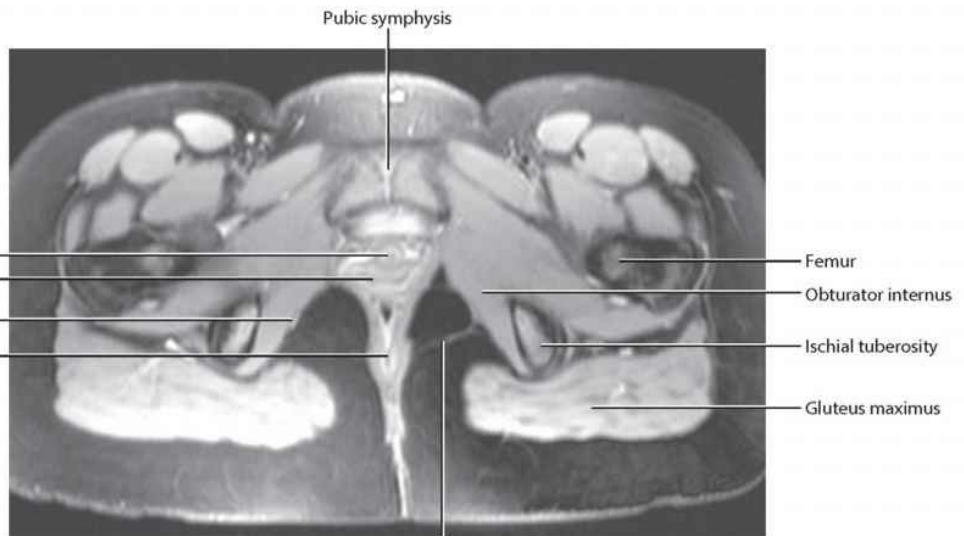
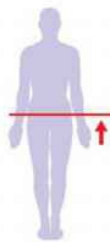


**Venous drainage of pelvic viscera in men  
 (oblique sagittal view)**

# **Venous drainage of rectum**

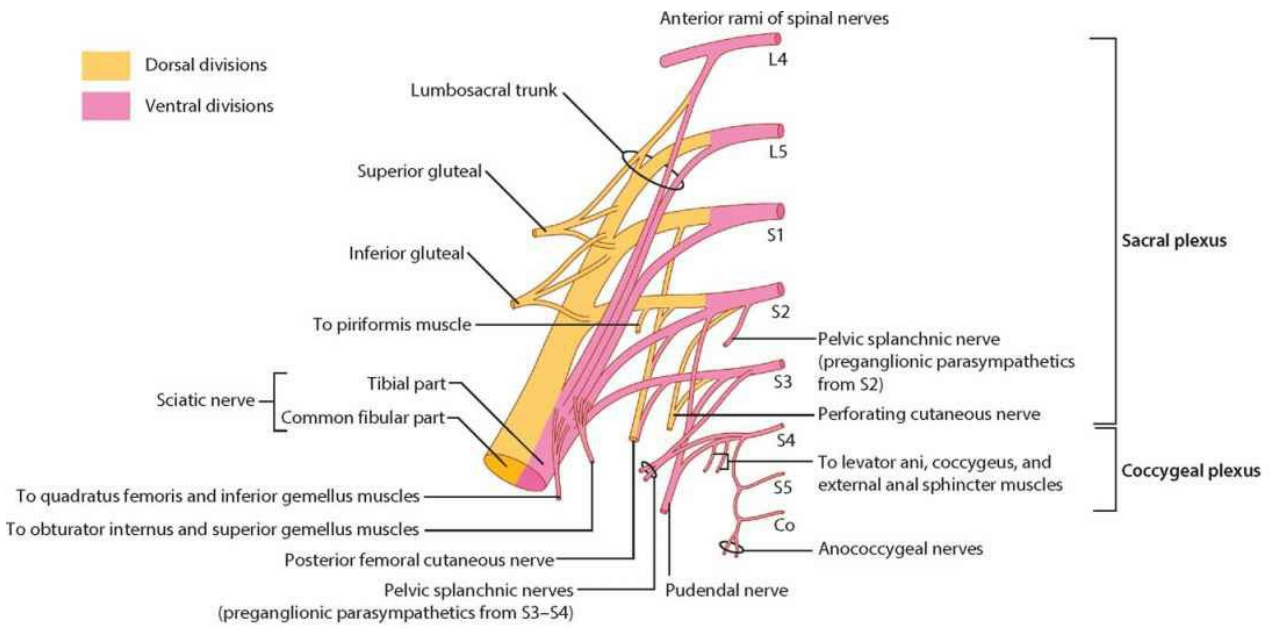


**Vasculature of the rectum (posterior view)**

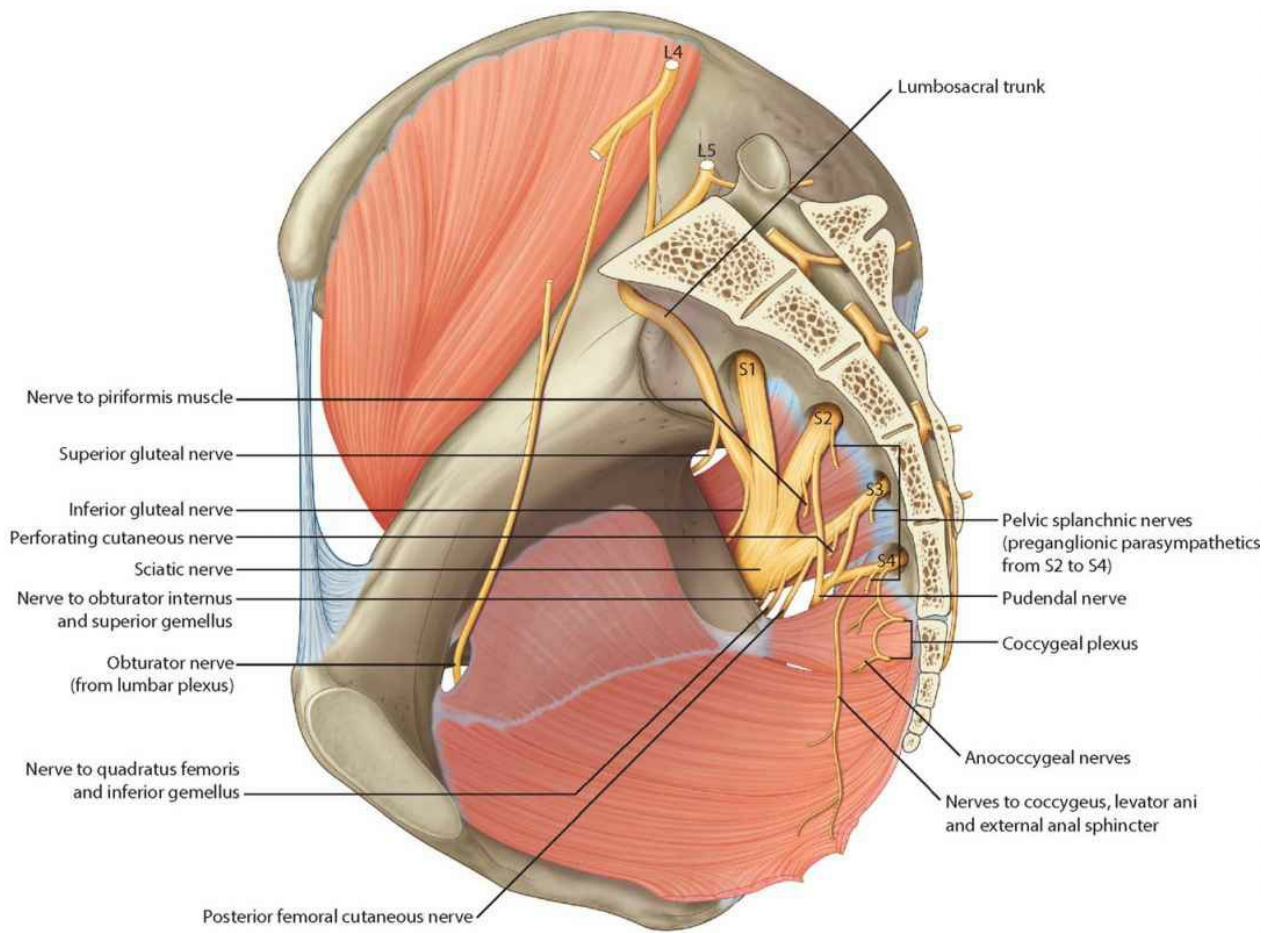


**Inferior rectal neurovascular bundle crossing the ischio-anal fossa.**  
T2-weighted MR image in axial plane

# Sacral and coccygeal nerve plexuses

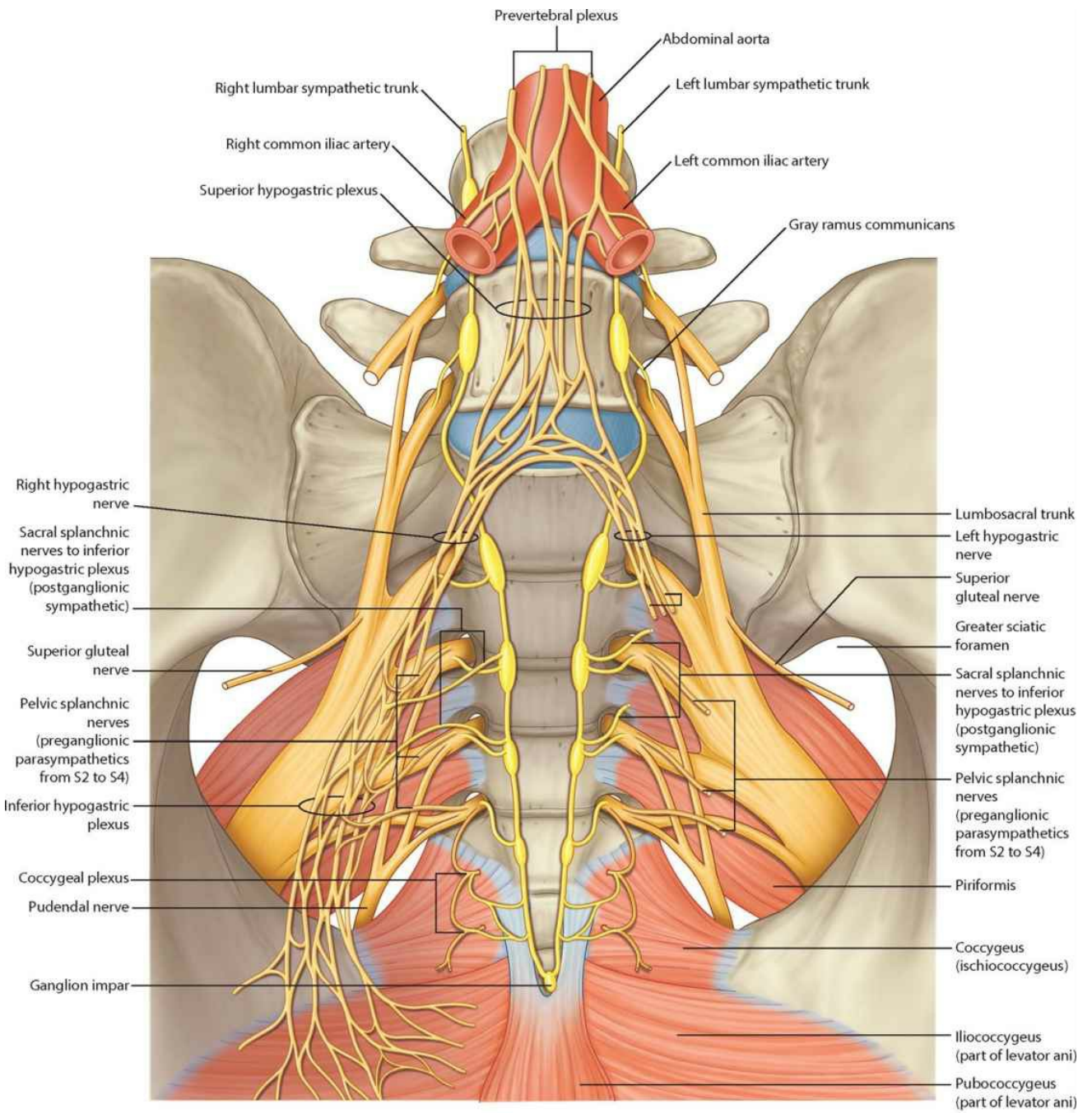


**Components and branches of the sacral and coccygeal nerve plexuses**



**Sacral and coccygeal nerve plexuses within the pelvic cavity (sagittal view)**

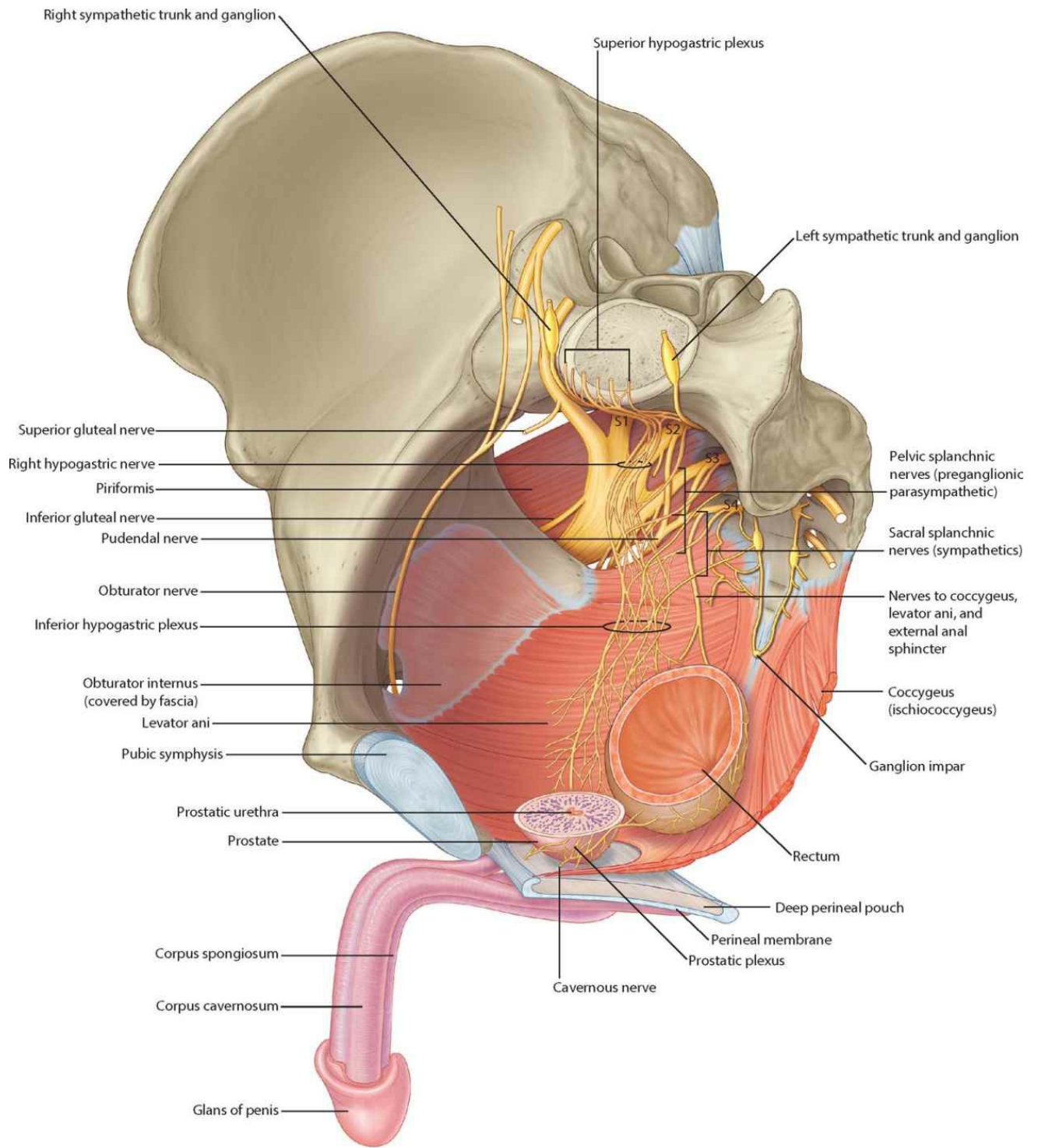
# Pelvic nerve plexus



Pelvic extensions of the prevertebral nerve plexus (anterior view)

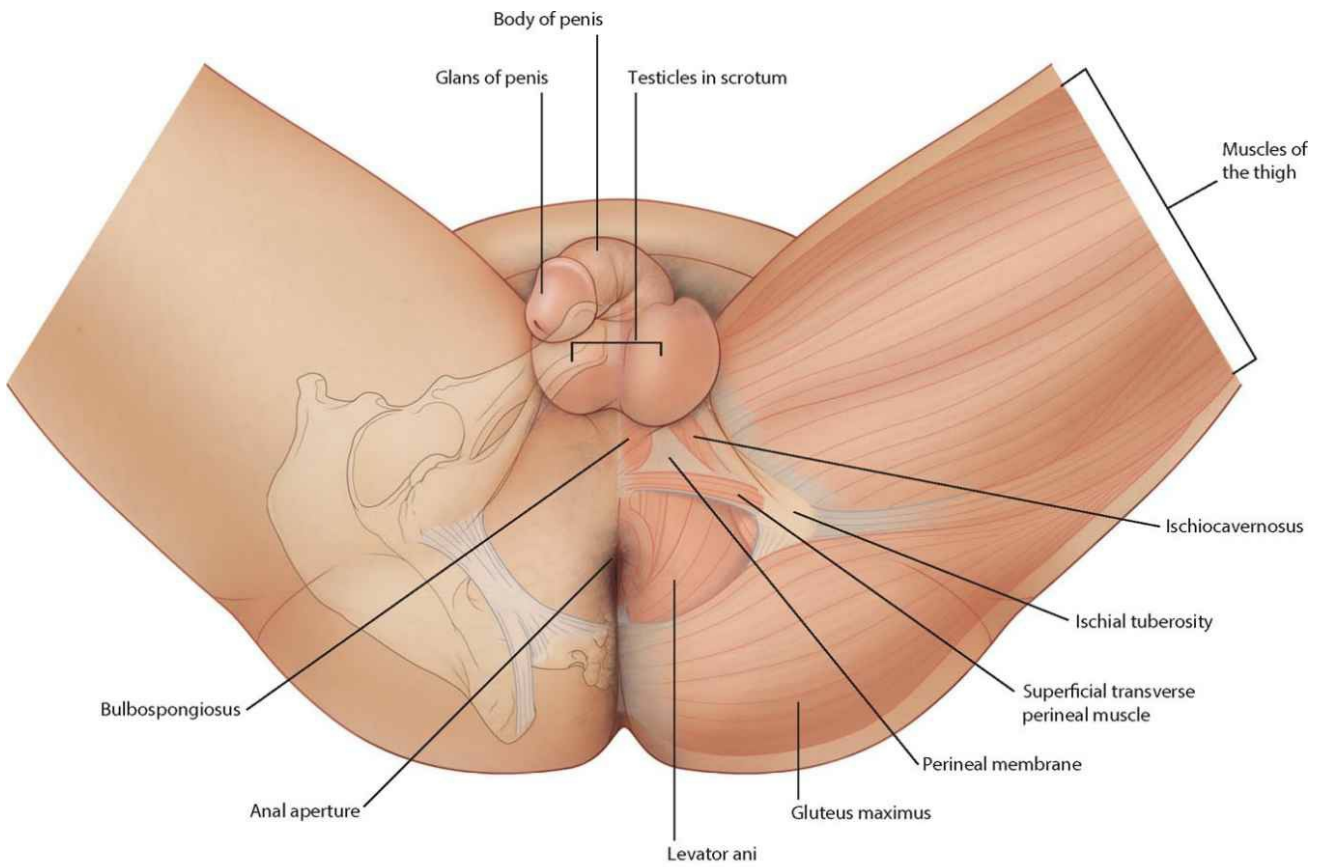


# Hypogastric plexus

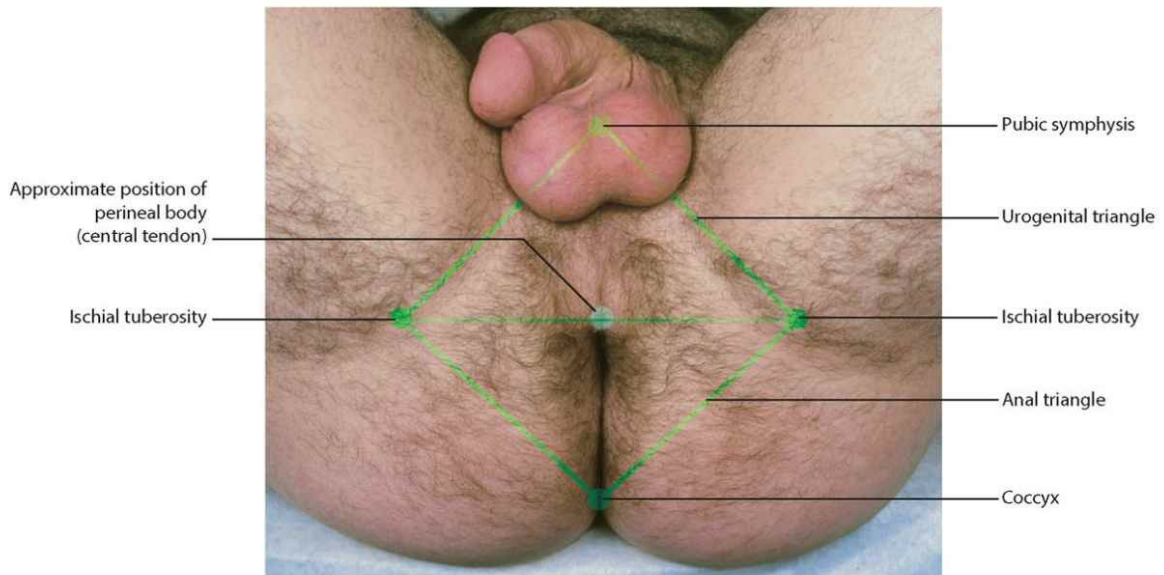


**Hypogastric nerve plexuses  
(oblique sagittal view)**

# Surface anatomy of the perineum

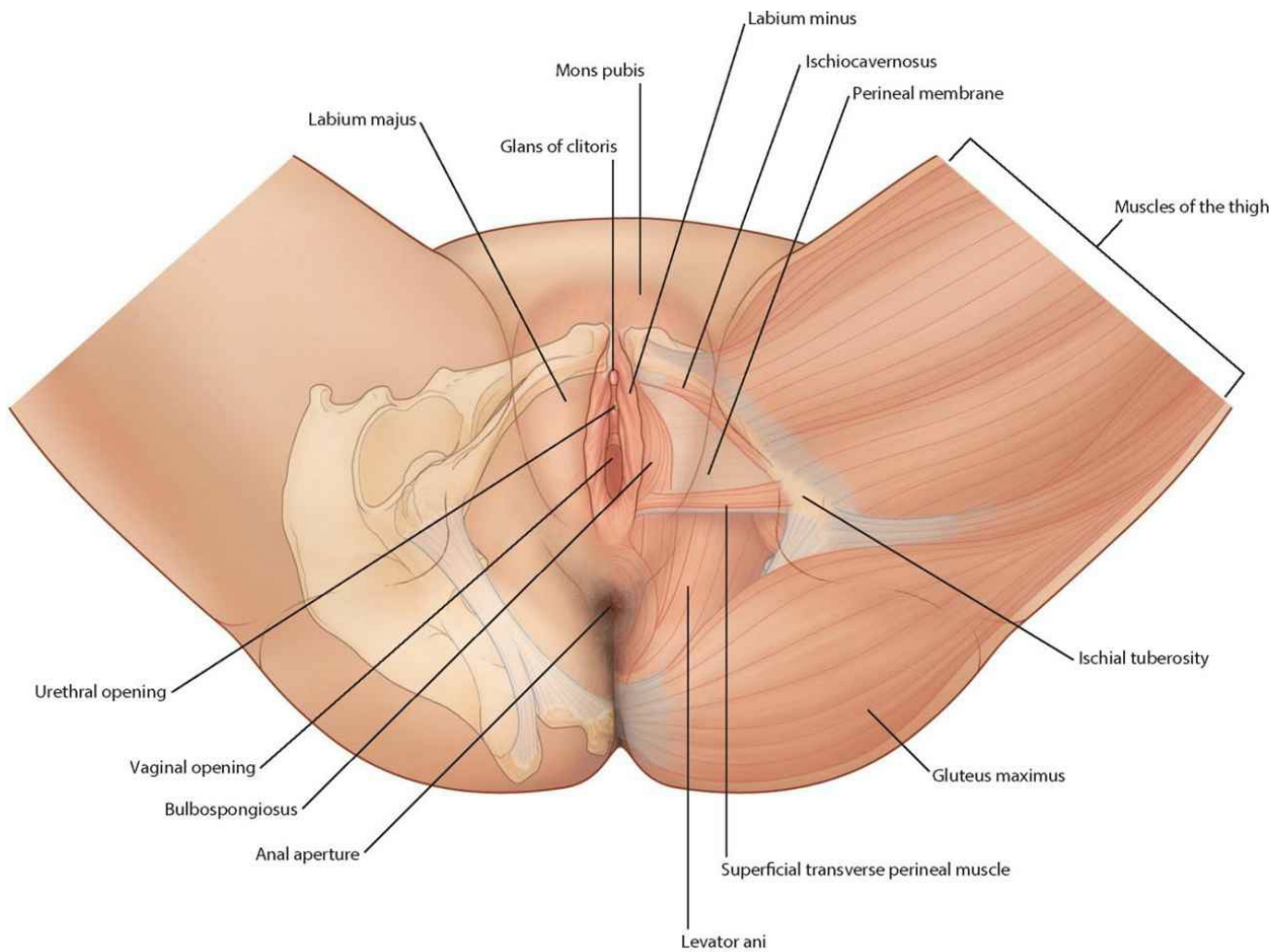


**Structures of the perineum in men**

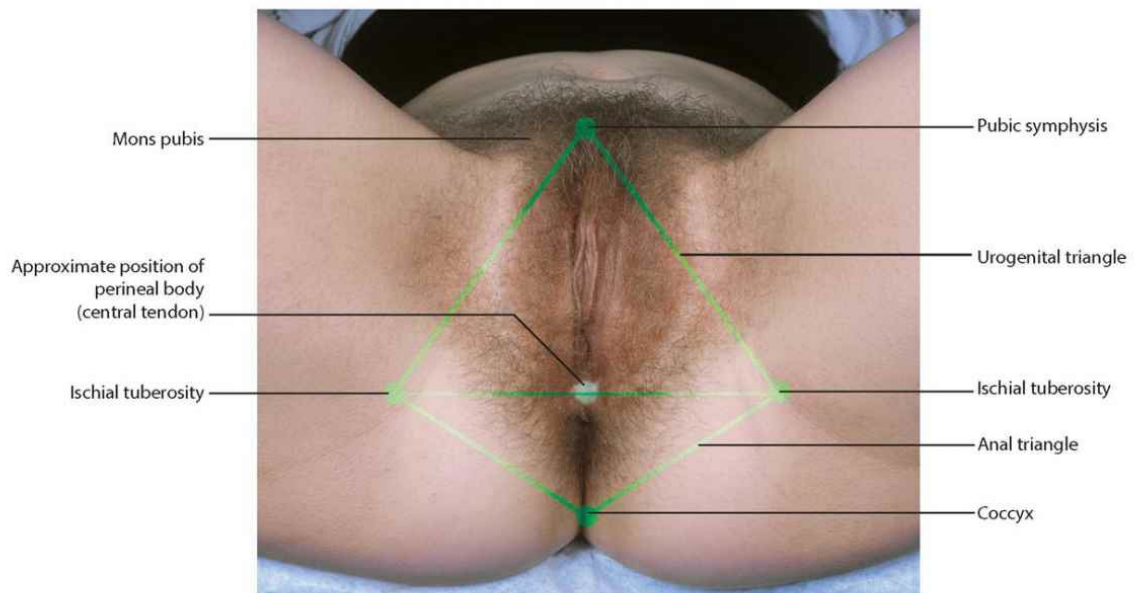


**Surface anatomy of the perineum in men**

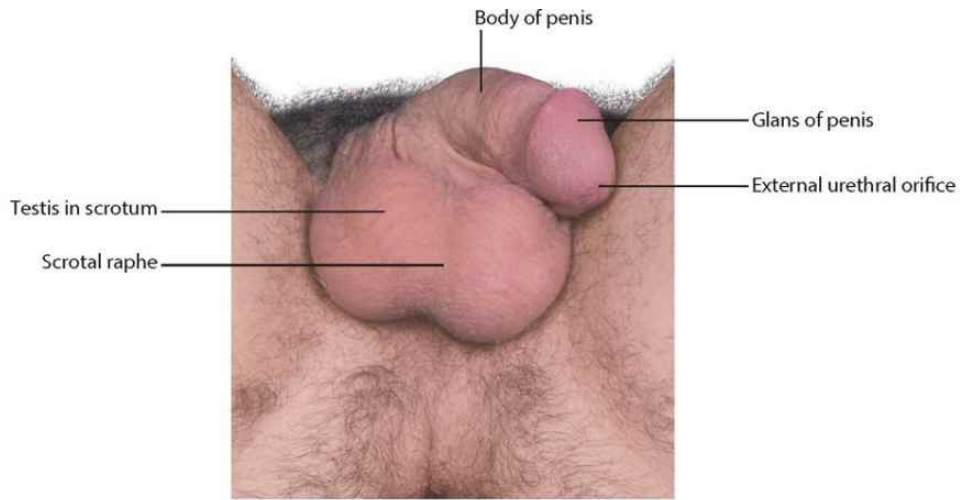




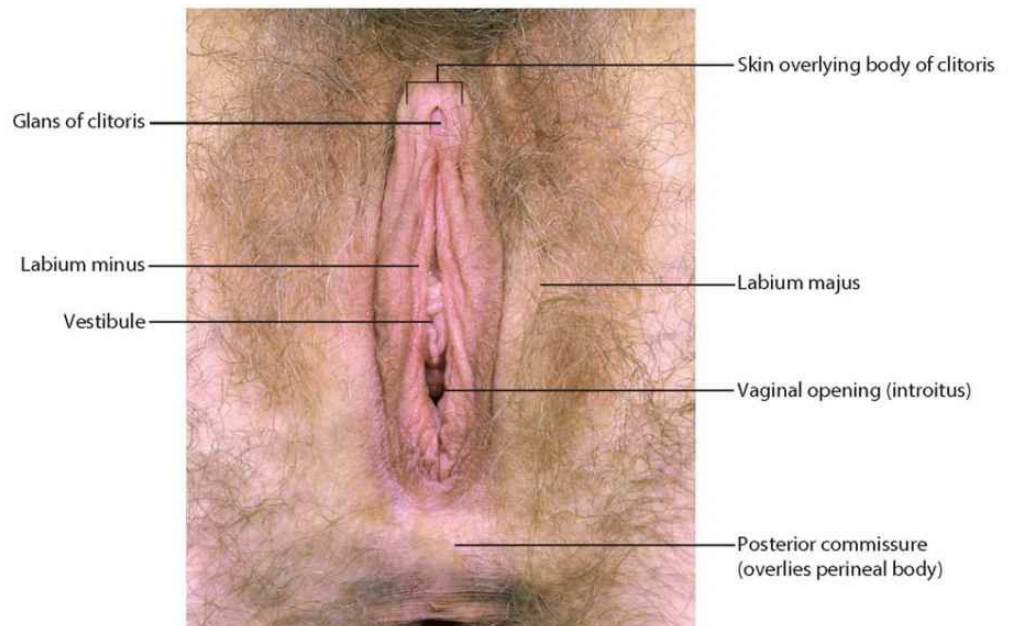
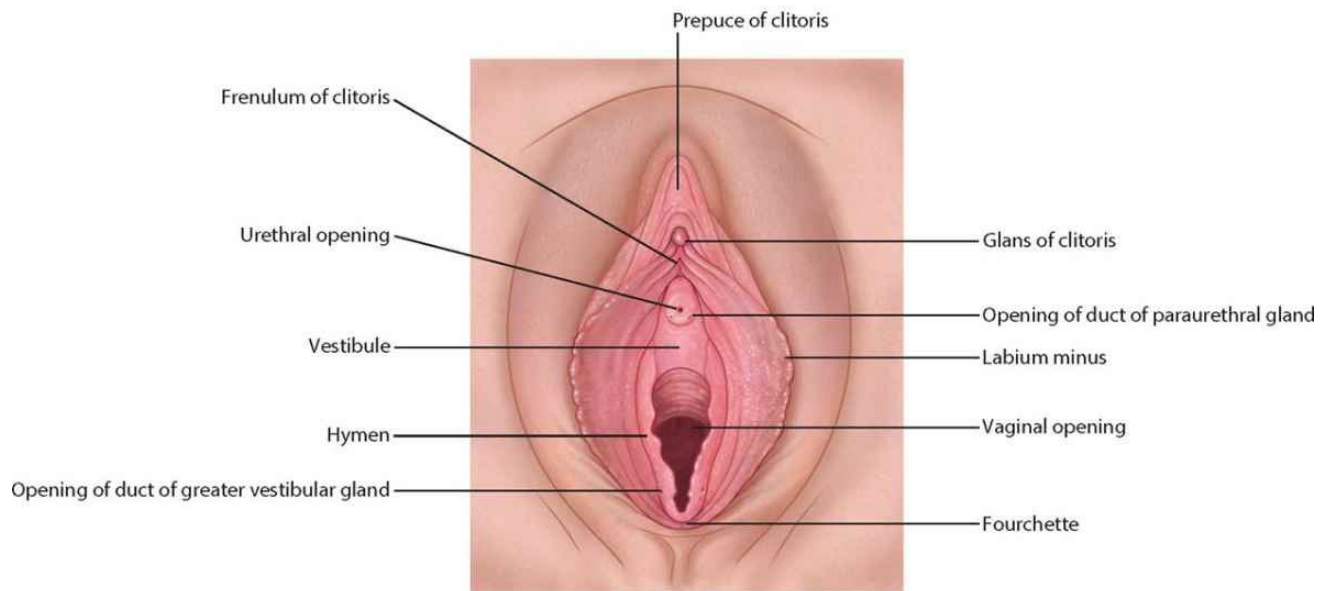
**Structures of the perineum in women**



**Surface anatomy of the perineum in women**



**Superficial features of the perineum in men**

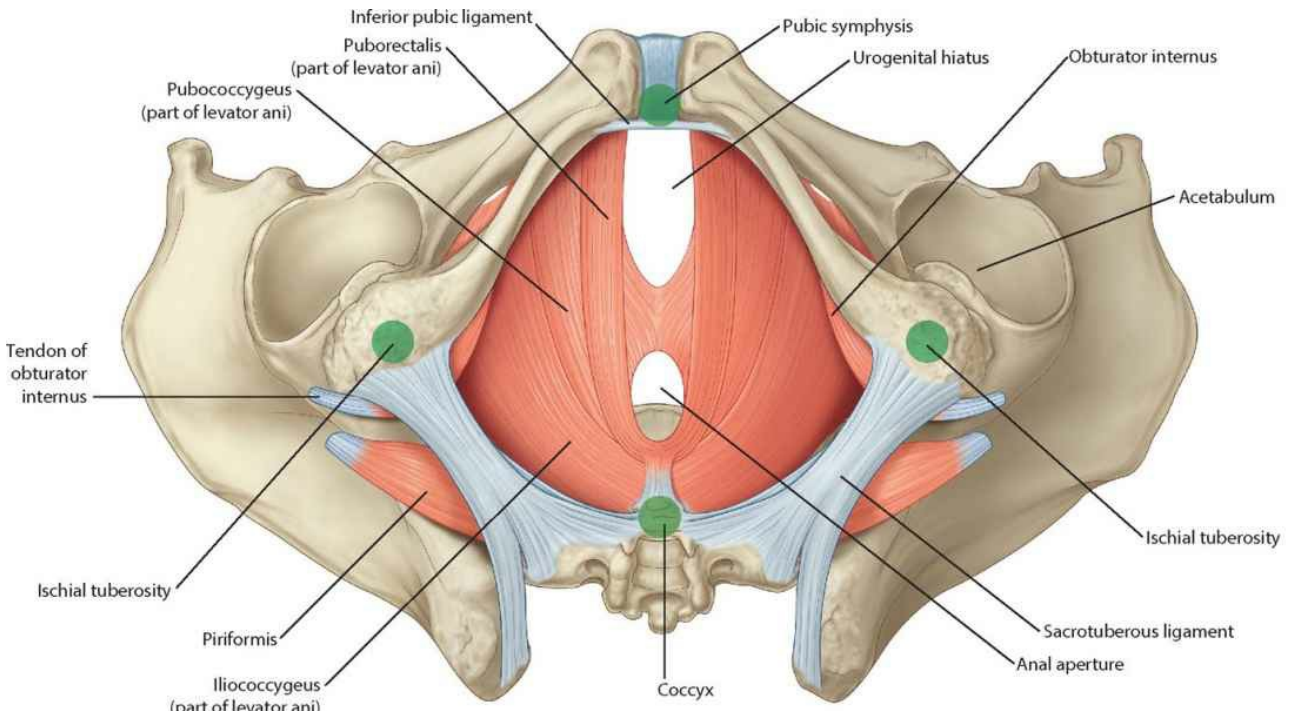


**Superficial features of the perineum in women**

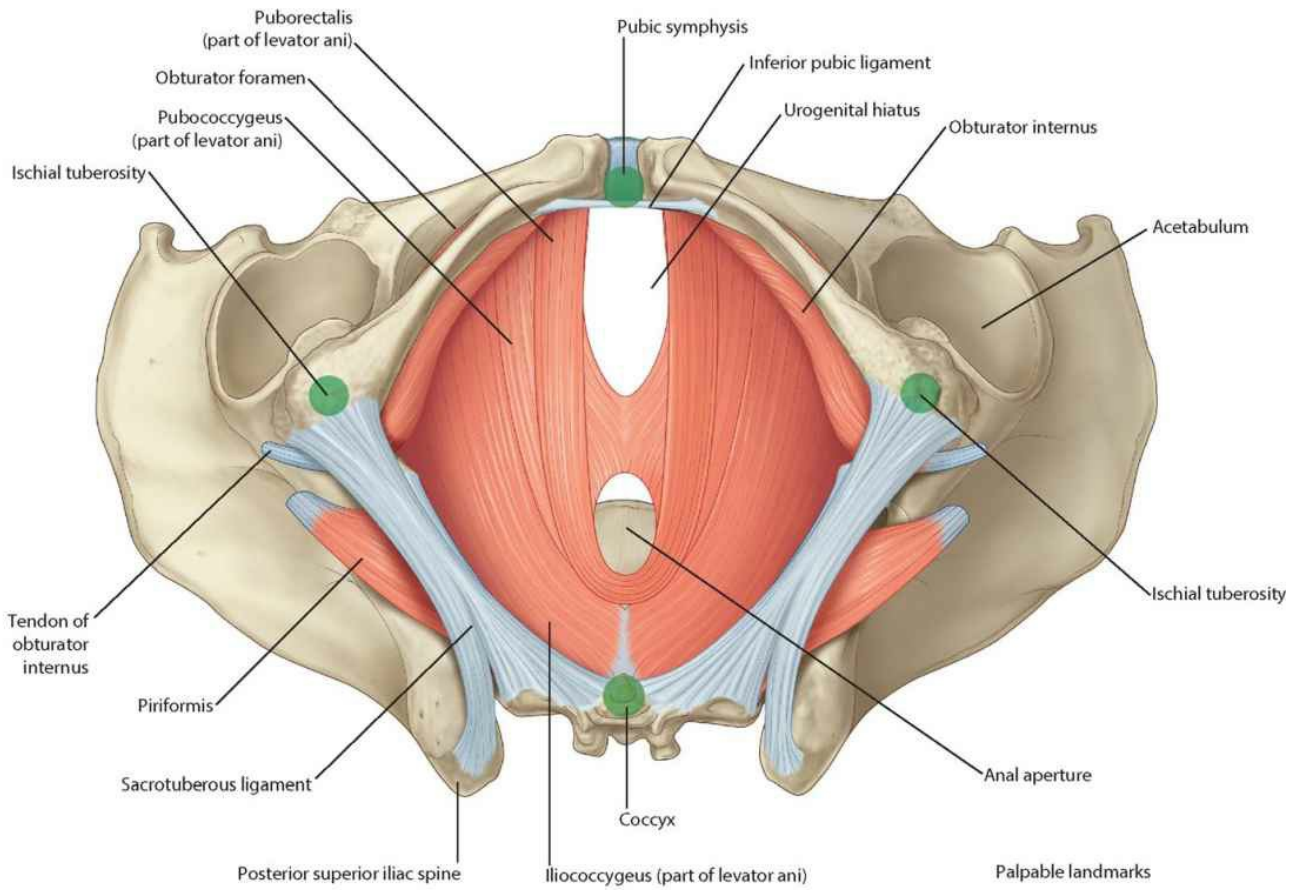




## **Borders and ceiling of the perineum**

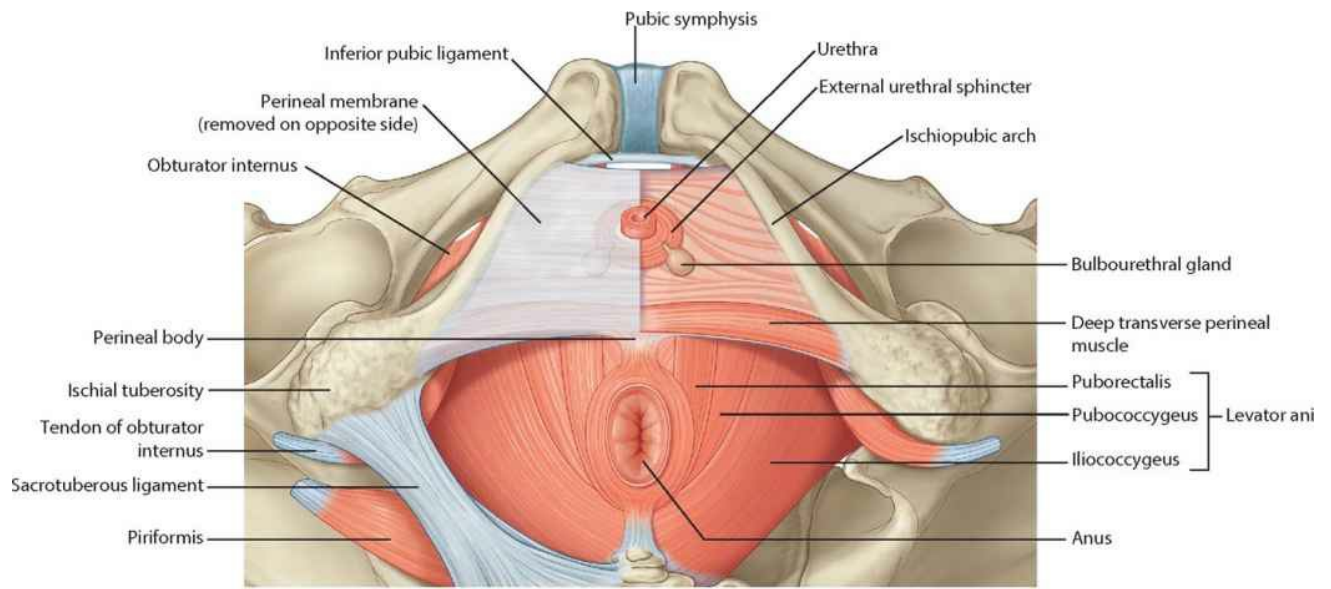


**Borders and ceiling of the perineum in men**

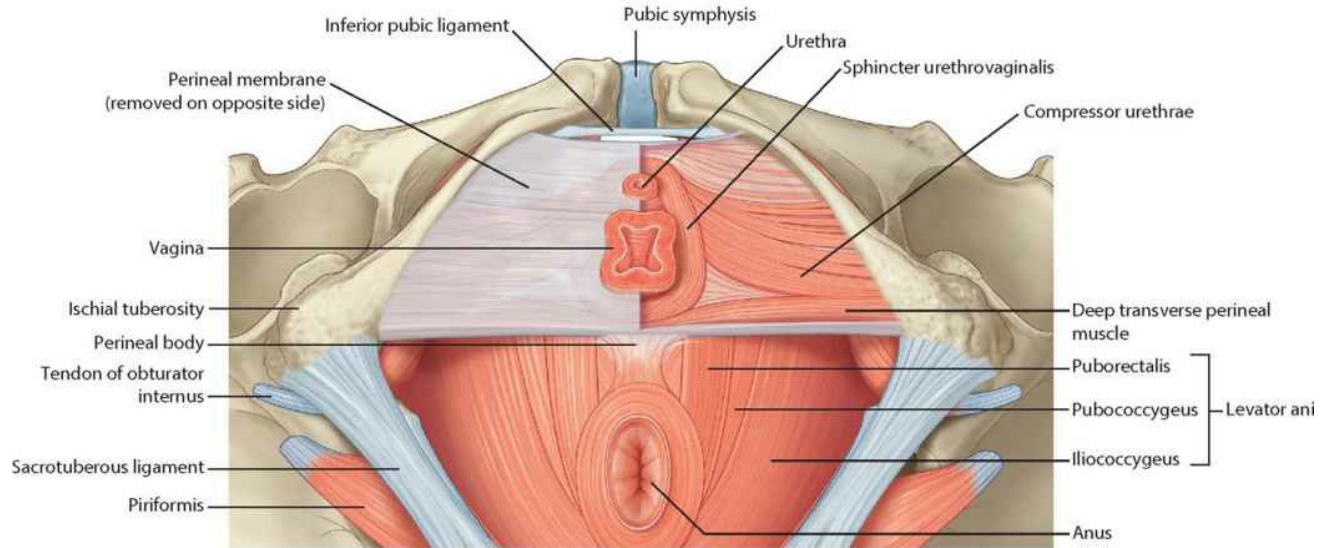


**Borders and ceiling of the perineum in women**

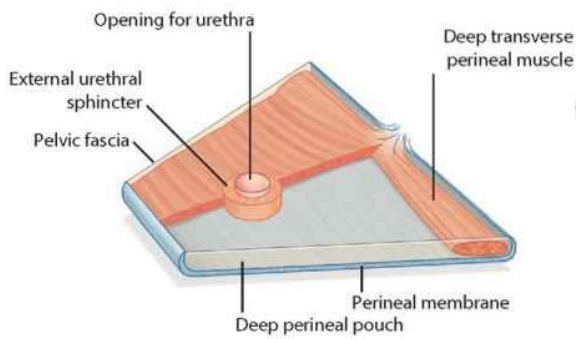
## Deep pouch and perineal membrane



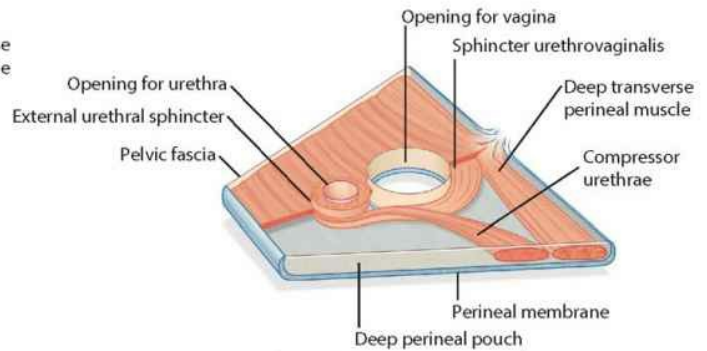
**Muscles of deep perineal pouch in men**  
(perineal membrane removed on left side to expose deep perineal pouch)



**Muscles of deep perineal pouch in women**  
(perineal membrane removed on left side to expose deep perineal pouch)

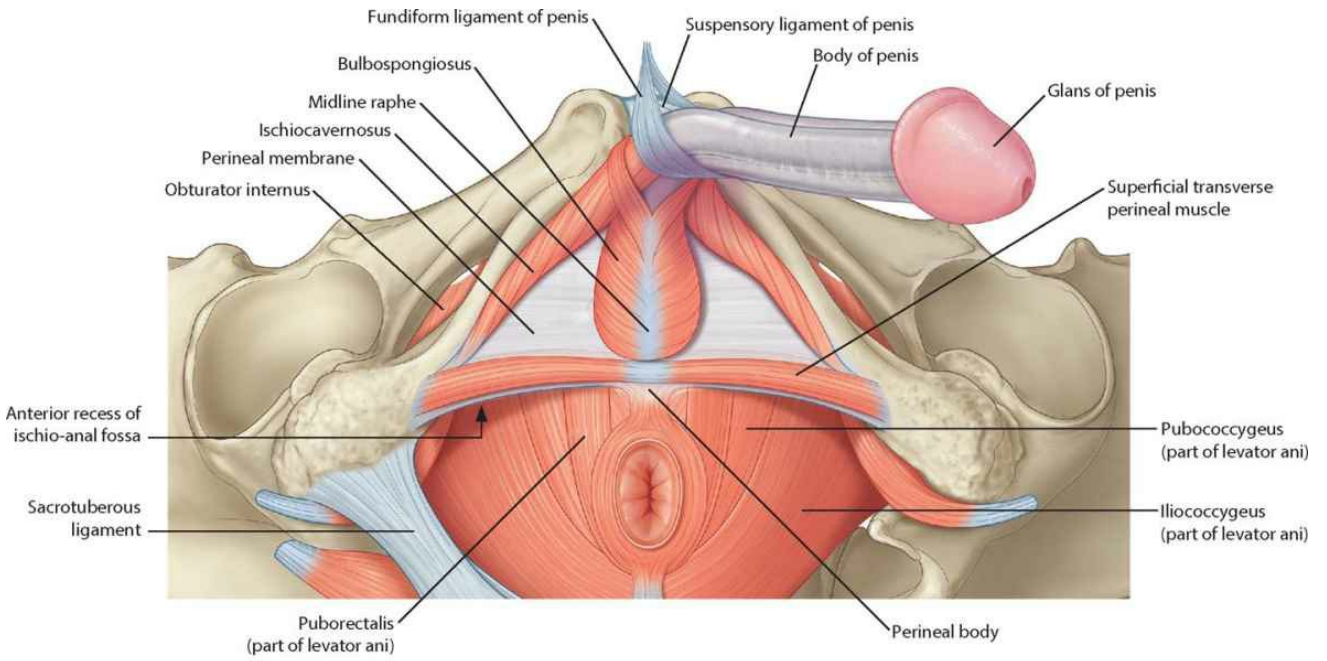


**Muscles of deep perineal pouch in men**

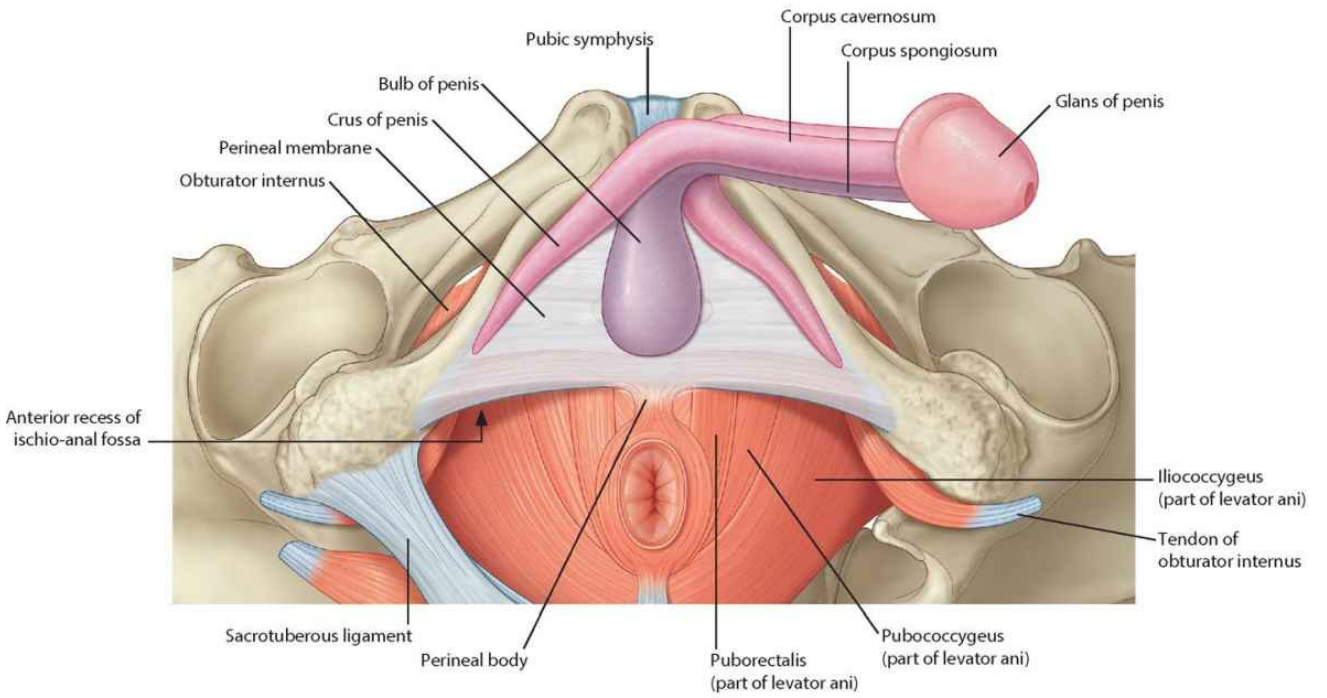


**Muscles of deep perineal pouch in women**

# Muscles and erectile tissues in men

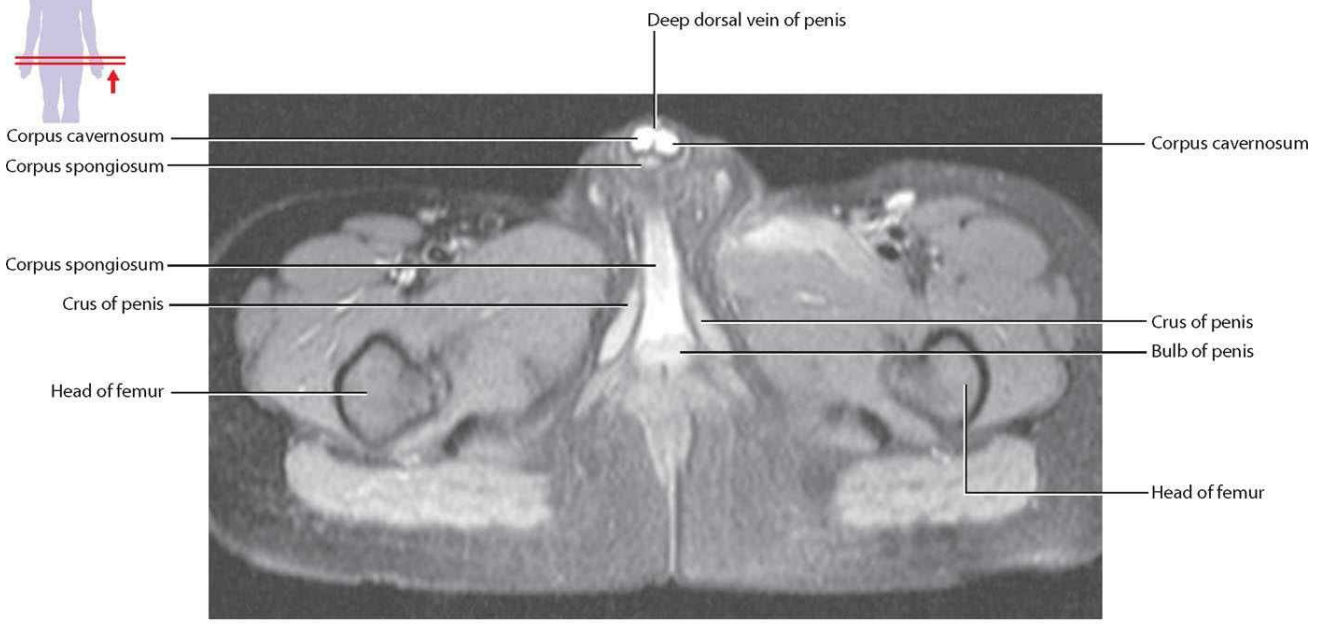
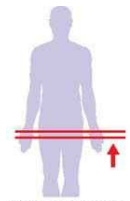


**Muscles of the superficial perineal pouch in men**

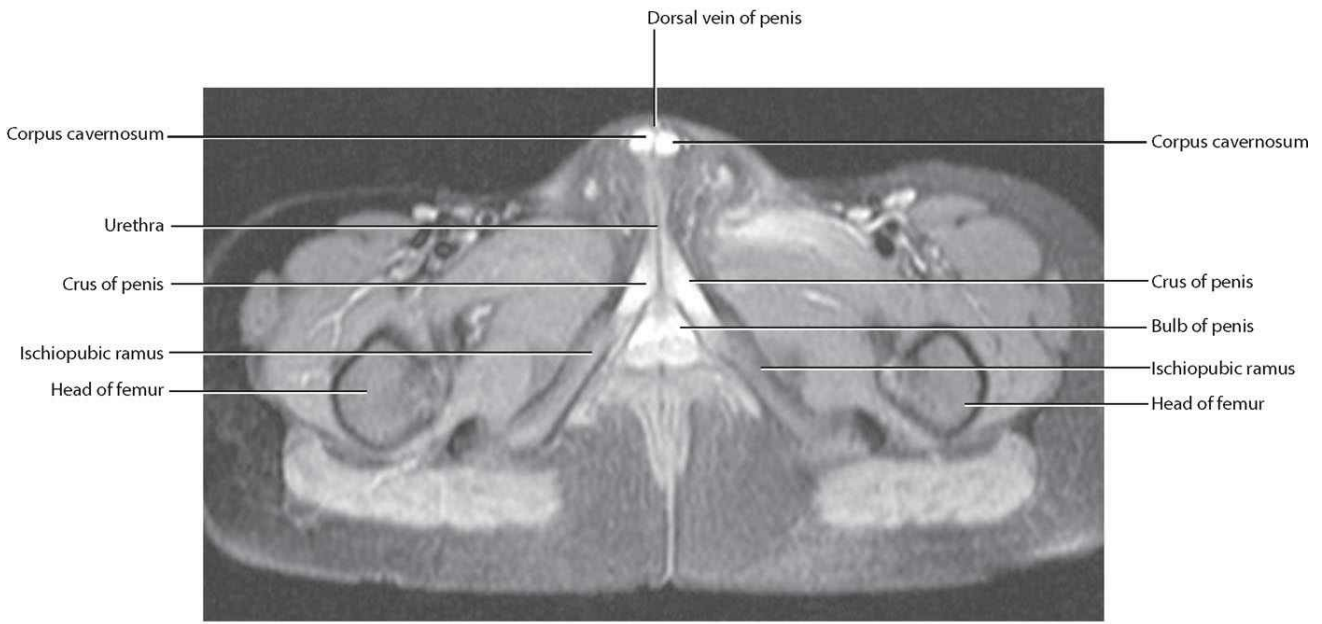


**Erectile tissues of the superficial perineal pouch in men**

# Erectile tissue in men: imaging



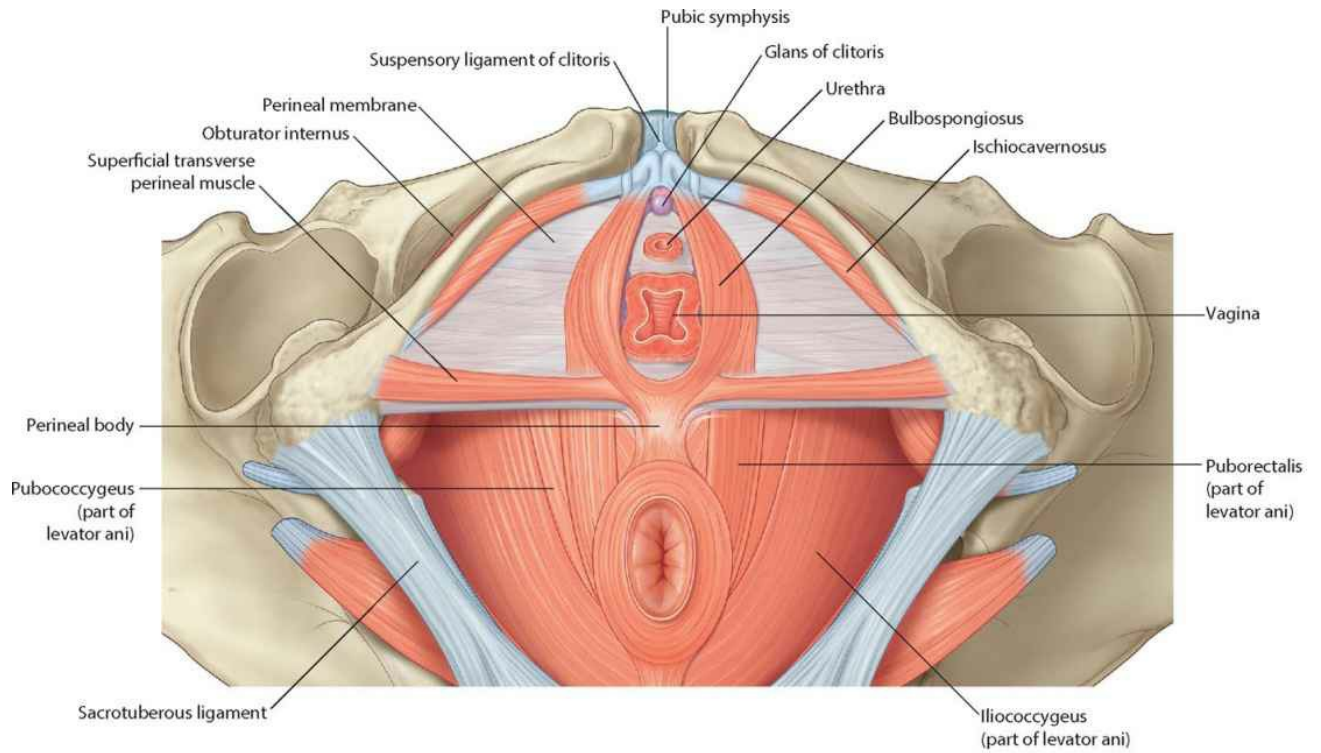
**Erectile tissues in relation to other structures in the male perineum.**  
T2-weighted MR image in axial plane



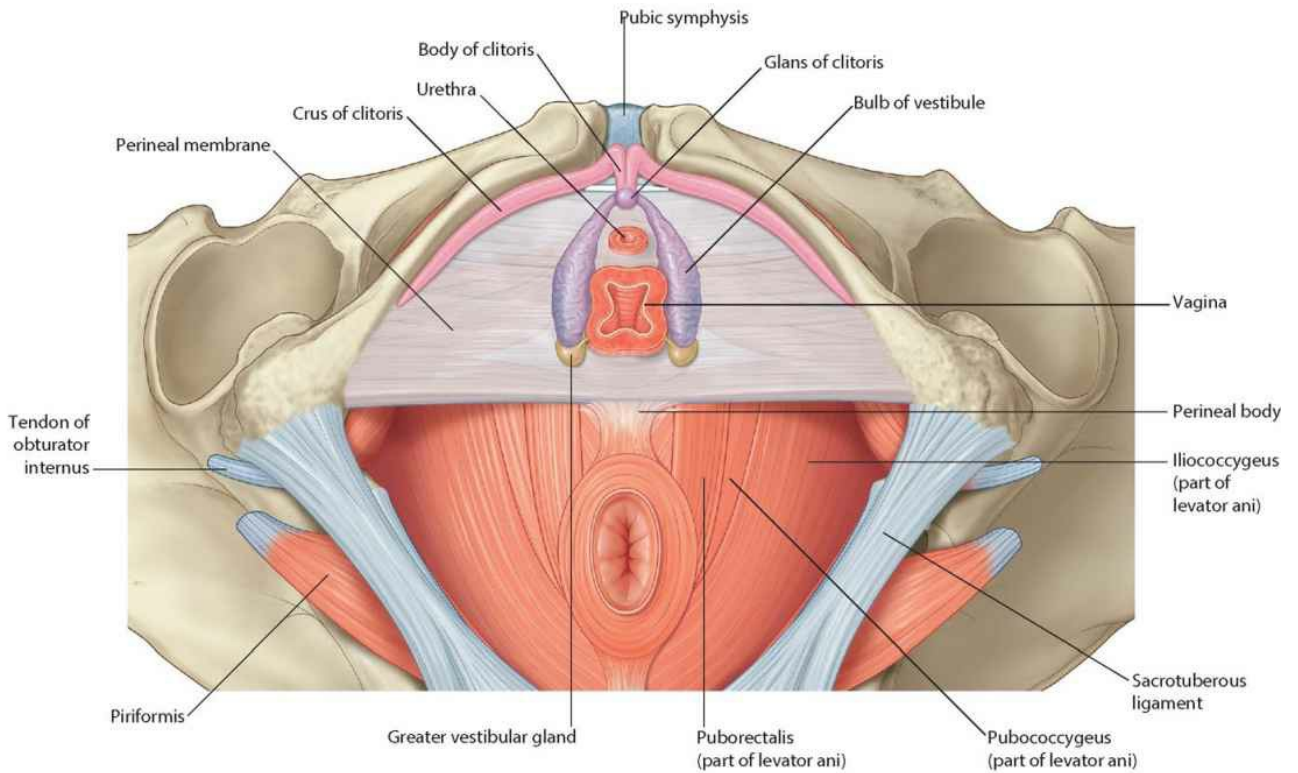
**Erectile tissues in relation to other structures in the male perineum.**  
T2-weighted MR image in axial plane



# **Muscles and erectile tissues in women**

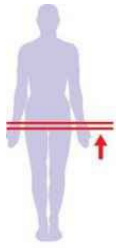


**Muscles of the superficial perineal pouch in women**

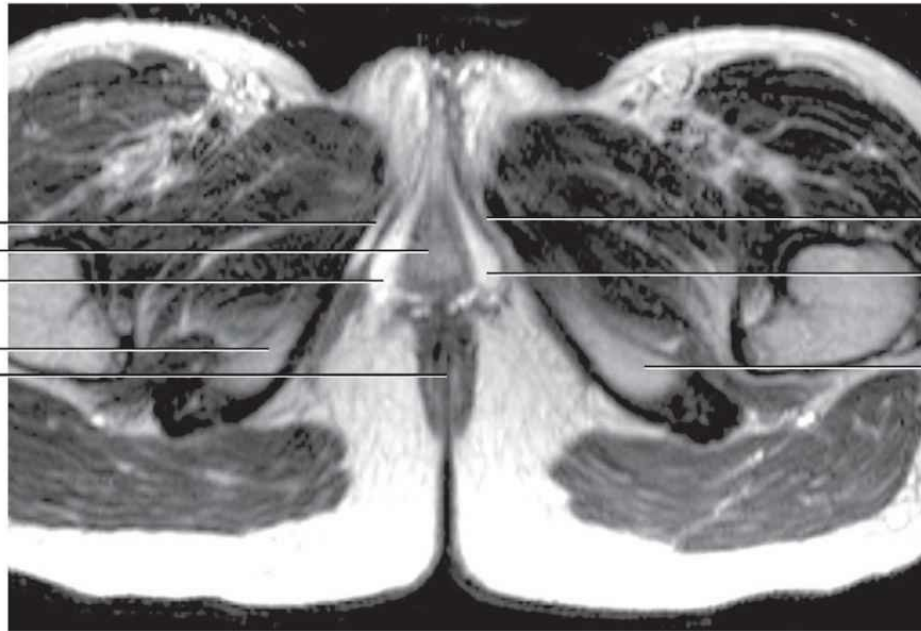


**Erectile tissues of the superficial perineal pouch in women**

# Erectile tissue in women: imaging



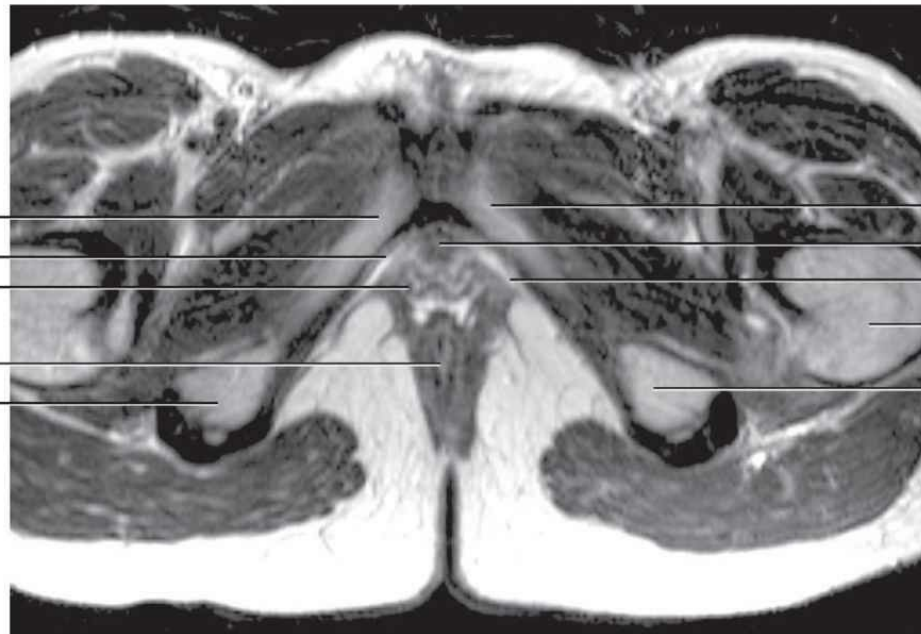Crus of clitoris  
 Vestibule  
 Bulb of vestibule  
 Ischium  
 Anus



Crus of clitoris  
 Bulb of vestibule  
 Ischium

**Erectile tissues in relation to other structures in the female perineum.**  
 T2-weighted MR image in axial plane

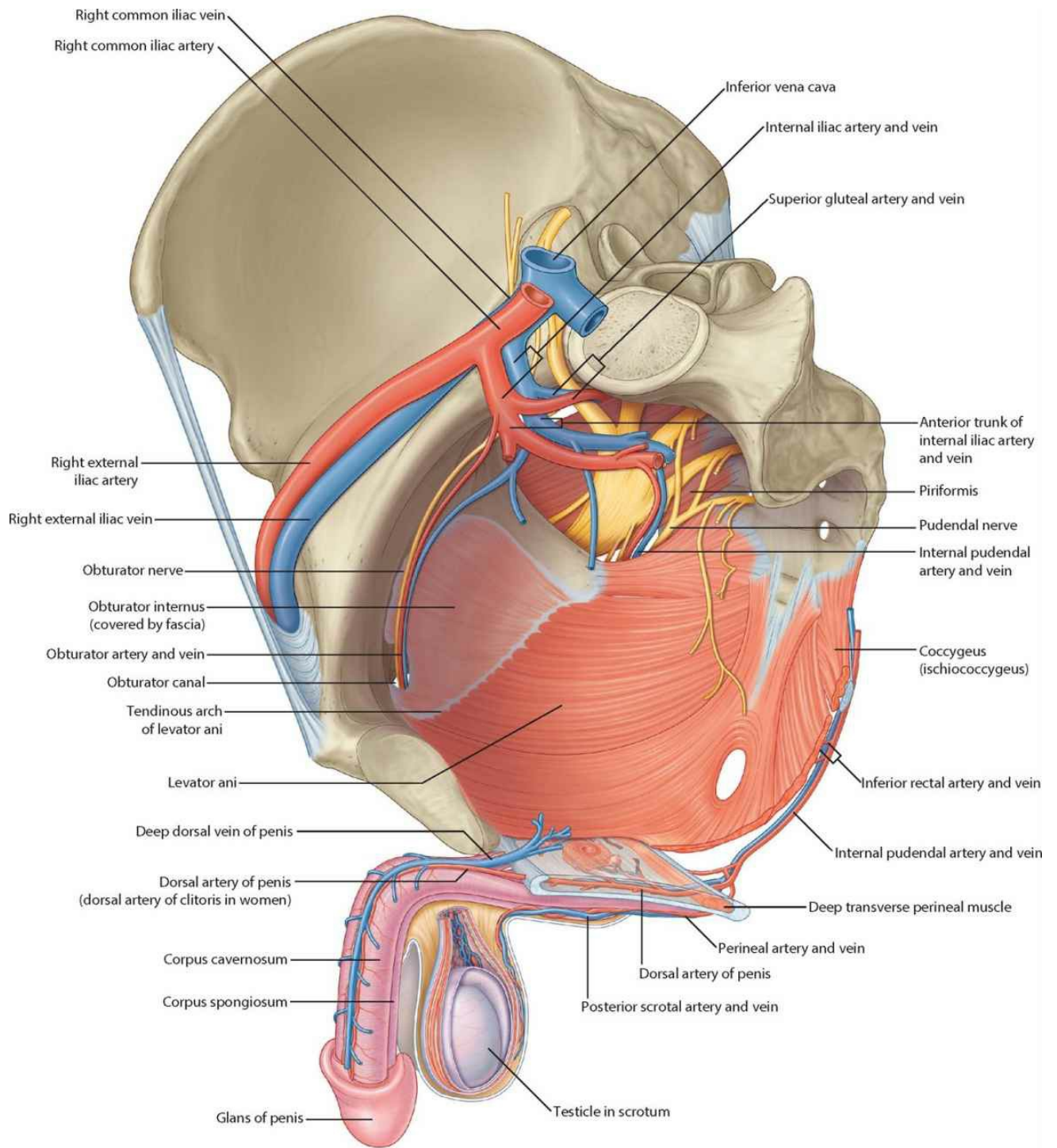
Pubic ramus  
 Crus of clitoris  
 Vagina  
 Anus  
 Ischial tuberosity



Pubic ramus  
 Urethra  
 Crus of clitoris  
 Femur  
 Ischial tuberosity

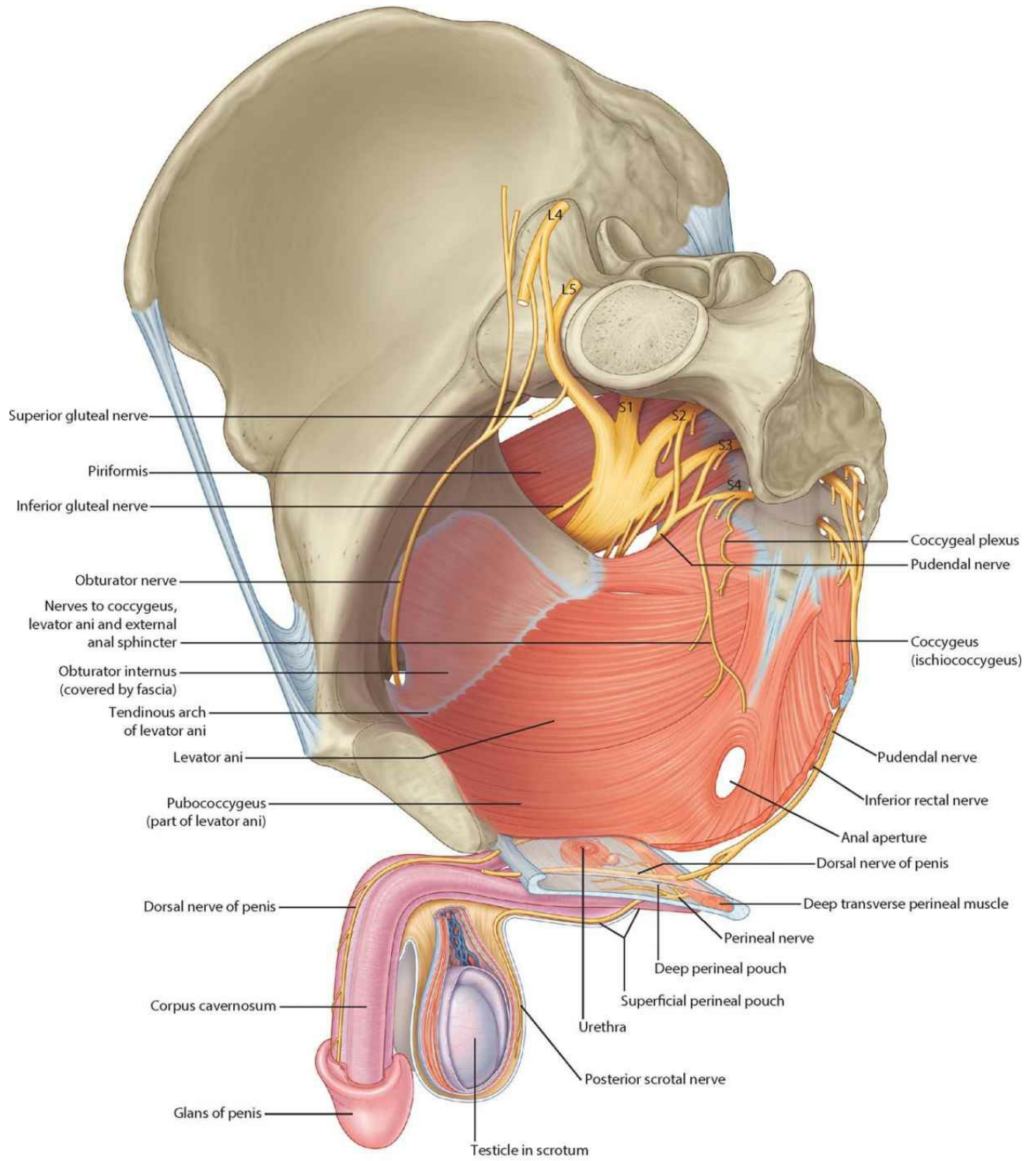
**Erectile tissues in relation to other structures in the female perineum.**  
 T2-weighted MR image in axial plane

# Internal pudendal artery and vein



**Course of internal pudendal artery and vein in men (oblique sagittal view)**

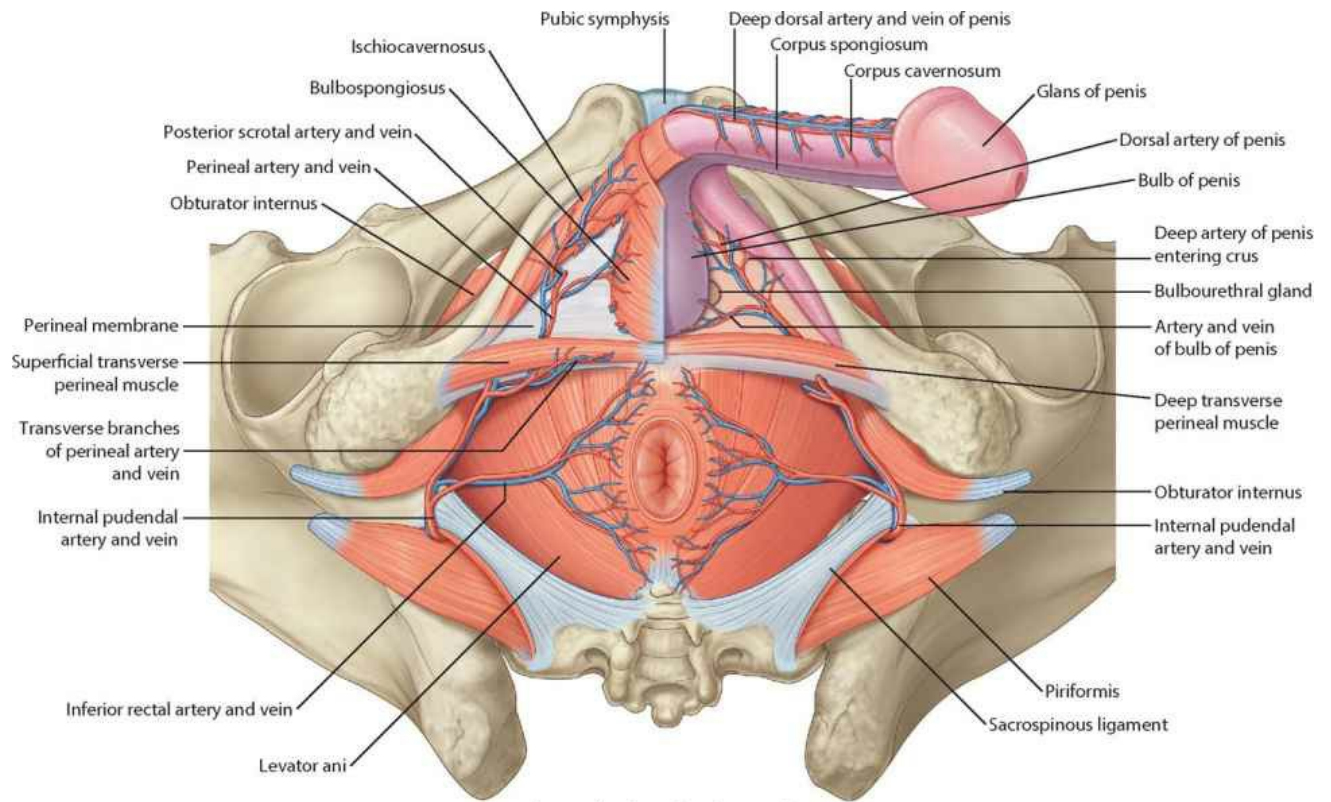
# Pudendal nerve



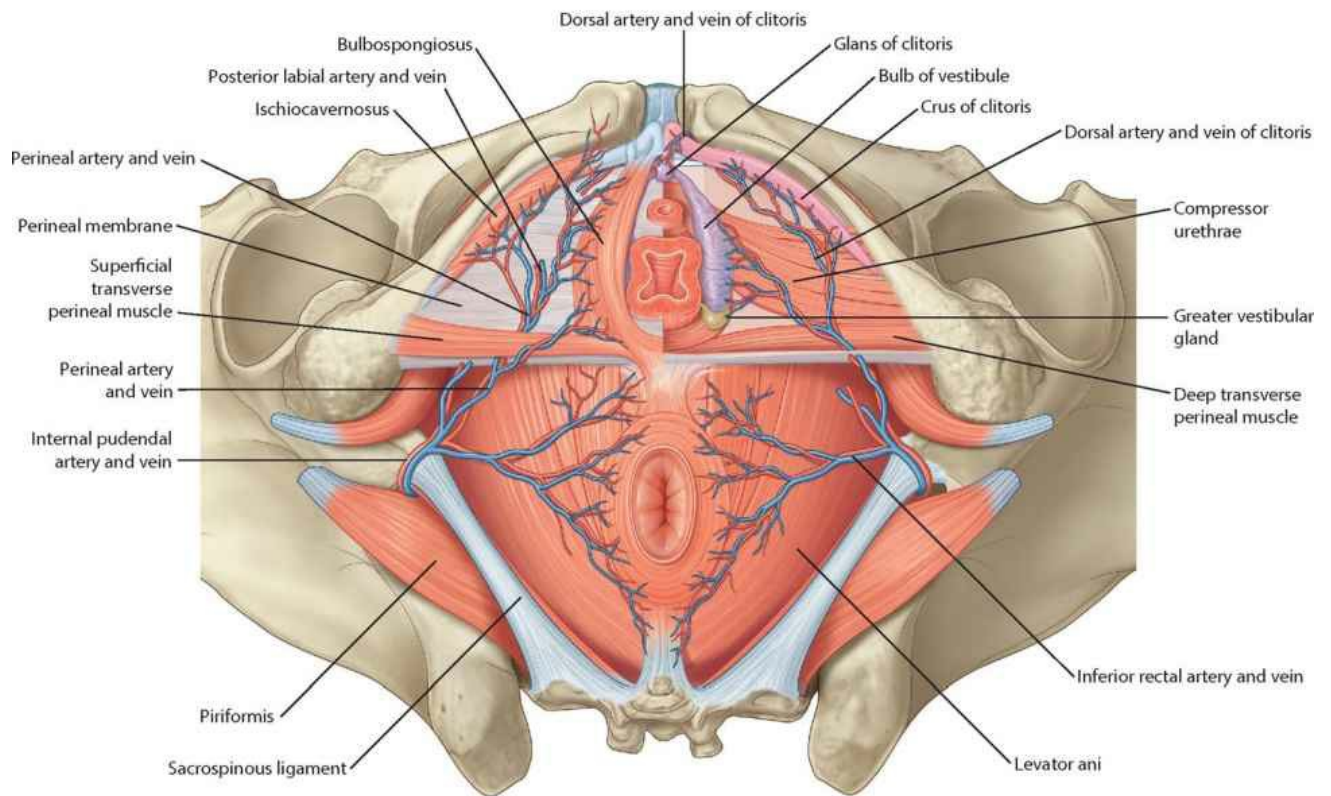
**Course of pudendal nerve in men  
(oblique sagittal view)**



# Vasculature of perineum

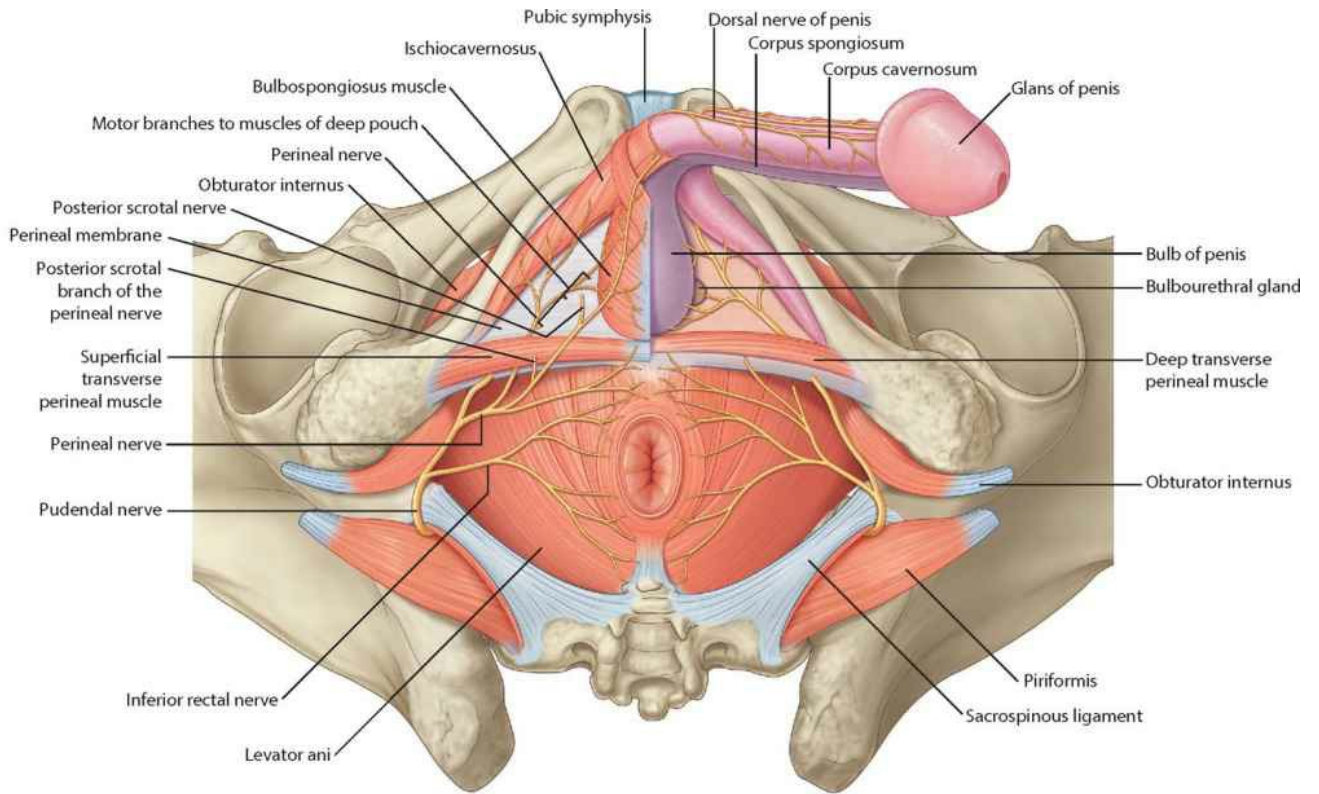


**Arteries and veins of perineum in men**  
 (perineal membrane removed on left side to expose deep perineal pouch, inferior view)

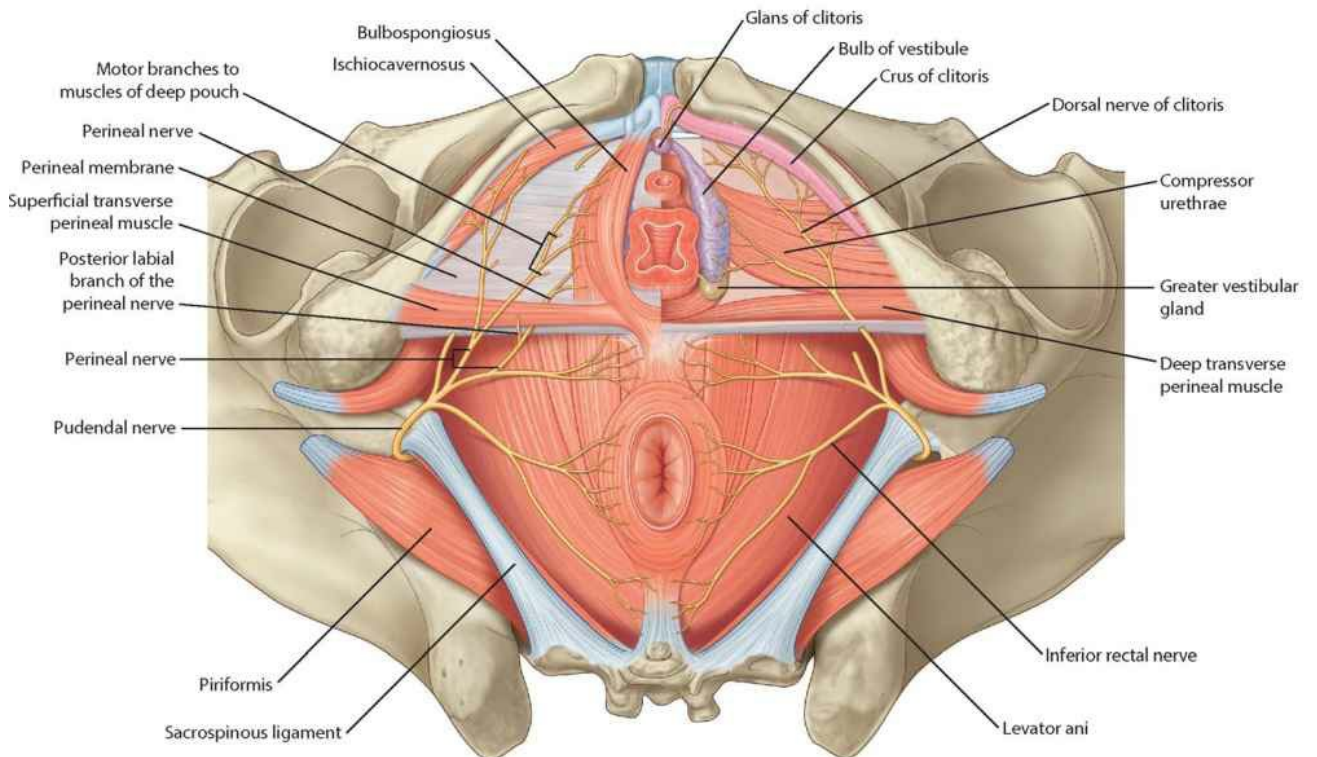


**Arteries and veins of perineum in women**  
 (perineal membrane removed on left side to expose deep perineal pouch, inferior view)

## Nerves of perineum

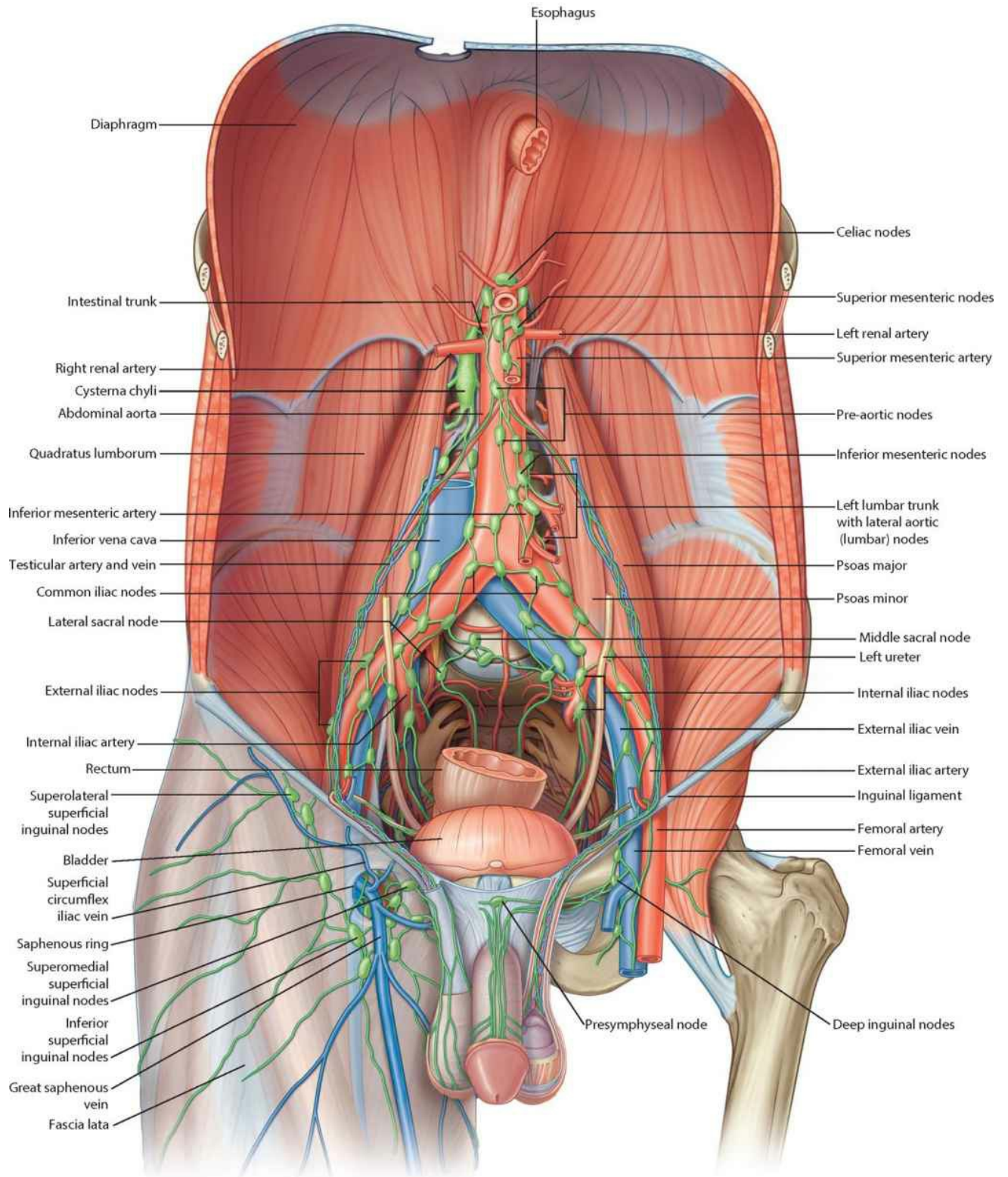


**Nerves of the perineum in men**  
 (perineal membrane removed on left side to expose deep perineal pouch, inferior view)



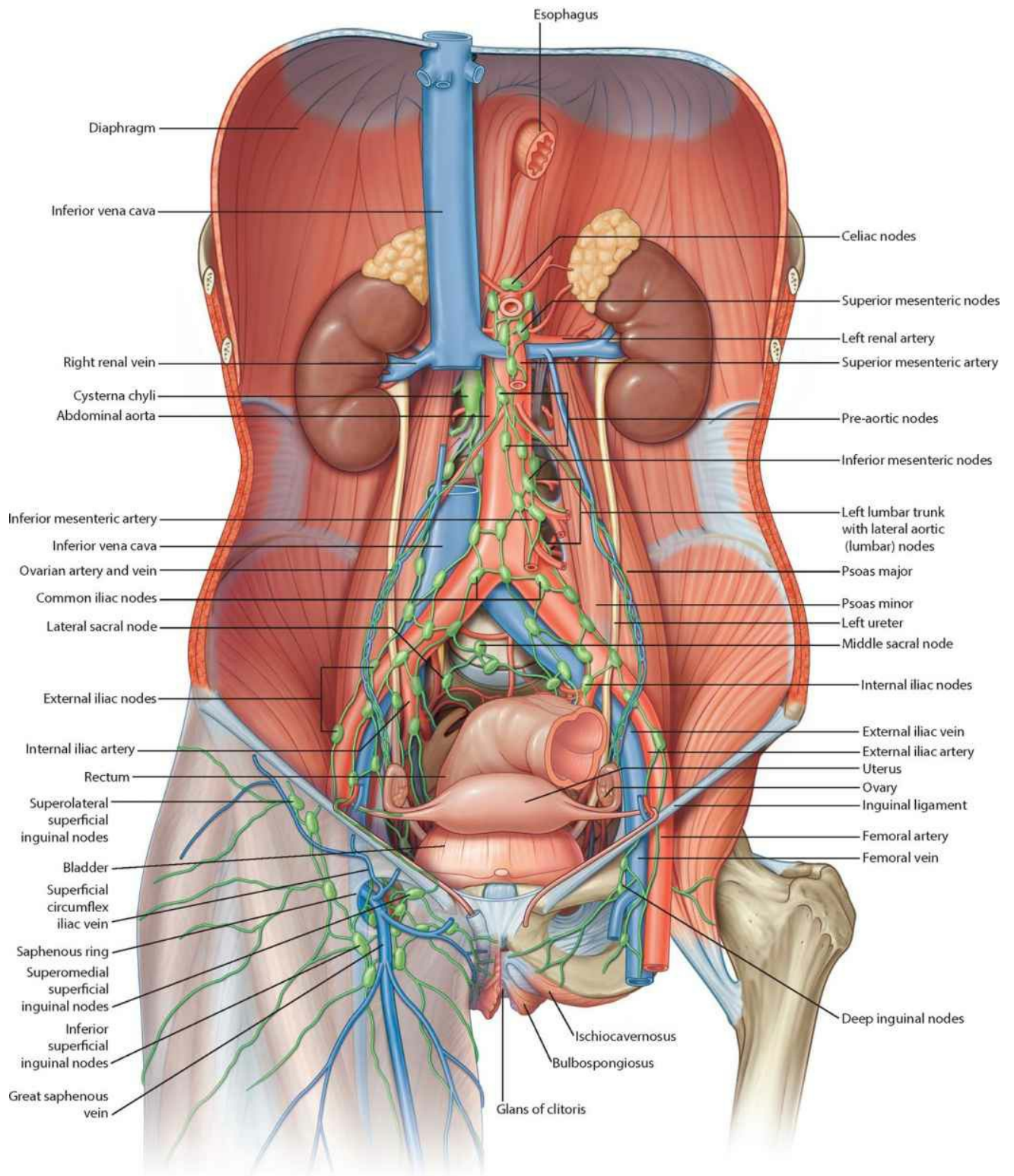
**Nerves of the perineum in women**  
 (perineal membrane removed on left side to expose deep perineal pouch, inferior view)

# Lymphatics of pelvis and perineum in men



Lymphatics of pelvis and perineum in men

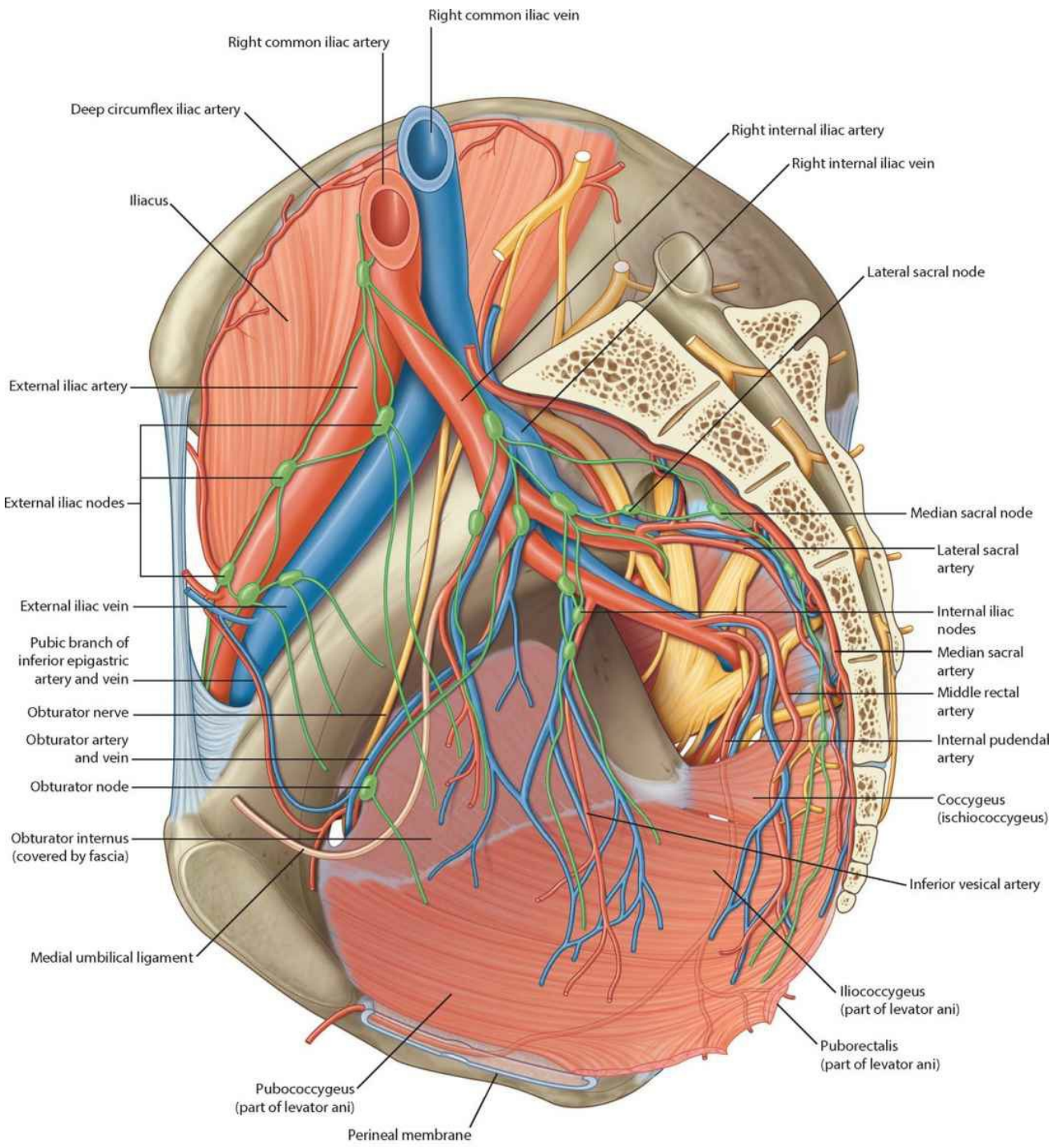
# **Lymphatics of pelvis and perineum in women**



Lymphatics of pelvis and perineum in women

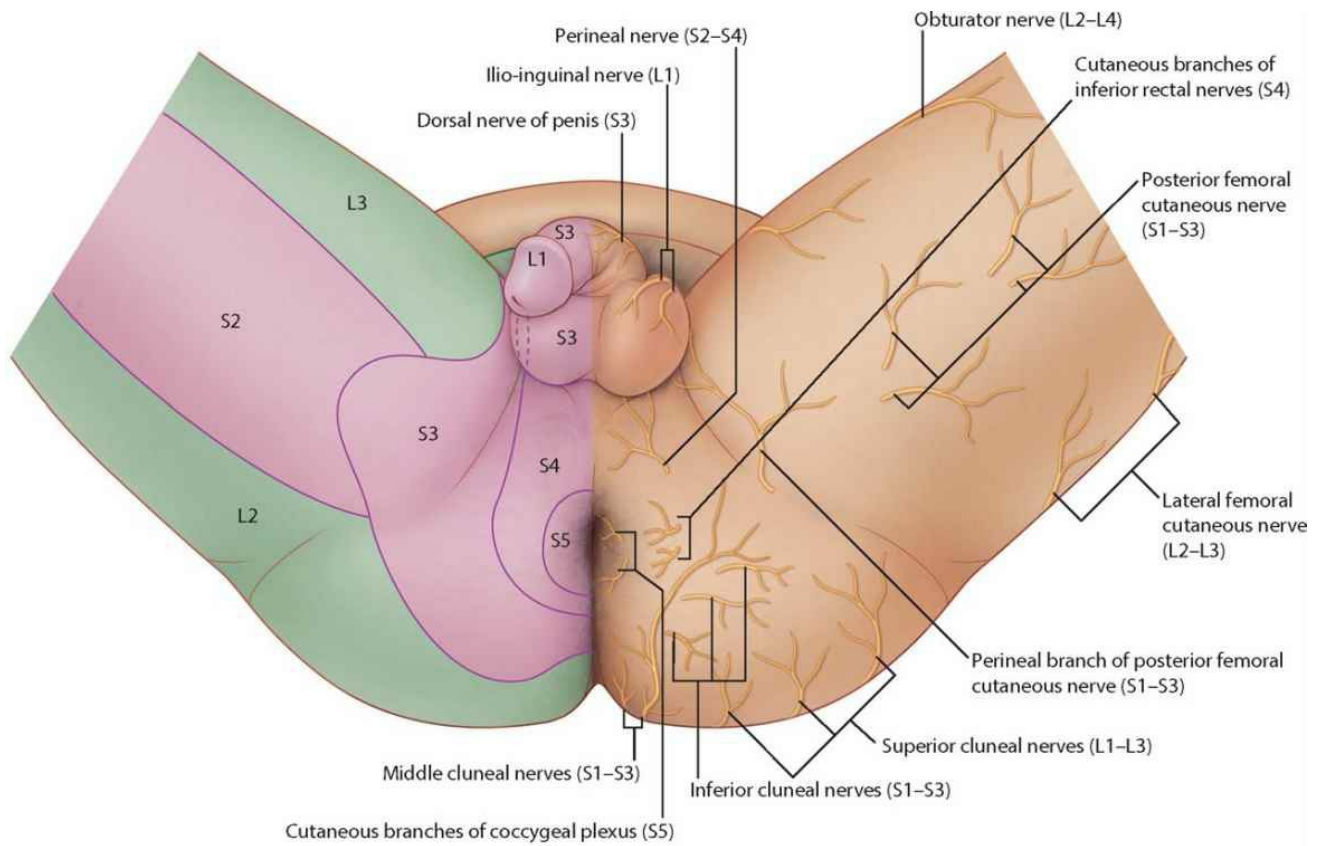


# Lymphatics

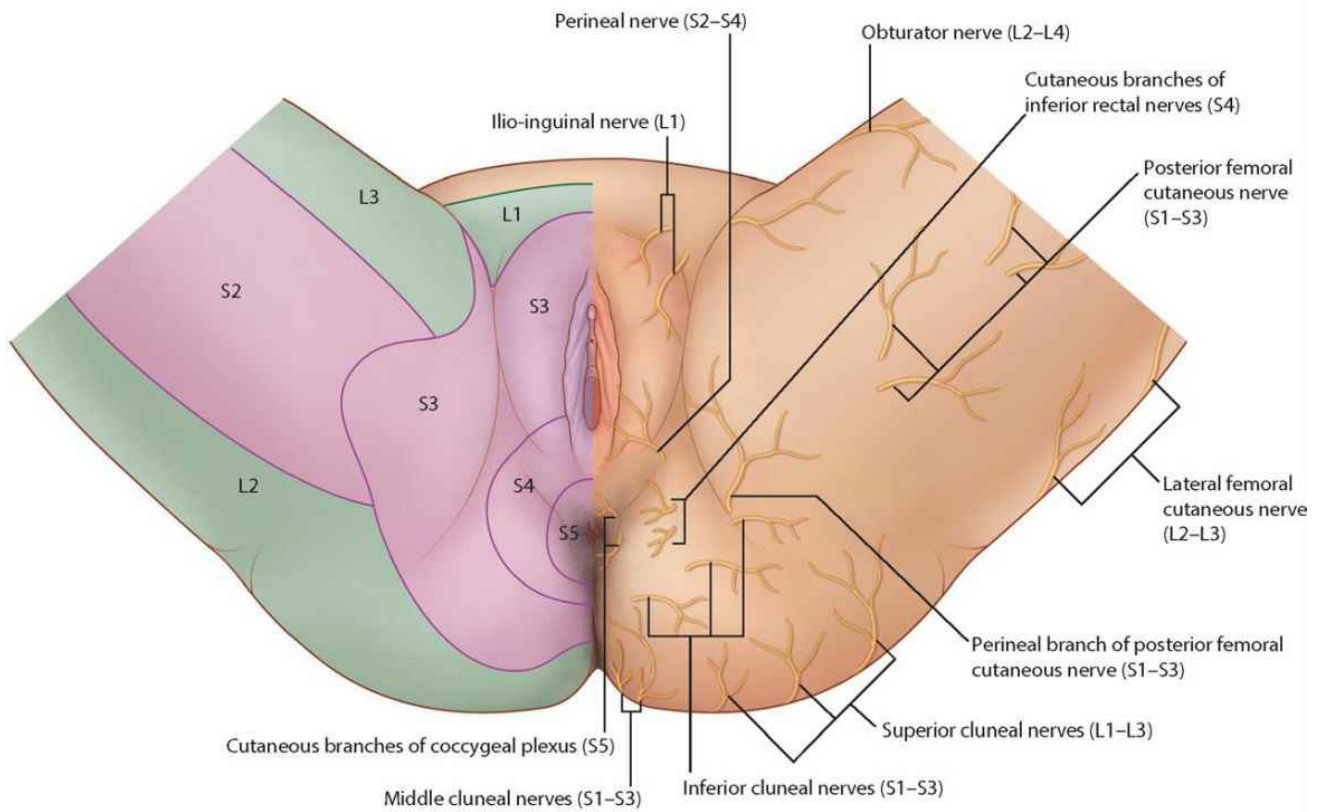


Lymphatics of pelvic cavity (sagittal view)

# Dermatomes



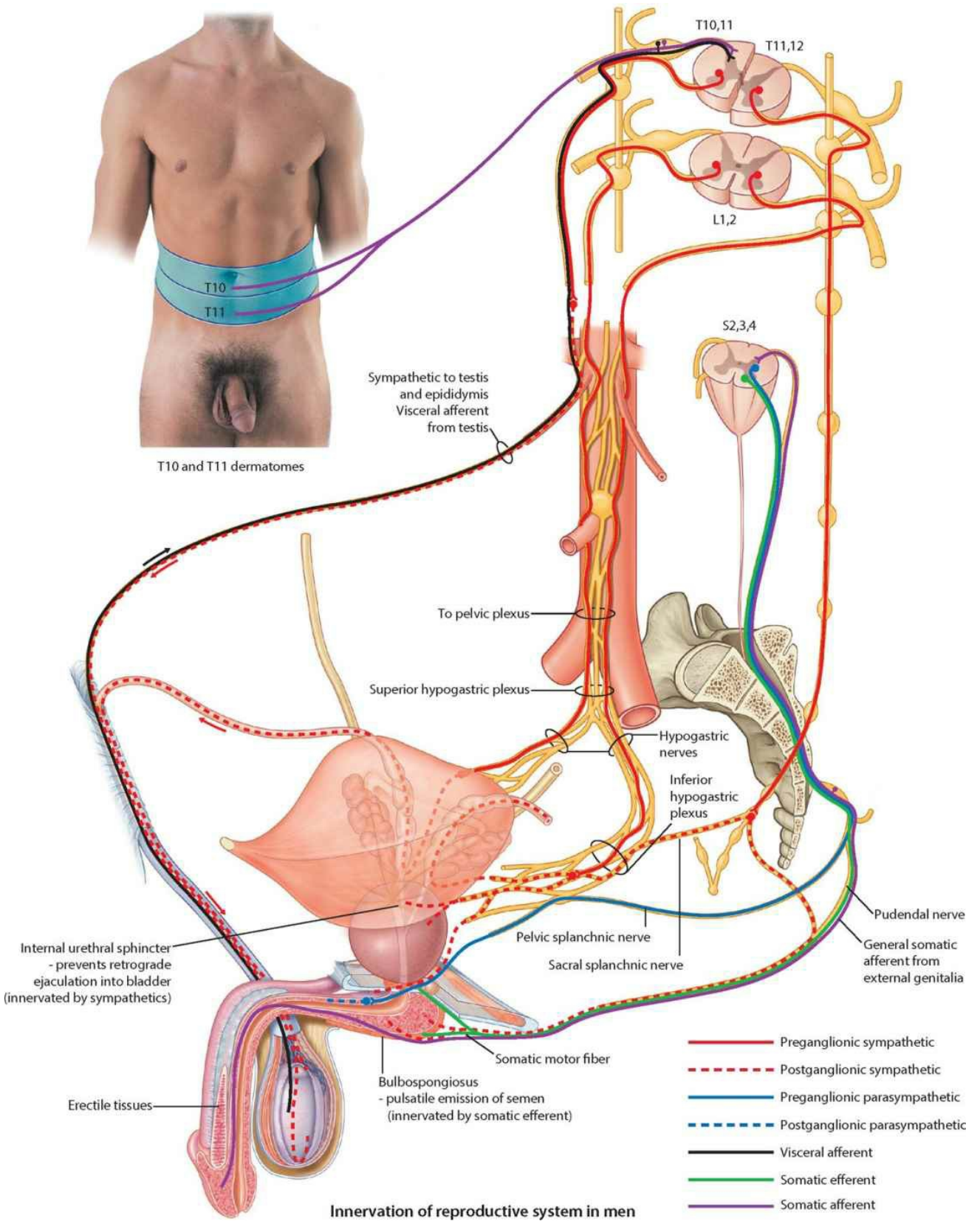
**Dermatomes and cutaneous nerves of perineum in men**



**Dermatomes and cutaneous nerves of perineum in women**

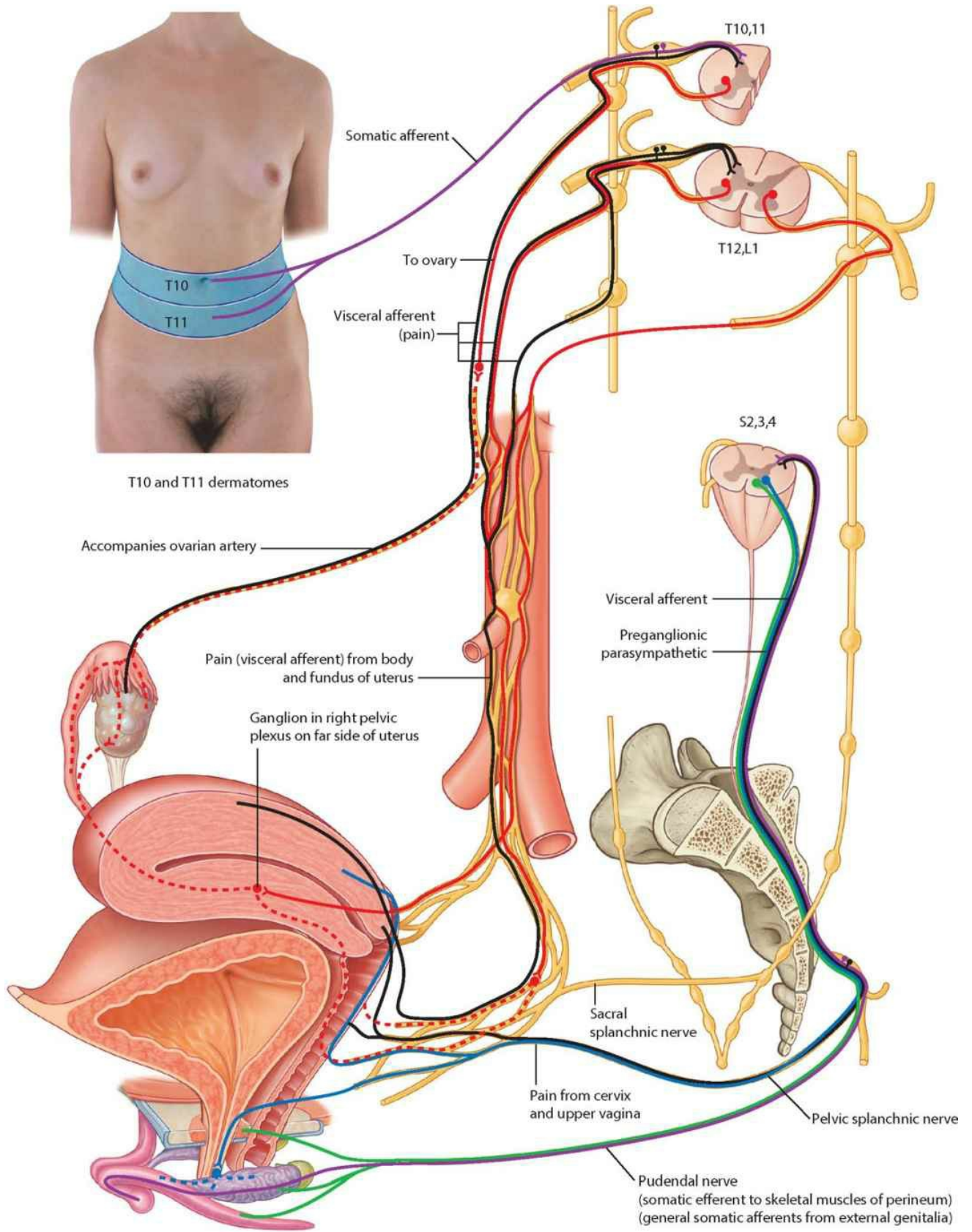


# Innervation of reproductive system in men



# Innervation of reproductive system in women

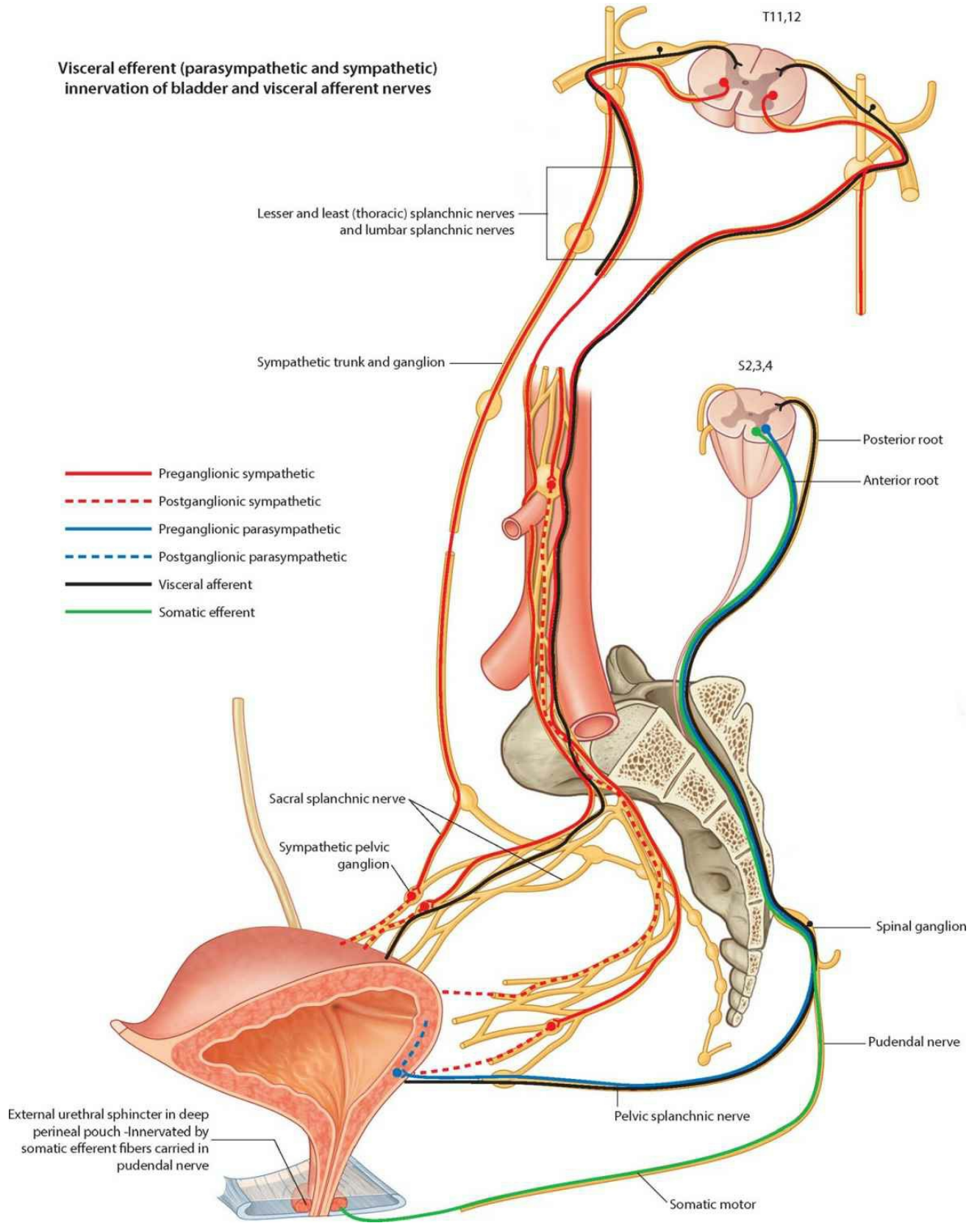




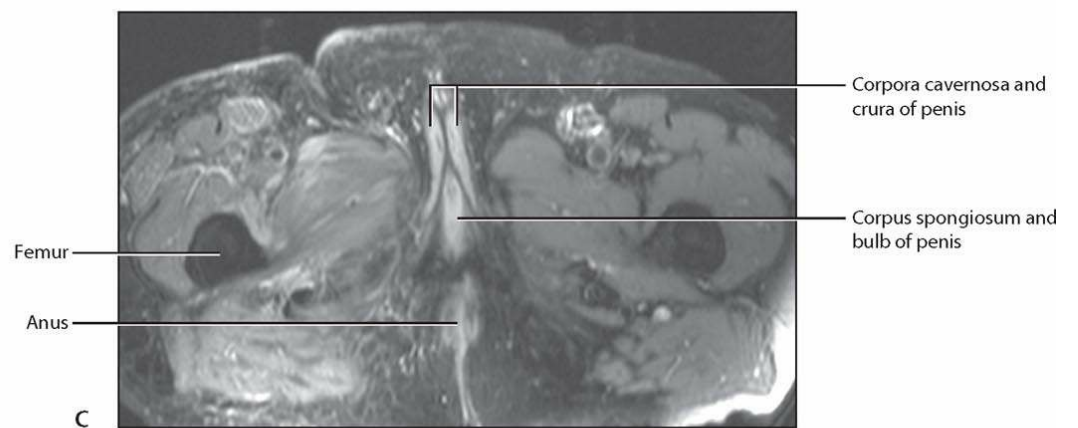
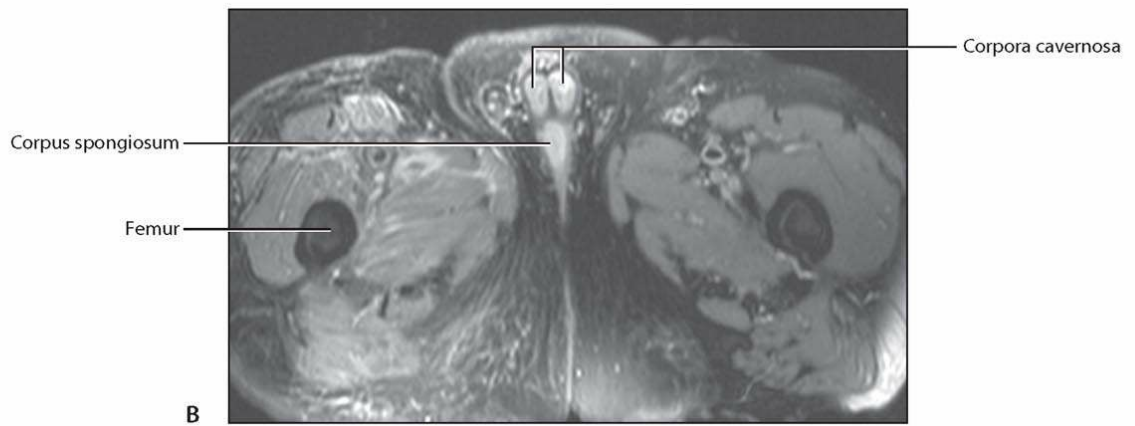
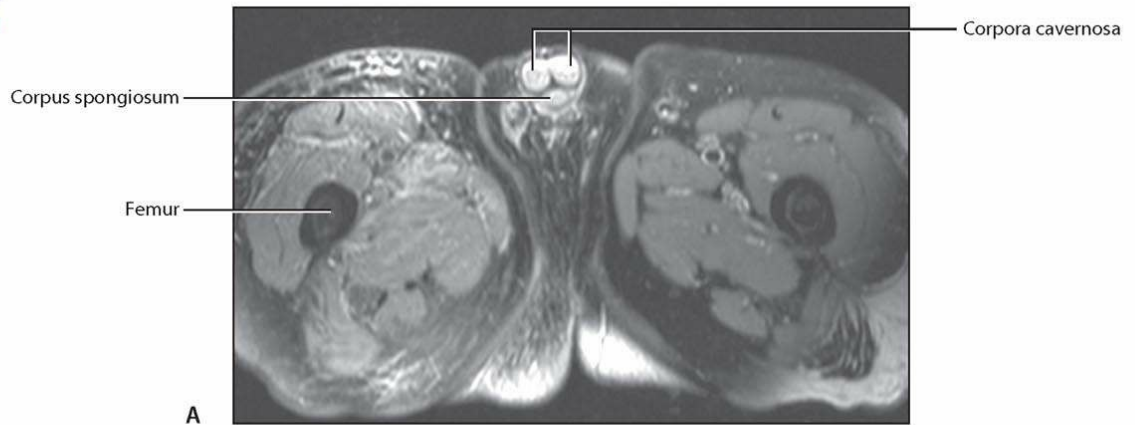
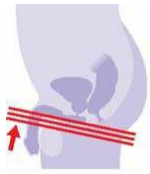**Innervation of reproductive system in women**

# Innervation of bladder

**Visceral efferent (parasympathetic and sympathetic) innervation of bladder and visceral afferent nerves**

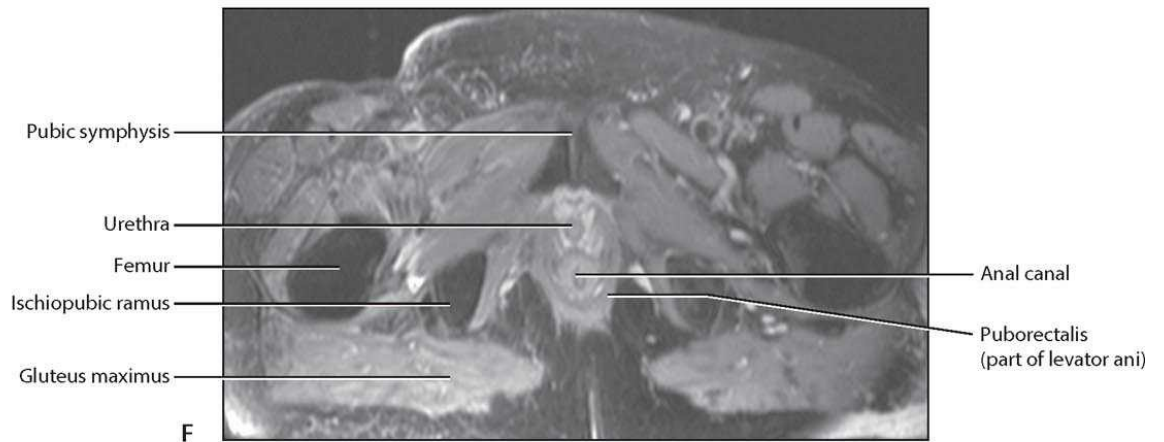
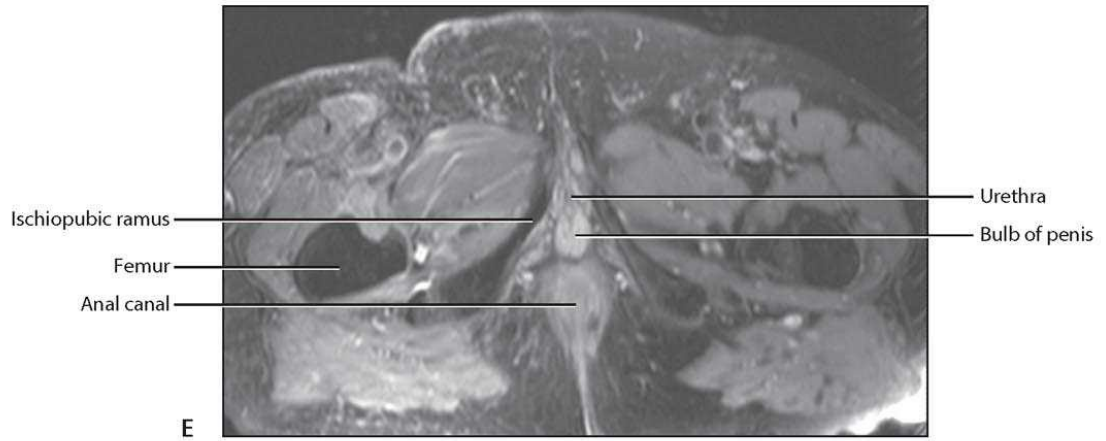
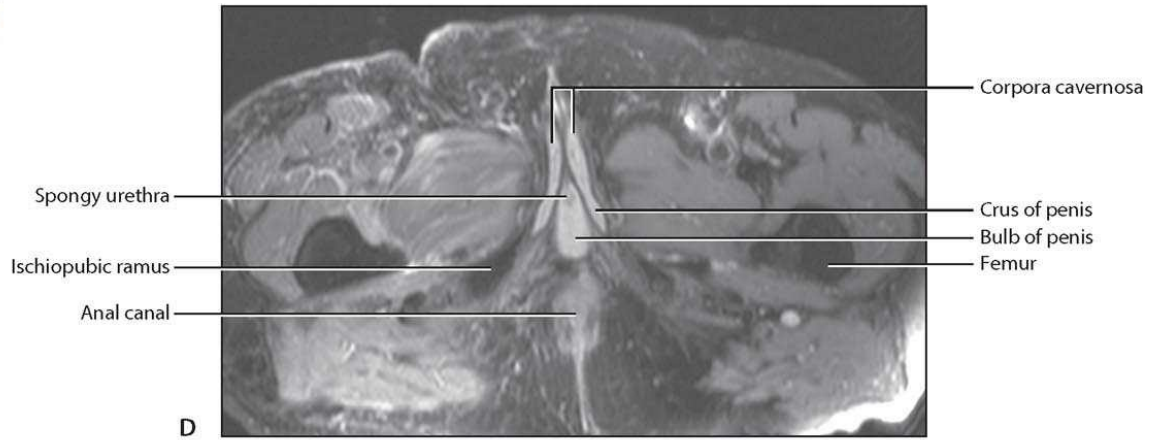
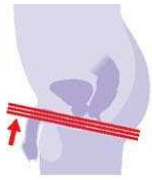


# Pelvic cavity imaging in men



**A through C – Series of axial images that pass through the pelvic cavity and perineum from inferior to superior showing the various structures and their relationships with each other.**  
T2-weighted MR images in axial plane

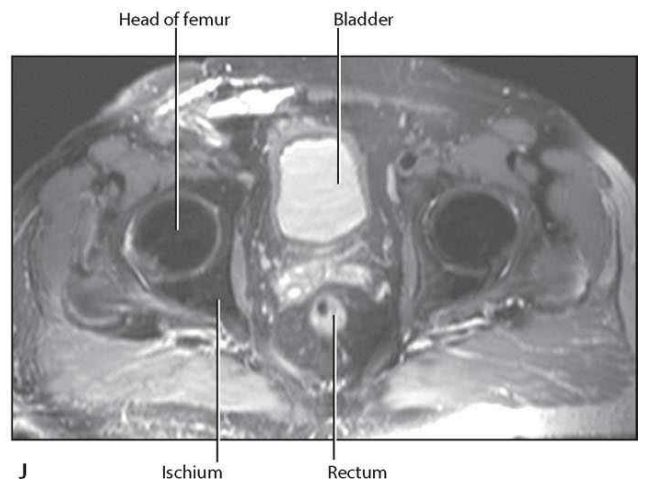
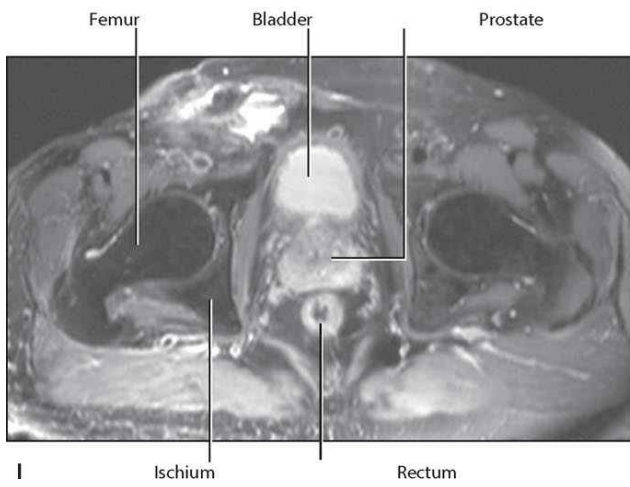
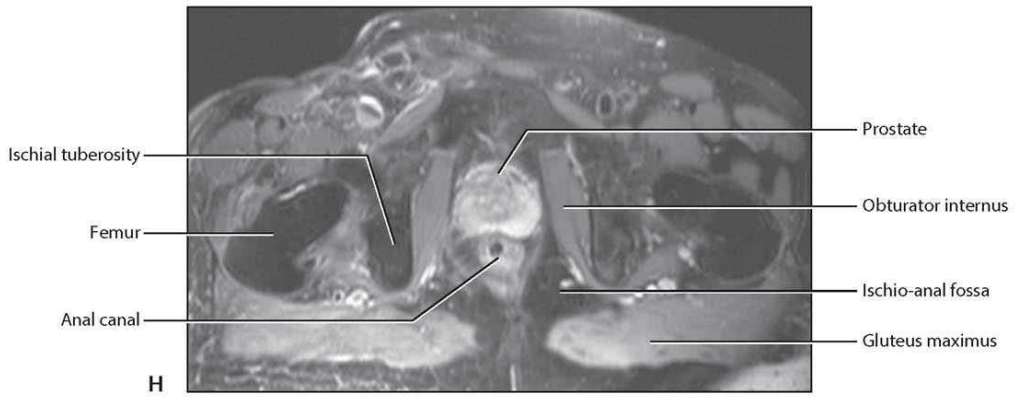
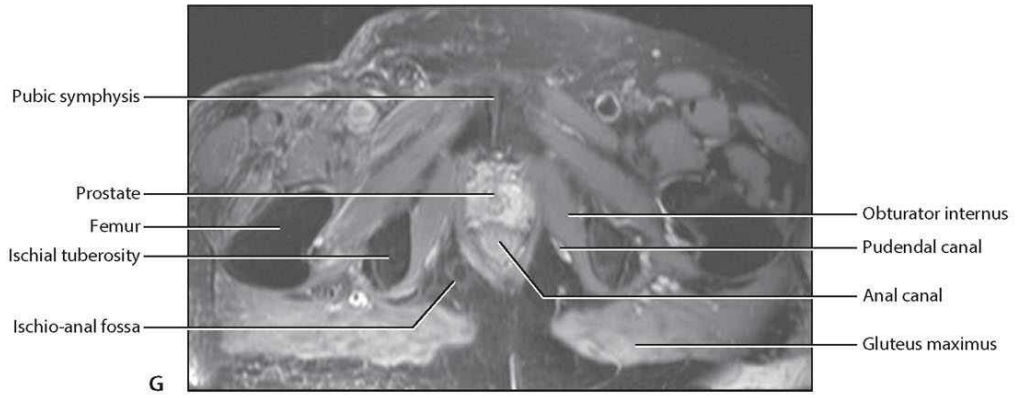
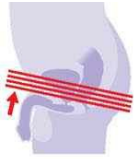



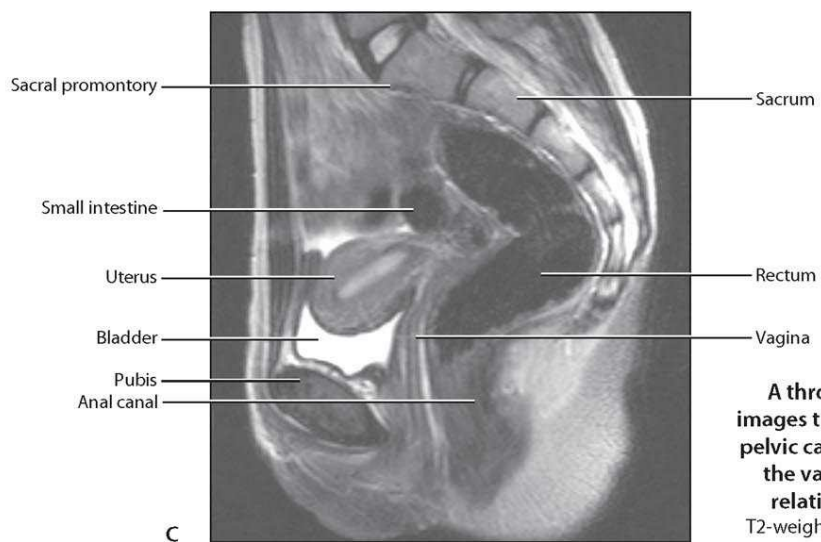
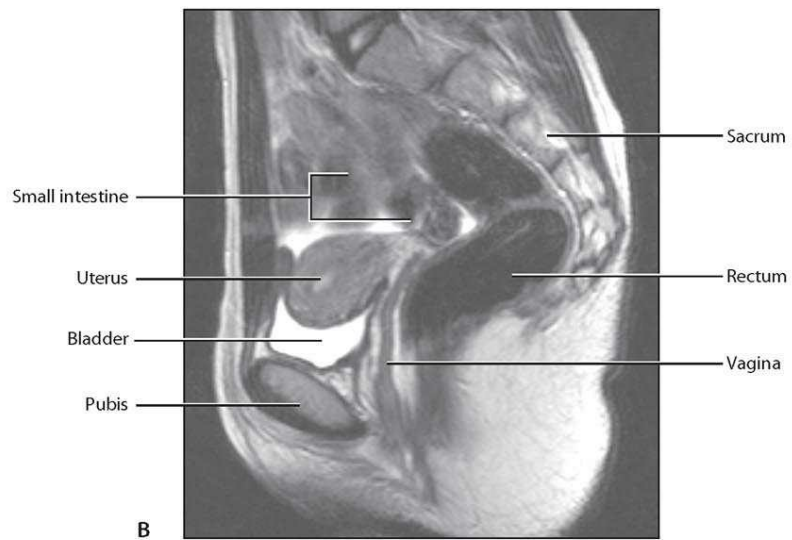
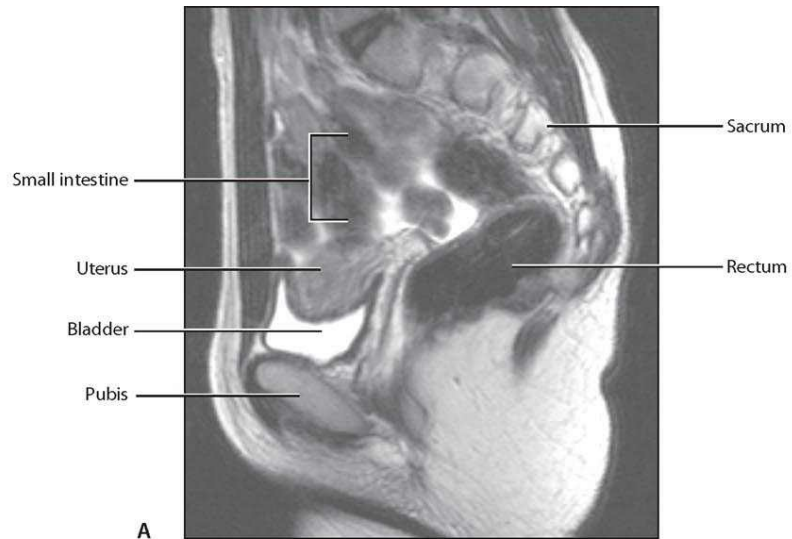
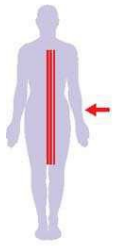
**D through J – Series of axial images that pass through the pelvic cavity and perineum from inferior to superior showing the various structures and their relationships with each other.**  
T2-weighted MR images in axial plane



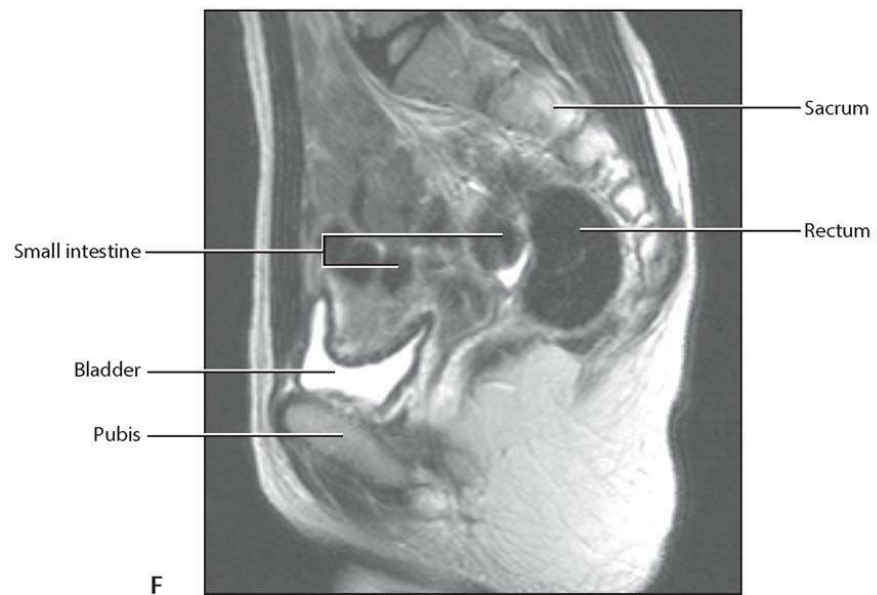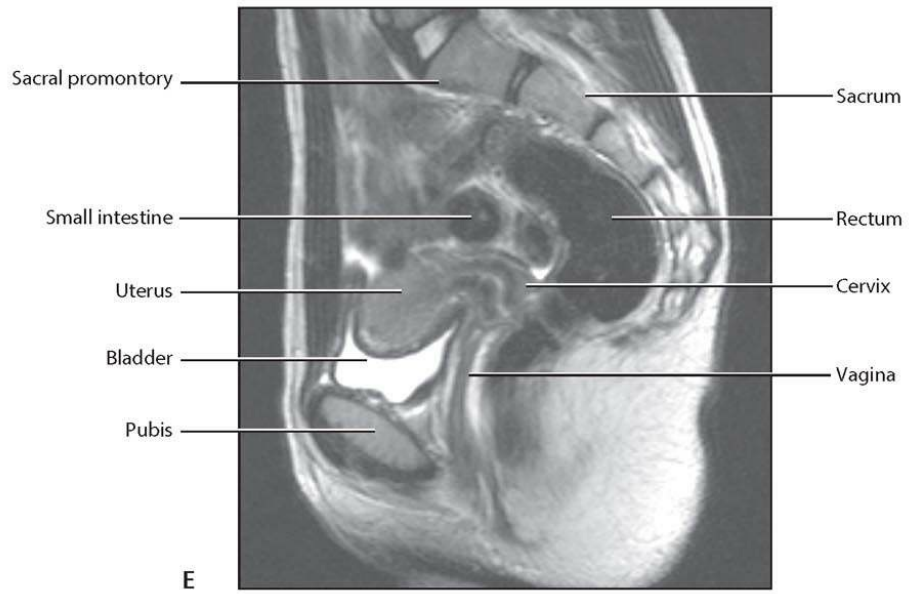
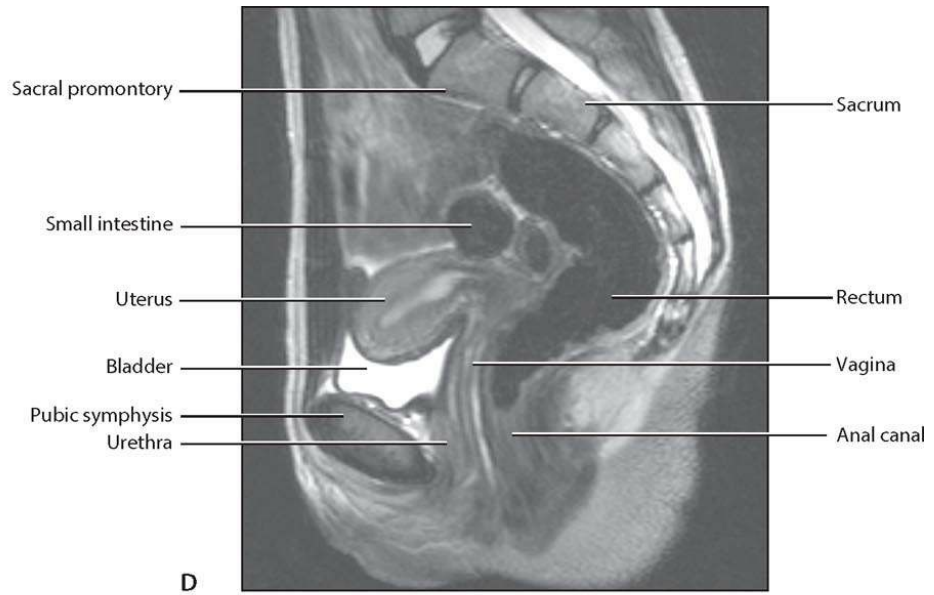
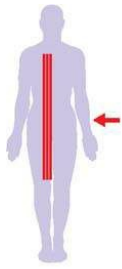




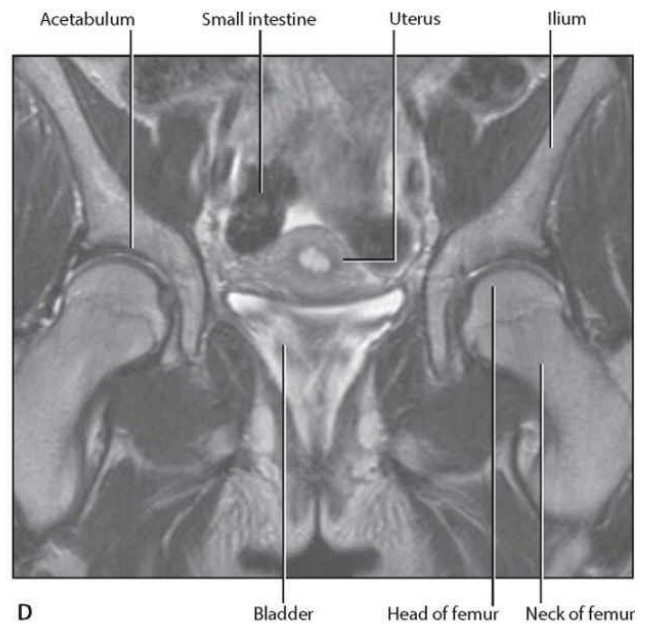
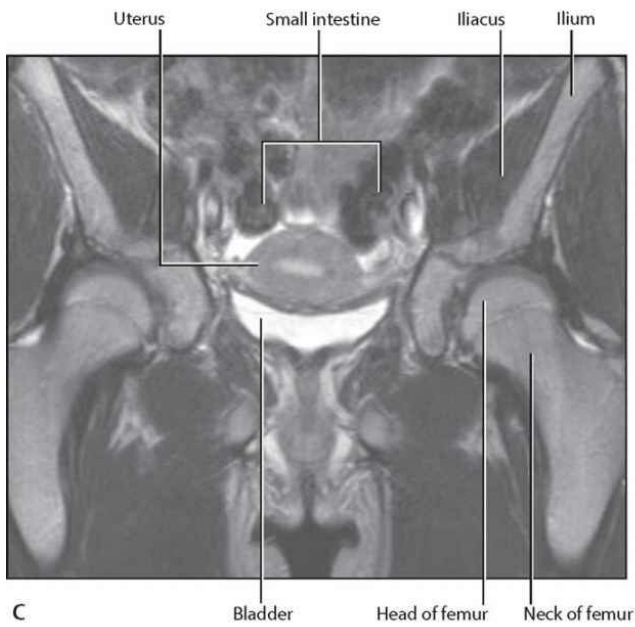
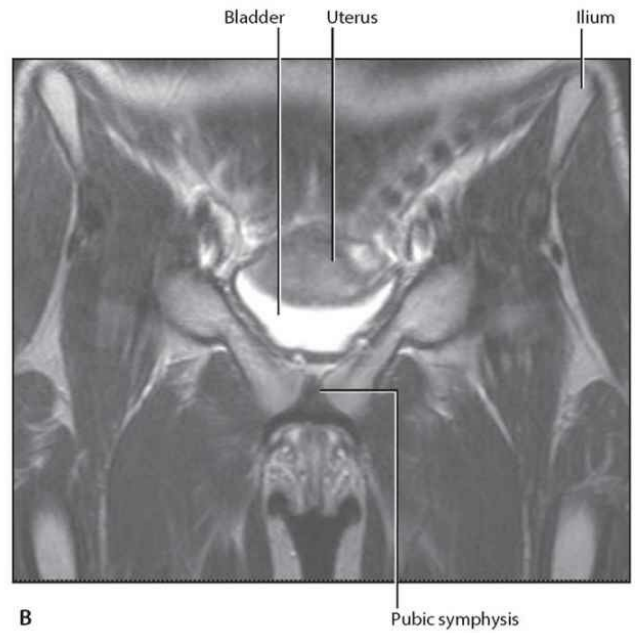
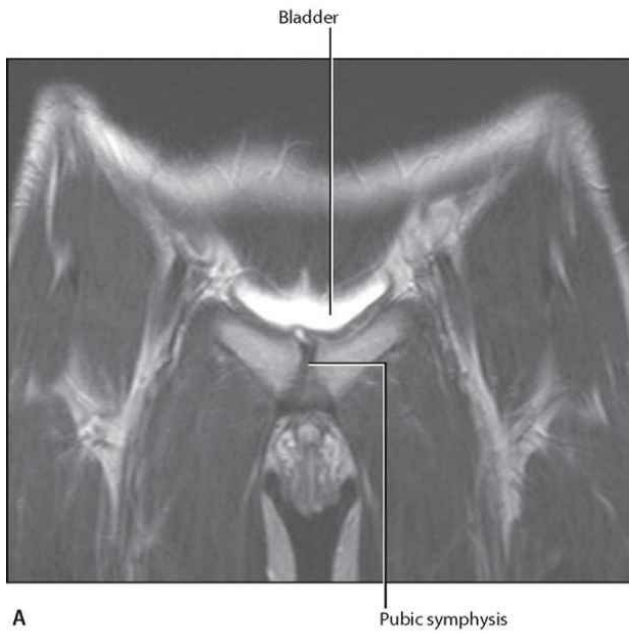
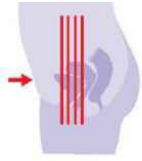
# Pelvic cavity imaging in women



**A through F – Series of sagittal images that pass through the female pelvic cavity and perineum showing the various structures and their relationships with each other. T2-weighted MR images in sagittal plane**

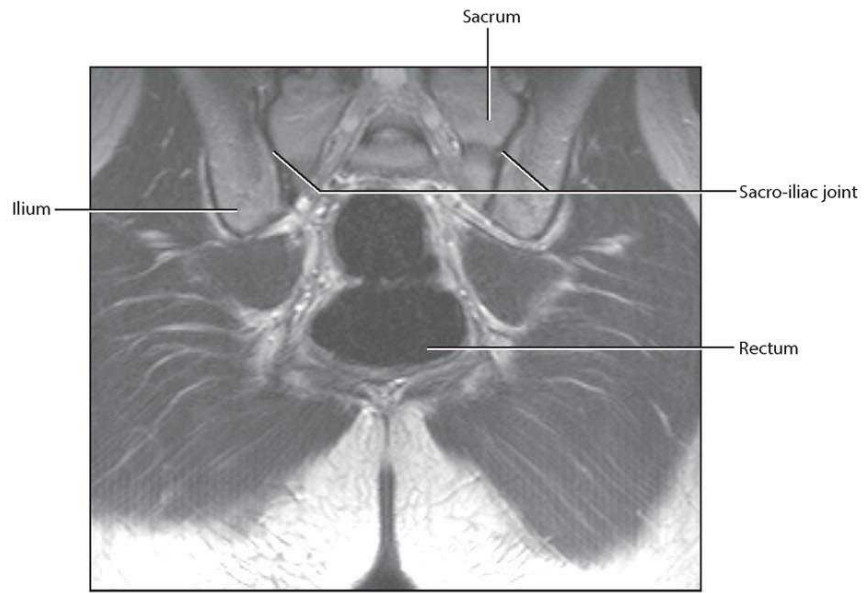
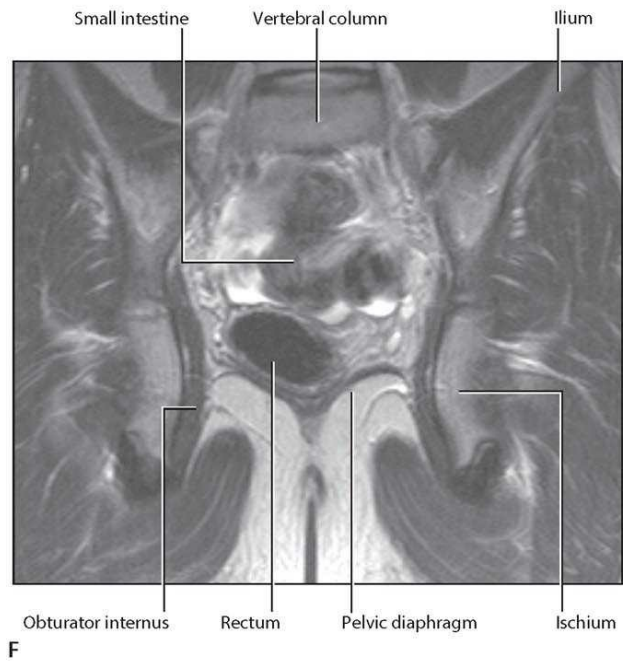
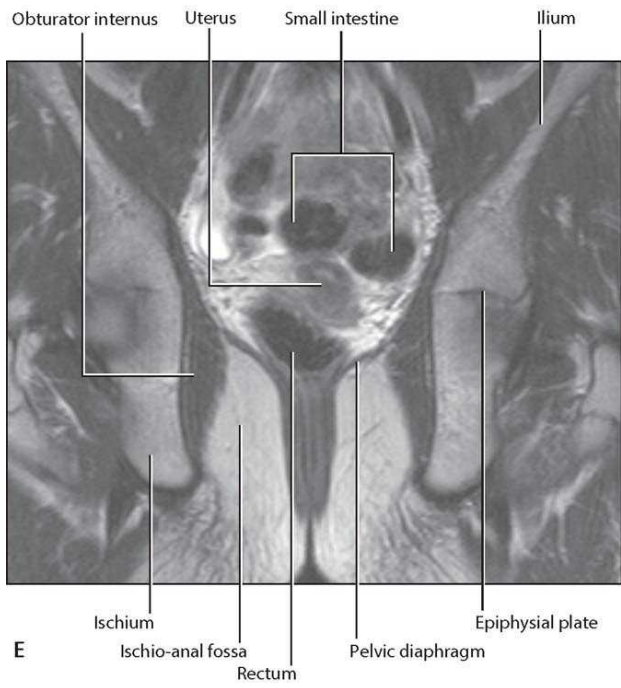
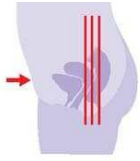




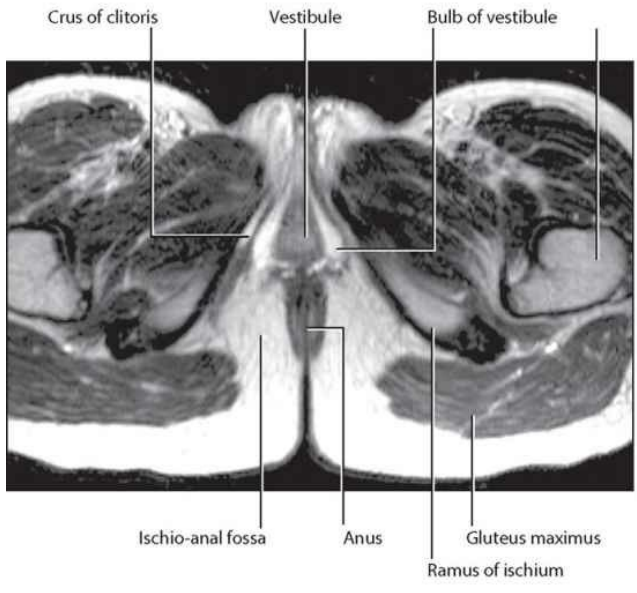
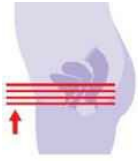


**A through G – Series of coronal images that pass through the pelvic cavity and perineum from anterior to posterior showing the various structures and their relationships with each other.**  
T2-weighted MR images in coronal plane

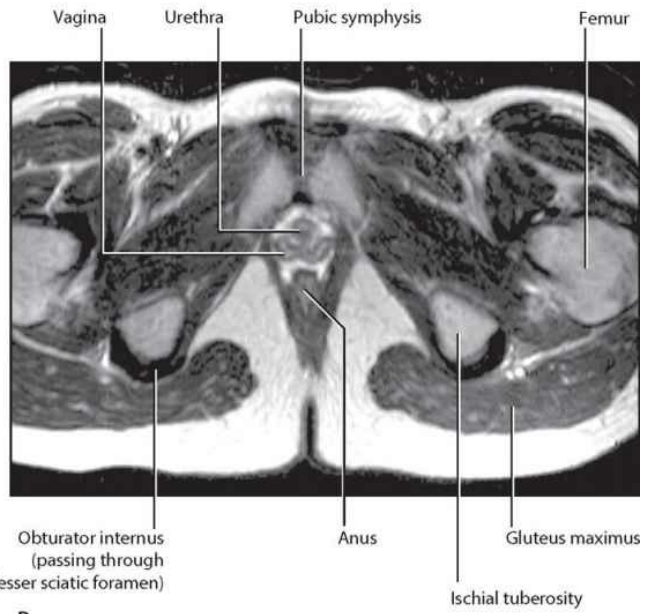




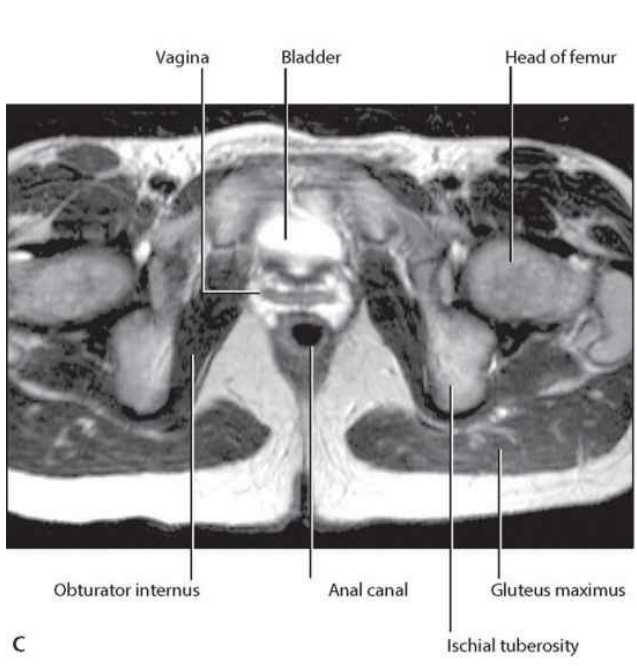




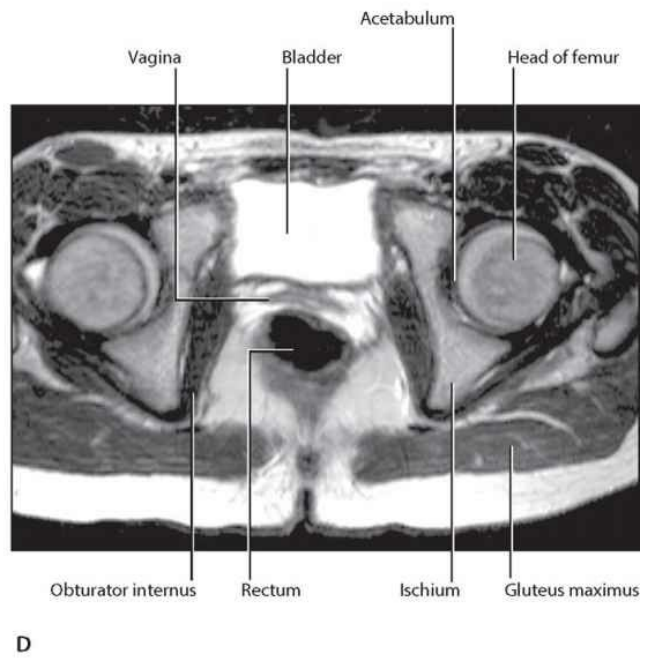
A



B



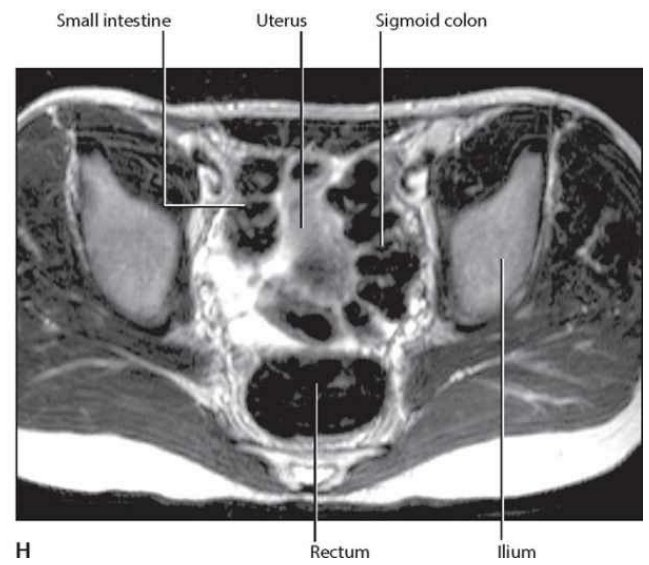
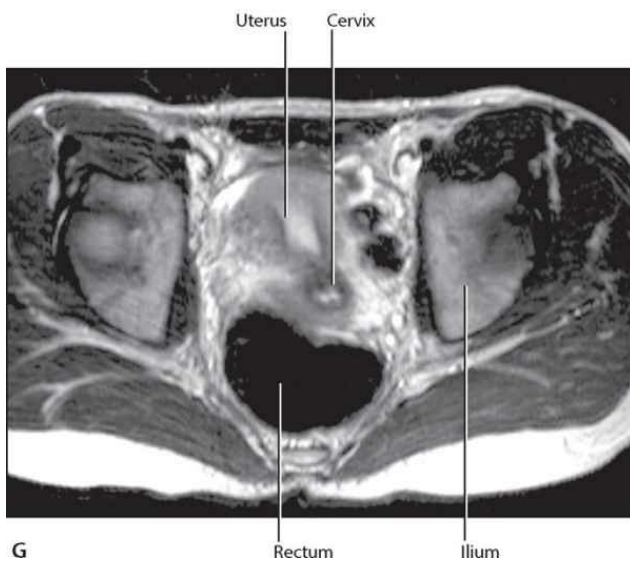
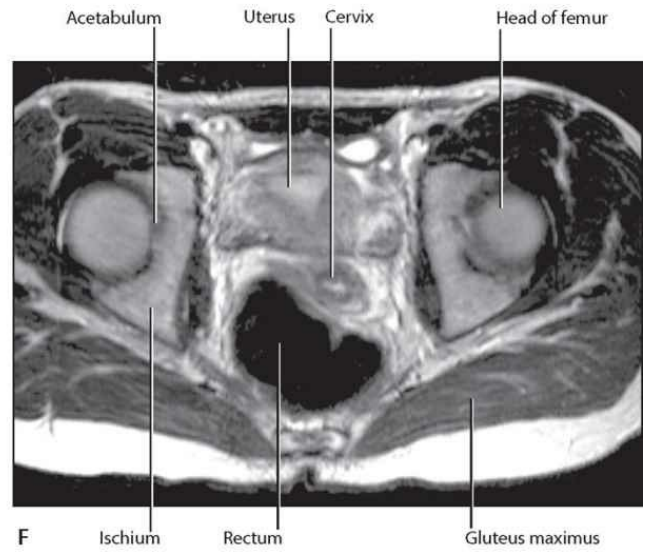
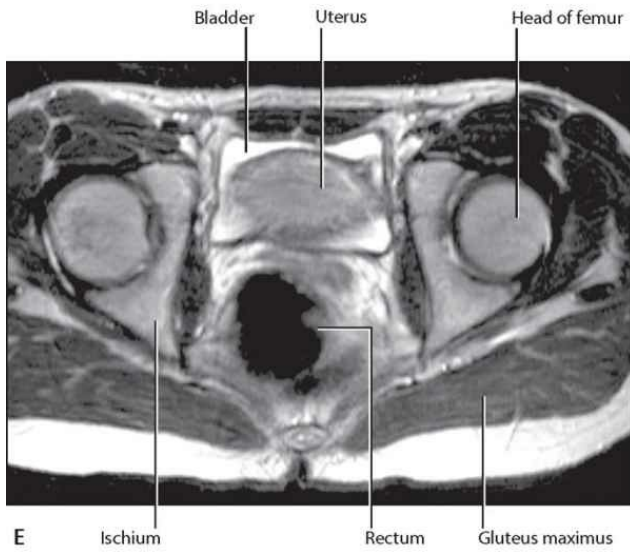
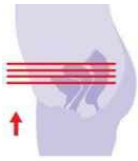C



D

A through H – Series of axial images that pass through the pelvic cavity and perineum from inferior to superior showing the various structures and their relationships with each other.  
T2-weighted MR images in axial plane





# Tables

## Branches of the sacral plexus

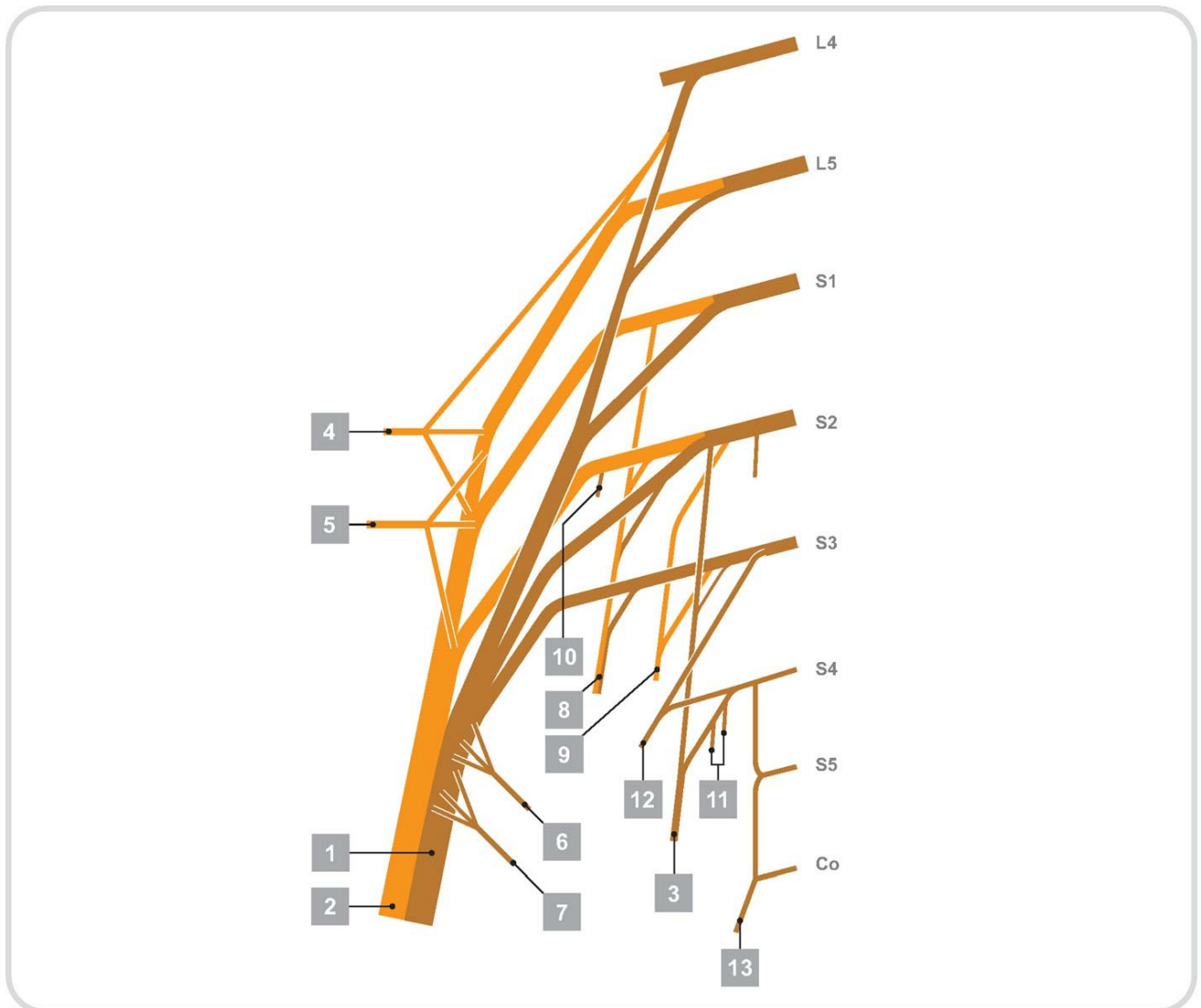
(spinal segments in parentheses do not consistently participate)

Branch		Spinal segments	Motor function	Sensory (cutaneous) function
Tibial part	1	L4 to S3	All muscles in the posterior or hamstring compartment of the thigh (including the hamstring part of the adductor magnus) except for the short head of the biceps All muscles in the posterior compartment of the leg All muscles in the sole of the foot	Skin on posterolateral and lateral surfaces of foot and sole of foot
Common fibular part	2	L4 to S2	Short head of biceps in the posterior compartment of the thigh All muscles in the anterior and lateral compartments of the leg Extensor digitorum brevis in the foot (also contributes to the supply of the first dorsal interosseous muscle)	Skin on the anterolateral surface of the leg and dorsal surface of the foot
Pudendal	3	S2 to S4	Skeletal muscles in the perineum including the external urethral and anal sphincters and levator ani (overlaps in supply of the levator ani and external sphincter with branches directly from ventral division of S4)	Most skin of the perineum. Penis and clitoris
Superior gluteal	4	L4 to S1	Gluteus medius, gluteus minimus, and tensor fasciae latae	
Inferior gluteal	5	L5 to S2	Gluteus maximus	
Nerve to obturator internus and superior gemellus	6	L5 to S2	Obturator internus and superior gemellus	
Nerve to quadratus femoris and inferior gemellus	7	L4 to S1	Quadratus femoris and inferior gemellus	
Posterior femoral cutaneous (posterior cutaneous nerve of thigh)	8	S1, S3		Skin on the posterior aspect of the thigh
Perforating cutaneous	9	S2, S3		Skin over gluteal fold (overlaps with posterior femoral cutaneous)
Nerve to piriformis	10	(L5), S1, S2	Piriformis muscle	
Nerves to levator ani, coccygeus, and external anal sphincter	11	S4	Levator ani, coccygeus, and external anal sphincter. (Overlaps with pudendal nerve)	Small patch of skin between anus and coccyx
Pelvic splanchnic nerves	12	S2, S3 (4)	Visceral motor (preganglionic parasympathetic) to pelvic part of prevertebral plexus Stimulate erection, modulate mobility in gastrointestinal system distal to the left colic flexure, inhibitory to internal urethral sphincter	Visceral afferents from pelvic viscera and distal parts of colon. Pain from cervix and possibly from bladder and proximal urethra

## Branches of the coccygeal plexus

Anococcygeal nerves	13	S4 to Co	Perianal skin	
---------------------	----	----------	---------------	--





## Muscles of the pelvic walls

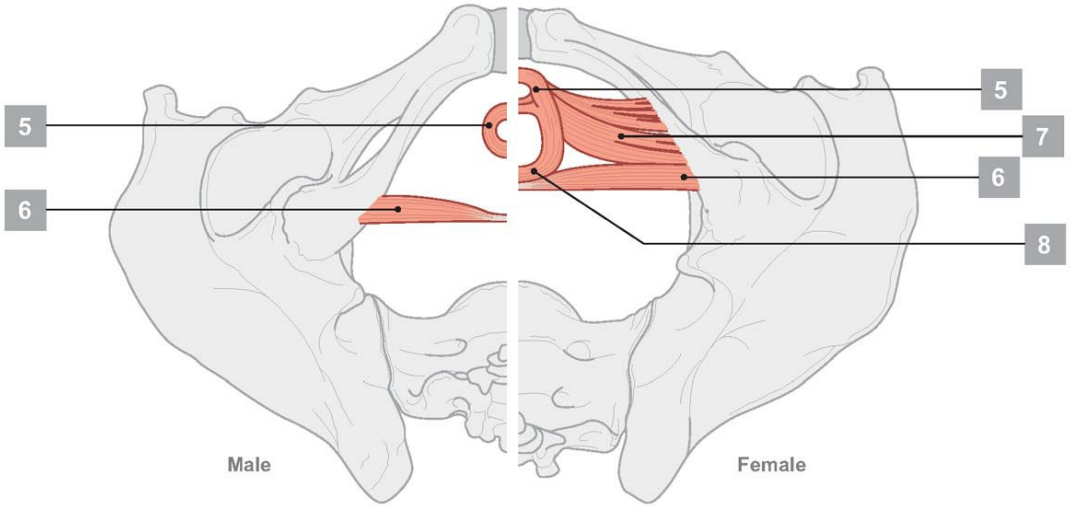
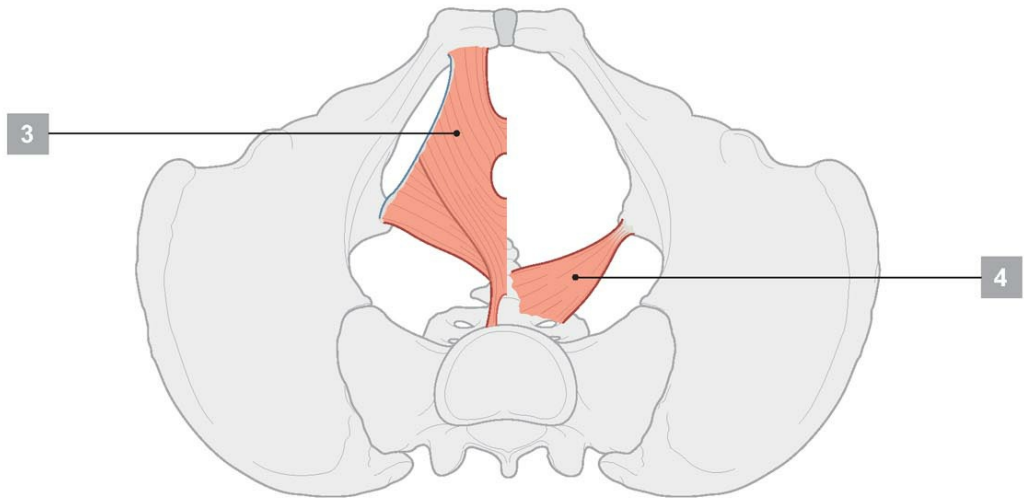
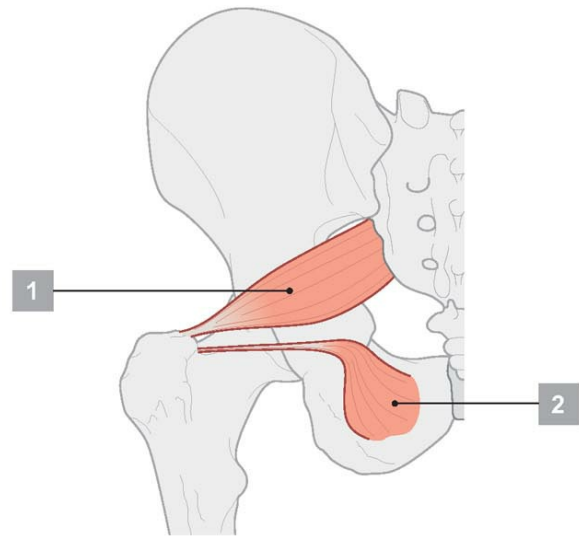
Muscle		Origin	Insertion	Innervation	Function
<b>Obturator internus</b>	1	Anterolateral wall of true pelvis (deep surface of obturator membrane and surrounding bone)	Medial surface of greater trochanter of femur	Nerve to obturator internus L5, S1	Lateral rotation of the extended hip joint; abduction of flexed hip
<b>Piriformis</b>	2	Anterior surface of sacrum between anterior sacral foramina	Medial side of superior border of greater trochanter of femur	Branches from L5, S1, and S2	Lateral rotation of the extended hip joint; abduction of flexed hip

## Muscles of the pelvic diaphragm

<b>Levator ani</b>	3	In a line around the pelvic wall beginning on the posterior aspect of the pubic bone and extending across the obturator internus muscle as a tendinous arch (thickening of the obturator internus fascia) to the ischial spine	The anterior part is attached to the superior surface of the perineal membrane; the posterior part meets its partner on the other side at the perineal body, around the anal canal, and along the anococcygeal ligament	Branches direct from the anterior ramus of S4, and by the inferior rectal branch of the pudendal nerve (S2 to S4)	Contributes to the formation of the pelvic floor, which supports the pelvic viscera; maintains an angle between the rectum and anal canal. Reinforces the external anal sphincter and, in women, functions as a vaginal sphincter
<b>Coccygeus</b>	4	Ischial spine and pelvic surface of the sacrospinous ligament	Lateral margin of coccyx and related border of sacrum	Branches from the anterior rami of S3 and S4	Contributes to the formation of the pelvic floor, which supports the pelvic viscera; pulls coccyx forward after defecation

## Muscles within the deep perineal pouch

<b>External urethral sphincter</b>	5	From the inferior ramus of the pubis on each side and adjacent walls of the deep perineal pouch	Surrounds membranous part of urethra	Perineal branches of the pudendal nerve (S2 to S4)	Compresses the membranous urethra; relaxes during micturition
<b>Deep transverse perineal</b>	6	Medial aspect of ischial ramus	Perineal body	Perineal branches of the pudendal nerve (S2 to S4)	Stabilizes the position of the perineal body
<b>Compressor urethrae (in women only)</b>	7	Ischiopubic ramus on each side	Blends with partner on other side anterior to the urethra	Perineal branches of the pudendal nerve (S2 to S4)	Functions as an accessory sphincter of the urethra
<b>Sphincter urethrovaginalis (in women only)</b>	8	Perineal body	Passes forward lateral to the vagina to blend with partner on other side anterior to the urethra	Perineal branches of the pudendal nerve (S2 to S4)	Functions as an accessory sphincter of the urethra (also may facilitate closing the vagina)



Male

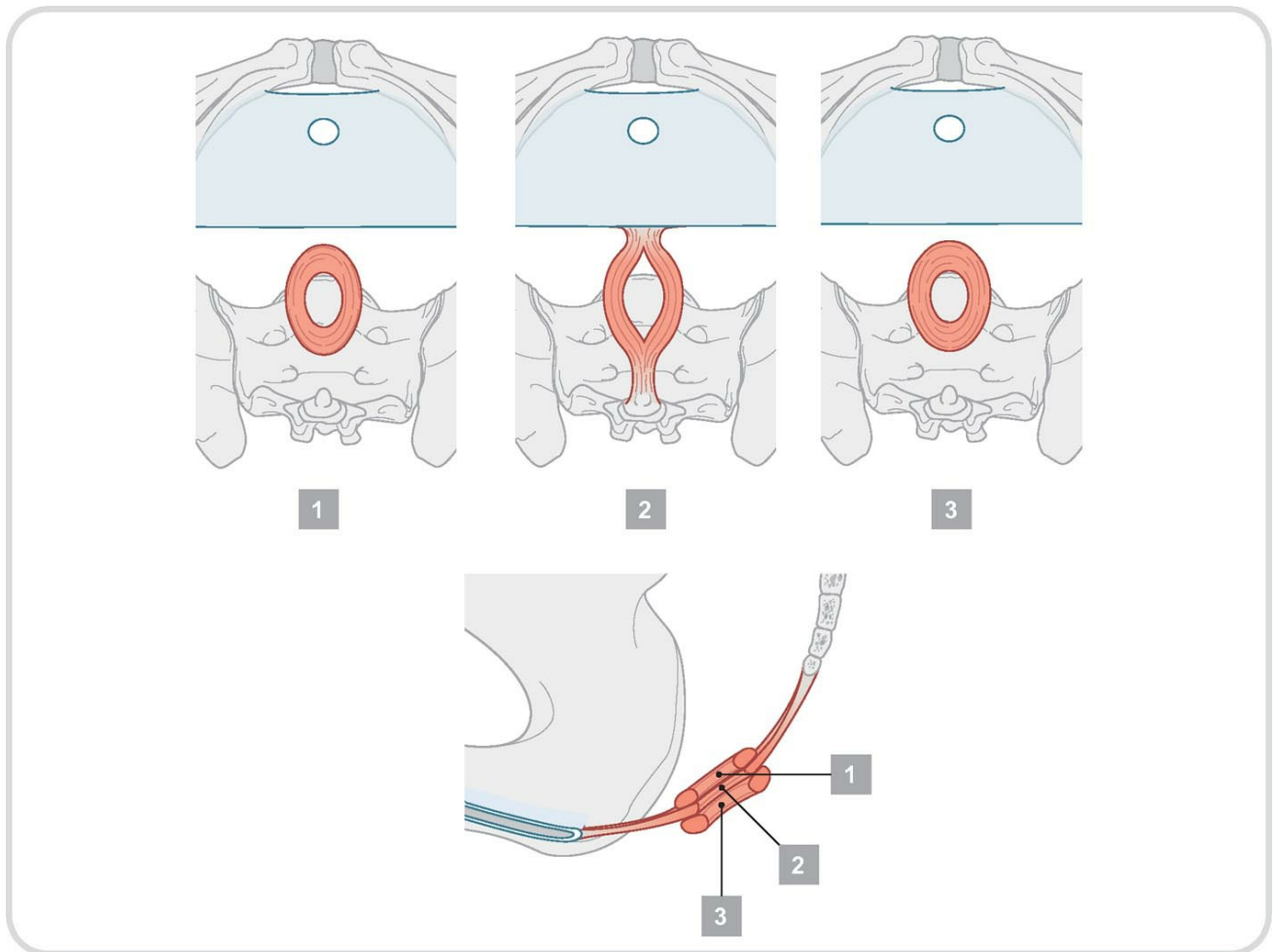
Female



## Muscles of the anal triangle

---

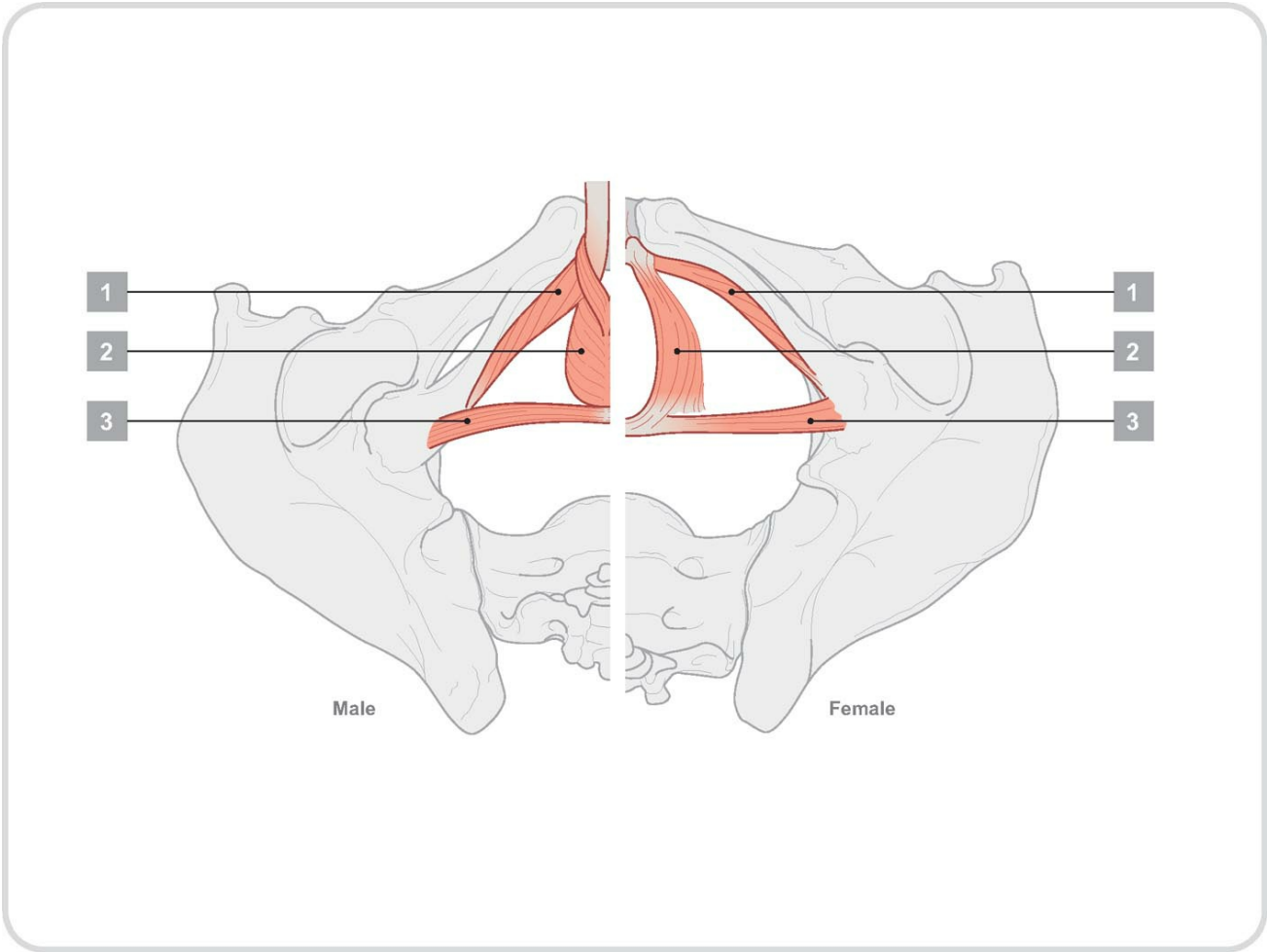
Muscle		Origin	Insertion	Innervation	Function
<b>EXTERNAL ANAL SPHINCTER</b> Deep part	1	Surrounds superior aspect of anal canal		Pudendal nerve (S2 and S3) and branches directly from S4	Closes anal canal
<b>Superficial part</b>	2	Surrounds lower part of anal canal	Anchored to perineal body and an coccygeal body		
<b>Subcutaneous part</b>	3	Surrounds anal aperture			



## Muscles of the superficial perineal pouch

Muscle		Origin	Insertion	Innervation	Function
<b>Ischiocavernosus</b>	1	Ischial tuberosity and ramus	Crus of penis and clitoris	Pudendal nerve (S2 to S4)	Move blood from crura into the body of the erect penis and clitoris
<b>Bulbospongiosus</b>	2	In women: perineal body In men: perineal body, midline raphe	In women: bulb of vestibule, perineal membrane, body of clitoris, and corpus cavernosum In men: bulbospongiosus, perineal membrane, corpus cavernosum	Pudendal nerve (S2 to S4)	Move blood from attached parts of the clitoris and penis into the glans In men: removal of residual urine from urethra after urination; pulsatile emission of semen during ejaculation
<b>Superficial transverse perineal</b>	3	Ischial tuberosity and ramus	Perineal body	Pudendal nerve (S2 to S4)	Stabilize the perineal body





1

2

3

Male

1

2

3

Female



# LOWER LIMB

---

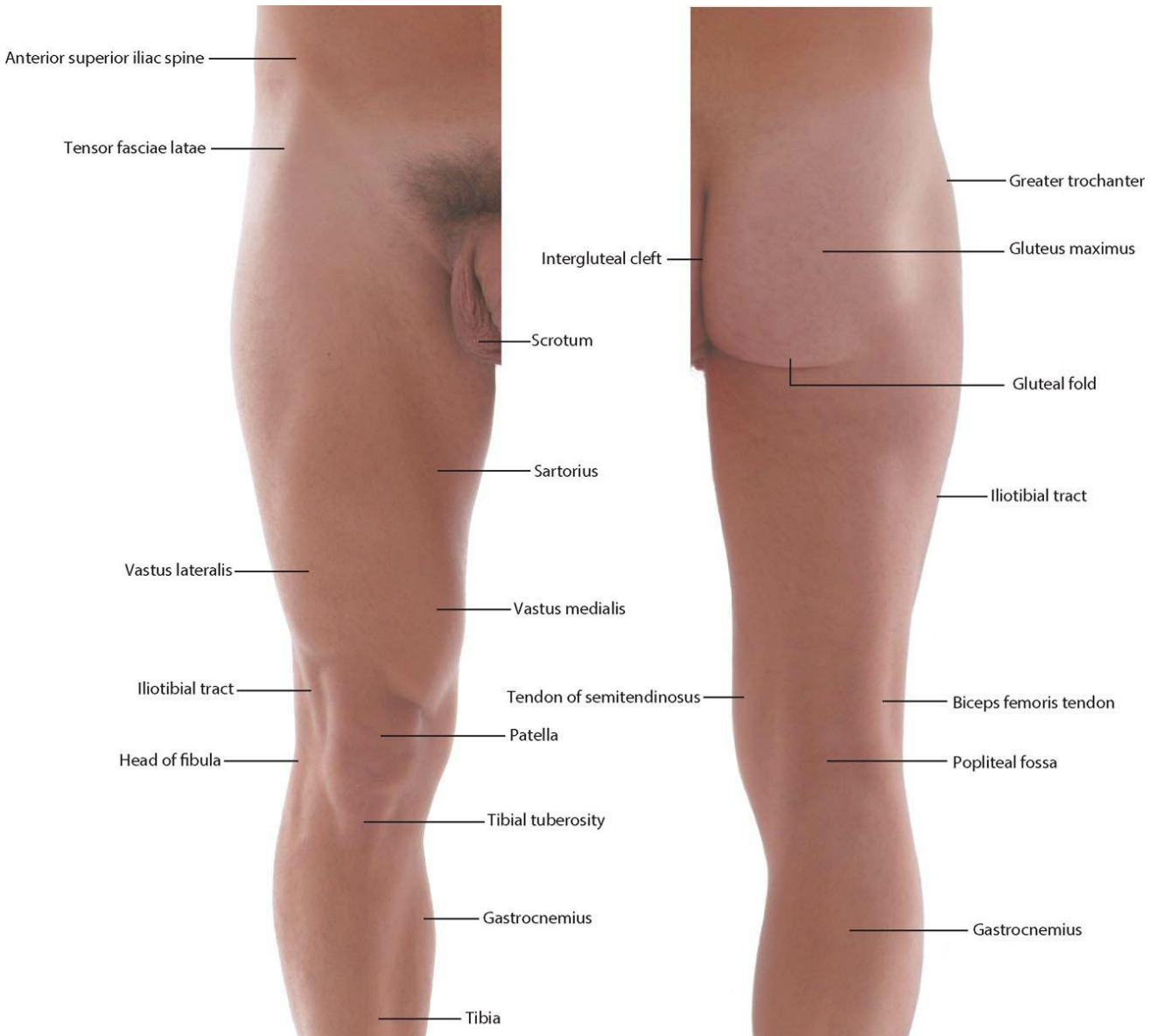# CONTENTS

Surface anatomy	294
Bones of the lower limb	295
Pelvic bones and sacrum	296
Articulated pelvis	297
Proximal femur	298
Hip joint	299
Hip joint: structure and arterial supply	301
Gluteal region: attachments and superficial musculature	302
Gluteal region: superficial and deep muscles	303
Gluteal region: arteries and nerves	304
Distal femur and proximal tibia and fibula	306
Thigh: muscle attachments	307
Thigh: anterior superficial musculature	308
Thigh: posterior superficial musculature	309
Thigh: anterior compartment muscles	310
Thigh: medial compartment muscles	311
Femoral triangle	312
Anterior thigh: arteries and nerves	313
Anterior thigh: arteries	314
Thigh: posterior compartment muscles	315
Posterior thigh: arteries and nerves	316
Transverse sections: thigh	318
Knee joint	320
Ligaments of the knee	322
Menisci and cruciate ligaments	324
Knee: bursa and capsule	328
Knee surface: muscles, capsule, and arteries	329
Popliteal fossa	330
Tibia and fibula	331

Bones of the foot **332**  
Bones and joints of the foot **335**  
Talus and calcaneus **336**  
Ankle joint **337**  
Ligaments of the ankle joint **338**  
Leg: muscle attachments **341**  
Posterior leg: superficial muscles **342**  
Posterior compartment: deep muscles **343**  
Posterior leg: arteries and nerves **344**  
Lateral compartment: muscles **345**  
Anterior leg: superficial muscles **346**  
Anterior compartment: muscles **347**  
Anterior leg: arteries and nerves **348**  
Leg: cutaneous nerves **349**  
Transverse sections: leg **350**  
Foot: muscle attachments **352**  
Foot: ligaments **353**  
Dorsum of foot **355**  
Dorsum of foot: arteries and nerves **356**  
Plantar aponeurosis **358**  
Plantar region (sole) musculature: first layer **359**  
Plantar region (sole) musculature: second layer **360**  
Plantar region (sole) musculature: third layer **361**  
Plantar region (sole) musculature: fourth layer **362**  
Plantar region (sole): arteries and nerves **363**  
Dorsal hood and tarsal tunnel **365**  
Superficial veins of the lower limb **366**  
Lymphatics of the lower limb **367**  
Anterior cutaneous nerves and dermatomes of the lower limb **368**  
Posterior cutaneous nerves and dermatomes of the lower limb **369**  
Tables **370**

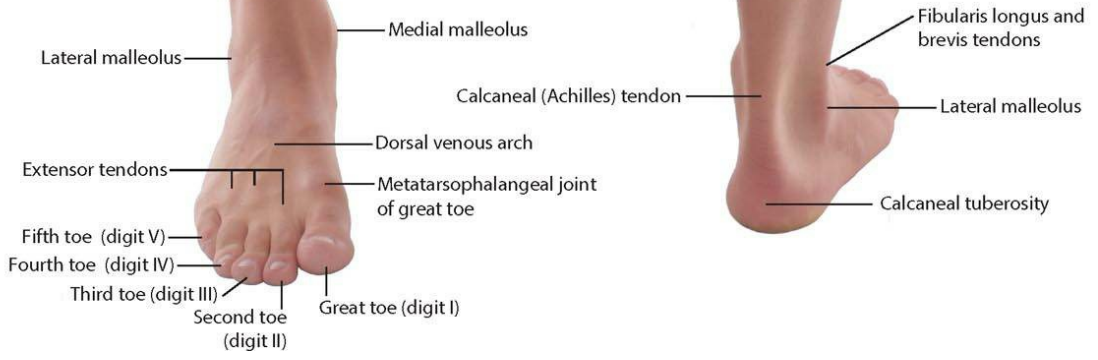


# Surface anatomy

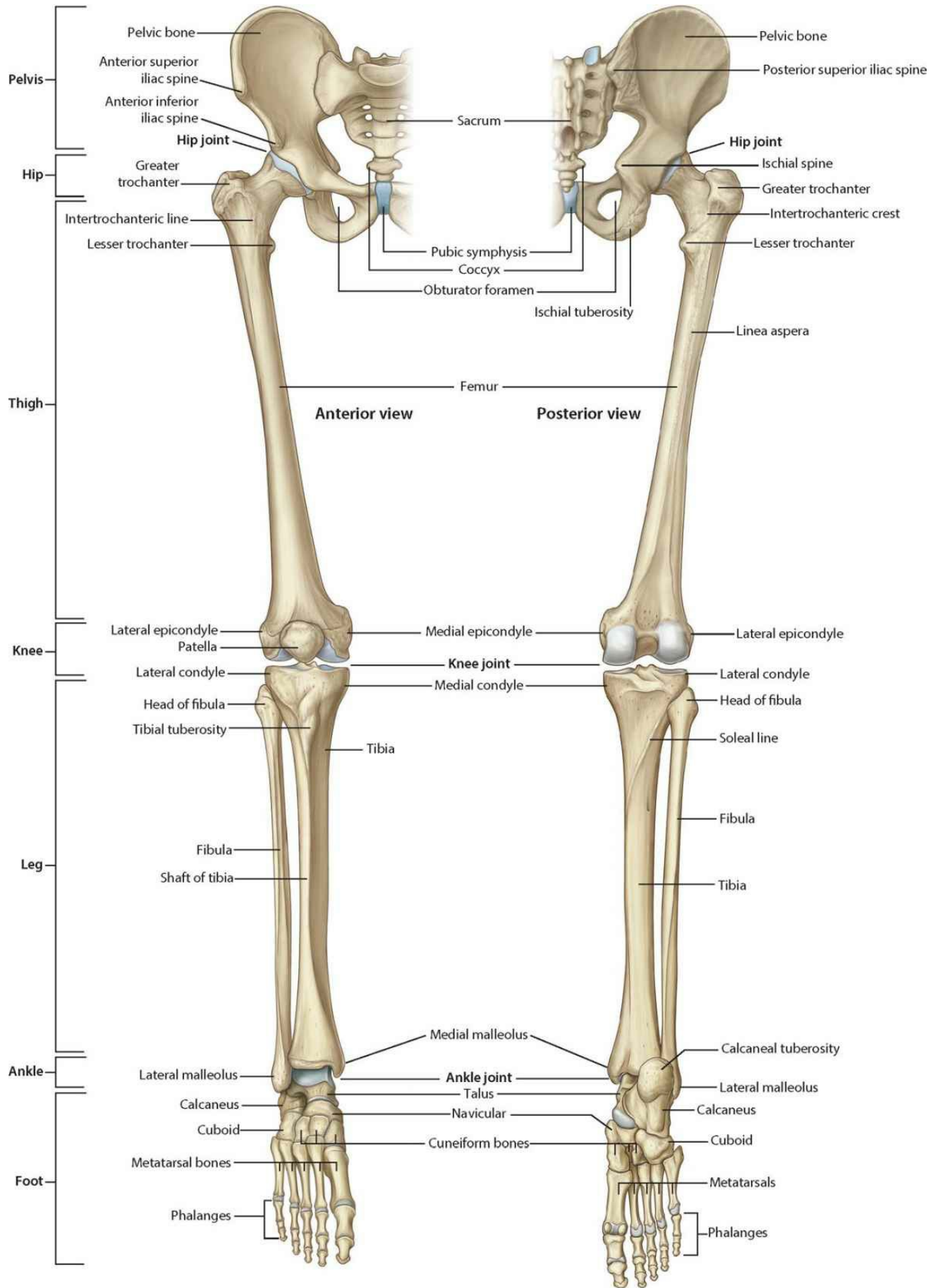


**Anterior view**

**Posterior view**

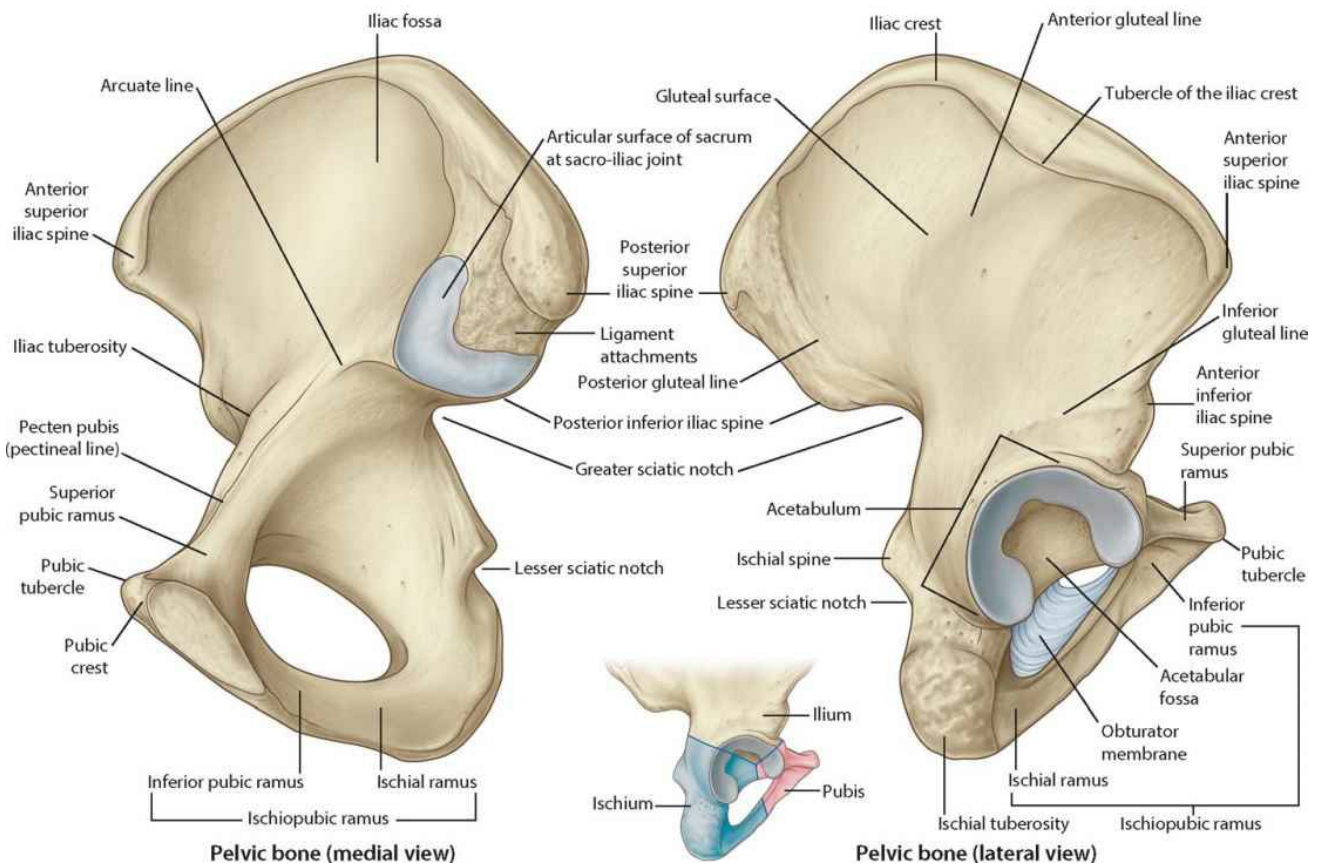
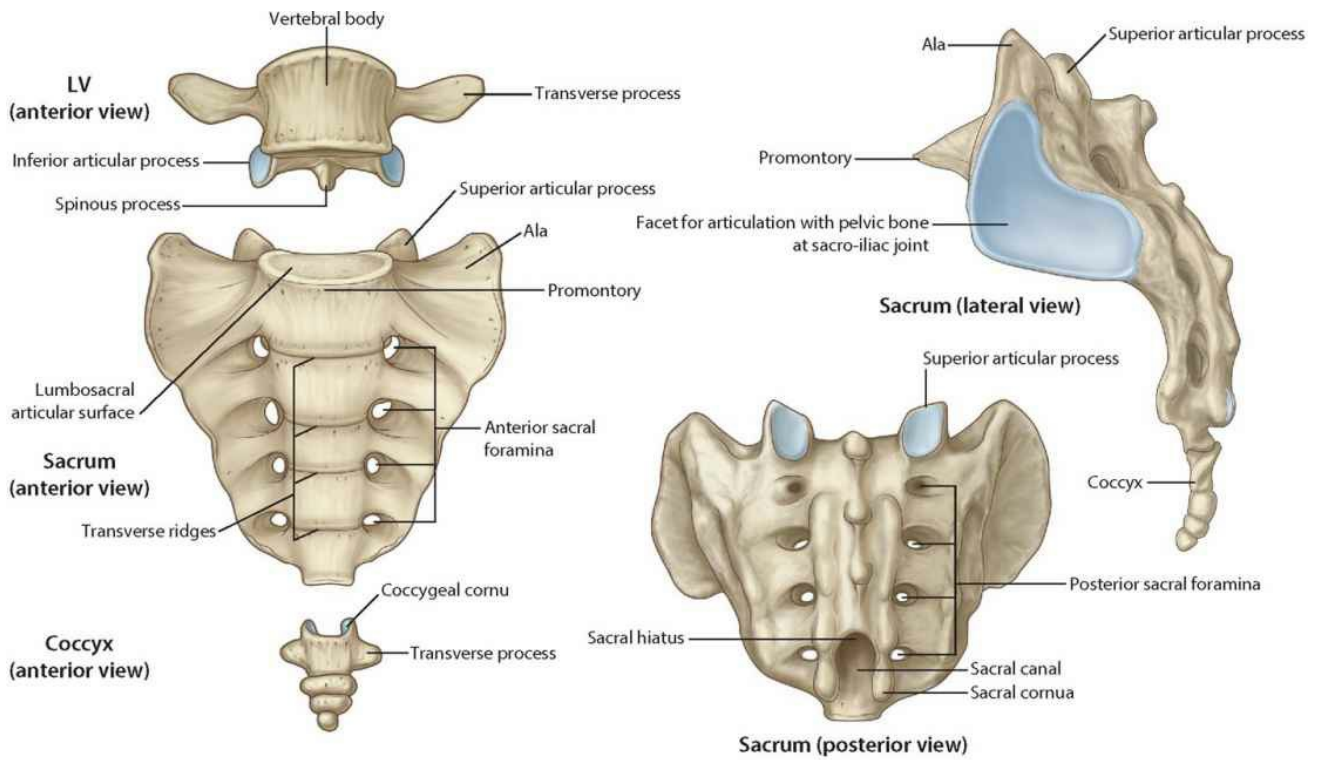


# Bones of the lower limb



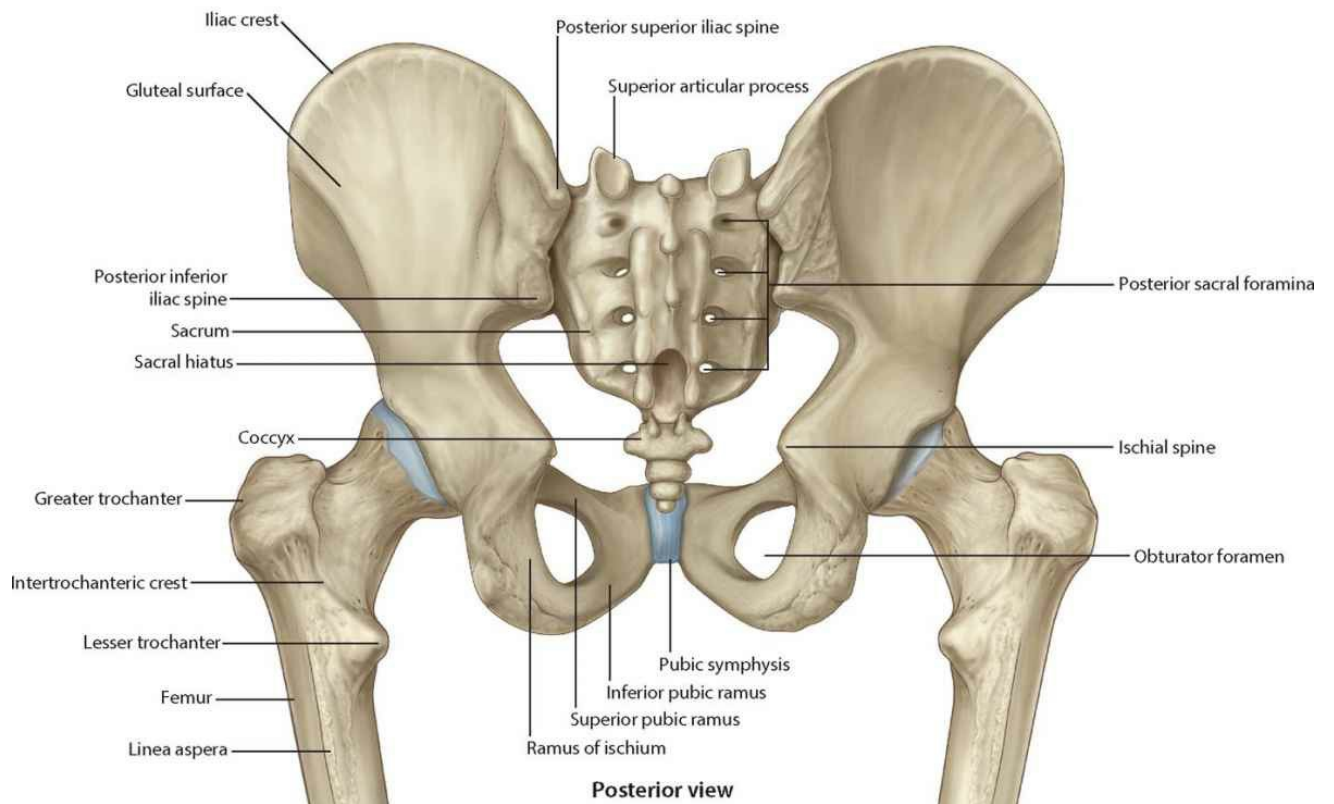
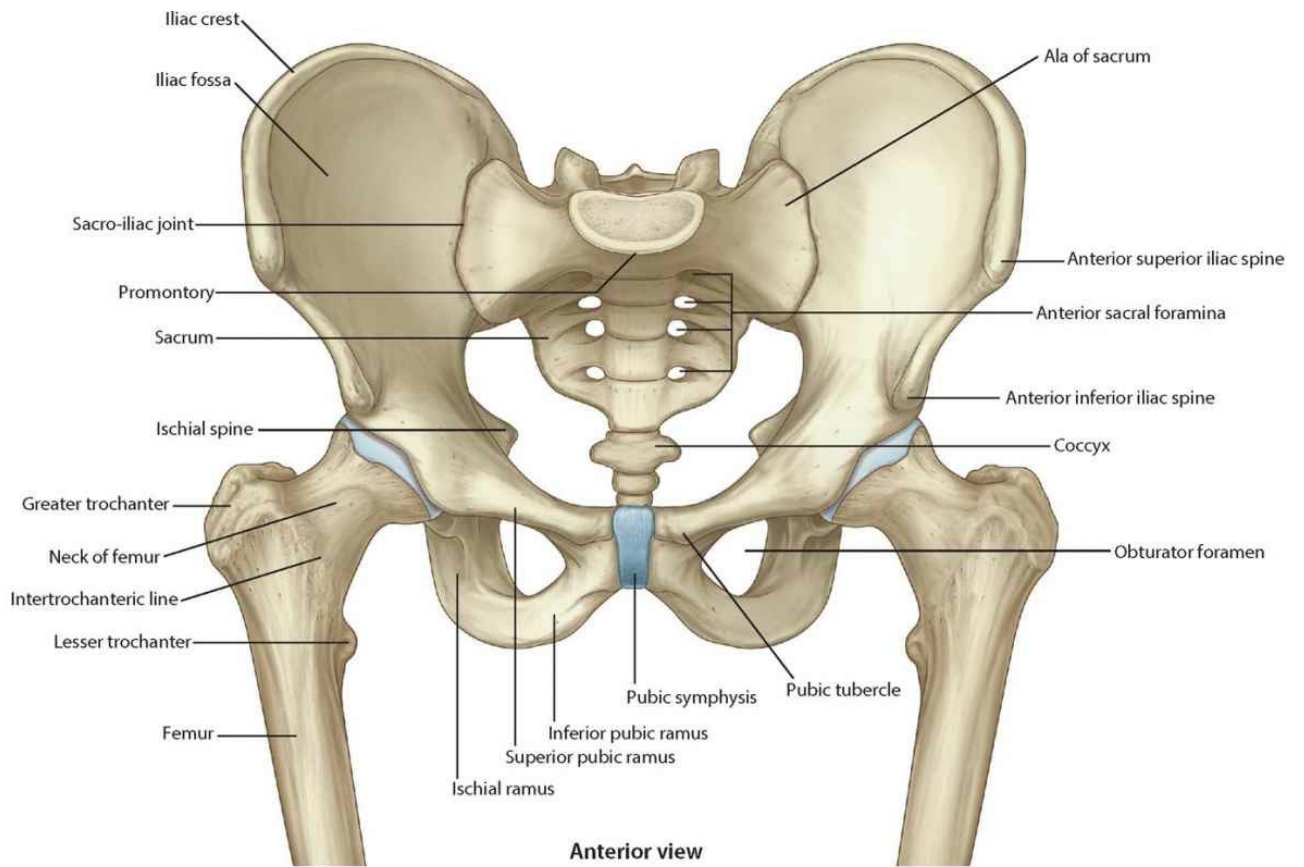


# Pelvic bones and sacrum

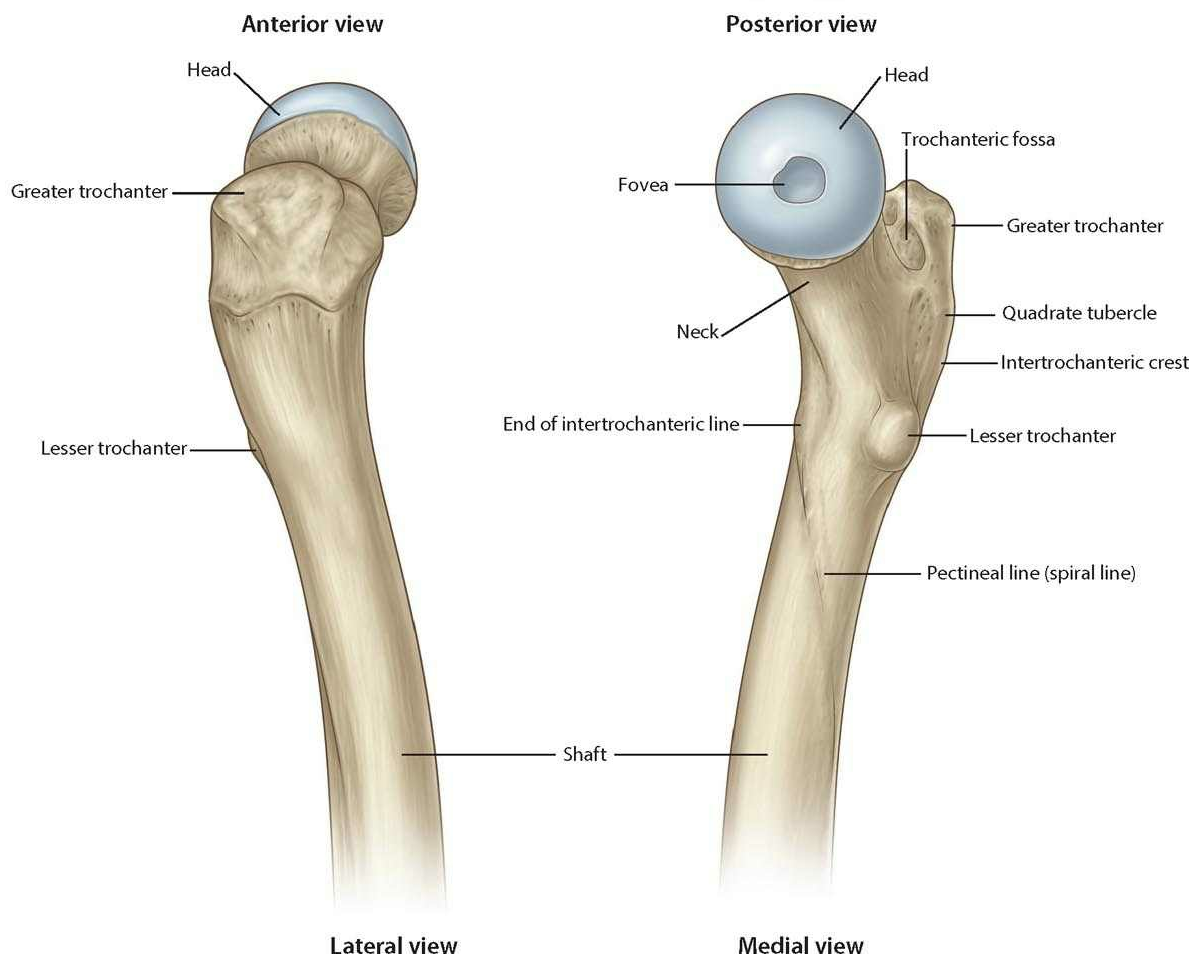
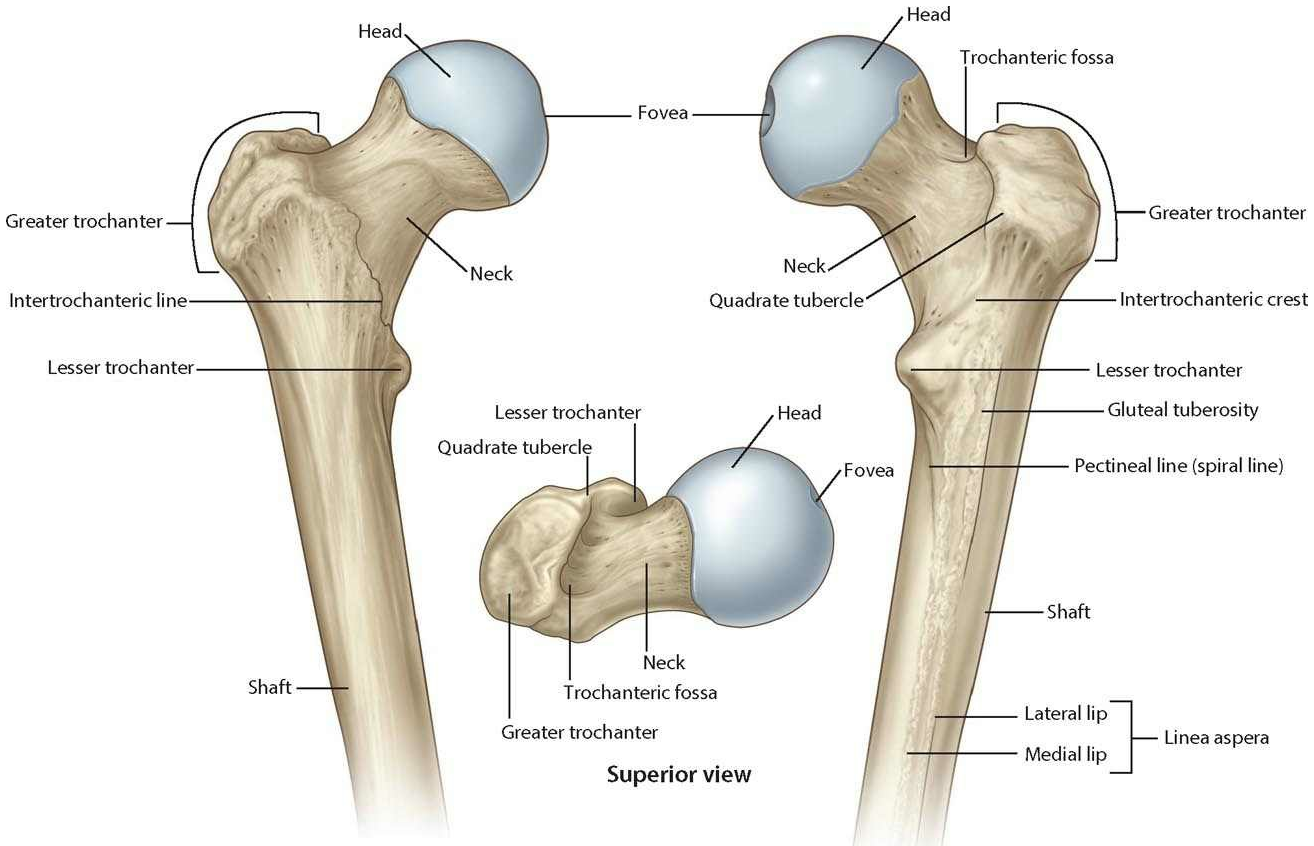


# Articulated pelvis

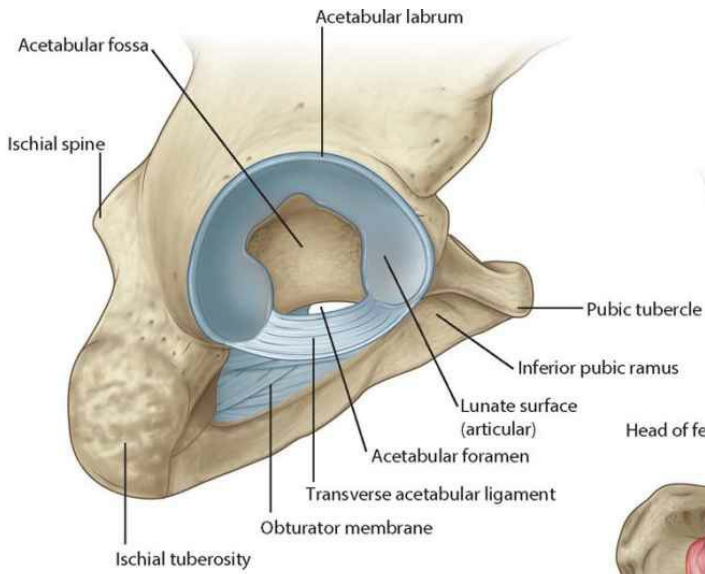




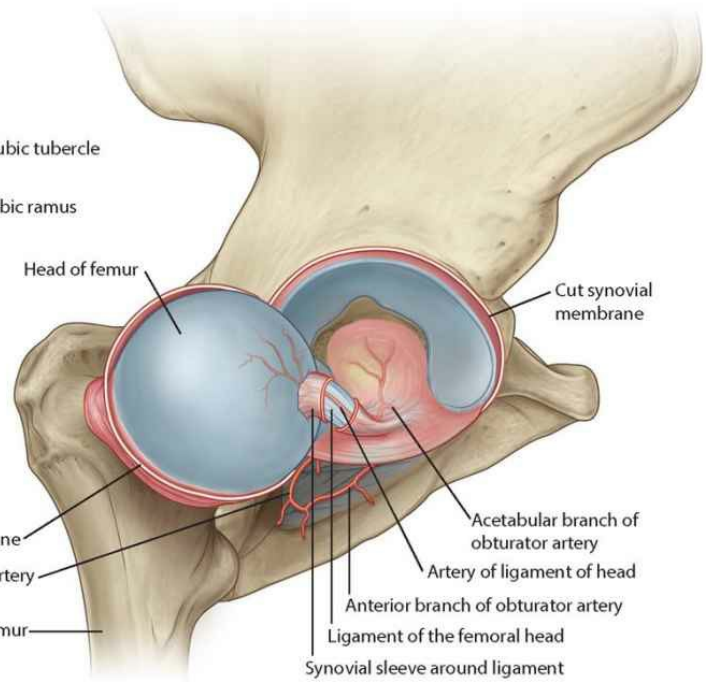
# Proximal femur



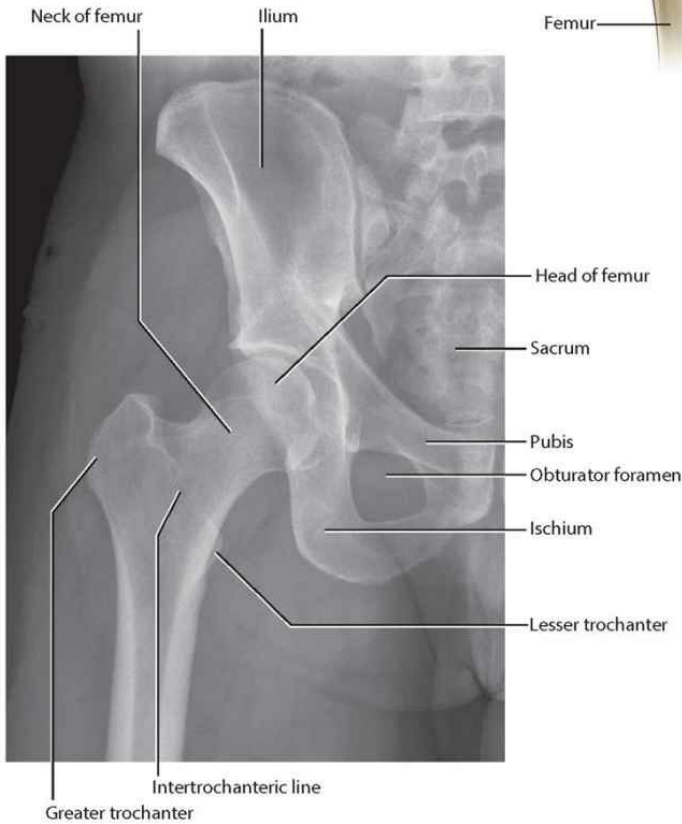# Hip joint



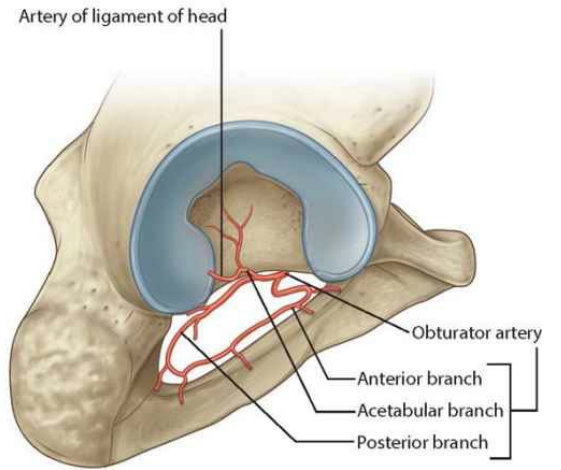
**Acetabular fossa and transverse acetabular ligament**



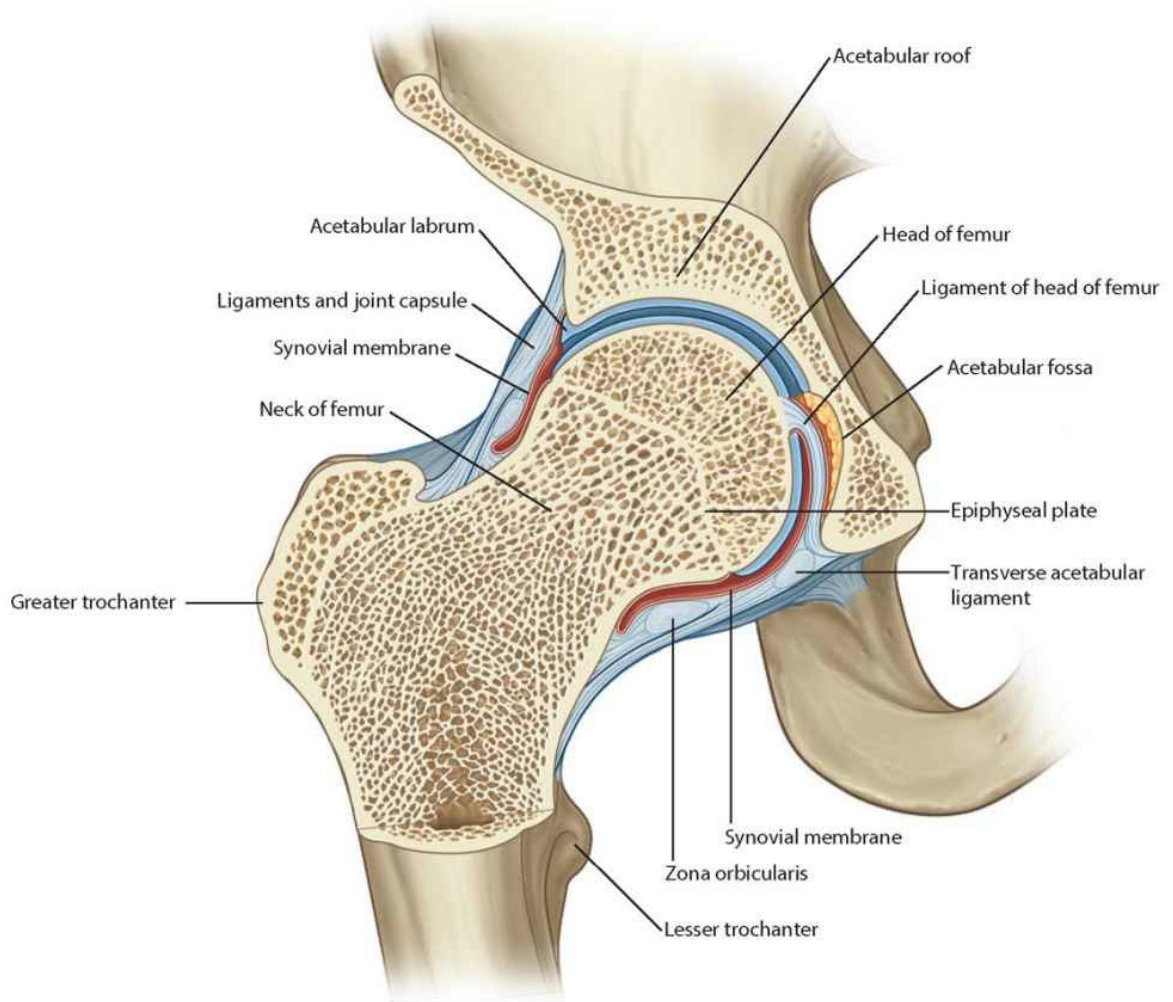
**Ligament of head of femur.**  
The head of the femur has been laterally rotated



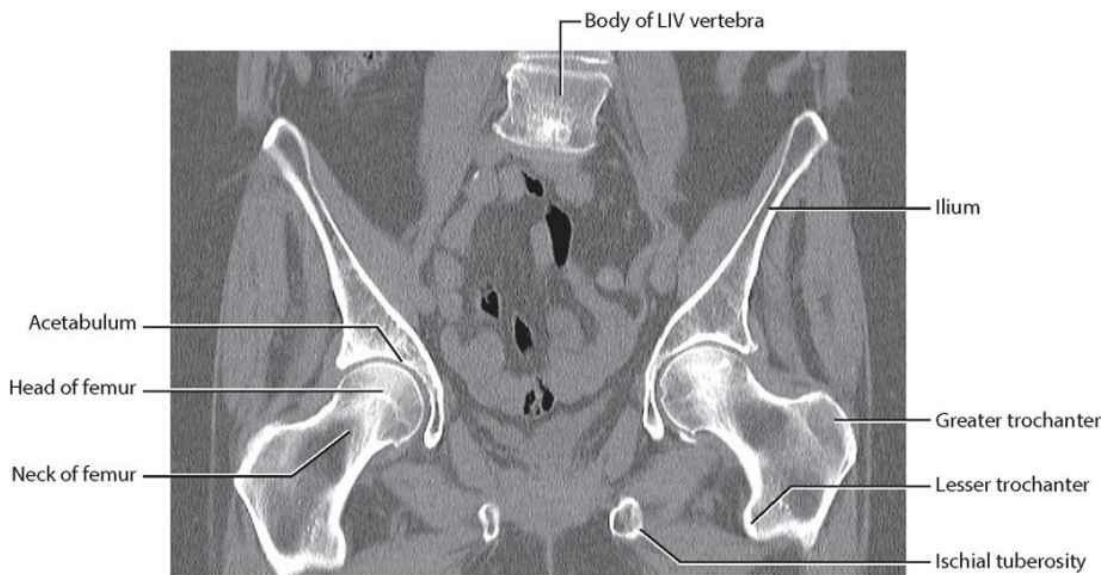
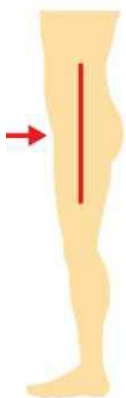**Normal hip joint.**  
Radiograph, AP view



**Obturator artery and branches**

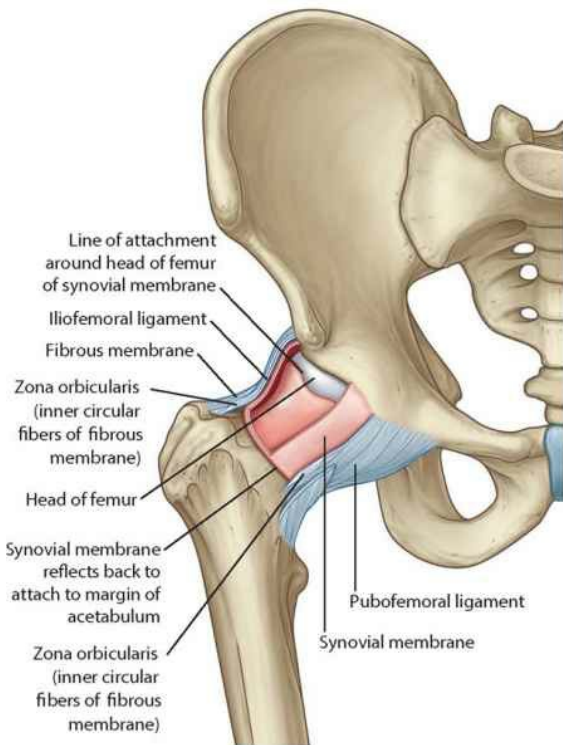


Coronal section through hip joint

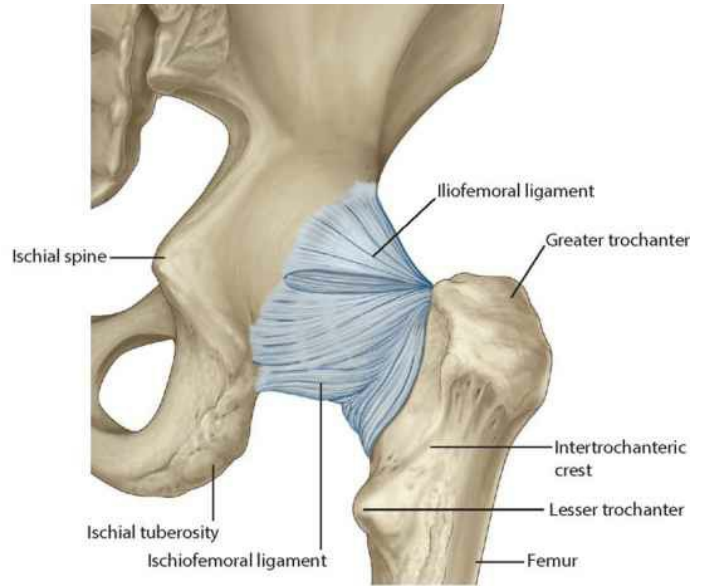


**Hip joints.**  
CT image in coronal plane

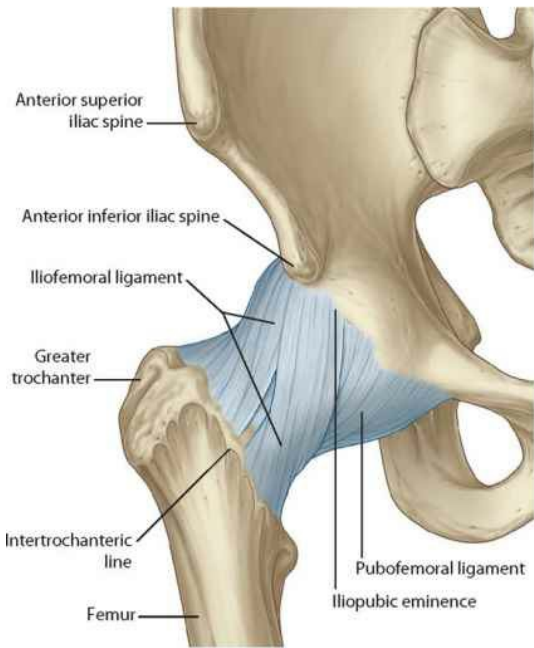
# **Hip joint: structure and arterial supply**



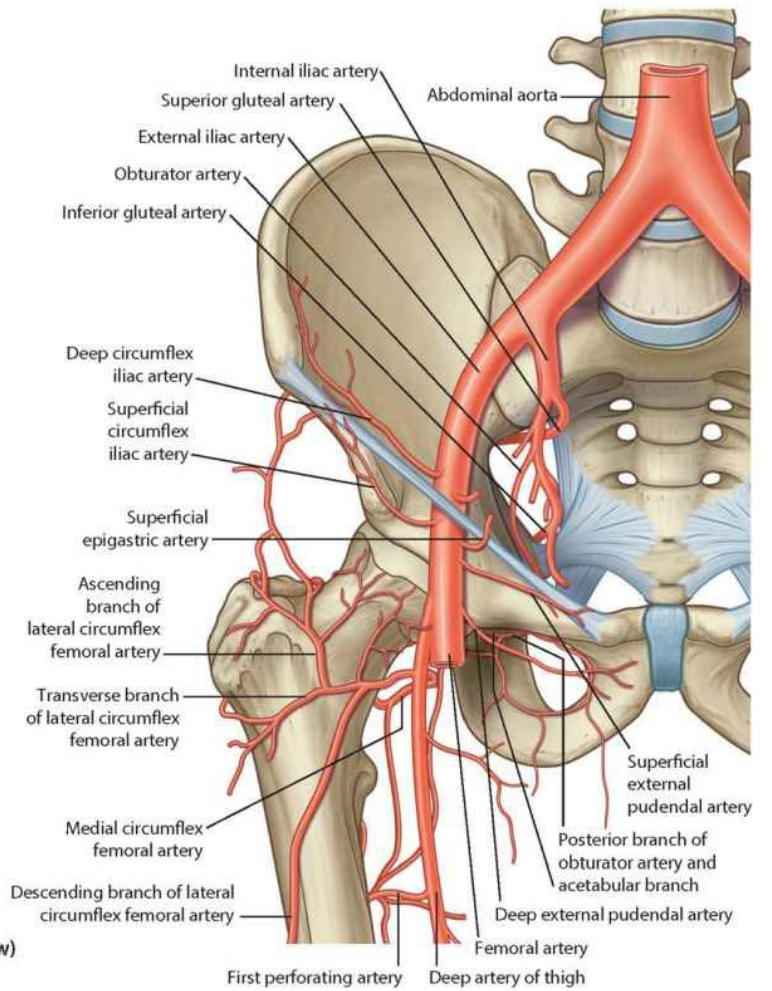
**Joint capsule and synovial membrane**



**Ischioferoral ligament (posterior view)**



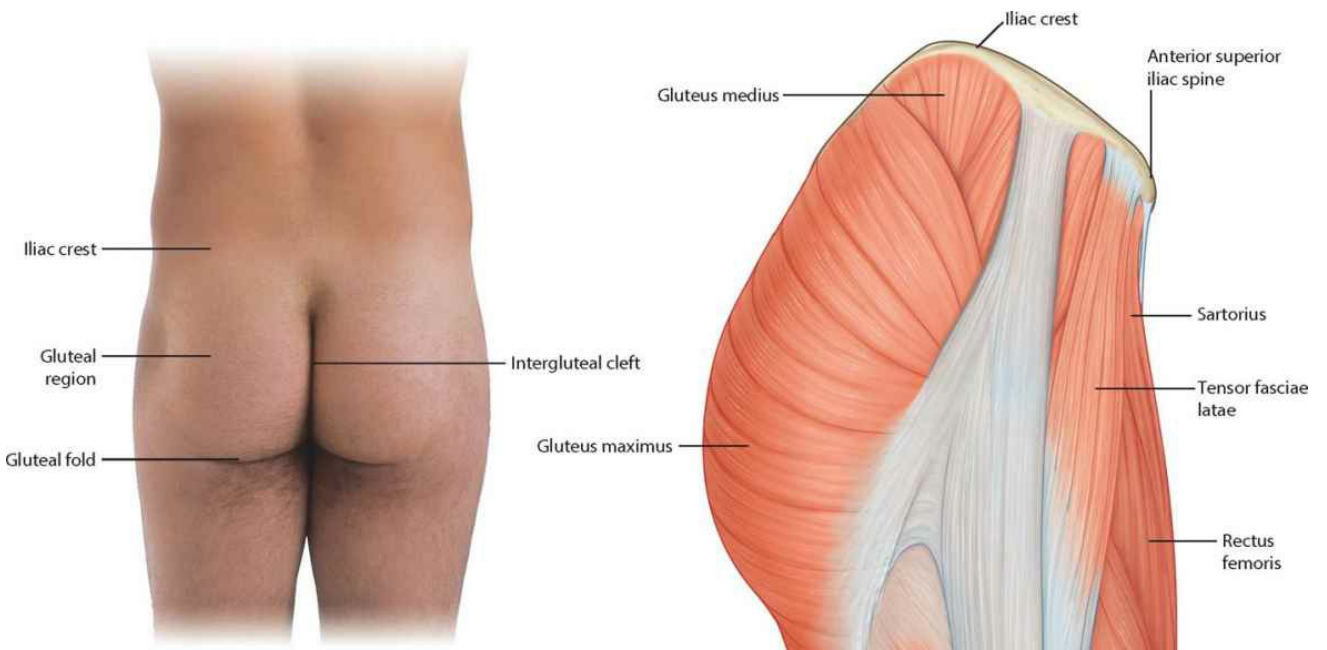
**Ilioferoral and pubofemoral ligaments (anterior view)**



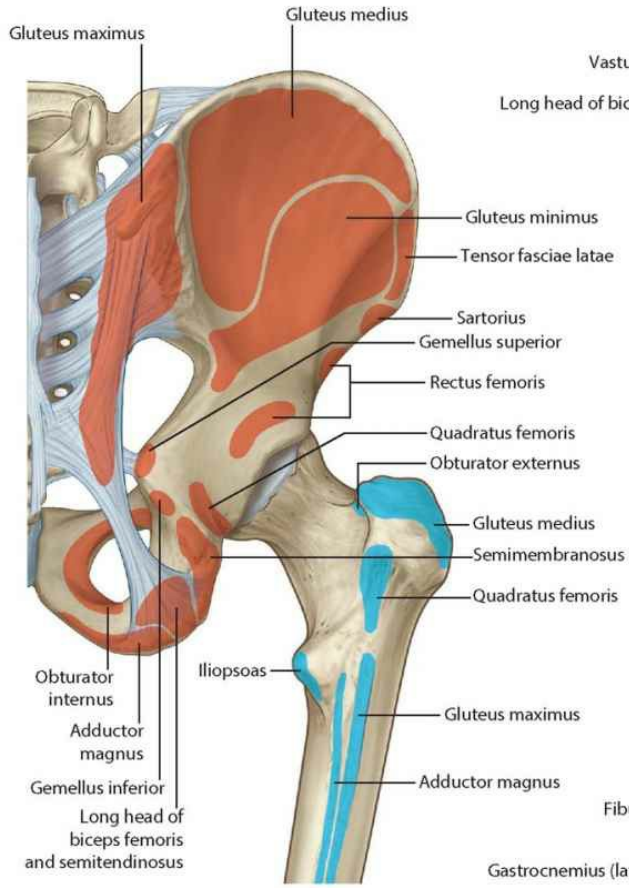
**Arterial supply of the hip joint**



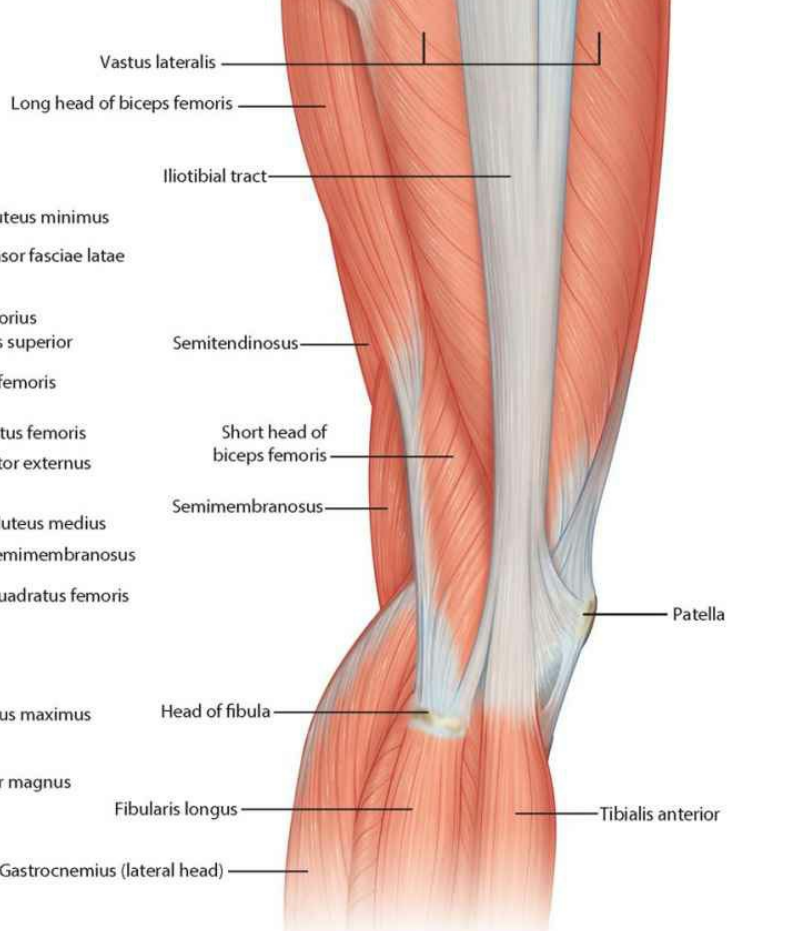
# **Gluteal region: attachments and superficial musculature**



**Surface anatomy of the gluteal region**

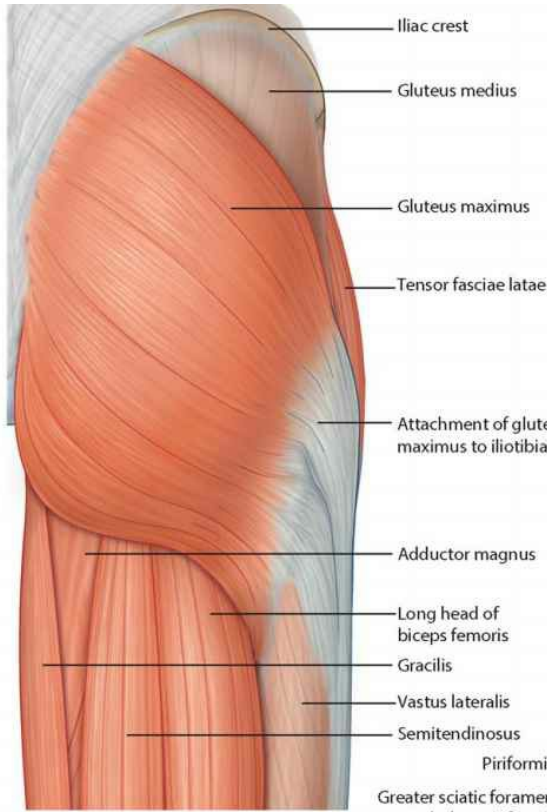


**Muscle attachments of the gluteal region**

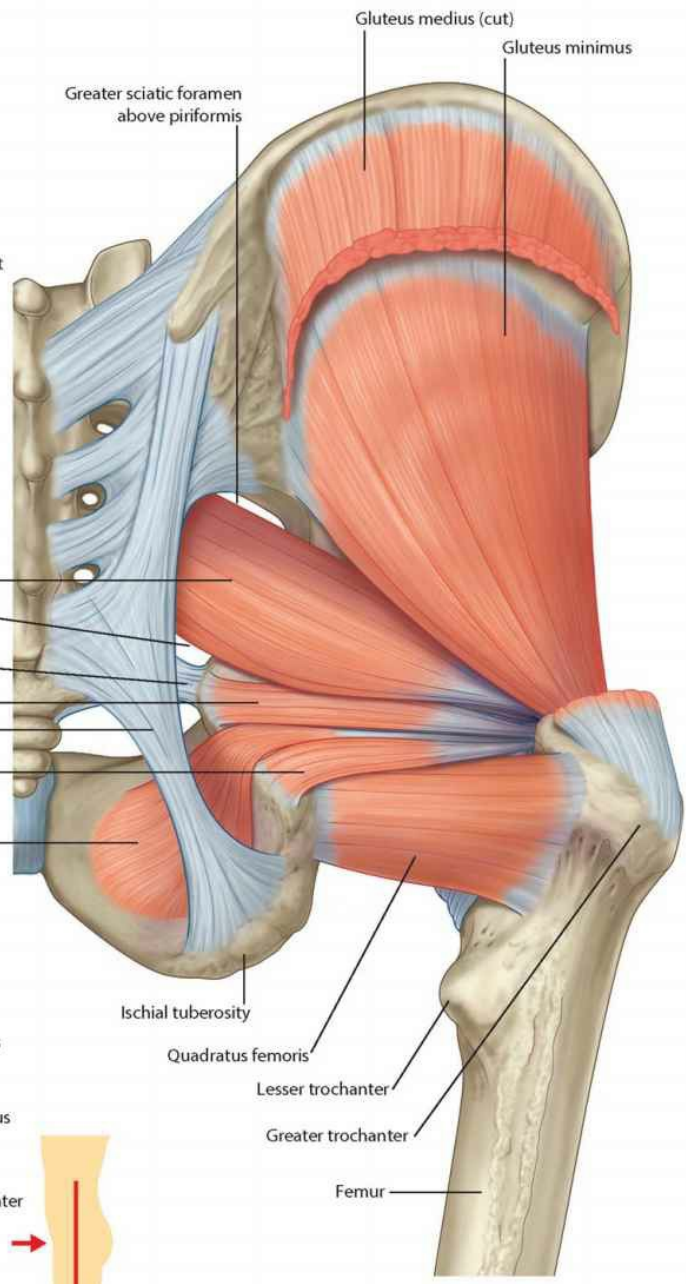


**Muscles of the hip and thigh (lateral view)**

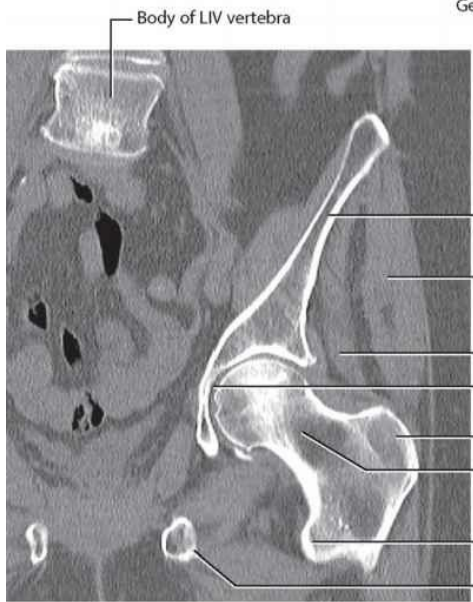# **Gluteal region: superficial and deep muscles**



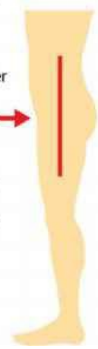**Superficial muscles of the gluteal region (posterior view)**



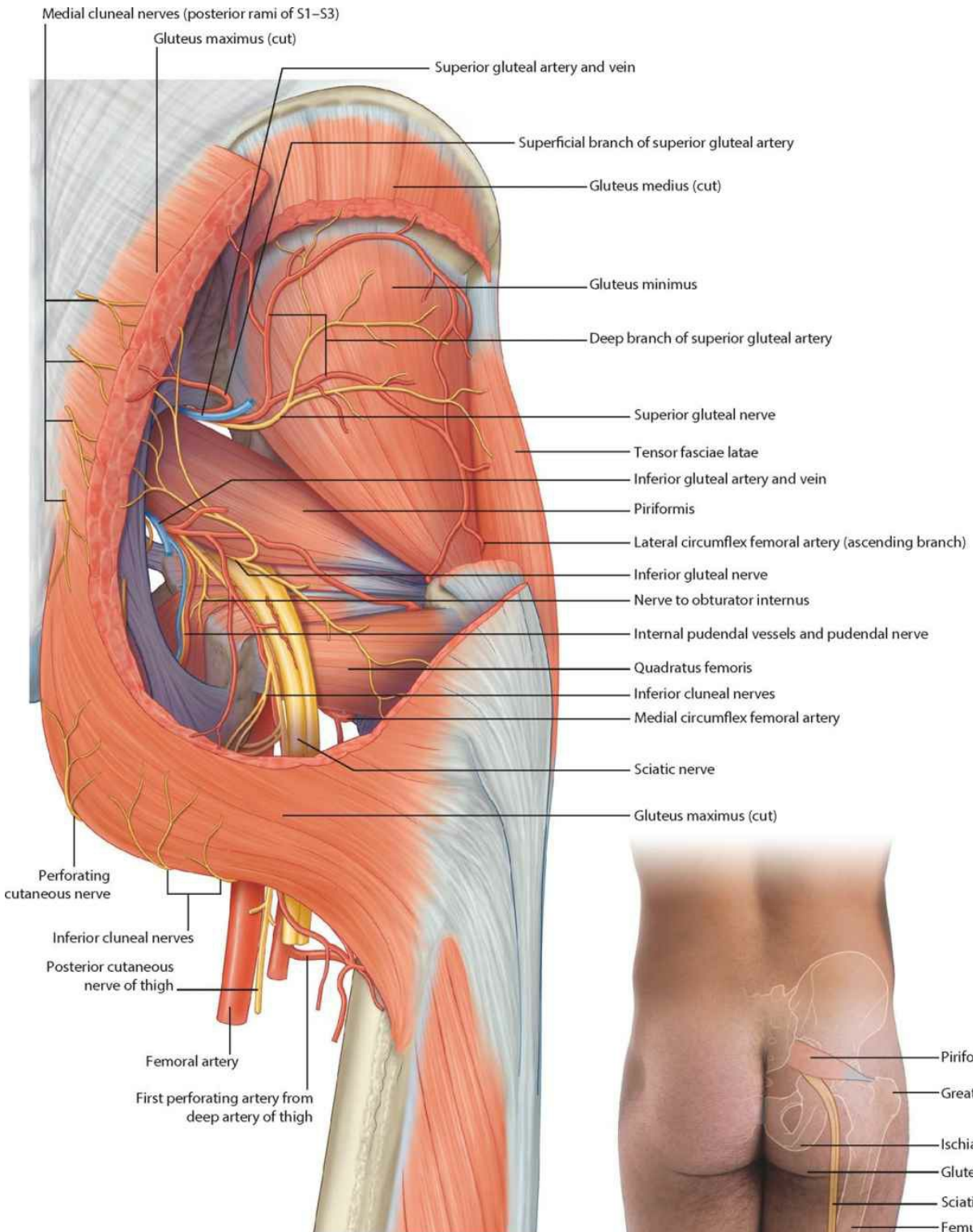
**Deep muscles of the gluteal region (posterior view)**



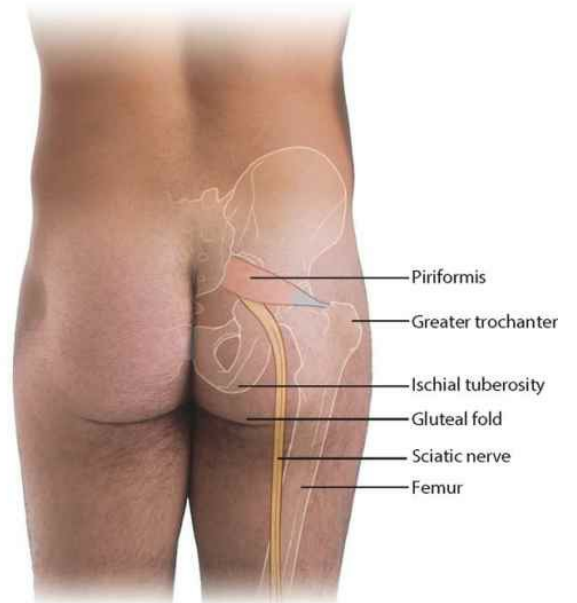**Positioning of gluteus medius and minimus muscles in relation to the hip joint.**  
CT image in coronal plane



## **Gluteal region: arteries and nerves**

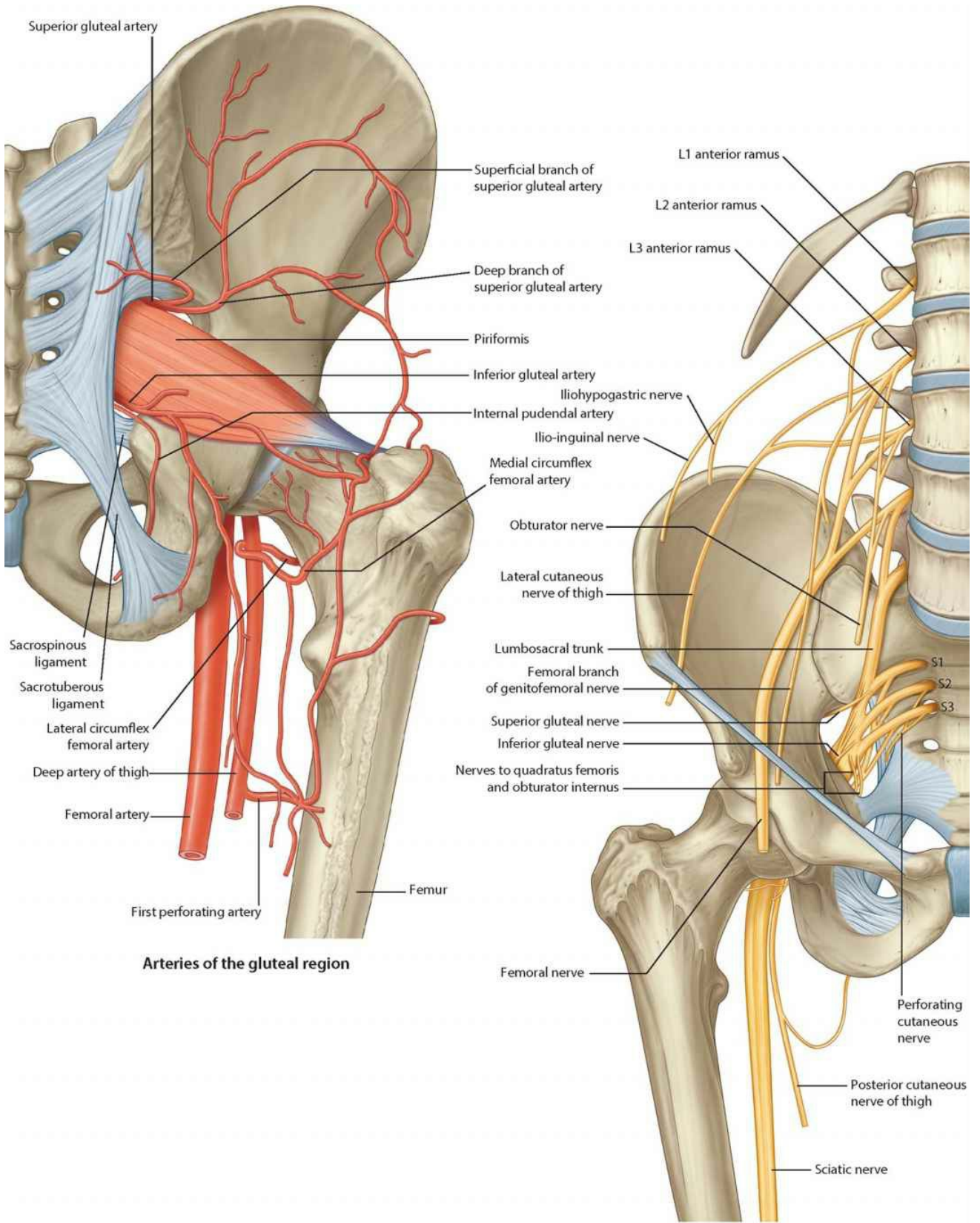


**Arteries and nerves of the gluteal region**



**Sciatic nerve in the gluteal region as it relates to the surface (posterior view)**





Superior gluteal artery

Superficial branch of superior gluteal artery

Deep branch of superior gluteal artery

Piriformis

Inferior gluteal artery

Internal pudendal artery

Medial circumflex femoral artery

Obturator nerve

Lateral cutaneous nerve of thigh

Lumbosacral trunk

Femoral branch of genitofemoral nerve

Superior gluteal nerve

Inferior gluteal nerve

Nerves to quadratus femoris and obturator internus

Femoral nerve

L1 anterior ramus

L2 anterior ramus

L3 anterior ramus

Iliohypogastric nerve

Ilio-inguinal nerve

S1

S2

S3

Perforating cutaneous nerve

Posterior cutaneous nerve of thigh

Sciatic nerve

Sacrospinous ligament

Sacrotuberous ligament

Lateral circumflex femoral artery

Deep artery of thigh

Femoral artery

First perforating artery

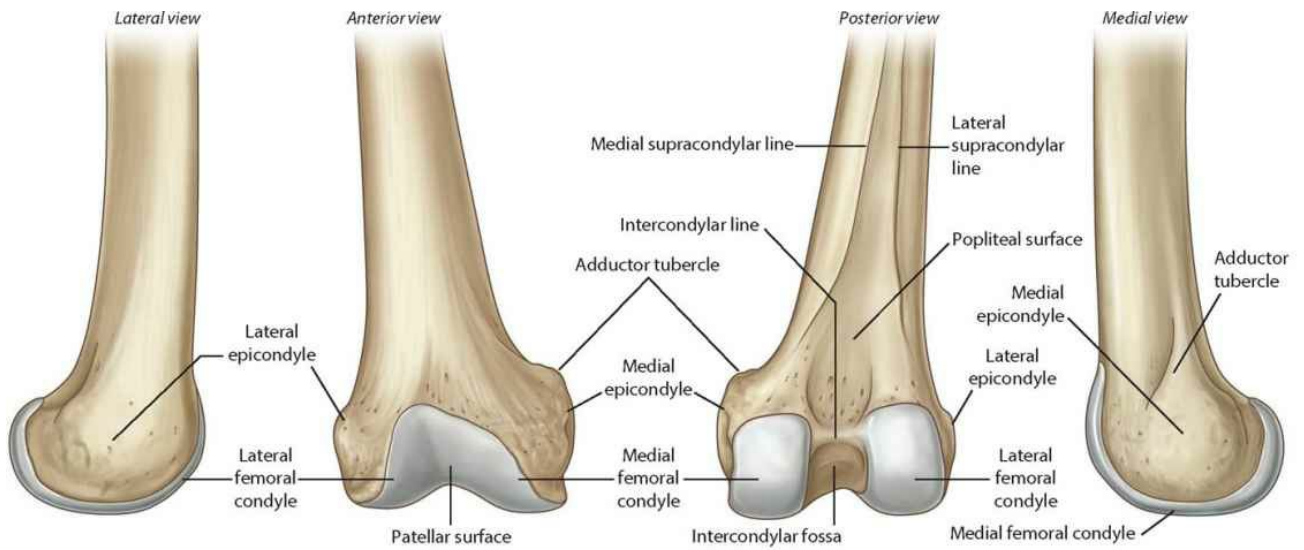
Femur

**Arteries of the gluteal region**

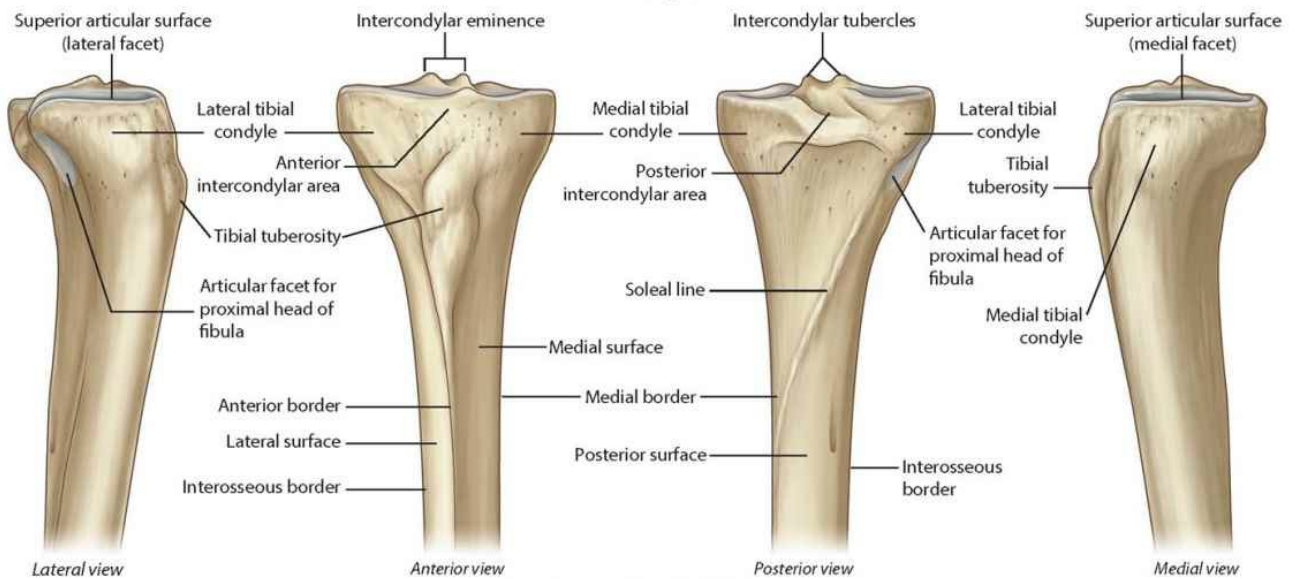
**Branches of the lumbosacral plexus related to lower limb**



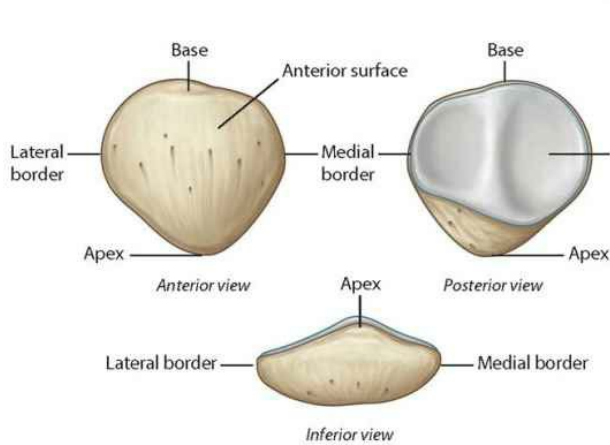
## **Distal femur and proximal tibia and fibula**



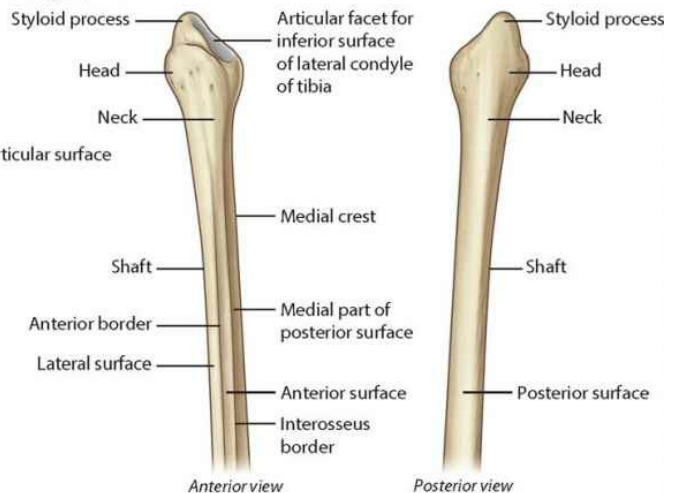
**Distal end of (right) femur**



**Proximal end of (right) tibia**

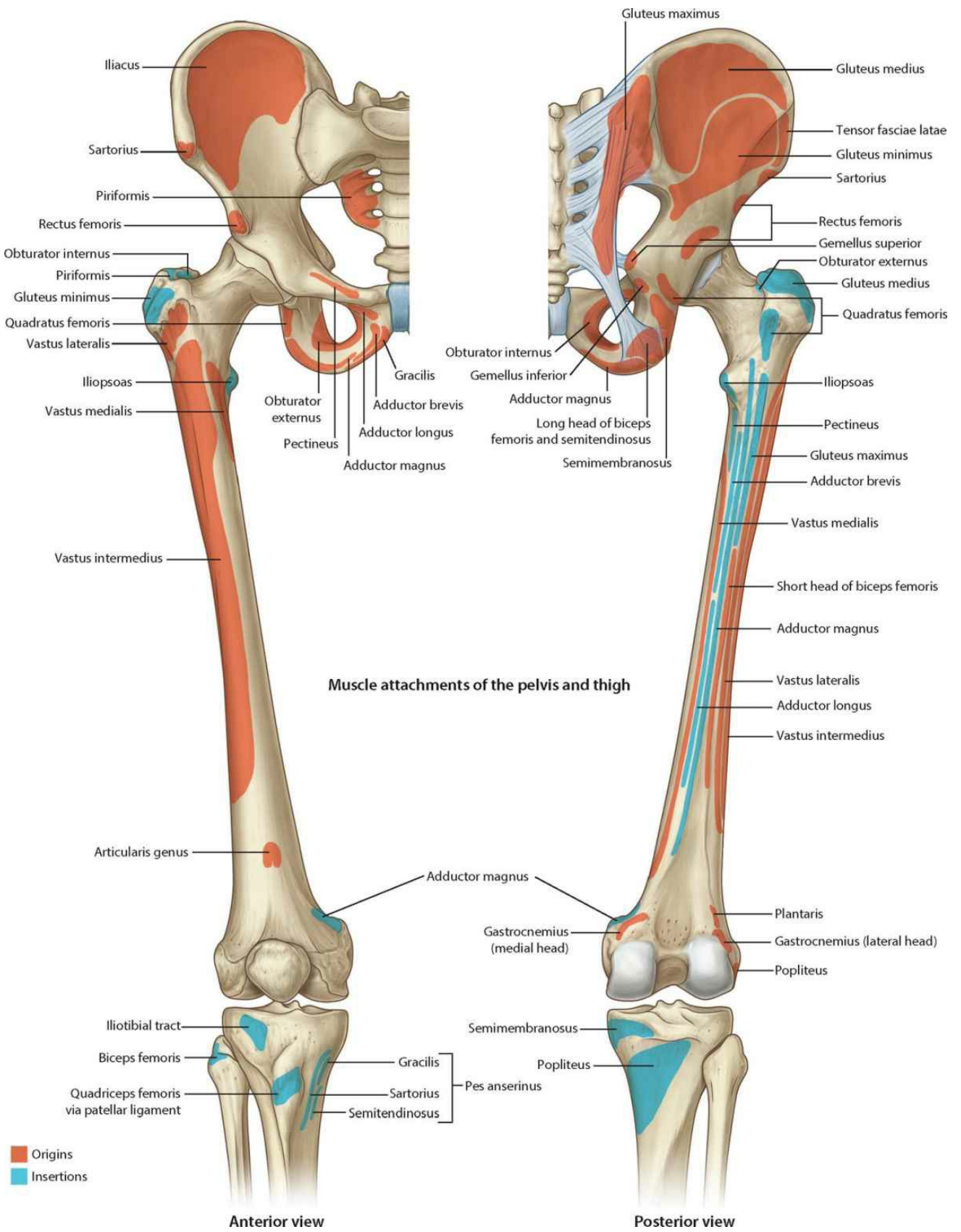


**Patella (right)**

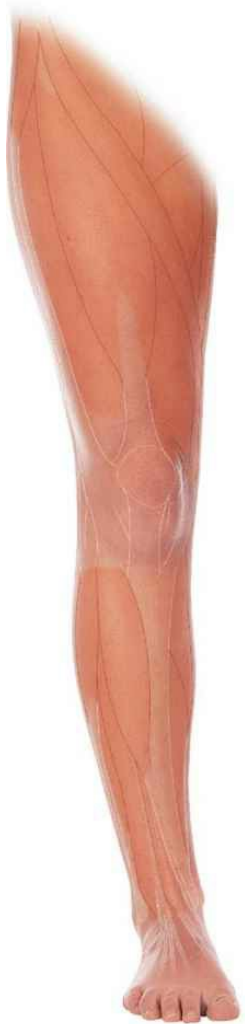

**Proximal end of (right) fibula**

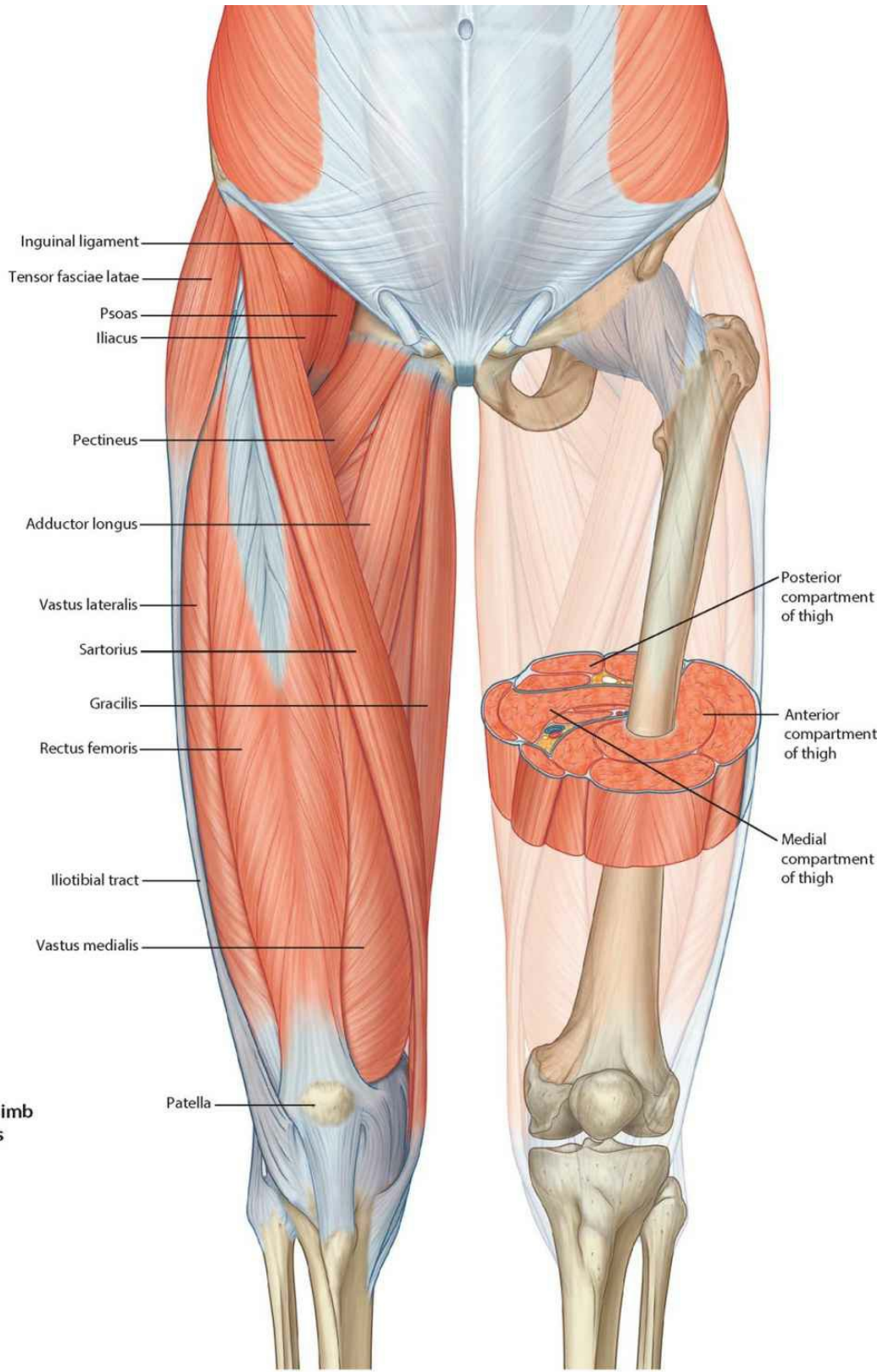
## Thigh: muscle attachments



## **Thigh: anterior superficial musculature**

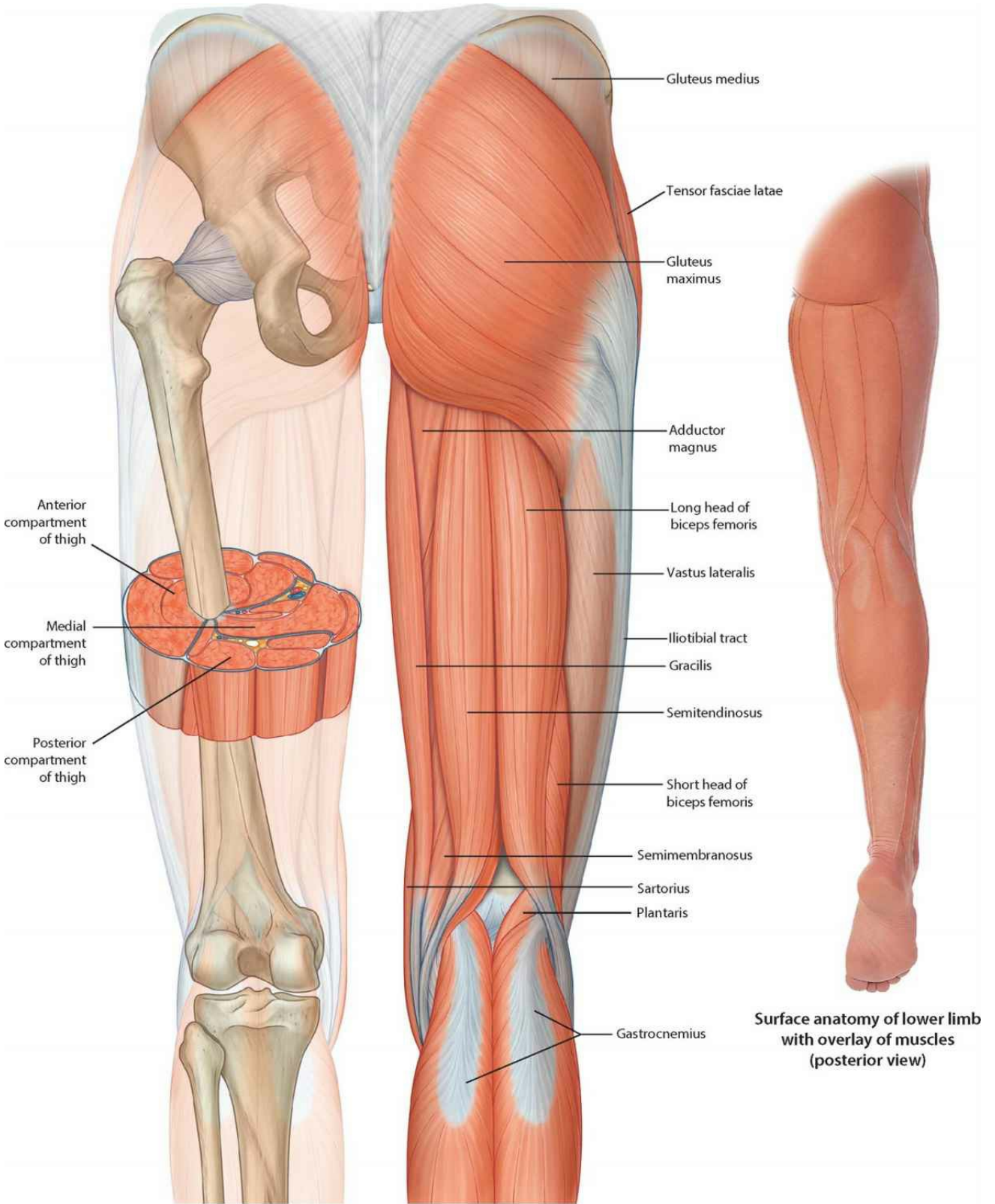


Surface anatomy of lower limb with overlay of muscles (anterior view)



Superficial muscles of the thigh (anterior view)

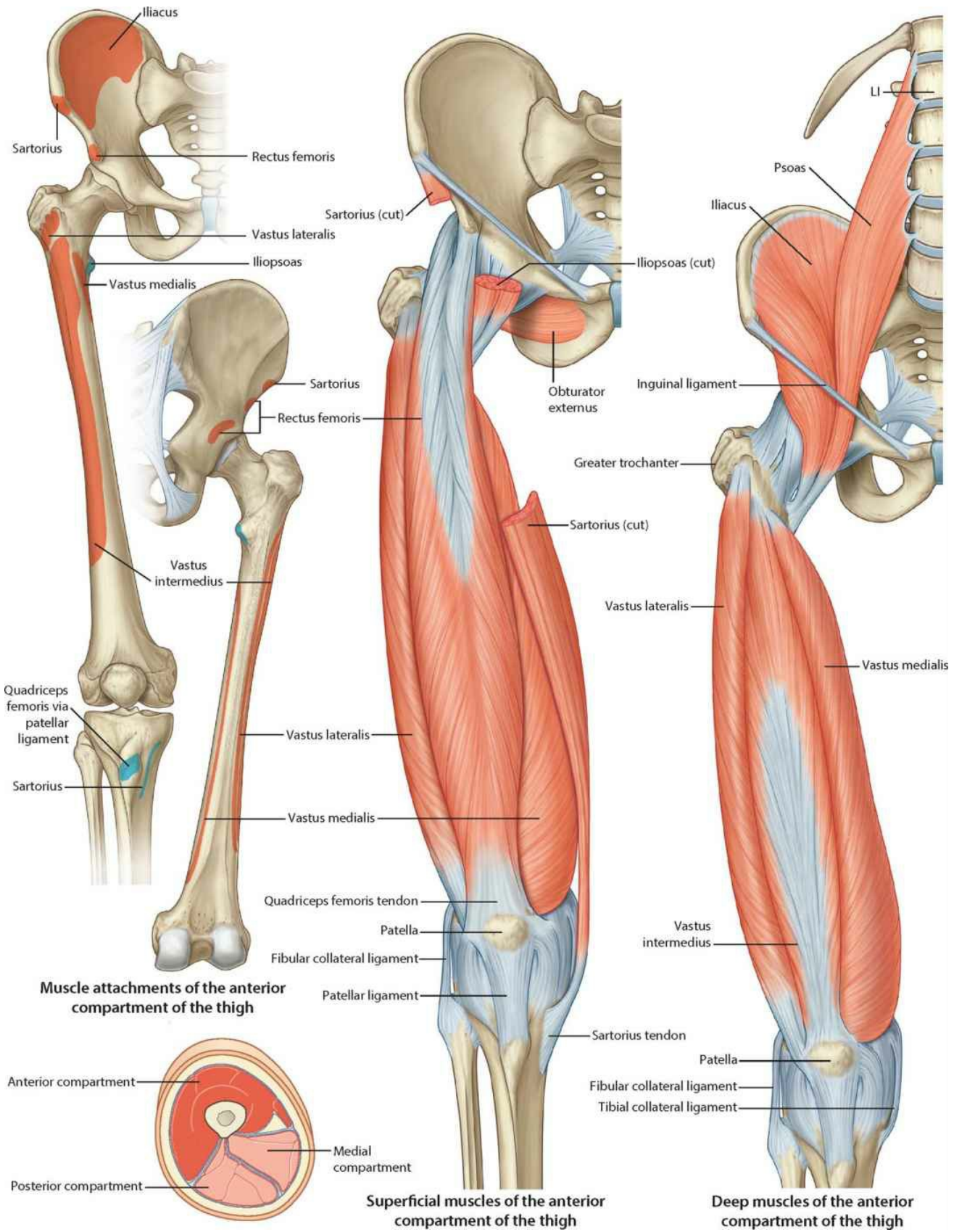
## **Thigh: posterior superficial musculature**



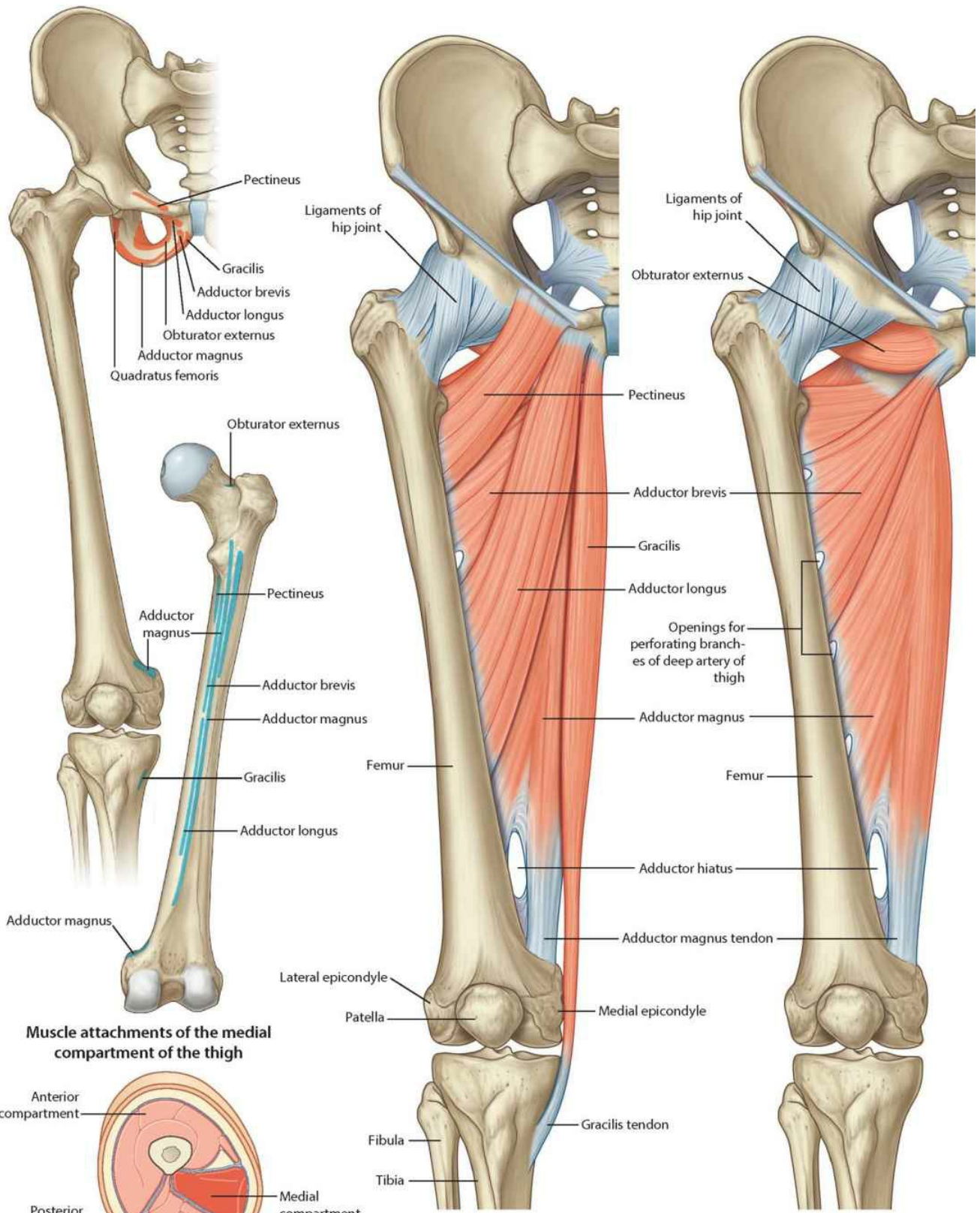
Superficial muscles of the thigh (posterior view)



## **Thigh: anterior compartment muscles**



## **Thigh: medial compartment muscles**

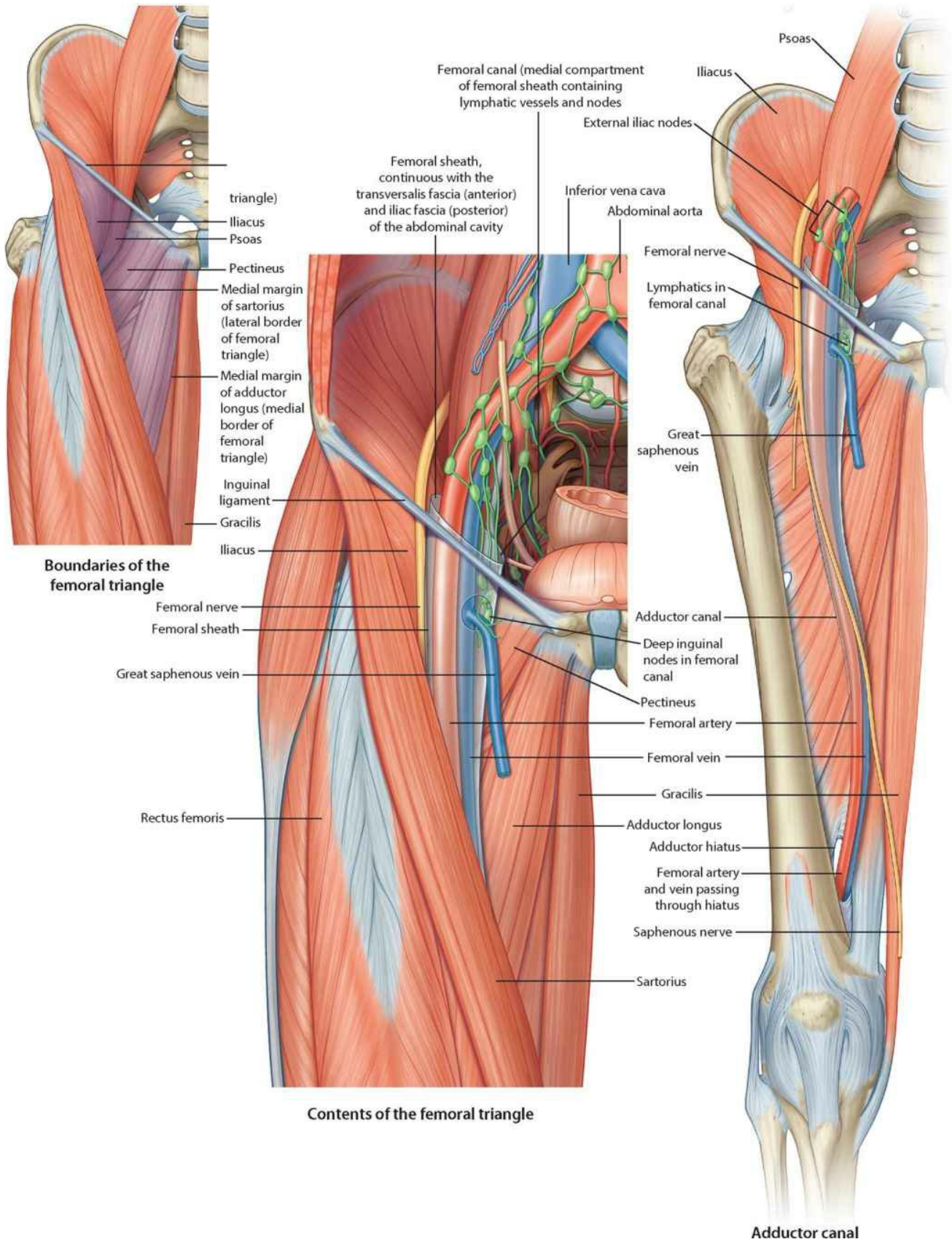


**Muscle attachments of the medial compartment of the thigh**

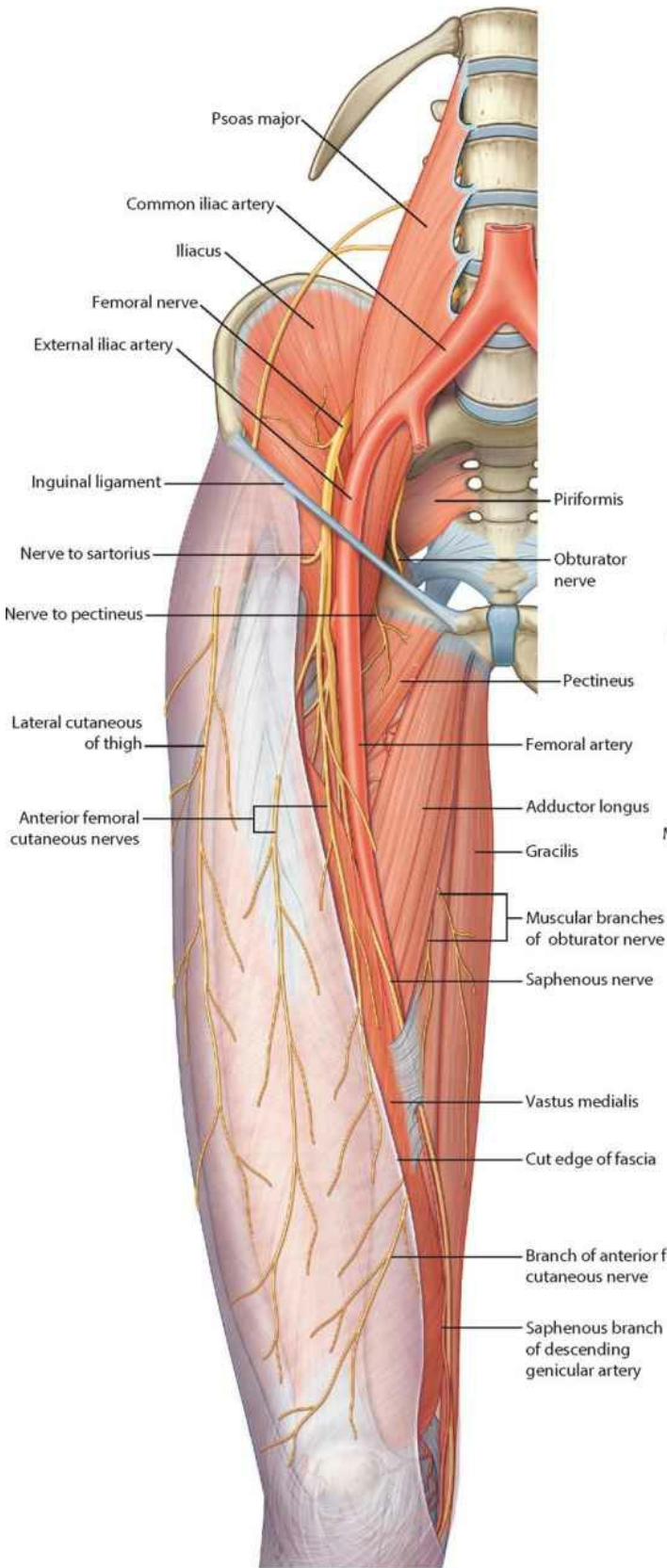
**Superficial muscles of the medial compartment of the thigh**

**Deep muscles of the medial compartment of the thigh**

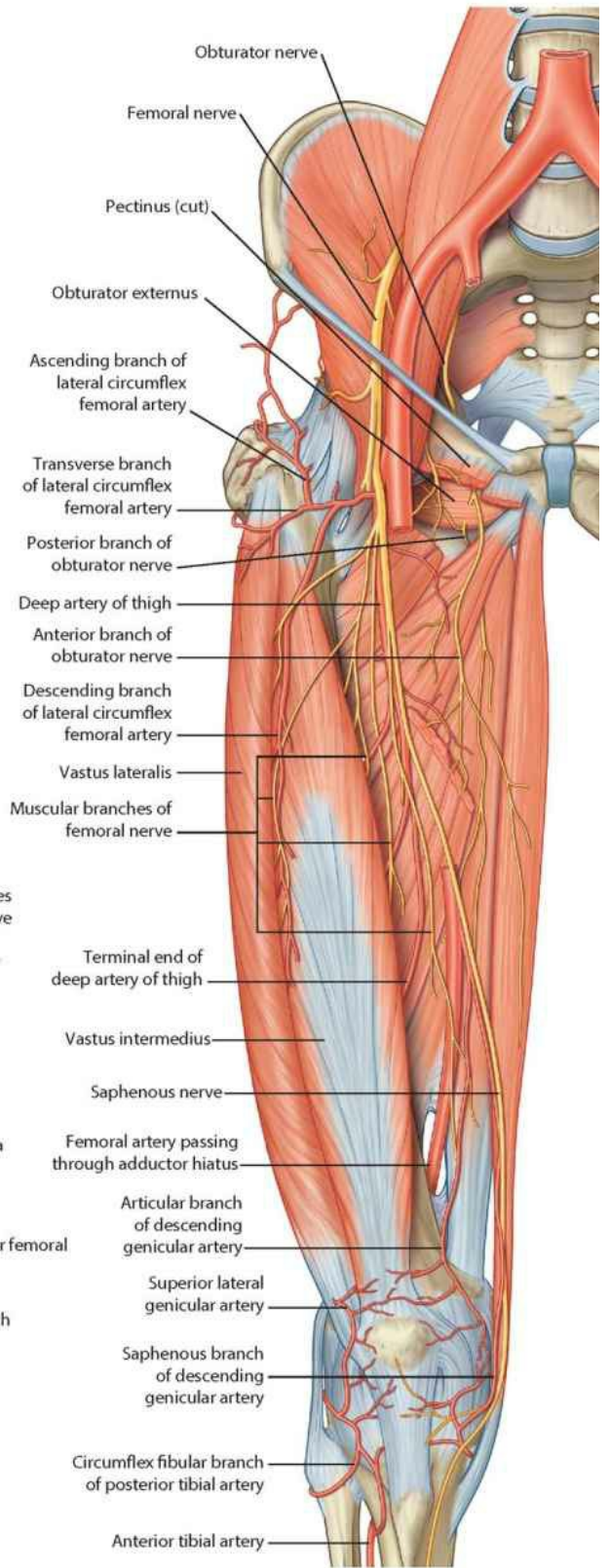
# Femoral triangle



# Anterior thigh: arteries and nerves



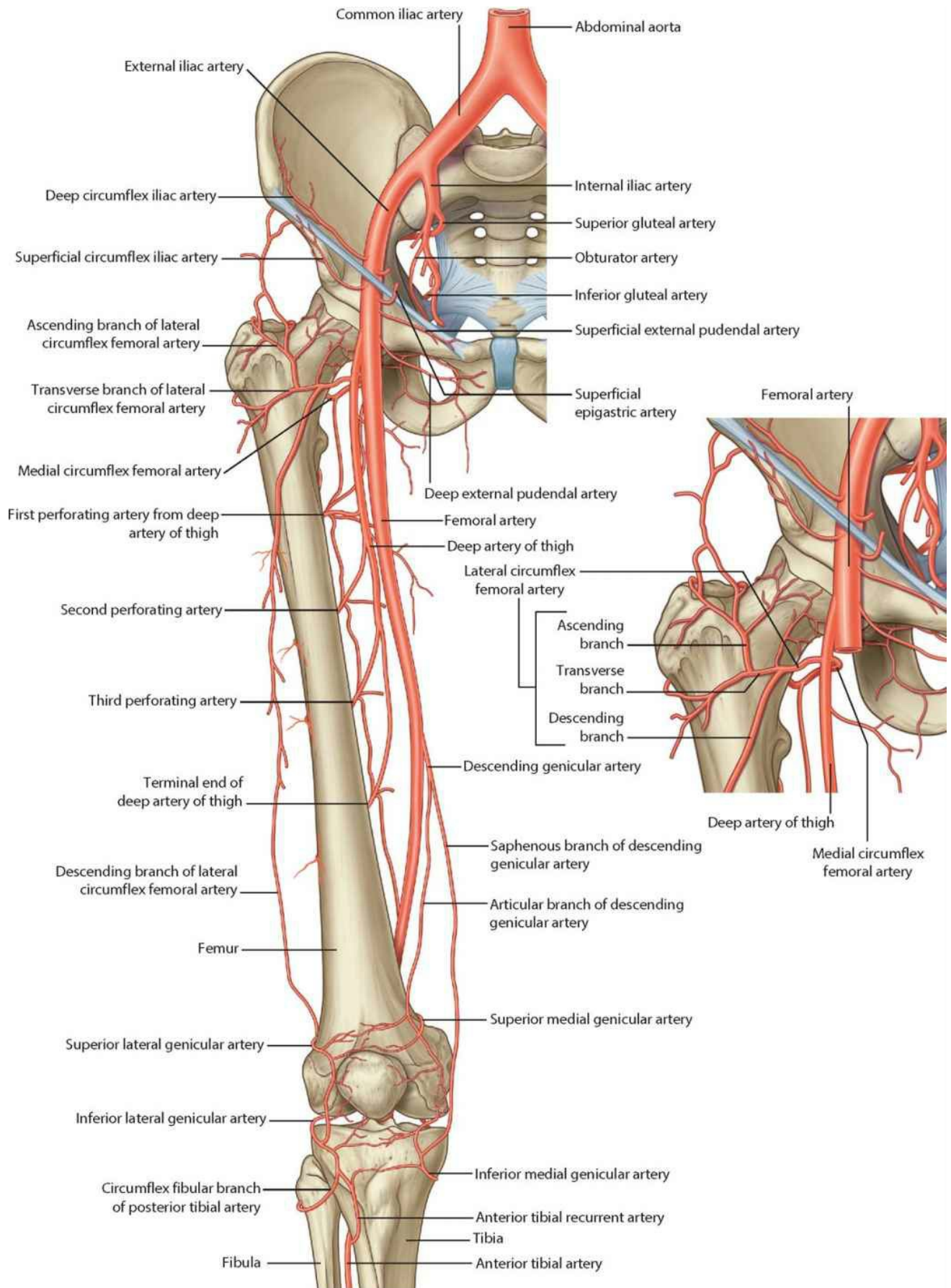
Superficial arteries and nerves of the thigh (anterior view)



Deep arteries and nerves of the thigh (anterior view)



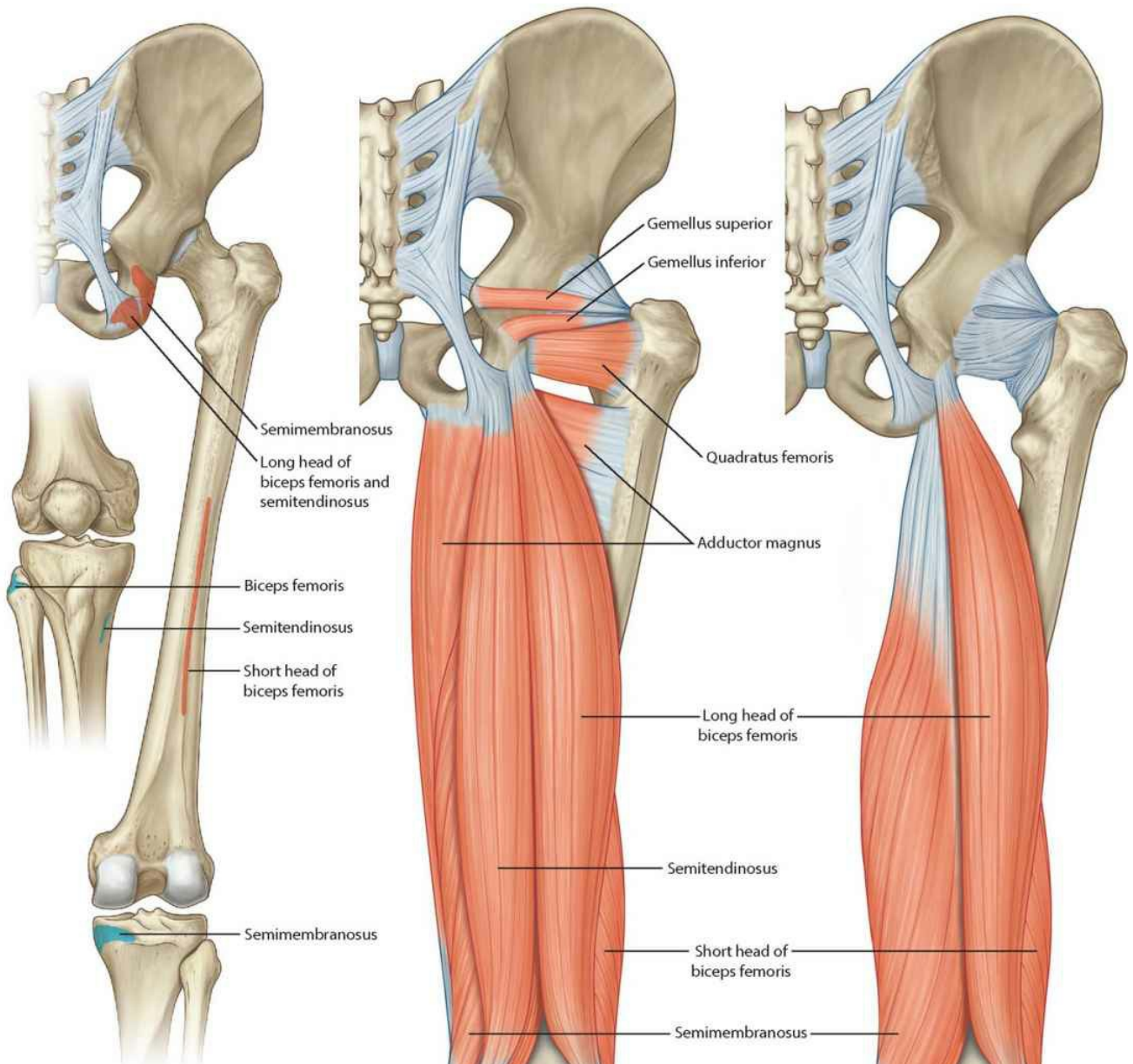
## **Anterior thigh: arteries**



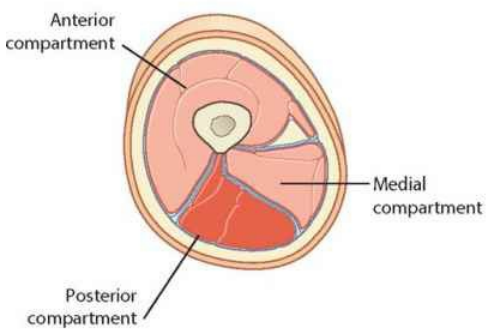
**Arteries of the thigh (anterior view)**



## **Thigh: posterior compartment muscles**



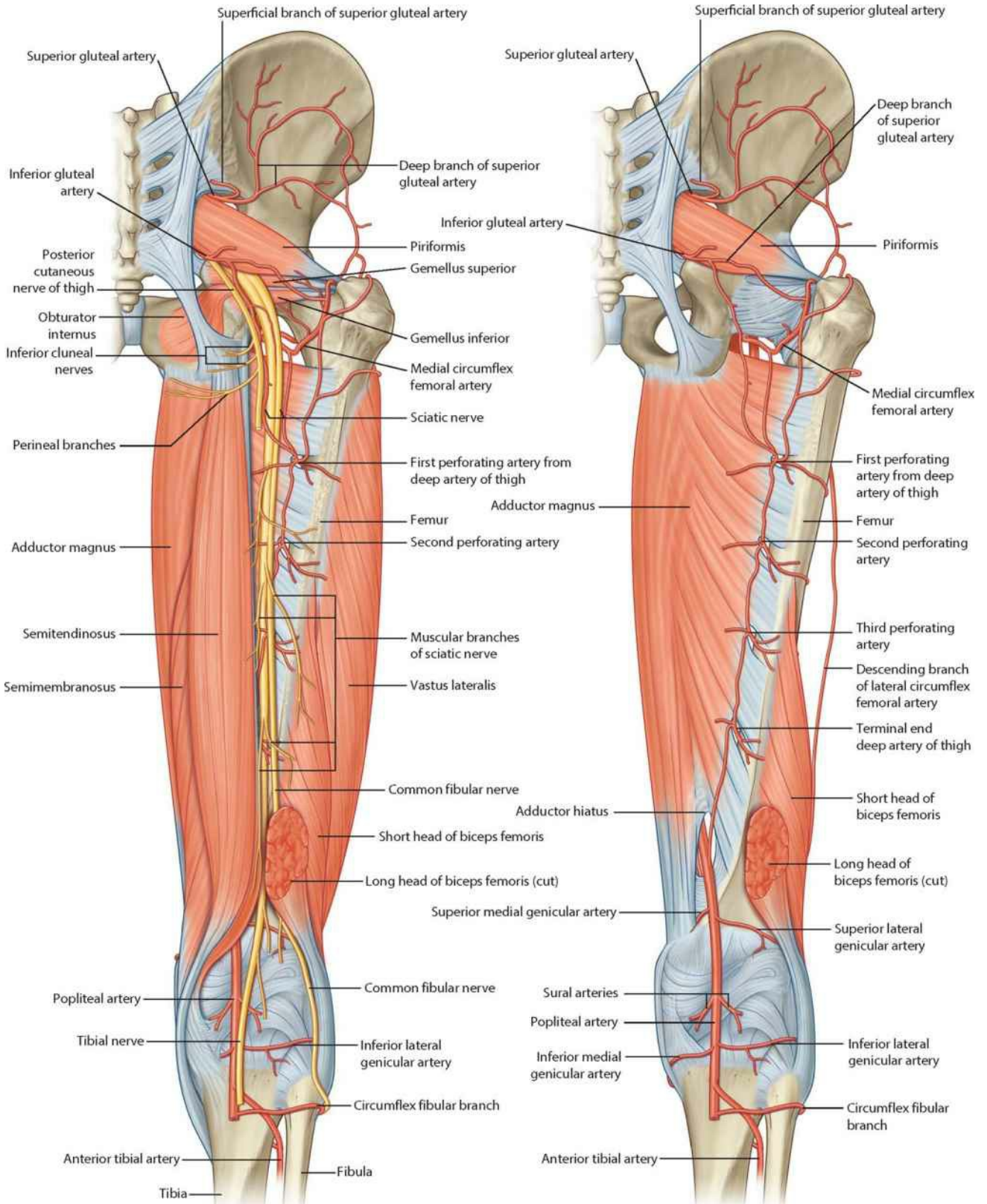
**Muscle attachments of the posterior compartment of the thigh**



**Superficial muscles of the posterior compartment of the thigh**

**Deep muscles of the posterior compartment of the thigh**

## Posterior thigh: arteries and nerves

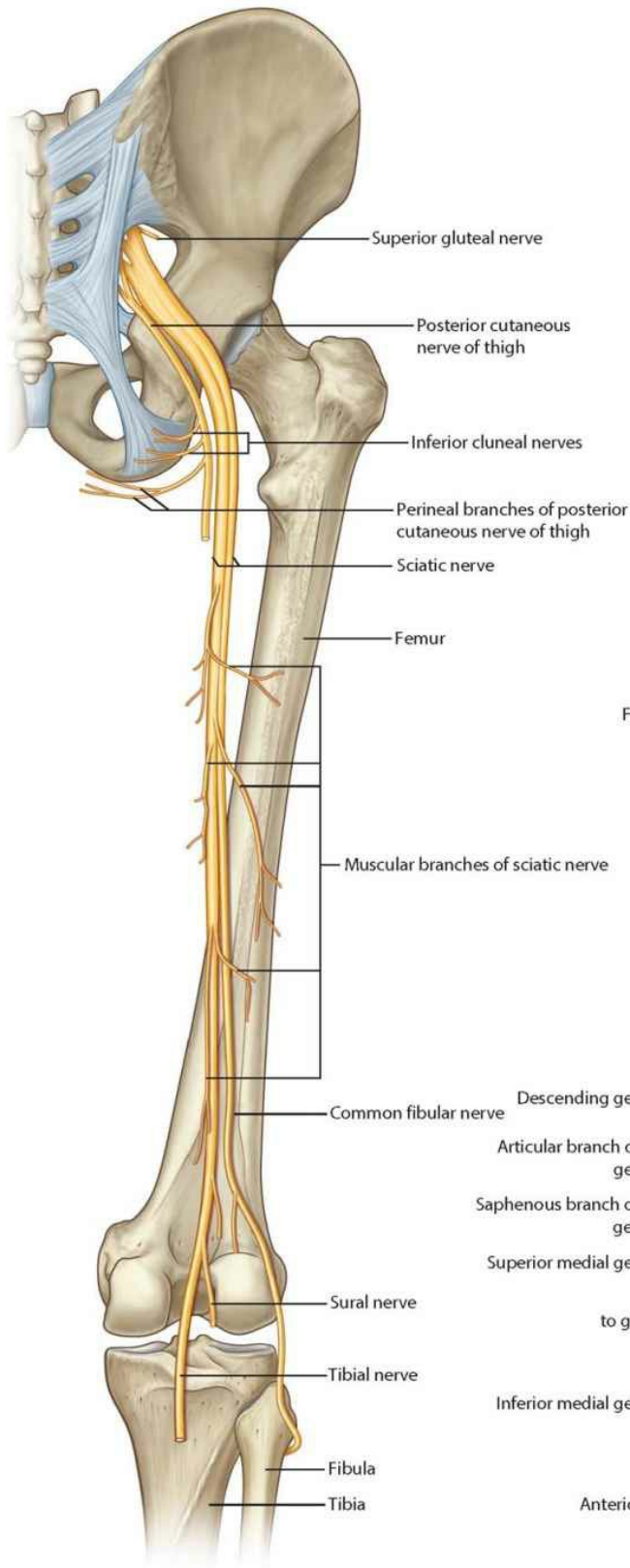


Arteries and nerves of the thigh (posterior view)

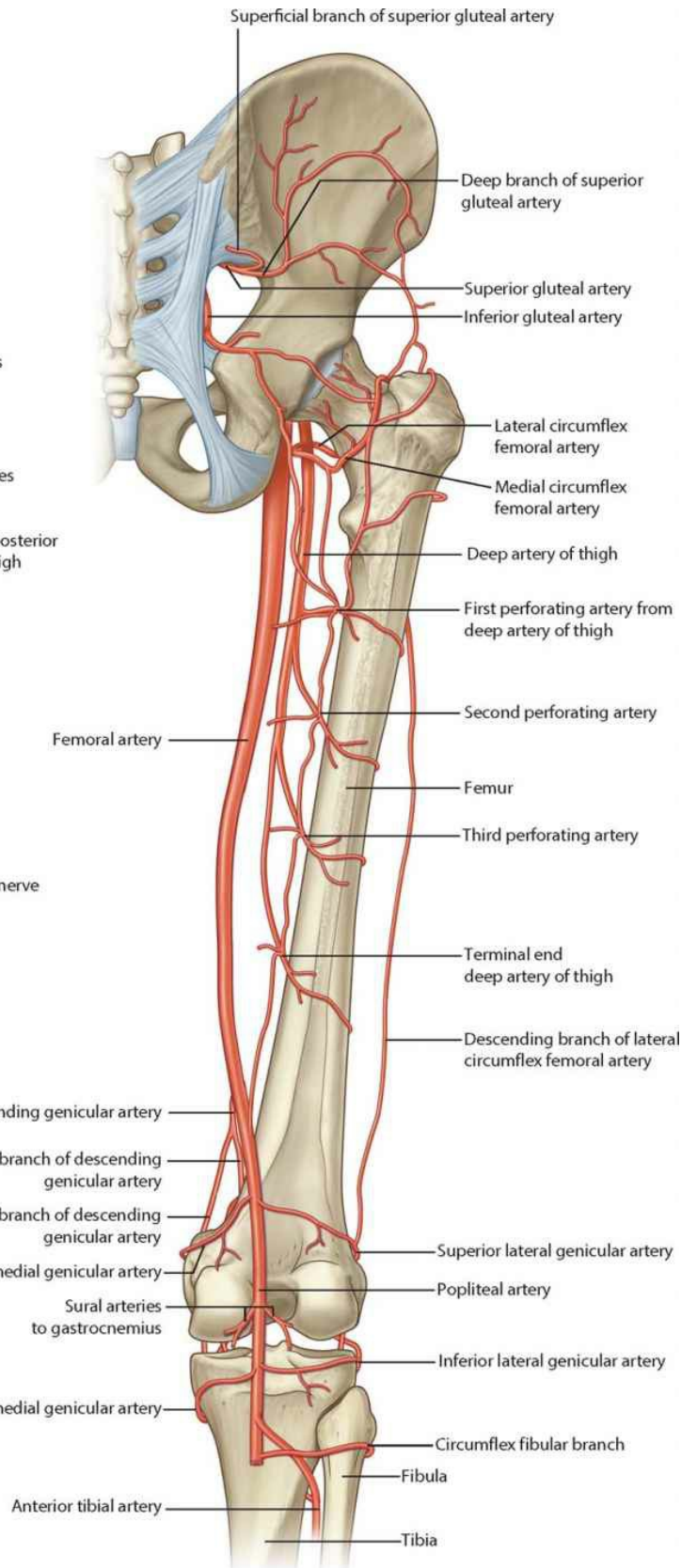
Deep arteries of the thigh (posterior view)





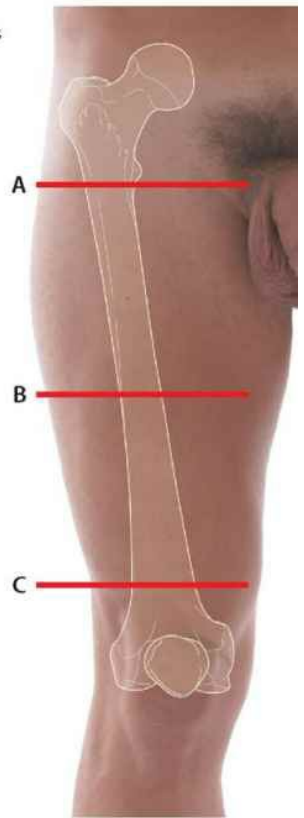
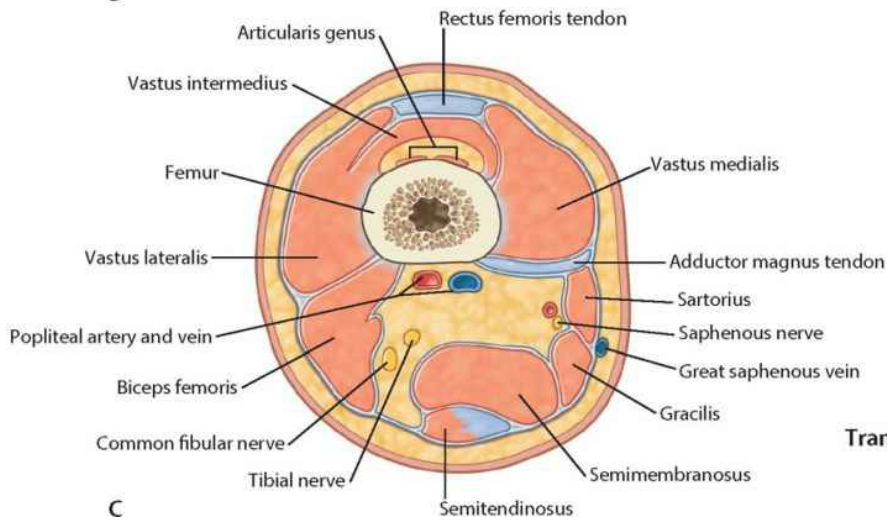
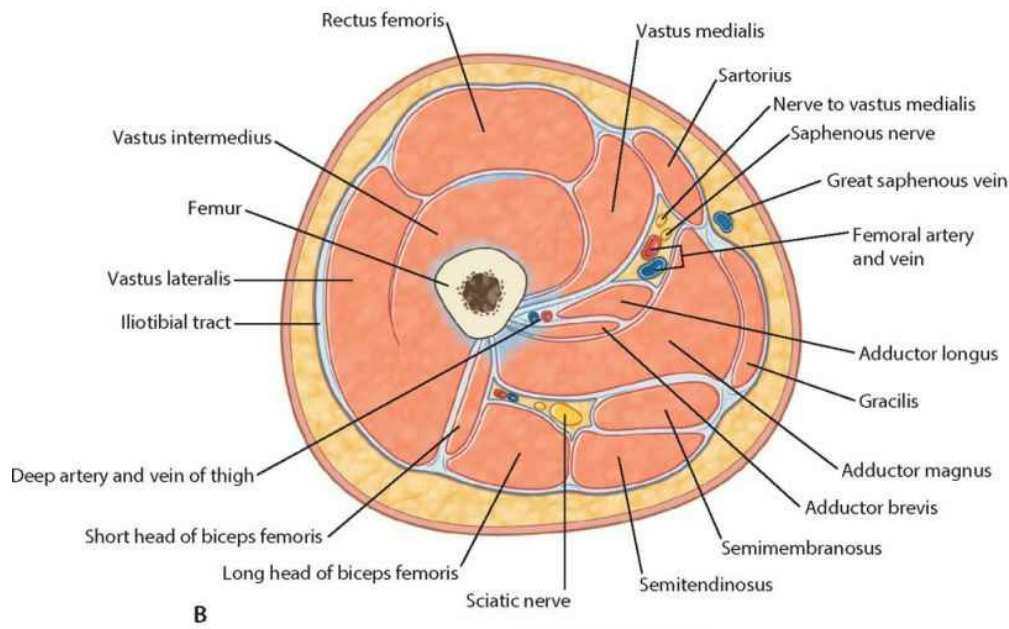
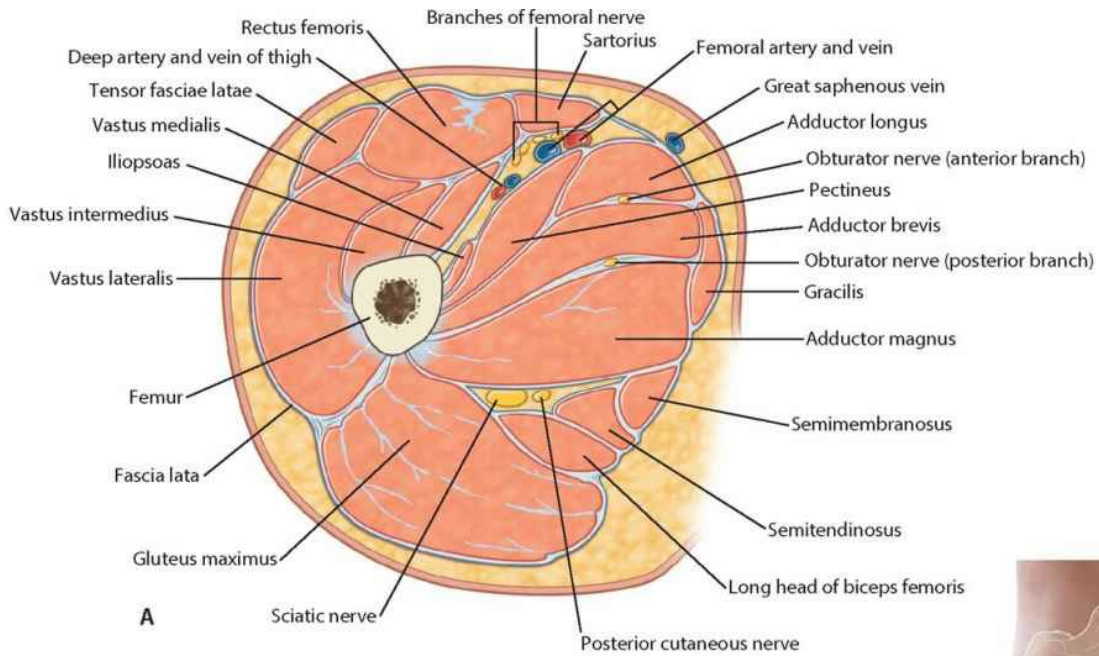


**Nerves of the thigh (posterior view)**



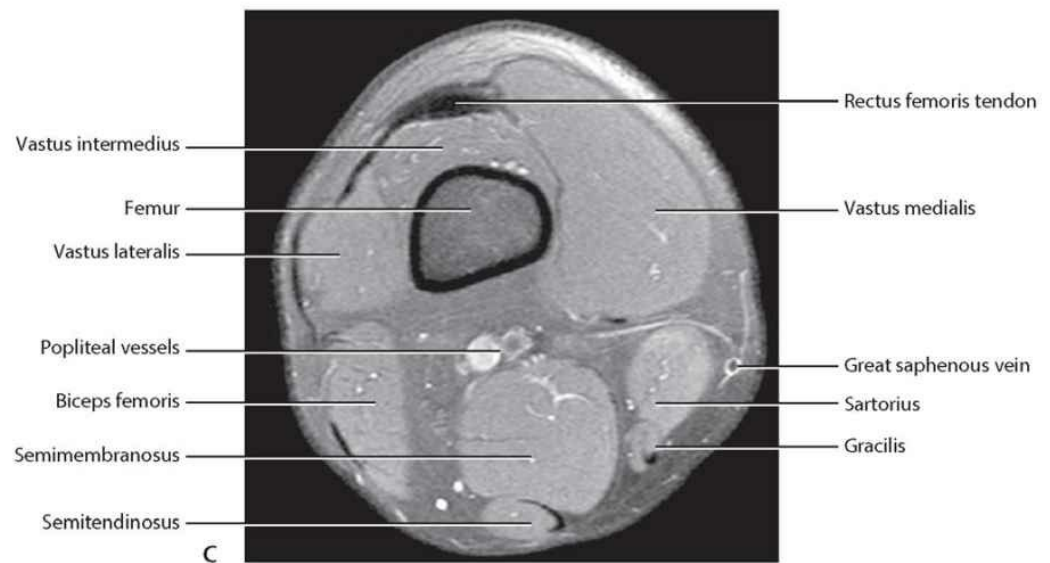
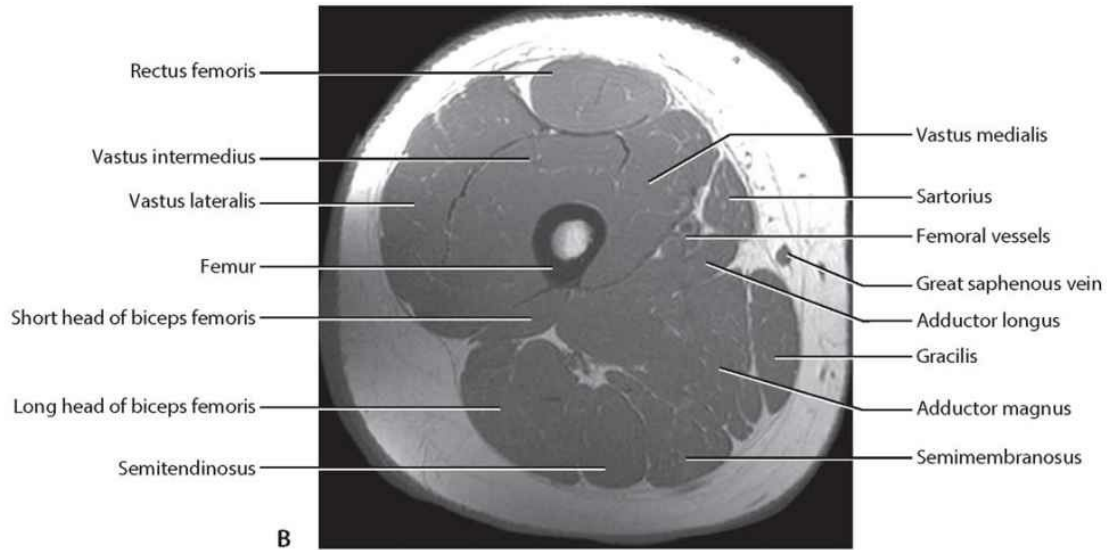
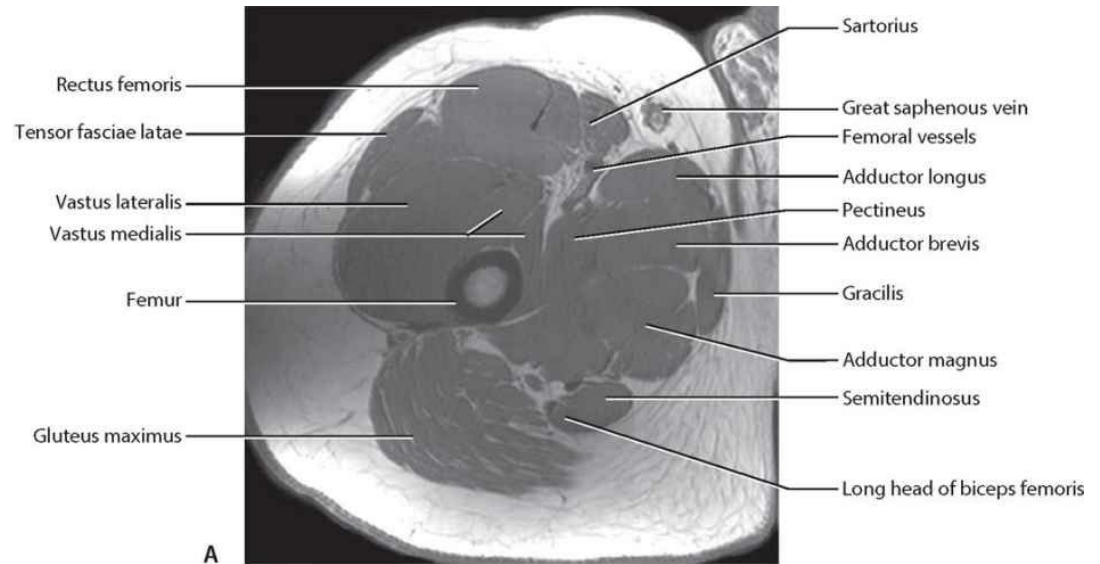
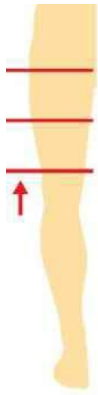
**Arteries of the thigh (posterior view)**

## **Transverse sections: thigh**



**Transverse sections through thigh**

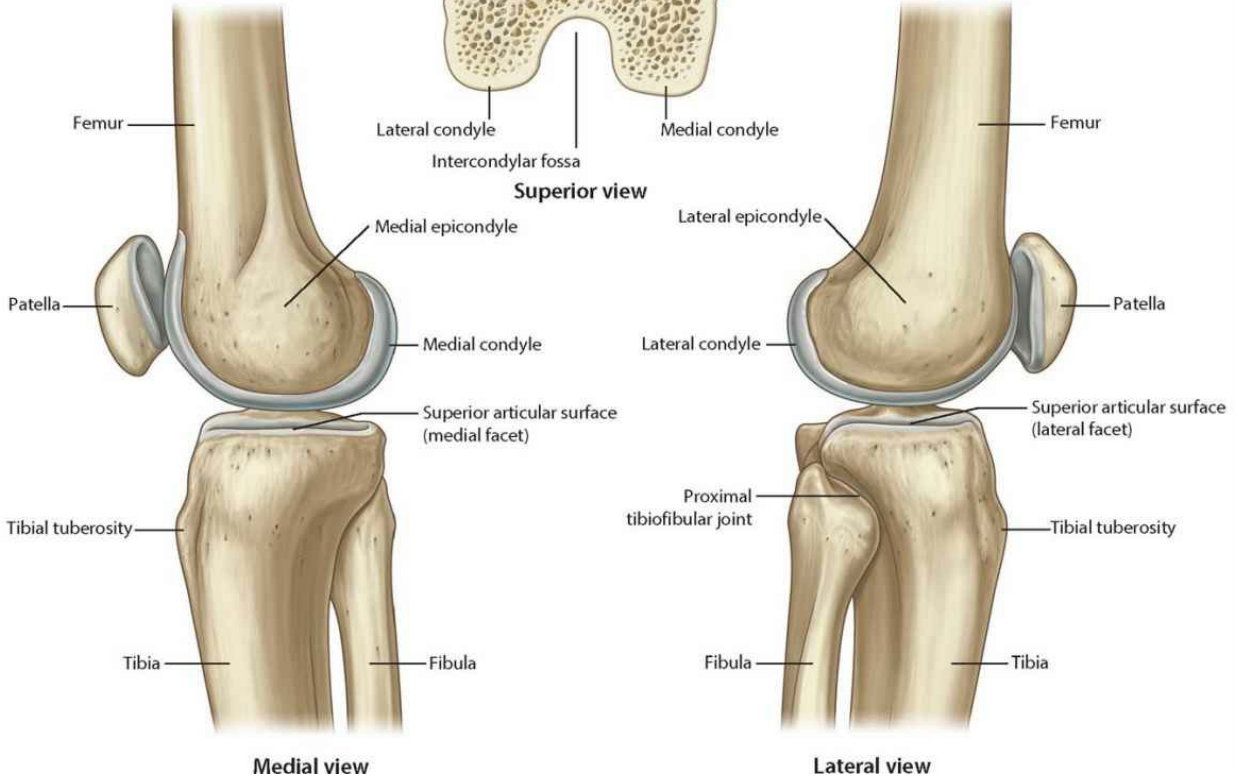
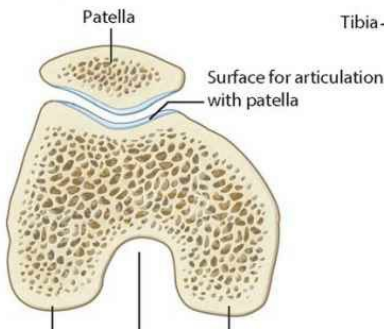
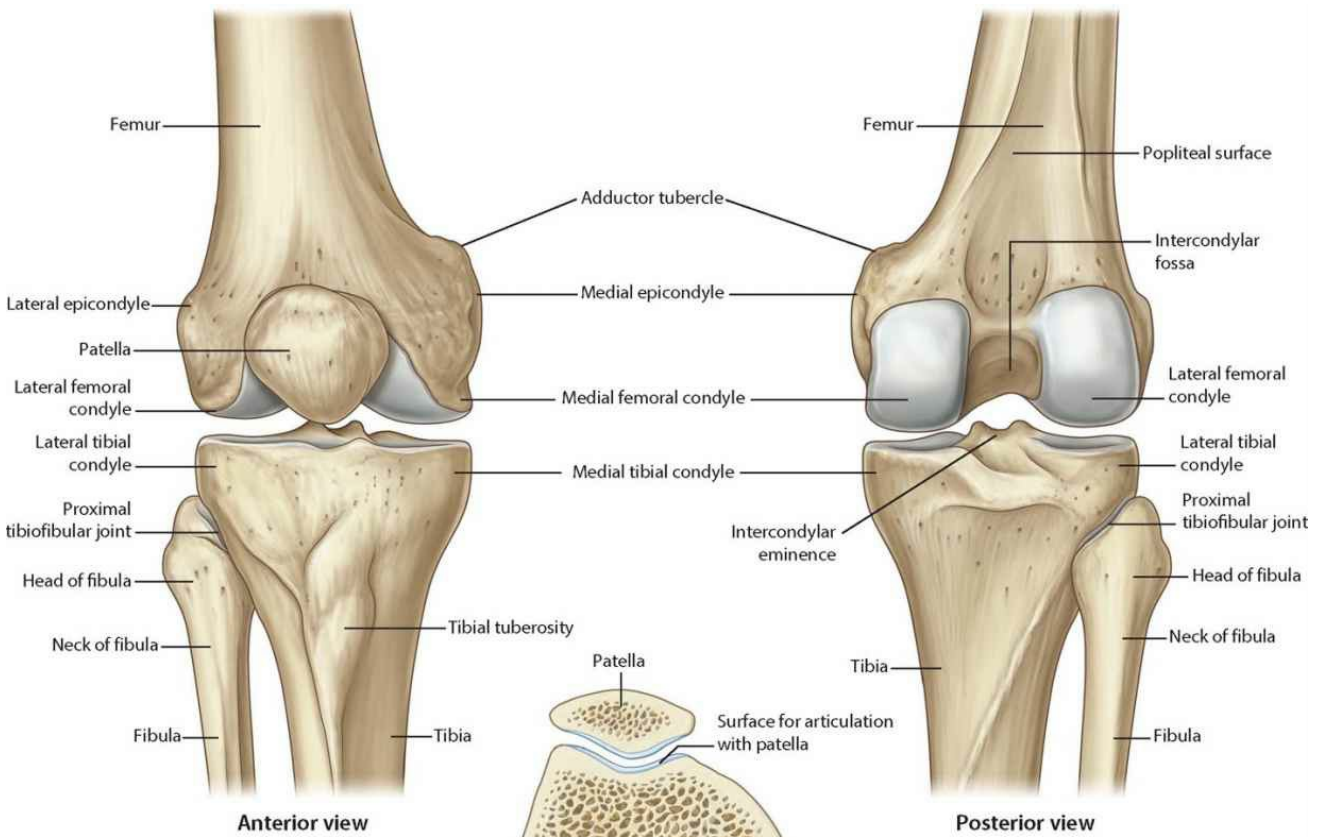




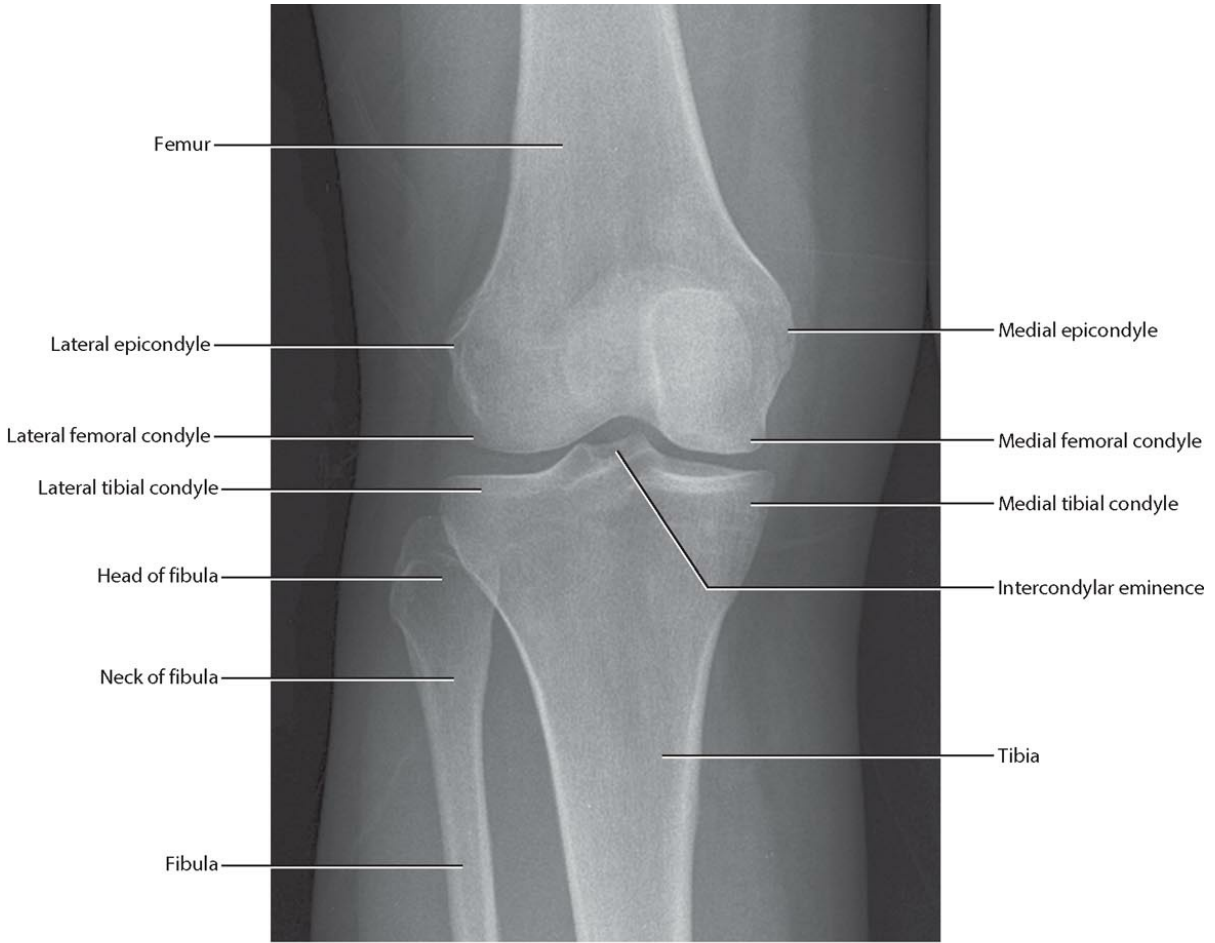
**Transverse/axial sections through the thigh.**  
**A.** Proximal/upper thigh. T1-weighted MR image in axial plane  
**B.** Middle thigh. T1-weighted MR image in axial plane  
**C.** Distal/lower thigh. T2-weighted MR image in axial plane



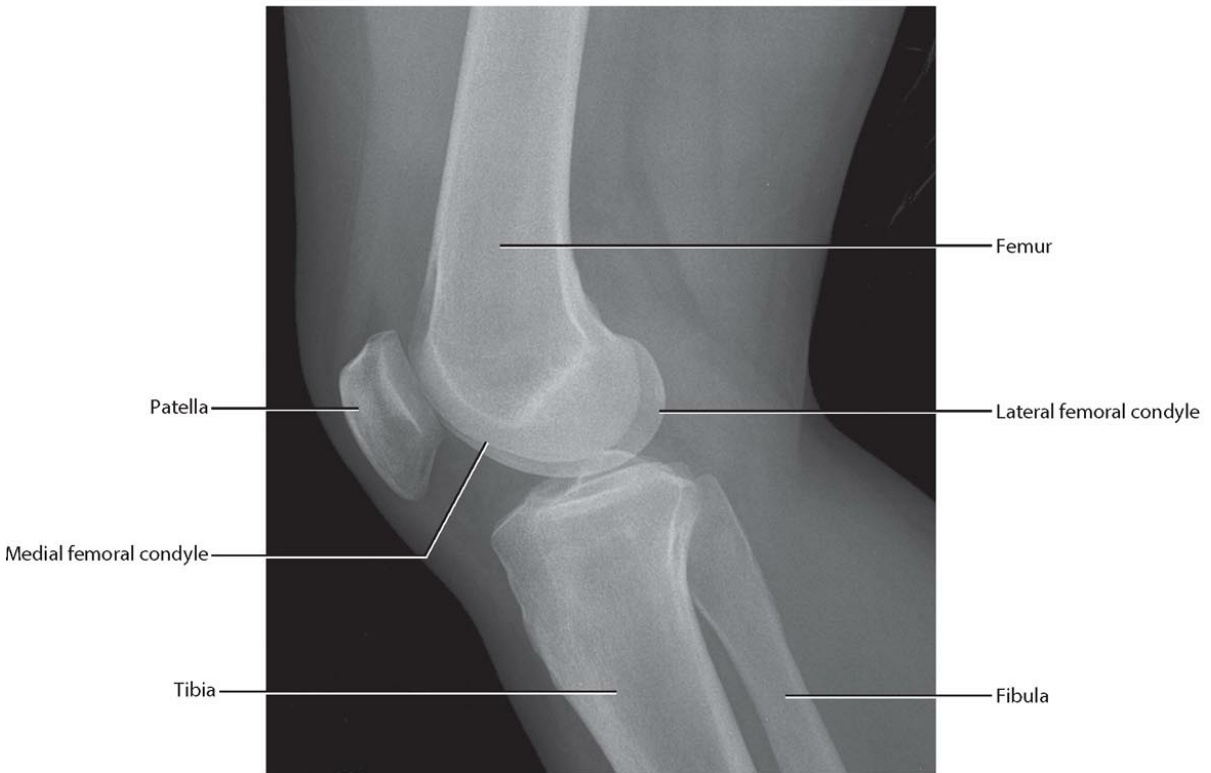
# Knee joint







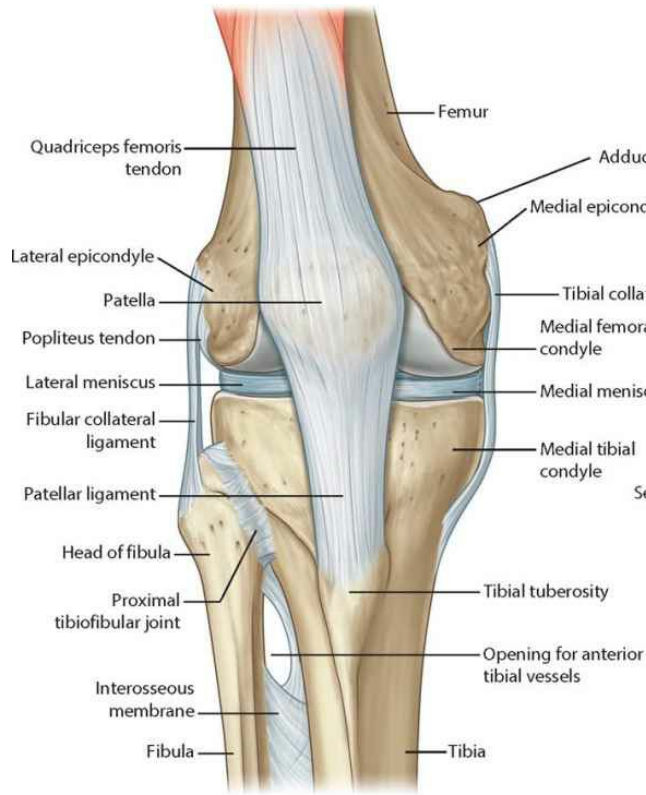**Normal knee joint.**  
 Radiograph, AP view



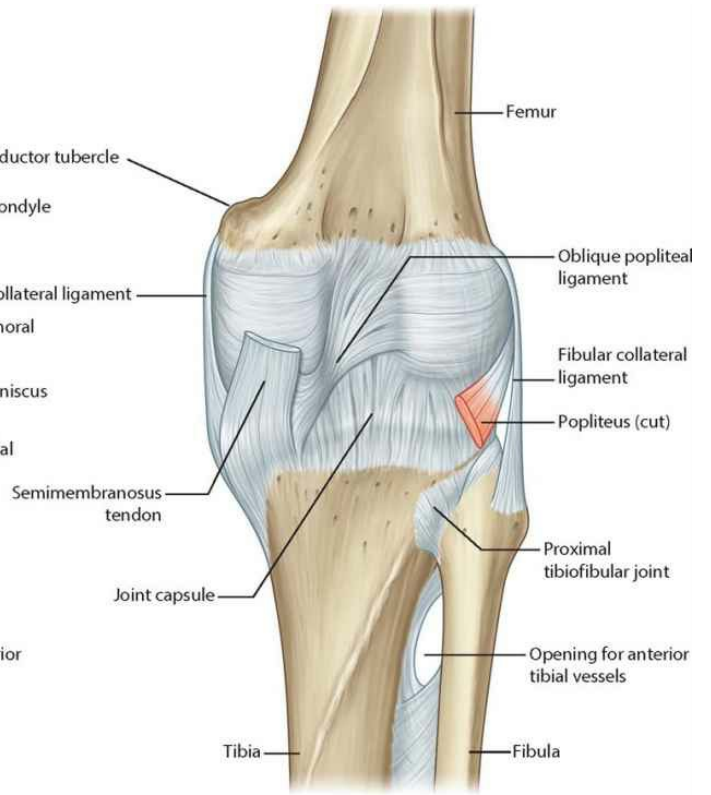
**Normal knee joint.**  
 Radiograph, lateral view



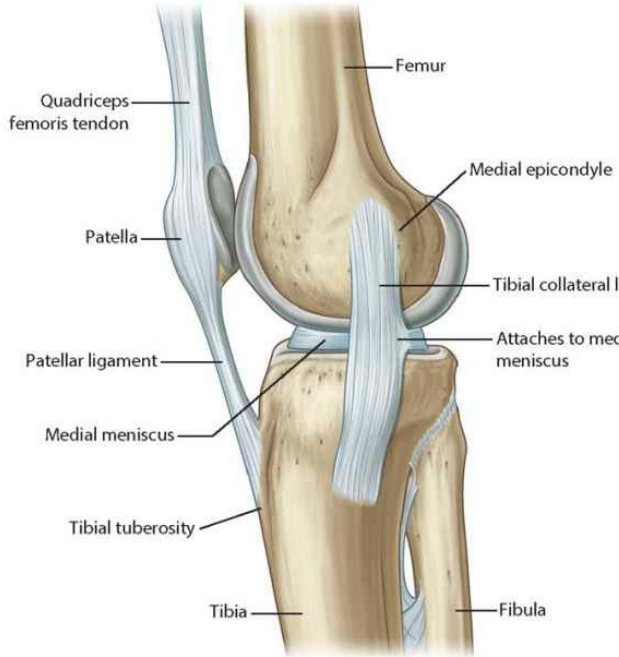
# Ligaments of the knee



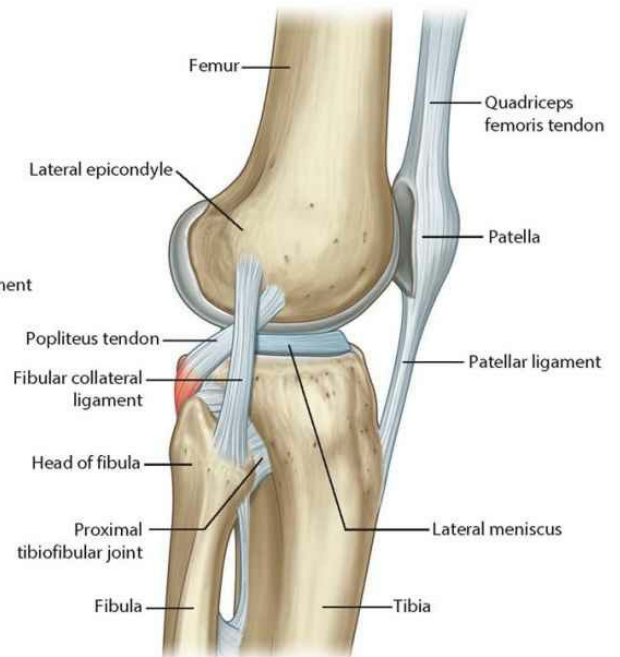
**Anterior view**



**Posterior view**

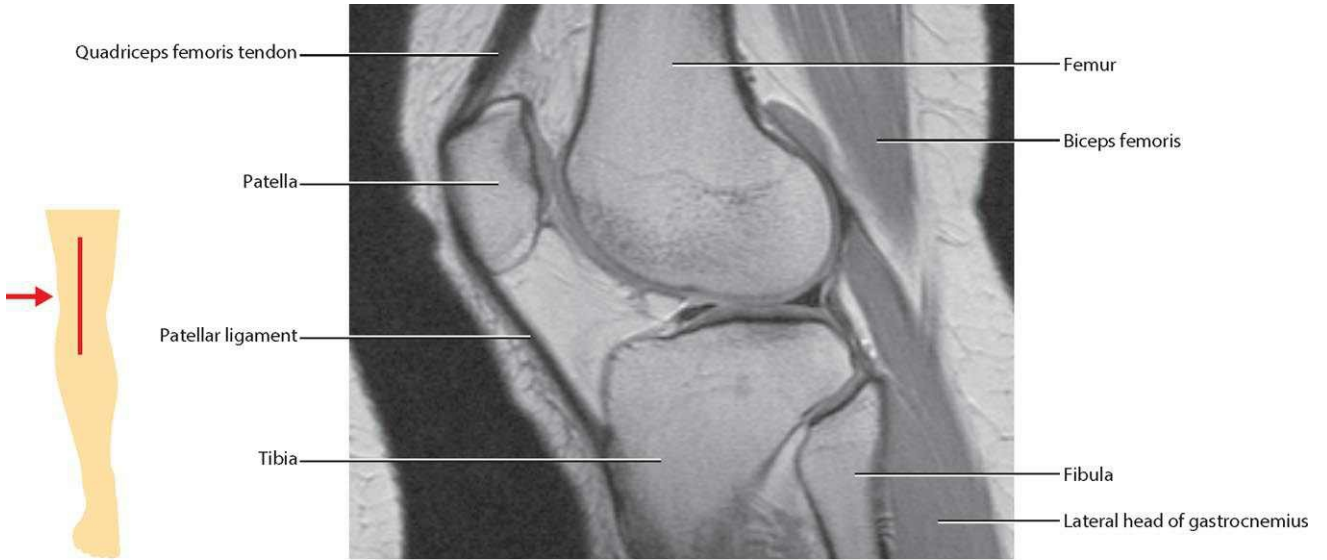

**Medial view**

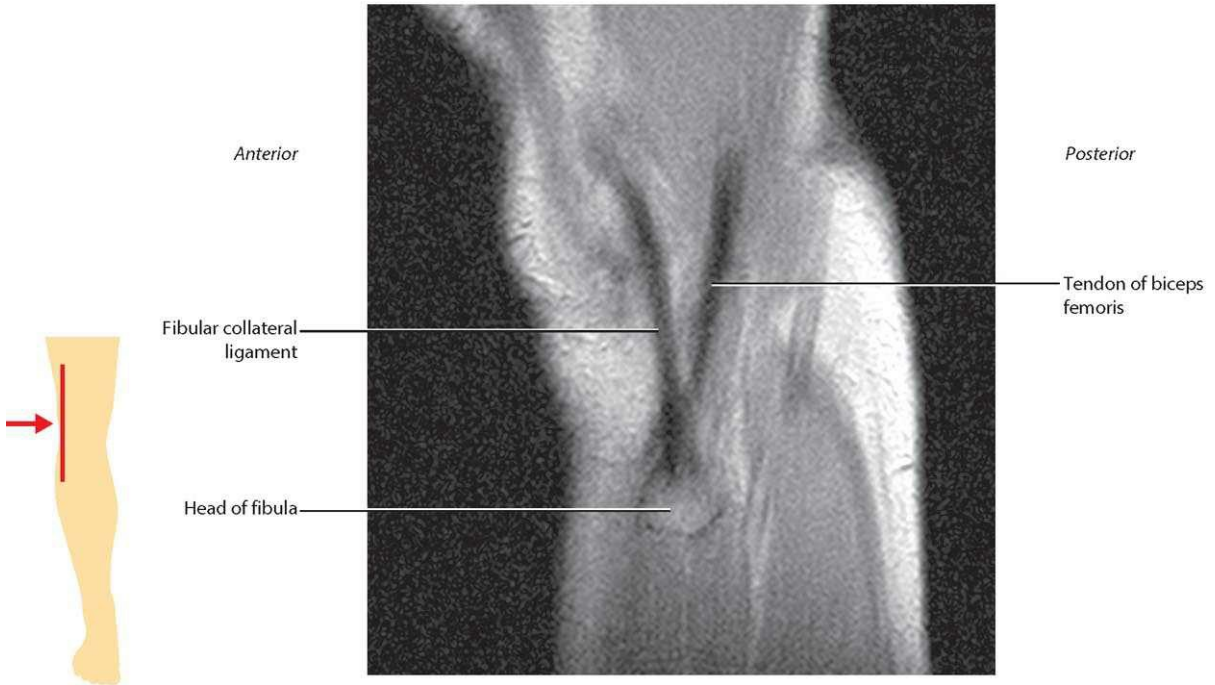


**Lateral view**



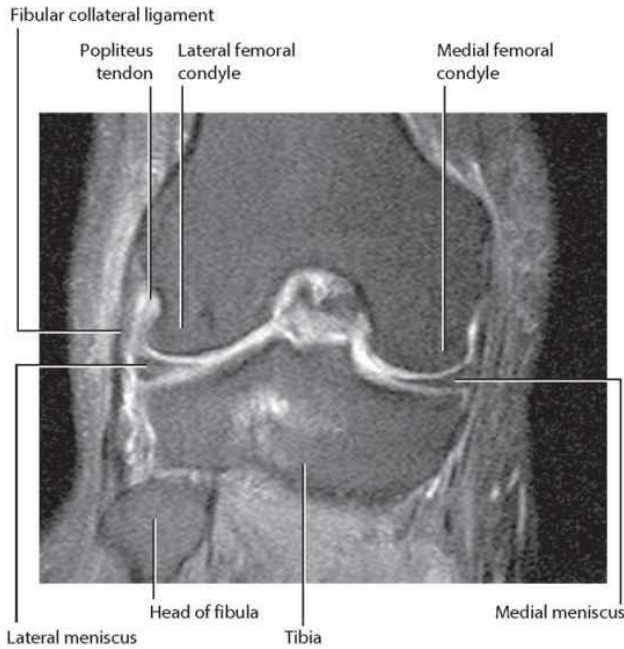


**Normal knee joint.**  
T2-weighted MR image in sagittal plane

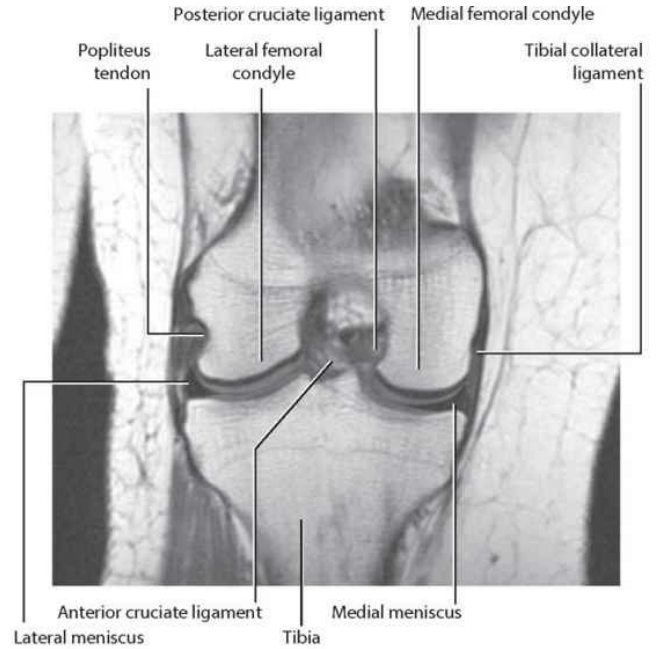


**Unique view showing the fibular collateral ligament and the tendon of the biceps femoris muscle attaching to the head of the fibula.**  
T2-weighted MR image in sagittal plane

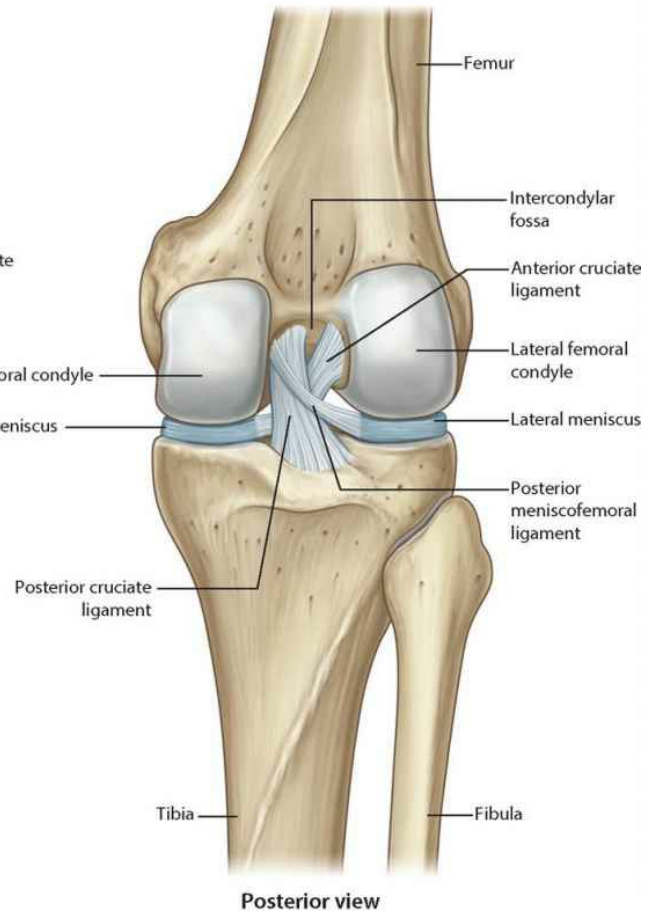
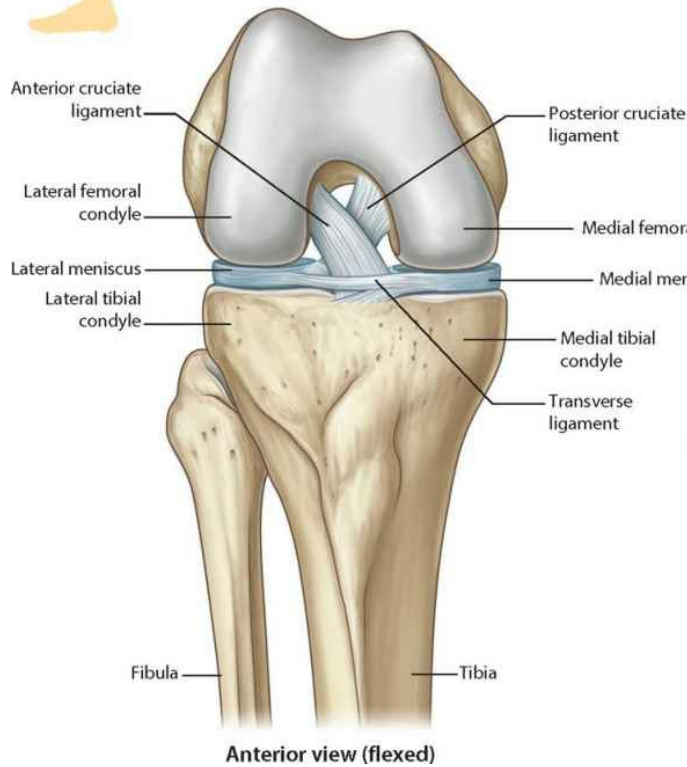
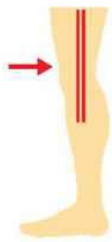
# Menisci and cruciate ligaments



**Coronal view of knee joint showing the fibular collateral ligament and its relationship to surrounding structures.**  
T2-weighted MR image in coronal plane

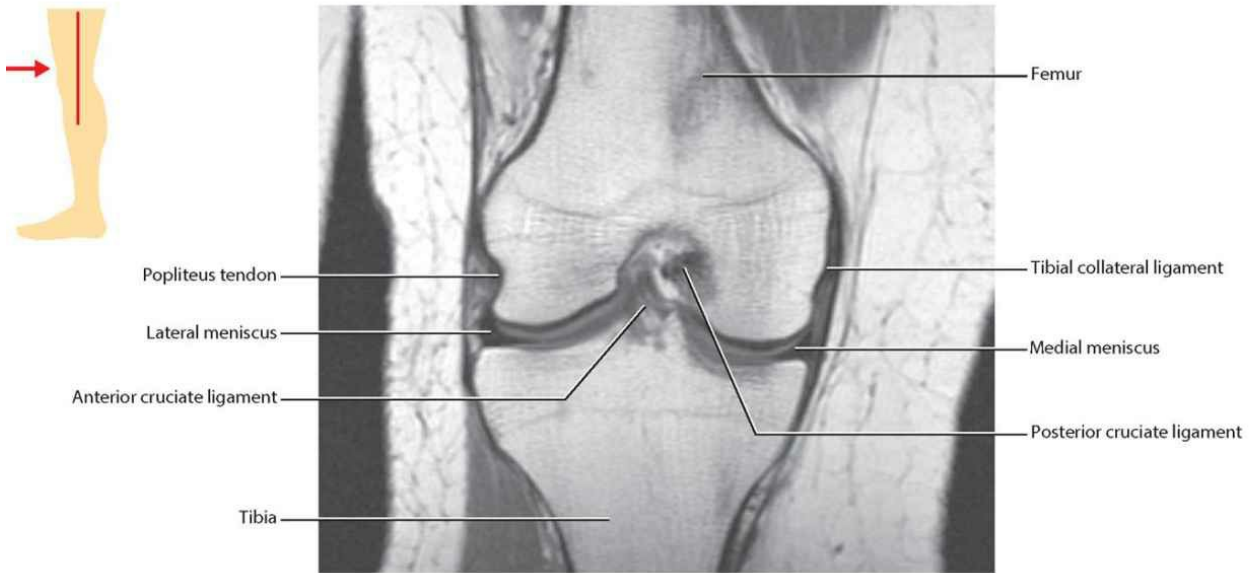
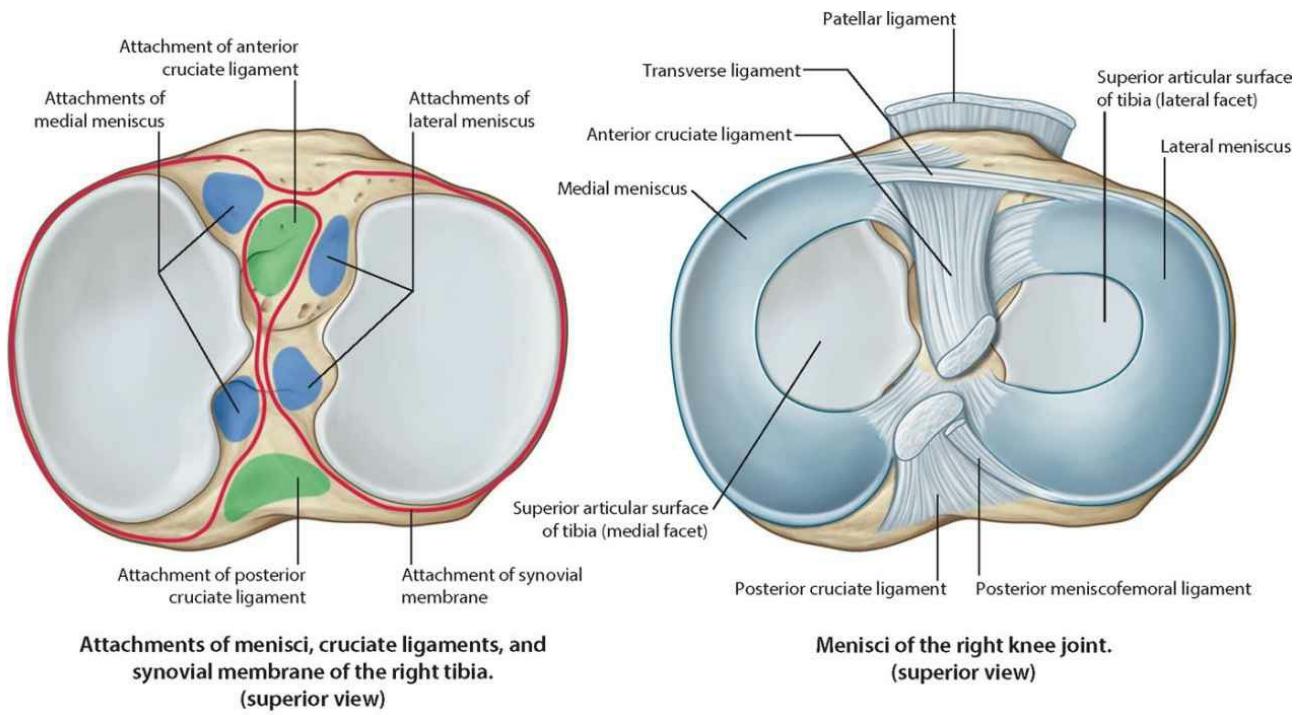


**Anterior view of knee joint showing the relationship between the tibial collateral ligament and the medial meniscus.**  
T1-weighted MR image in coronal plane

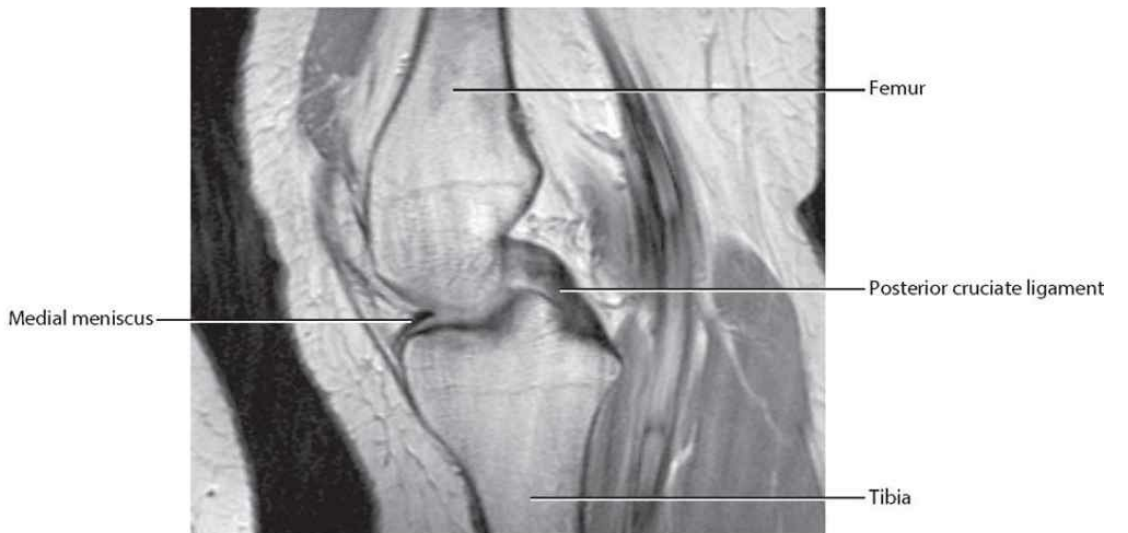
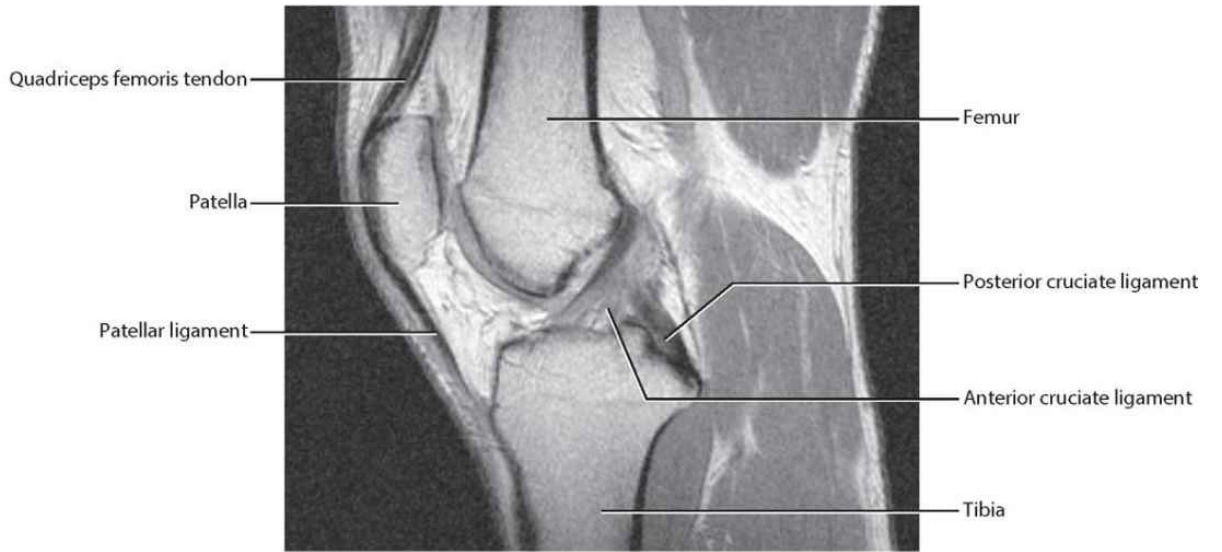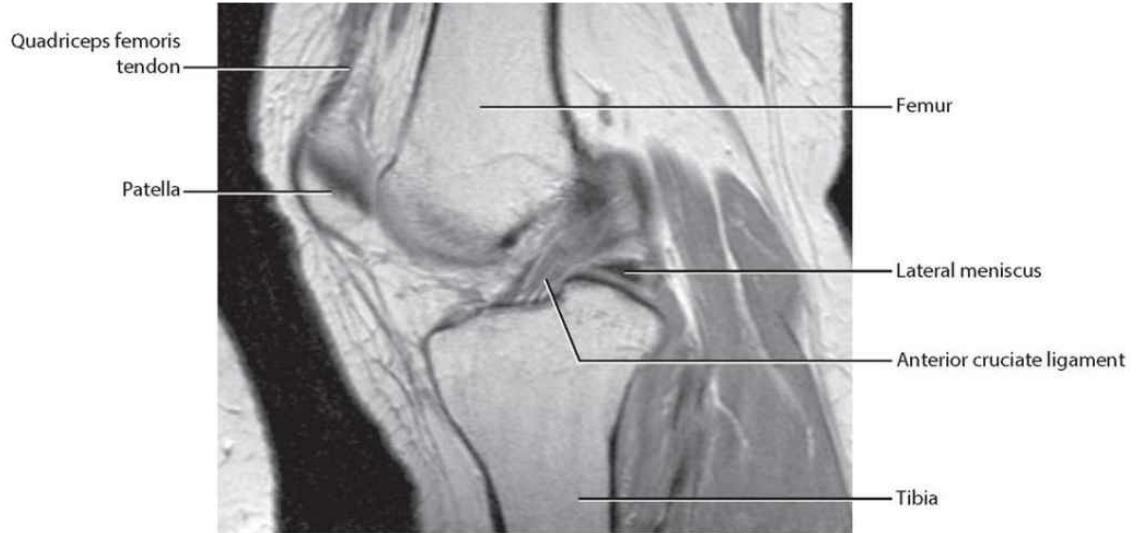






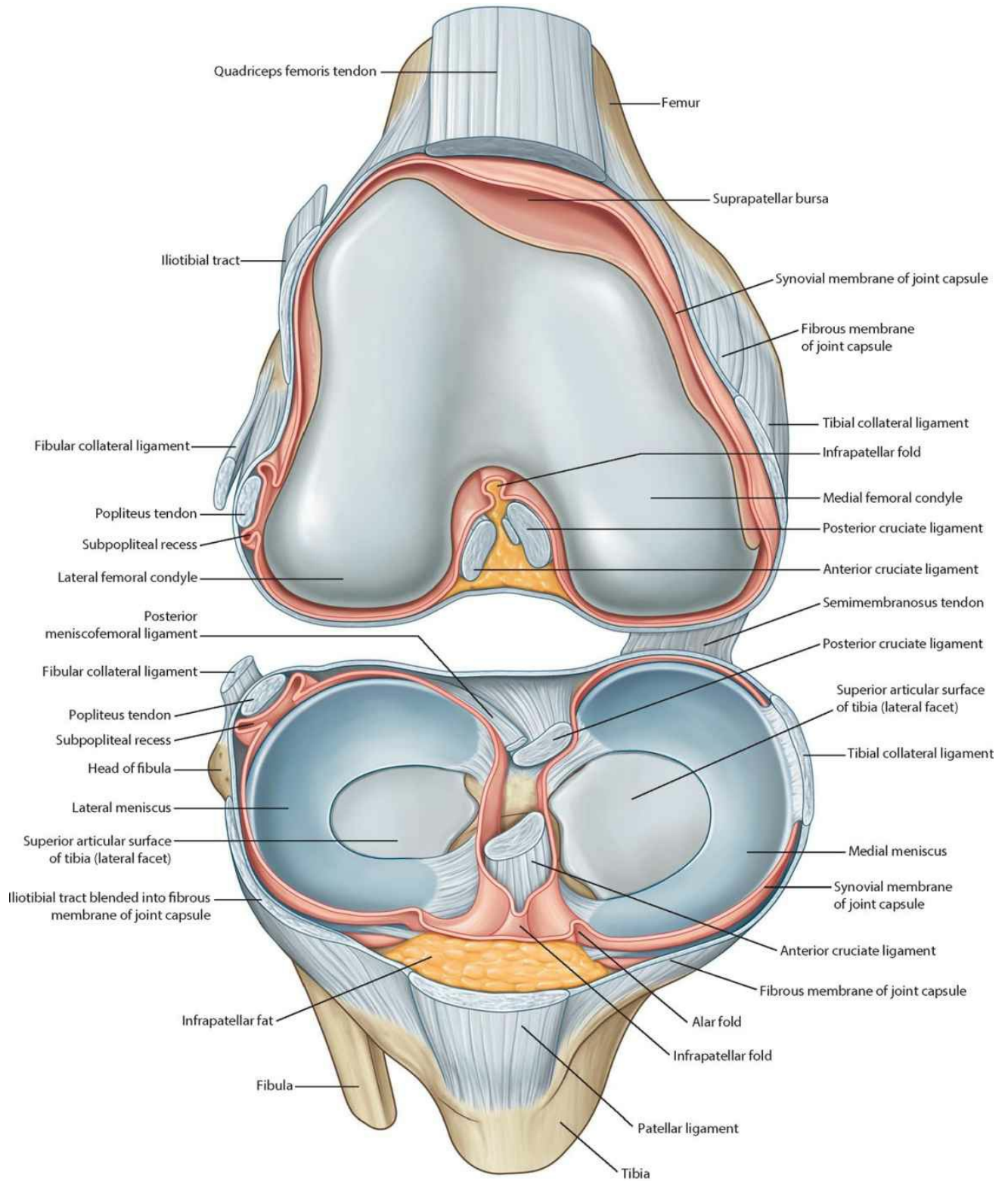


**Anterior view of knee joint showing the anterior and posterior cruciate ligaments.**  
 T2-weighted MR image in coronal plane



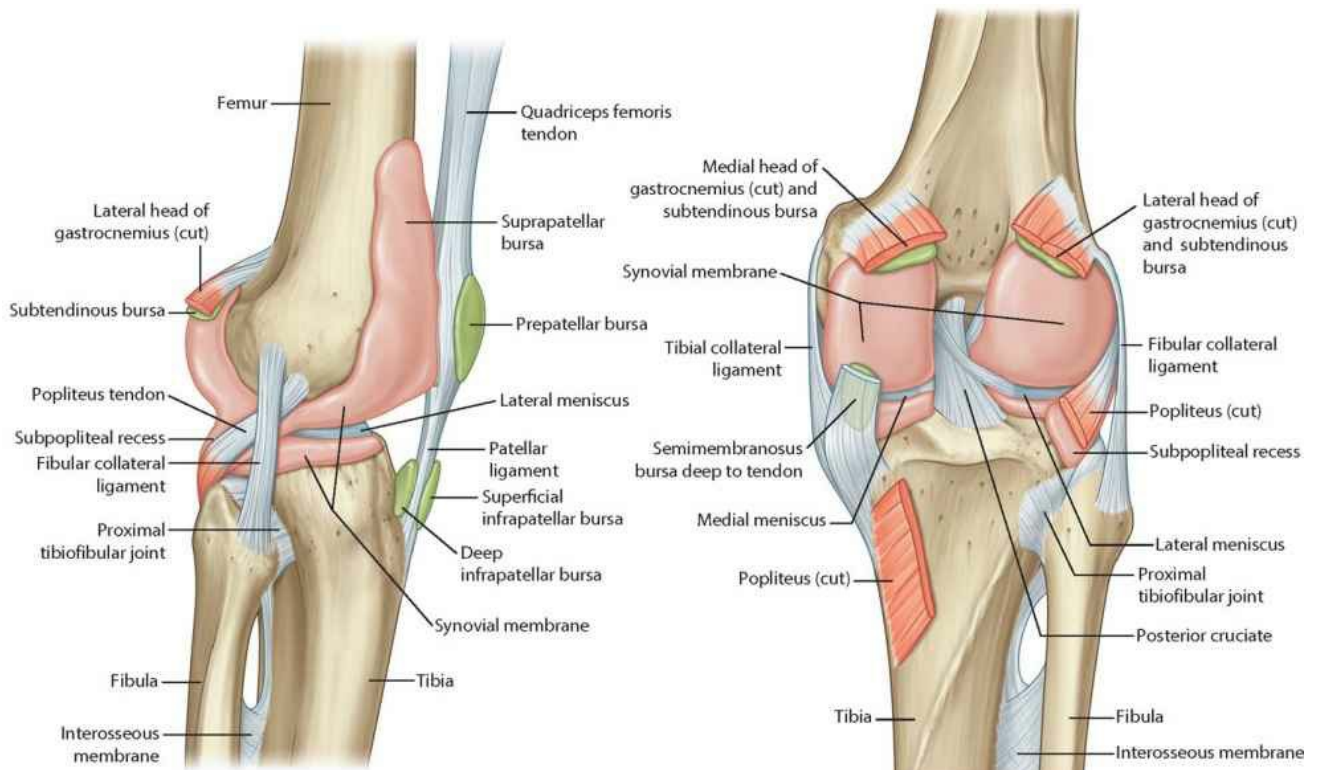
**A series of images moving from lateral to medial showing the relationship between anterior and posterior cruciate ligaments.**  
T2-weighted MR images in sagittal plane





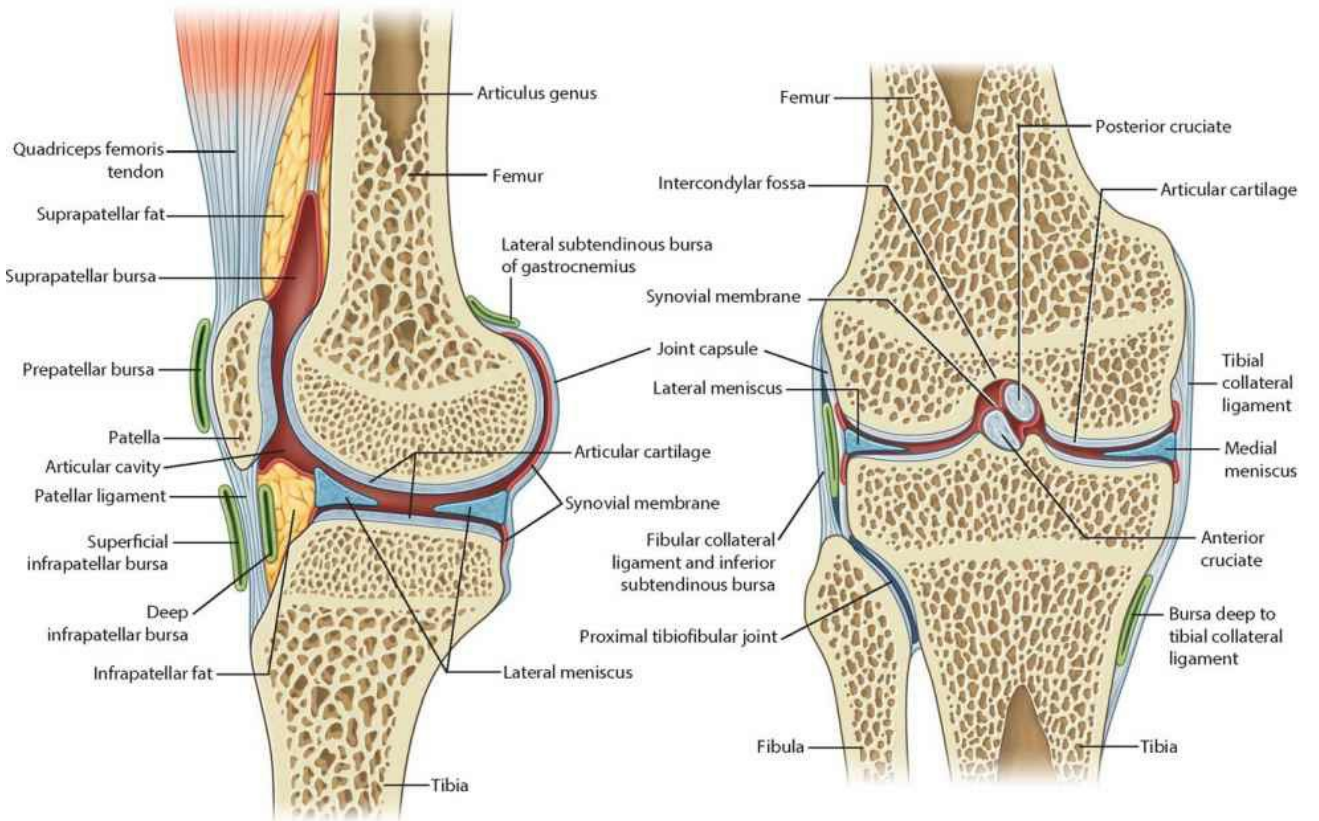
**Knee joint with patella removed (anterosuperior view)**

## **Knee: bursa and capsule**



Lateral view

Posterior view

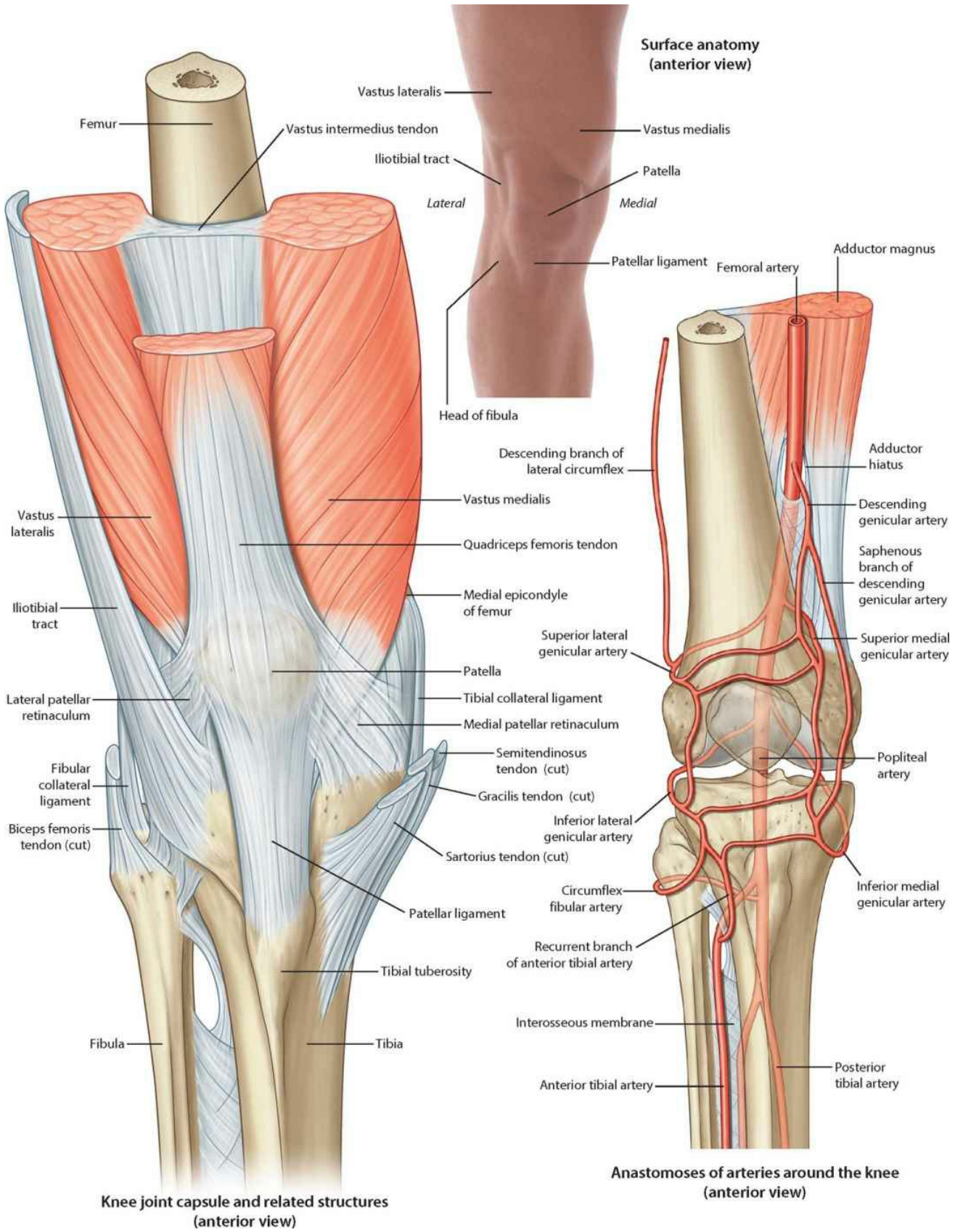


Paramedian section through knee joint

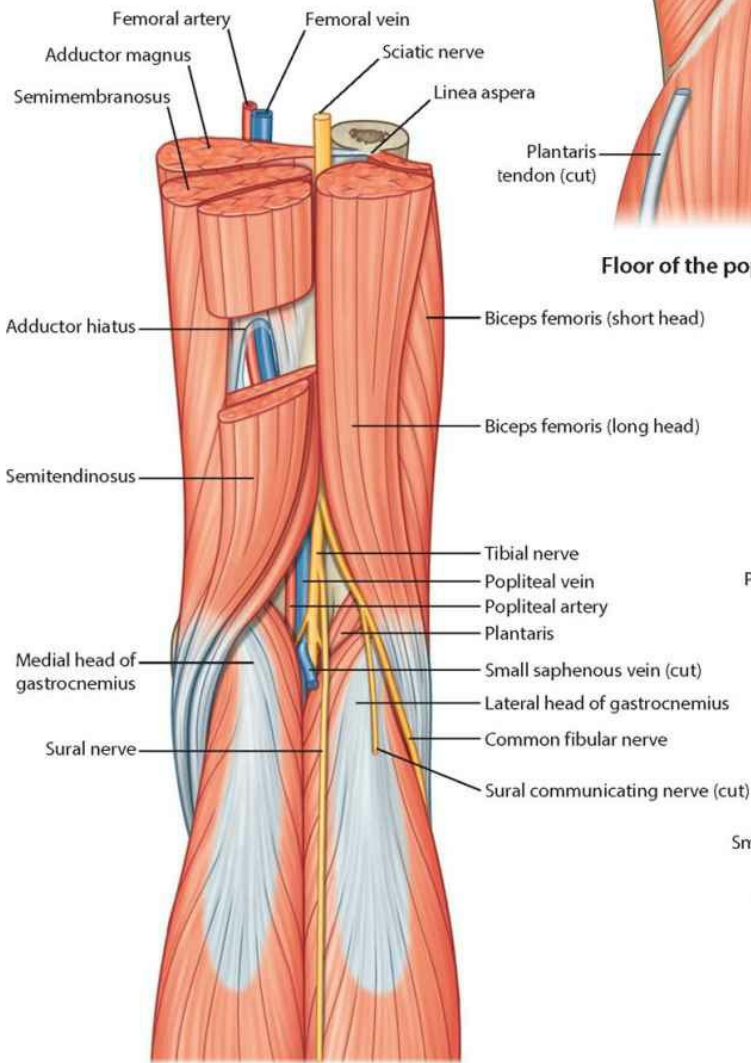
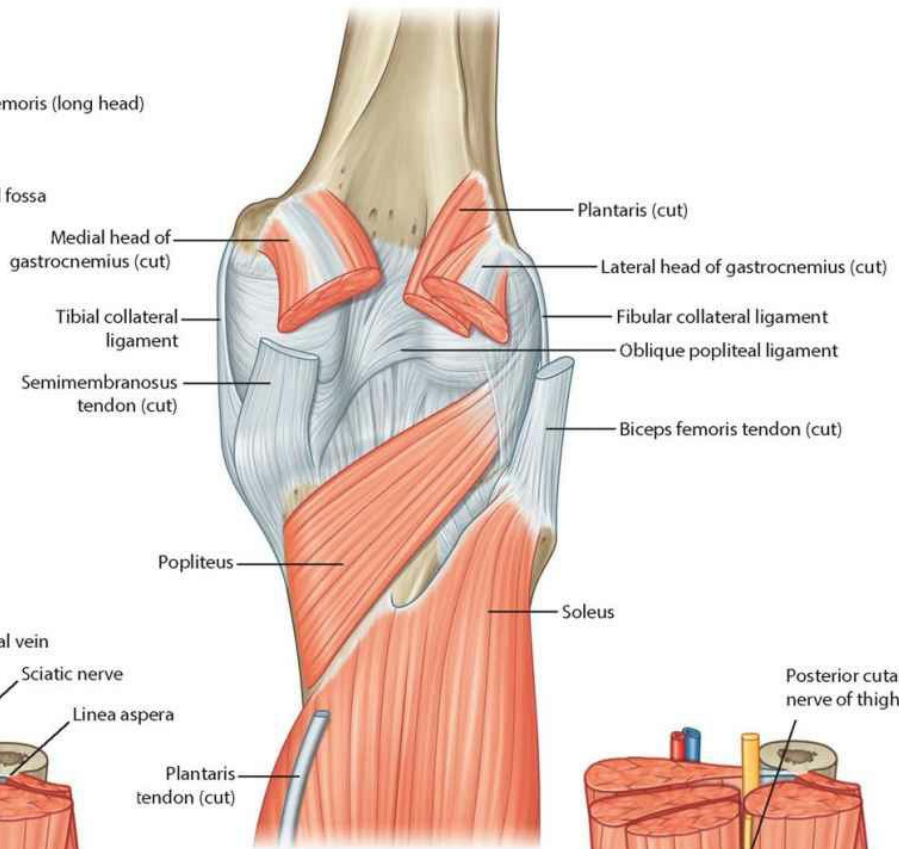
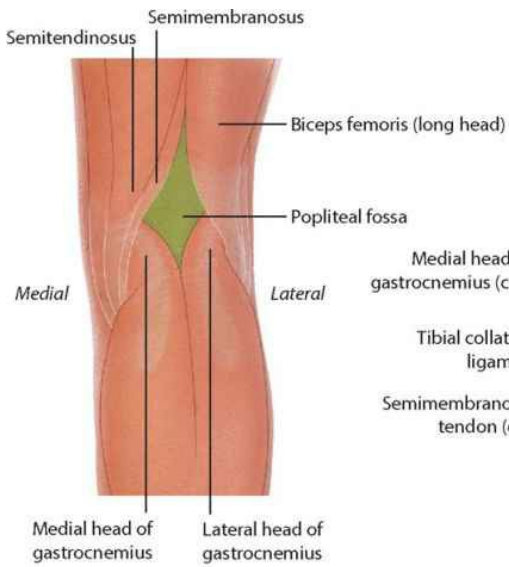
Coronal section through knee joint (anterior view)

## **Knee surface: muscles, capsule, and arteries**

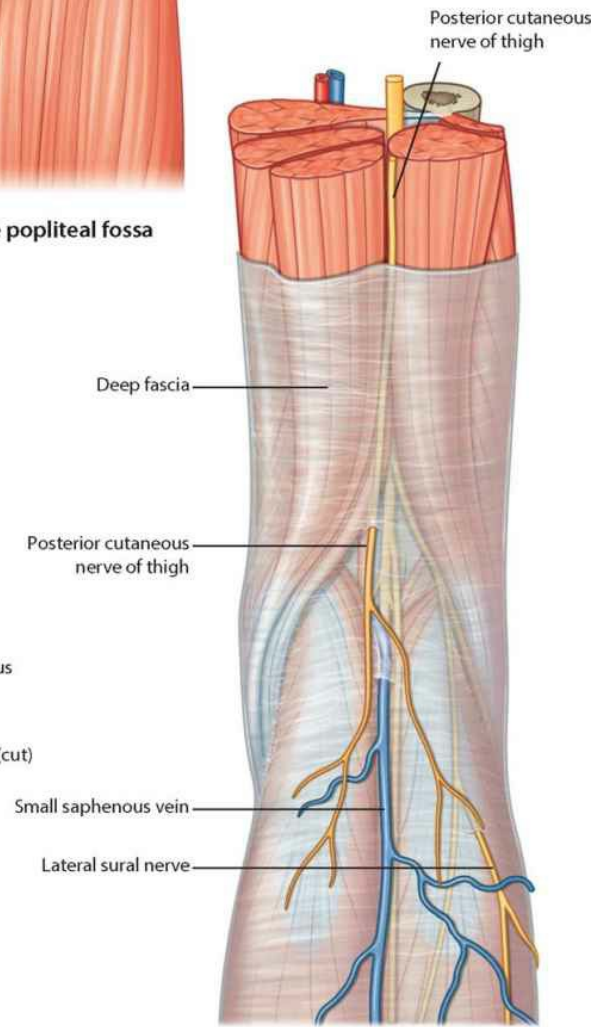




# Popliteal fossa



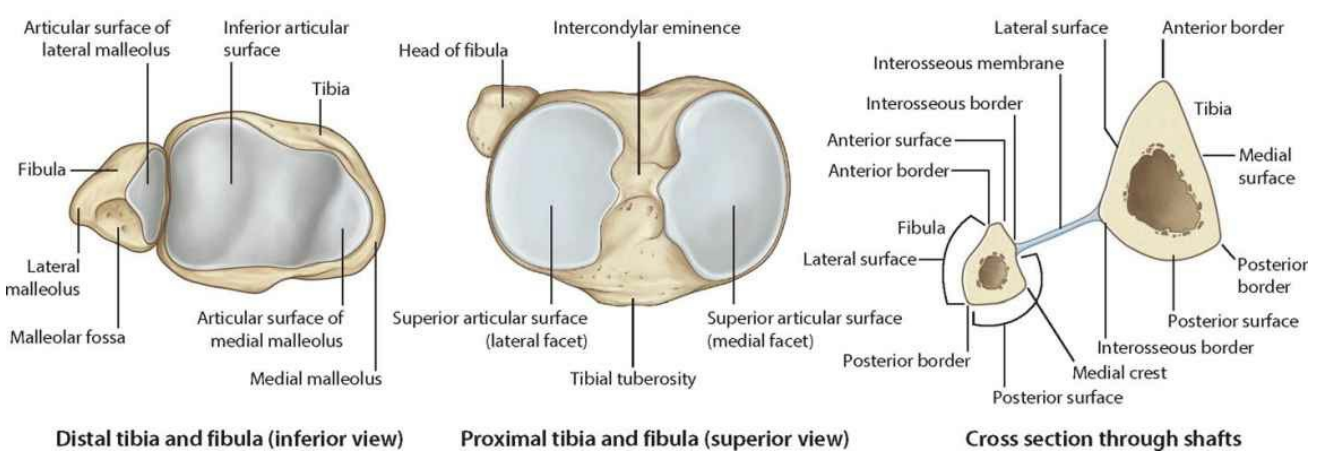
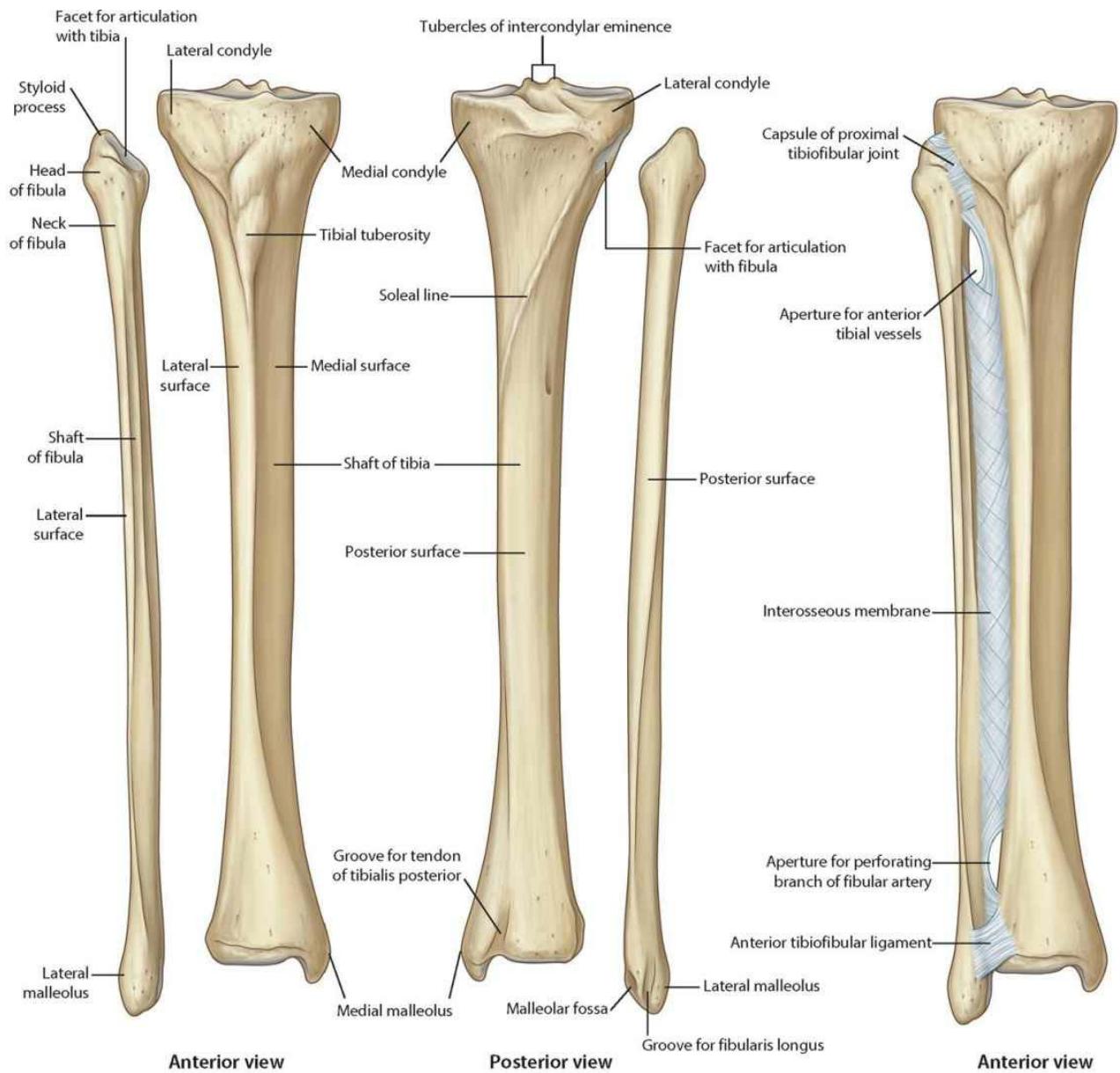
Floor of the popliteal fossa



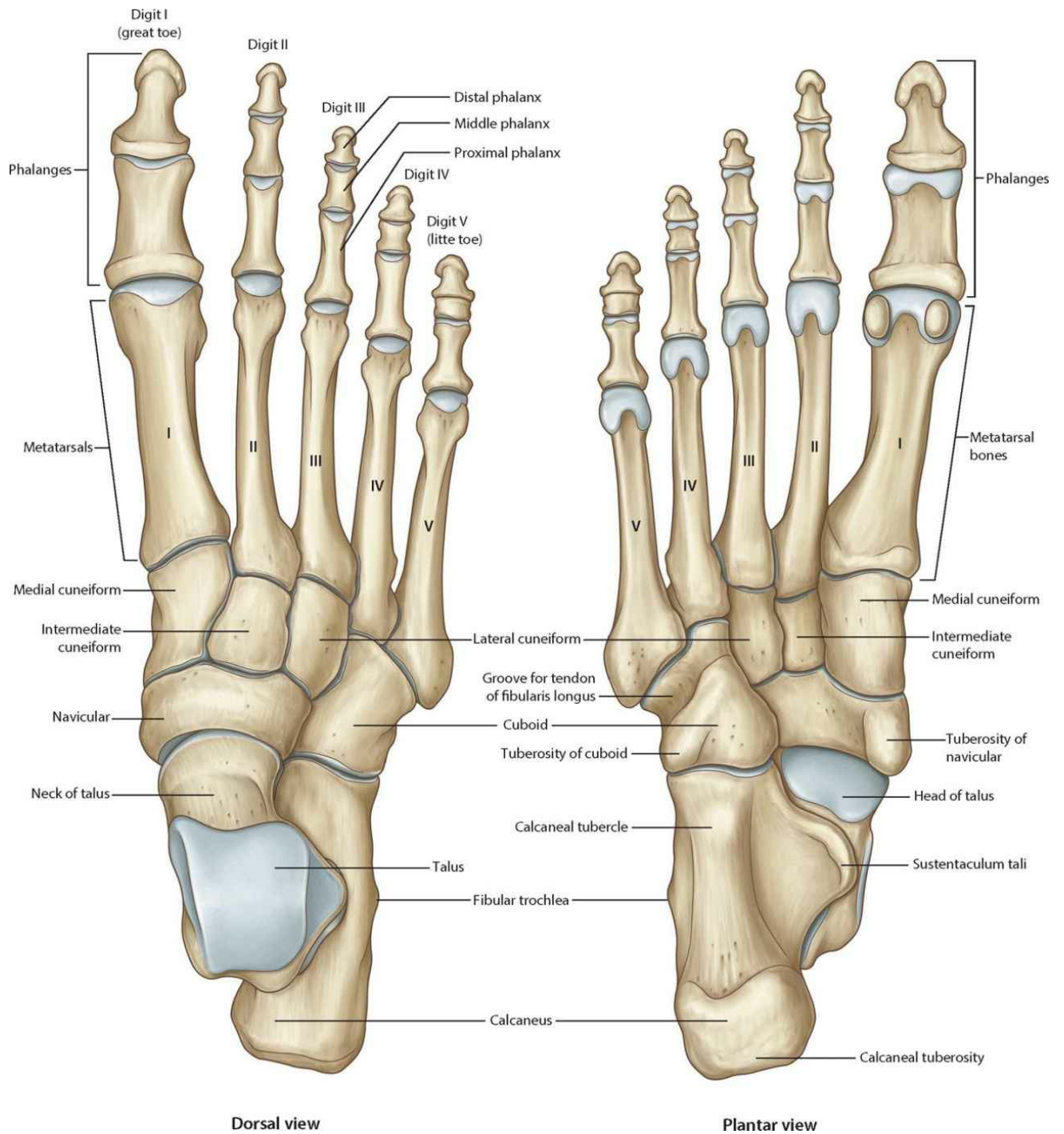
Structures in the popliteal fossa

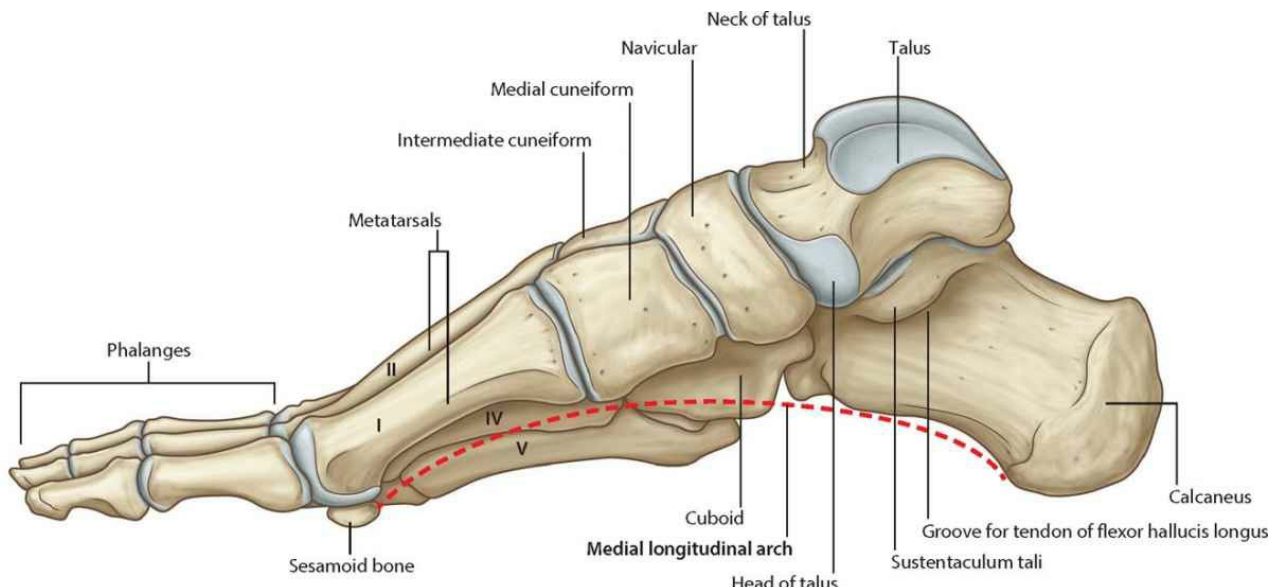
Superficial structures

# Tibia and fibula

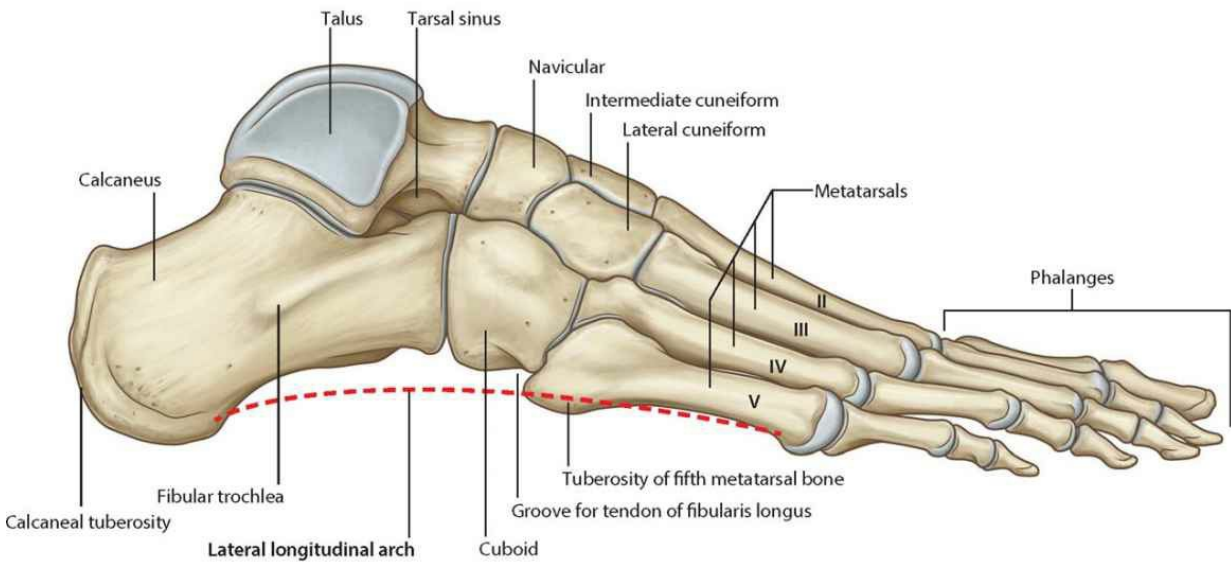


# Bones of the foot

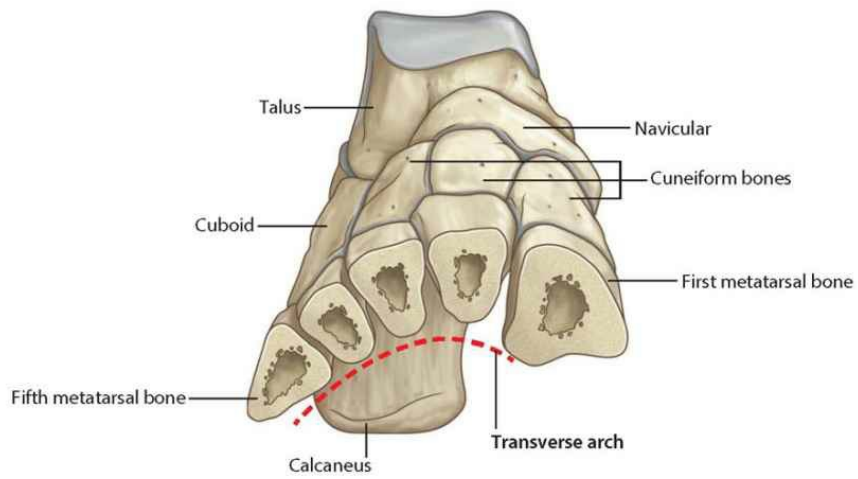




**Medial view**



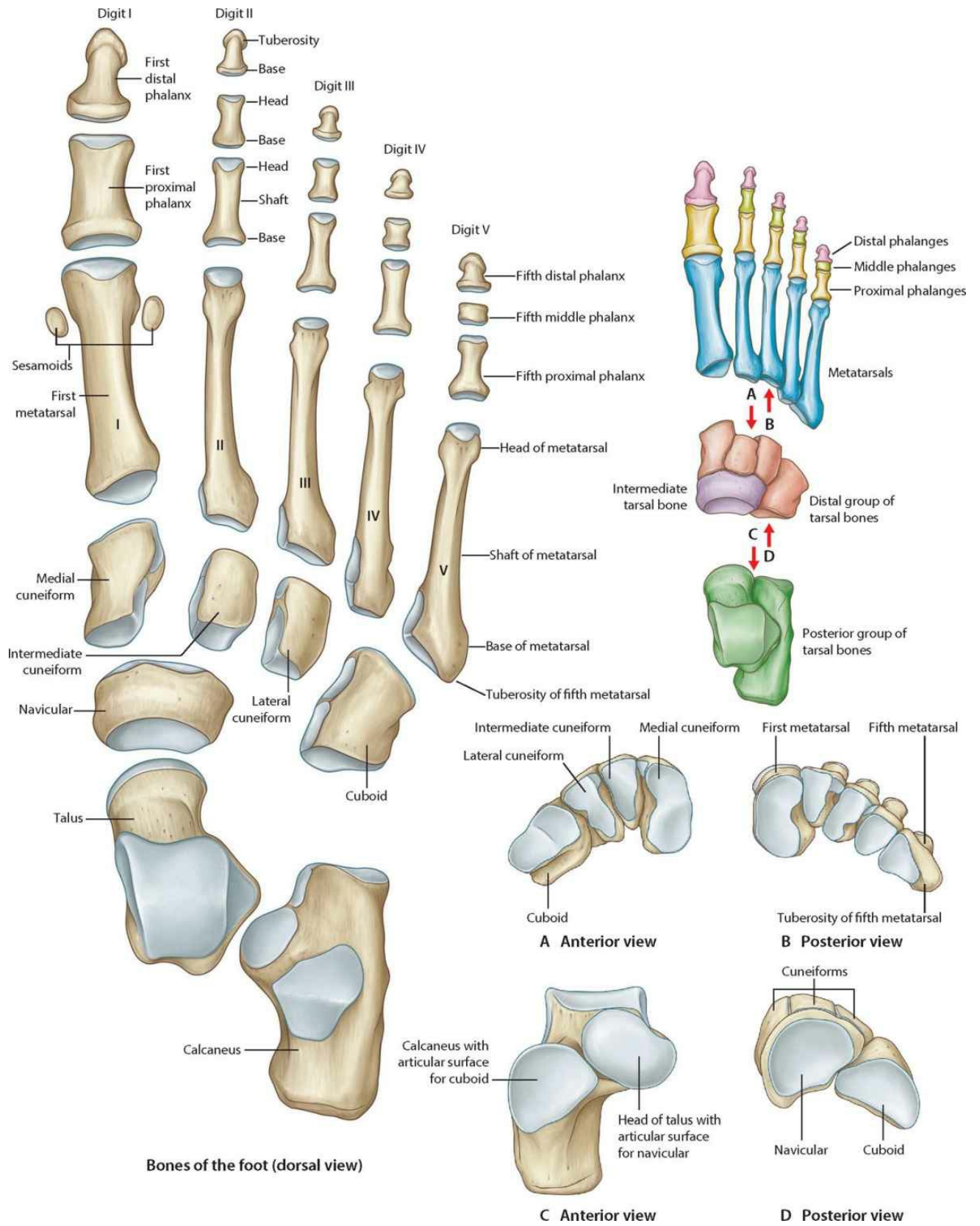
**Lateral view**



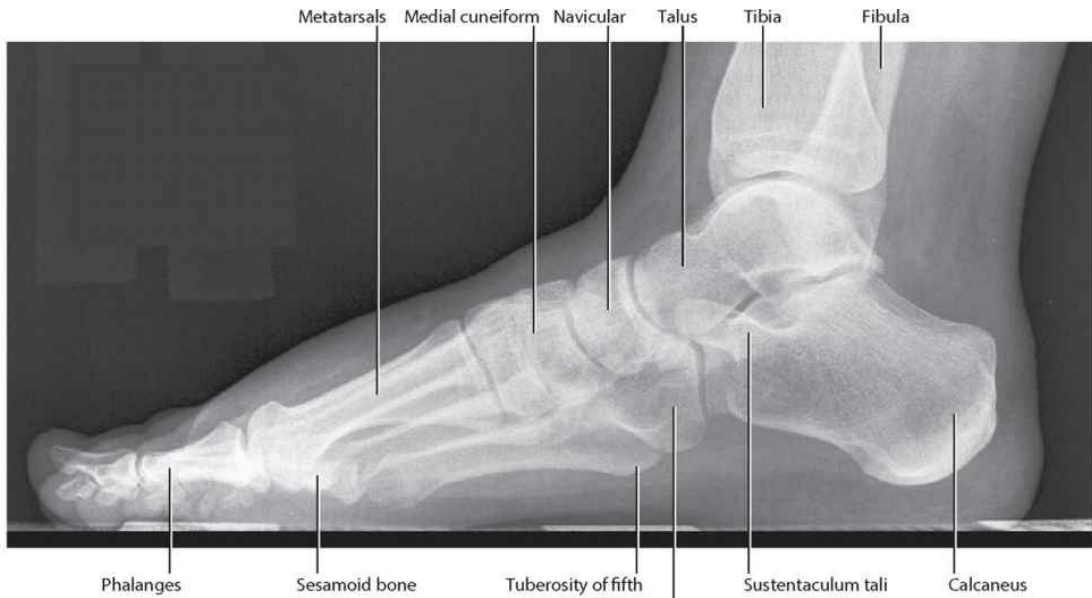
**Cross section through the foot bones**



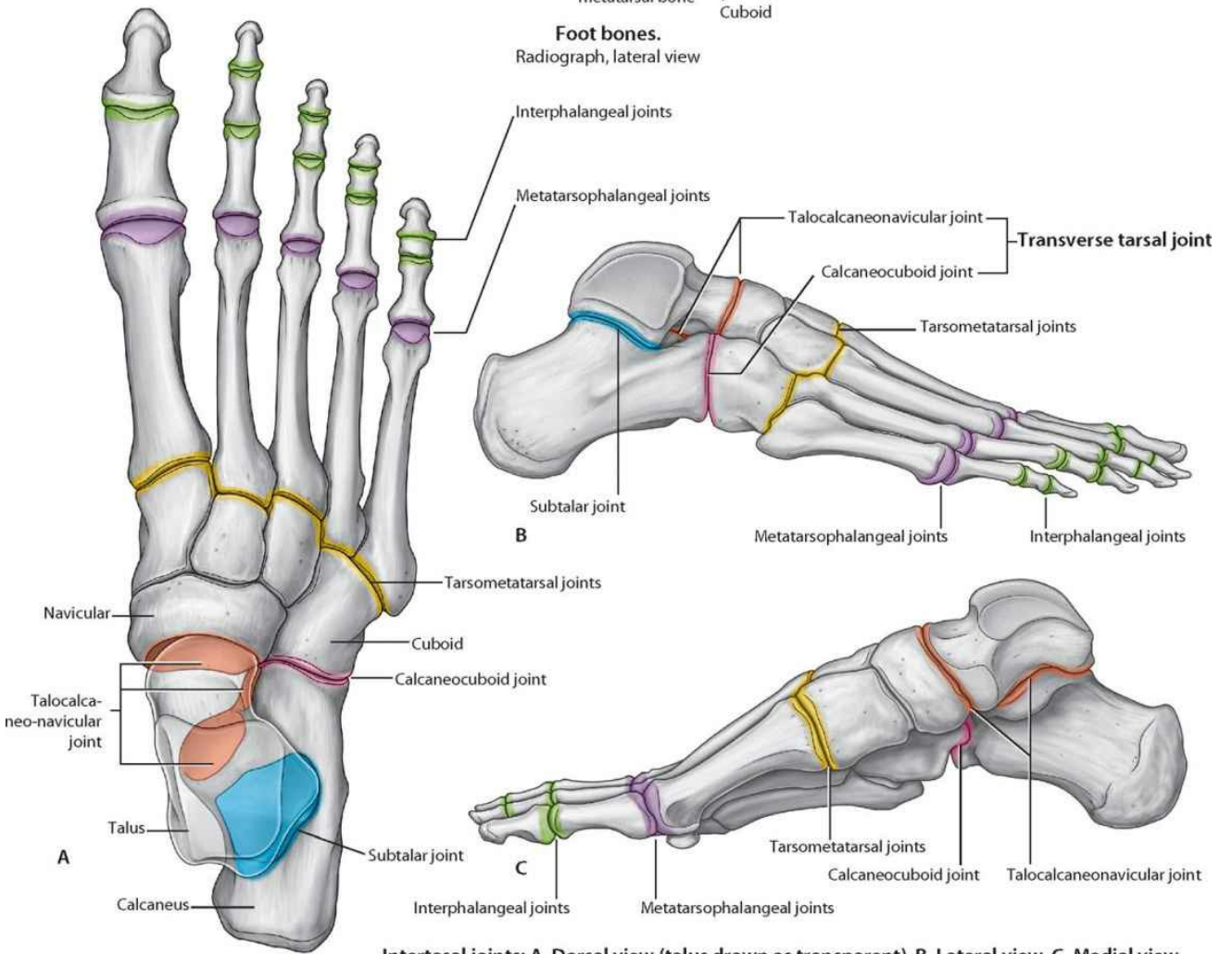




# **Bones and joints of the foot**

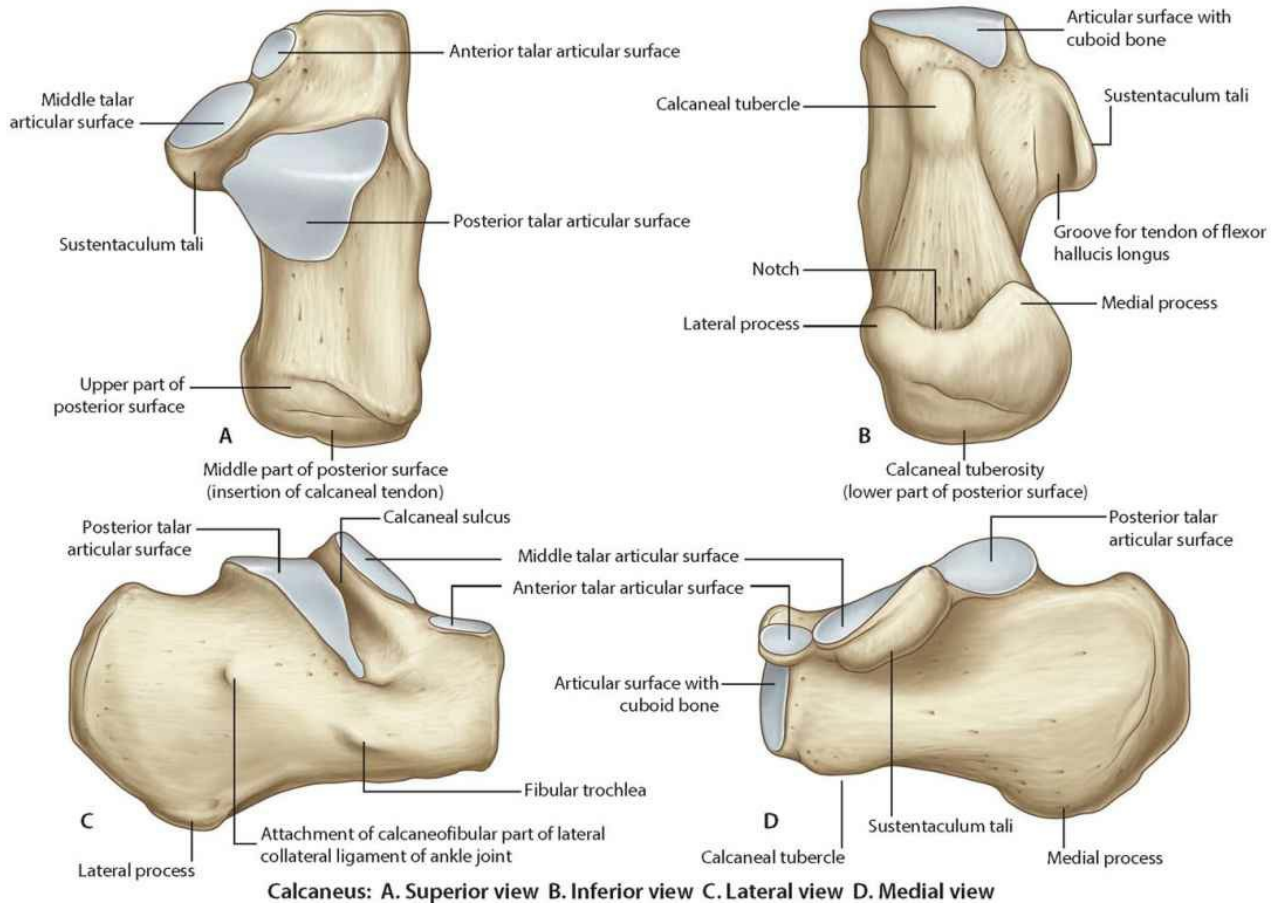
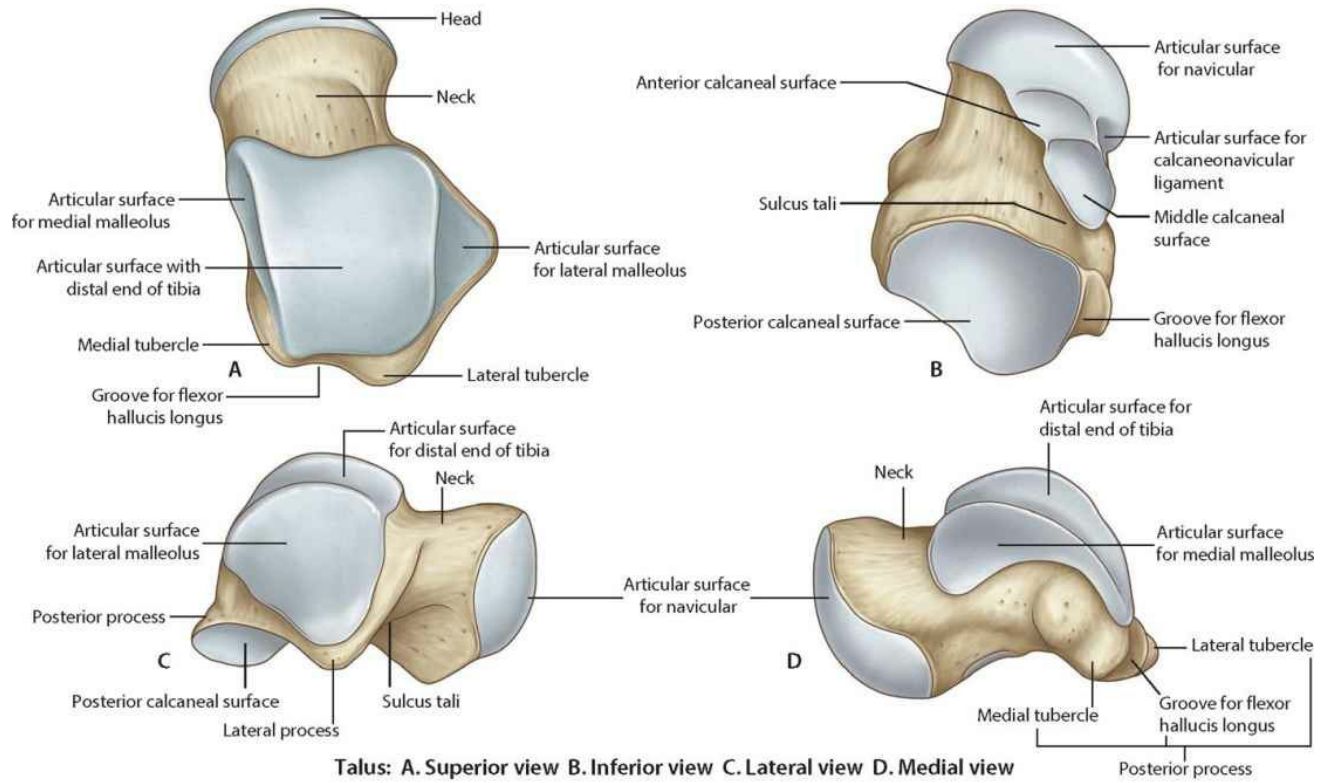


**Foot bones.**  
Radiograph, lateral view

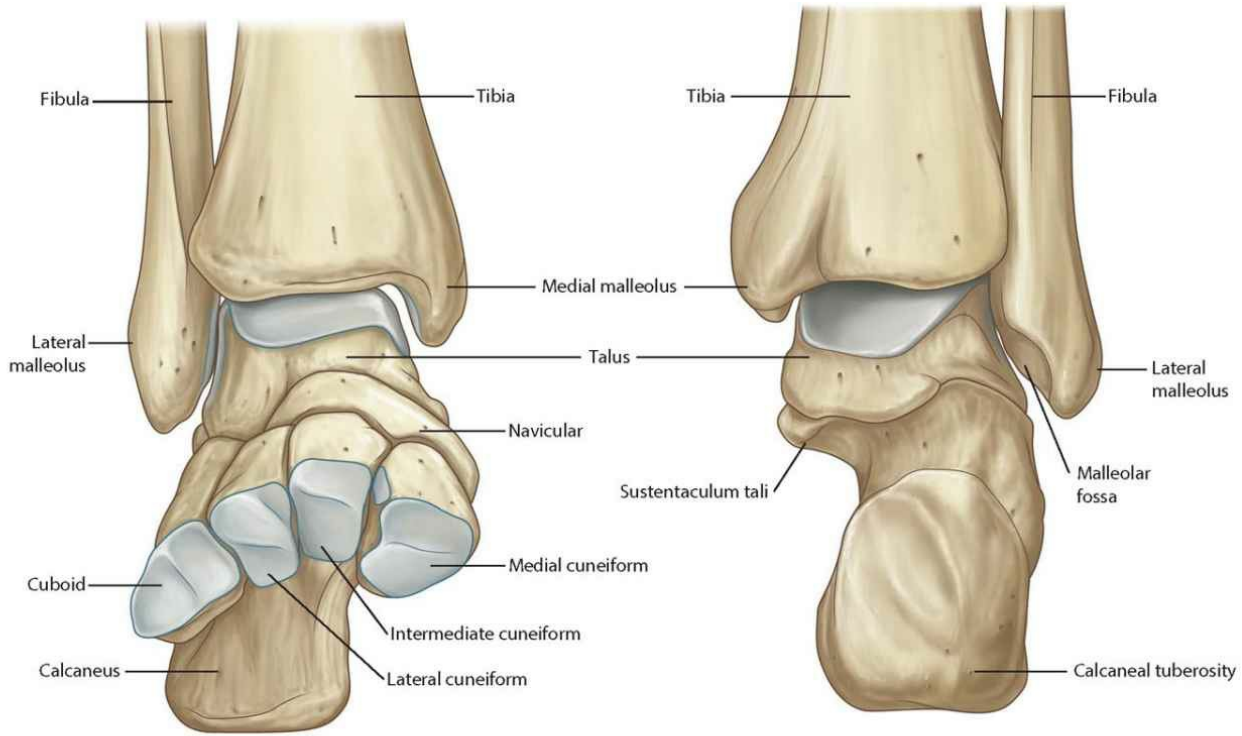


**Intertarsal joints: A. Dorsal view (talus drawn as transparent) B. Lateral view C. Medial view**

# Talus and calcaneus

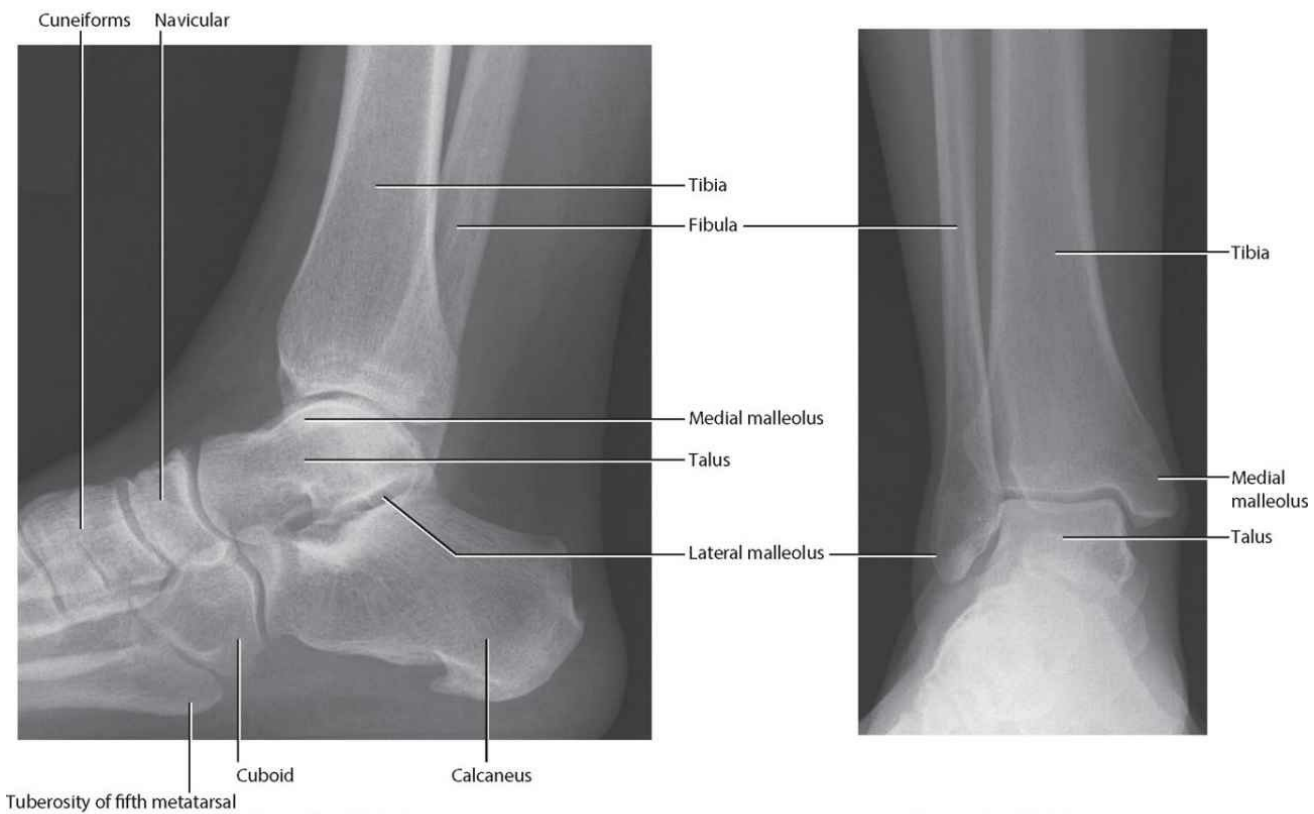


# Ankle joint



**Anterior view  
(metatarsals and phalanges removed)**

**Posterior view**

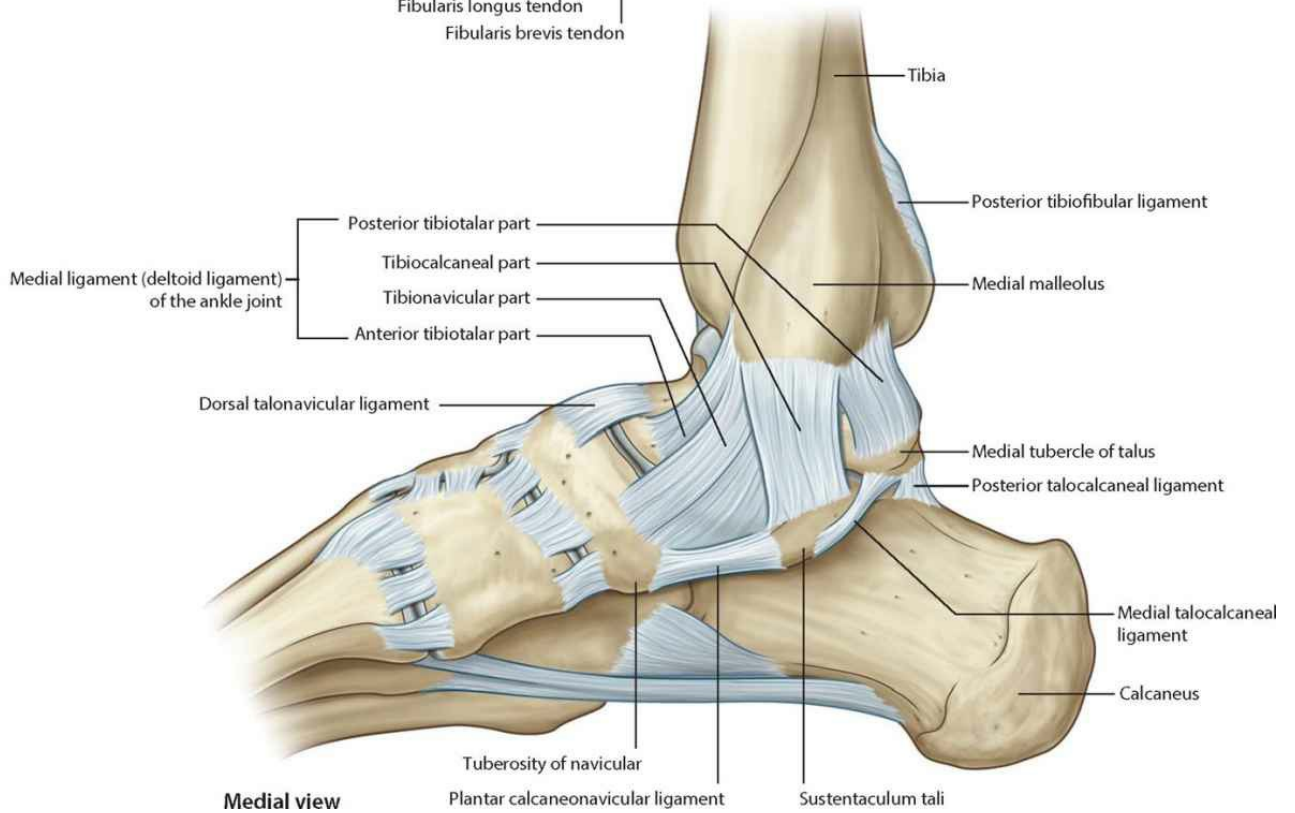
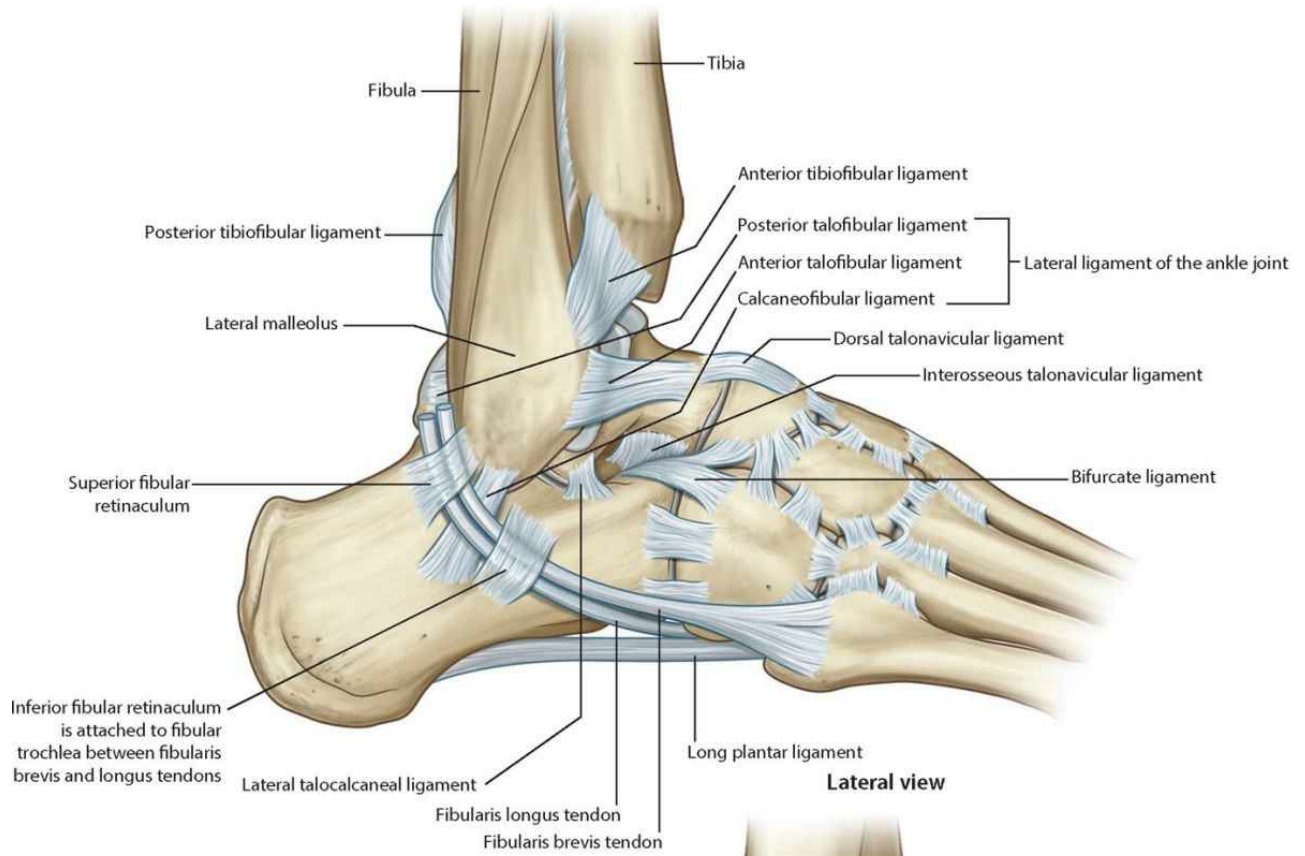


**Normal ankle joint.  
Radiograph, lateral view**

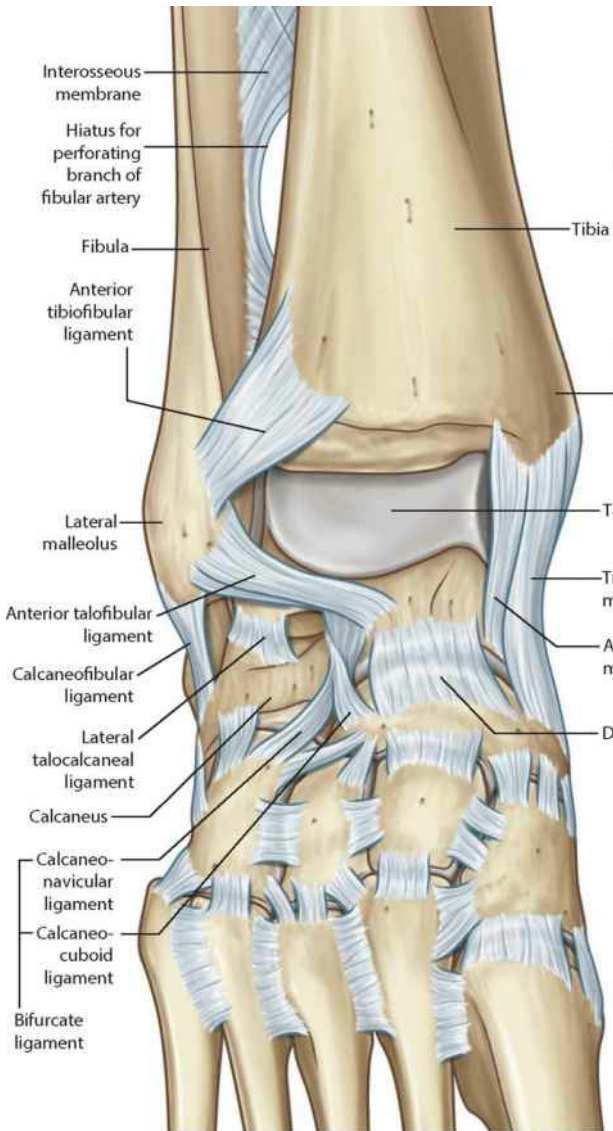
**Normal ankle joint.  
Radiograph, AP view**



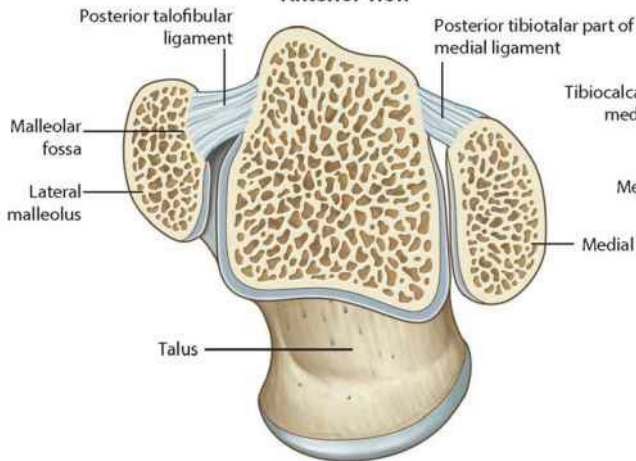
# Ligaments of the ankle joint



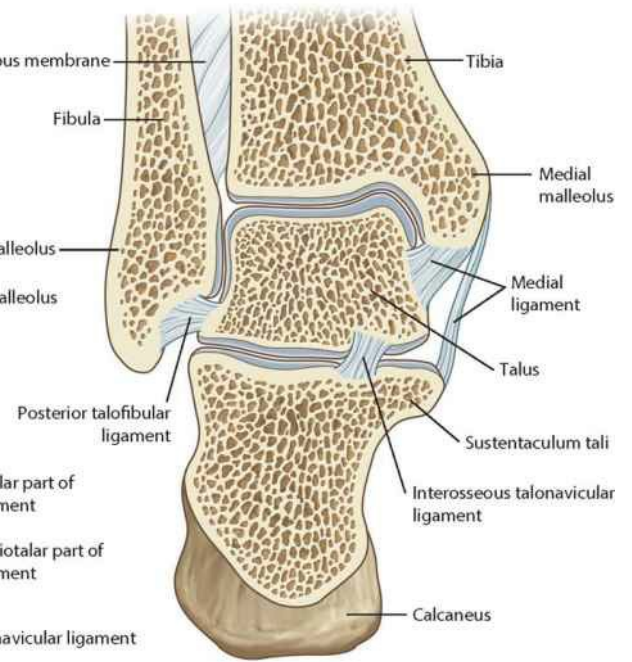




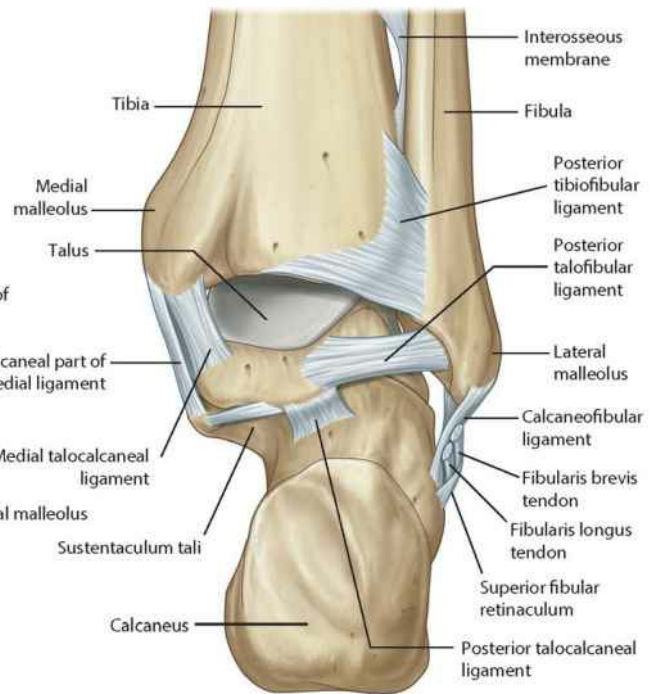**Anterior view**



**Transverse section through ankle joint (superior view)**

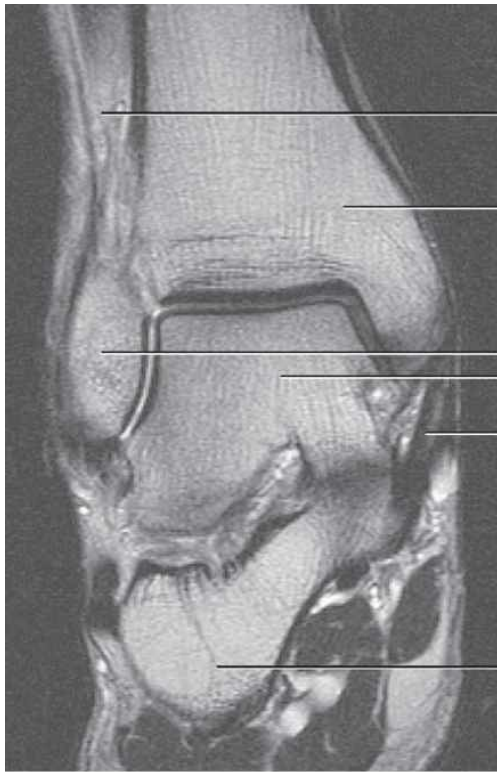


**Coronal section through ankle joint (anterior view)**

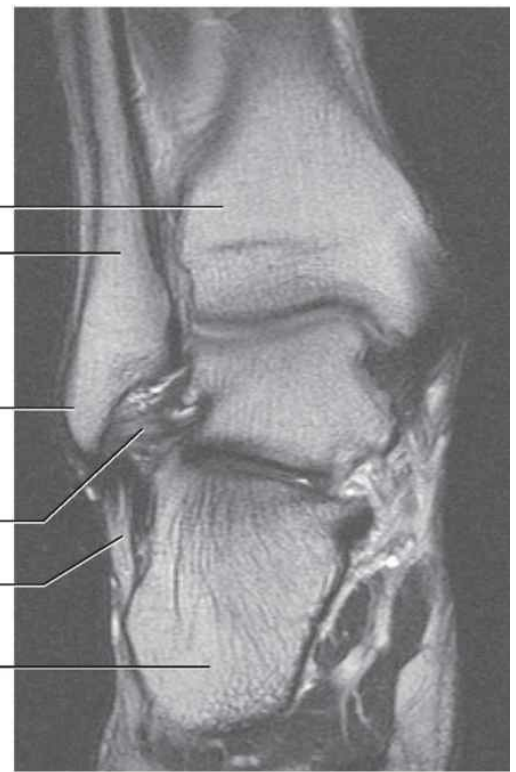


**Posterior view**

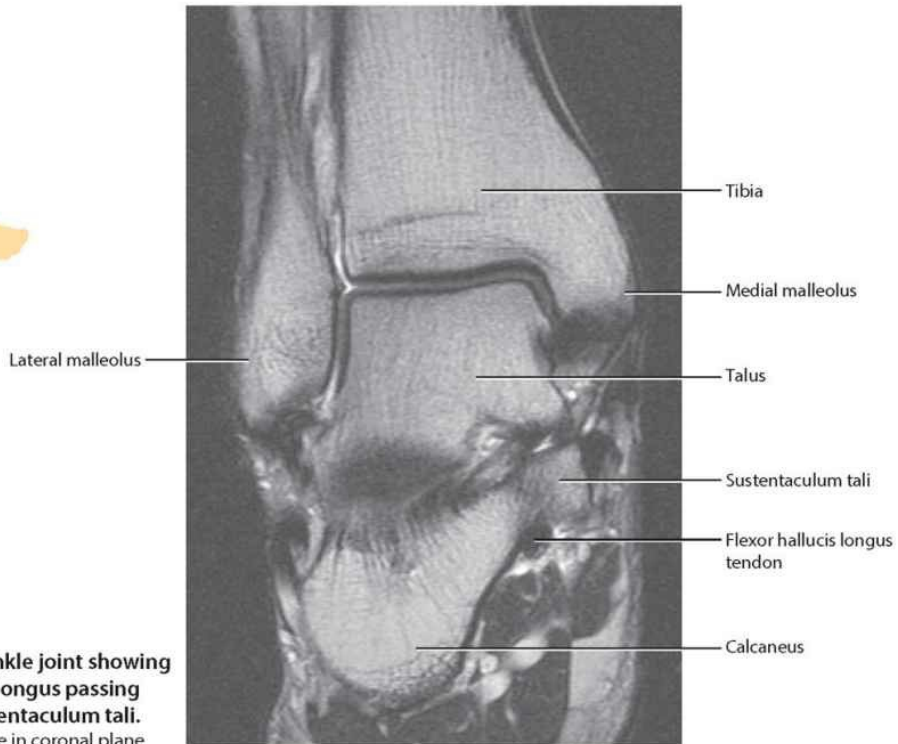
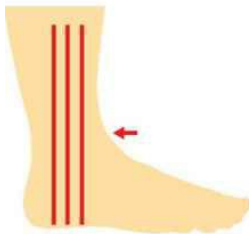




Coronal view of the ankle joint showing the medial ligament of the ankle joint (deltoid ligament).  
T2-weighted MR image in coronal plane

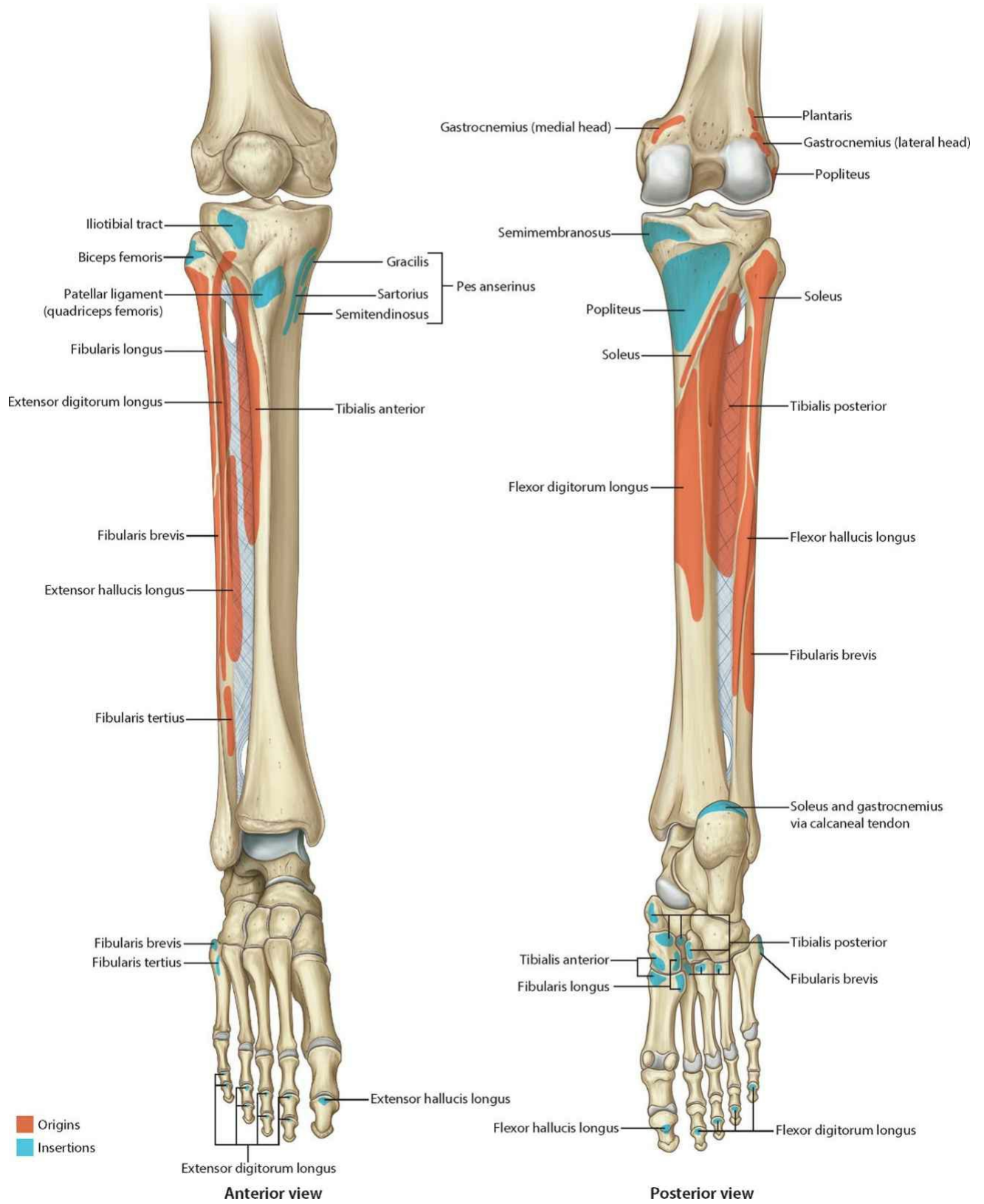


Coronal view of the ankle joint showing the posterior talofibular and calcaneofibular ligaments.  
T2-weighted MR image in coronal plane



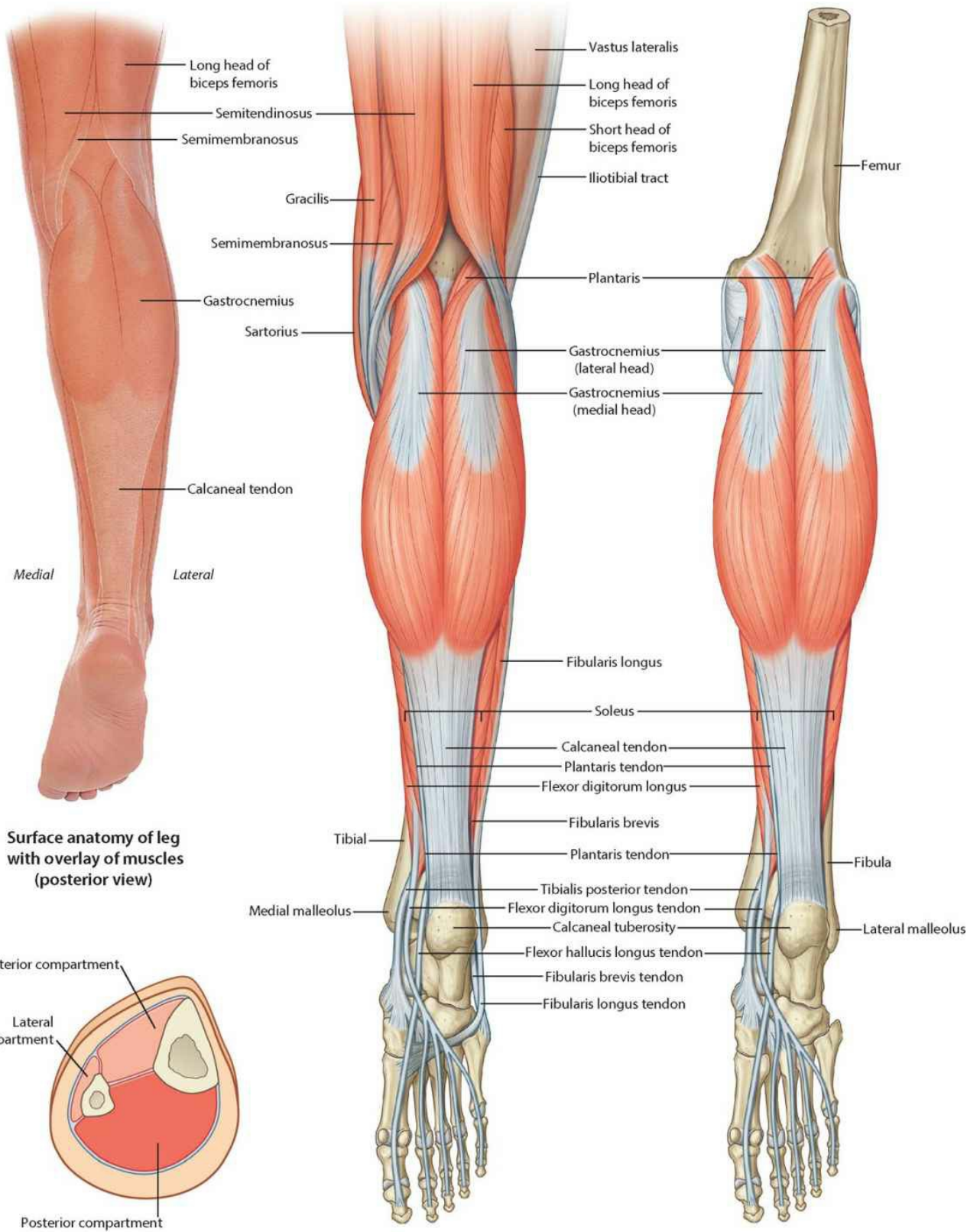
Coronal view of the ankle joint showing the flexor hallucis longus passing inferior to the sustentaculum tali.  
T2-weighted MR image in coronal plane

## Leg: muscle attachments





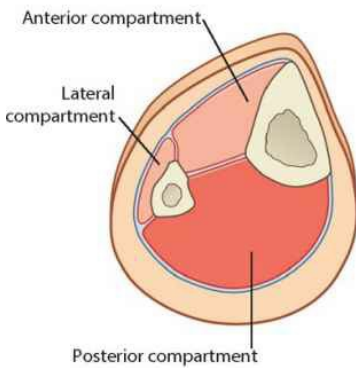
# Posterior leg: superficial muscles



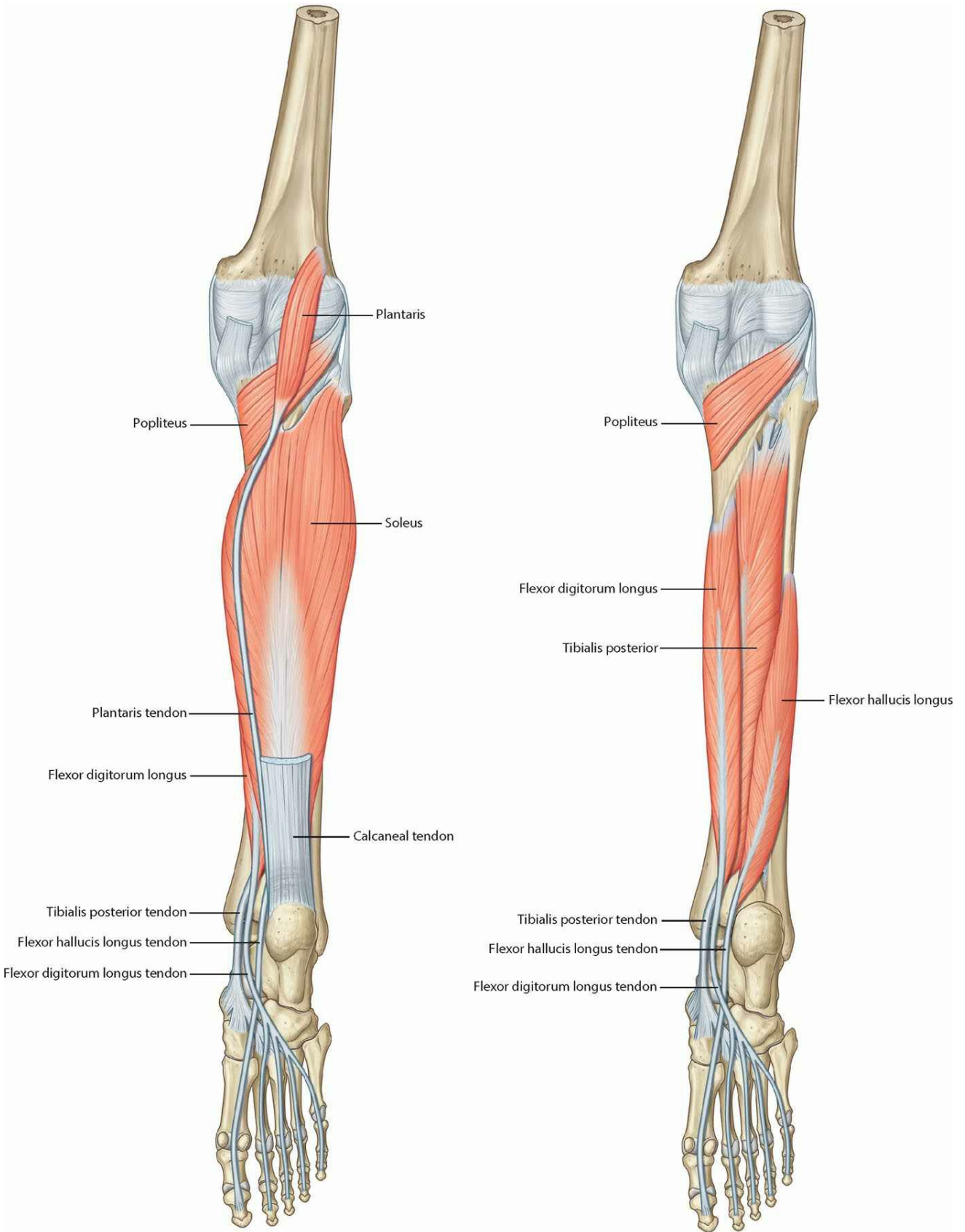
Surface anatomy of leg with overlay of muscles (posterior view)

Superficial muscles of leg (posterior view)

Superficial muscles of the posterior compartment of leg

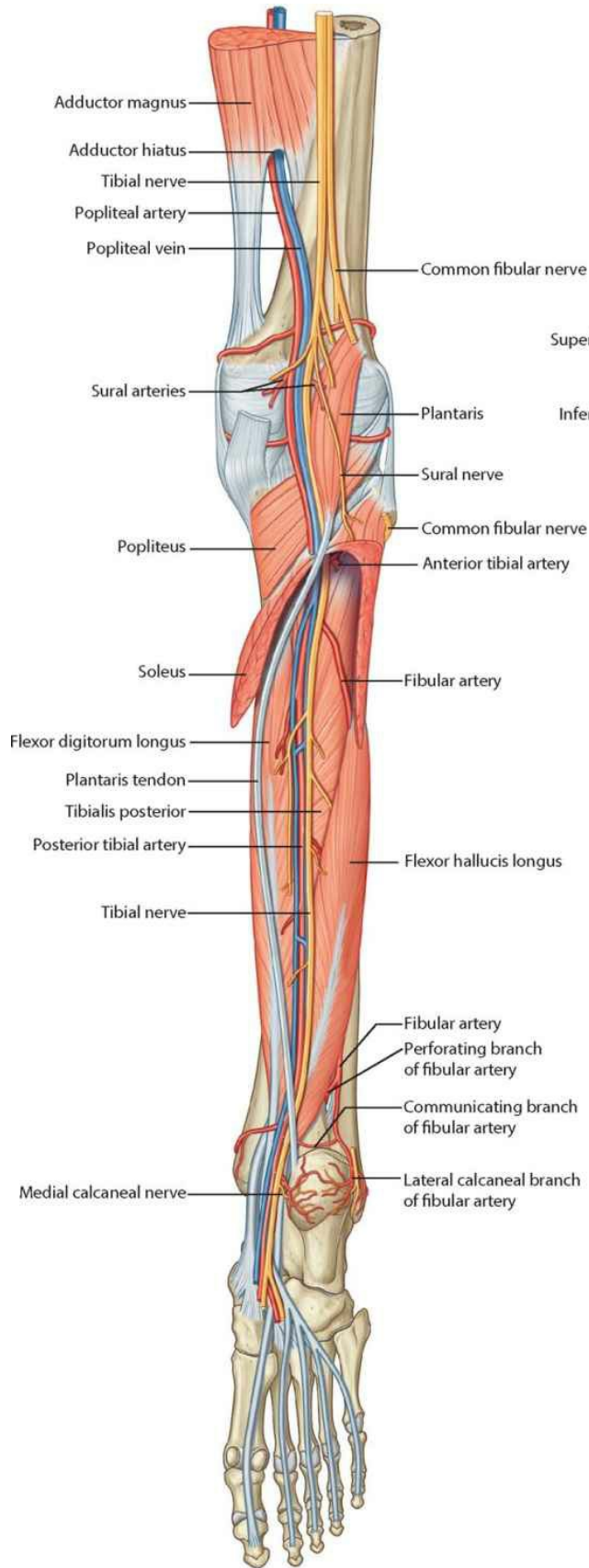


## Posterior compartment: deep muscles

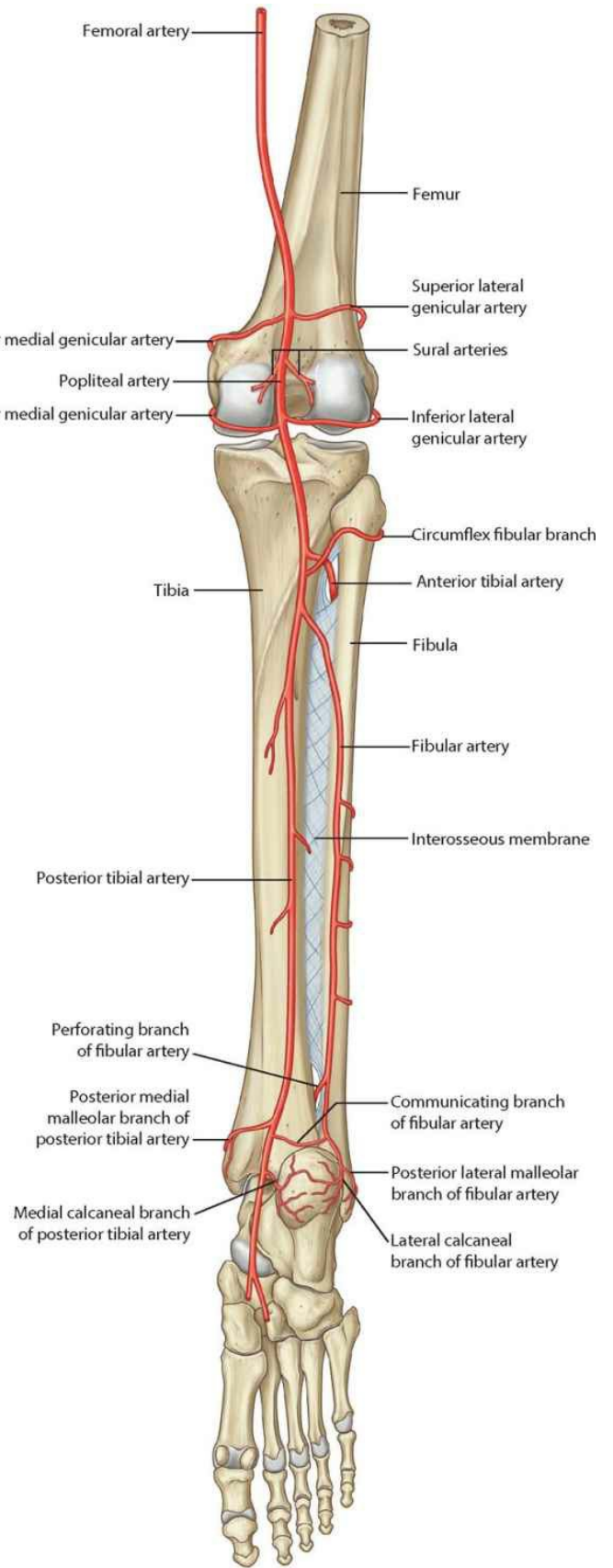


Deep muscles of the posterior compartment of leg

# Posterior leg: arteries and nerves

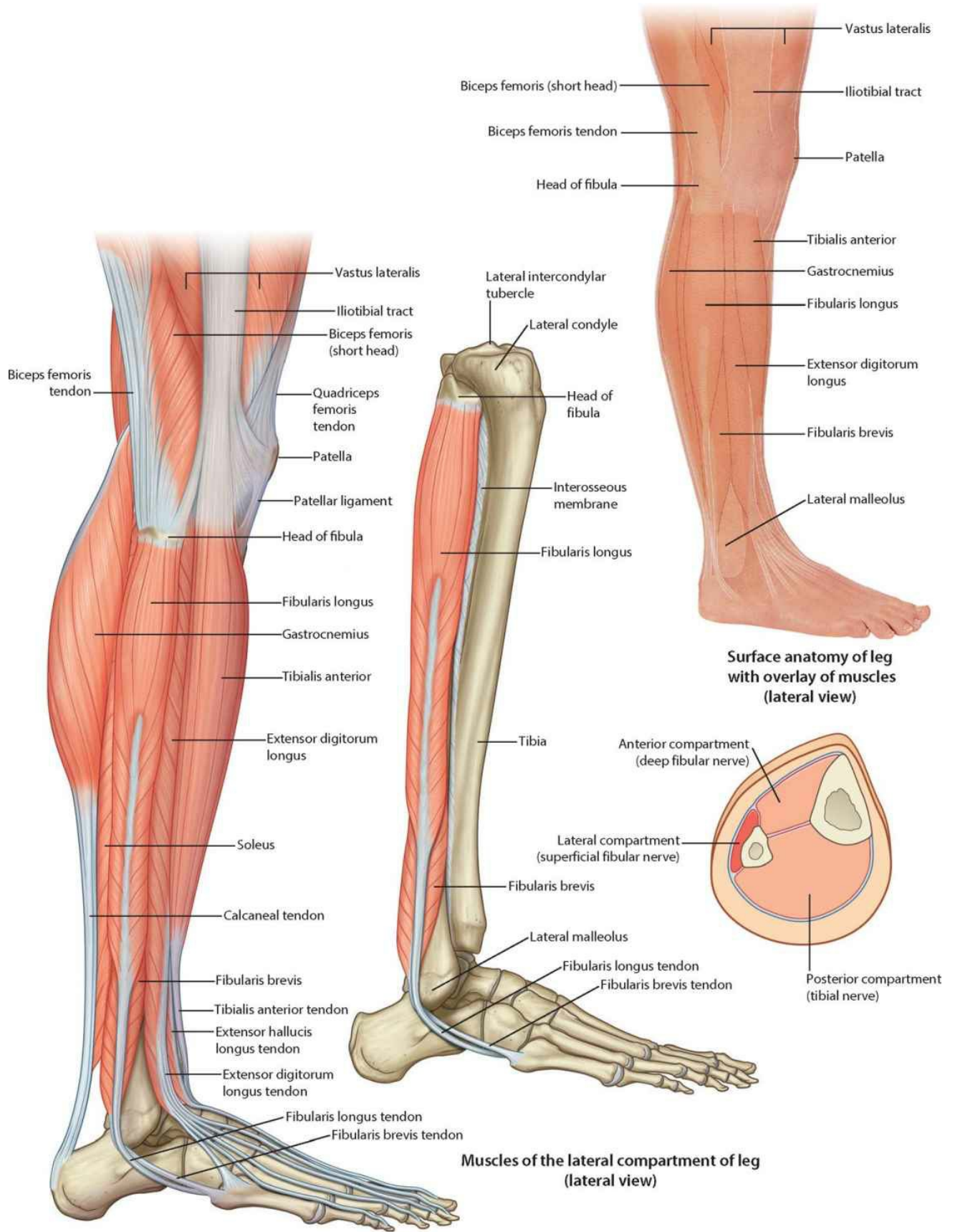


Arteries and nerves of leg (posterior view)



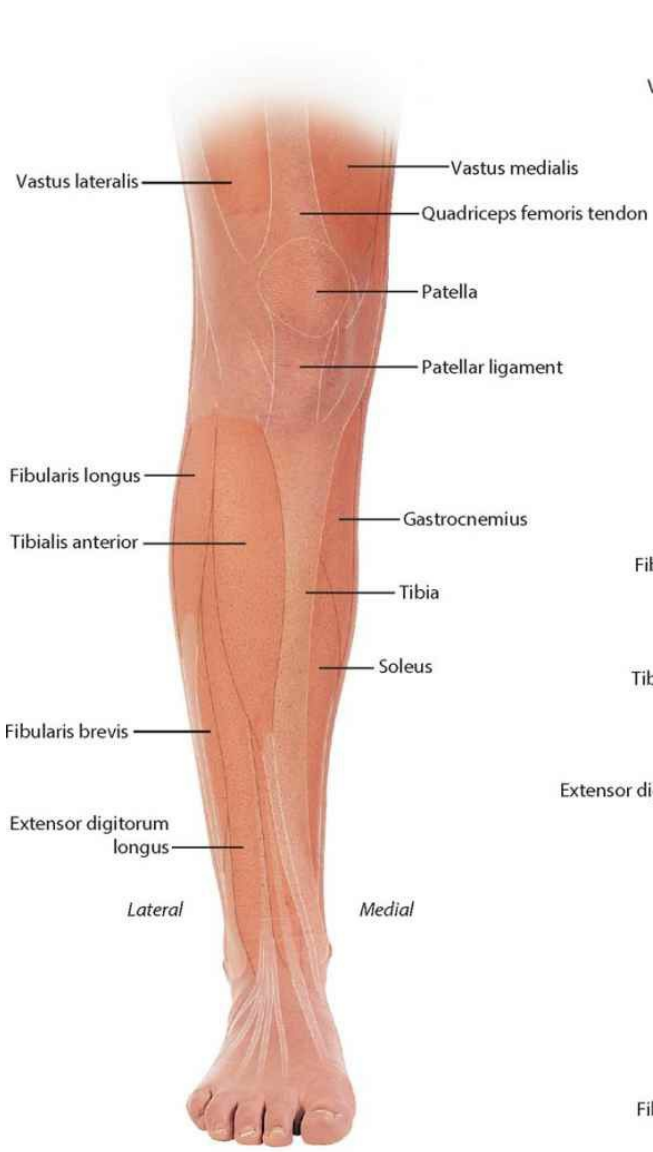
Arteries of leg (posterior view)

## **Lateral compartment: muscles**

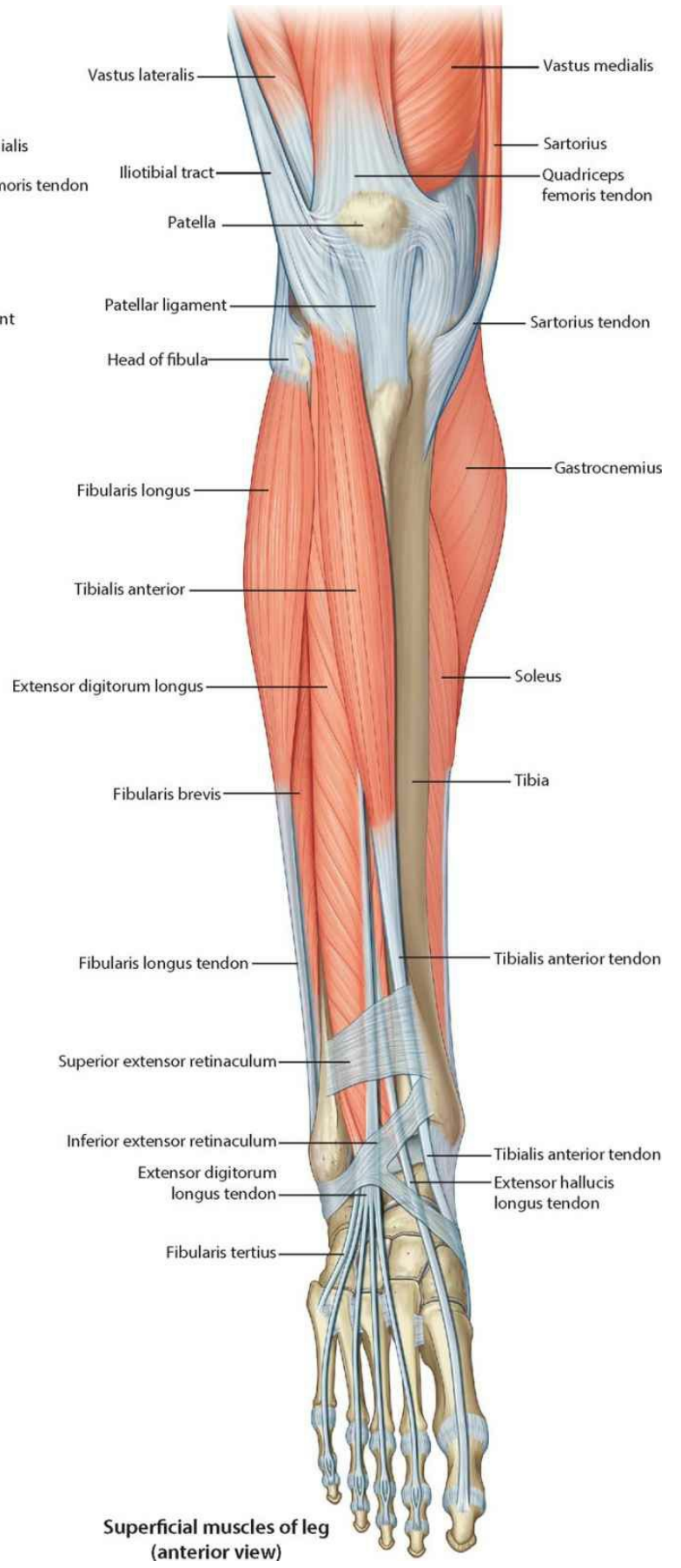
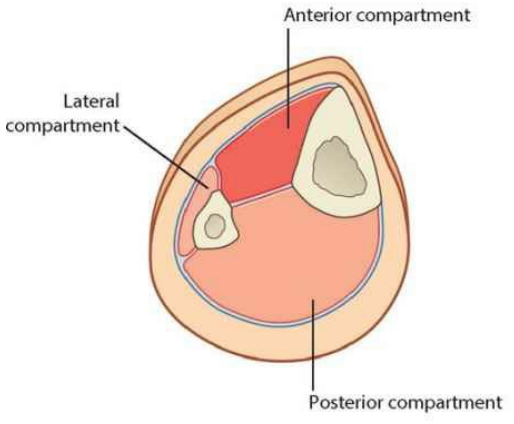




## **Anterior leg: superficial muscles**

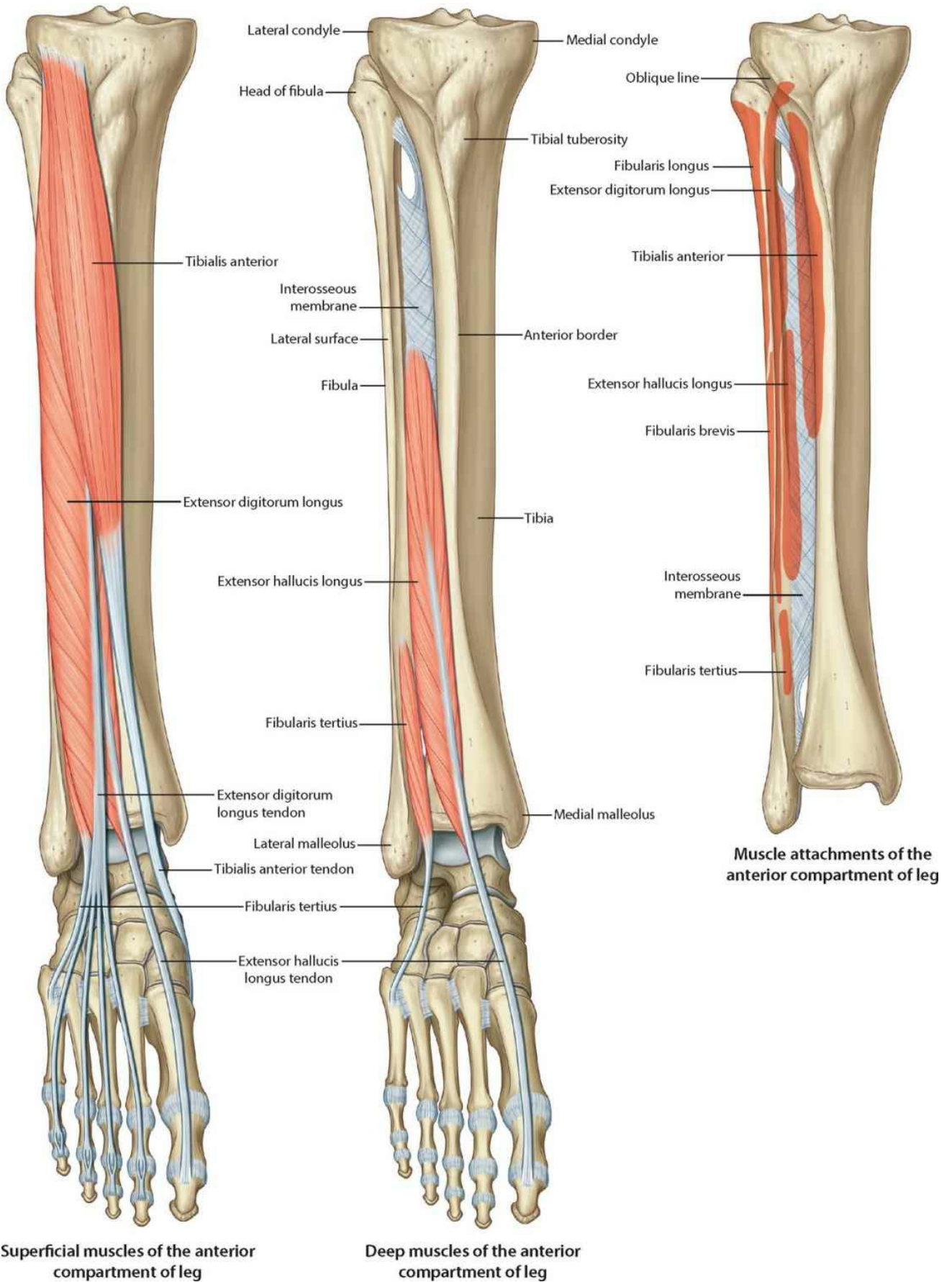


**Surface anatomy of leg with overlay of muscles (anterior view)**

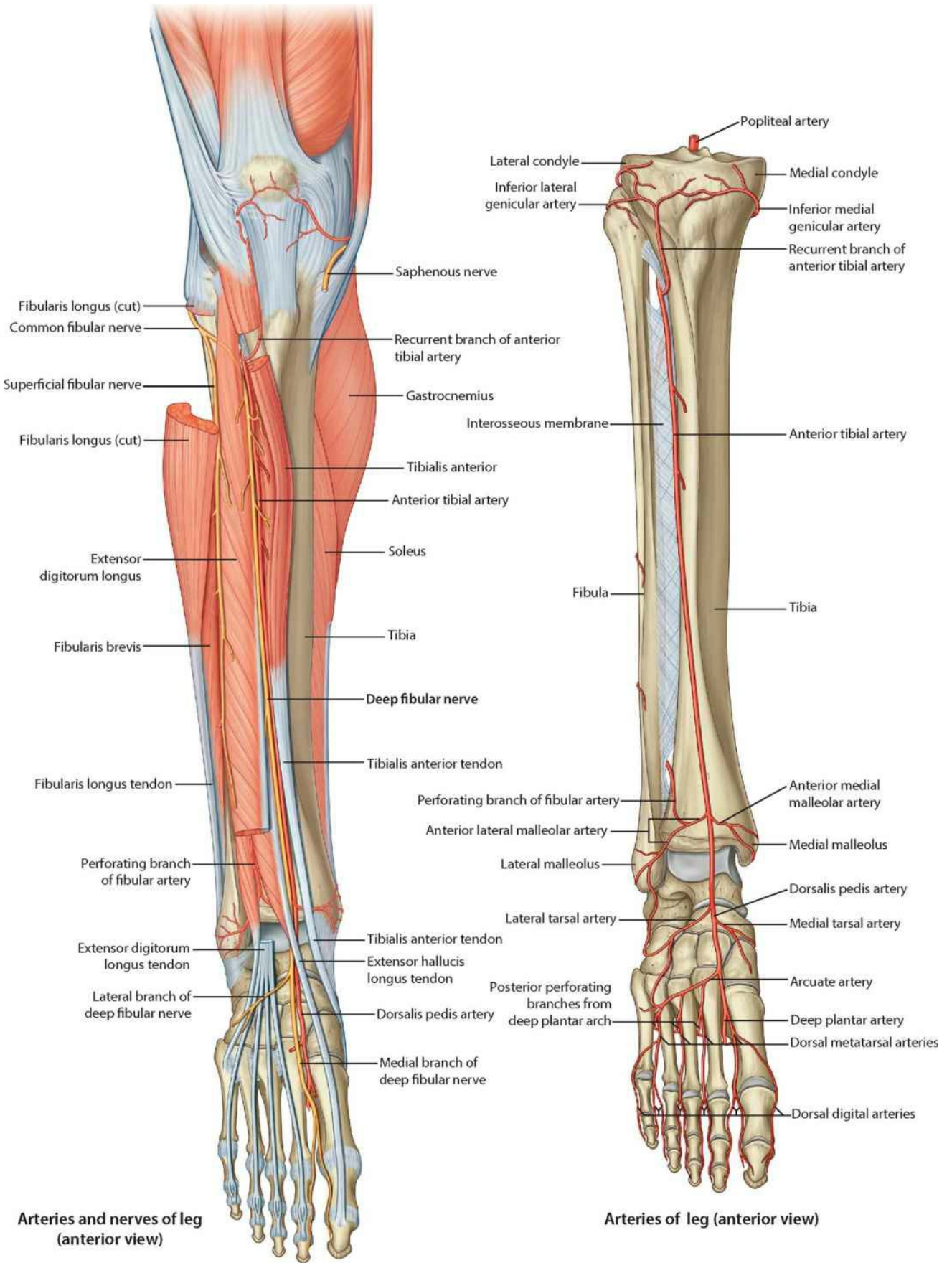


**Superficial muscles of leg (anterior view)**

## **Anterior compartment: muscles**



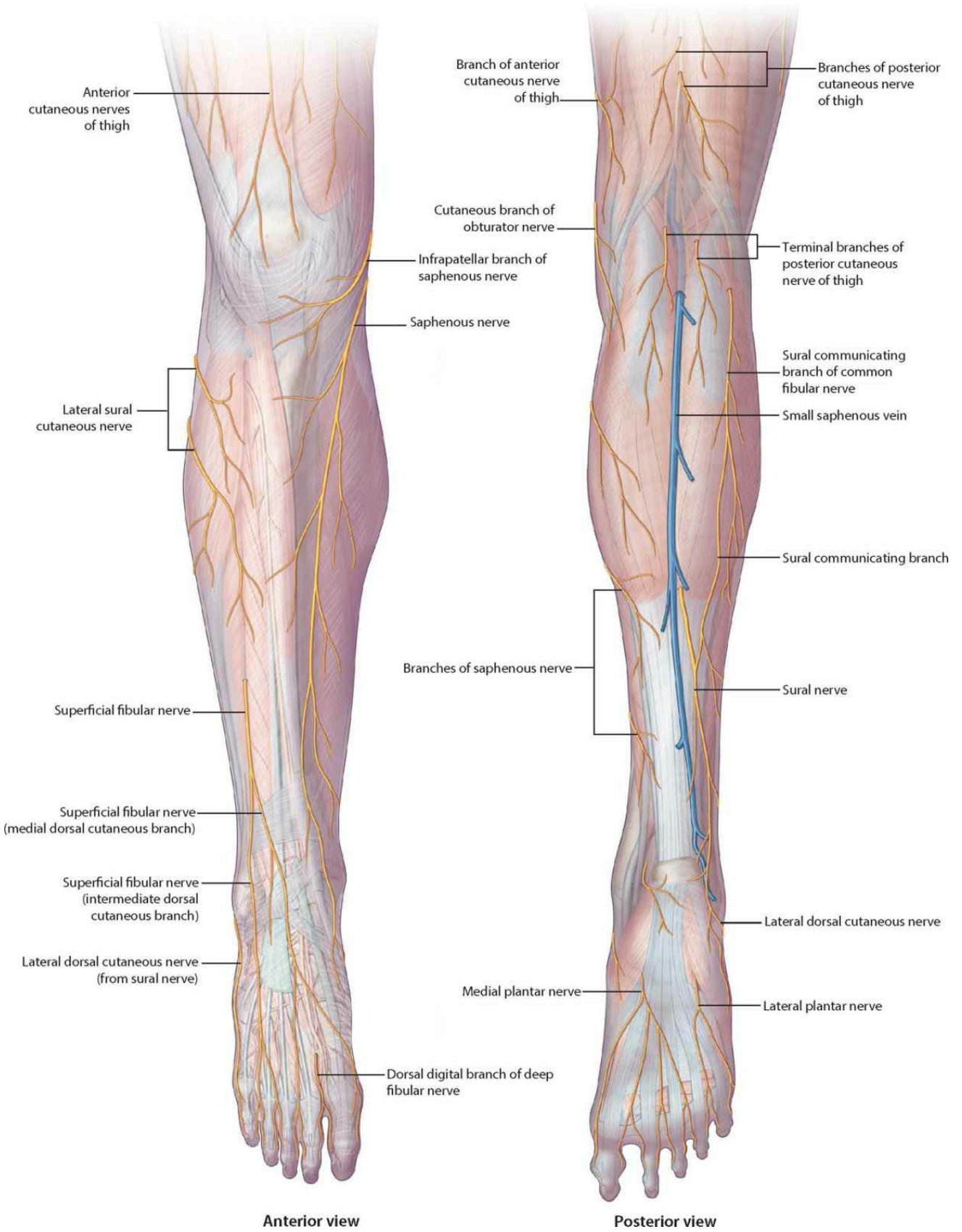
# Anterior leg: arteries and nerves



Arteries and nerves of leg (anterior view)

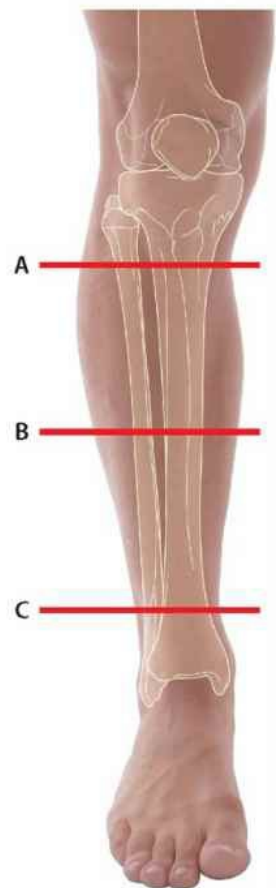
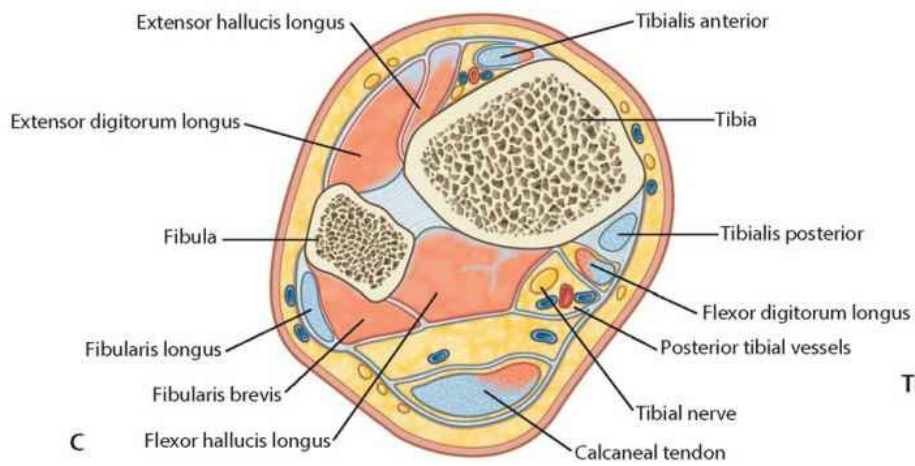
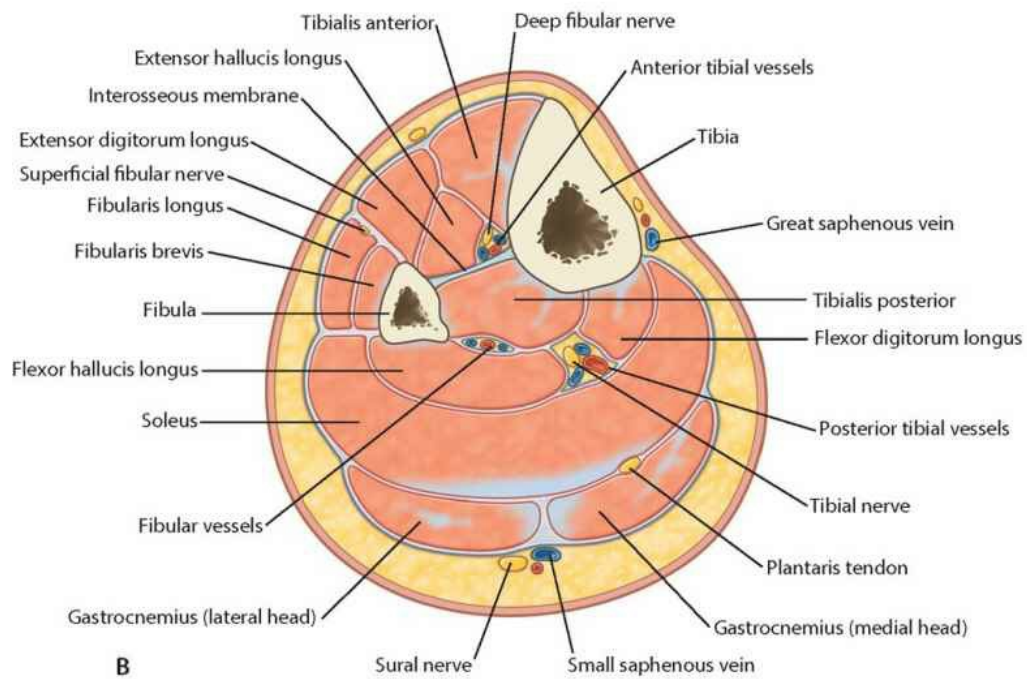
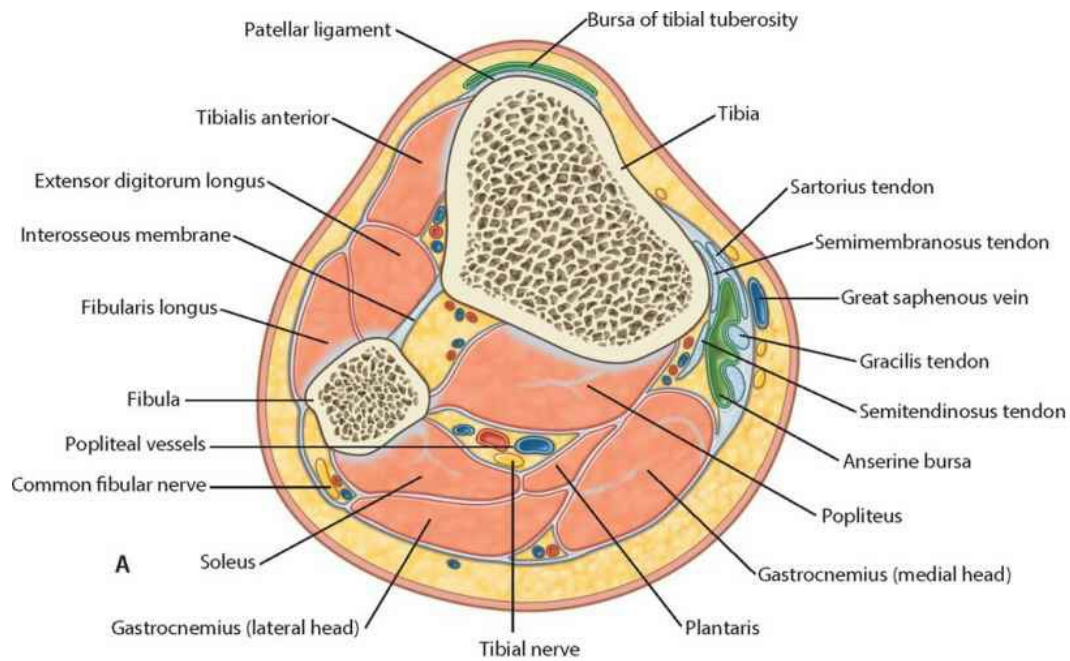
Arteries of leg (anterior view)

## **Leg: cutaneous nerves**



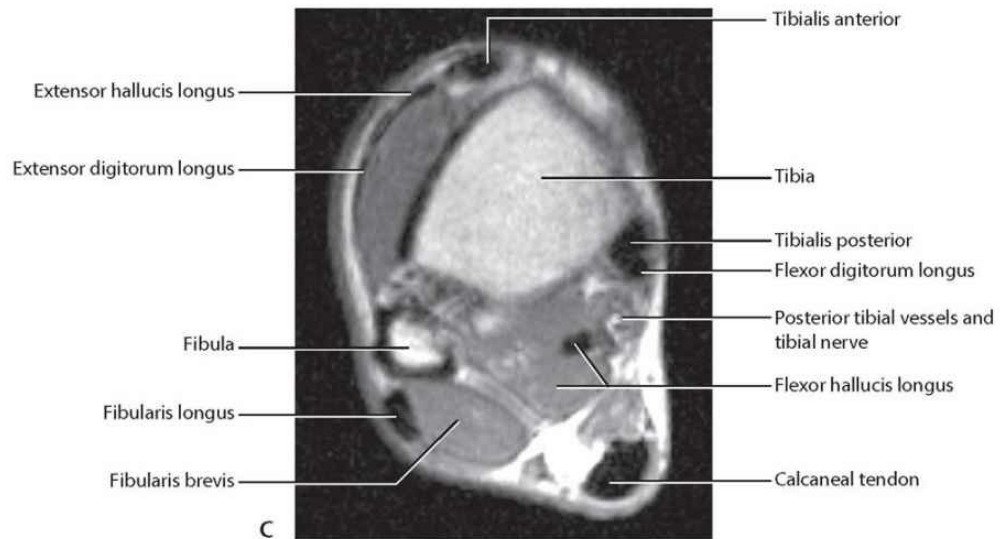
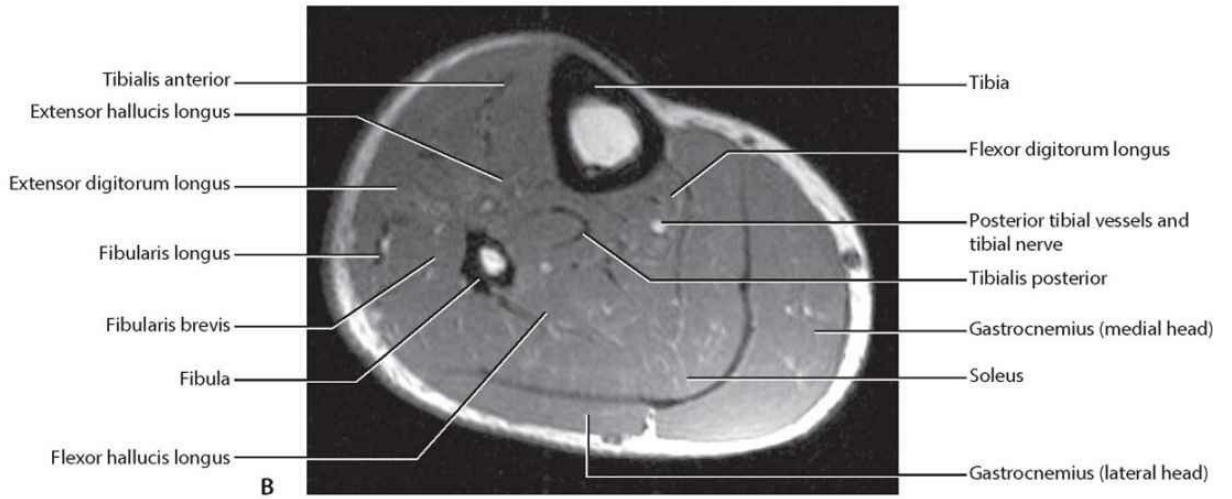
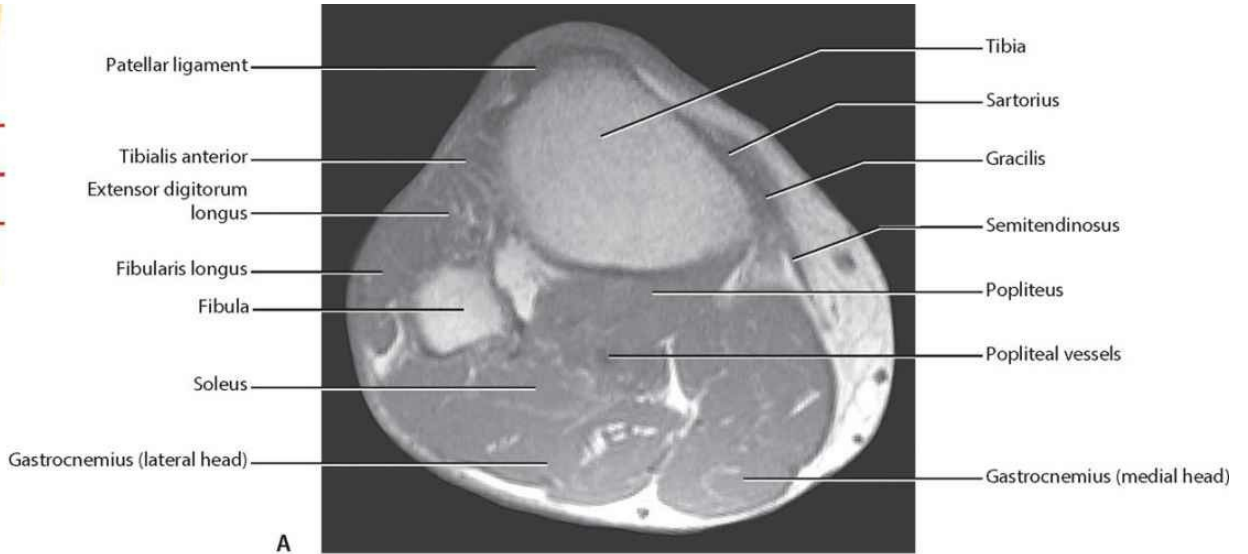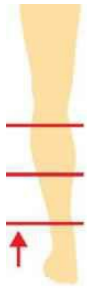


## Transverse sections: leg



Transverse sections through leg



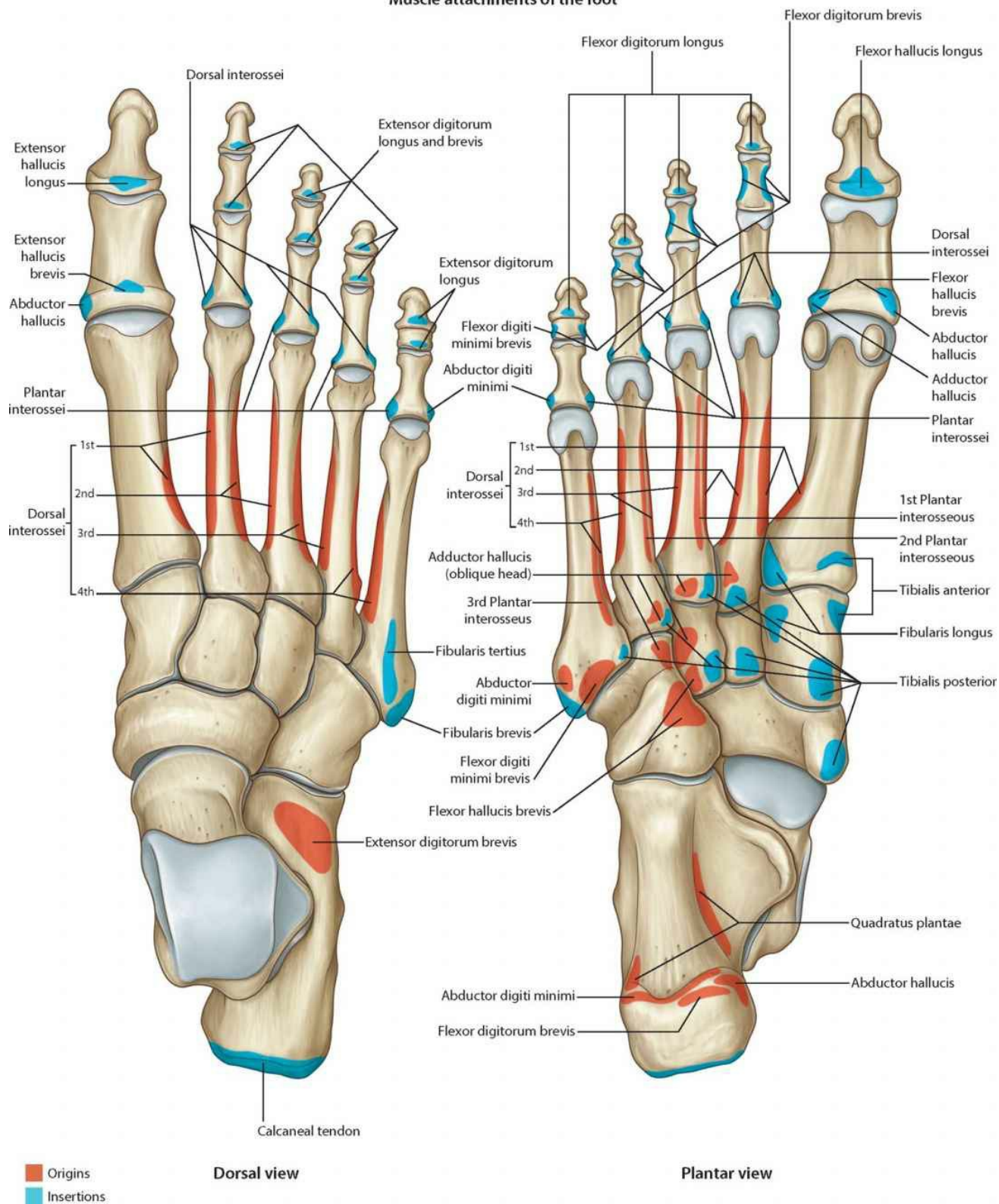


**Transverse/axial sections through the leg.**

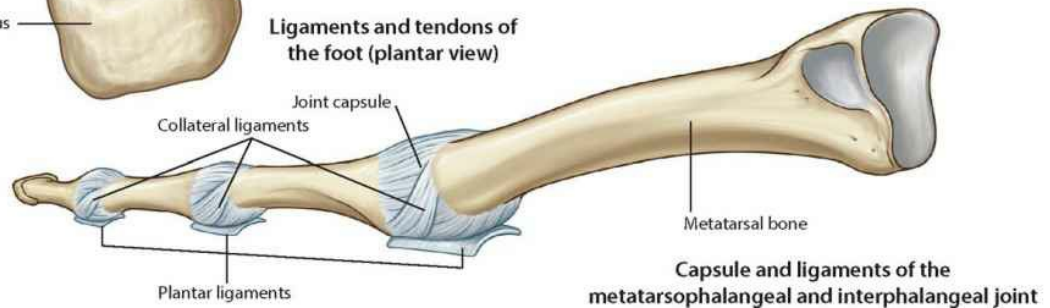
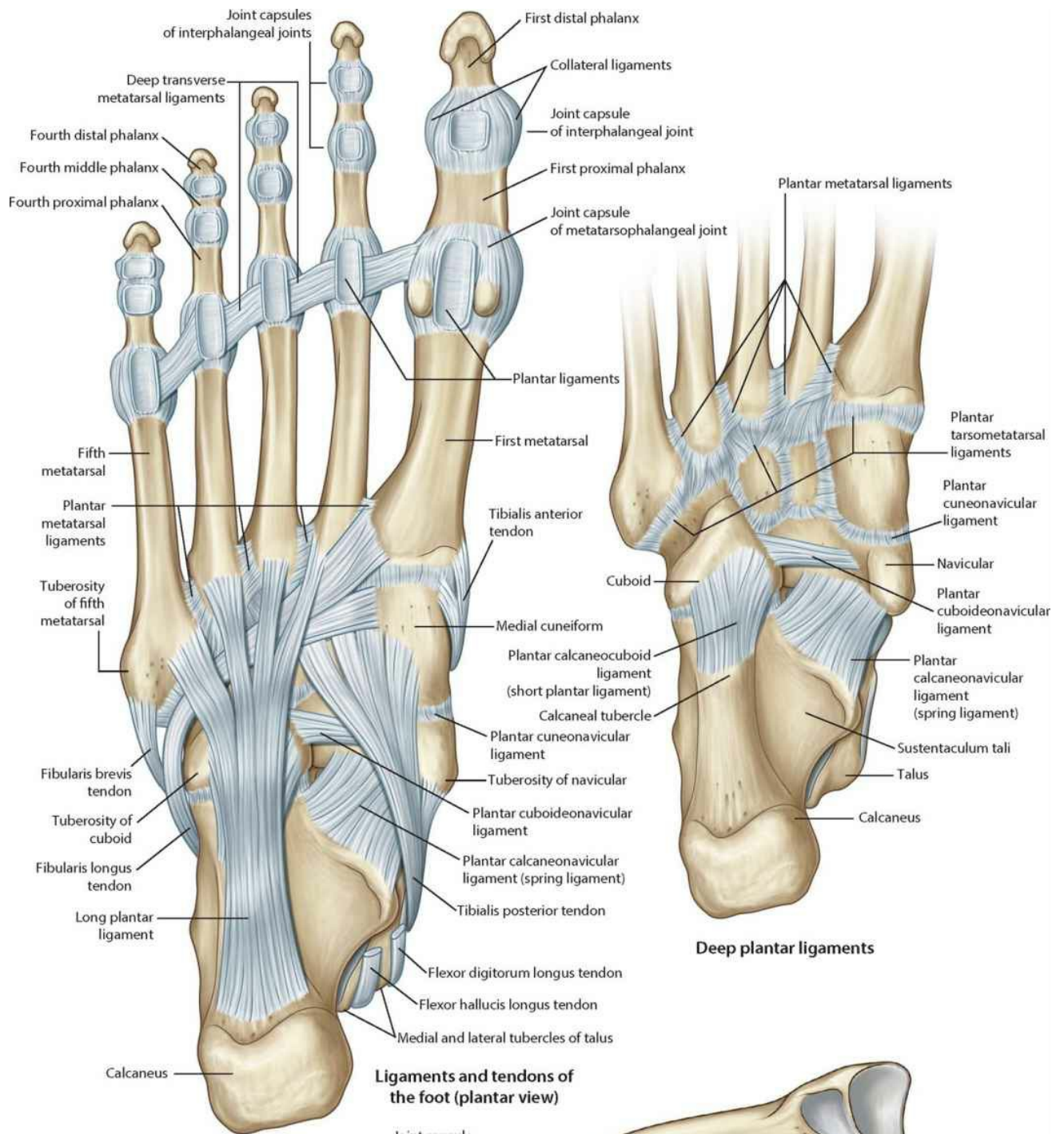
- A. Proximal/upper leg. T1-weighted MR image in axial plane
- B. Middle leg. T1-weighted MR image in axial plane
- C. Distal/lower leg. T1-weighted MR image in axial plane

## Foot: muscle attachments

### Muscle attachments of the foot

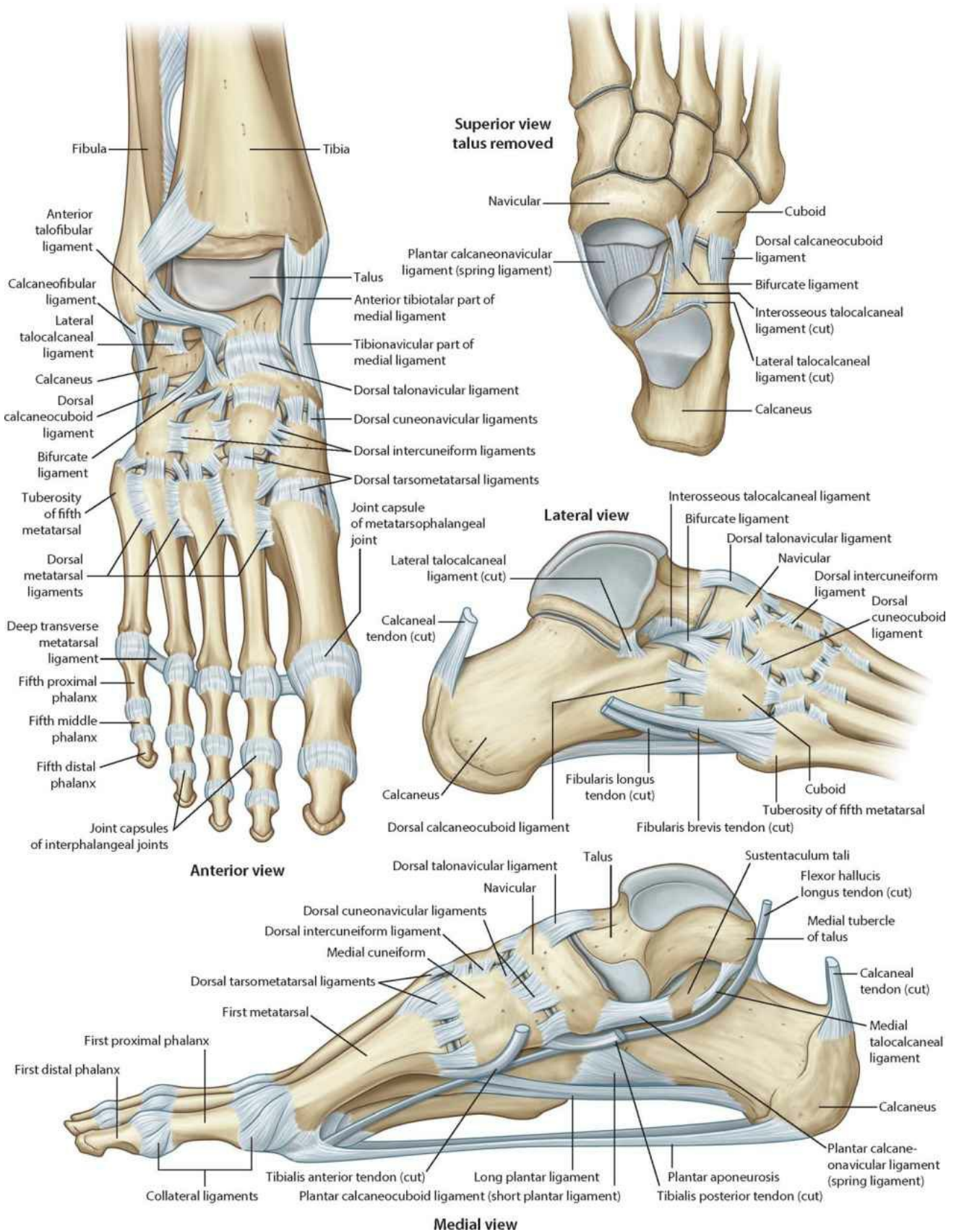


# Foot: ligaments

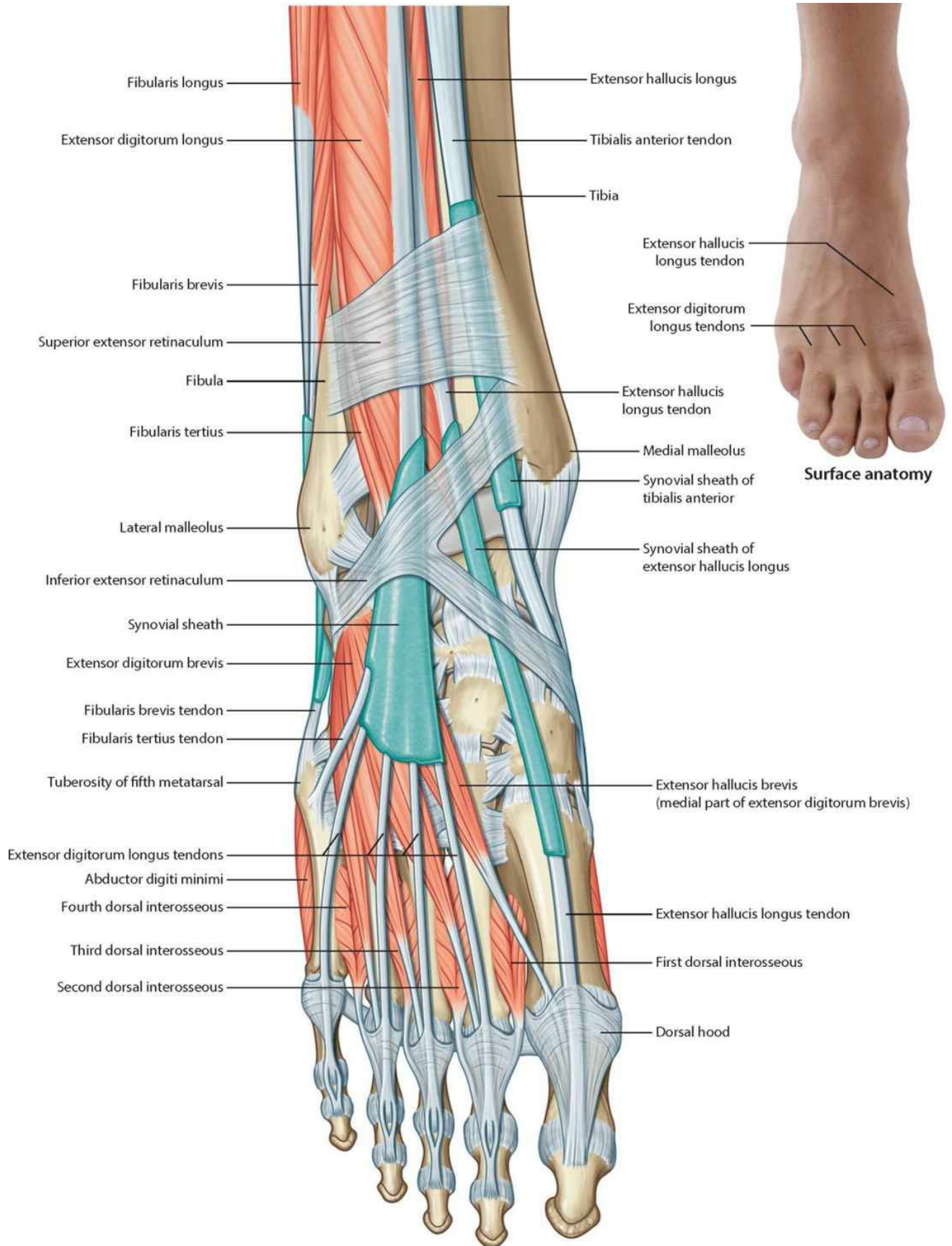






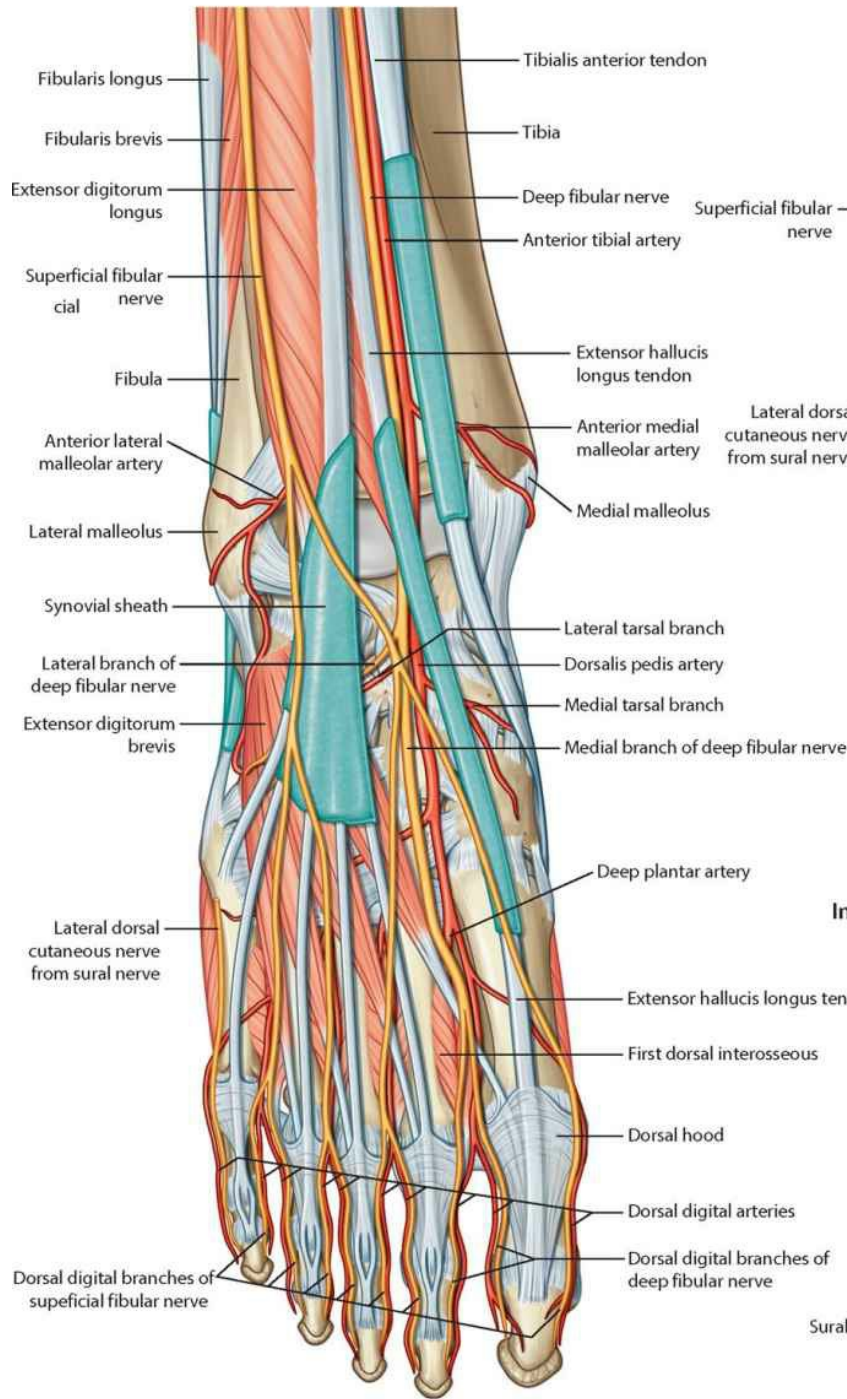


## Dorsum of foot

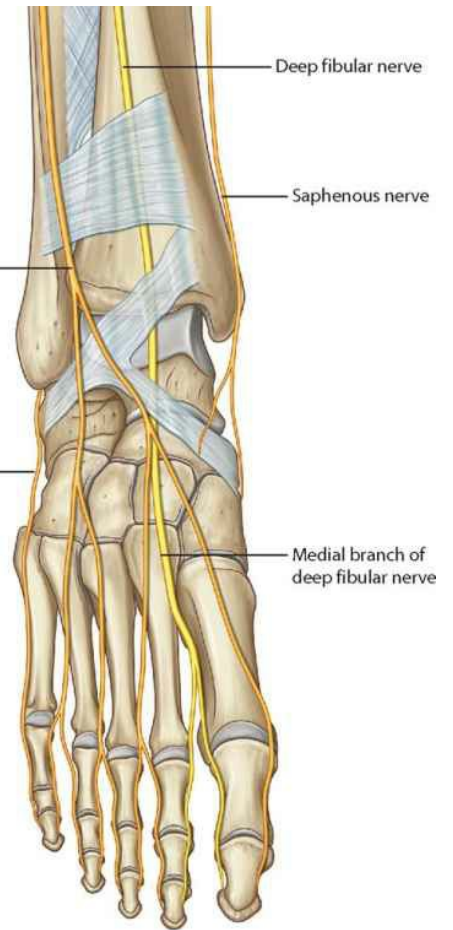


Superficial structures of the foot (dorsal view)

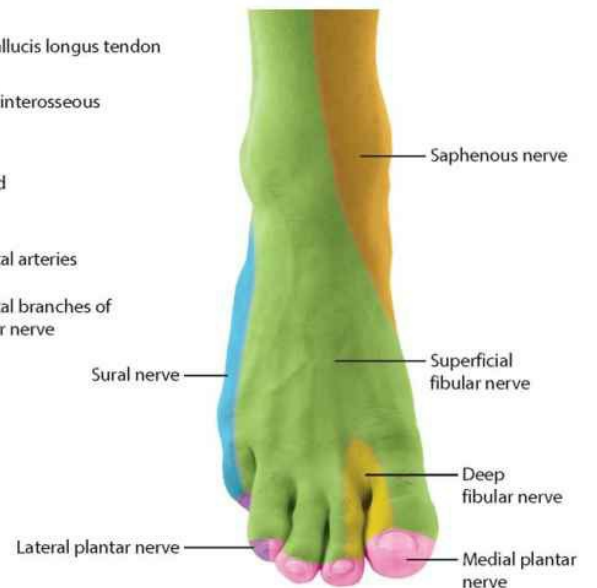
## **Dorsum of foot: arteries and nerves**



**Arteries and nerves of the foot (dorsal view)**

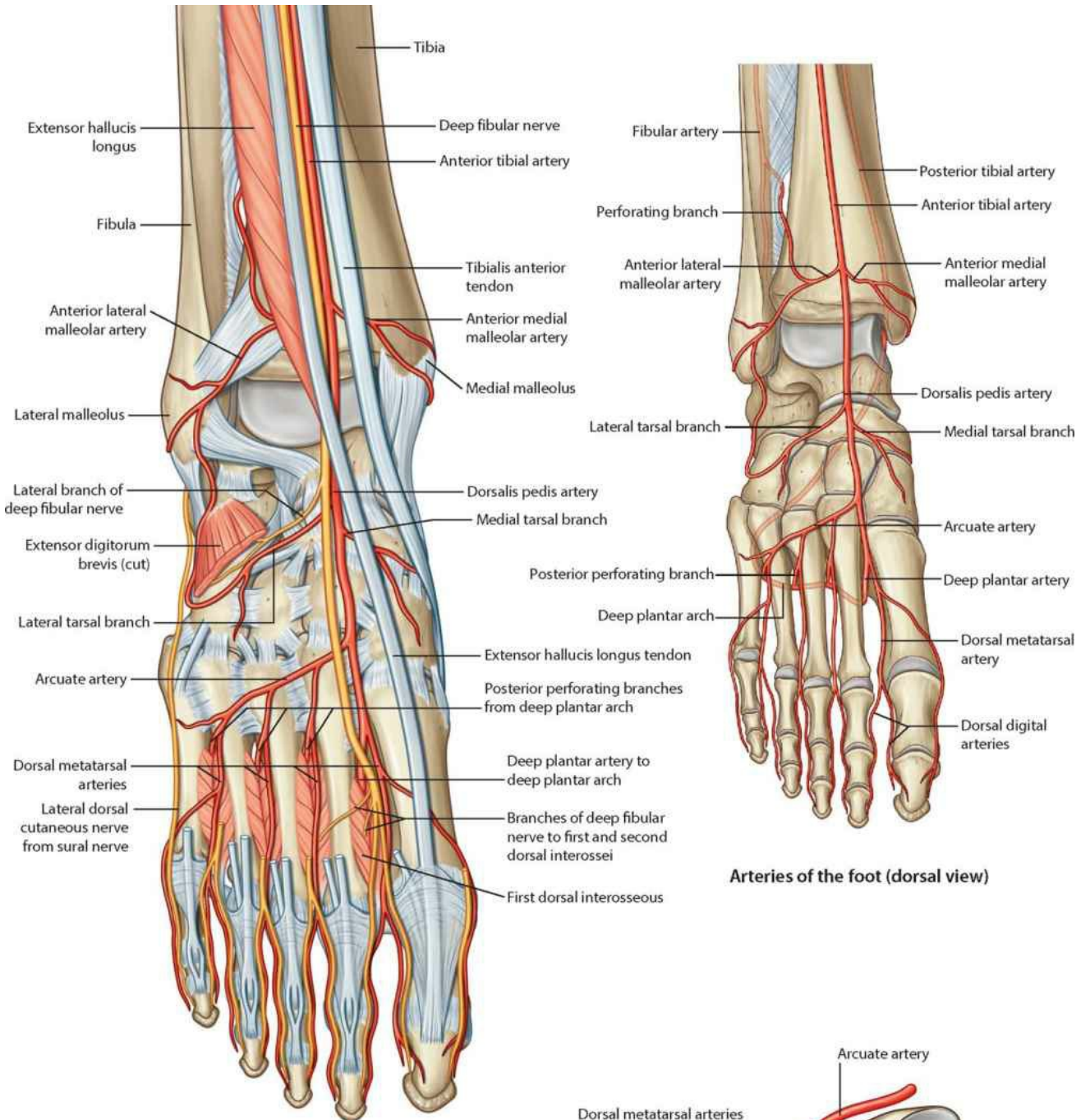


**Innervation of the foot (dorsal view)**



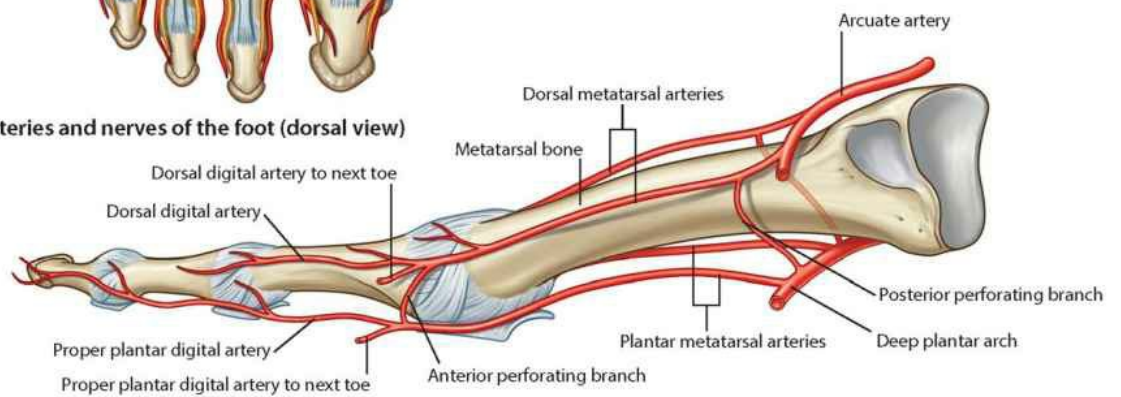
**Cutaneous distribution**





**Arteries of the foot (dorsal view)**

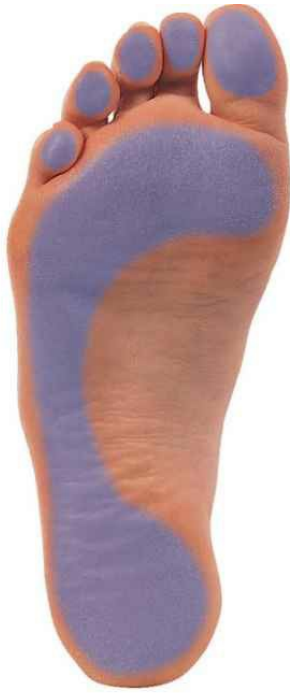**Deep arteries and nerves of the foot (dorsal view)**



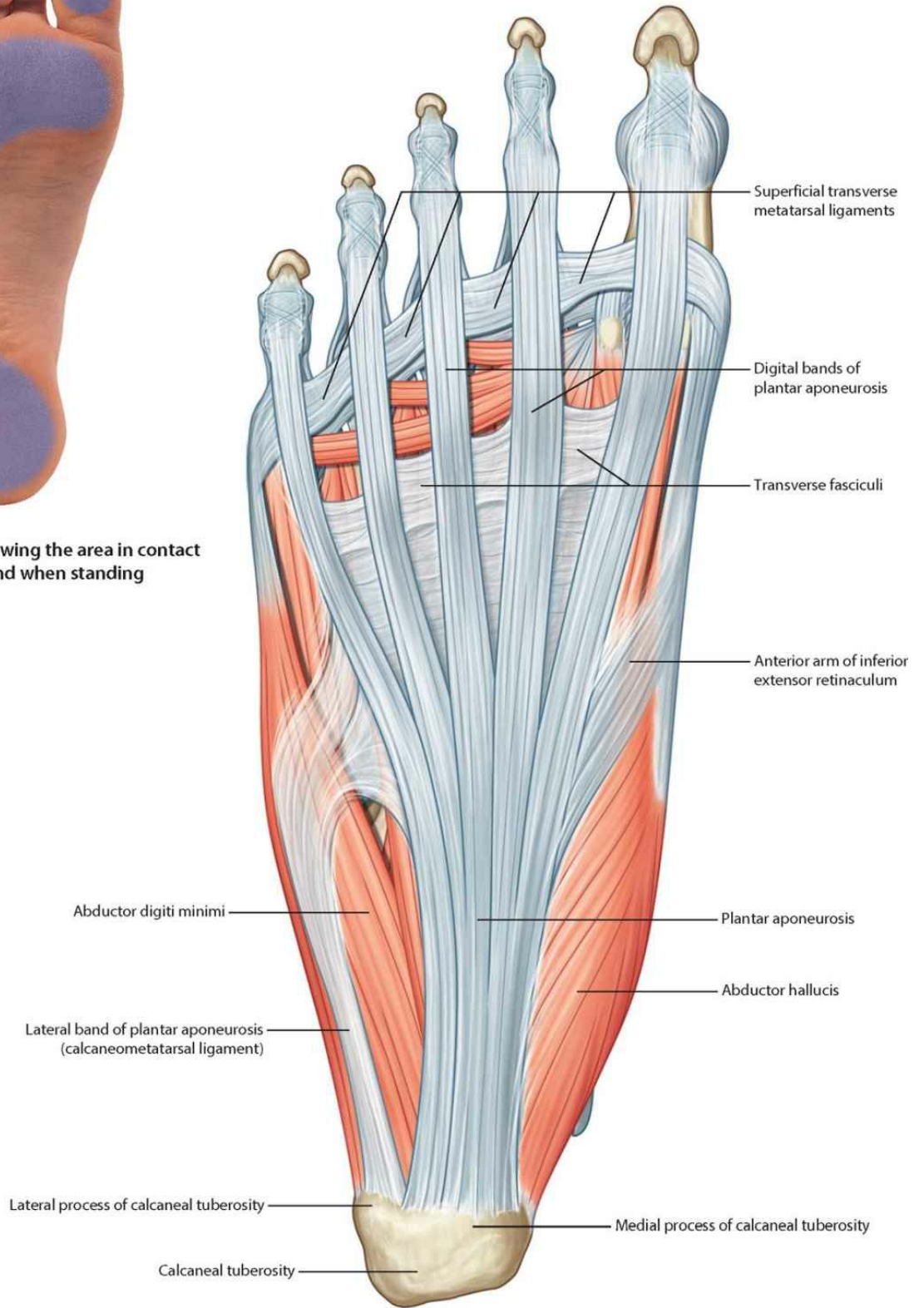
**Arteries of digit III (middle toe)**



# Plantar aponeurosis

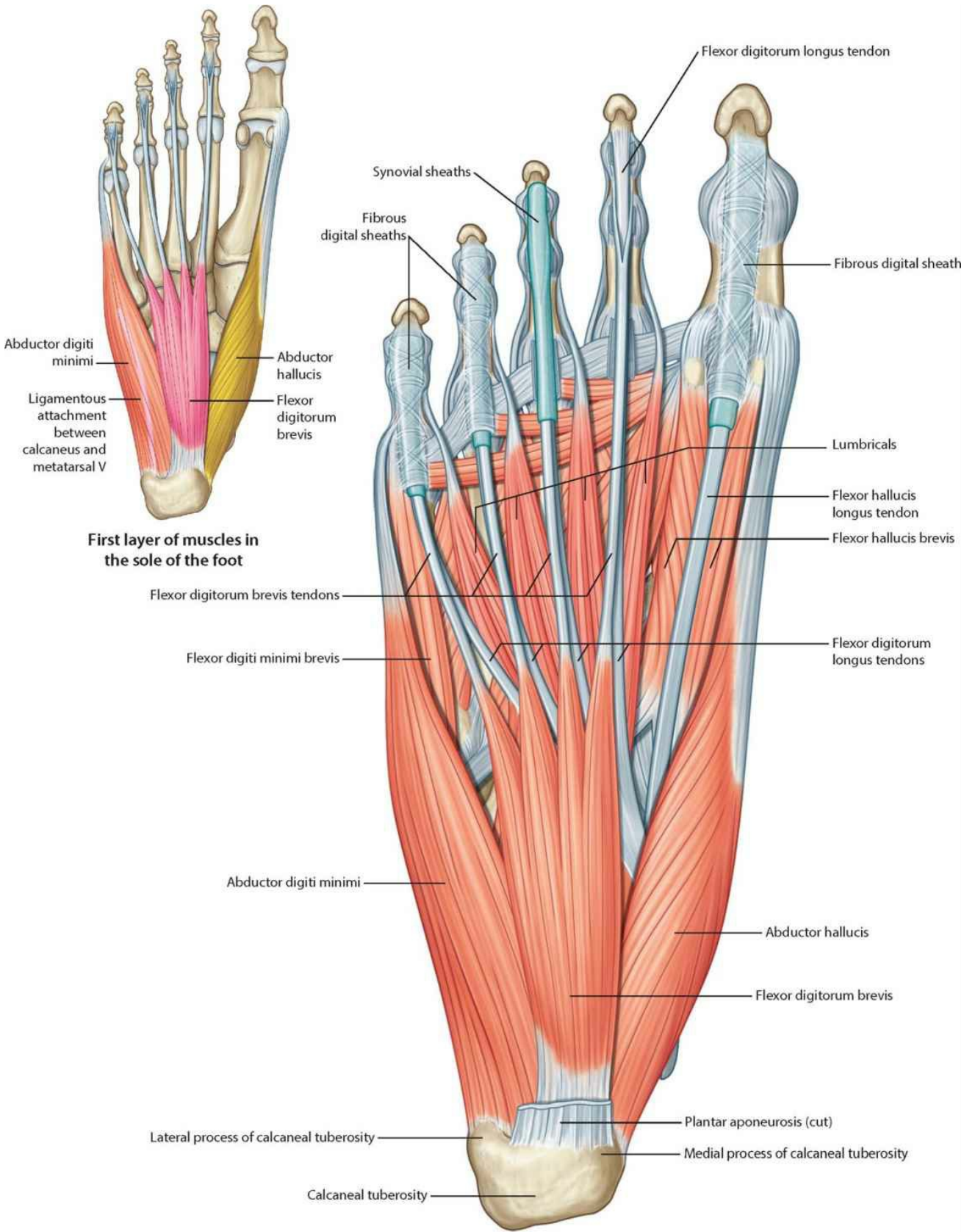


Surface anatomy showing the area in contact with the ground when standing



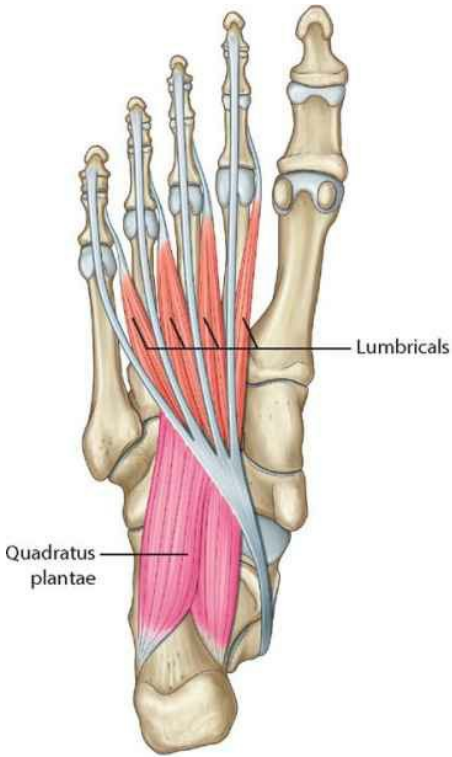
Superficial structures of the foot (plantar view)

## **Plantar region (sole) musculature: first layer**

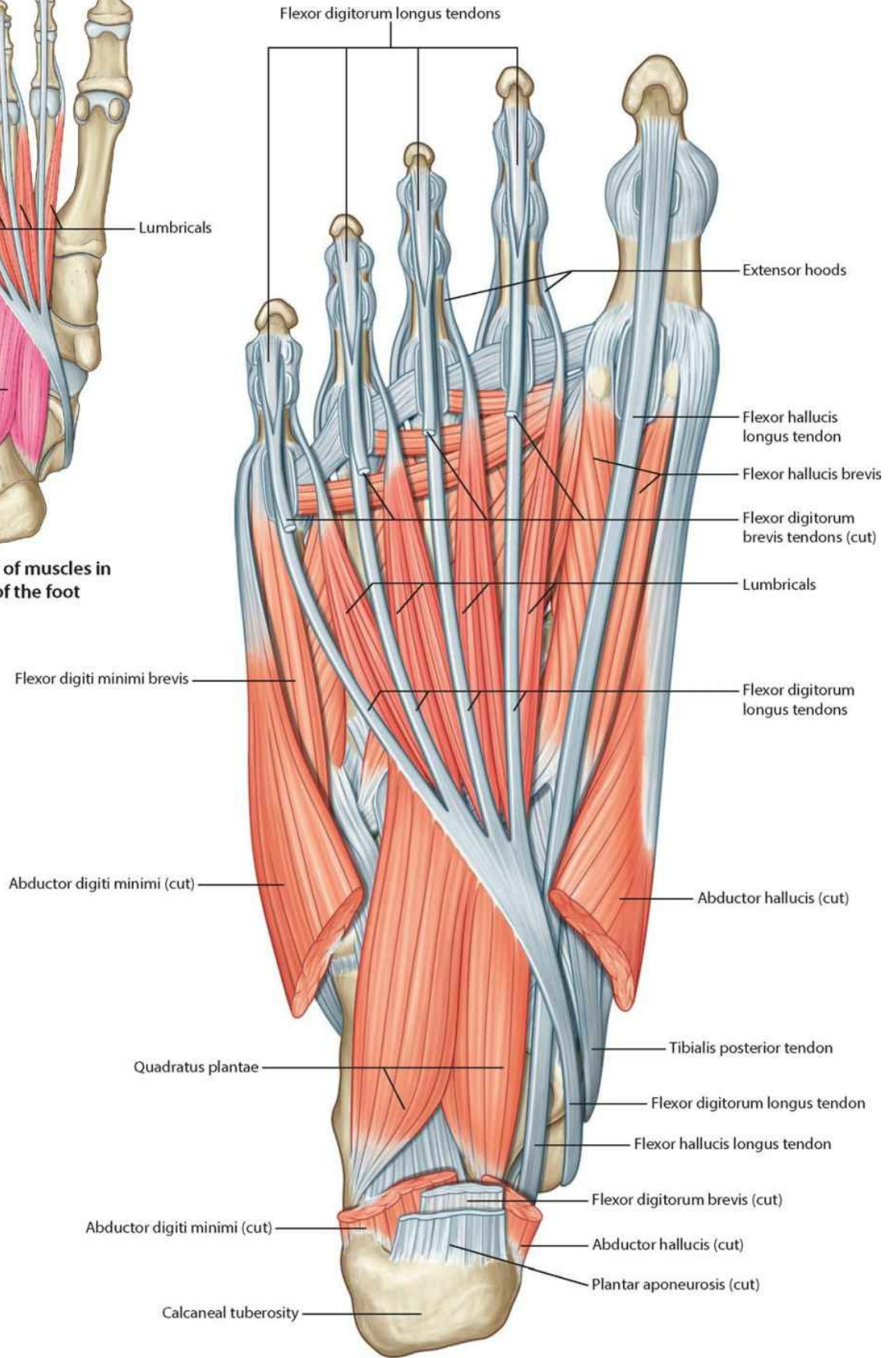


**Muscles of sole of foot (first layer)**

## **Plantar region (sole) musculature: second layer**



Second layer of muscles in the sole of the foot

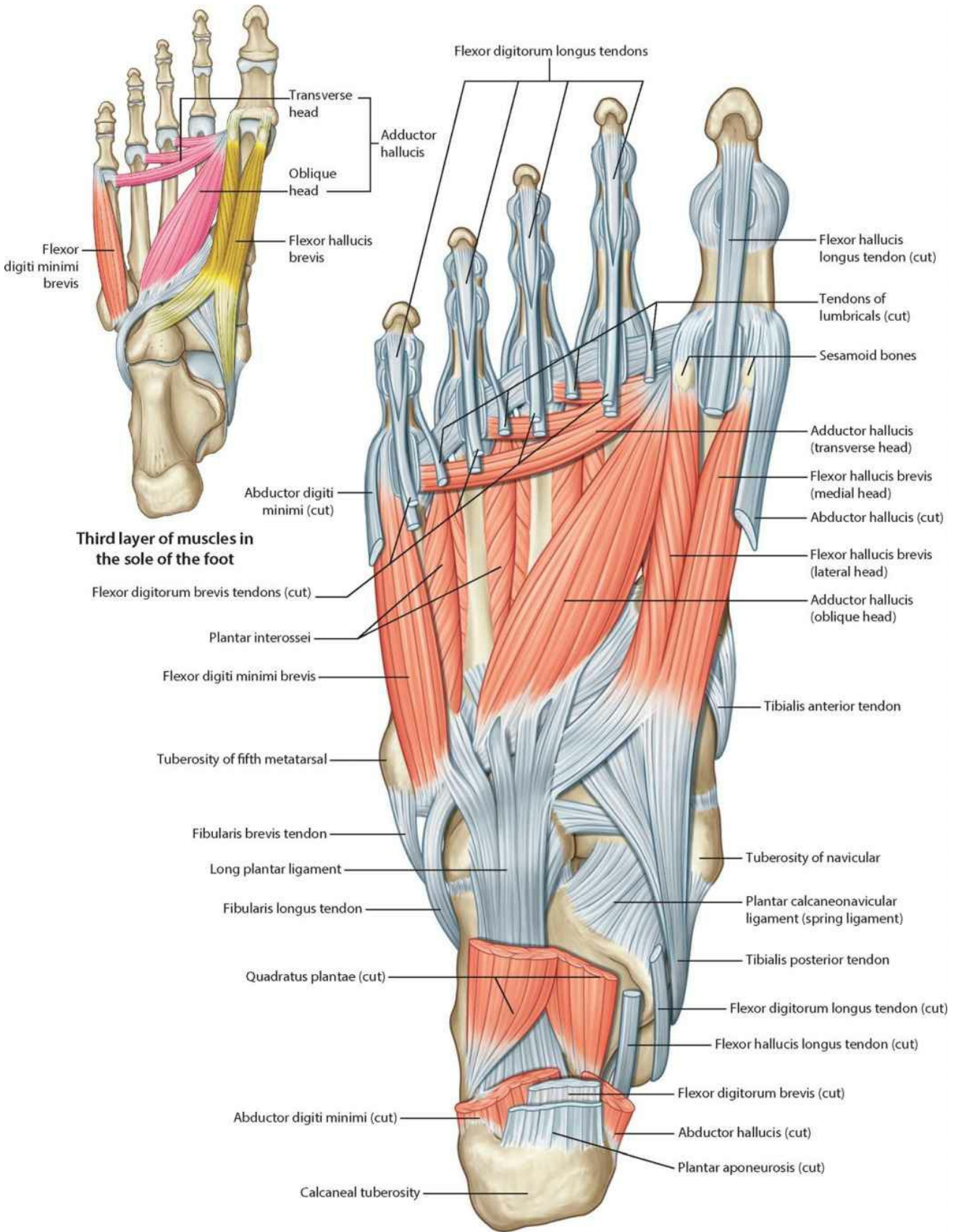


Muscles of sole of foot (second layer)



## **Plantar region (sole) musculature: third layer**

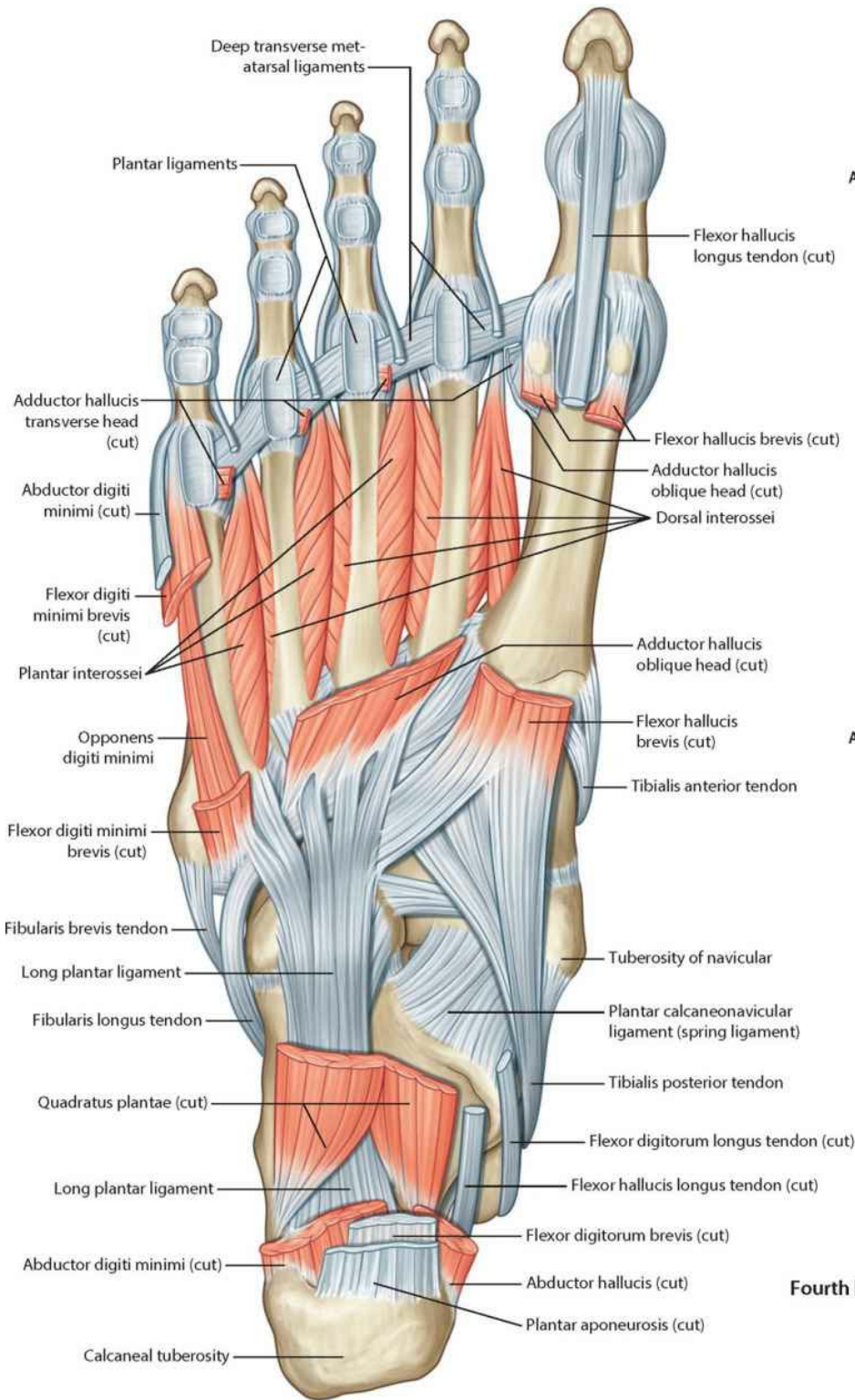




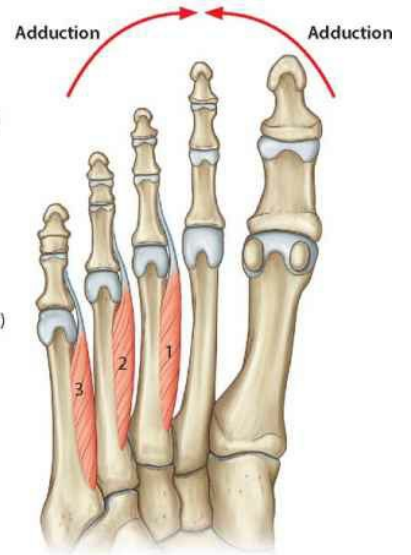
**Third layer of muscles in the sole of the foot**

**Muscles of sole of foot (third layer)**

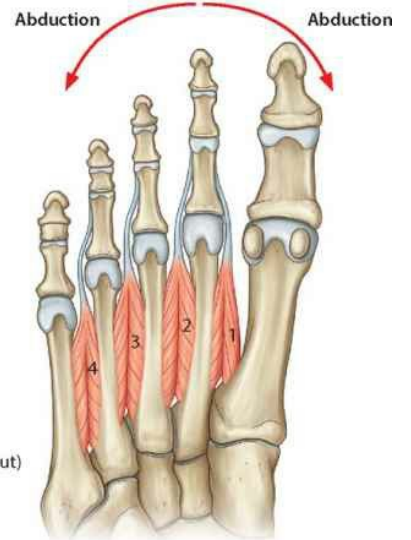
## **Plantar region (sole) musculature: fourth layer**



Muscles of sole of foot (fourth layer)



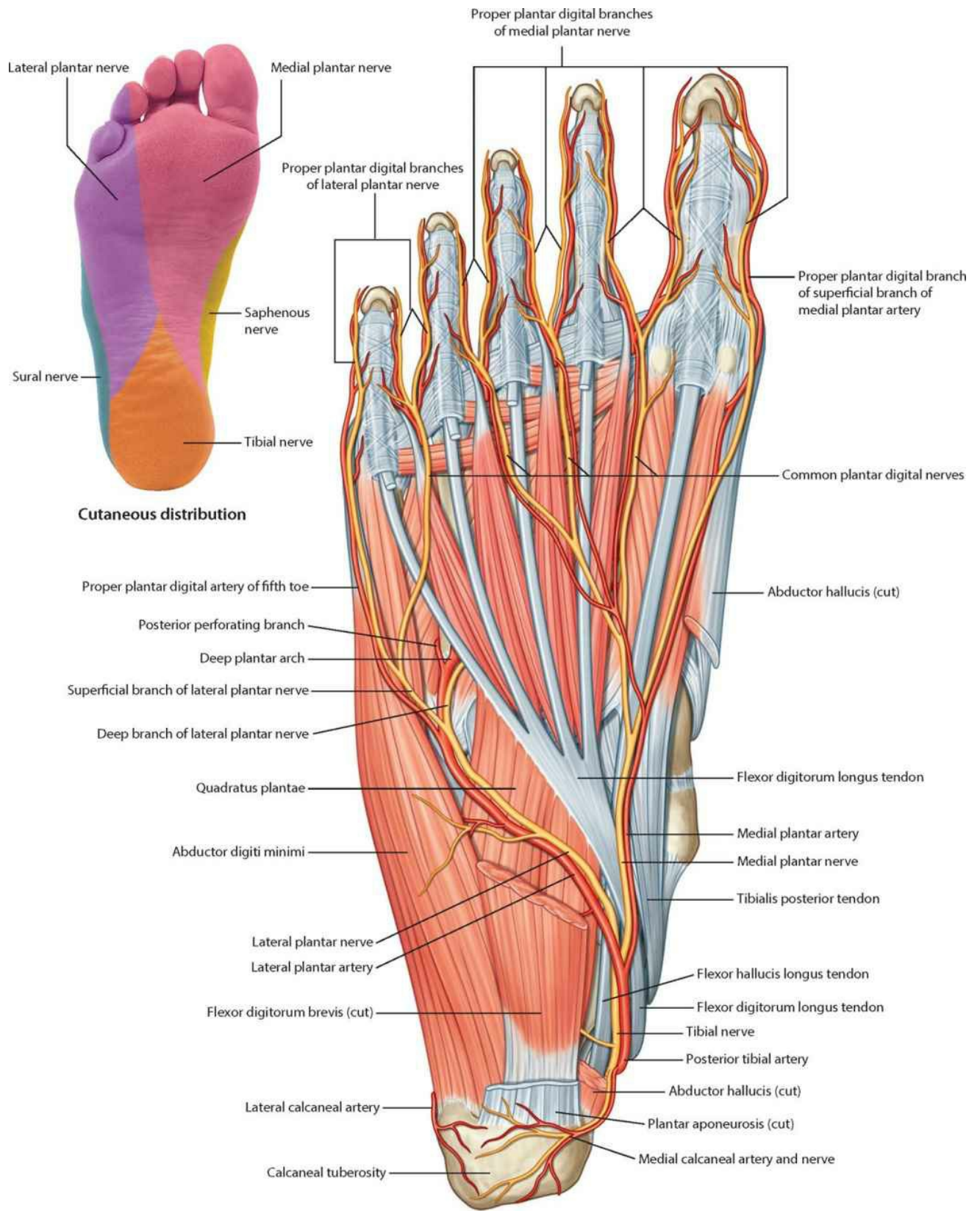
Plantar interossei (unipennate)



Dorsal interossei (bipennate)

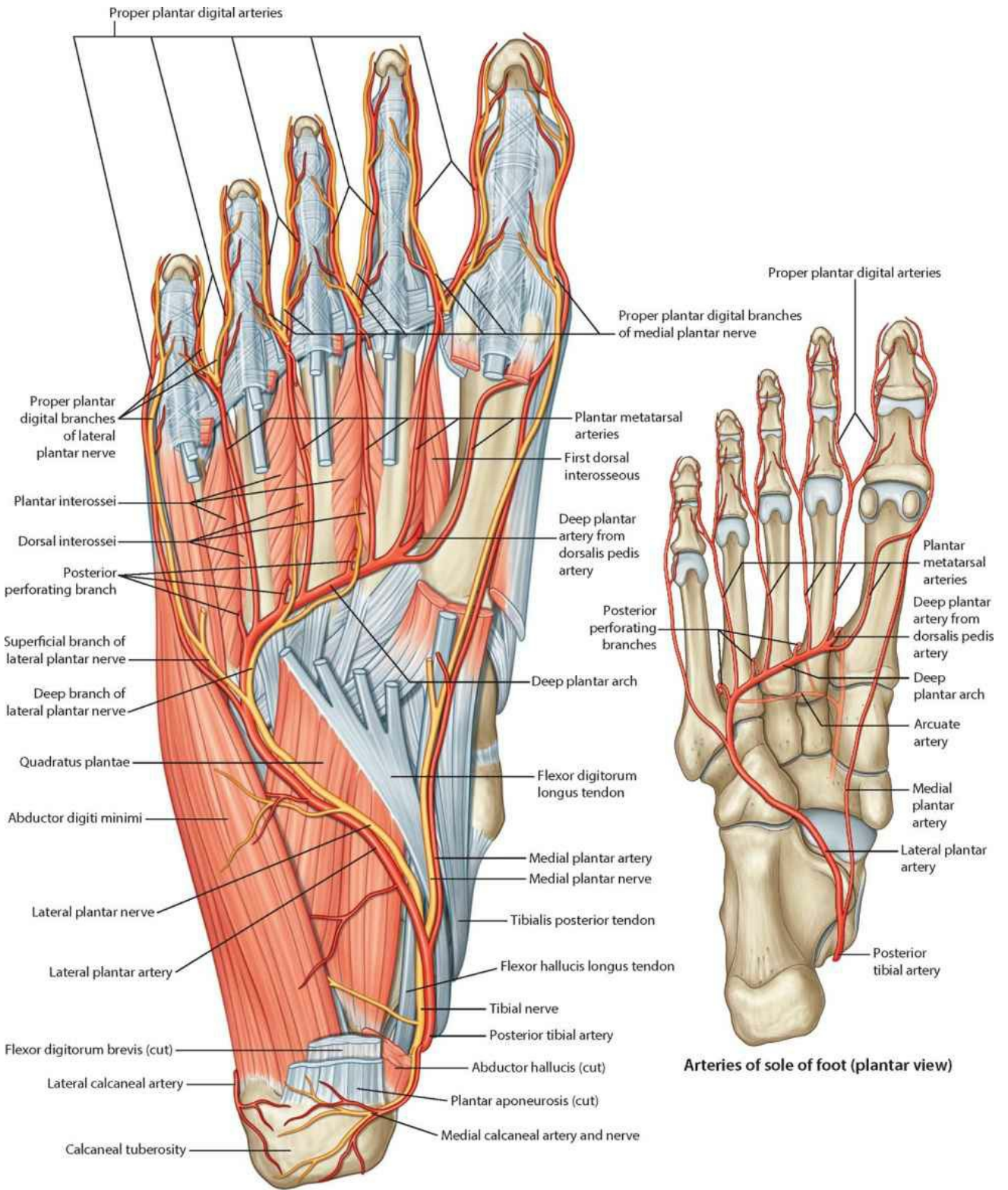
Fourth layer of muscles in the sole of the foot

## **Plantar region (sole): arteries and nerves**



**Arteries and nerves of sole of foot (plantar view)**



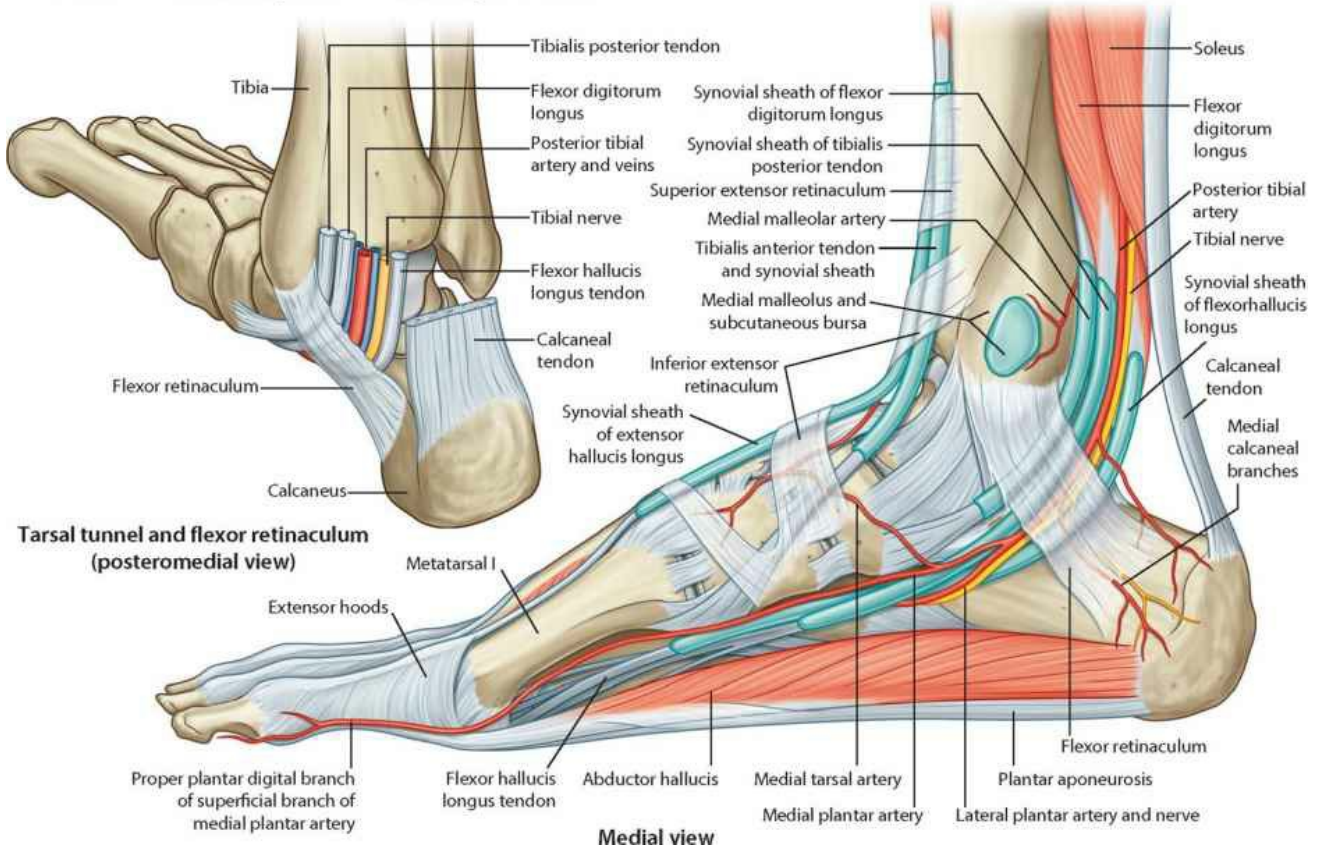
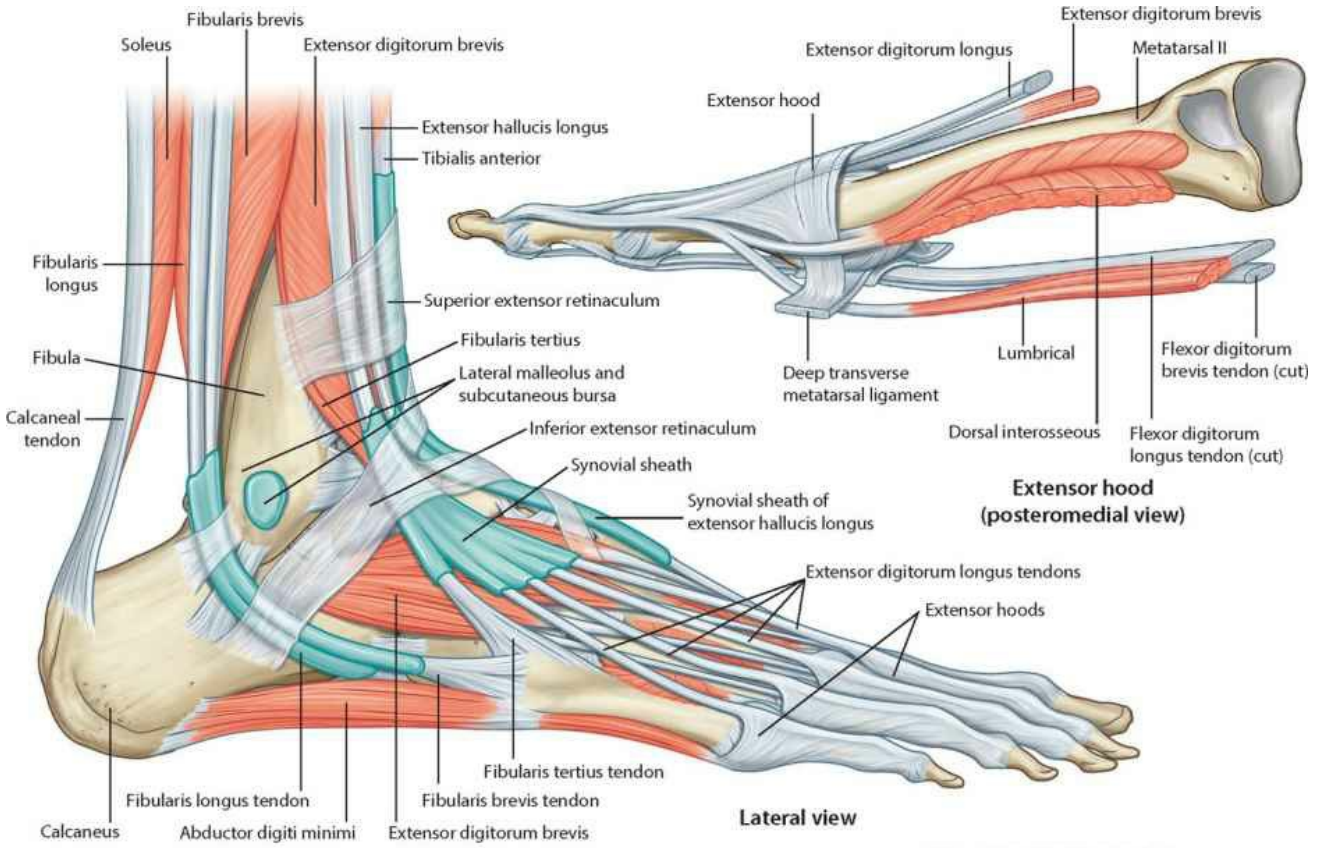


**Arteries and nerves of sole of foot (plantar view)**

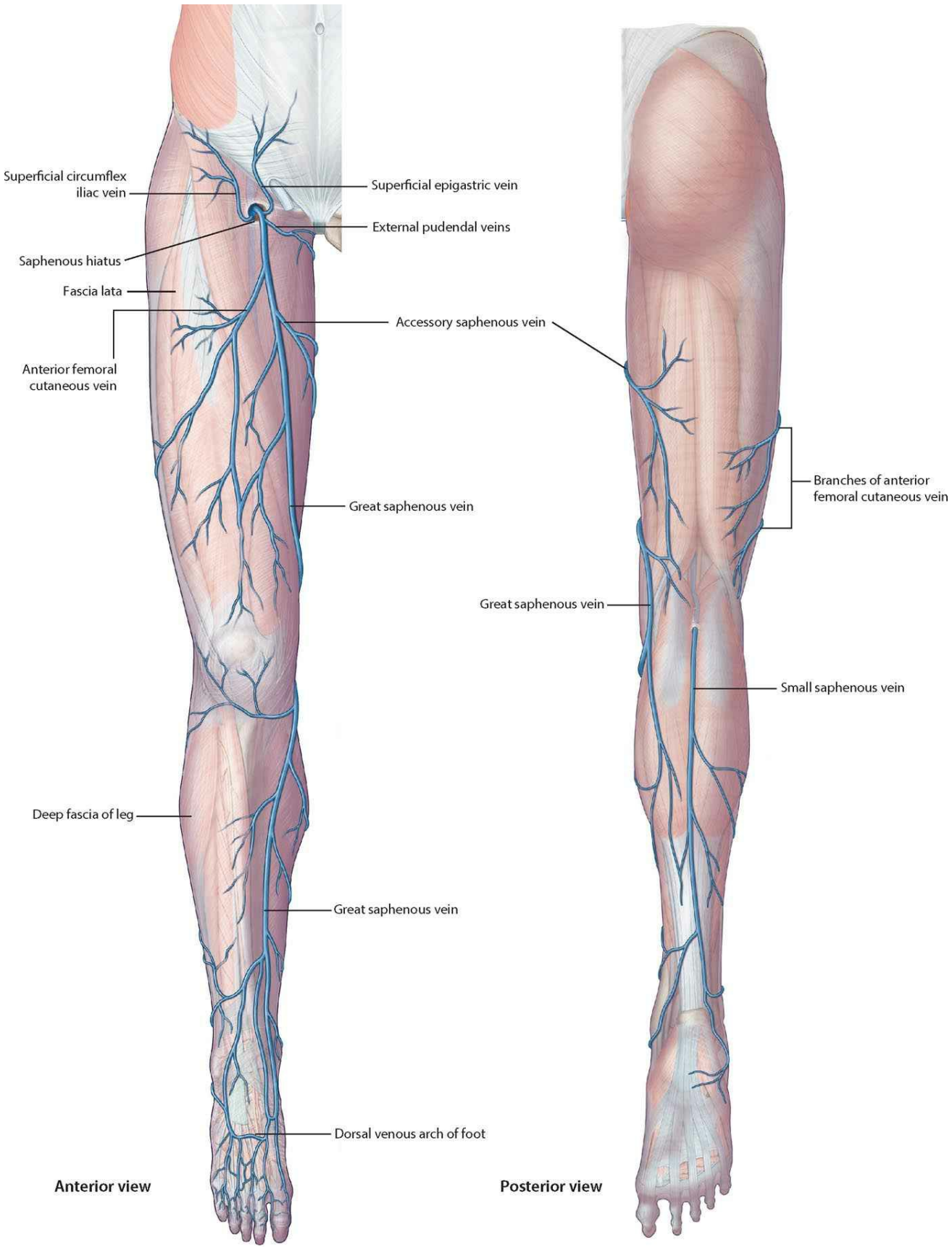
**Arteries of sole of foot (plantar view)**

## **Dorsal hood and tarsal tunnel**

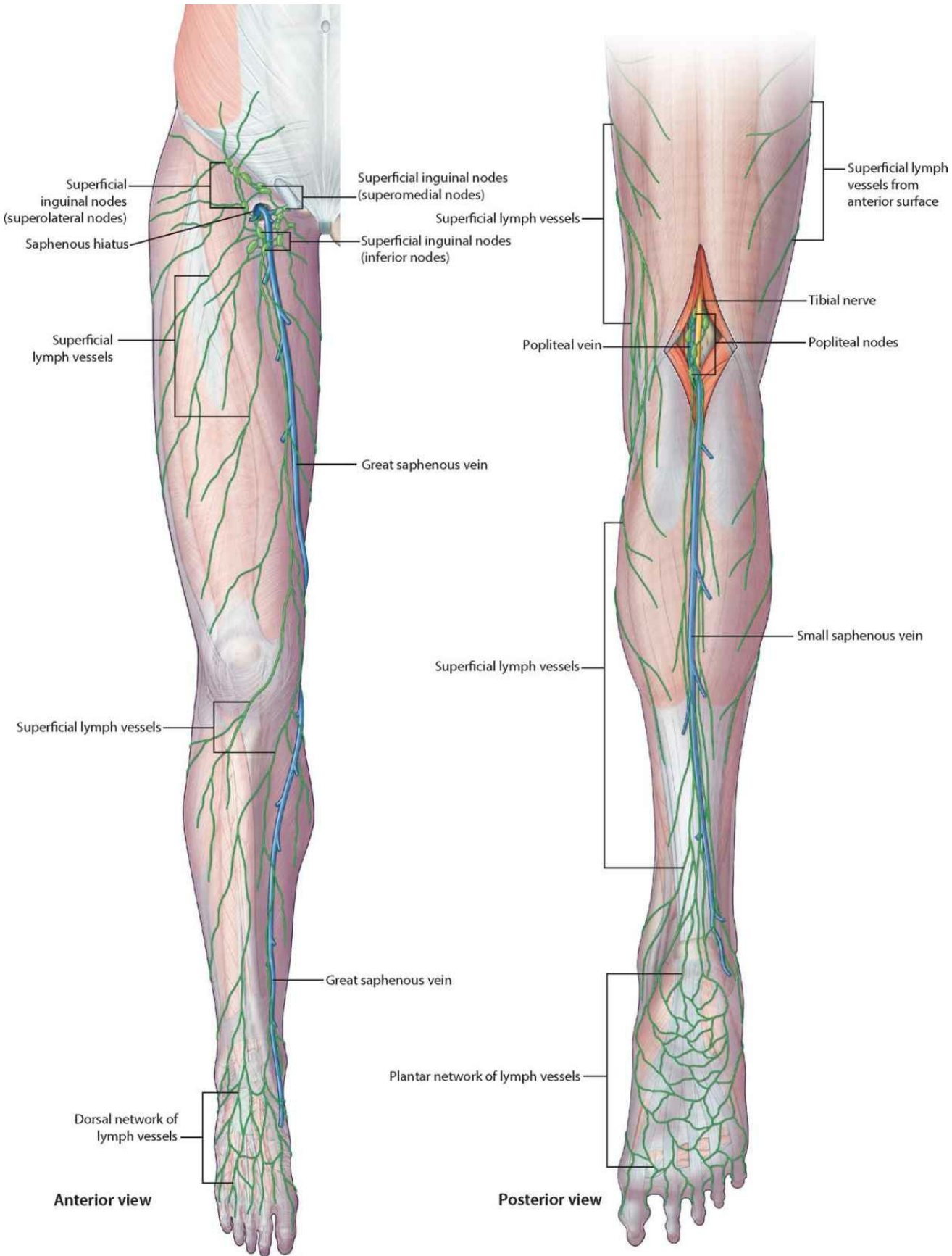




# Superficial veins of the lower limb



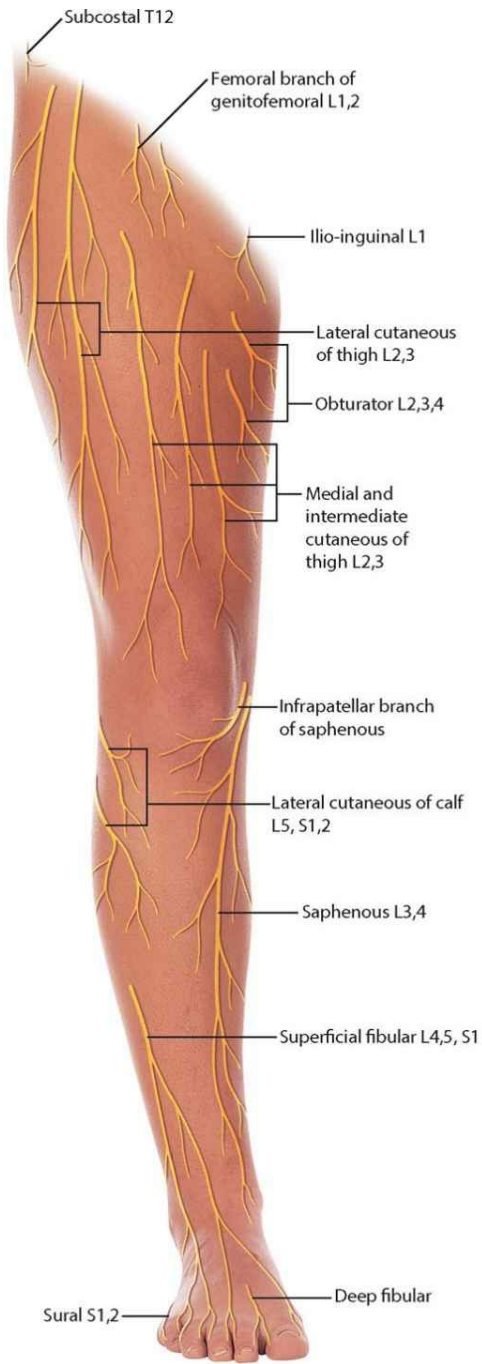
# Lymphatics of the lower limb



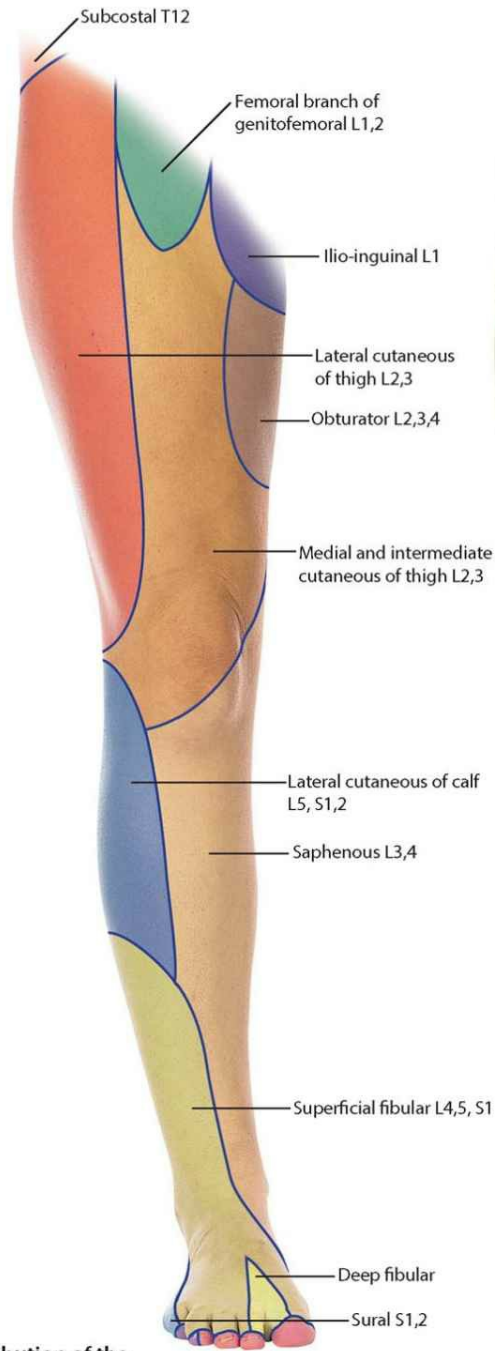
**Anterior view**

**Posterior view**

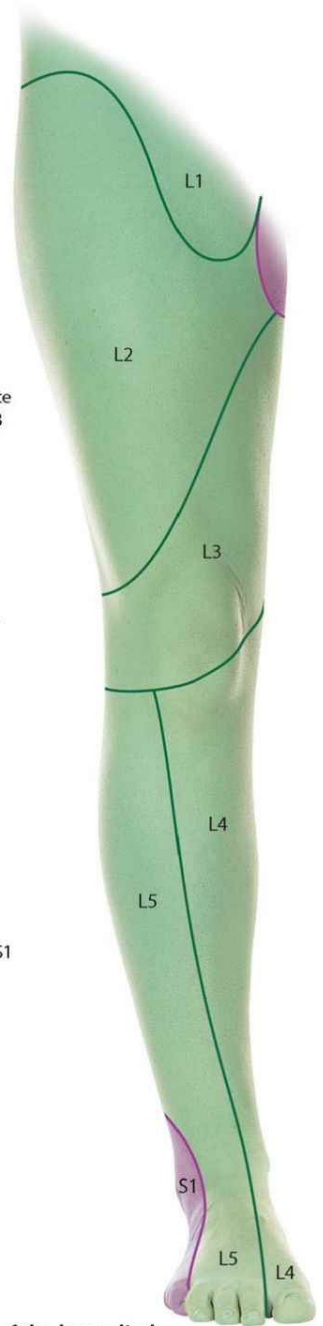# **Anterior cutaneous nerves and dermatomes of the lower limb**



**Cutaneous nerves of the lower limb**



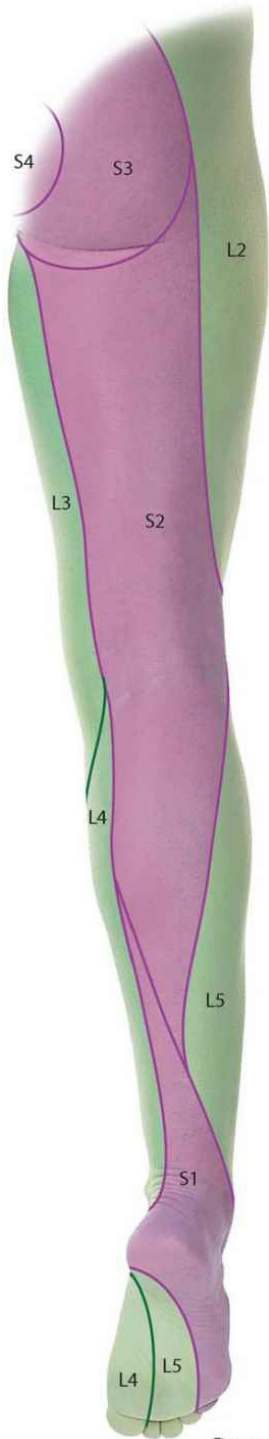
**Areas of distribution of the cutaneous nerves of the lower limb**



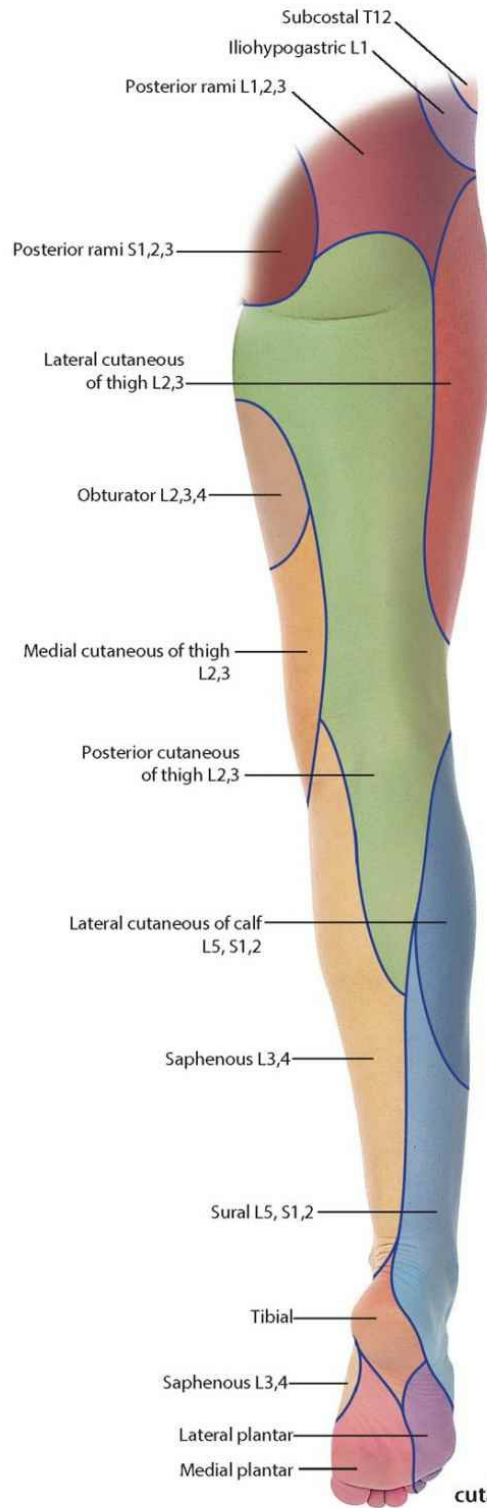
**Dermatomes of the lower limb**

# Posterior cutaneous nerves and dermatomes of the lower limb

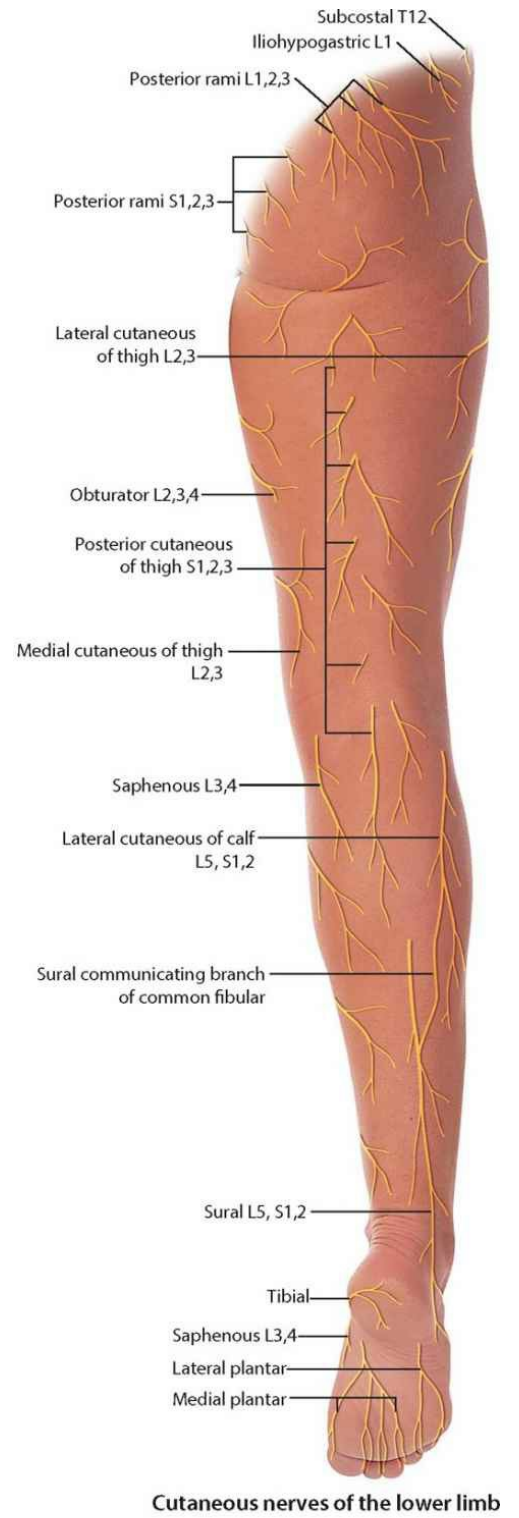




**Dermatomes of the lower limb**



**Areas of distribution of the cutaneous nerves of the lower limb**

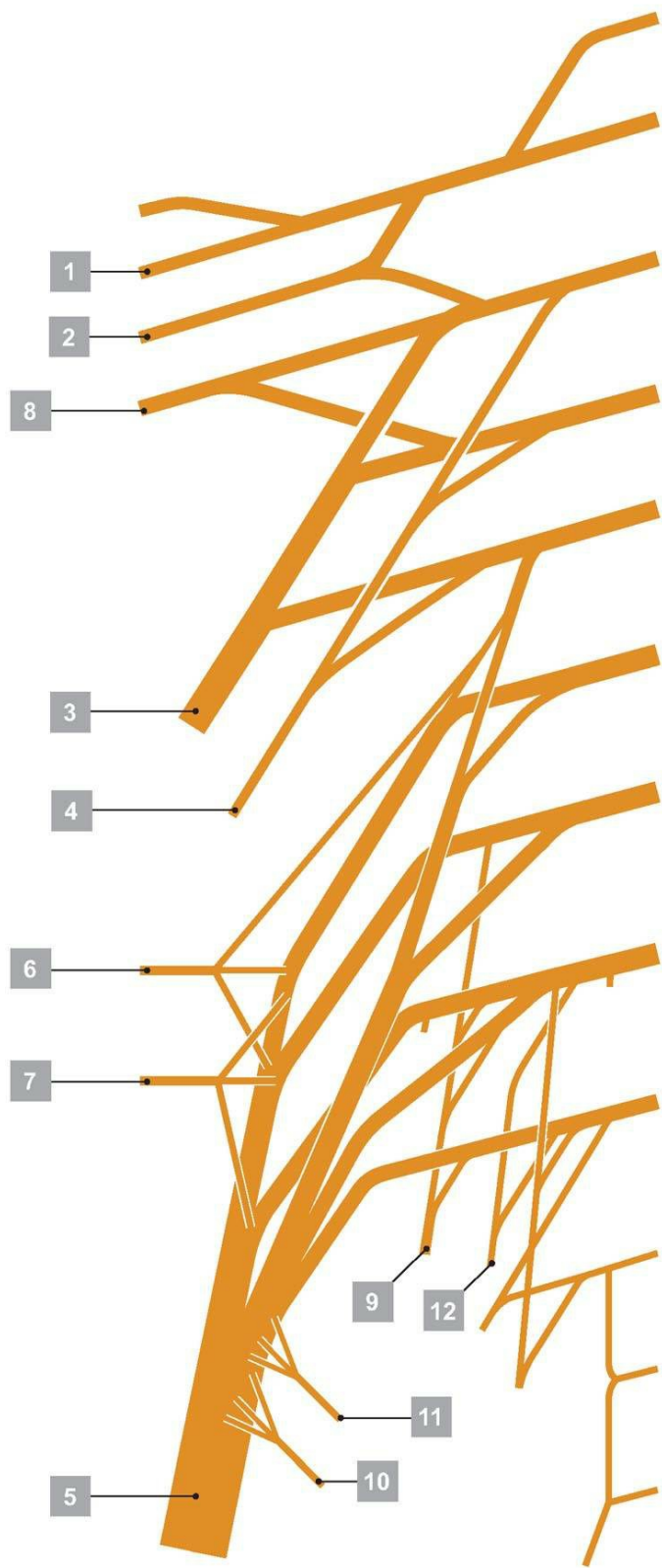


**Cutaneous nerves of the lower limb**

# Tables

## Branches of the lumbosacral plexus associated with the lower limb

Branch		Spinal segments	Function: motor	Function: sensory (cutaneous)
Ilio-inguinal	1	L1	No motor function in lower limb, but innervates muscles of the abdominal wall	Skin over anteromedial part of upper thigh and adjacent skin of perineum
Genitofemoral	2	L1, L2	No motor function in lower limb, but genital branch innervates cremaster muscle in the wall of the spermatic cord in men	Femoral branch innervates skin on anterior central part of upper thigh; the genital branch innervates skin in anterior part of perineum (anterior scrotum in men, and mons pubis and anterior labia majora in women)
Femoral	3	L2 to L4	All muscles in the anterior compartment of thigh; in the abdomen, also gives rise to branches that supply iliacus and pectineus	Skin over the anterior thigh, anteromedial knee, medial side of the leg, and the medial side of the foot
Obturator	4	L2 to L4	All muscles in the medial compartment of thigh (except pectineus and the part of adductor magnus attached to the ischium); also innervates obturator externus	Skin over upper medial aspect of thigh
Sciatic	5	L4 to S3	All muscles in the posterior compartment of thigh and the part of adductor magnus attached to the ischium; all muscles in the leg and foot	Skin over lateral side of leg and foot, and over the sole and dorsal surface of foot
Superior gluteal	6	L4 to S1	Muscles of the gluteal region (gluteus medius, gluteus minimus, tensor fasciae latae)	
Inferior gluteal	7	L5 to S2	Muscle of the gluteal region (gluteus maximus)	
Lateral cutaneous nerve of thigh	8	L2, L3		Parietal peritoneum in iliac fossa; skin over anterolateral thigh
Posterior cutaneous nerve of thigh	9	S1 to S3		Skin over gluteal fold and upper medial aspect of thigh and adjacent perineum, posterior aspect of thigh and upper posterior leg
Nerve to quadratus femoris	10	L4 to S1	Muscles of gluteal region (quadratus femoris and gemellus inferior)	
Nerve to obturator internus	11	L5 to S2	Muscles of gluteal region (obturator internus and gemellus superior)	
Perforating cutaneous nerve	12	S2, S3		Skin over medial aspect of gluteal fold



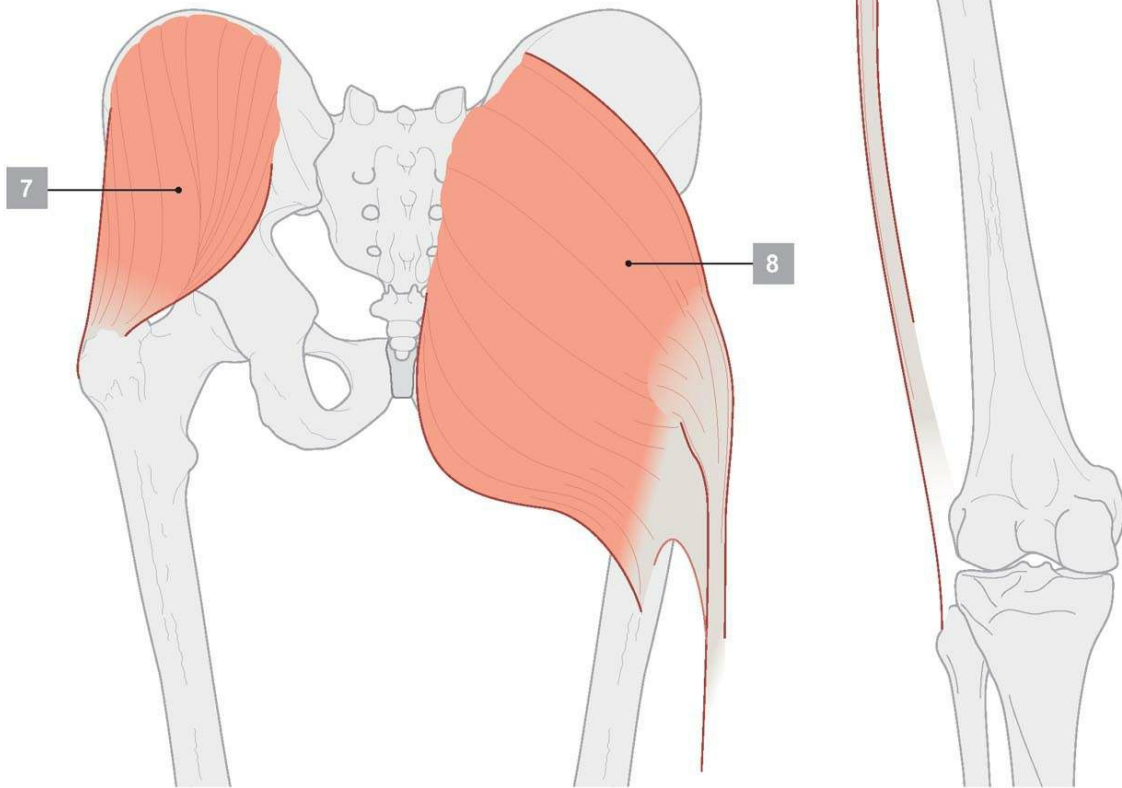
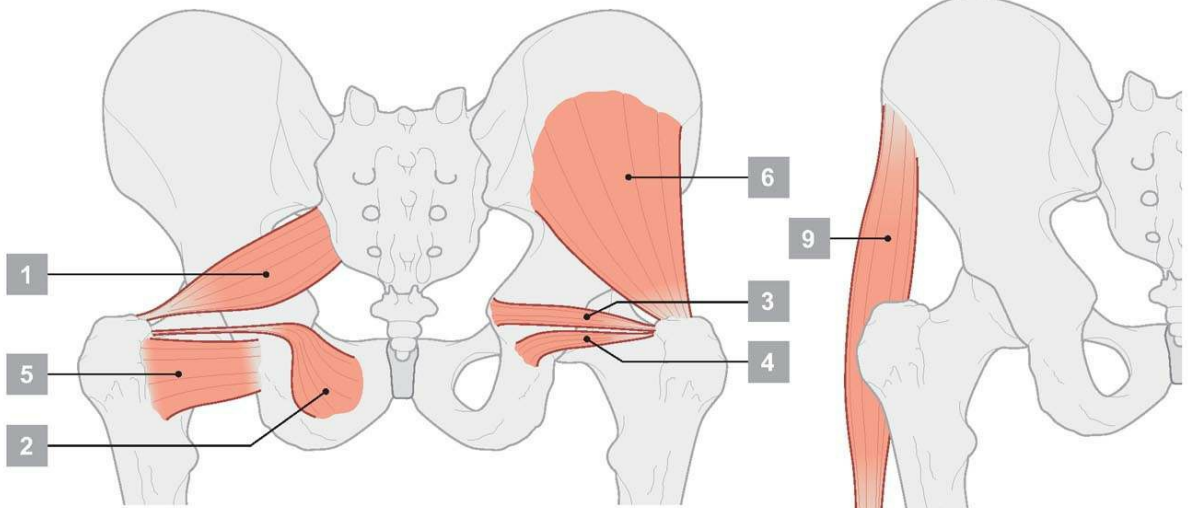
## Muscles of the gluteal region

(spinal segments in bold are the major segments innervating the muscle)

---

Muscle		Origin	Insertion	Innervation	Function
<b>Piriformis</b>	1	Anterior surface of sacrum between anterior sacral foramina	Medial side of superior border of greater trochanter of femur	Branches from <b>L5, S1, S2</b>	Laterally rotates the extended femur at hip joint; abducts flexed femur at hip joint
<b>Obturator internus</b>	2	Anterolateral wall of true pelvis; deep surface of obturator membrane and surrounding bone	Medial side of greater trochanter of femur	Nerve to obturator internus ( <b>L5, S1</b> )	Laterally rotates the extended femur at hip joint; abducts flexed femur at hip joint
<b>Gemellus superior</b>	3	External surface of ischial spine	Along length of superior surface of the obturator internus tendon and into the medial side of greater trochanter of femur with obturator internus tendon	Nerve to obturator internus ( <b>L5, S1</b> )	Laterally rotates the extended femur at hip joint; abducts flexed femur at hip joint
<b>Gemellus inferior</b>	4	Upper aspect of ischial tuberosity	Along length of inferior surface of the obturator internus tendon and into the medial side of greater trochanter of femur with obturator internus tendon	Nerve to quadratus femoris ( <b>L5, S1</b> )	Laterally rotates the extended femur at hip joint; abducts flexed femur at hip joint
<b>Quadratus femoris</b>	5	Lateral aspect of the ischium just anterior to the ischial tuberosity	Quadratus tubercle on the intertrochanteric crest of the proximal femur	Nerve to quadratus femoris ( <b>L5, S1</b> )	Laterally rotates femur at hip joint
<b>Gluteus minimus</b>	6	External surface of ilium between inferior and anterior gluteal lines	Linear facet on the anterolateral aspect of the greater trochanter	Superior gluteal nerve ( <b>L4, L5, S1</b> )	Abducts femur at hip joint; holds pelvis secure over stance leg and prevents pelvic drop on the opposite swing side during walking; medially rotates thigh
<b>Gluteus medius</b>	7	External surface of ilium between anterior and posterior gluteal lines	Elongate facet on the lateral surface of the greater trochanter	Superior gluteal nerve ( <b>L4, L5, S1</b> )	Abducts femur at hip joint; holds pelvis secure over stance leg and prevents pelvic drop on the opposite swing side during walking; medially rotates thigh
<b>Gluteus maximus</b>	8	Fascia covering gluteus medius, external surface of ilium behind posterior gluteal line, fascia of erector spinae, dorsal surface of lower sacrum, lateral margin of coccyx, external surface of sacrotuberous ligament	Posterior aspect of iliotibial tract of fascia lata and gluteal tuberosity of proximal femur	Inferior gluteal nerve ( <b>L5, S1, S2</b> )	Powerful extensor of flexed femur at hip joint; lateral stabilizer of hip joint and knee joint; laterally rotates and abducts thigh
<b>Tensor fasciae latae</b>	9	Lateral aspect of crest of ilium between anterior superior iliac spine and tubercle of the crest	Iliotibial tract of fascia lata	Superior gluteal nerve ( <b>L4, L5, S1</b> )	Stabilizes the knee in extension

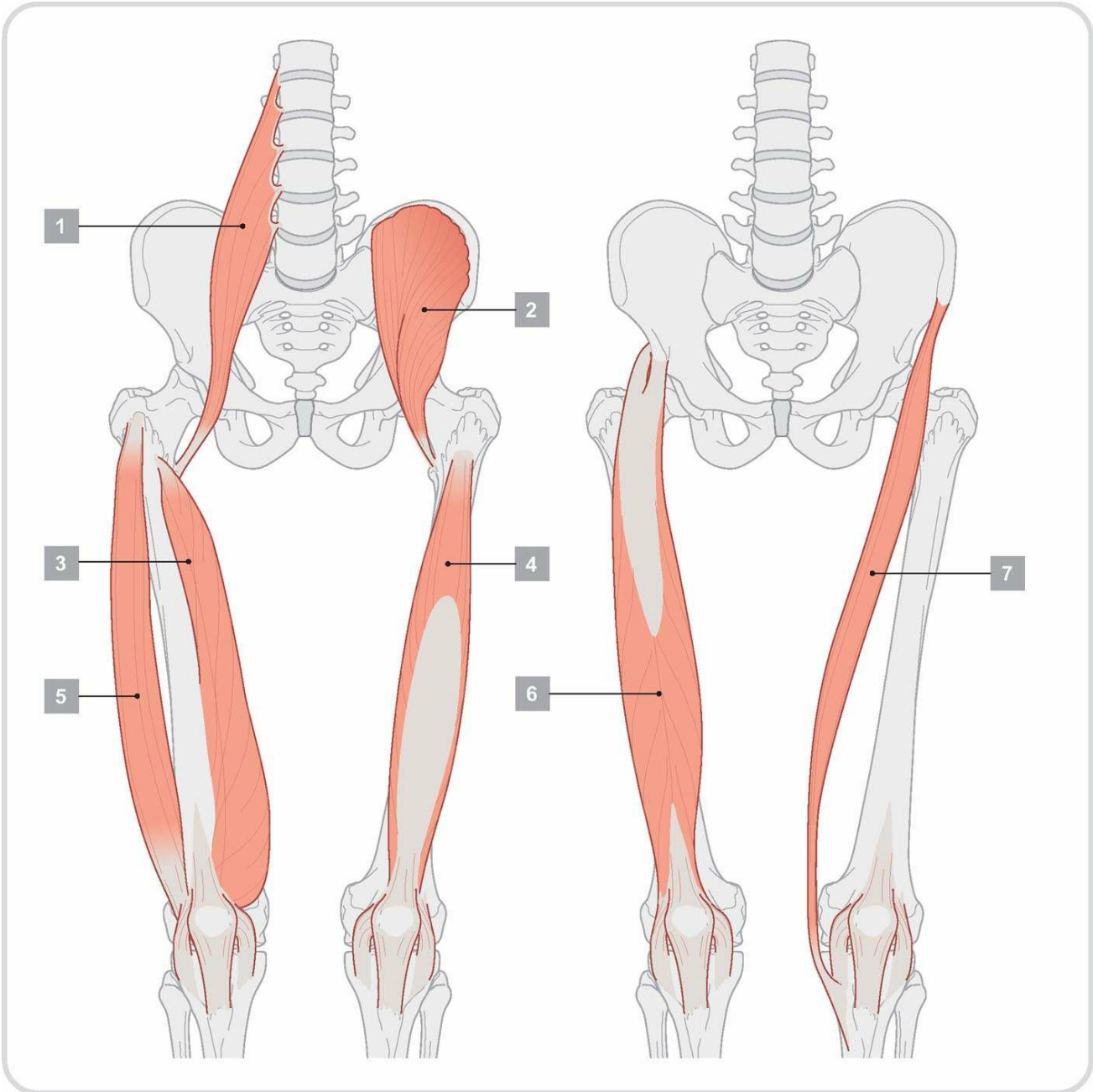




## Muscles of the anterior compartment of thigh (spinal segments in bold are the major segments innervating the muscle)

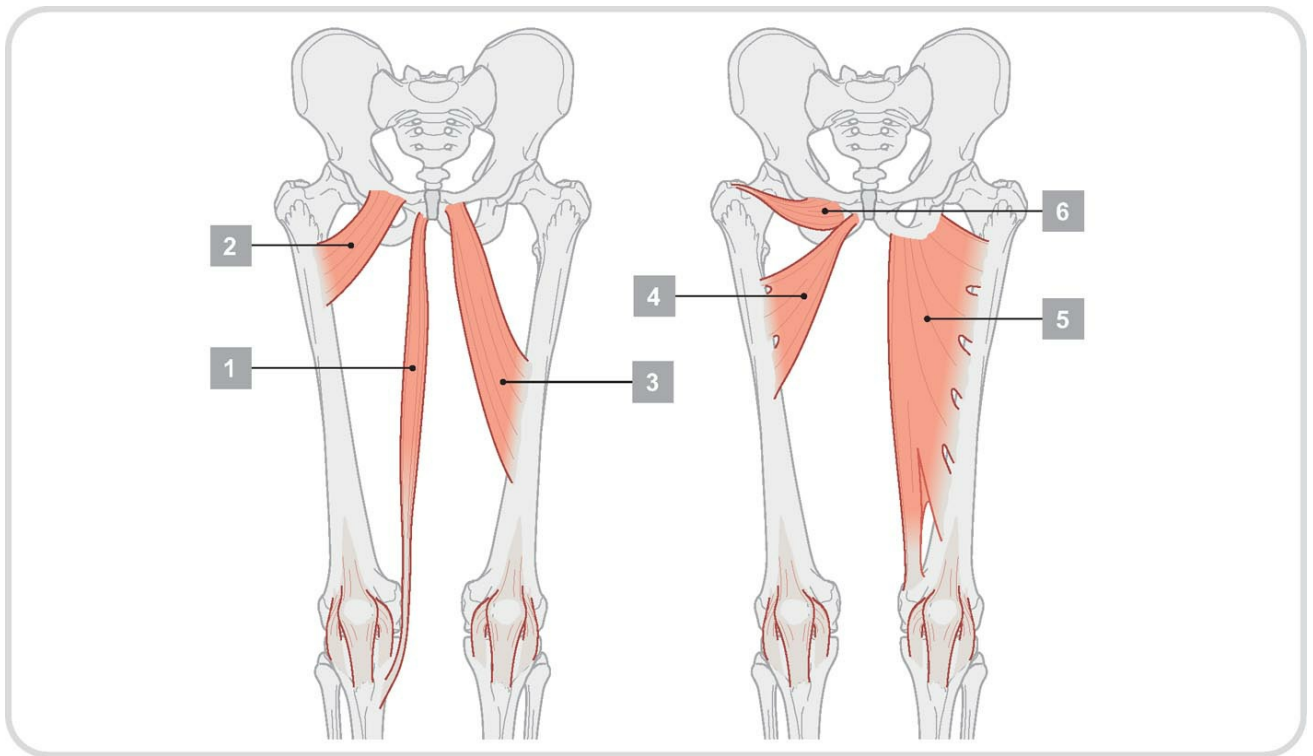
Muscle		Origin	Insertion	Innervation	Function
<b>Psoas major</b>	1	Posterior abdominal wall (lumbar transverse processes, intervertebral discs, and adjacent bodies from TXII to LV and tendinous arches between these points)	Lesser trochanter of femur	Anterior rami [ <b>L1, L2, L3</b> ]	Flexes the thigh at the hip joint
<b>Iliacus</b>	2	Posterior abdominal wall (iliac fossa)	Lesser trochanter of femur	Femoral nerve [ <b>L2, L3</b> ]	Flexes the thigh at the hip joint
<b>Vastus medialis</b>	3	Femur—medial part of intertrochanteric line, pectineal line, medial lip of the linea aspera, medial supracondylar line	Quadriceps femoris tendon and medial border of patella	Femoral nerve [ <b>L2, L3, L4</b> ]	Extends the leg at the knee joint
<b>Vastus intermedius</b>	4	Femur—upper two-thirds of anterior and lateral surfaces	Quadriceps femoris tendon and lateral margin of patella	Femoral nerve [ <b>L2, L3, L4</b> ]	Extends the leg at the knee joint
<b>Vastus lateralis</b>	5	Femur—lateral part of intertrochanteric line, margin of greater trochanter, lateral margin of gluteal tuberosity, lateral lip of the linea aspera	Quadriceps femoris tendon	Femoral nerve [ <b>L2, L3, L4</b> ]	Extends the leg at the knee joint
<b>Rectus femoris</b>	6	Straight head originates from the anterior inferior iliac spine; reflected head originates from the ilium just superior to the acetabulum	Quadriceps femoris tendon	Femoral nerve [ <b>L2, L3, L4</b> ]	Flexes the thigh at the hip joint and extends the leg at the knee joint
<b>Sartorius</b>	7	Anterior superior iliac spine	Medial surface of tibia just inferomedial to tibial tuberosity	Femoral nerve [ <b>L2, L3</b> ]	Flexes the thigh at the hip joint and flexes the leg at the knee joint





## Muscles of the medial compartment of thigh (spinal segments in bold are the major segments innervating the muscle)

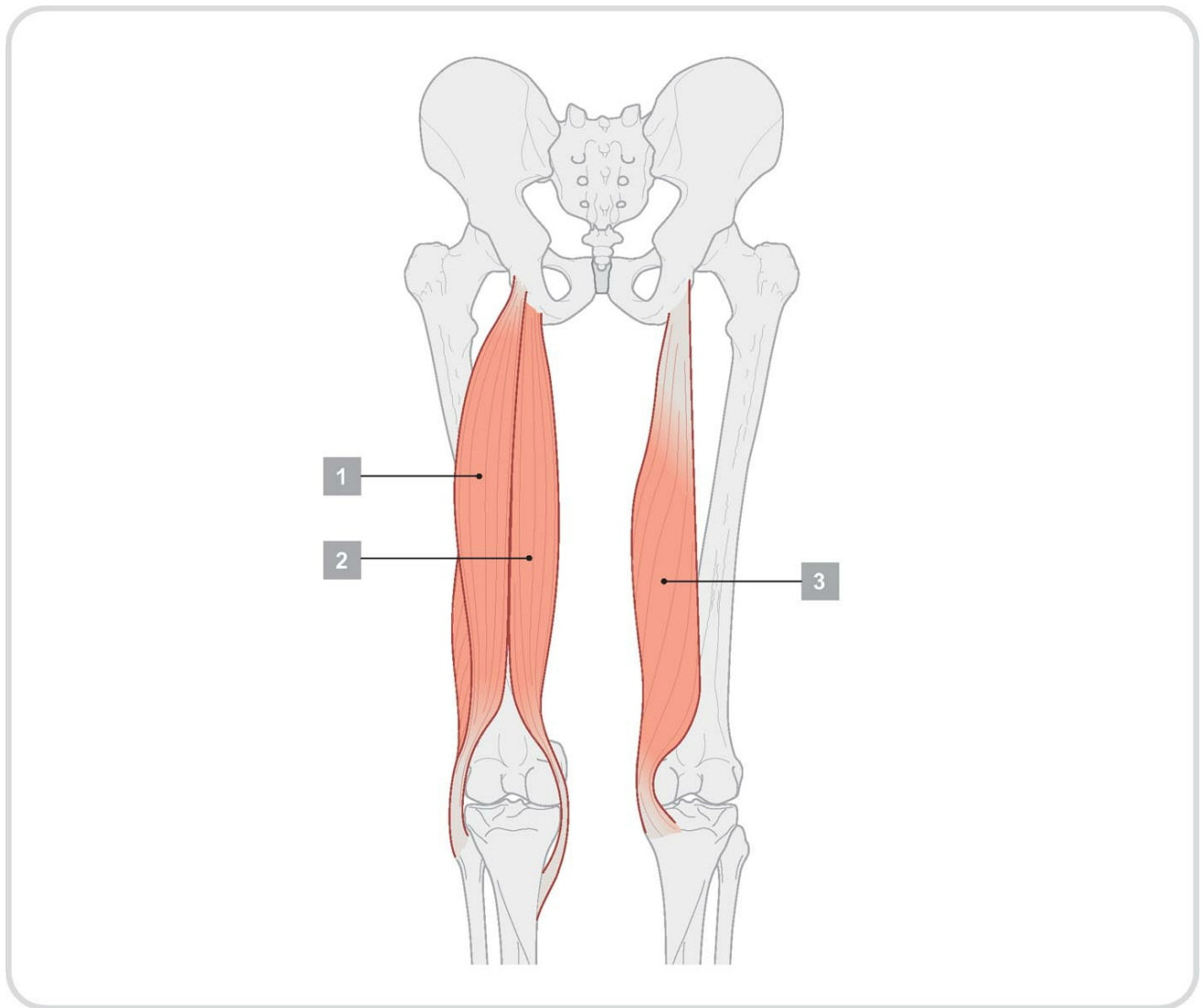
Muscle		Origin	Insertion	Innervation	Function
Gracilis	1	A line on the external surfaces of the body of the pubis, the inferior pubic ramus, and the ramus of the ischium	Medial surface of proximal shaft of tibia	Obturator nerve [L2, L3]	Adducts thigh at hip joint and flexes leg at knee joint
Pectineus	2	Pectineal line (pecten pubis) and adjacent bone of pelvis	Oblique line extending from base of lesser trochanter to linea aspera on posterior surface of proximal femur	Femoral nerve [L2, L3]	Adducts and flexes thigh at hip joint
Adductor longus	3	External surface of body of pubis (triangular depression inferior to pubic crest and lateral to pubic symphysis)	Linea aspera on middle one-third of shaft of femur	Obturator nerve (anterior division) [L2, L3, L4]	Adducts and medially rotates thigh at hip joint
Adductor brevis	4	External surface of body of pubis and inferior pubic ramus	Posterior surface of proximal femur and upper one-third of linea aspera	Obturator nerve [L2, L3]	Adducts and medially rotates thigh at hip joint
Adductor magnus	5	Adductor part —ischiopubic ramus Hamstring part —ischial tuberosity	Posterior surface of proximal femur, linea aspera, medial supracondylar line Adductor tubercle and supracondylar line	Obturator nerve [L2, L3, L4] Sciatic nerve (tibial division) [L2, L3, L4]	Adducts and medially rotates thigh at hip joint
Obturator externus	6	External surface of obturator membrane and adjacent bone	Trochanteric fossa	Obturator nerve (posterior division) [L3, L4]	Laterally rotates thigh at hip joint



**Muscles of the posterior compartment of thigh**  
**(spinal segments in bold are the major segments innervating the muscle)**

Muscle		Origin	Insertion	Innervation	Function
<b>Biceps femoris</b>	<b>1</b>	Long head—inferomedial part of the upper area of the ischial tuberosity; short head—lateral lip of linea aspera	Head of fibula	Sciatic nerve [L5, <b>S1</b> , S2]	Flexes leg at knee joint; extends and laterally rotates thigh at hip joint and laterally rotates leg at knee joint
<b>Semitendinosus</b>	<b>2</b>	Inferomedial part of the upper area of the ischial tuberosity	Medial surface of proximal tibia	Sciatic nerve [L5, <b>S1</b> , S2]	Flexes leg at knee joint and extends thigh at hip joint; medially rotates thigh at hip joint and leg at knee joint
<b>Semimembranosus</b>	<b>3</b>	Superolateral impression on the ischial tuberosity	Groove and adjacent bone on medial and posterior surface of medial tibial condyle	Sciatic nerve [L5, <b>S1</b> , S2]	Flexes leg at knee joint and extends thigh at hip joint; medially rotates thigh at hip joint and leg at knee joint

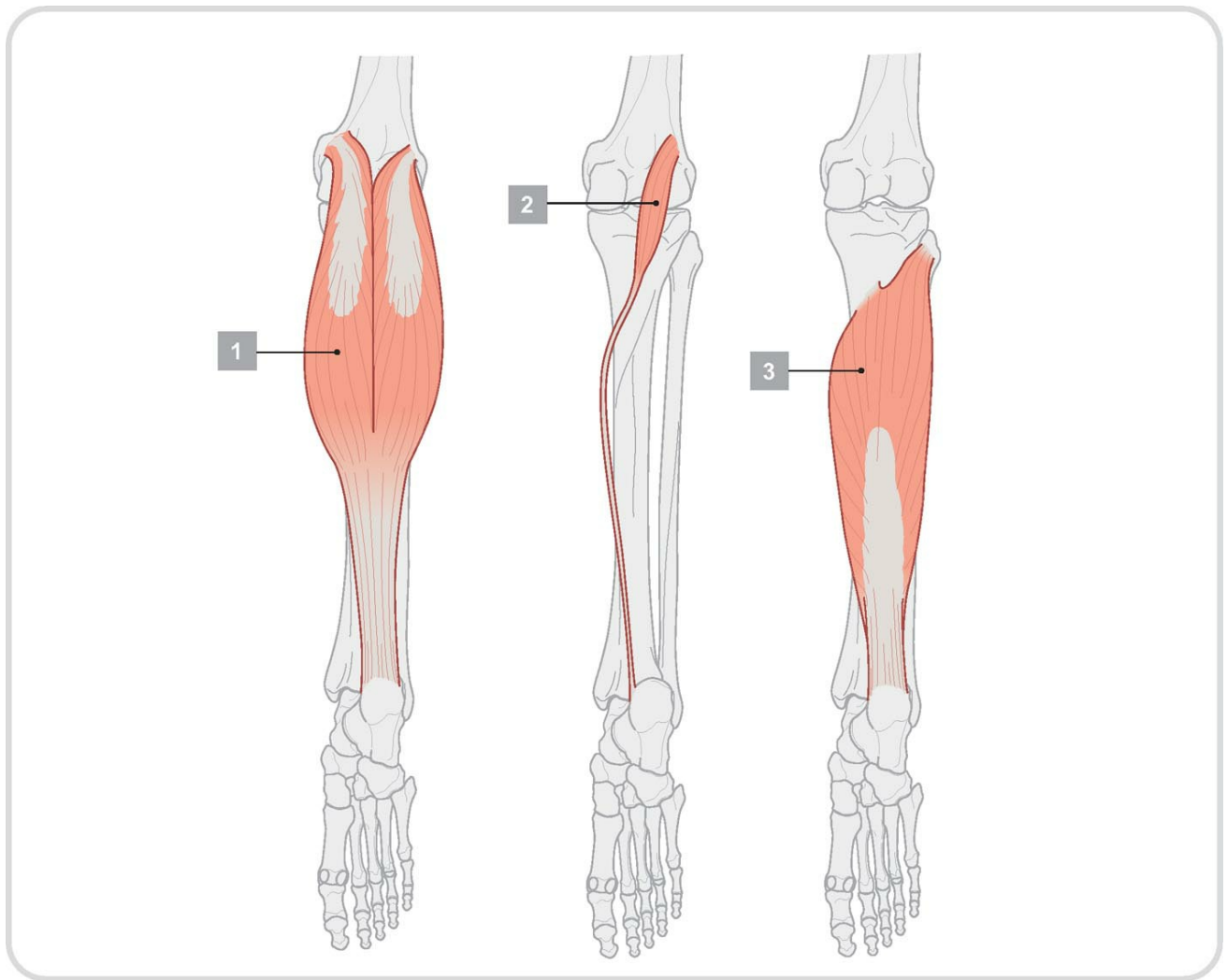




**Superficial group of muscles in the posterior compartment of leg  
(spinal segments in bold are the major segments innervating the muscle)**

Muscle		Origin	Insertion	Innervation	Function
<b>Gastrocnemius</b>	1	Medial head—posterior surface of distal femur just superior to medial condyle; lateral head—upper posterolateral surface of lateral femoral condyle	Via calcaneal tendon, to posterior surface of calcaneus	Tibial nerve <b>[S1, S2]</b>	Plantarflexes foot and flexes knee
<b>Plantaris</b>	2	Inferior part of lateral supracondylar line of femur and oblique popliteal ligament of knee	Via calcaneal tendon, to posterior surface of calcaneus	Tibial nerve <b>[S1, S2]</b>	Plantarflexes foot and flexes knee
<b>Soleus</b>	3	Soleal line and medial border of tibia; posterior aspect of fibular head and adjacent surfaces of neck and proximal shaft; tendinous arch between tibial and fibular attachments	Via calcaneal tendon, to posterior surface of calcaneus	Tibial nerve <b>[S1, S2]</b>	Plantarflexes the foot



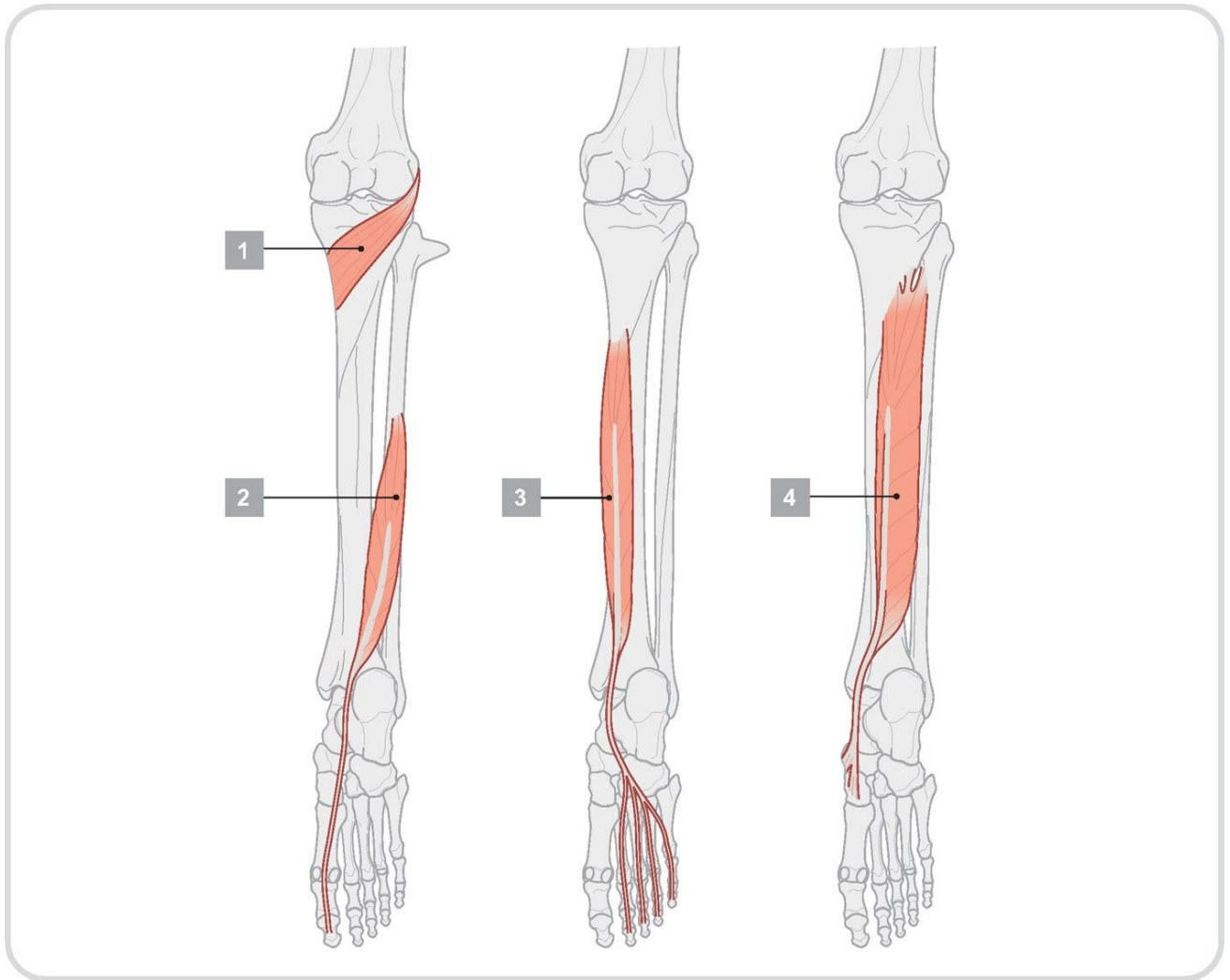


**Deep group of muscles in the posterior compartment of leg  
(spinal segments in bold are the major segments innervating the muscle)**

Muscle		Origin	Insertion	Innervation	Function
Popliteus	1	Lateral femoral condyle	Posterior surface of proximal tibia	Tibial nerve [L4 to S1]	Stabilizes knee joint (resists lateral rotation of tibia on femur) Unlocks knee joint (laterally rotates femur on fixed tibia)
Flexor hallucis longus	2	Posterior surface of fibula and adjacent interosseous membrane	Plantar surface of distal phalanx of great toe	Tibial nerve [S2, S3]	Flexes great toe
Flexor digitorum longus	3	Medial side of posterior surface of the tibia	Plantar surfaces of bases of distal phalanges of the lateral four toes	Tibial nerve [S2, S3]	Flexes lateral four toes
Tibialis posterior	4	Posterior surfaces of interosseous membrane and adjacent regions of tibia and fibula	Mainly to tuberosity of navicular and adjacent region of medial cuneiform	Tibial nerve [L4, L5]	Inversion and plantarflexion of foot; support of medial arch of foot during walking







**Muscles of the lateral compartment of leg  
(spinal segments in bold are the major segments innervating the muscle)**

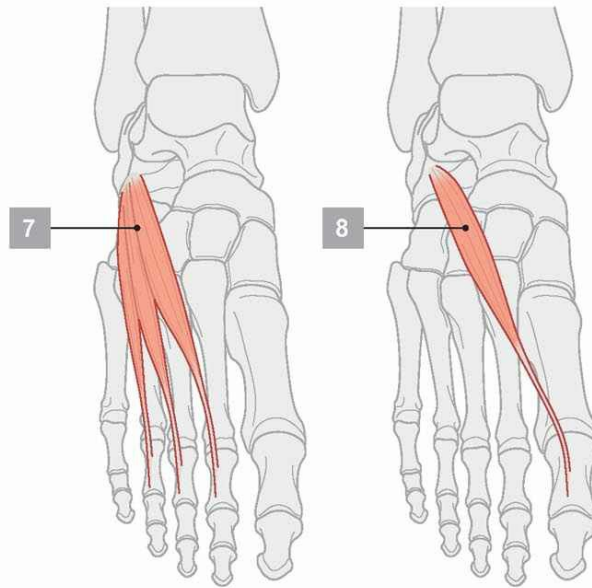
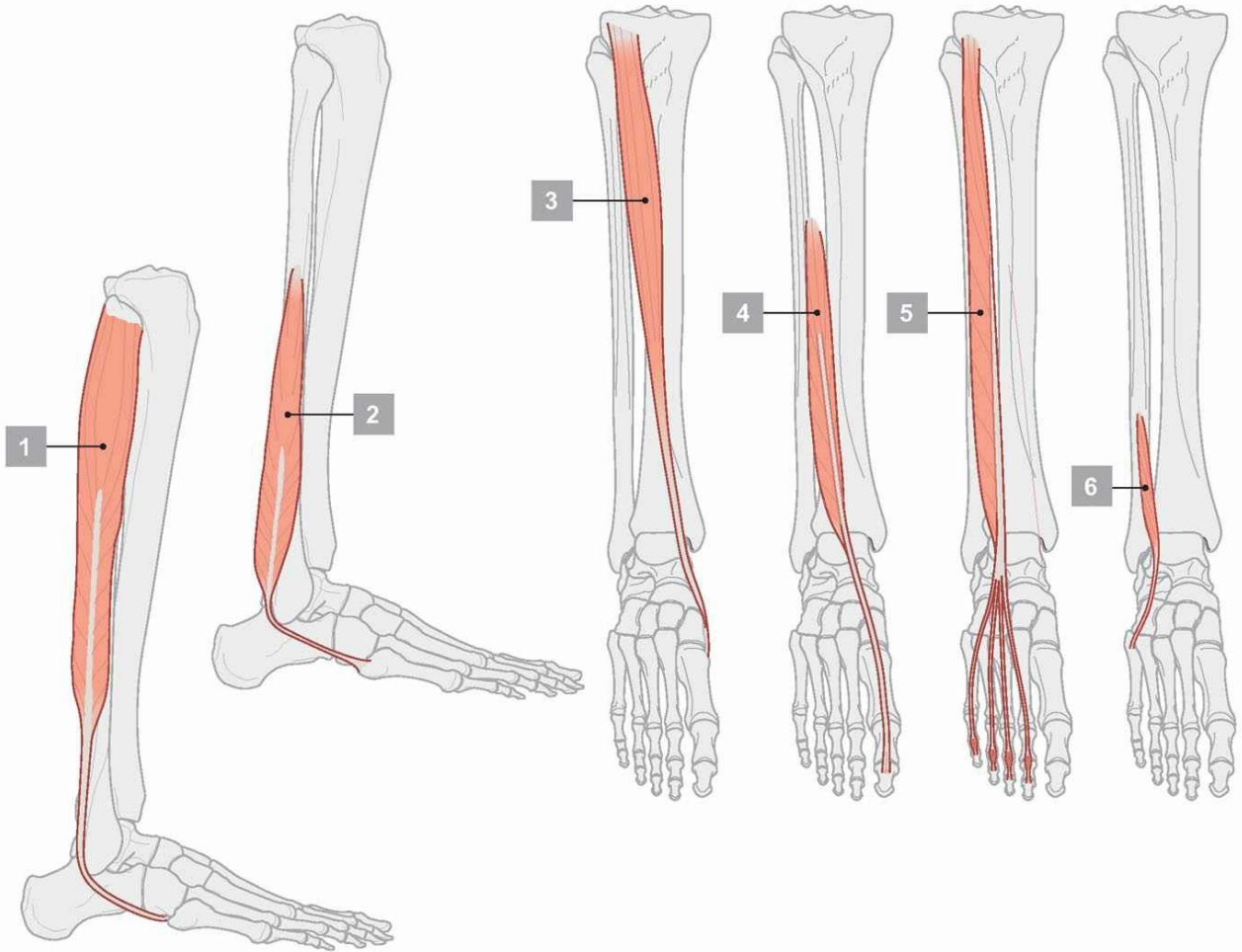
Muscle		Origin	Insertion	Innervation	Function
<b>Fibularis longus</b>	1	Upper lateral surface of fibula, head of fibula, and occasionally the lateral tibial condyle	Undersurface of lateral sides of distal end of medial cuneiform and base of metatarsal I	Superficial fibular nerve [ <b>L5</b> , <b>S1</b> , <b>S2</b> ]	Eversion and plantarflexion of foot; supports arches of foot
<b>Fibularis brevis</b>	2	Lower two-thirds of lateral surface of shaft of fibula	Lateral tubercle at base of metatarsal V	Superficial fibular nerve [ <b>L5</b> , <b>S1</b> , <b>S2</b> ]	Eversion of foot

## Muscles of the anterior compartment of leg

Tibialis anterior	3	Lateral surface of tibia and adjacent interosseous membrane	Medial and inferior surfaces of medial cuneiform and adjacent surfaces on base of metatarsal I	Deep fibular nerve [L4, L5]	Dorsiflexion of foot at ankle joint; inversion of foot; dynamic support of medial arch of foot
Extensor hallucis longus	4	Middle one-half of medial surface of fibula and adjacent surface of interosseous membrane	Dorsal surface of base of distal phalanx of great toe	Deep fibular nerve [L5, S1]	Extension of great toe and dorsiflexion of foot
Extensor digitorum longus	5	Proximal one-half of medial surface of fibula and related surface of lateral tibial condyle	Via dorsal digital expansions into bases of distal and middle phalanges of lateral four toes	Deep fibular nerve [L5, S1]	Extension of lateral four toes and dorsiflexion of foot
Fibularis tertius	6	Distal part of medial surface of fibula	Dorsomedial surface of base of metatarsal V	Deep fibular nerve [L5, S1]	Dorsiflexion and eversion of foot

## Muscles of the dorsal aspect of the foot

Extensor digitorum brevis	7	Superolateral surface of the calcaneus	Lateral sides of the tendons of extensor digitorum longus of toes II to IV	Deep fibular nerve [S1, S2]	Extension of metatarsophalangeal joints of toes II to IV
Extensor hallucis brevis	8	Superolateral surface of calcaneus	Base of proximal phalanx of great toe	Deep fibular nerve [S1, S2]	Extension of metatarsophalangeal joint of great toe

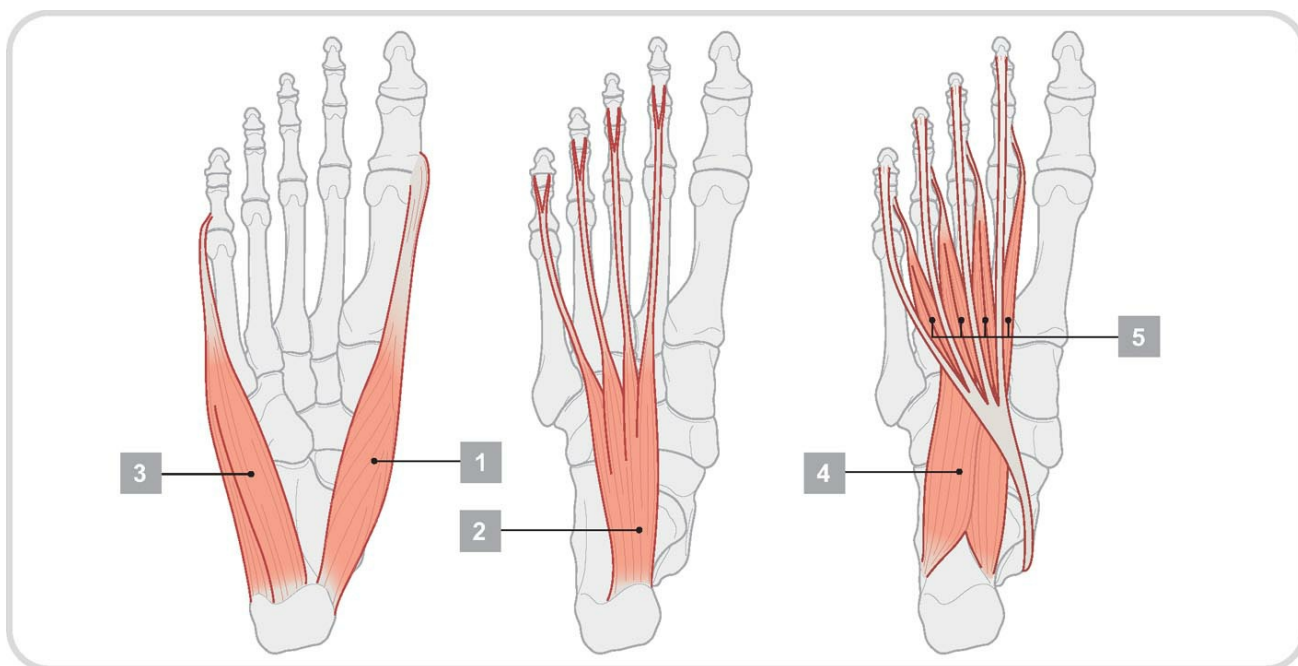


## First layer of muscles in the sole of the foot (spinal segments in bold are the major segments innervating the muscle)

Muscle		Origin	Insertion	Innervation	Function
<b>Abductor hallucis</b>	<b>1</b>	Medial process of calcaneal tuberosity	Medial side of base of proximal phalanx of great toe	Medial plantar nerve from the tibial nerve [ <b>S1, S2, S3</b> ]	Abducts and flexes great toe at metatarsophalangeal joint
<b>Flexor digitorum brevis</b>	<b>2</b>	Medial process of calcaneal tuberosity and plantar aponeurosis	Sides of plantar surface of middle phalanges of lateral four toes	Medial plantar nerve from the tibial nerve [ <b>S1, S2, S3</b> ]	Flexes lateral four toes at proximal interphalangeal joint
<b>Abductor digiti minimi</b>	<b>3</b>	Lateral and medial processes of calcaneal tuberosity, and band of connective tissue connecting calcaneus with base of metatarsal V	Lateral side of base of proximal phalanx of little toe	Lateral plantar nerve from the tibial nerve [ <b>S1, S2, S3</b> ]	Abducts little toe at the metatarsophalangeal joint

## Second layer of muscles in the sole of the foot

<b>Quadratus plantae</b>	<b>4</b>	Medial surface of calcaneus and lateral process of calcaneal tuberosity	Lateral side of tendon of flexor digitorum longus in proximal sole of the foot	Lateral plantar nerve from tibial nerve [ <b>S1, S2, S3</b> ]	Assists flexor digitorum longus tendon in flexing toes II to V
<b>Lumbricals</b>	<b>5</b>	First lumbrical—medial side of tendon of flexor digitorum longus associated with toe II; second, third, and fourth lumbricals—adjacent surfaces of adjacent tendons of flexor digitorum longus	Medial free margins of extensor hoods of toes II to V	First lumbrical—medial plantar nerve from the tibial nerve; second, third, and fourth lumbricals—lateral plantar nerve from the tibial nerve [ <b>S2, S3</b> ]	Flexion of metatarsophalangeal joint and extension of interphalangeal joints

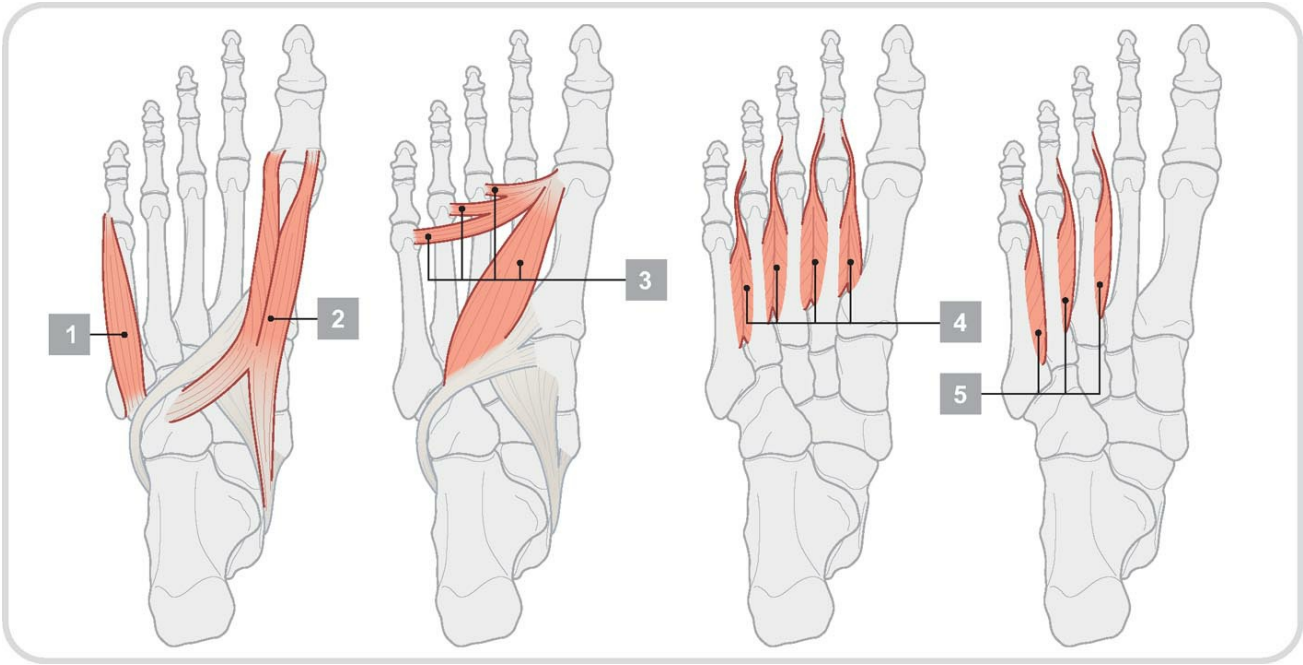


### Third layer of muscles in the sole of the foot (spinal segments in bold are the major segments innervating the muscle)

Muscle		Origin	Insertion	Innervation	Function
<b>Flexor hallucis brevis</b>	1	Plantar surface of cuboid and lateral cuneiform; tendon of tibialis posterior	Lateral and medial sides of base of proximal phalanx of the great toe	Medial plantar nerve from tibial nerve [ <b>S1</b> , <b>S2</b> ]	Flexes metatarsophalangeal joint of the great toe
<b>Adductor hallucis</b>	2	Transverse head—ligaments associated with metatarsophalangeal joints of lateral three toes; oblique head—bases of metatarsals II to IV and from sheath covering fibularis longus	Lateral side of base of proximal phalanx of great toe	Lateral plantar nerve from tibial nerve [ <b>S2</b> , <b>S3</b> ]	Adducts great toe at metatarsophalangeal joint
<b>Flexor digiti minimi brevis</b>	3	Base of metatarsal V and related sheath of fibularis longus tendon	Lateral side of base of proximal phalanx of little toe	Lateral plantar nerve from tibial nerve [ <b>S2</b> , <b>S3</b> ]	Flexes little toe at metatarsophalangeal joint

### Fourth layer of muscles in the sole of the foot

<b>Dorsal interossei</b>	4	Sides of adjacent metatarsals	Extensor hoods and bases of proximal phalanges of toes II to IV	Lateral plantar nerve from tibial nerve; first and second dorsal interossei also innervated by deep fibular nerve [ <b>S2</b> , <b>S3</b> ]	Abduction of toes II to IV at metatarsophalangeal joints; resist extension of metatarsophalangeal joints and flexion of interphalangeal joints
<b>Plantar interossei</b>	5	Medial sides of metatarsals of toes III to V	Extensor hoods and bases of proximal phalanges of toes III to V	Lateral plantar nerve from tibial nerve [ <b>S2</b> , <b>S3</b> ]	Adduction of toes III to V at metatarsophalangeal joints; resist extension of the metatarsophalangeal joints and flexion of the interphalangeal joints





# UPPER LIMB

---



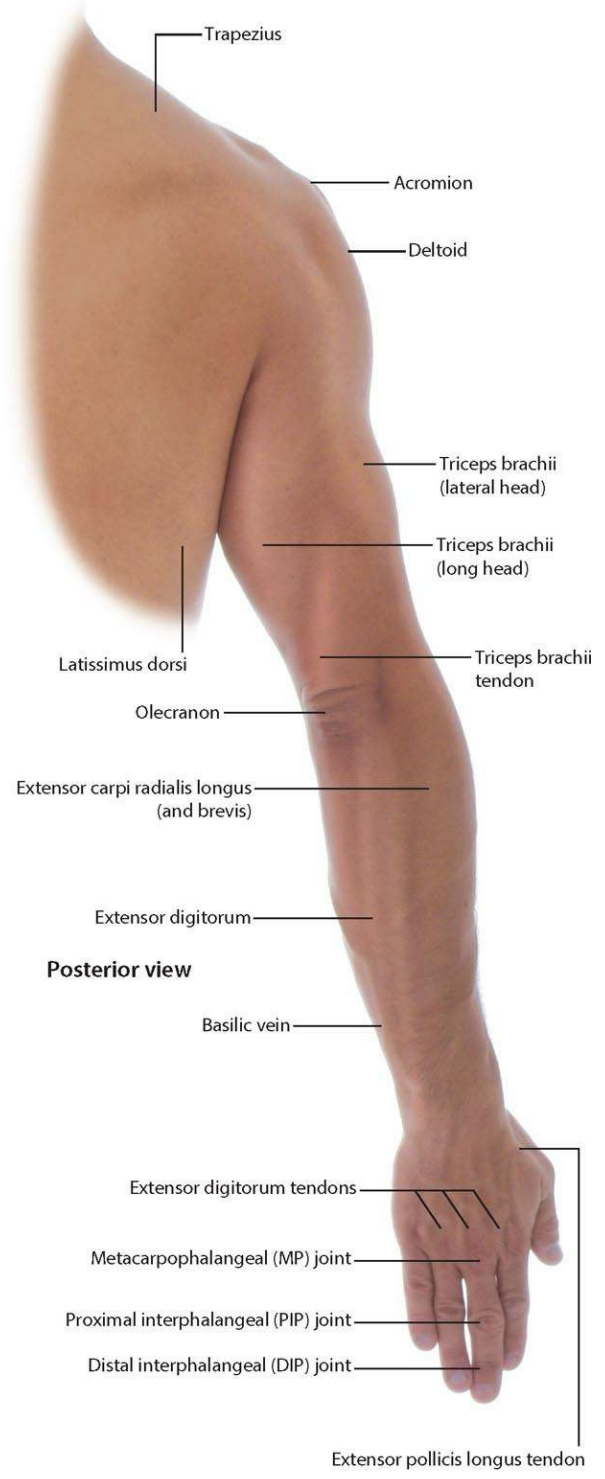
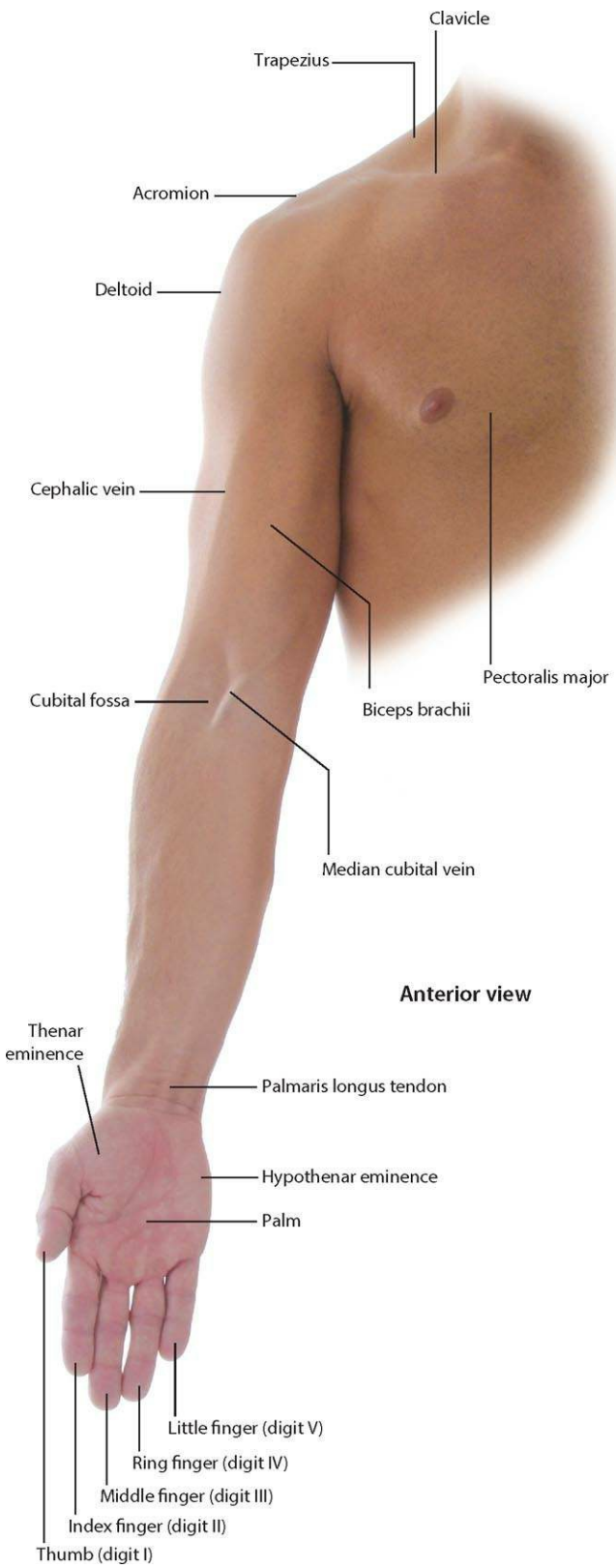
# CONTENTS

Surface anatomy	386
Bones of the upper limb	387
Bony framework of shoulder	388
Scapula	389
Clavicle: joints and ligaments	390
Proximal humerus	391
Glenohumeral joint	392
Muscle attachments	394
Pectoral region	396
Deep pectoral region	397
Walls of the axilla	398
The four rotator cuff muscles	400
Deep vessels and nerves of the shoulder	402
Axillary artery	403
Brachial artery	404
Brachial plexus	405
Medial and lateral cords	406
Posterior cord	407
Distal end of humerus and proximal end of radius and ulna	408
Muscle attachments	409
Anterior compartment: muscles	410
Anterior compartment: arteries and nerves	412
Veins of the arm	413
Posterior compartment: muscles	414
Posterior compartment: arteries and nerves	416
Lymphatics of the arm	417
Transverse sections: arm	418
Anterior cutaneous nerves of the arm	420
Posterior cutaneous nerves of the arm	421

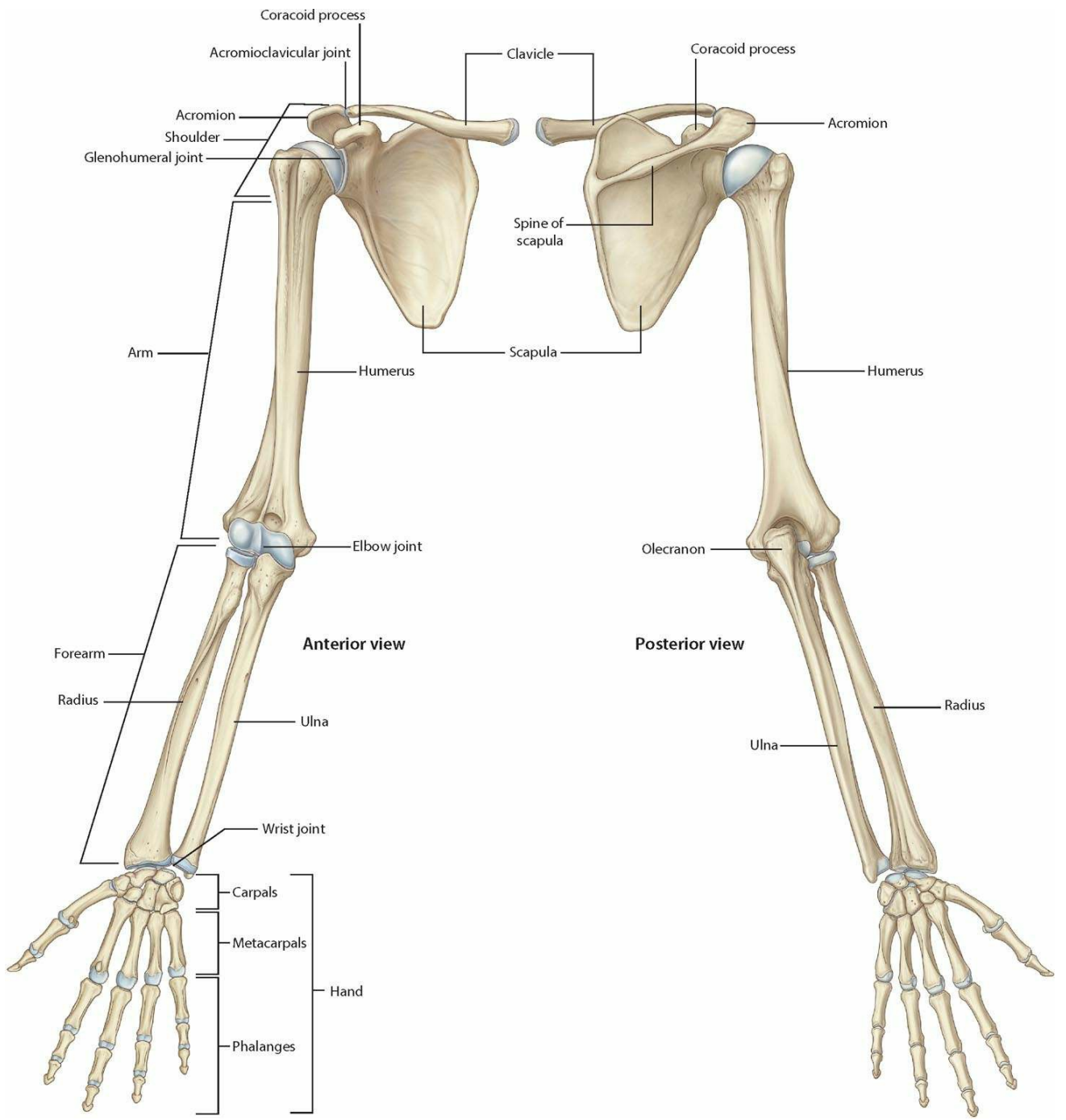
Elbow joint [422](#)  
Elbow joint: capsule and ligaments [424](#)  
Cubital fossa [426](#)  
Radius and ulna [427](#)  
Bones of the hand and wrist joint [428](#)  
Imaging of the hand and wrist joint [429](#)  
Bones of the hand [430](#)  
Joints and ligaments of the hand [431](#)  
Muscle attachments of forearm [432](#)  
Anterior compartment of forearm: muscles [433](#)  
Anterior compartment of forearm: arteries and nerves [436](#)  
Posterior compartment of forearm: muscles [437](#)  
Posterior compartment of forearm: arteries and nerves [439](#)  
Transverse sections: forearm [440](#)  
Carpal tunnel [442](#)  
Muscle attachments of the hand [444](#)  
Superficial palmar region (palm) of hand [445](#)  
Tendon sheaths of hand [446](#)  
Lumbrical muscles [447](#)  
Intrinsic muscles of hand [448](#)  
Palmar region (palm) of hand: arteries and nerves [450](#)  
Arteries of the hand [452](#)  
Innervation of the hand: median and ulnar nerves [453](#)  
Dorsum of hand [454](#)  
Dorsal hoods [455](#)  
Dorsum of hand: arteries [456](#)  
Dorsum of hand: nerves [457](#)  
Anatomical snuffbox [458](#)  
Superficial veins and lymphatics of forearm [459](#)  
Anterior cutaneous nerves of forearm [460](#)  
Posterior cutaneous nerves of upper limb [461](#)  
Tables [462](#)



# Surface anatomy

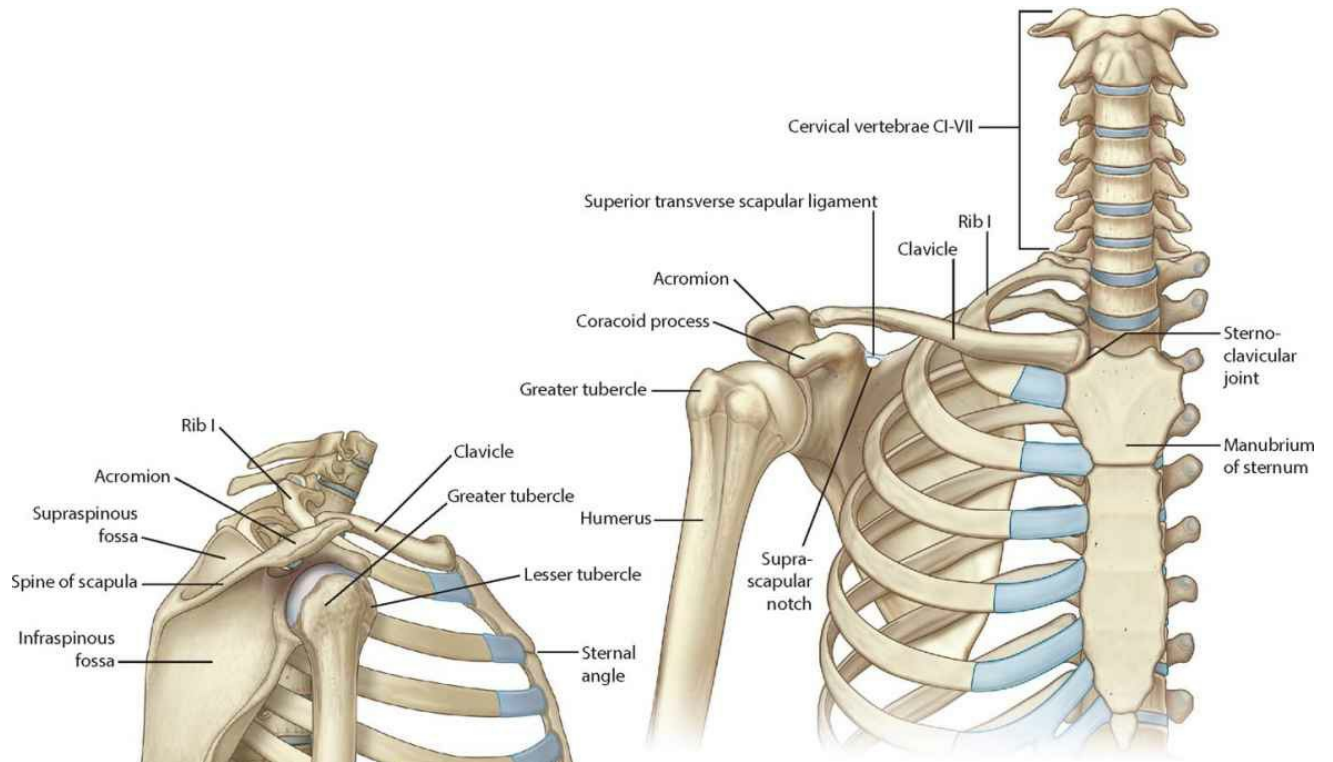


# Bones of the upper limb

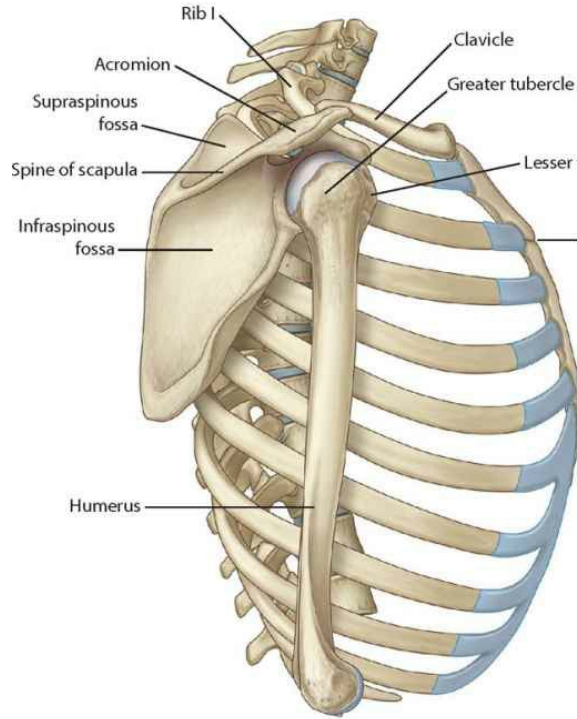


# Bony framework of shoulder

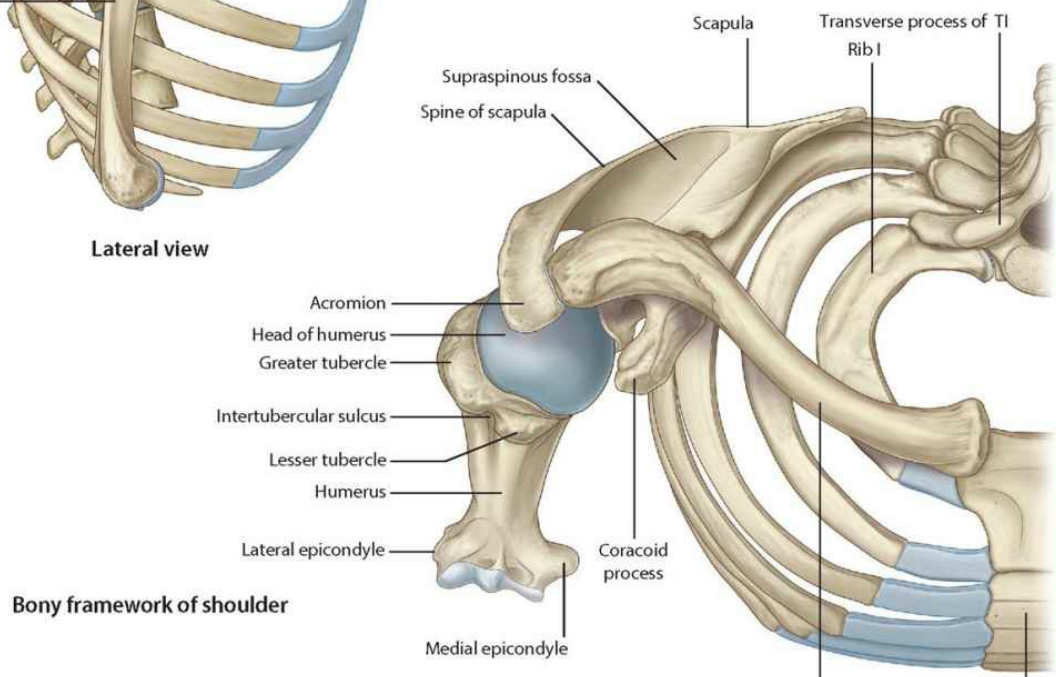




**Anterior view**



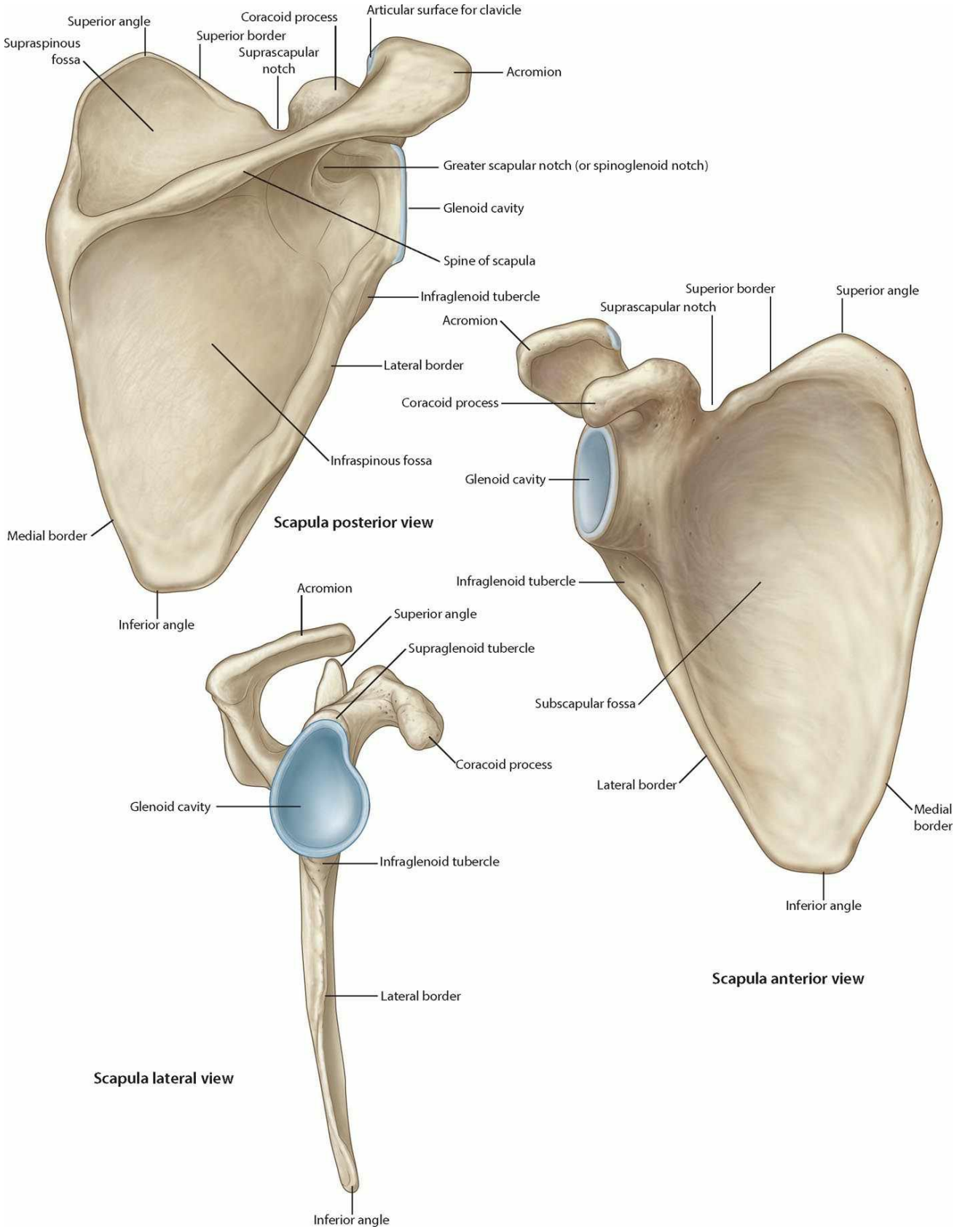
**Lateral view**



**Bony framework of shoulder**

**Superior view**

# Scapula



Superior angle  
Supraspinous fossa

Superior border  
Suprascapular notch  
Coracoid process

Articular surface for clavicle

Acromion

Greater scapular notch (or spinoglenoid notch)

Glenoid cavity

Spine of scapula

Infraglenoid tubercle

Acromion

Lateral border

Coracoid process

Infrapinuous fossa

Medial border

**Scapula posterior view**

Inferior angle

Superior border  
Suprascapular notch

Superior angle

Glenoid cavity

Infraglenoid tubercle

Superior angle

Supraglenoid tubercle

Subscapular fossa

Coracoid process

Glenoid cavity

Infraglenoid tubercle

Lateral border

Medial border

Inferior angle

**Scapula anterior view**

**Scapula lateral view**

Acromion

Superior angle

Supraglenoid tubercle

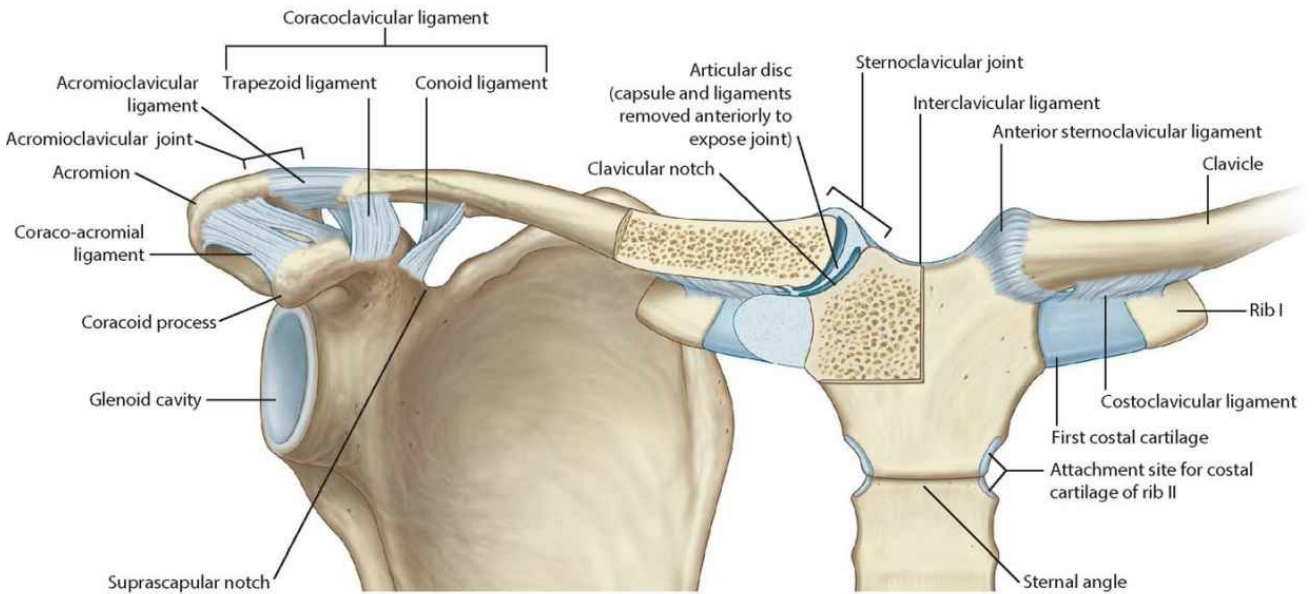
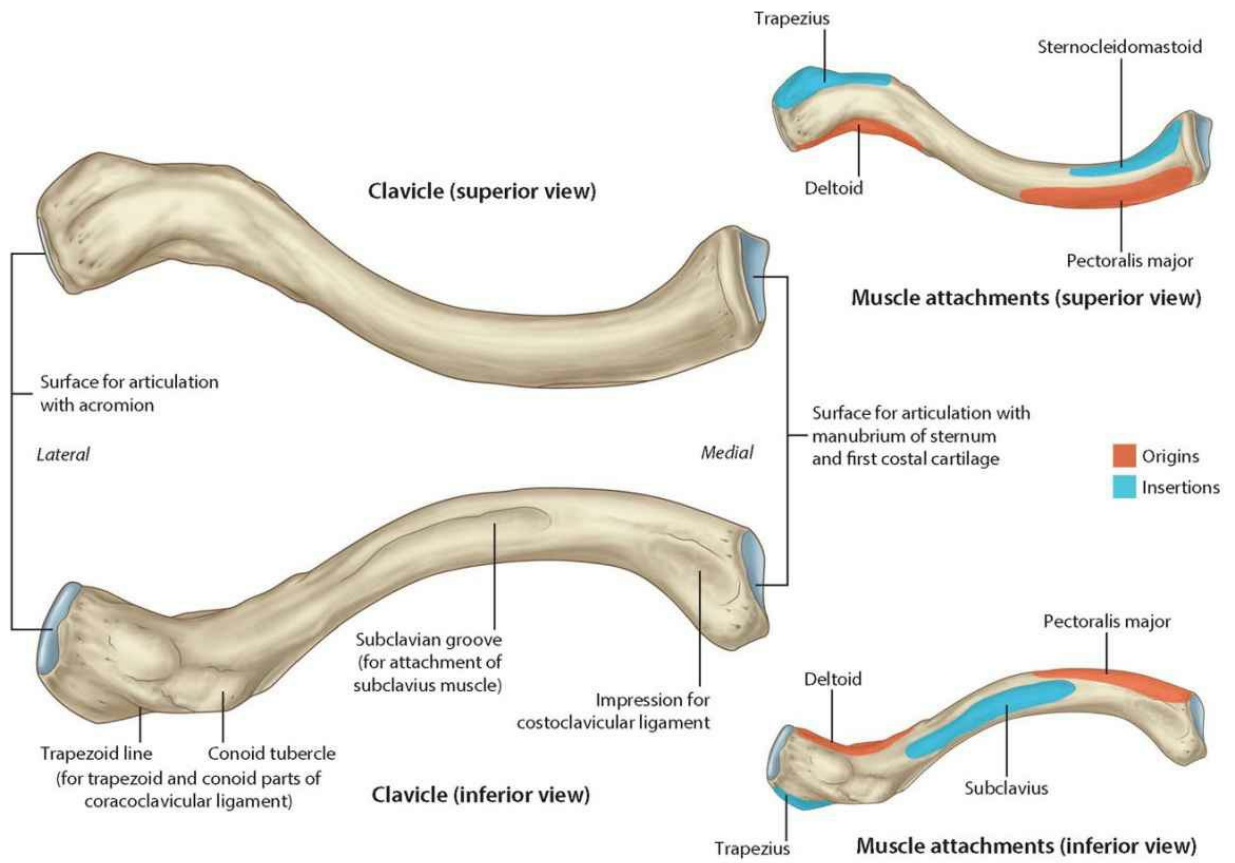
Coracoid process

Infraglenoid tubercle

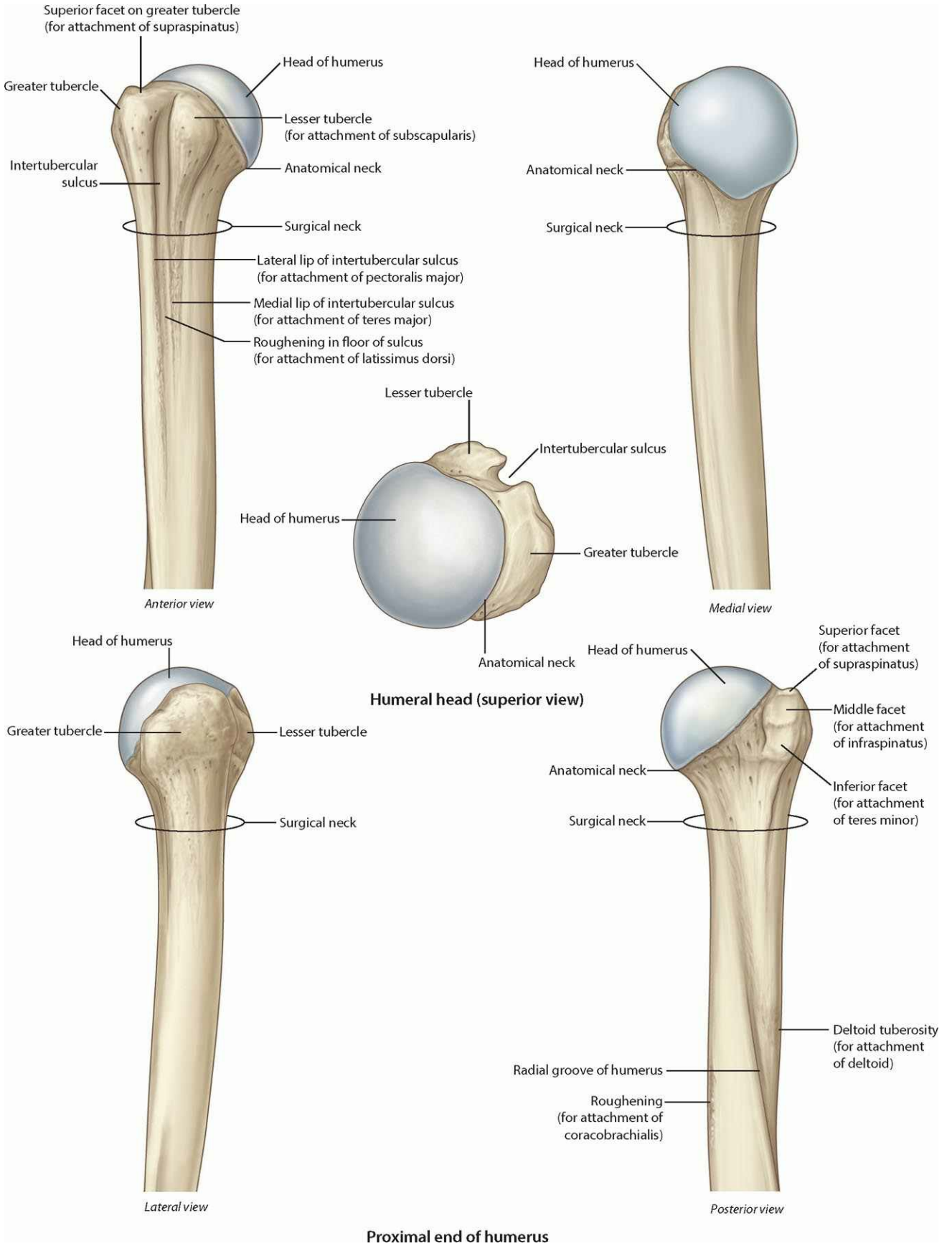
Lateral border

Inferior angle

# Clavicle: joints and ligaments

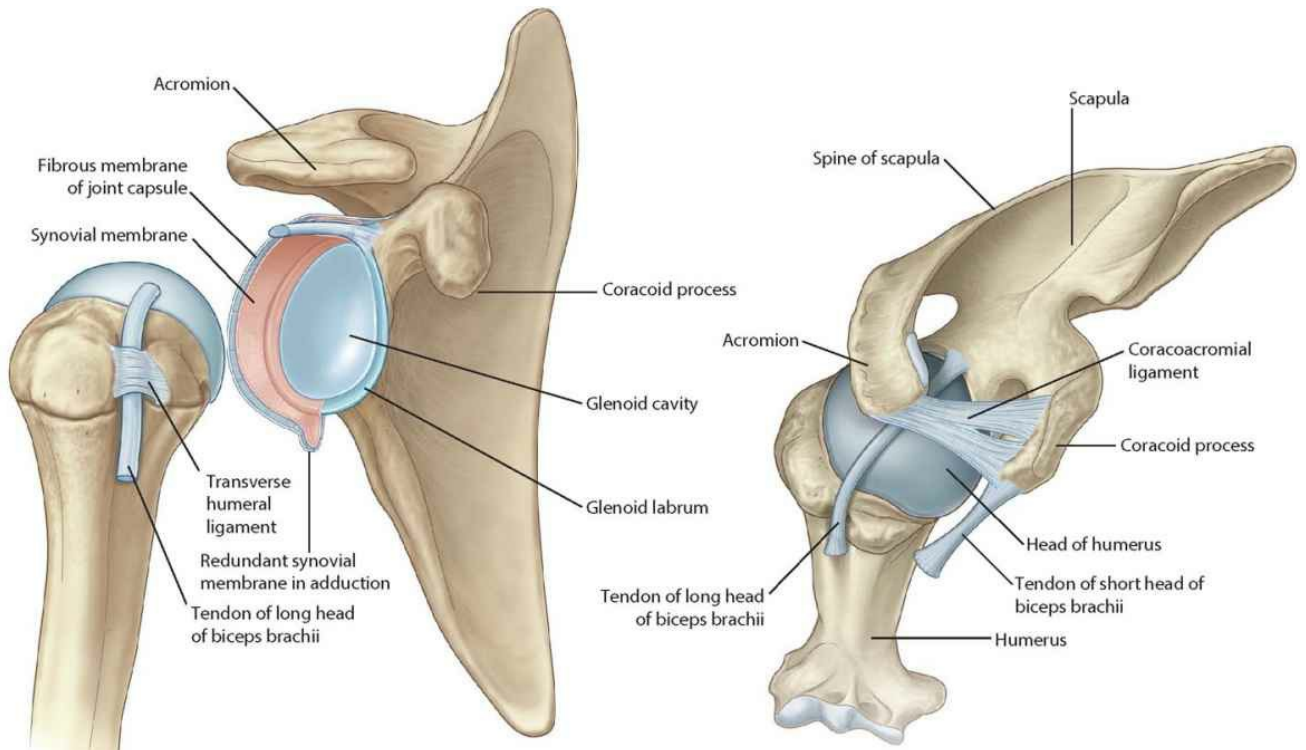


# Proximal humerus



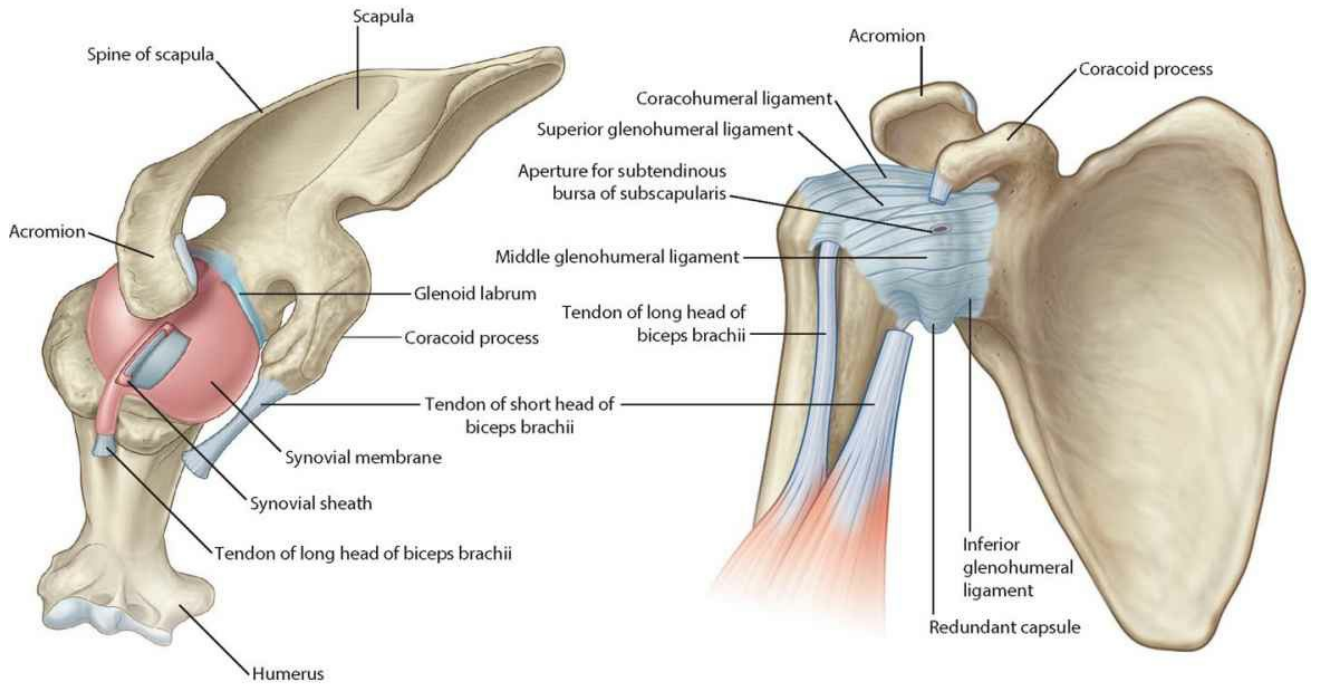
# Glenohumeral joint





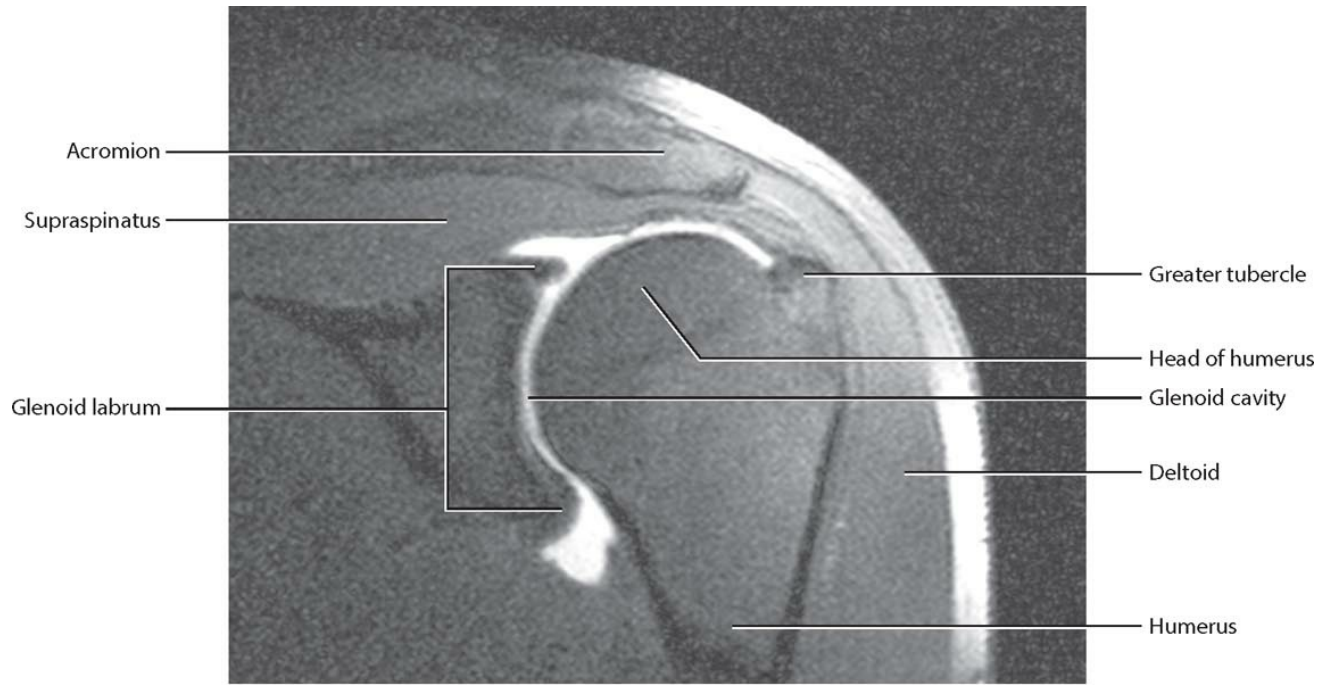
Origins of biceps brachii tendons (superior view)

Articular surfaces of glenohumeral joint (anterolateral oblique view)

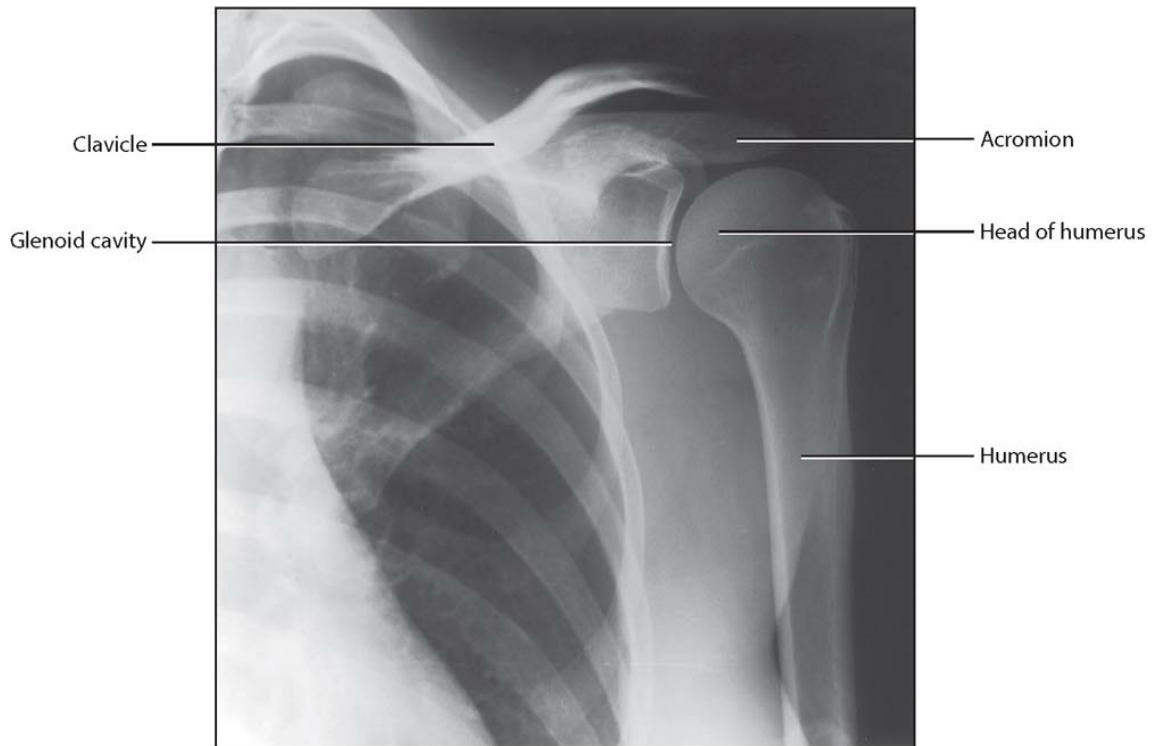


Synovial membrane (superior view)

Fibrous membrane of joint capsule (anterior view)

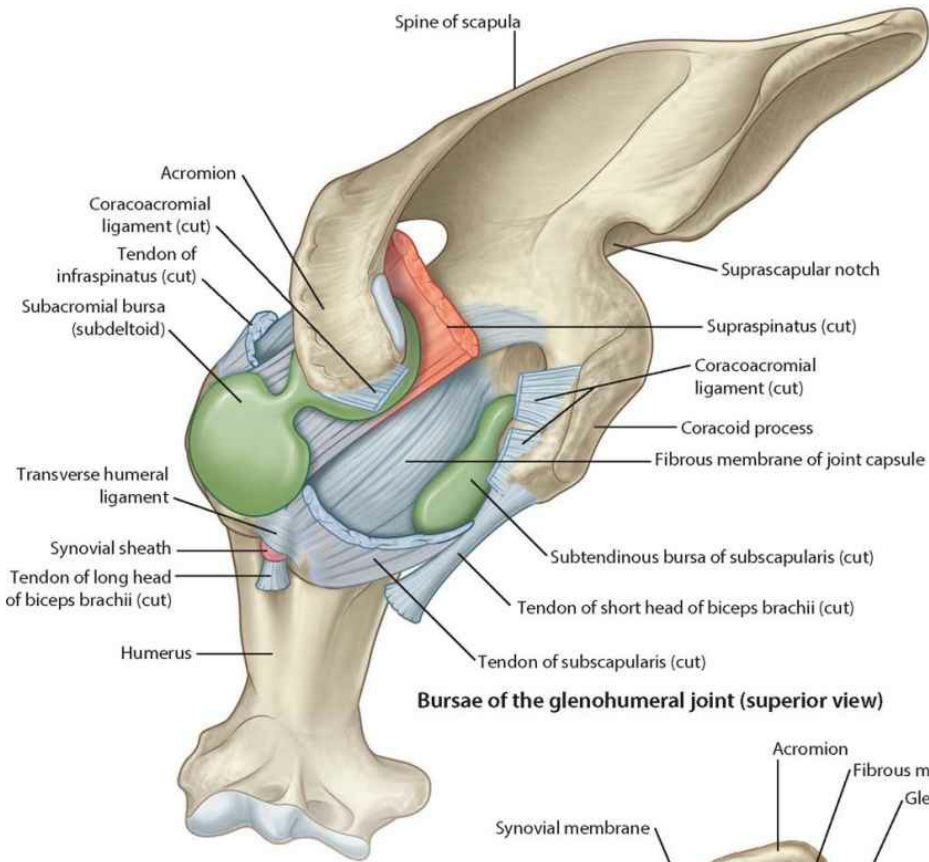


**Anterior view of the glenohumeral joint.**  
T1-weighted MR image in coronal plane

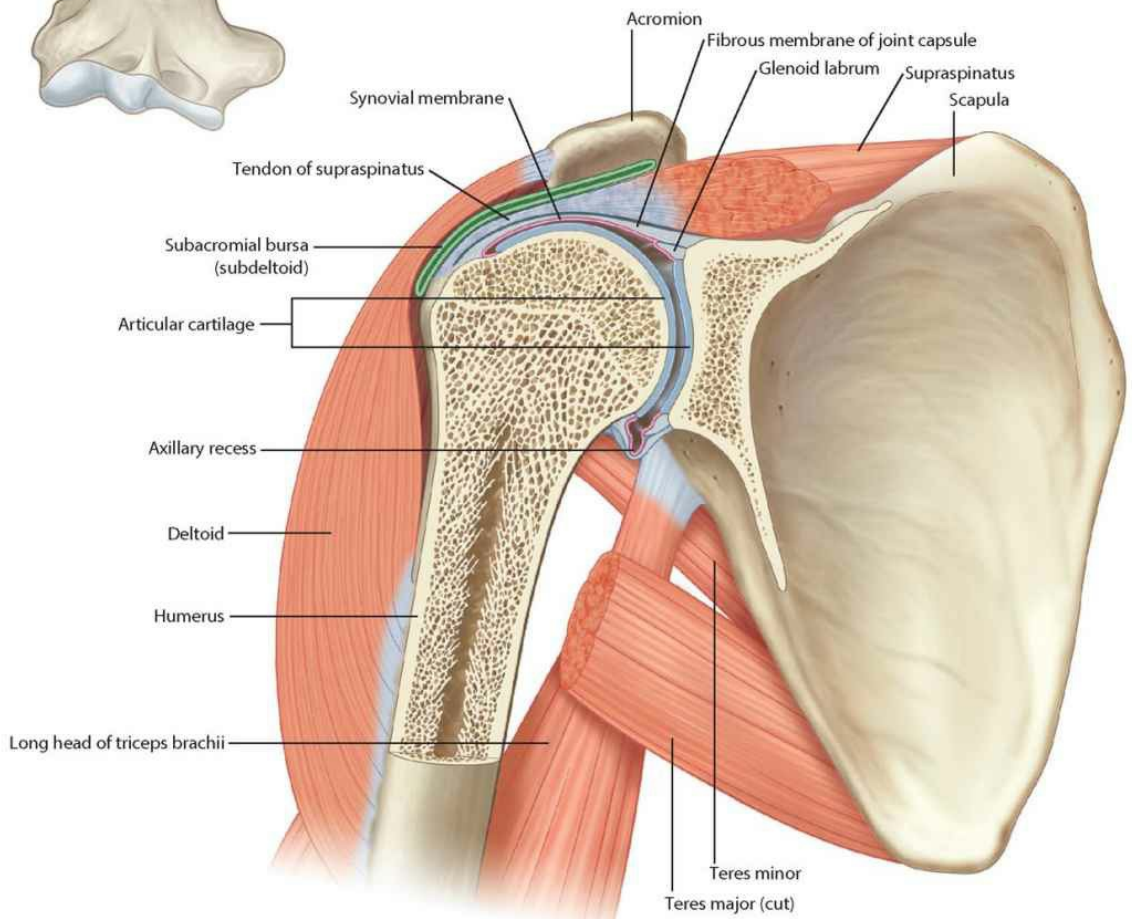


**Normal glenohumeral joint.**  
Radiograph, AP view

# Muscle attachments

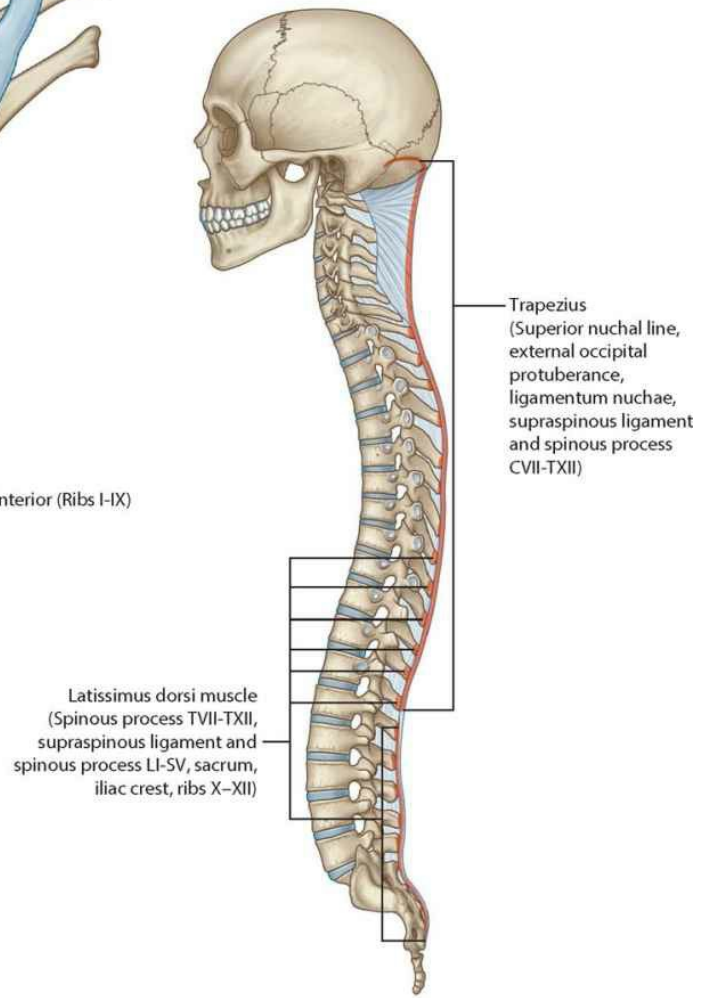
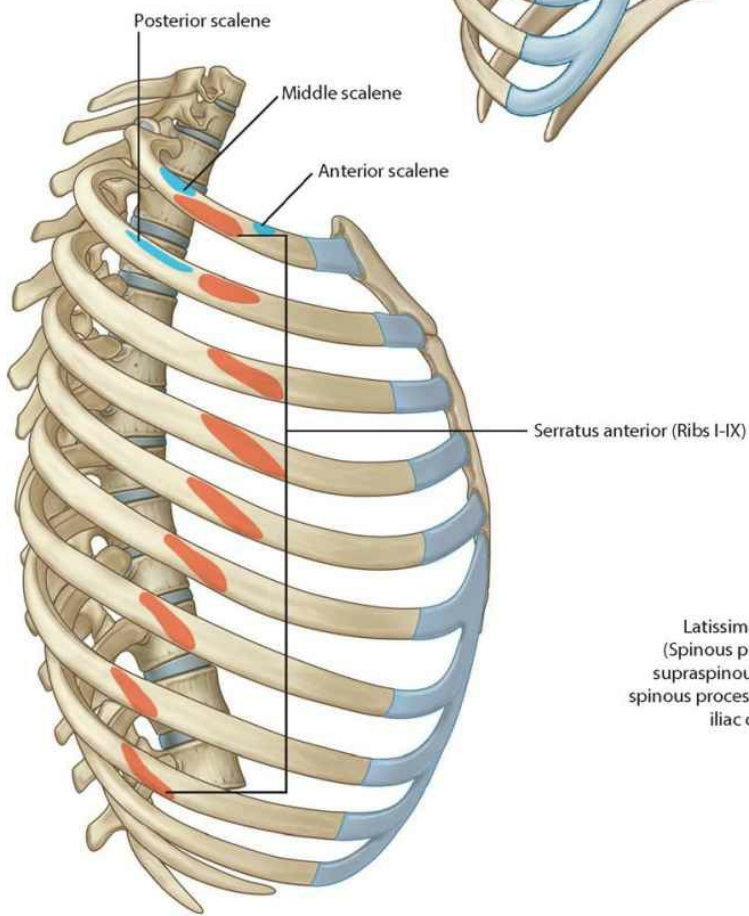
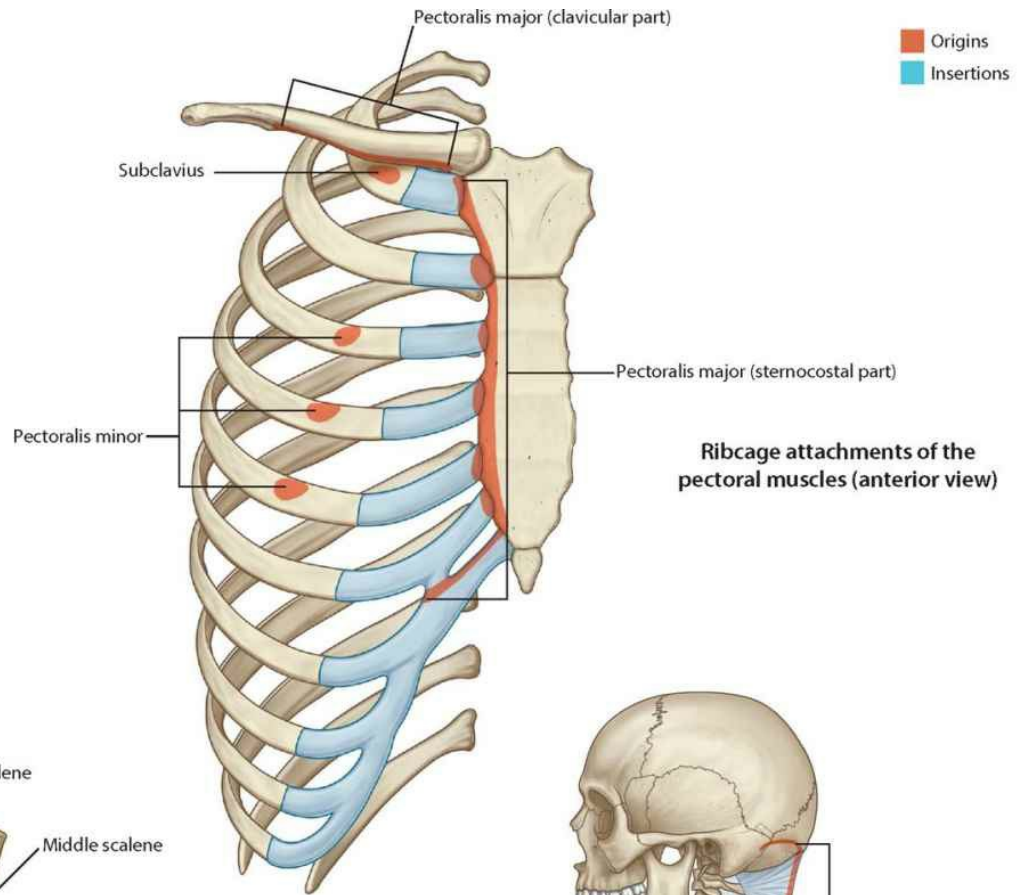


**Bursae of the glenohumeral joint (superior view)**

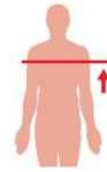
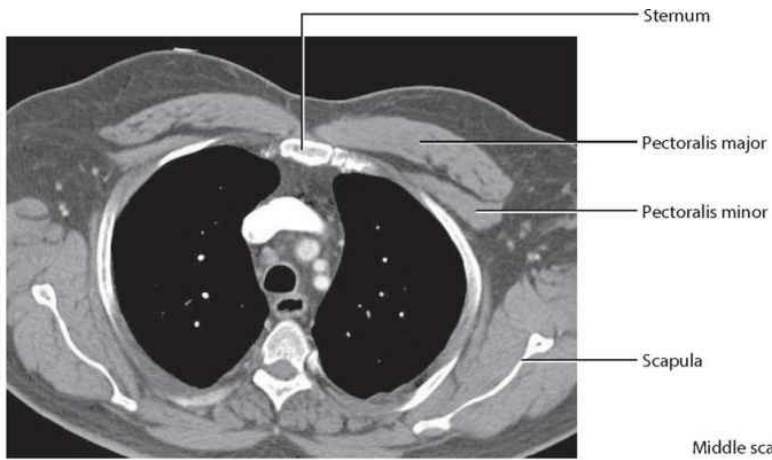


**Glenohumeral joint (anterior view)**

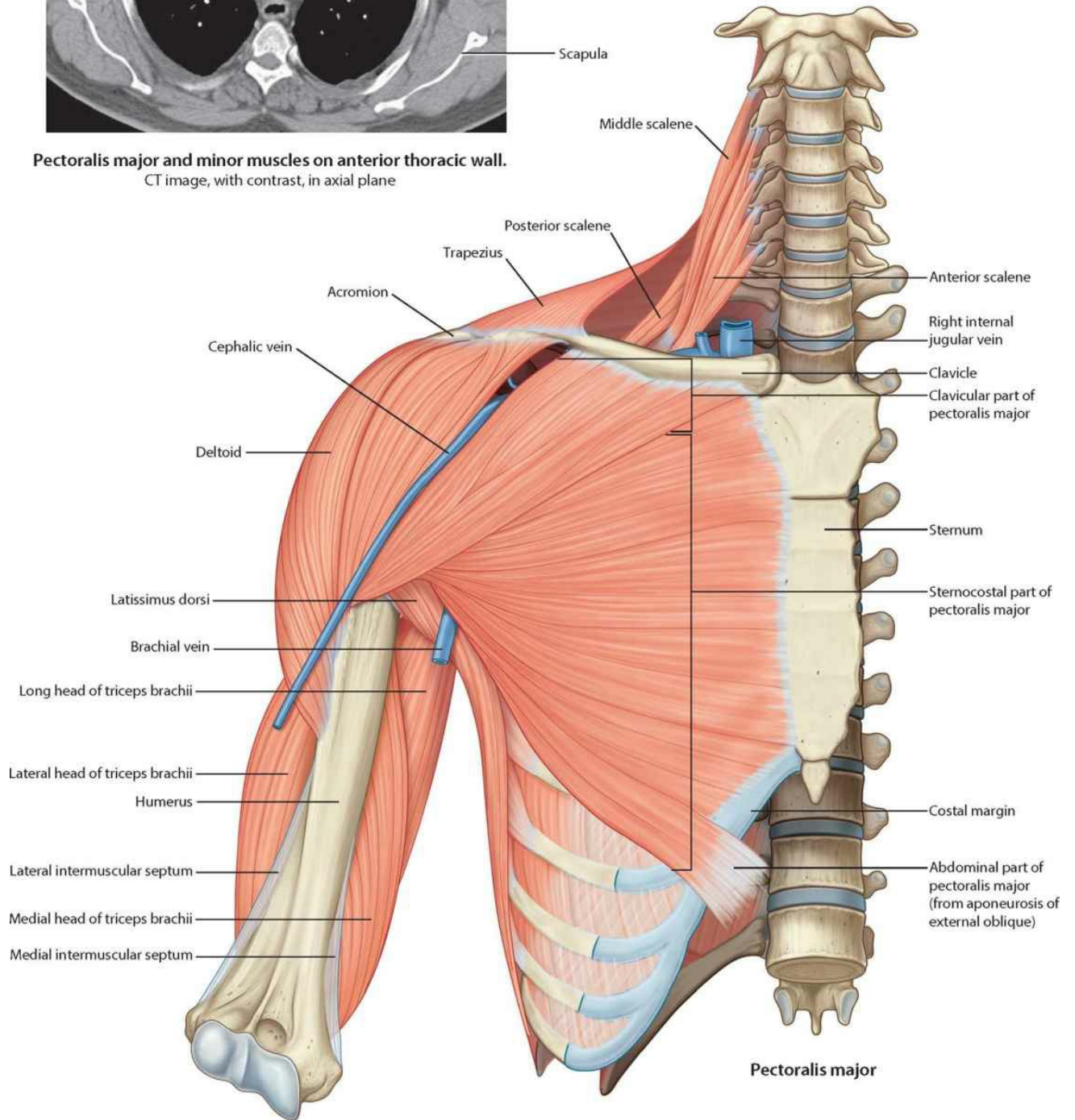




# Pectoral region

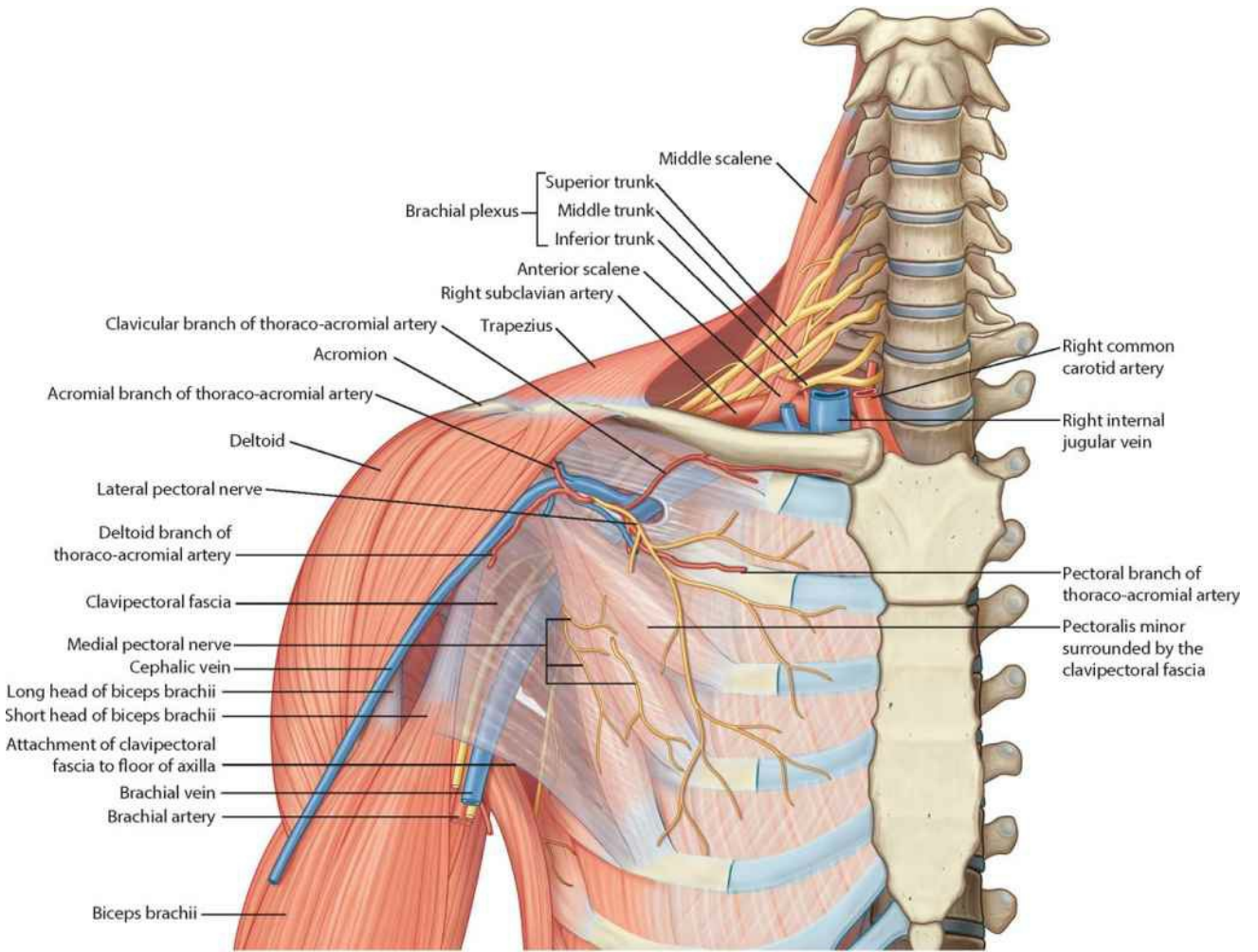


**Pectoralis major and minor muscles on anterior thoracic wall.**  
CT image, with contrast, in axial plane

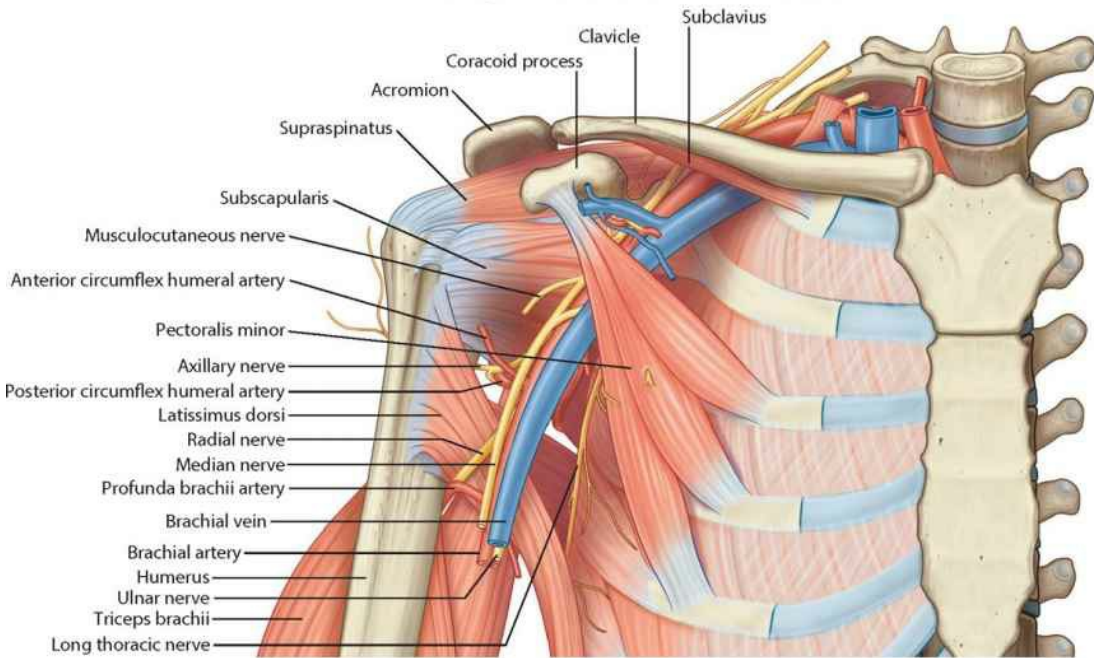




## Deep pectoral region

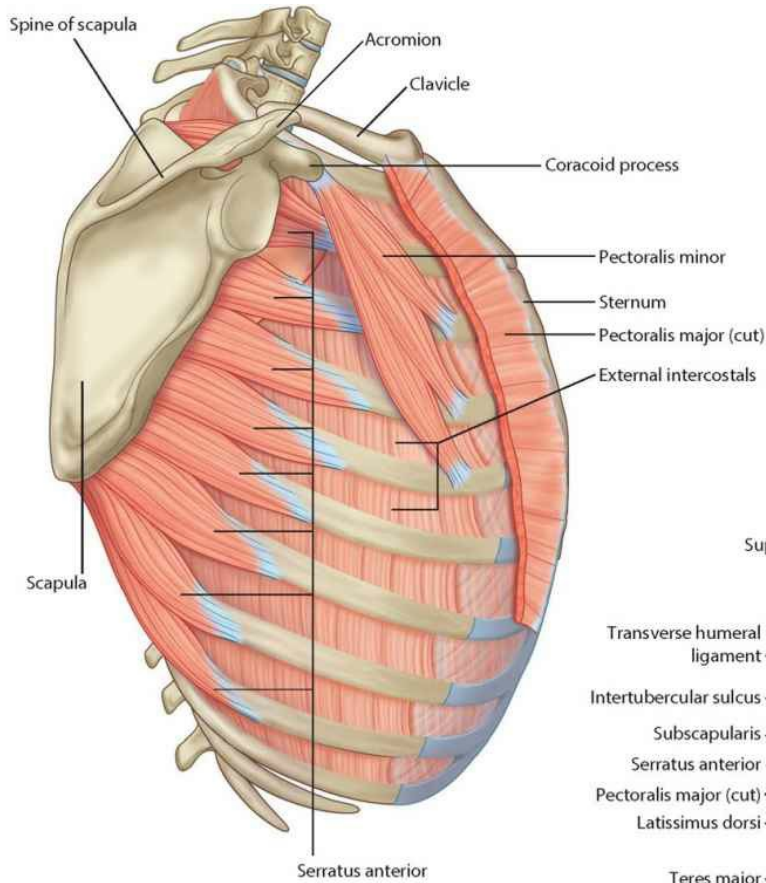


**Clavipectoral fascia and related structures**

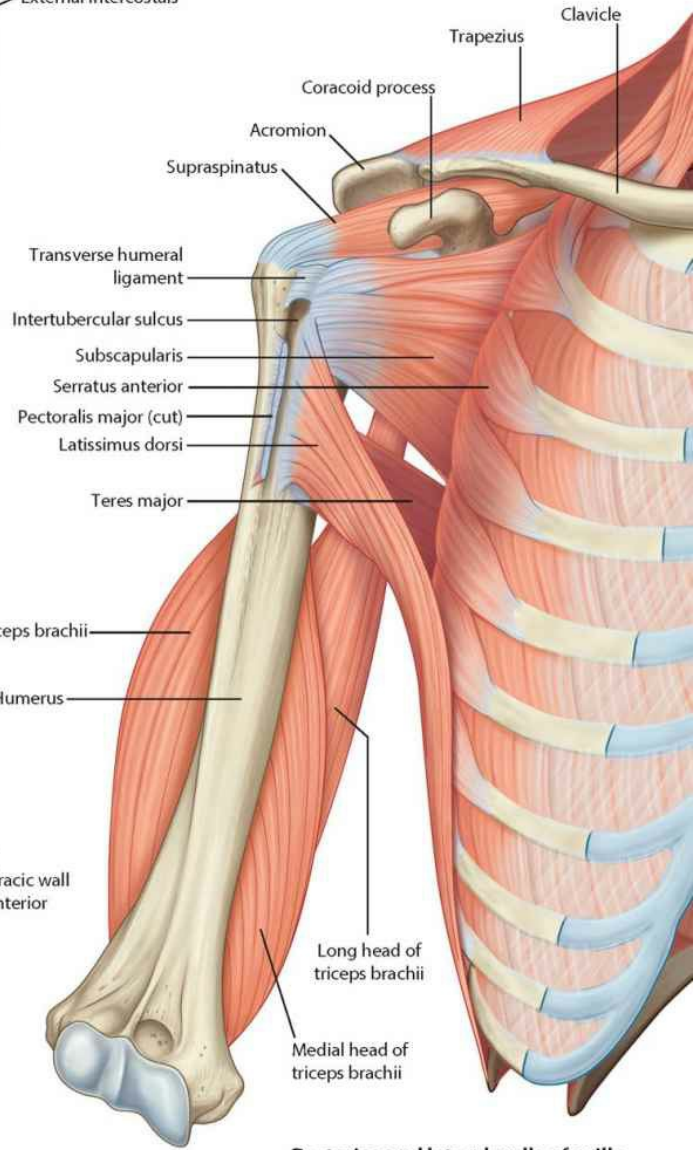
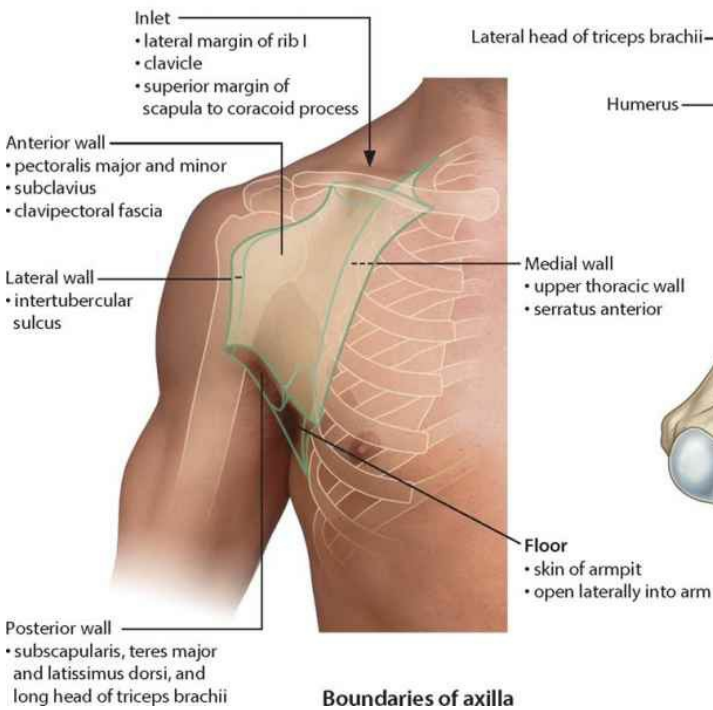


**Pectoralis minor**

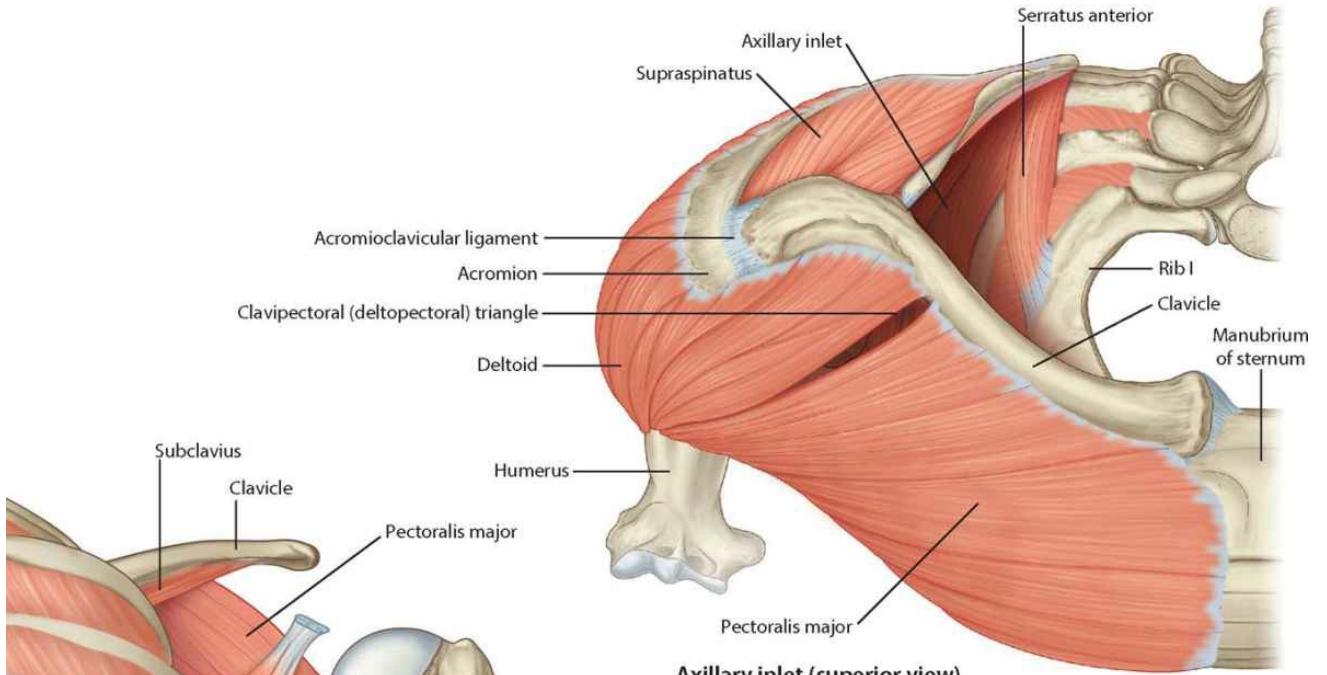
## Walls of the axilla



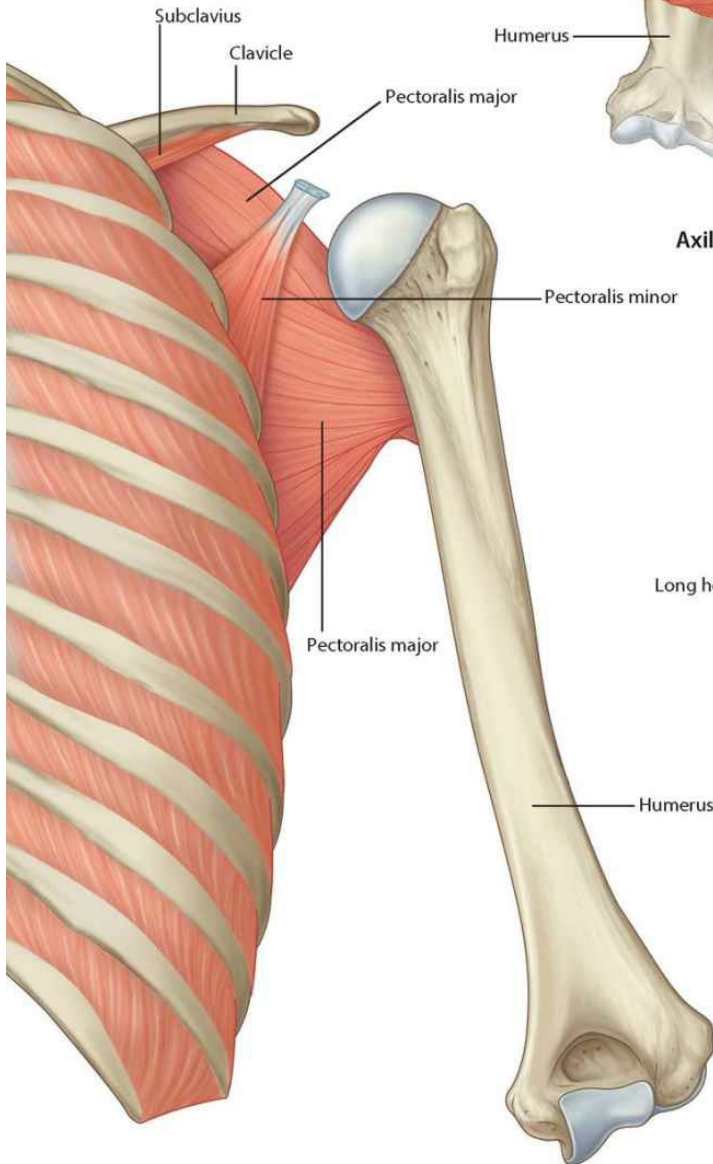
**Medial and anterior walls of axilla**



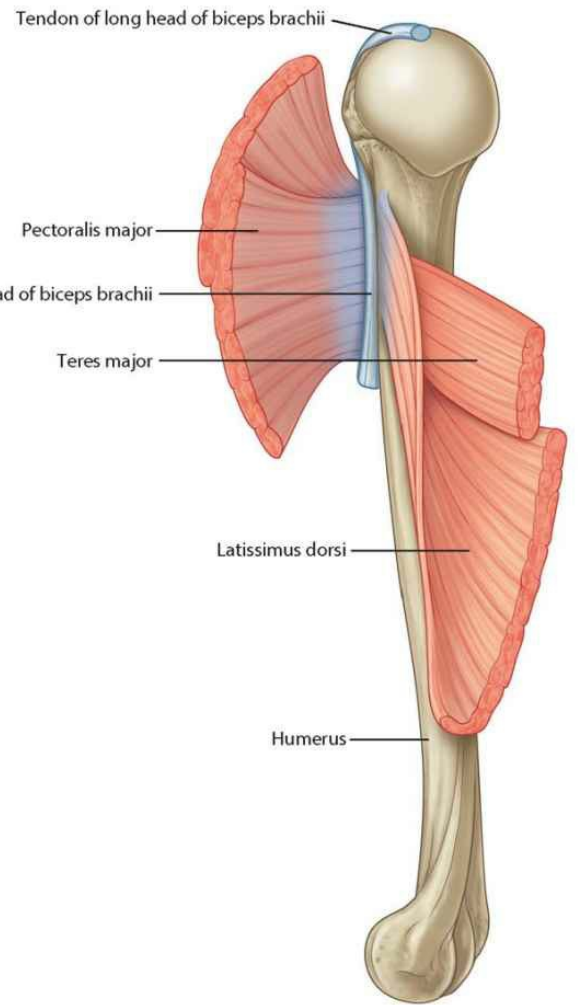
**Posterior and lateral walls of axilla**



**Axillary inlet (superior view)**



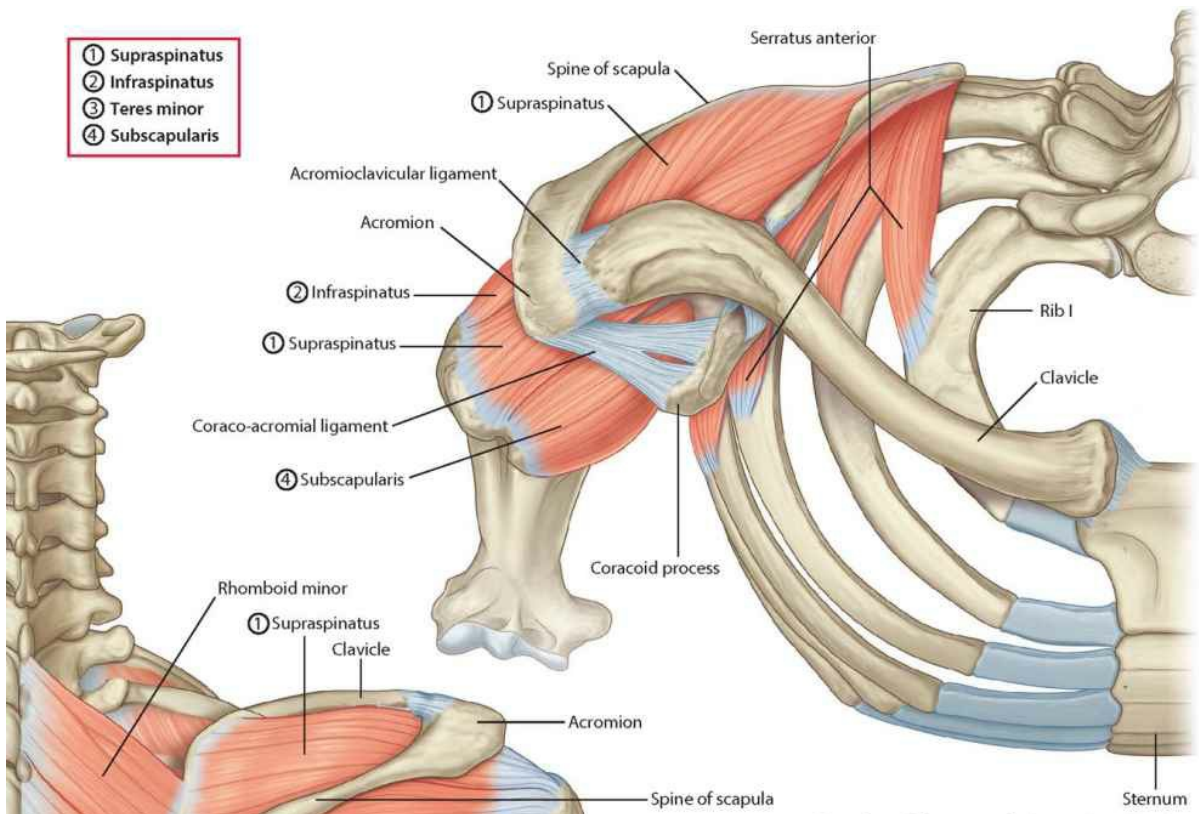
**Anterior wall of axilla (posterior view)**



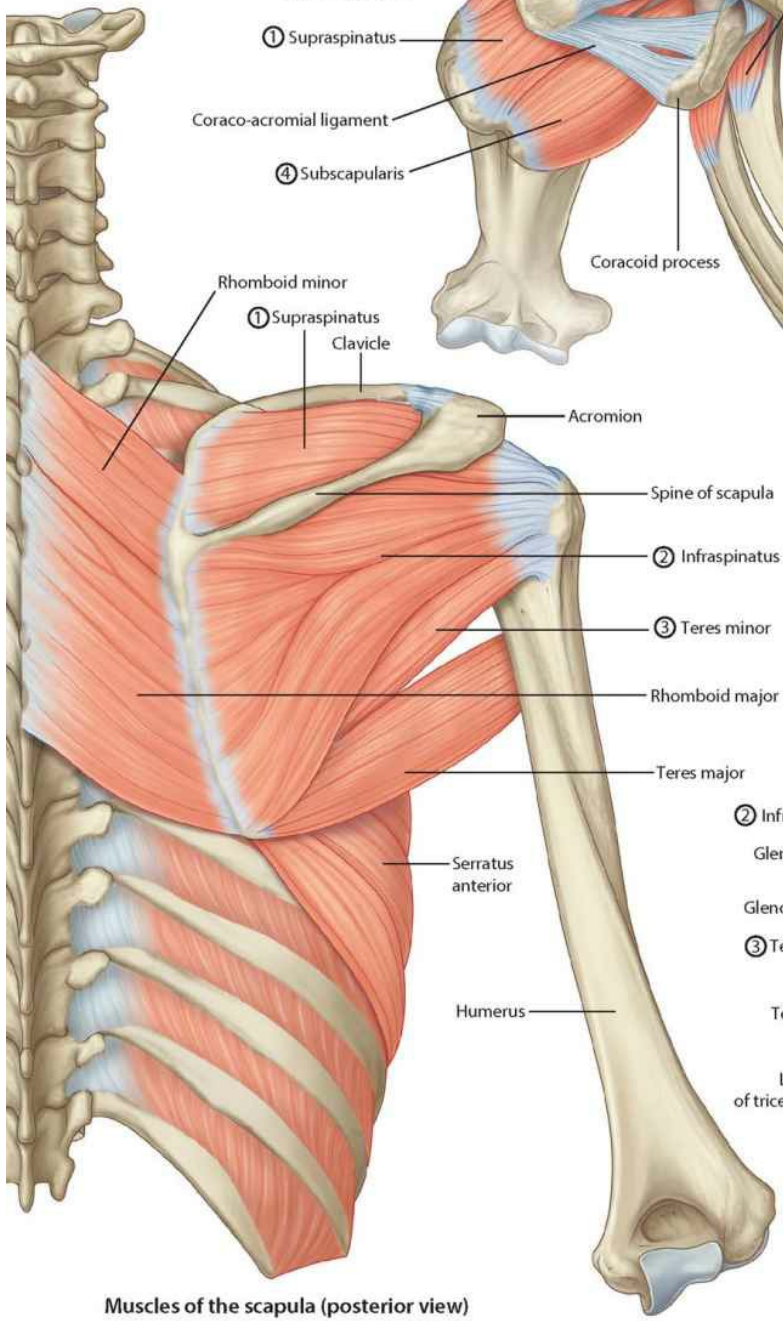
**Lateral wall of axilla (medial view)**

# The four rotator cuff muscles

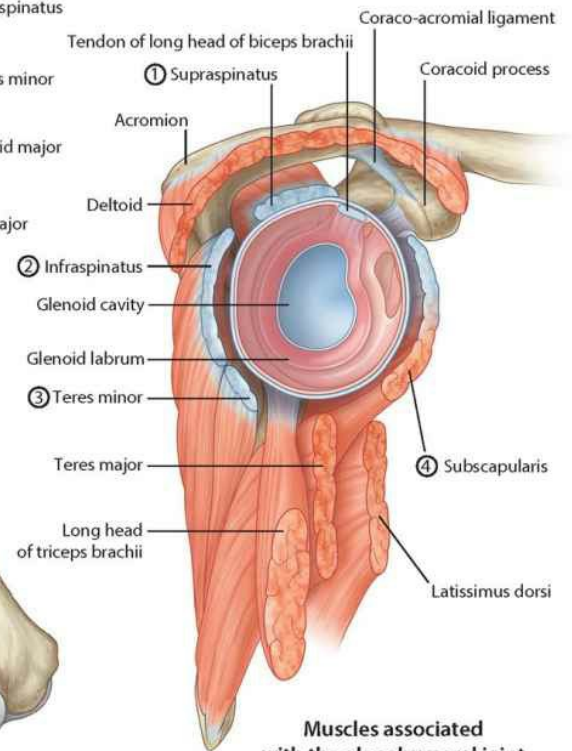
- ① Supraspinatus
- ② Infraspinatus
- ③ Teres minor
- ④ Subscapularis



**Muscles of the scapula (superior view)**



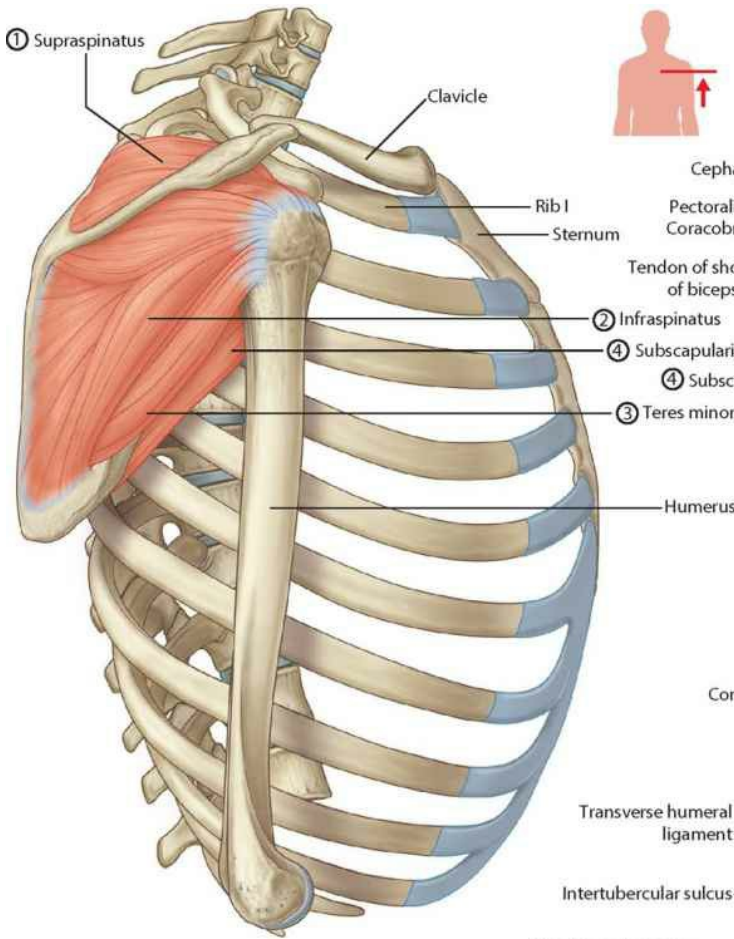
**Muscles of the scapula (posterior view)**



**Muscles associated with the glenohumeral joint (lateral view)**







① Supraspinatus

Clavicle

Rib I

Sternum

② Infraspinatus

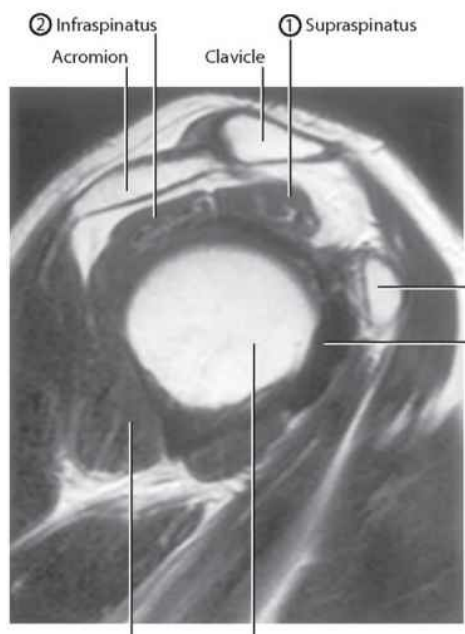
④ Subscapularis

④ Subscapularis

③ Teres minor

Humerus

**Muscles of the scapula (lateral view)**



② Infraspinatus

Acromion

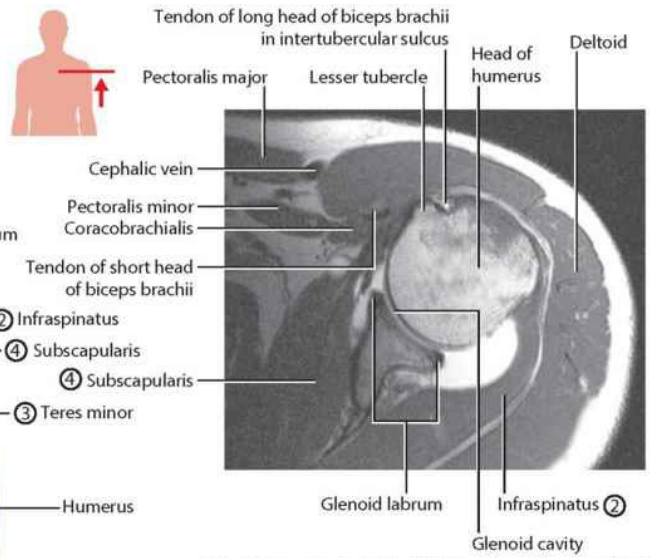
Clavicle

① Supraspinatus

③ Teres minor

Head of humerus

**Muscles associated with the glenohumeral joint.**  
T1-weighted MR image in sagittal plane



Tendon of long head of biceps brachii in intertubercular sulcus

Pectoralis major

Lesser tubercle

Head of humerus

Deltoid

Cephalic vein

Pectoralis minor

Coracobrachialis

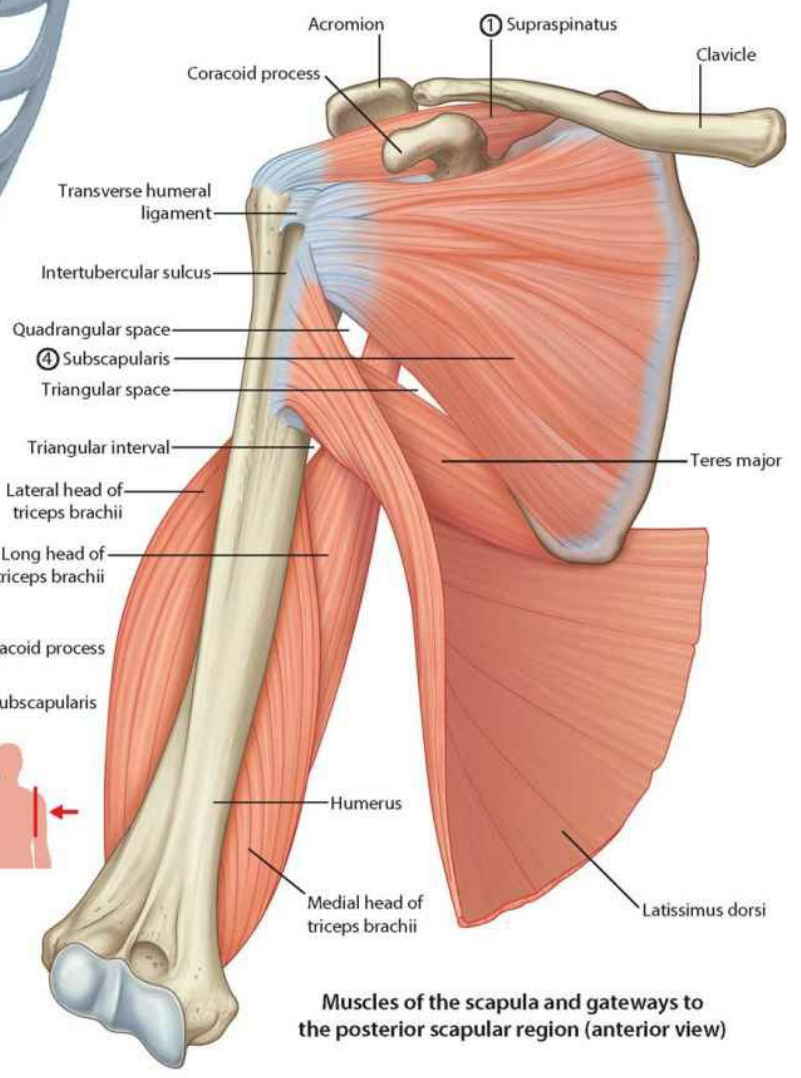
Tendon of short head of biceps brachii

Glenoid labrum

Infraspinatus ②

Glenoid cavity

**Muscles associated with the glenohumeral joint.**  
T1-weighted MR image in axial plane



Acromion

① Supraspinatus

Clavicle

Coracoid process

Transverse humeral ligament

Intertubercular sulcus

Quadrangular space

④ Subscapularis

Triangular space

Triangular interval

Lateral head of triceps brachii

Long head of triceps brachii

Coracoid process

④ Subscapularis

Humerus

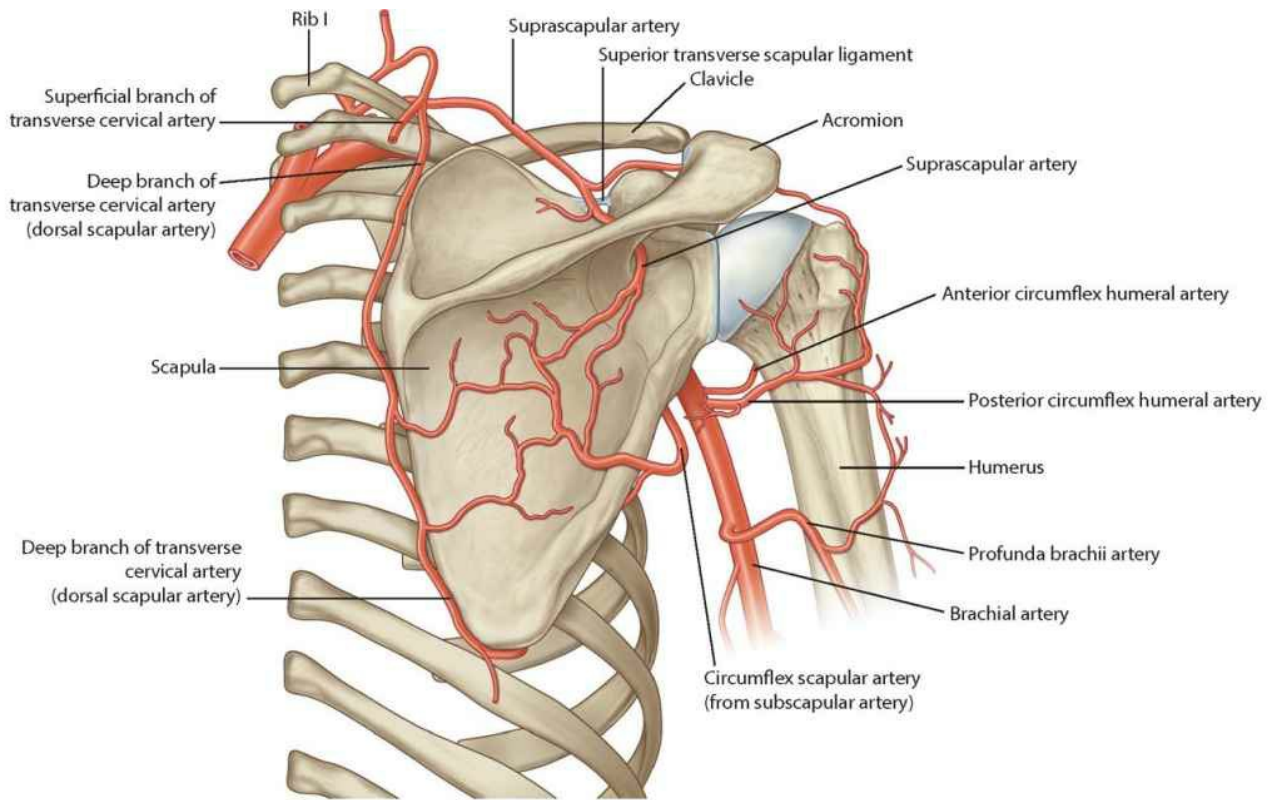
Medial head of triceps brachii

Latissimus dorsi

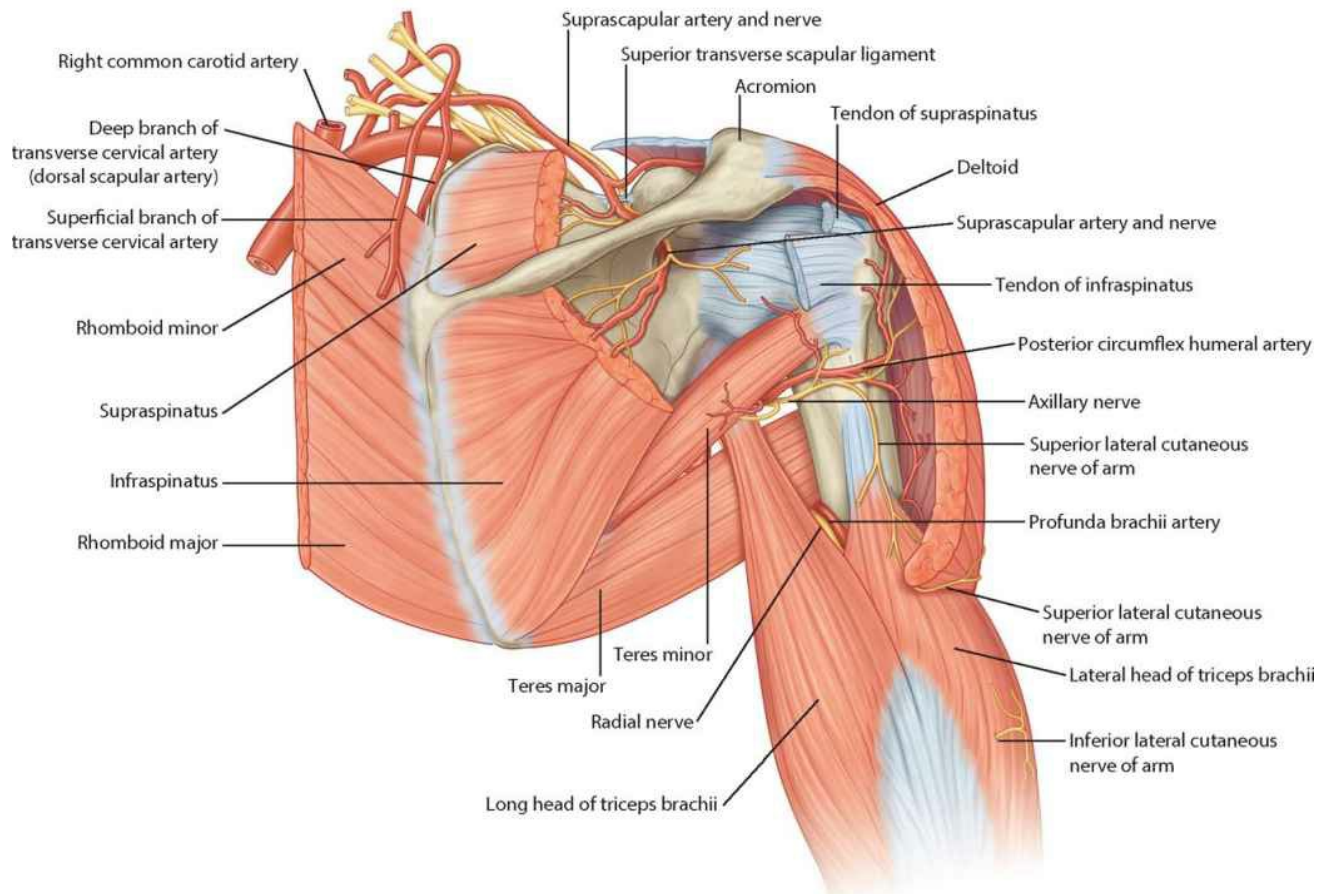
Teres major

**Muscles of the scapula and gateways to the posterior scapular region (anterior view)**

# Deep vessels and nerves of the shoulder

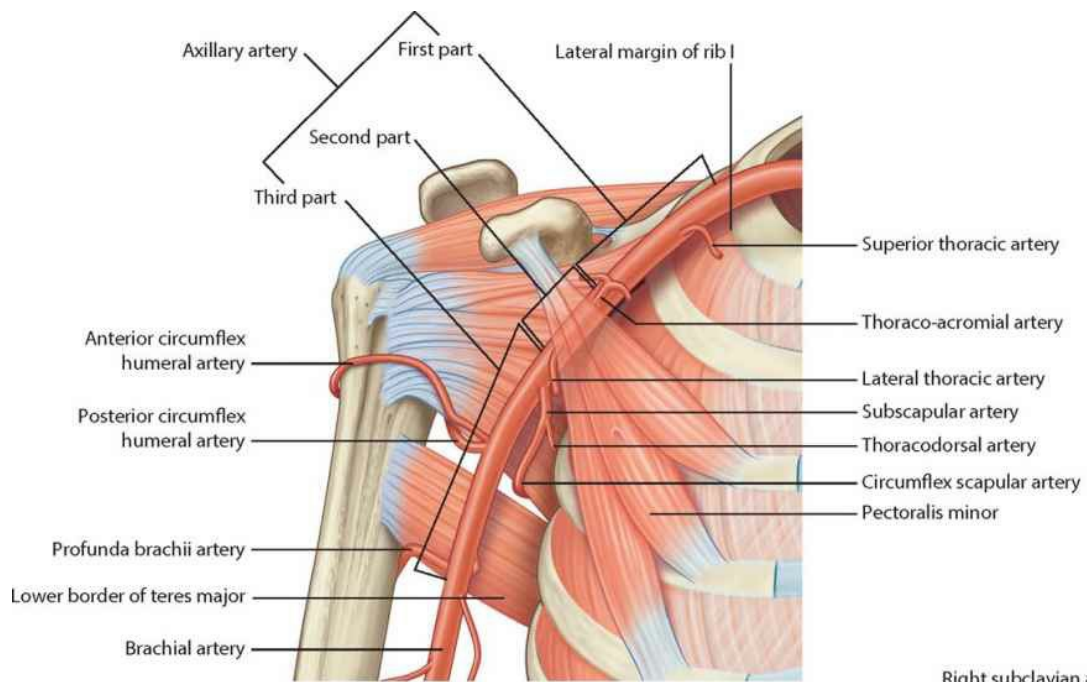


**Arteries of the shoulder (posterior view)**

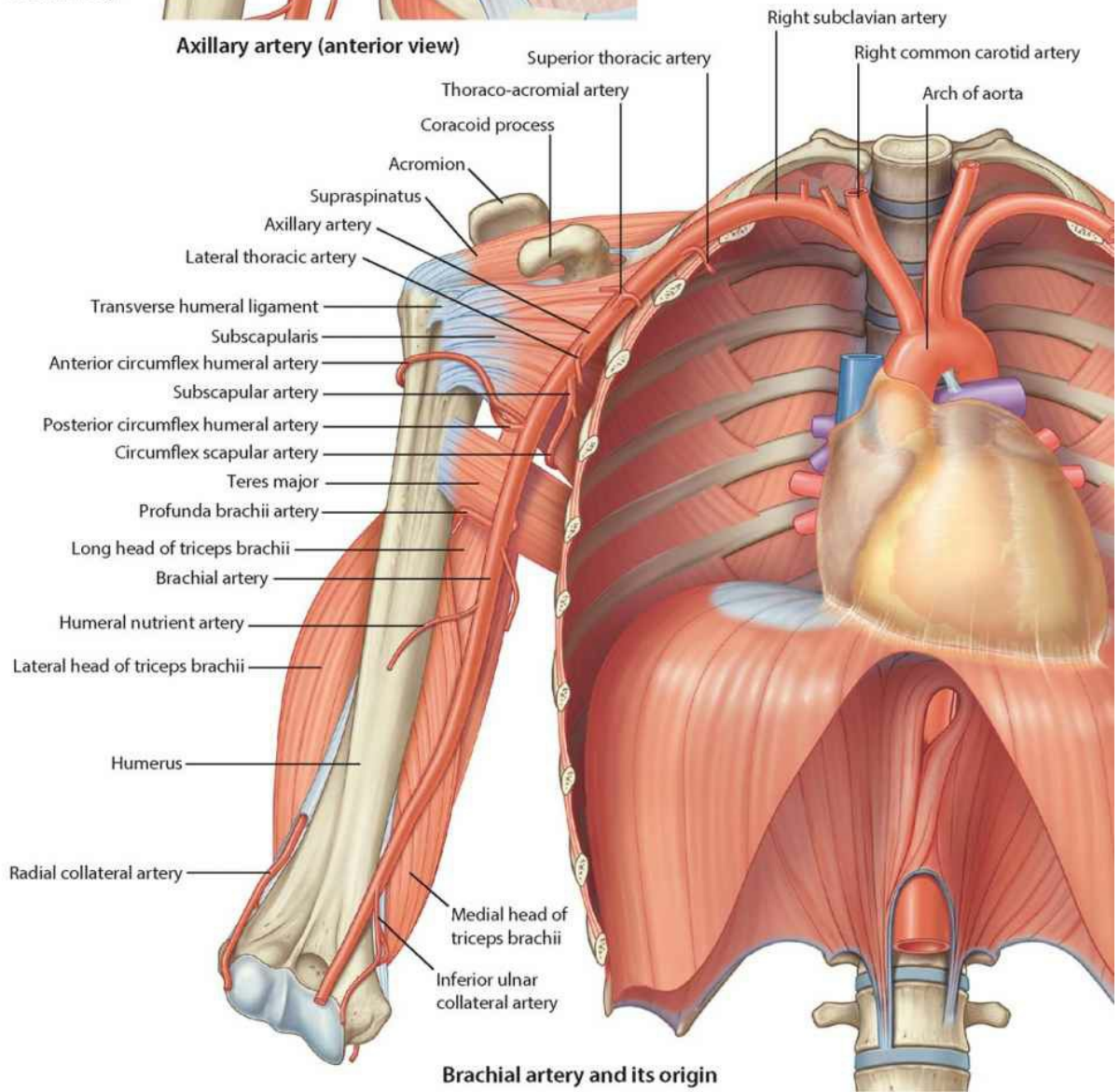


**Deep arteries and nerves of the shoulder (posterior view)**

# Axillary artery



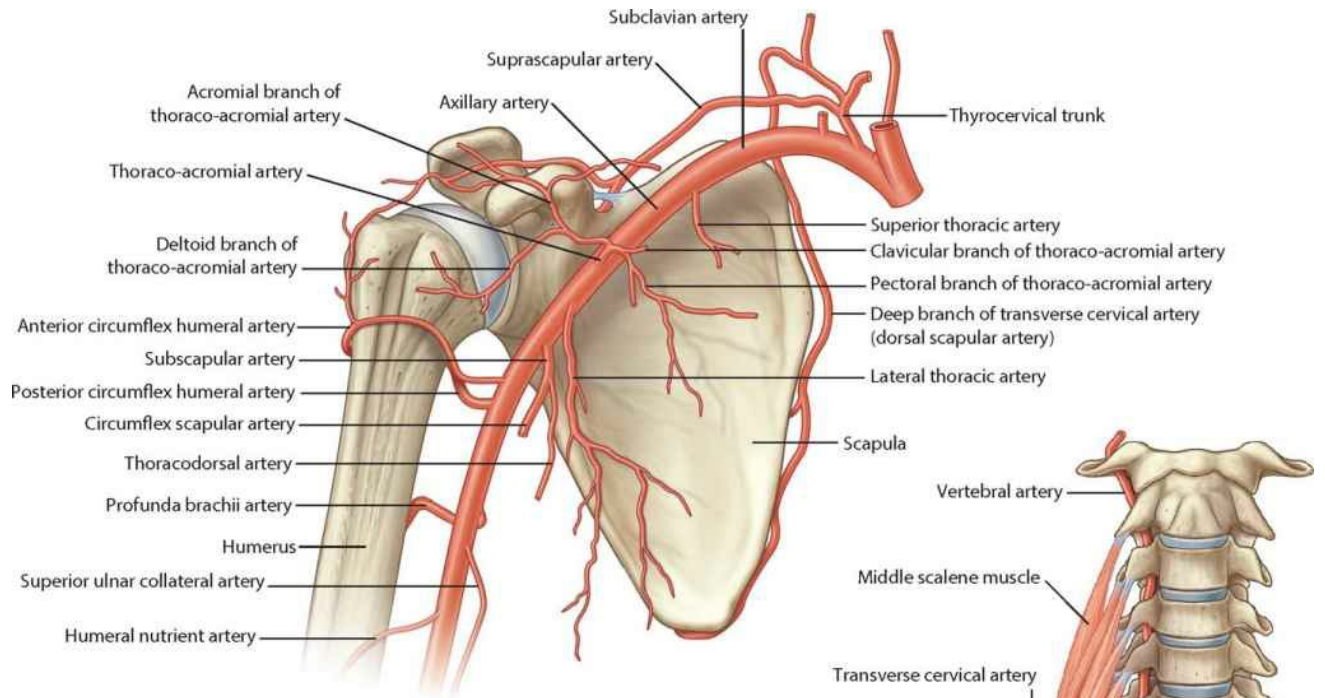
**Axillary artery (anterior view)**



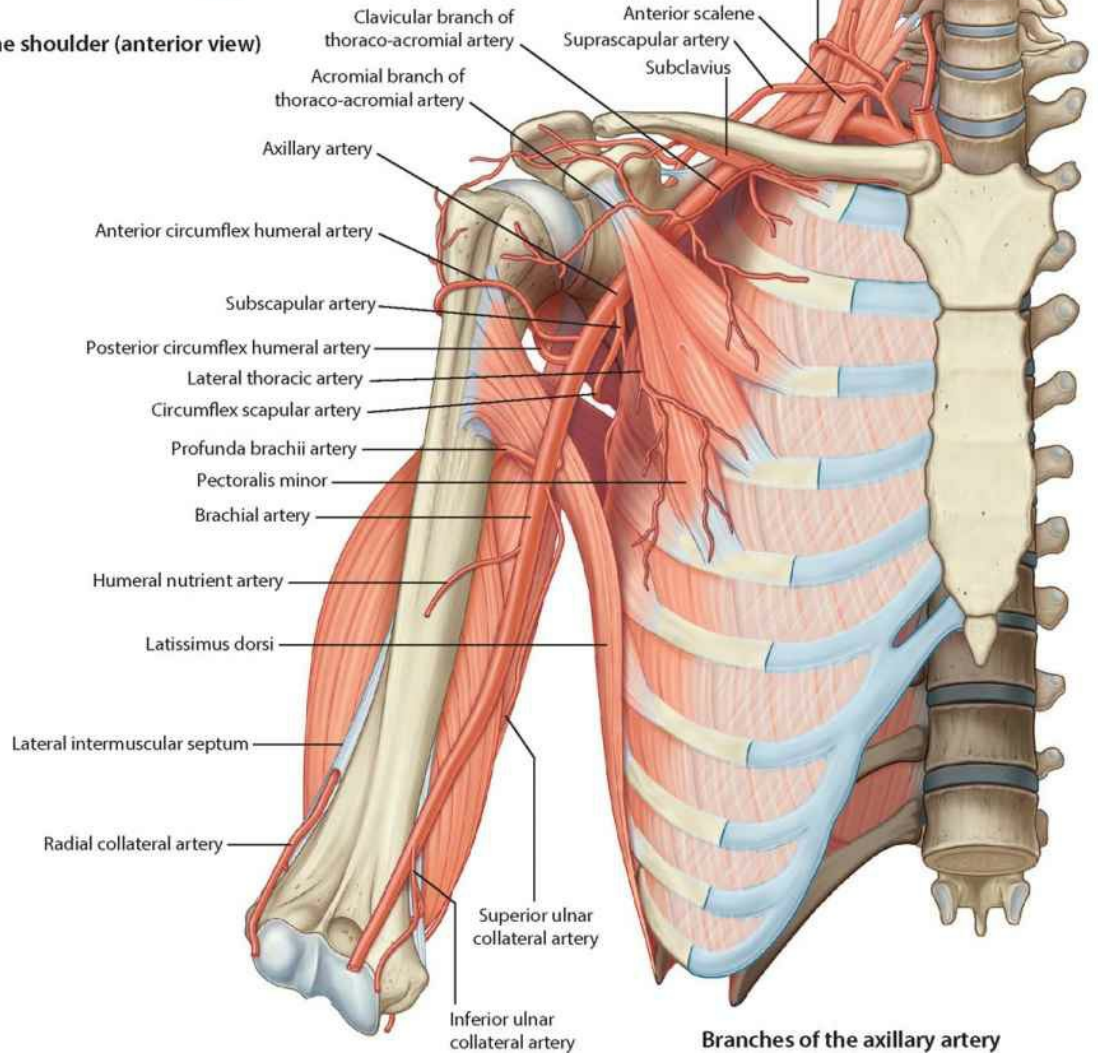
**Brachial artery and its origin**



# Brachial artery



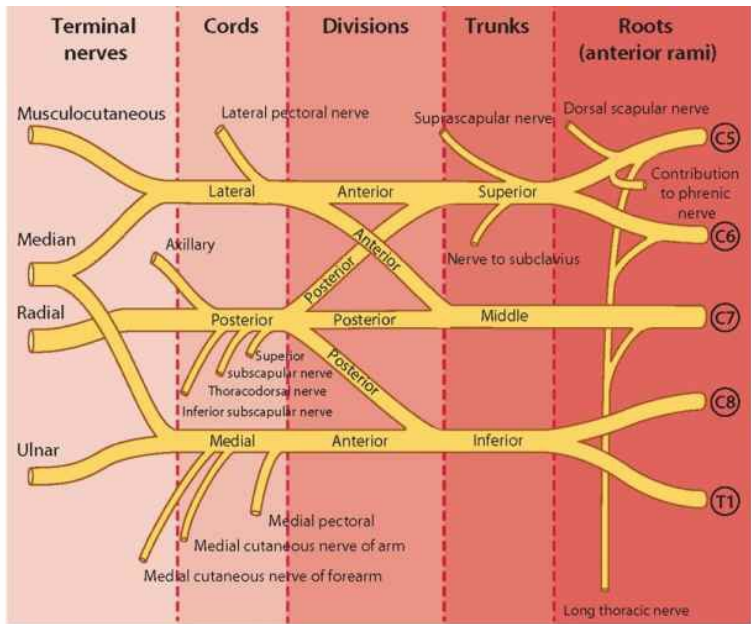
**Arteries of the shoulder (anterior view)**



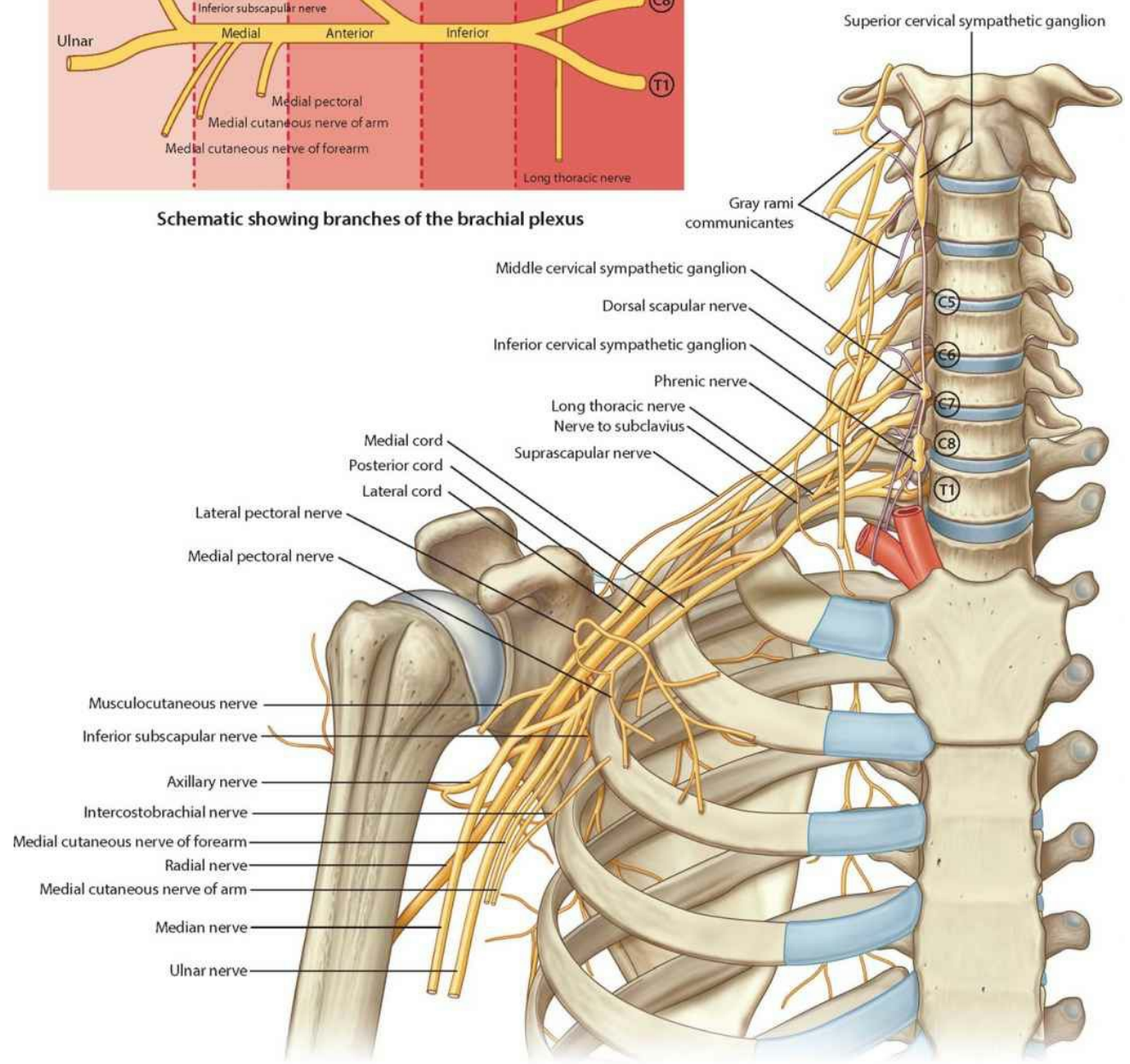
**Branches of the axillary artery**



# Brachial plexus

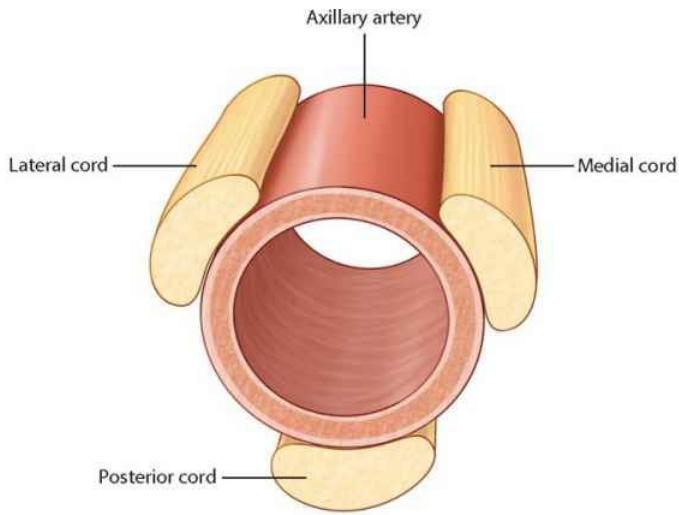


**Schematic showing branches of the brachial plexus**

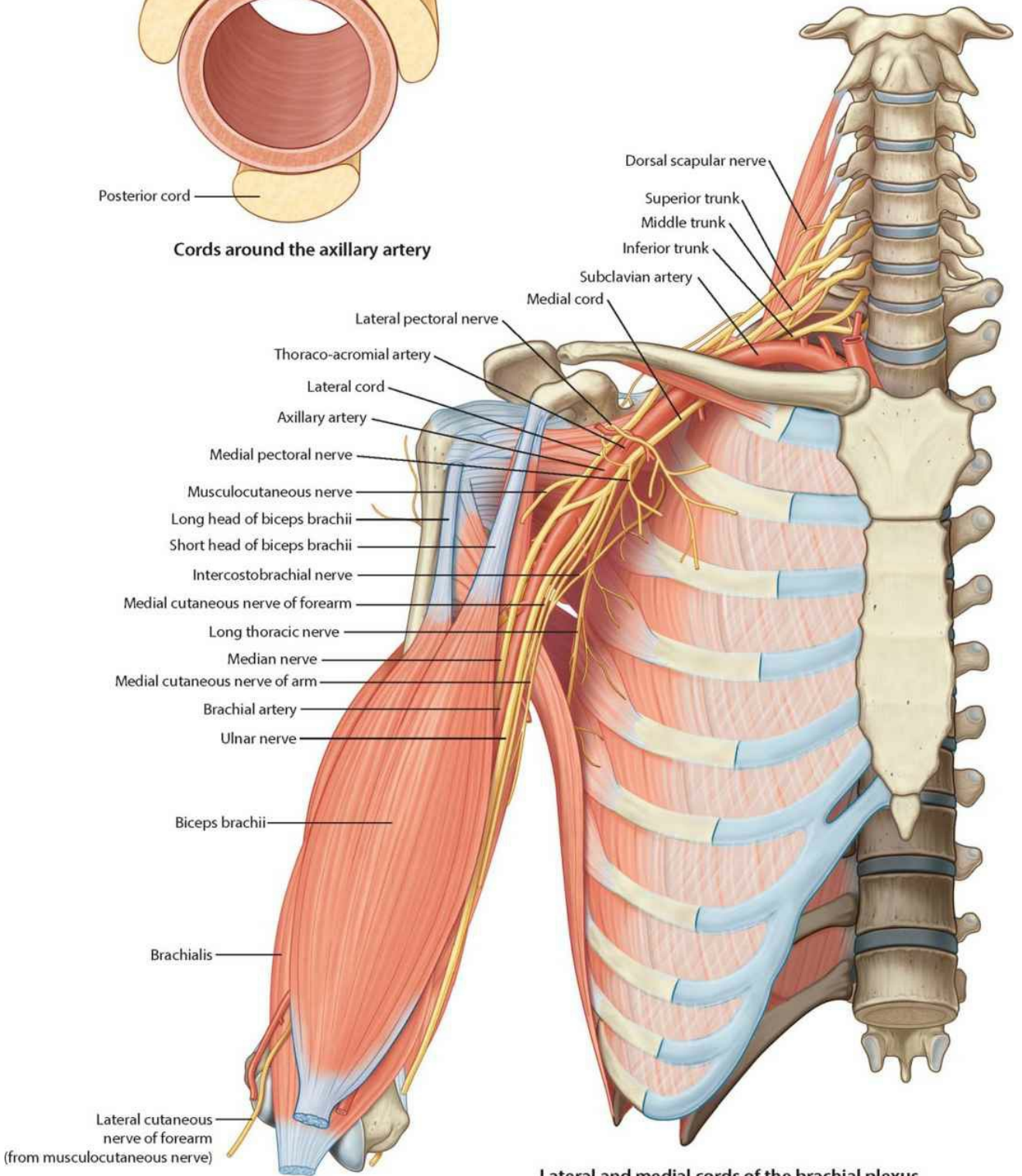


**Brachial plexus**

## Medial and lateral cords

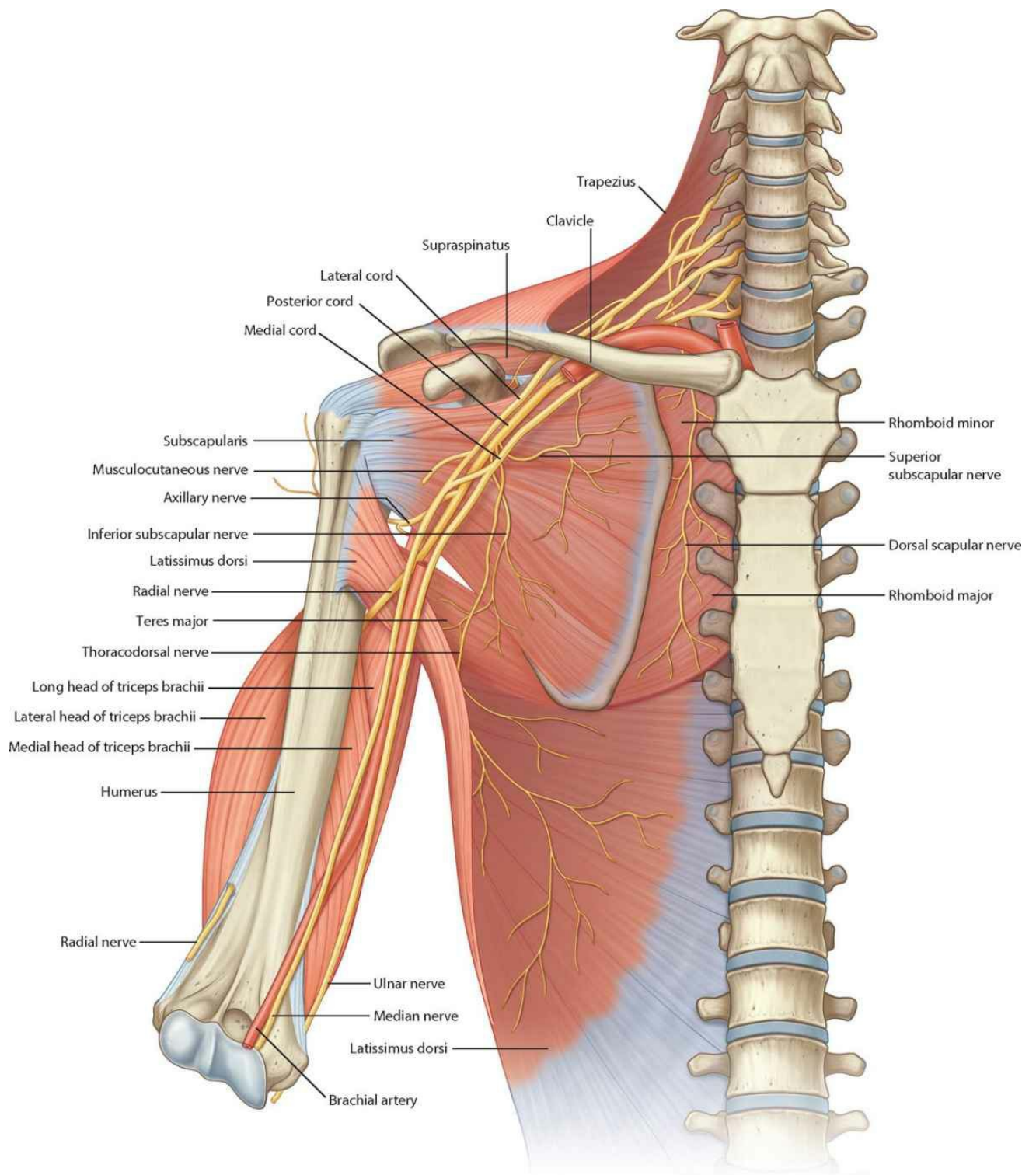


**Cords around the axillary artery**



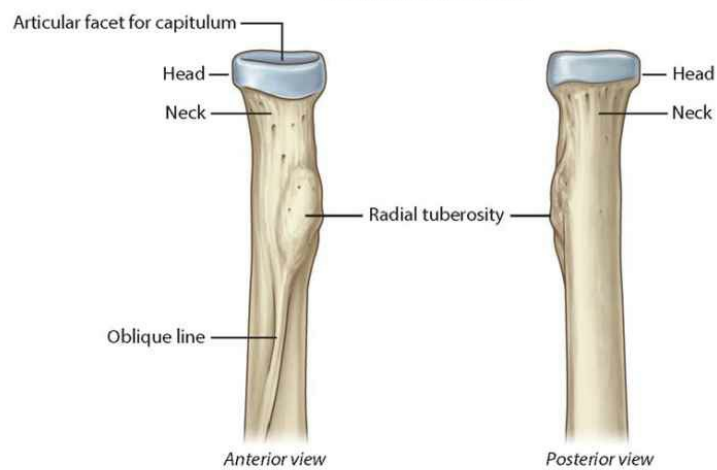
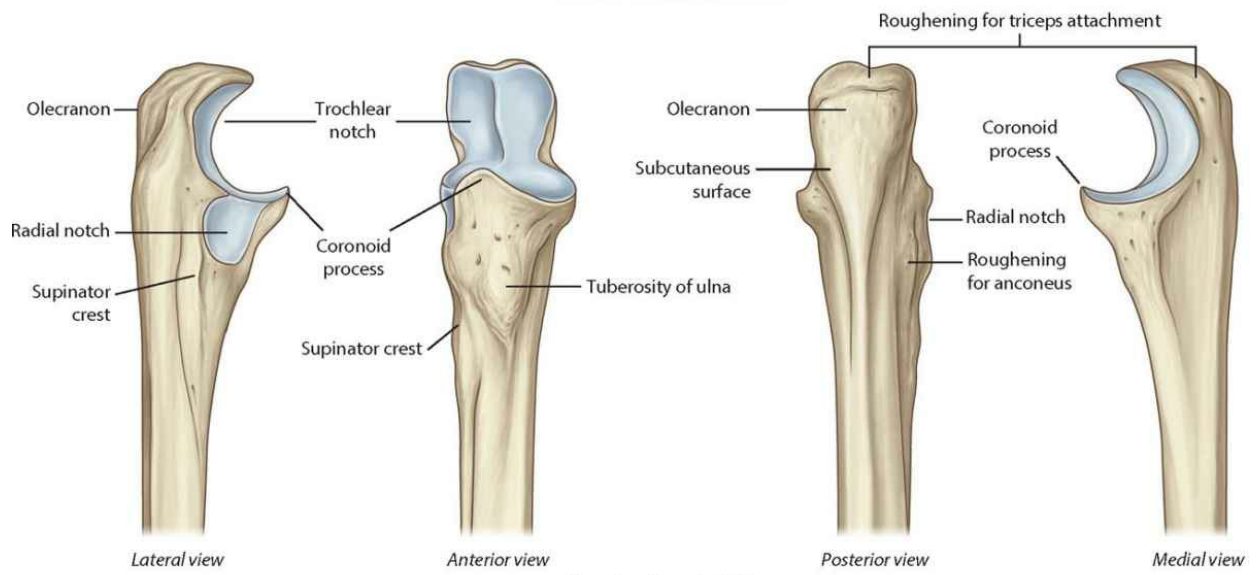
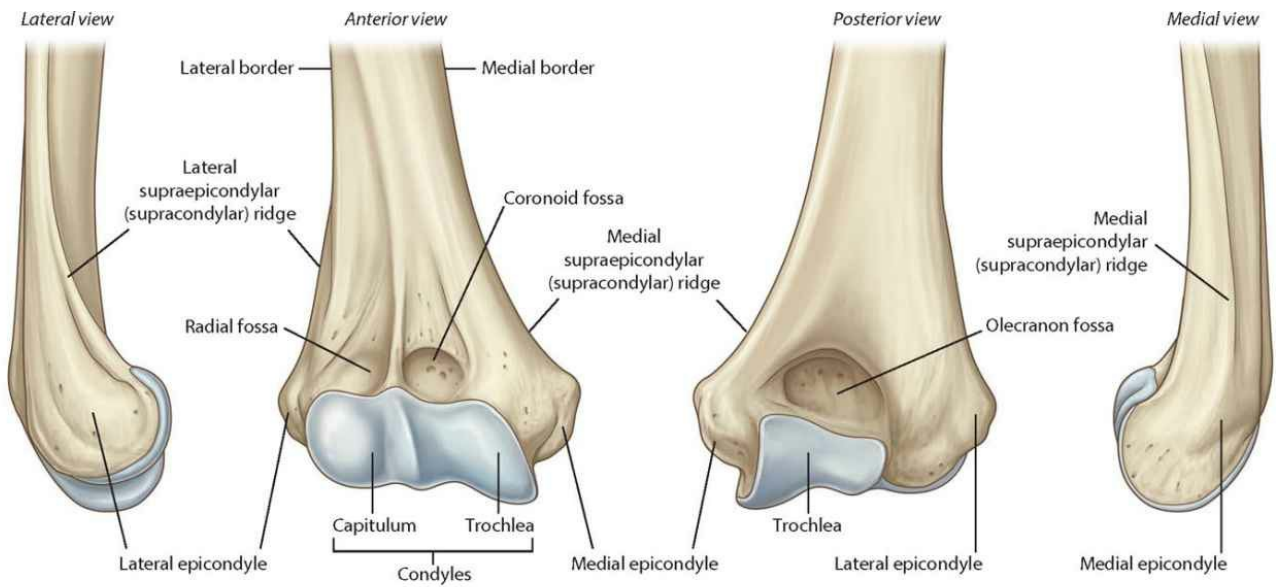
**Lateral and medial cords of the brachial plexus**

## Posterior cord



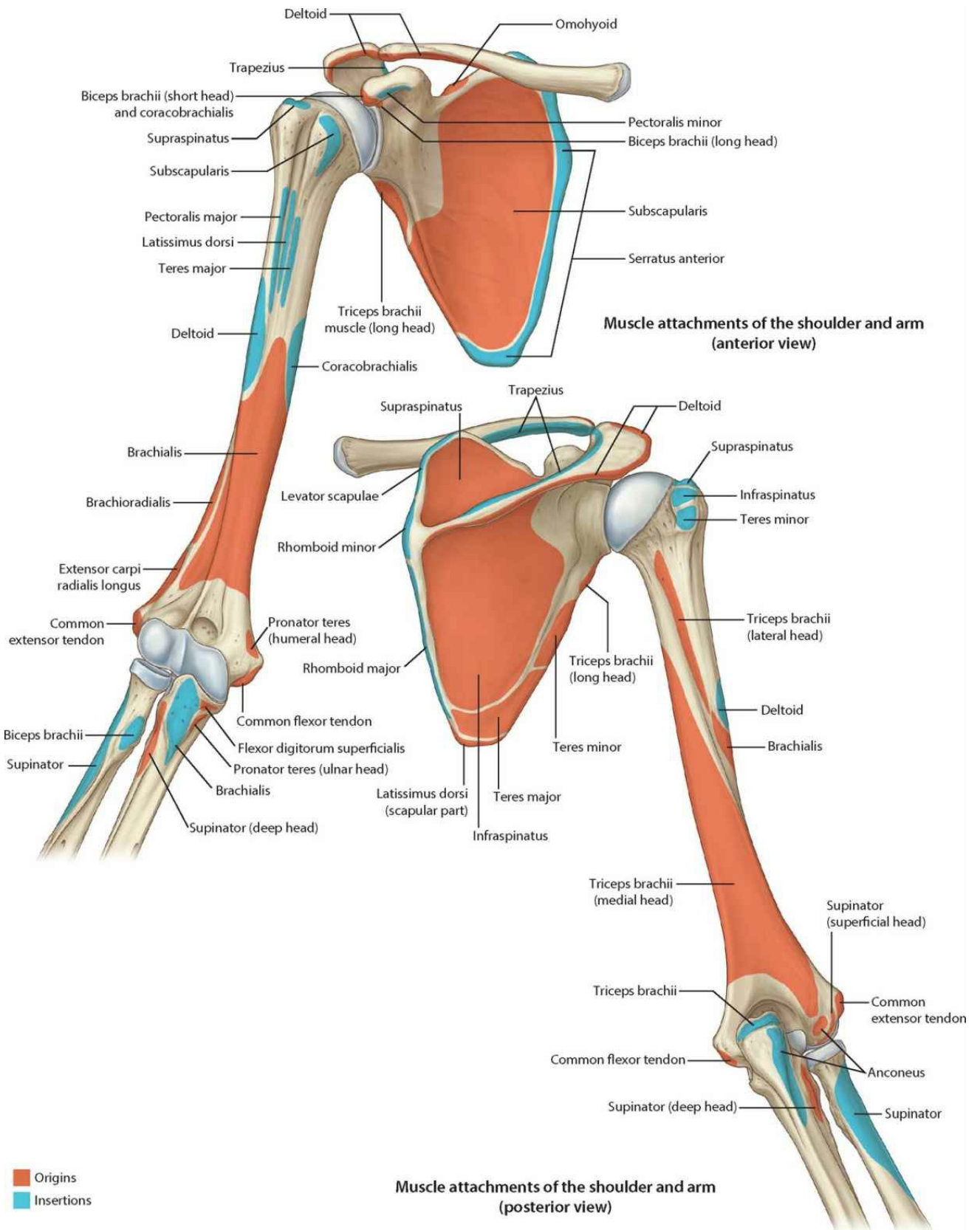
**Posterior cord of the brachial plexus  
 (ribs and associated muscles removed)**

# **Distal end of humerus and proximal end of radius and ulna**

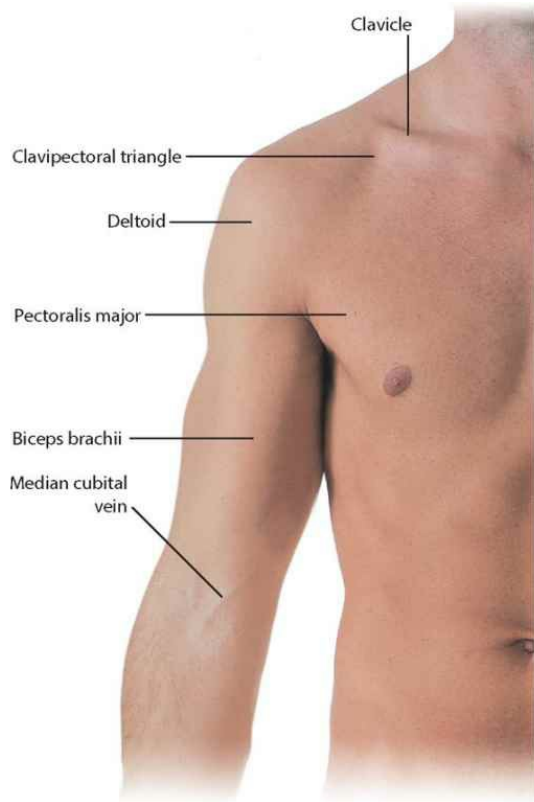




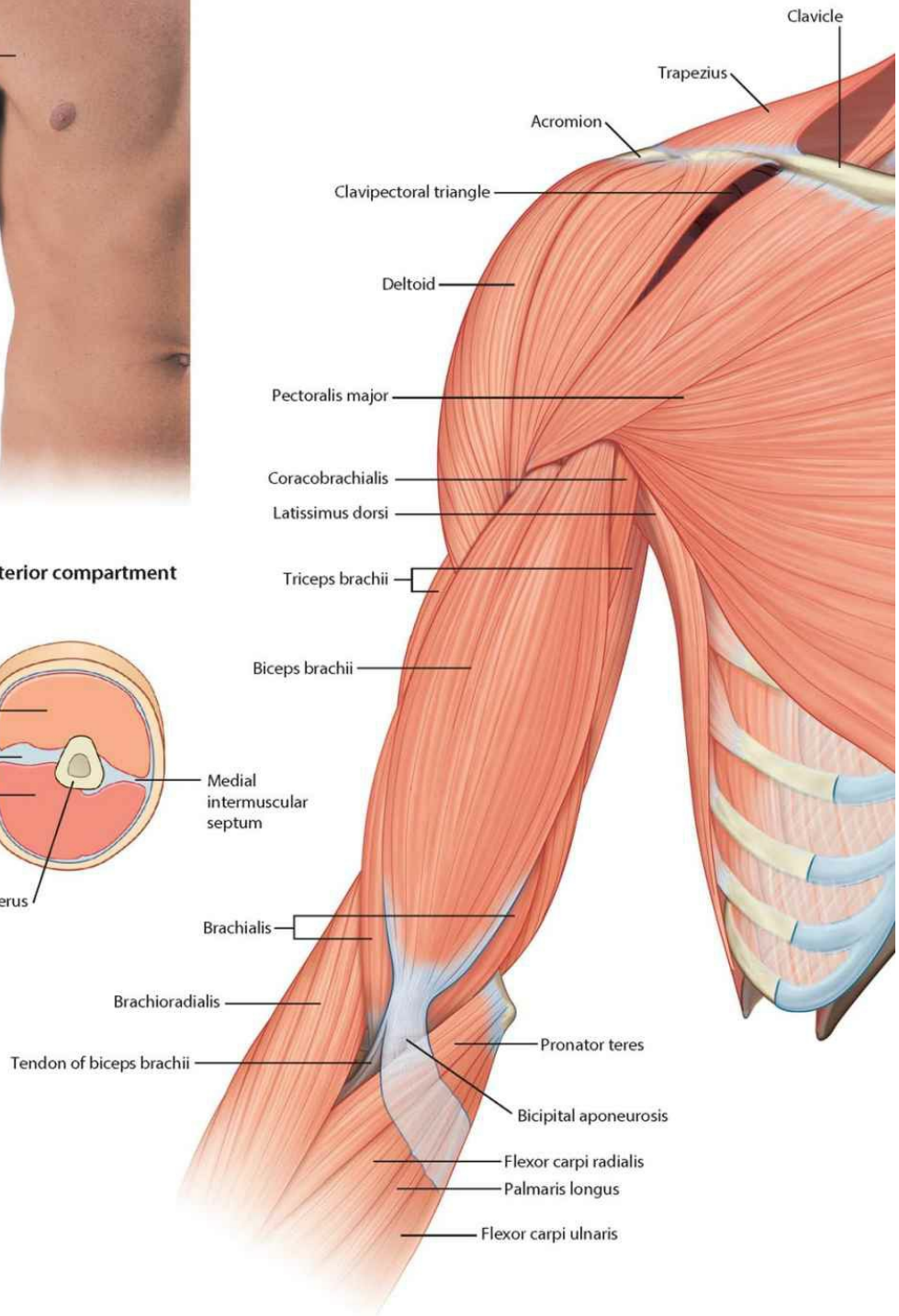
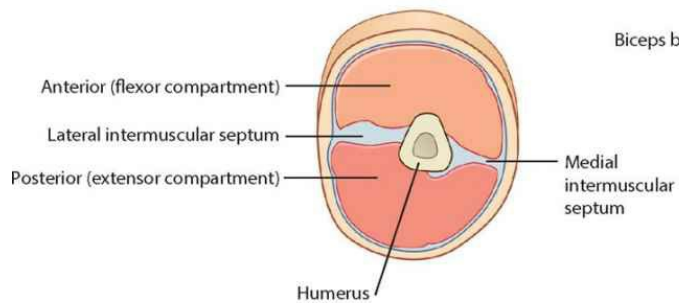
# Muscle attachments



## **Anterior compartment: muscles**

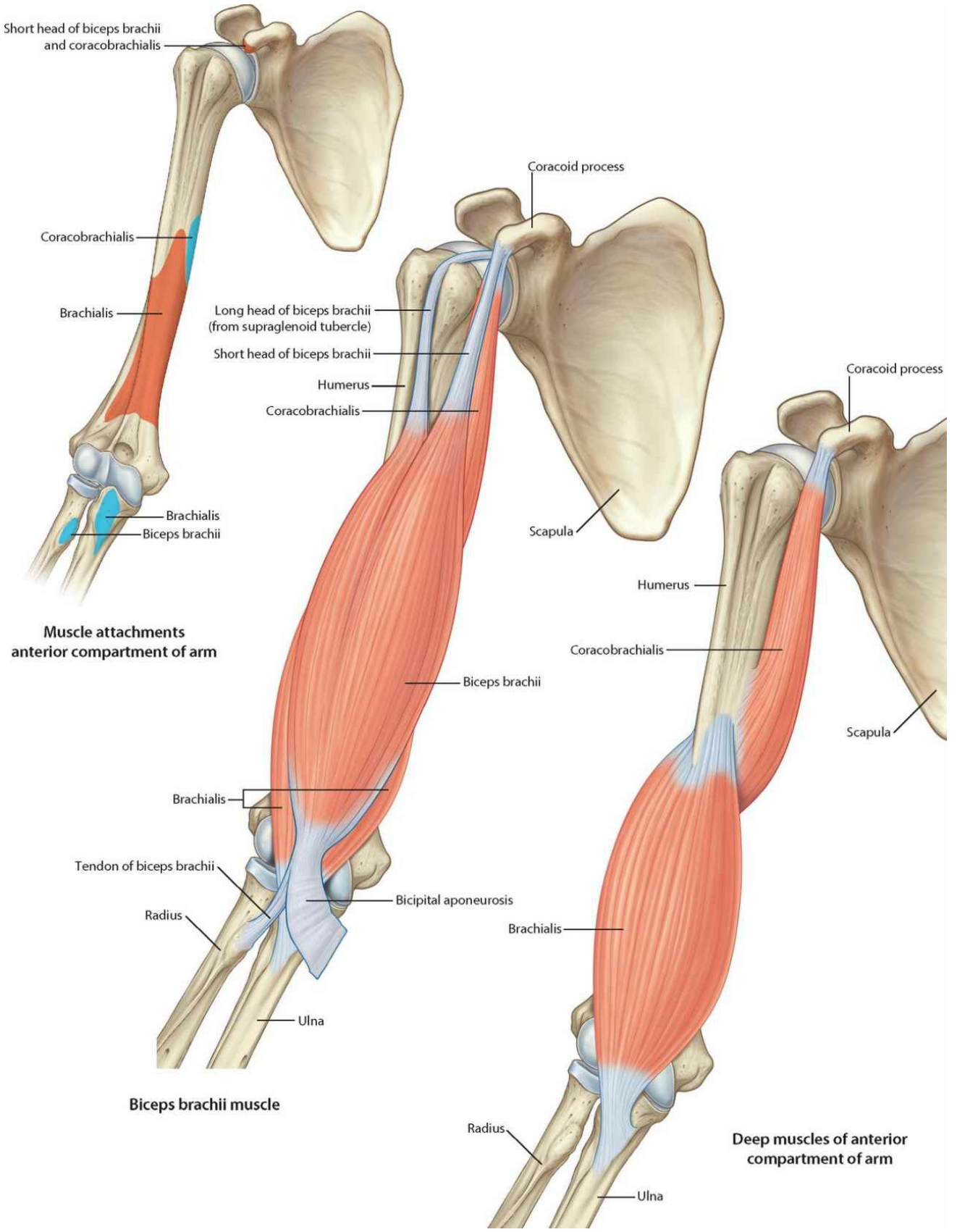


**Surface anatomy of anterior compartment**



**Muscles of anterior compartment of arm**



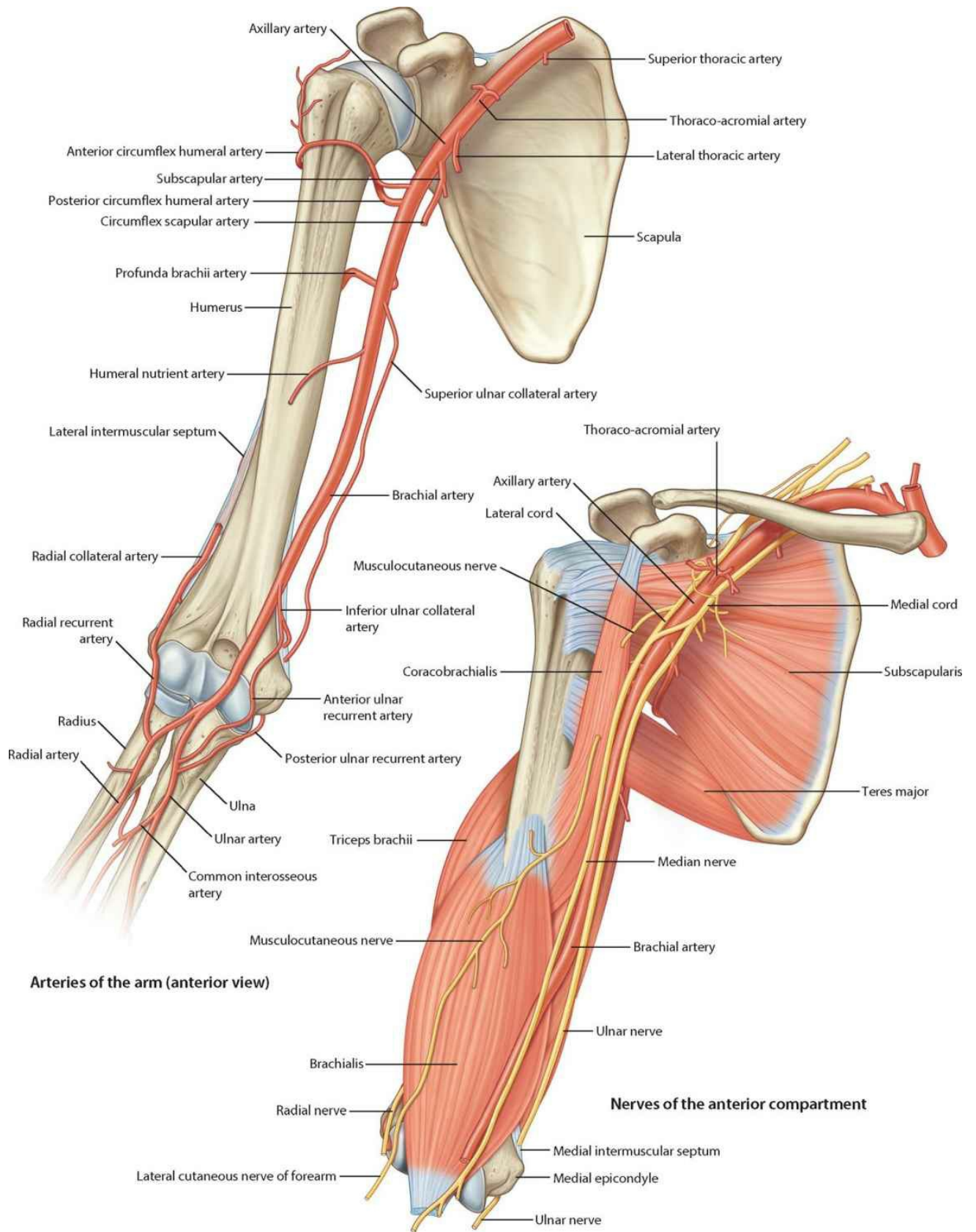


**Muscle attachments  
anterior compartment of arm**

**Biceps brachii muscle**

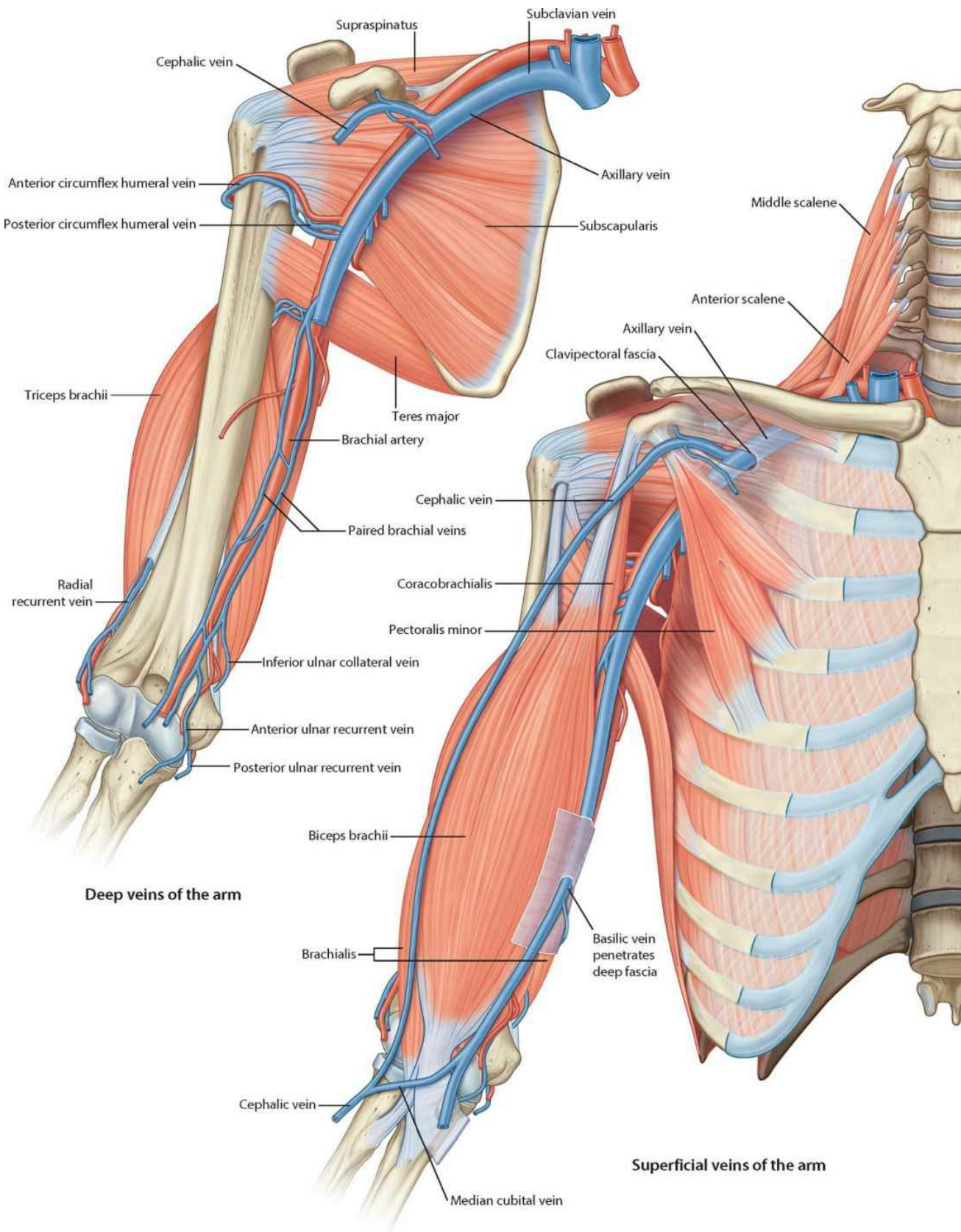
**Deep muscles of anterior  
compartment of arm**

## **Anterior compartment: arteries and nerves**

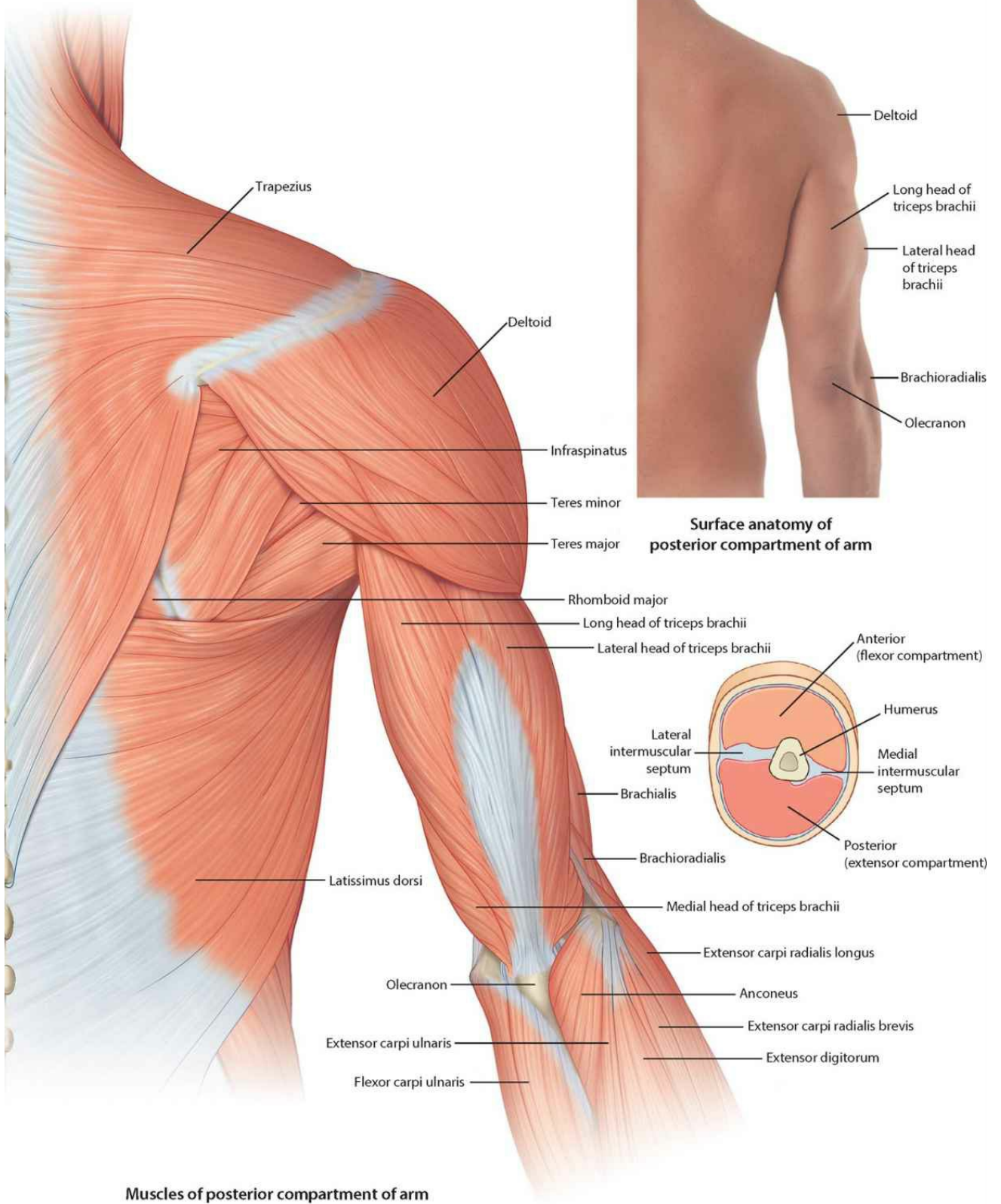




## Veins of the arm

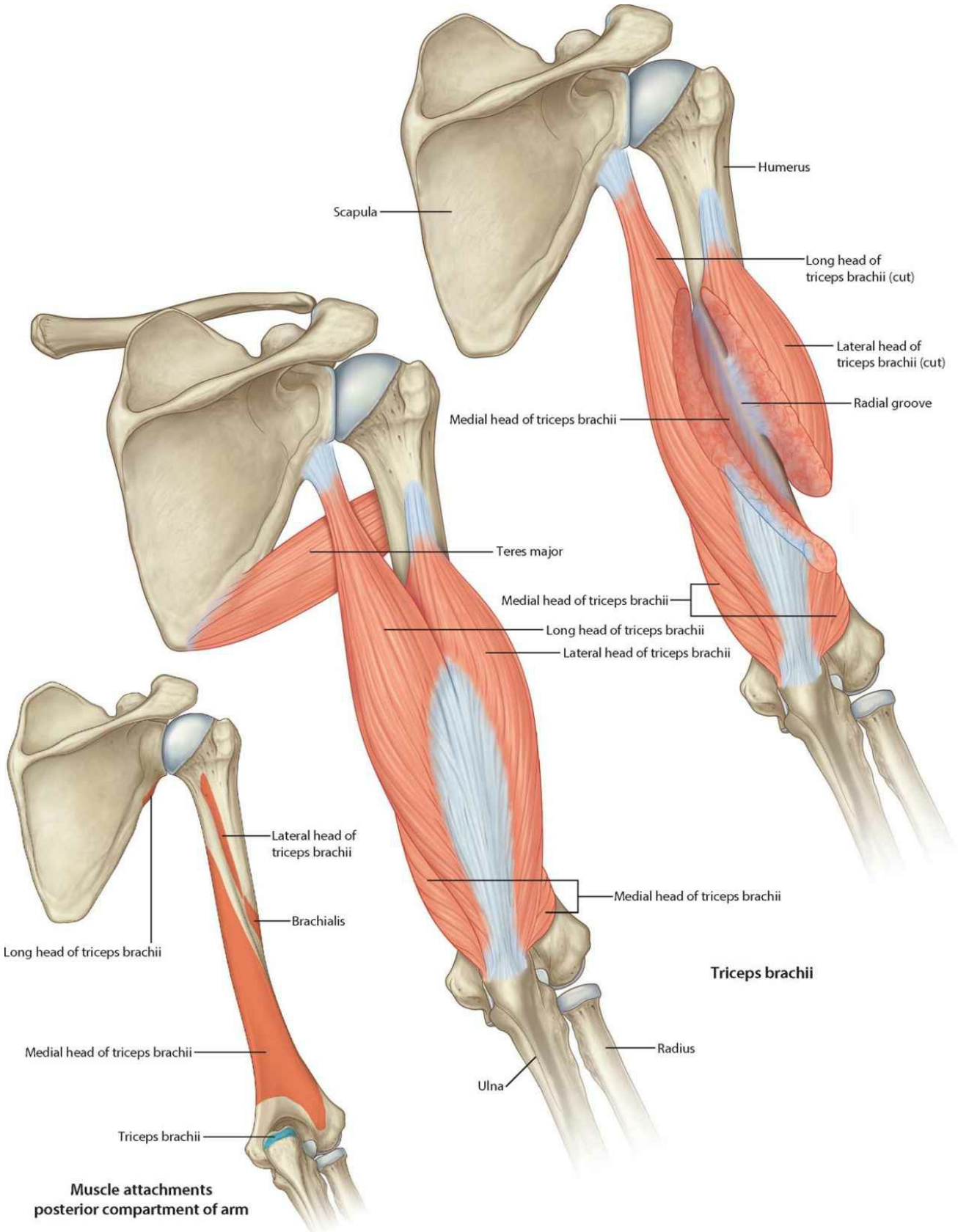


## Posterior compartment: muscles



**Muscles of posterior compartment of arm**

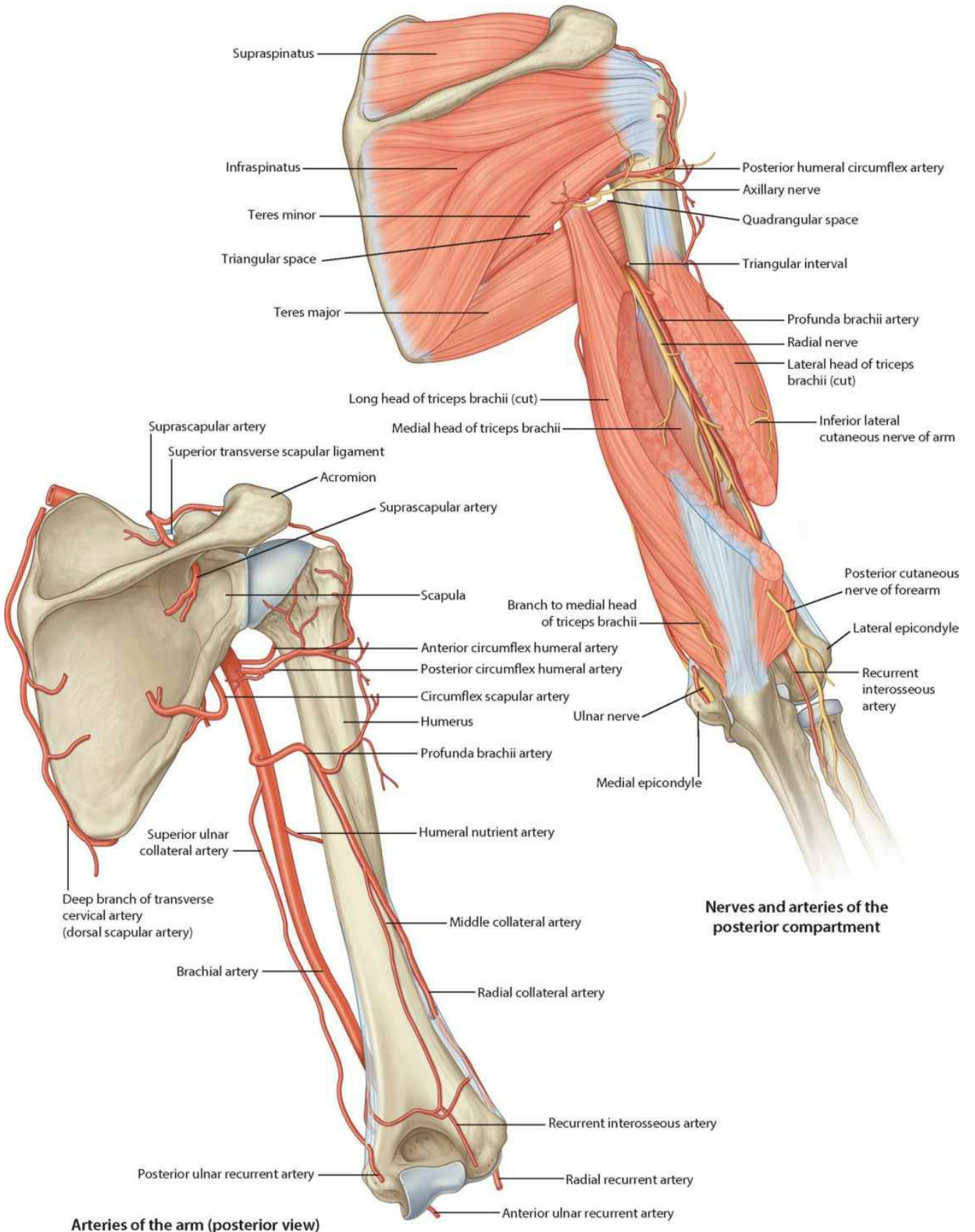




**Muscle attachments  
posterior compartment of arm**

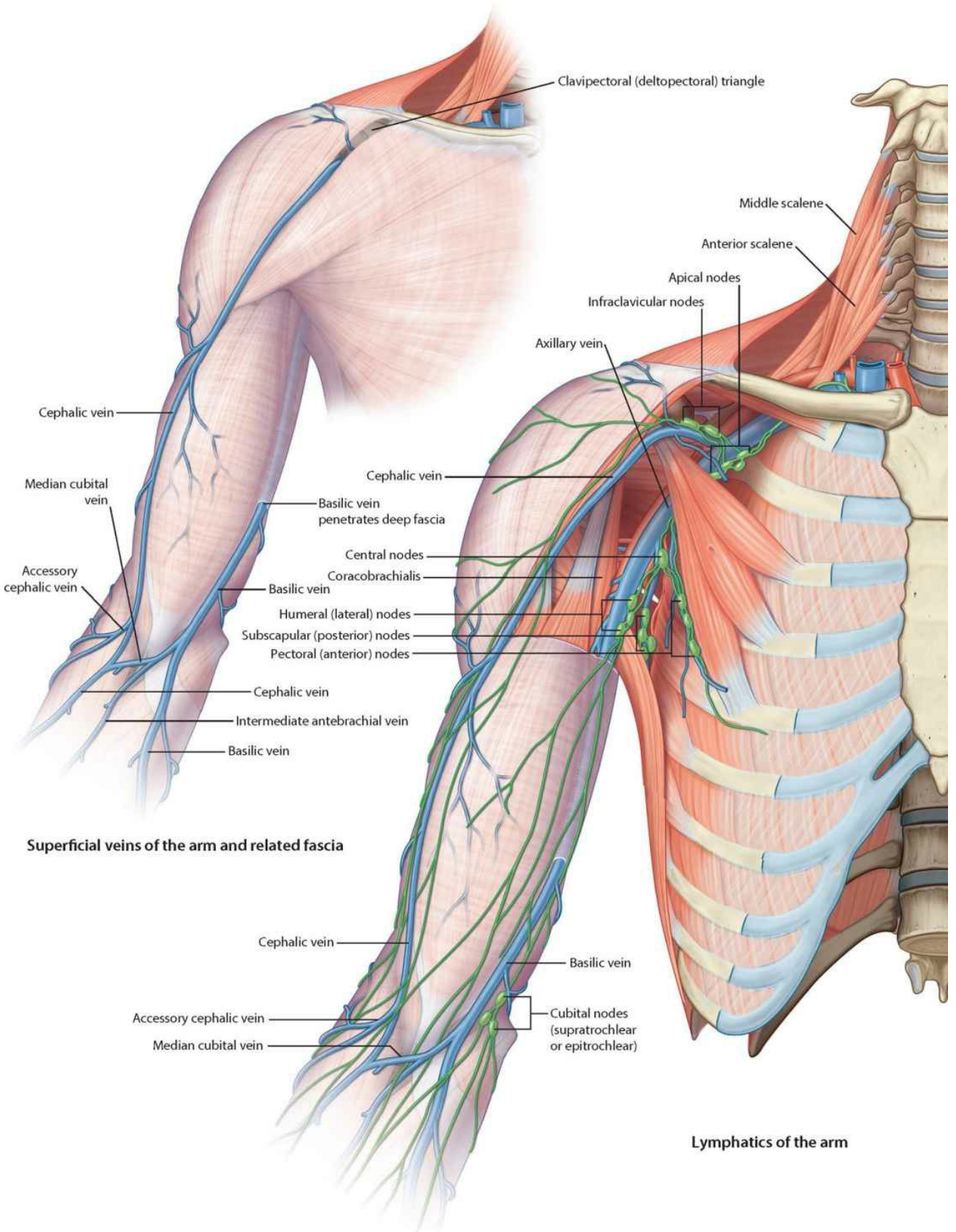
**Triceps brachii**

## Posterior compartment: arteries and nerves

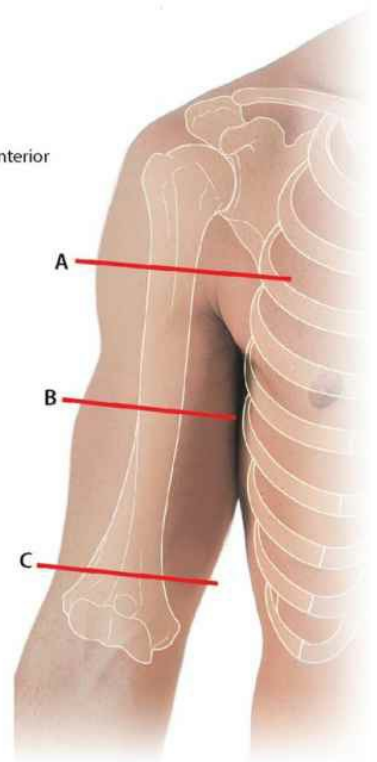
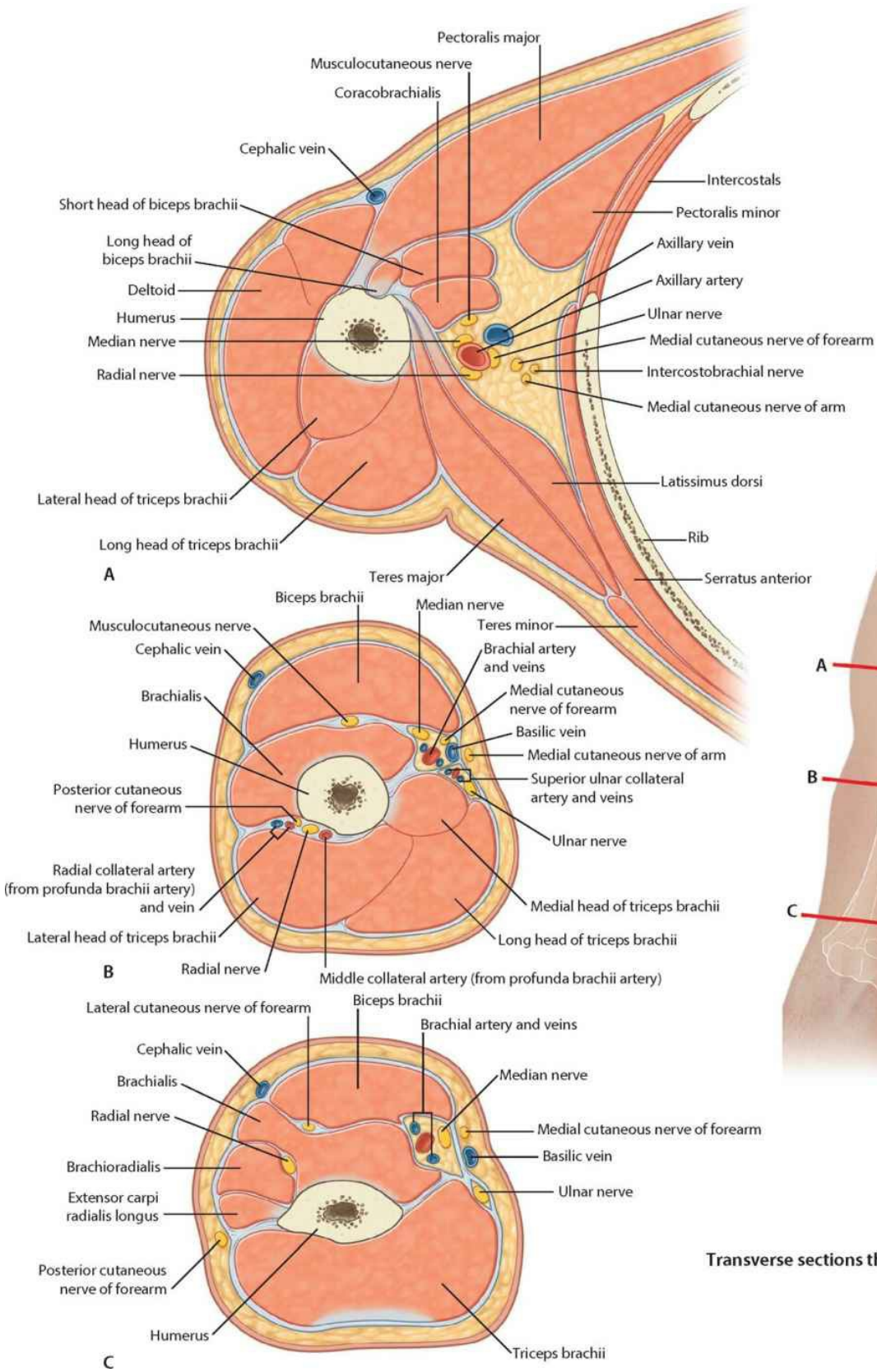




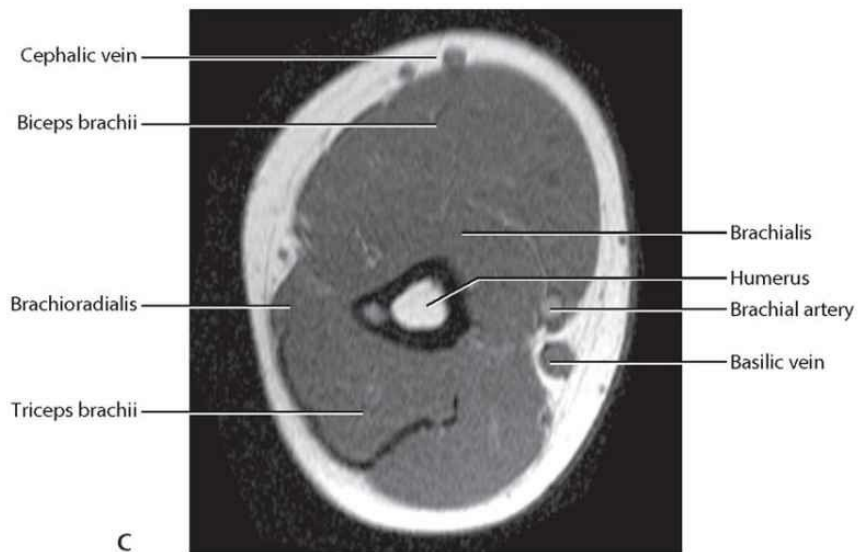
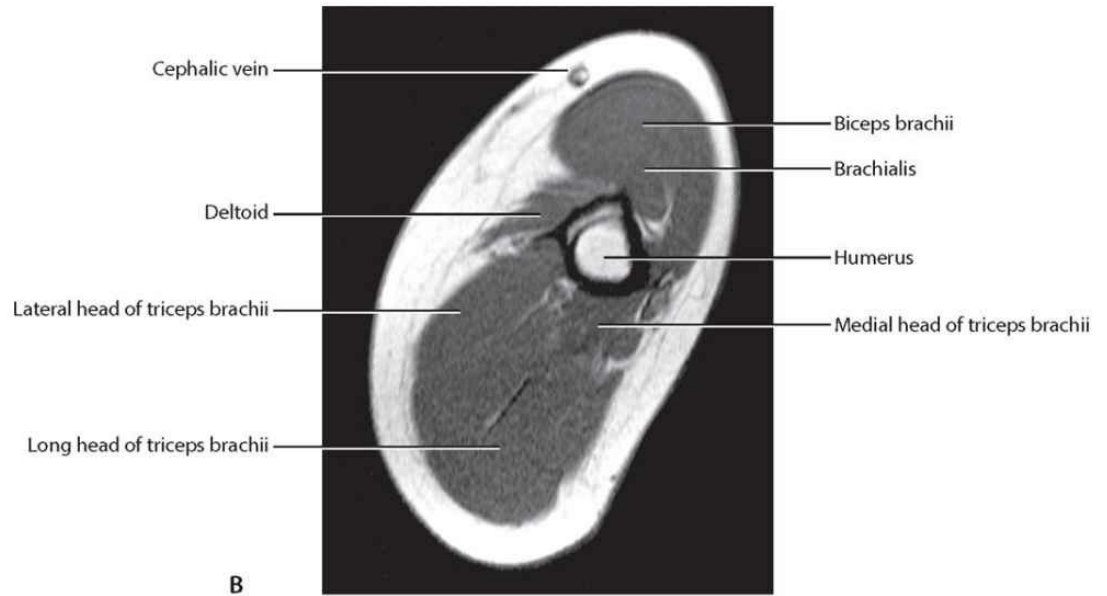
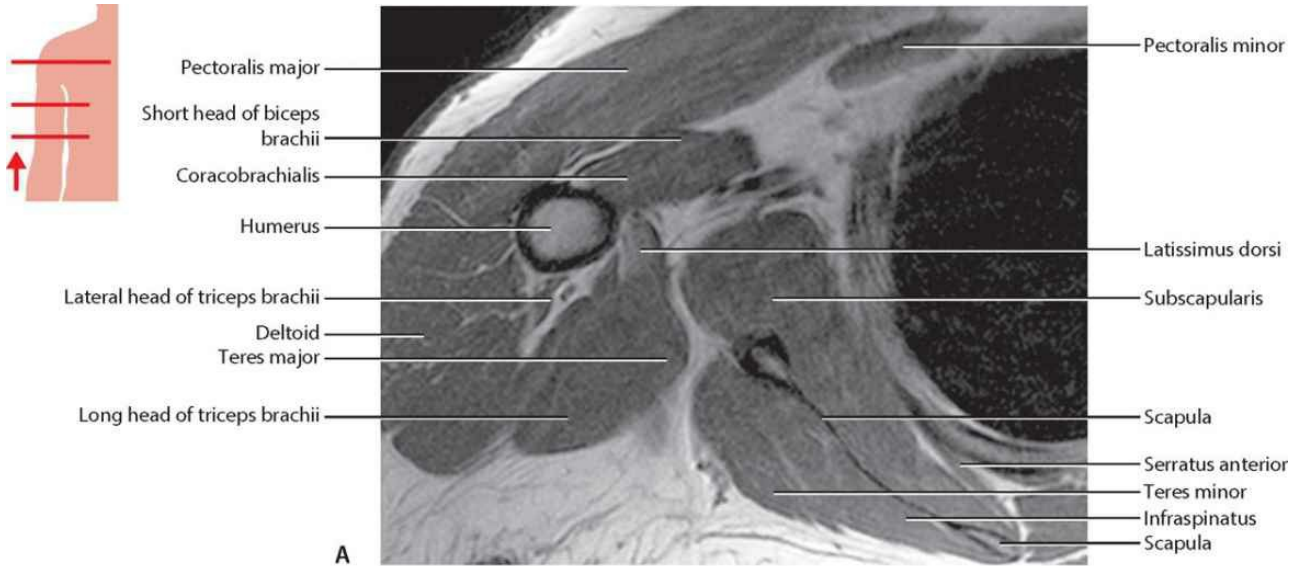
# Lymphatics of the arm



## **Transverse sections: arm**



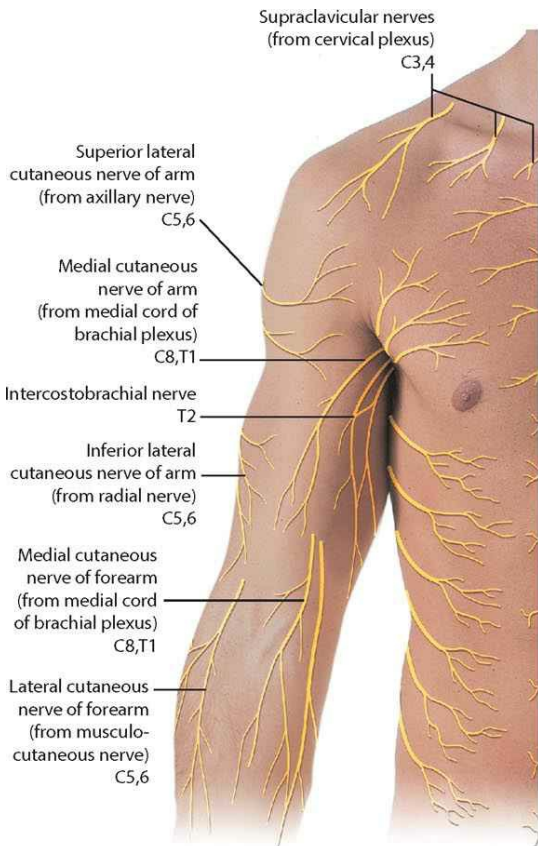
Transverse sections through arm



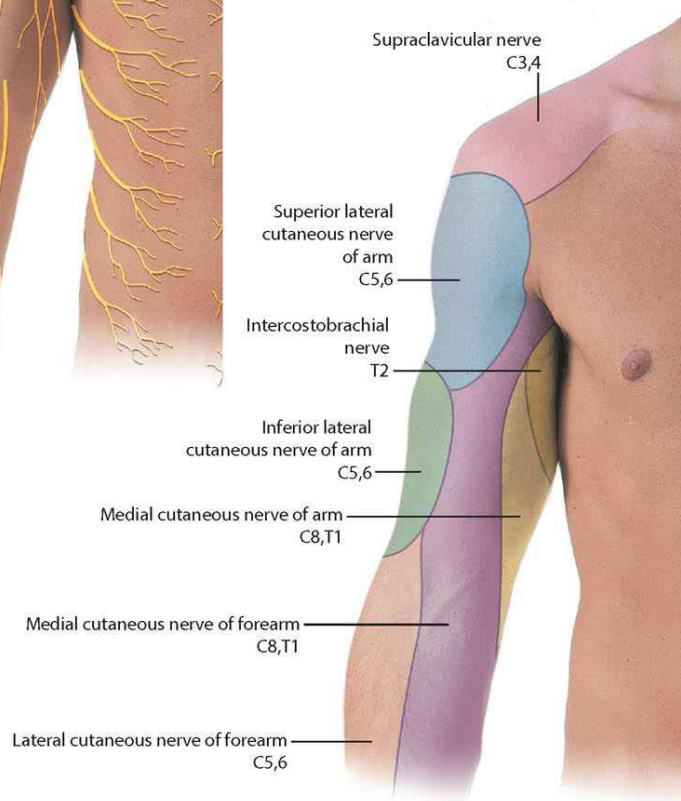
**Transverse/axial sections through the arm.**  
**A. Proximal/upper arm. B. Middle arm. C. Distal/lower arm.**  
 T1-weighted MR image in axial plane



## **Anterior cutaneous nerves of the arm**

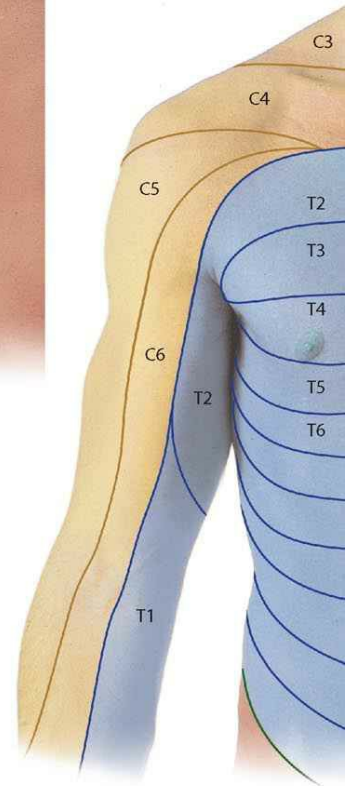


**Cutaneous nerves of the arm**



**Areas of distribution of the cutaneous nerves of the arm**

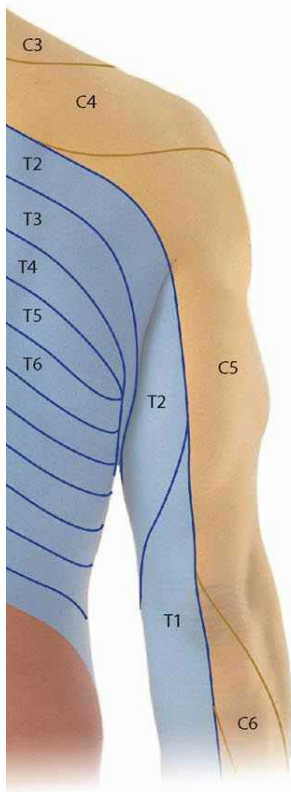
**Dermatomes of the arm**



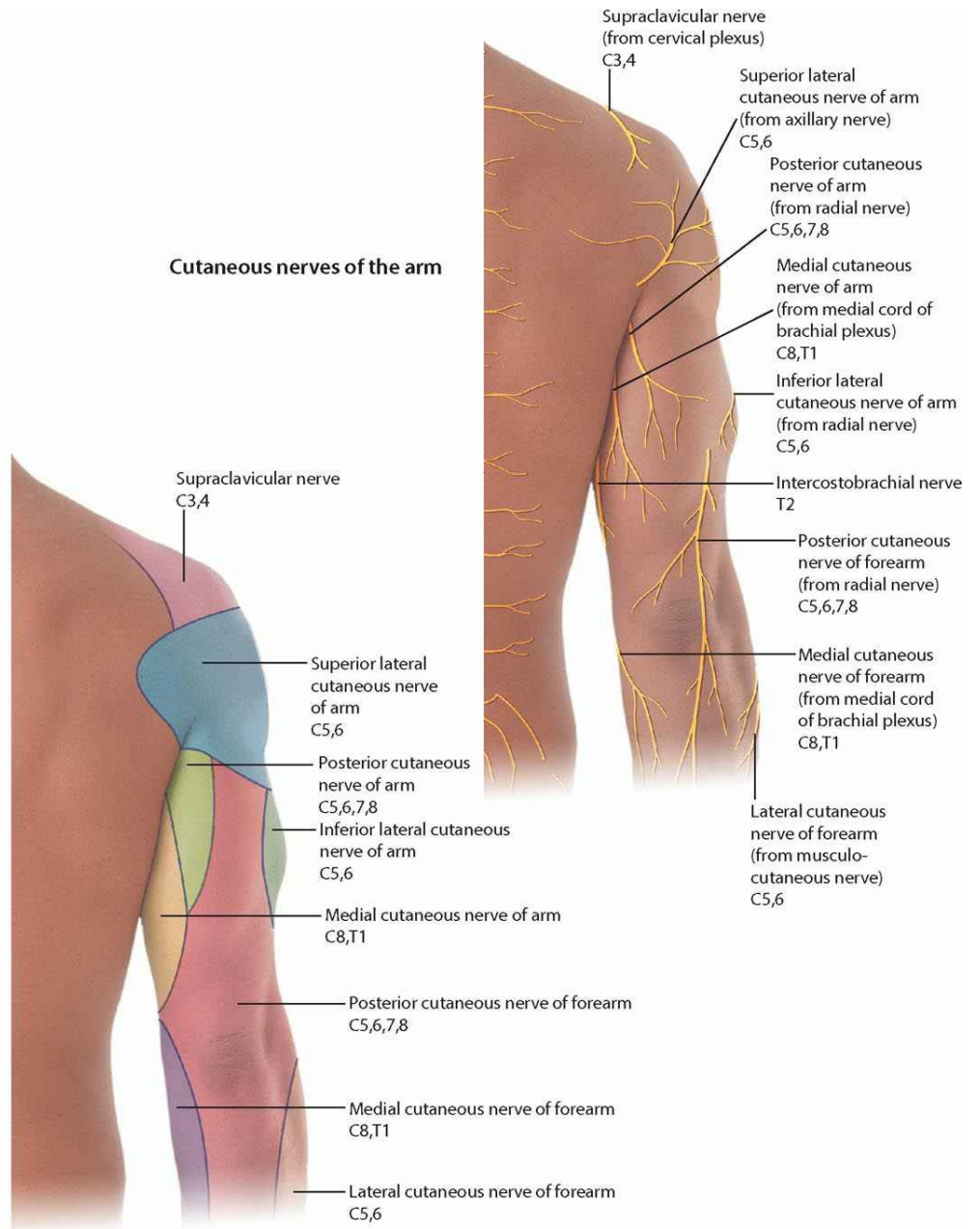


## Posterior cutaneous nerves of the arm

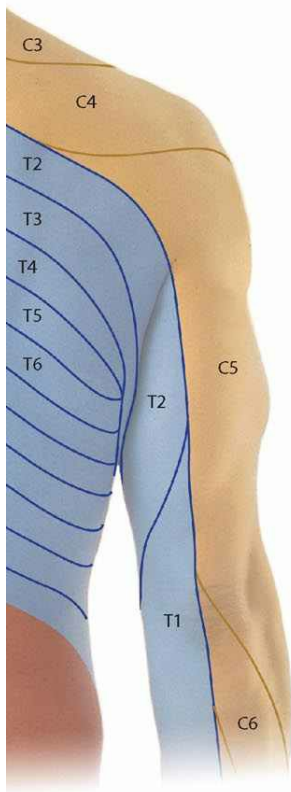
**Areas of distribution of the cutaneous nerves of the arm**



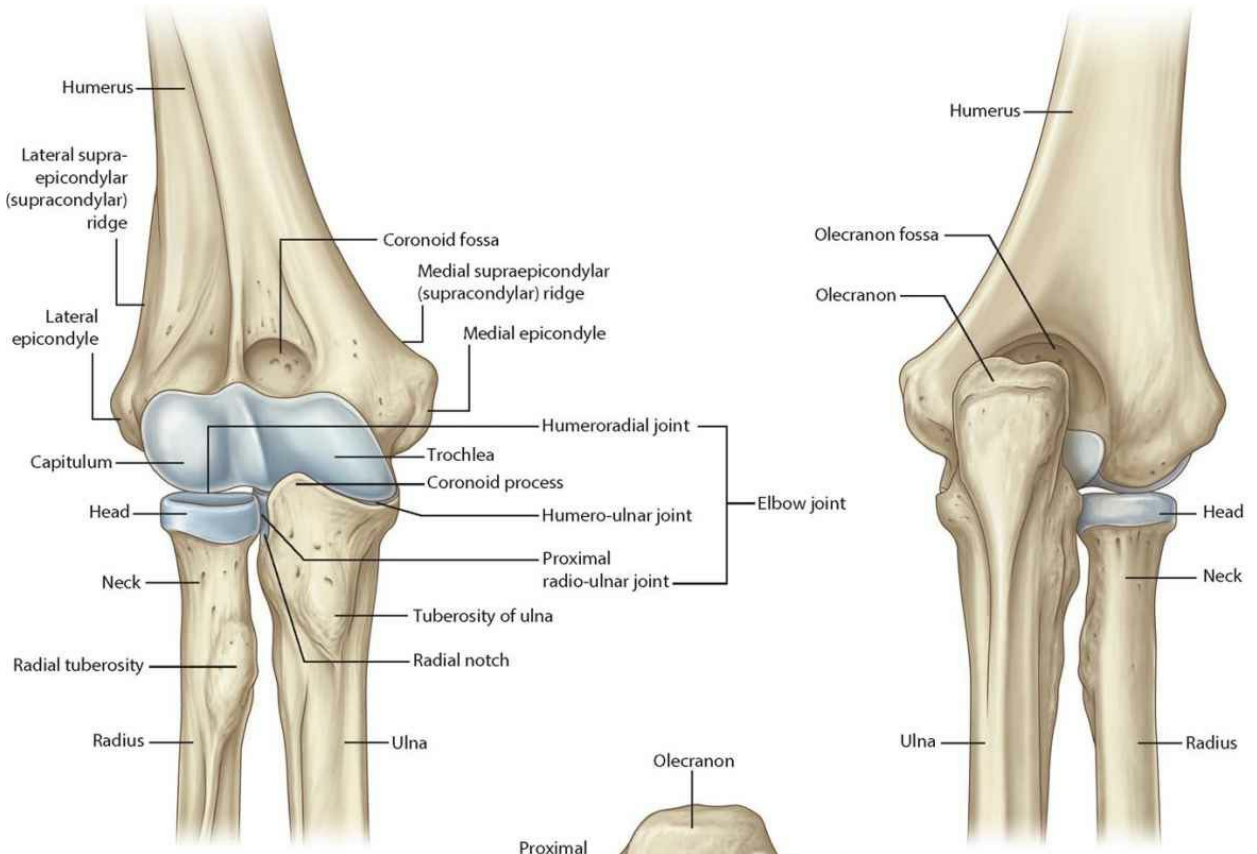
**Cutaneous nerves of the arm**



**Dermatomes of the arm**

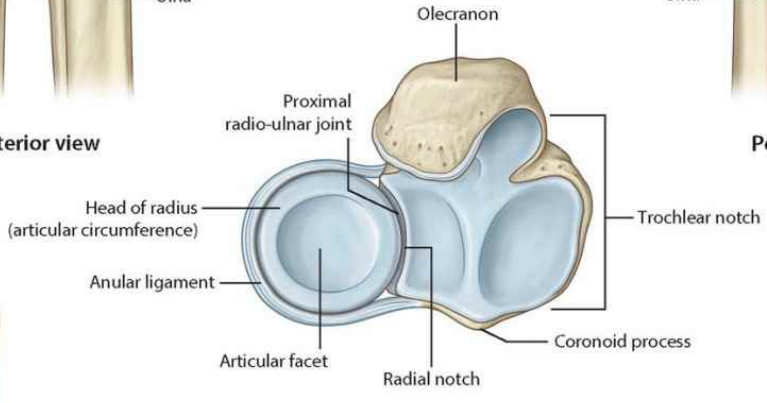


# Elbow joint

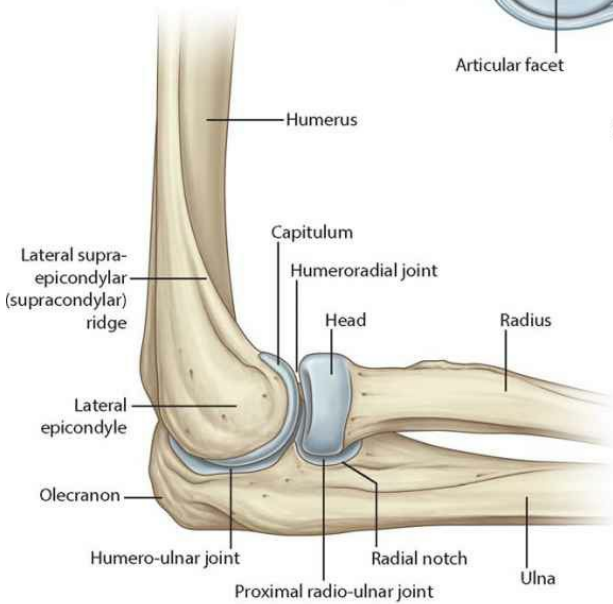


**Anterior view**

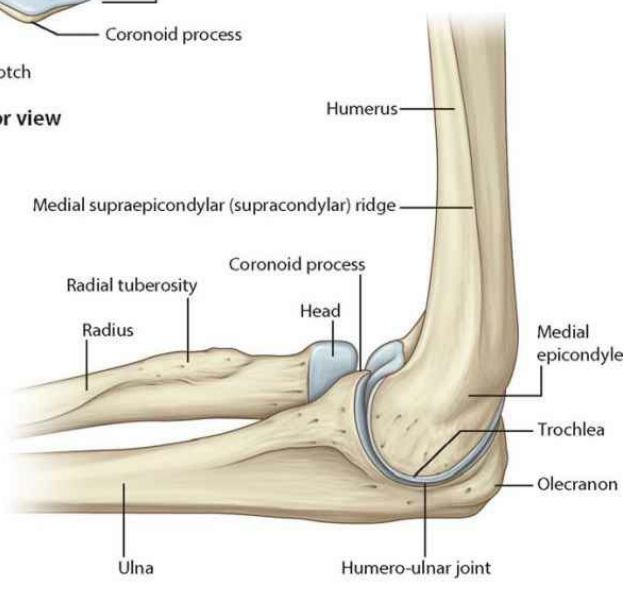
**Posterior view**



**Superior view**

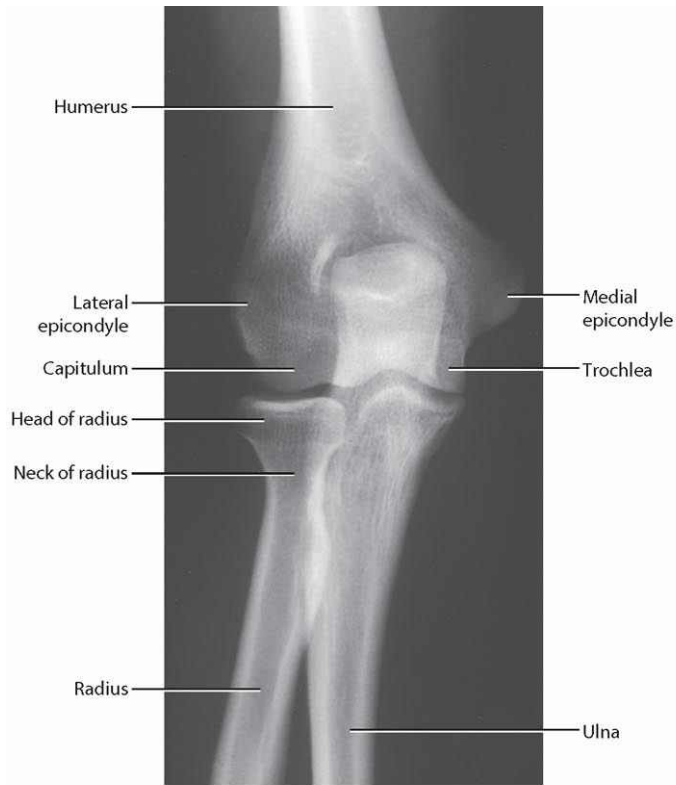


**Lateral view**

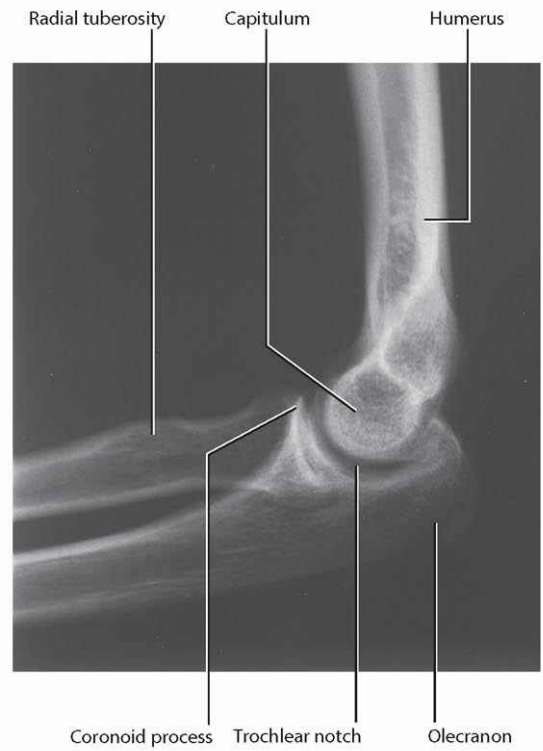

**Medial view**

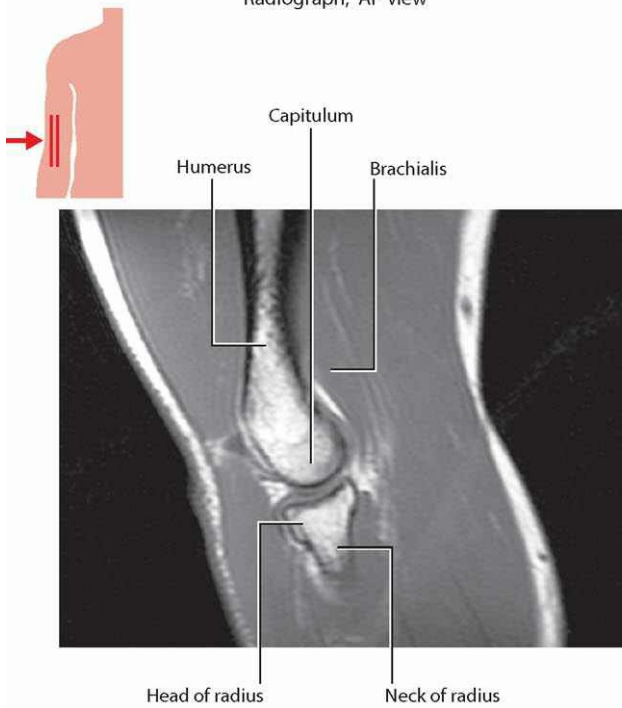




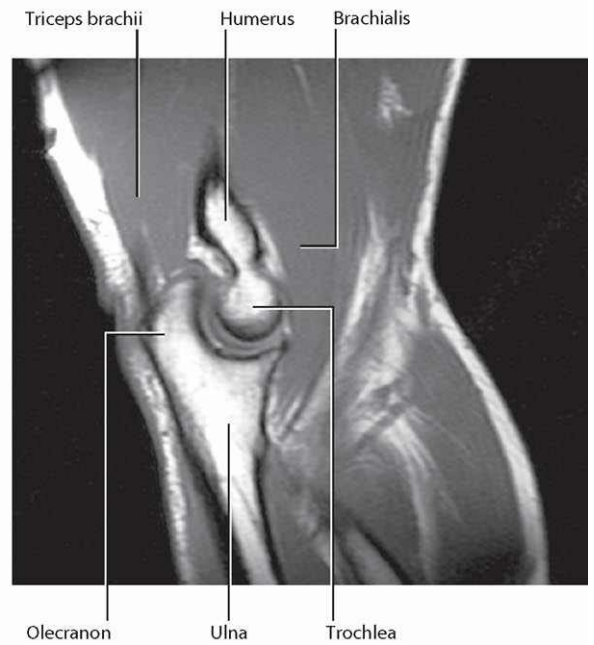**Normal elbow joint.**  
Radiograph, AP view



**Normal elbow joint.**  
Radiograph, lateral view

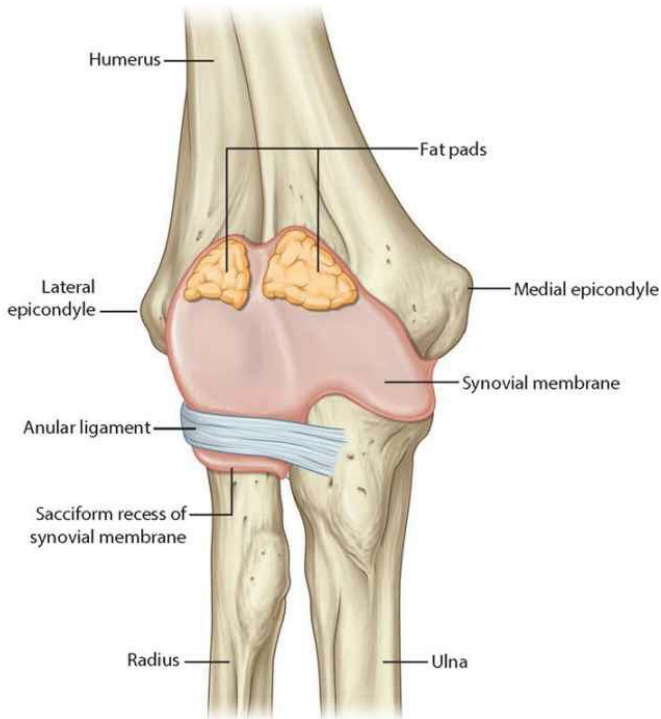


**Articulation of the capitulum of the humerus and the head of the radius at the elbow joint.**  
T2-weighted MR image in sagittal plane

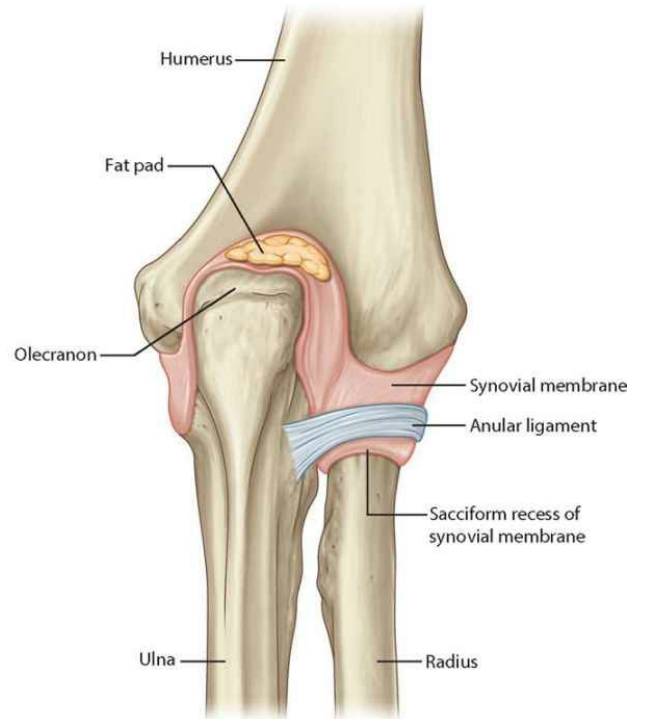


**Articulation of the trochlea of the humerus and the trochlear notch of the ulna.**  
T2-weighted MR image in sagittal plane

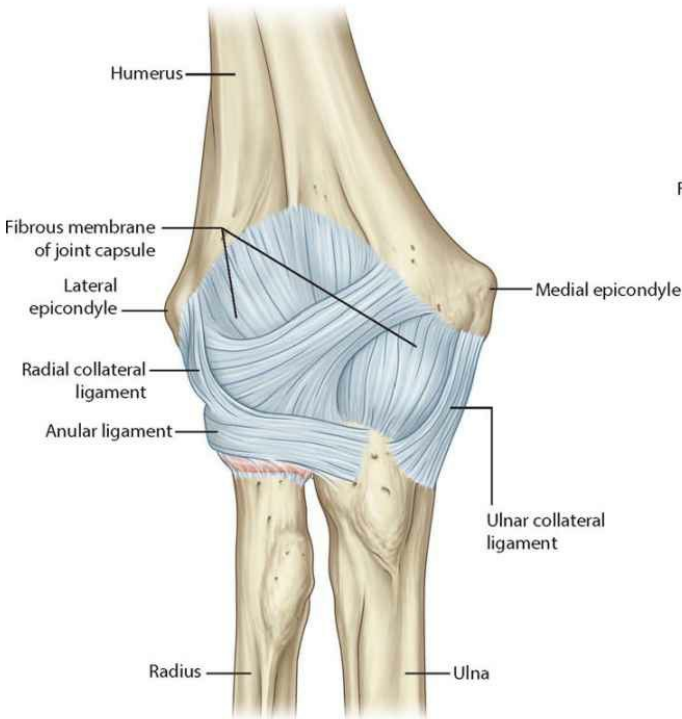
# Elbow joint: capsule and ligaments



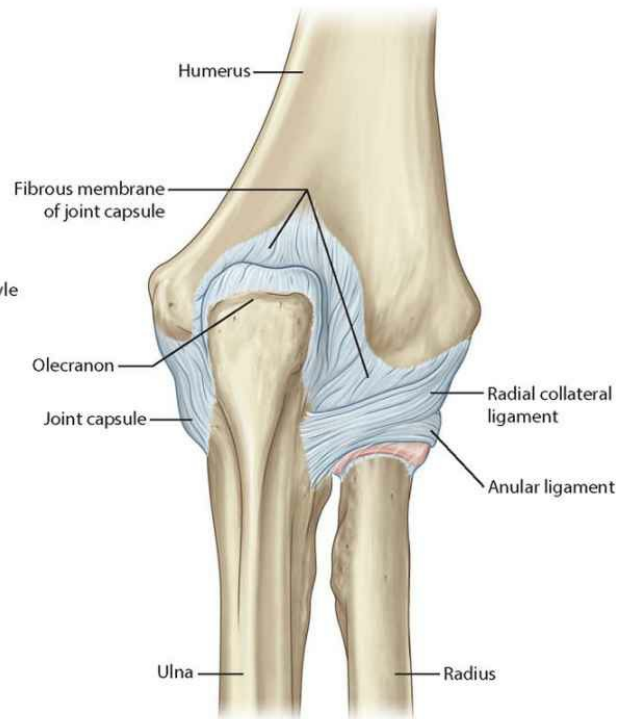
**Synovial membrane of the elbow joint (anterior view)**



**Synovial membrane of the elbow joint (posterior view)**



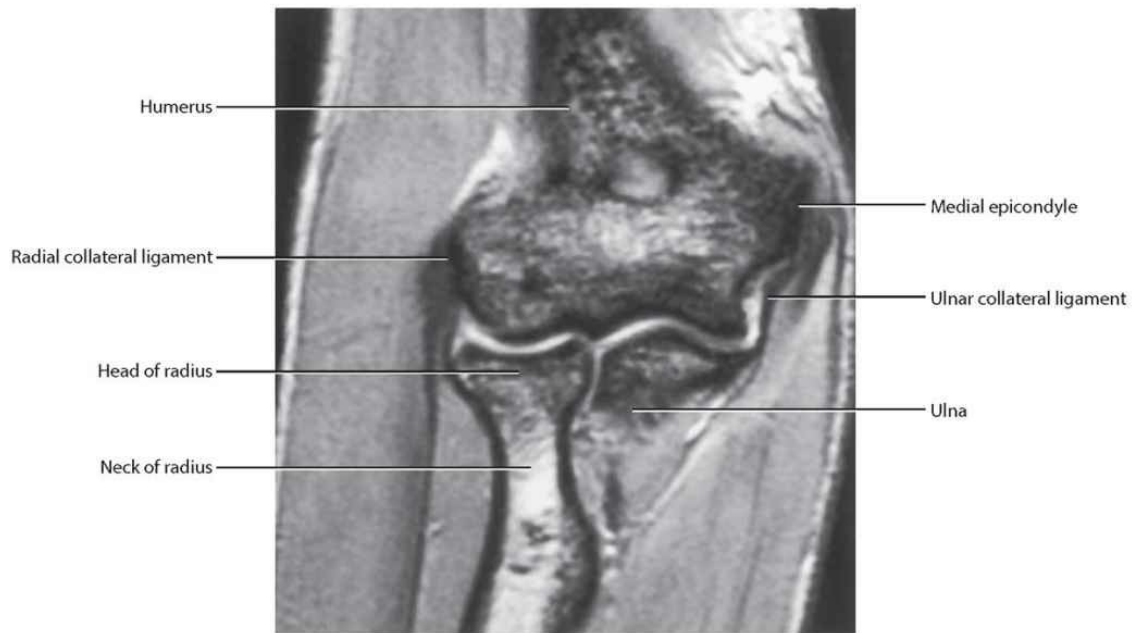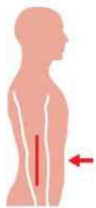
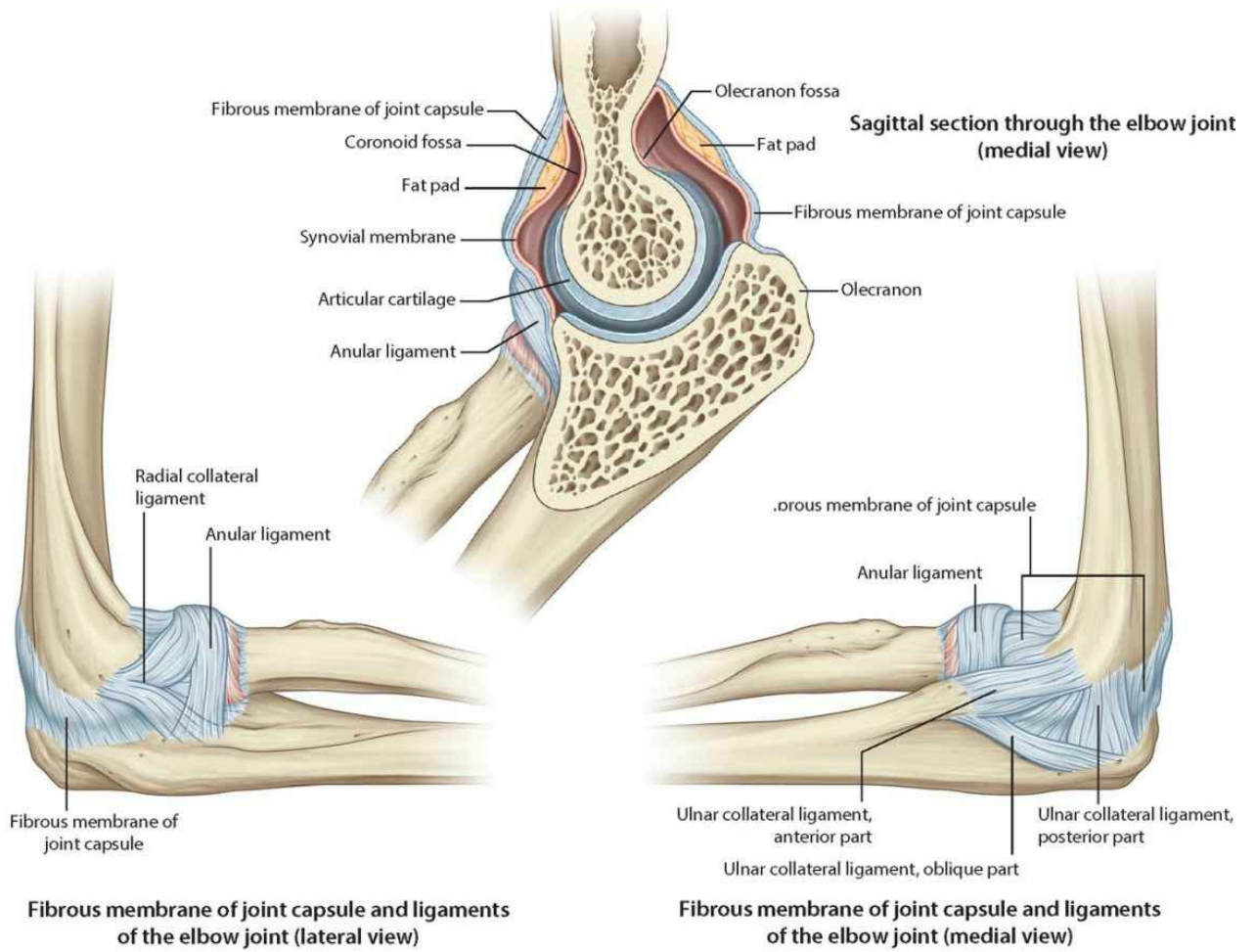
**Fibrous membrane of joint capsule and ligaments of the elbow joint (anterior view)**



**Fibrous membrane of joint capsule and ligaments of the elbow joint (posterior view)**

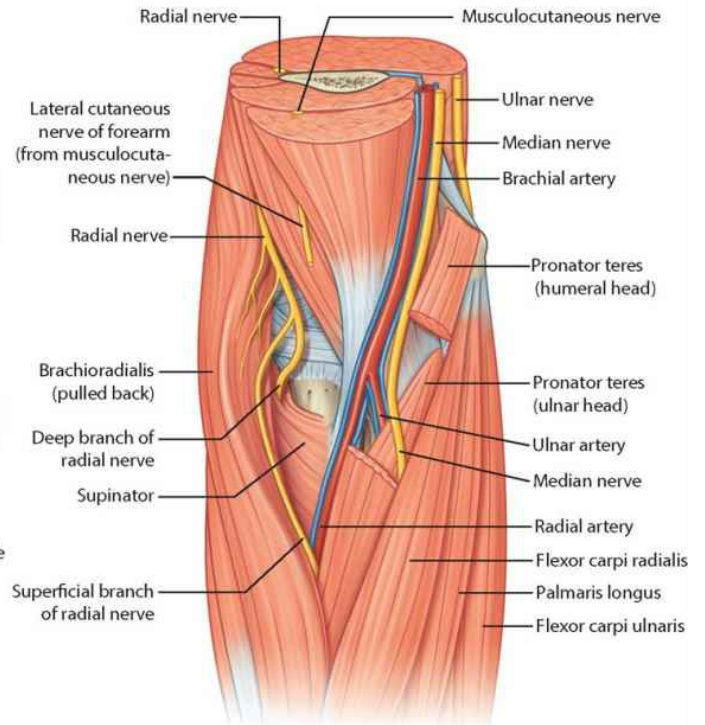
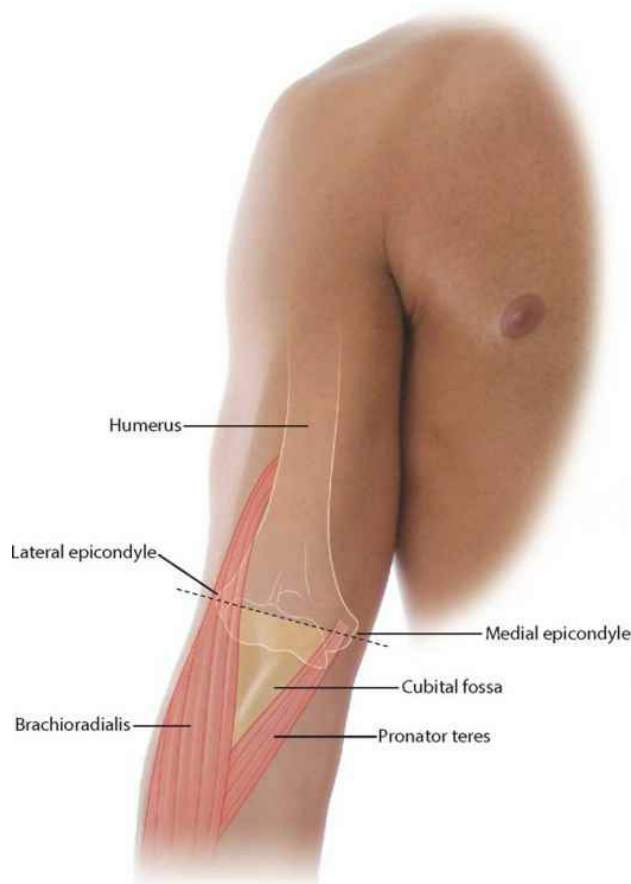






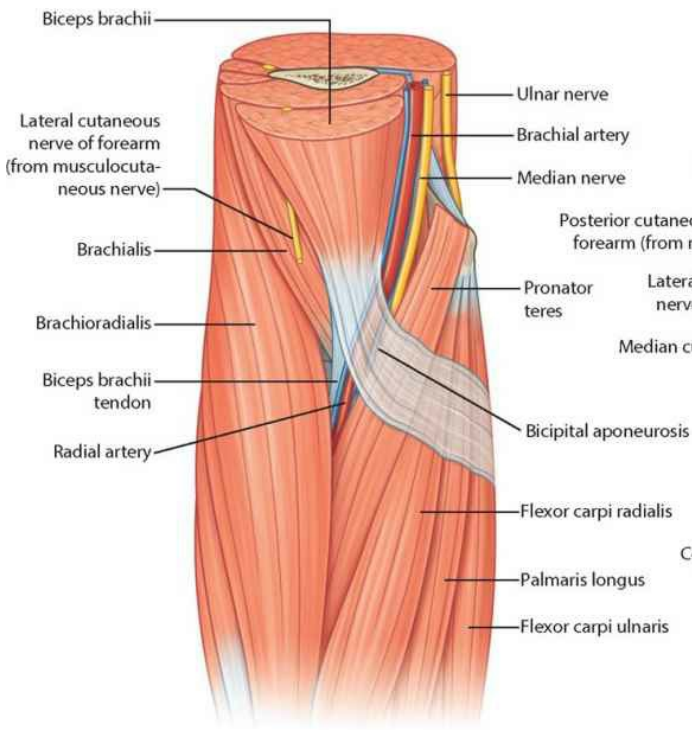
**Normal elbow joint.**  
T2-weighted MR image in coronal plane

# Cubital fossa

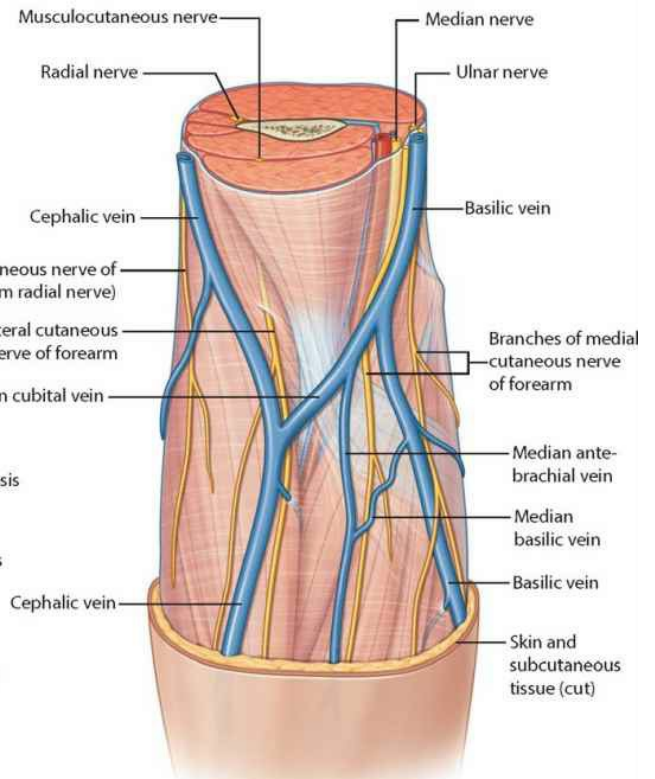


**Position of the radial nerve**

**Margins of the cubital fossa**

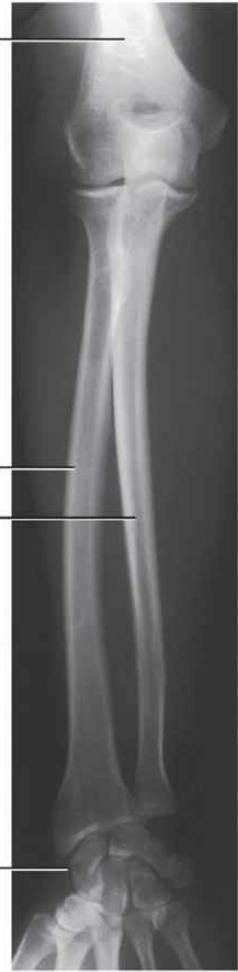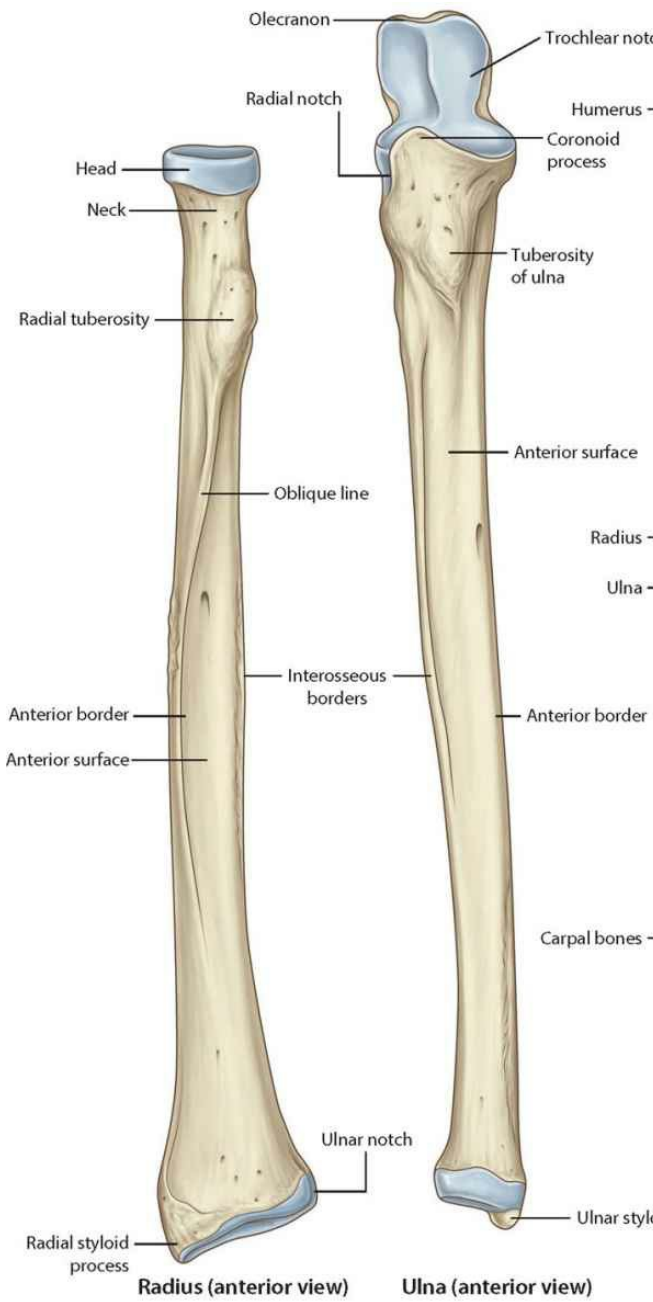


**Contents of the cubital fossa**

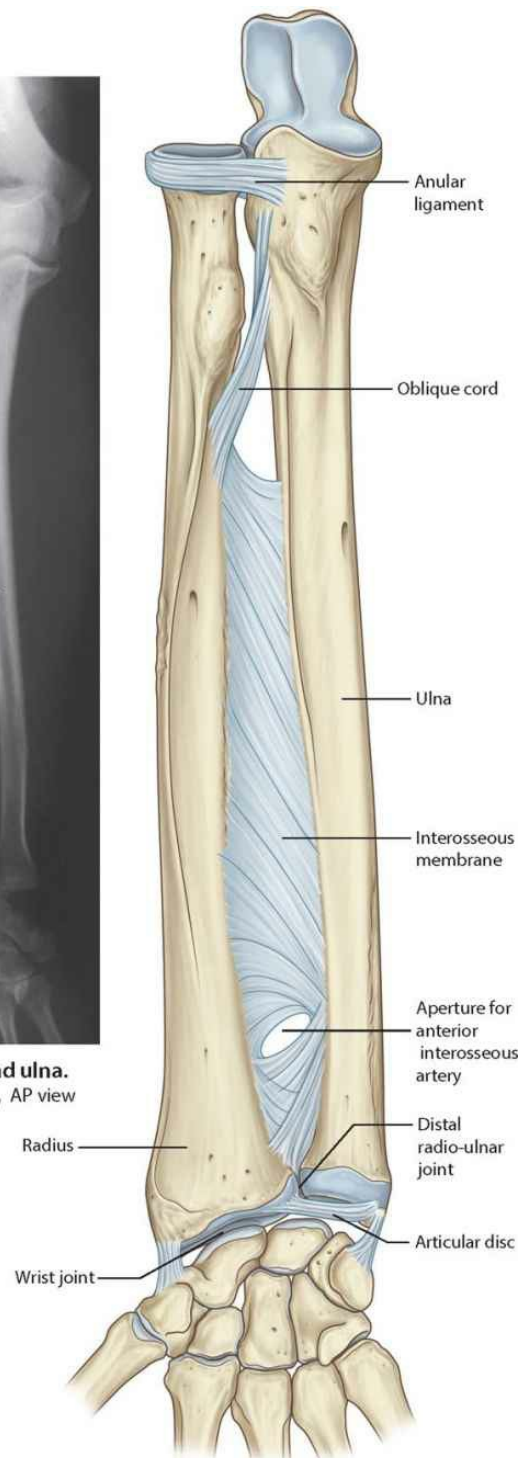


**Superficial structures**

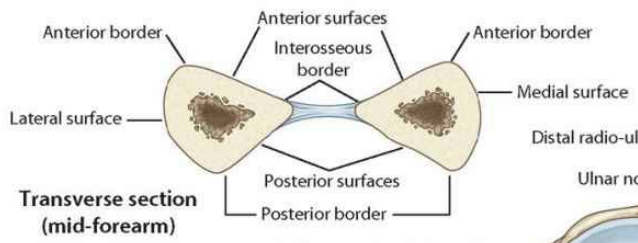
# Radius and ulna



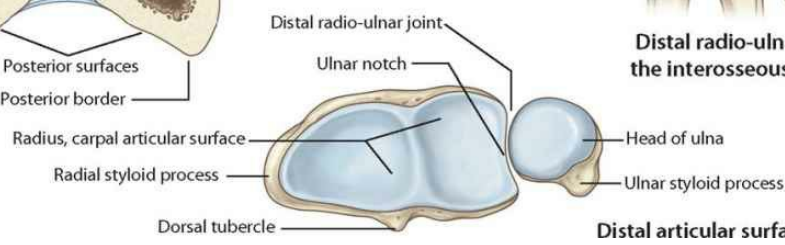
**Radius and ulna.**  
Radiograph, AP view



**Distal radio-ulnar joint and the interosseous membrane**

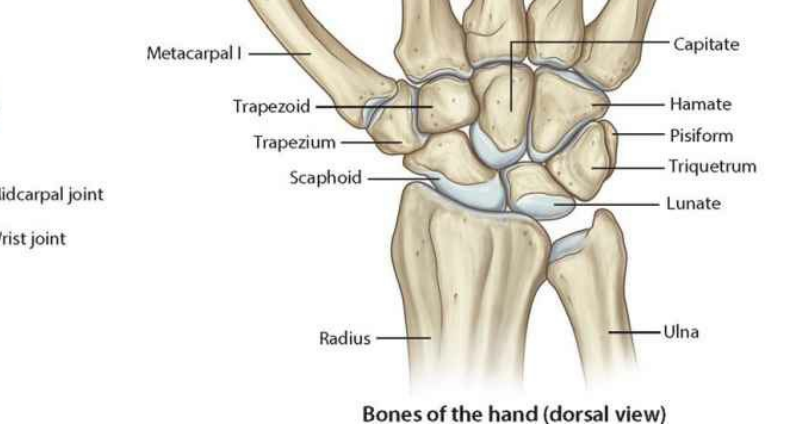
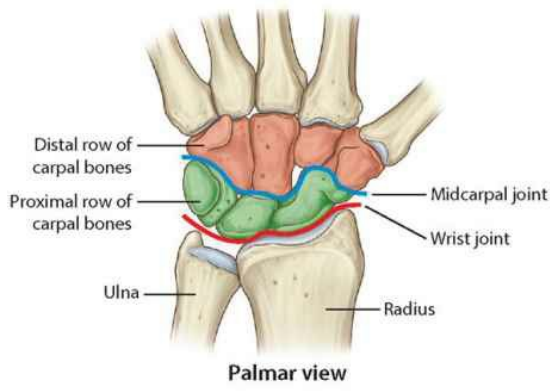
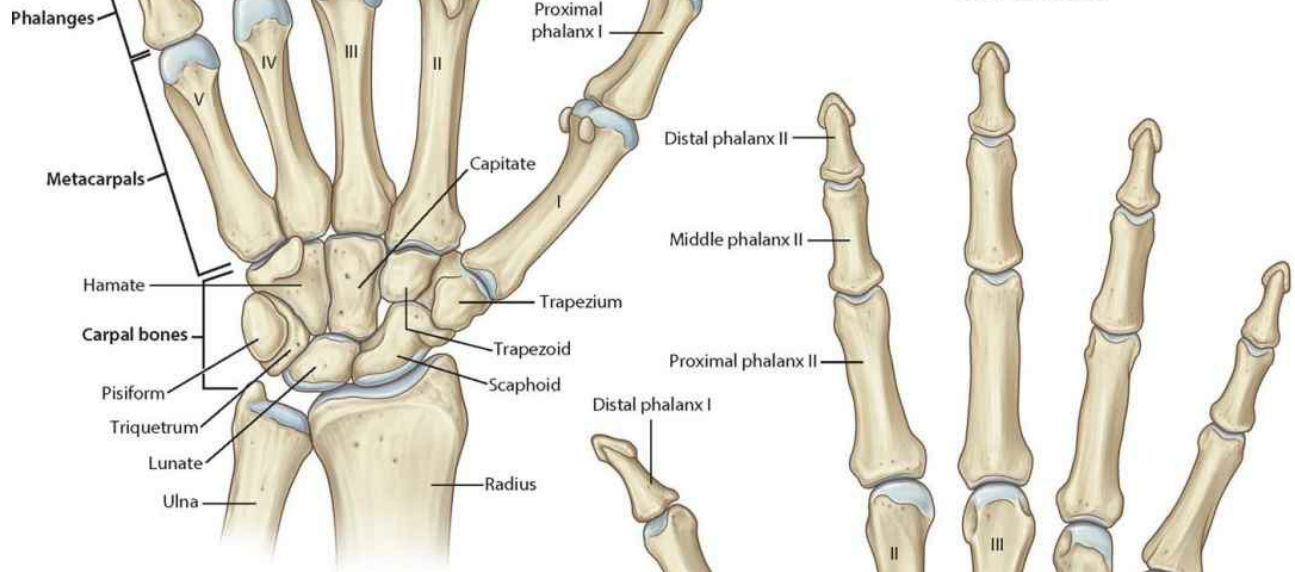
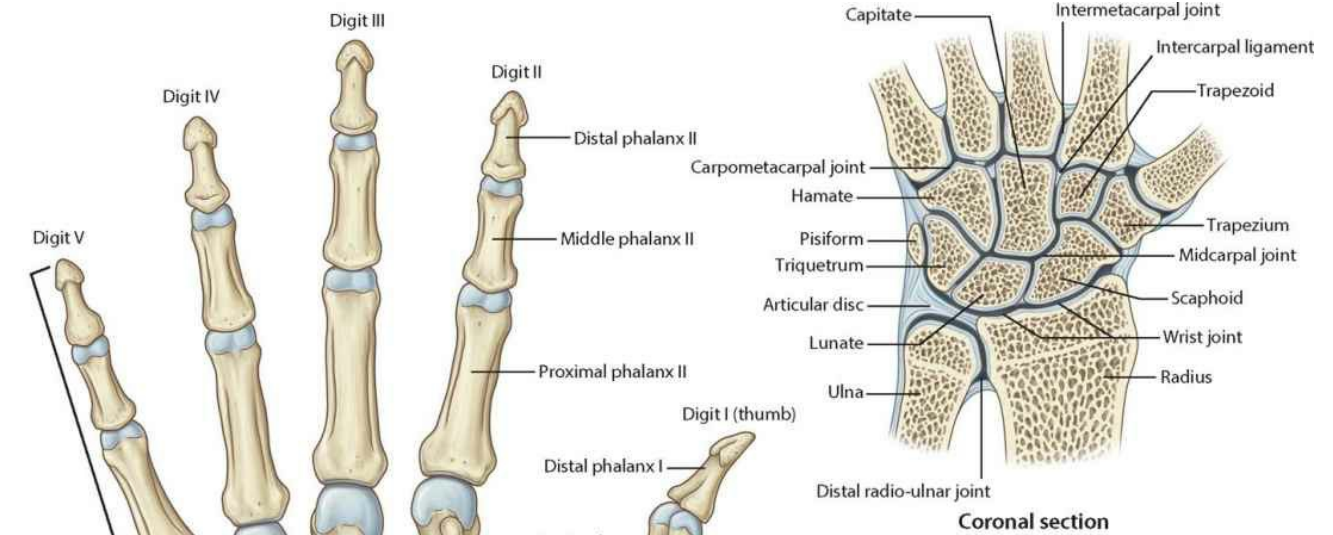


**Transverse section (mid-forearm)**



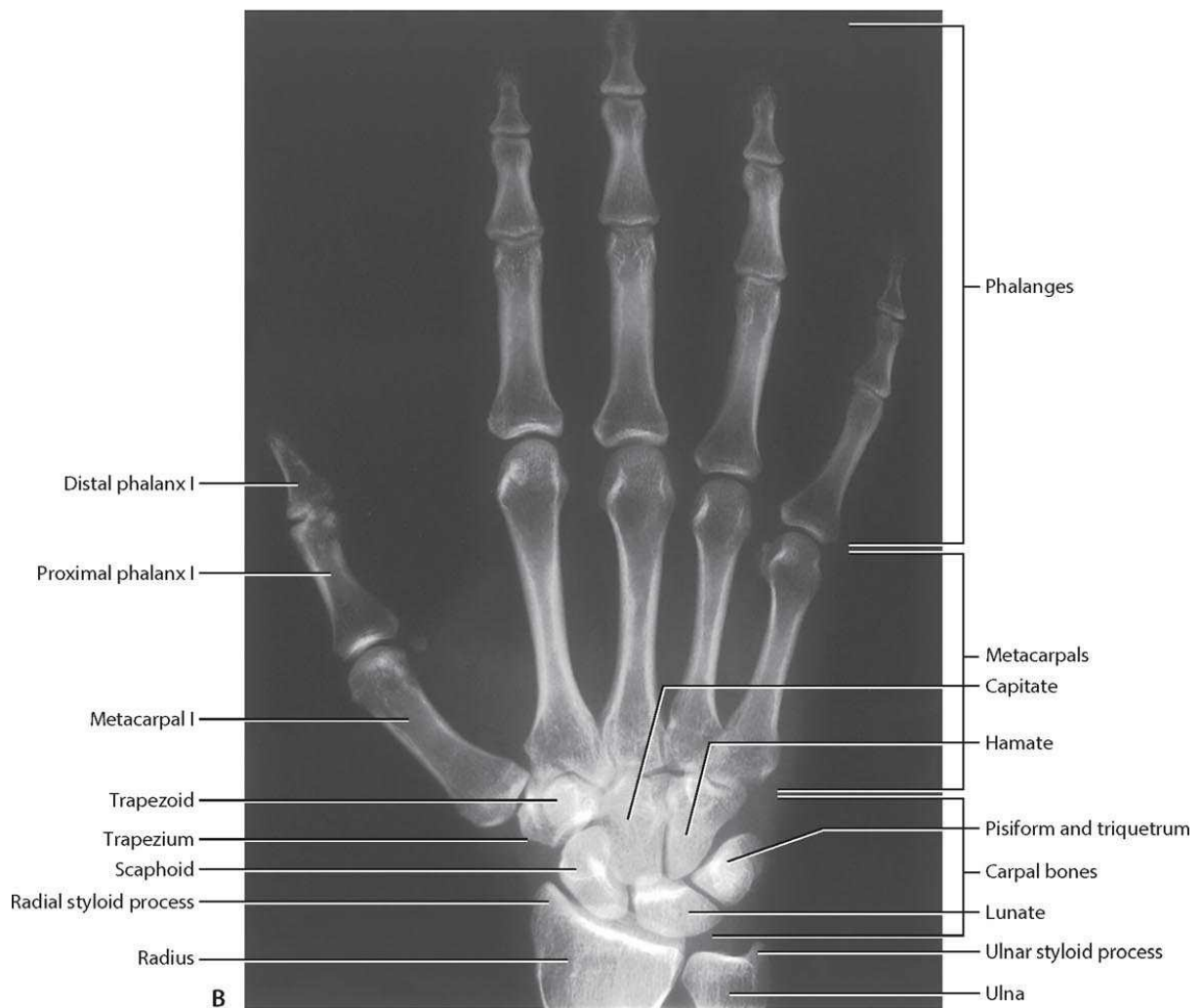
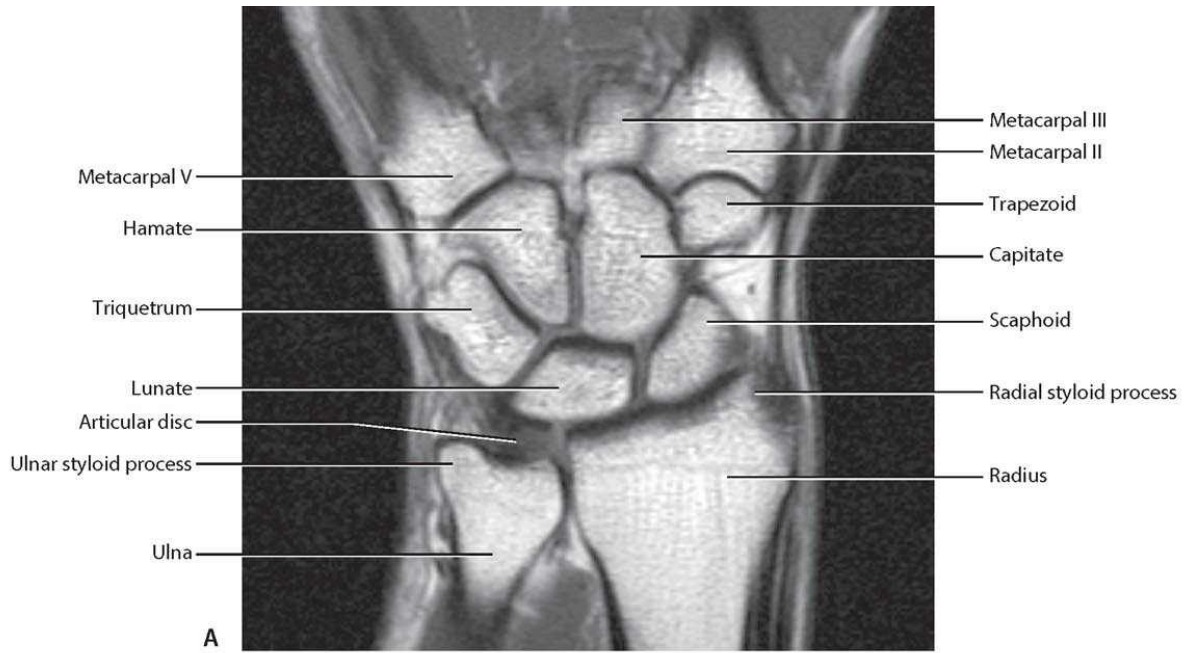**Distal articular surface**

# **Bones of the hand and wrist joint**





# Imaging of the hand and wrist joint



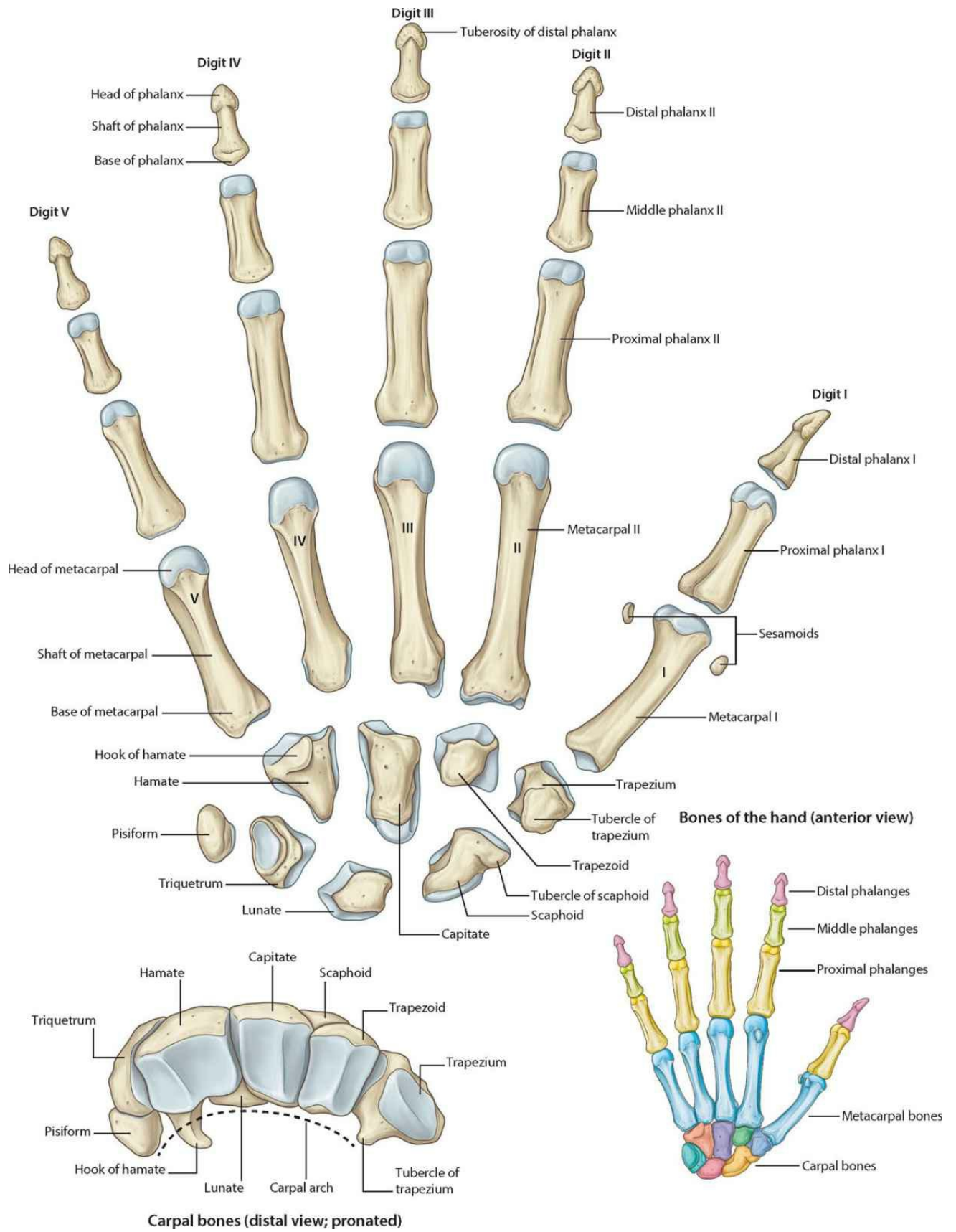
**Imaging of the wrist joint, the carpal bones, and the hand.**

A. T1-weighted MR image in coronal plane

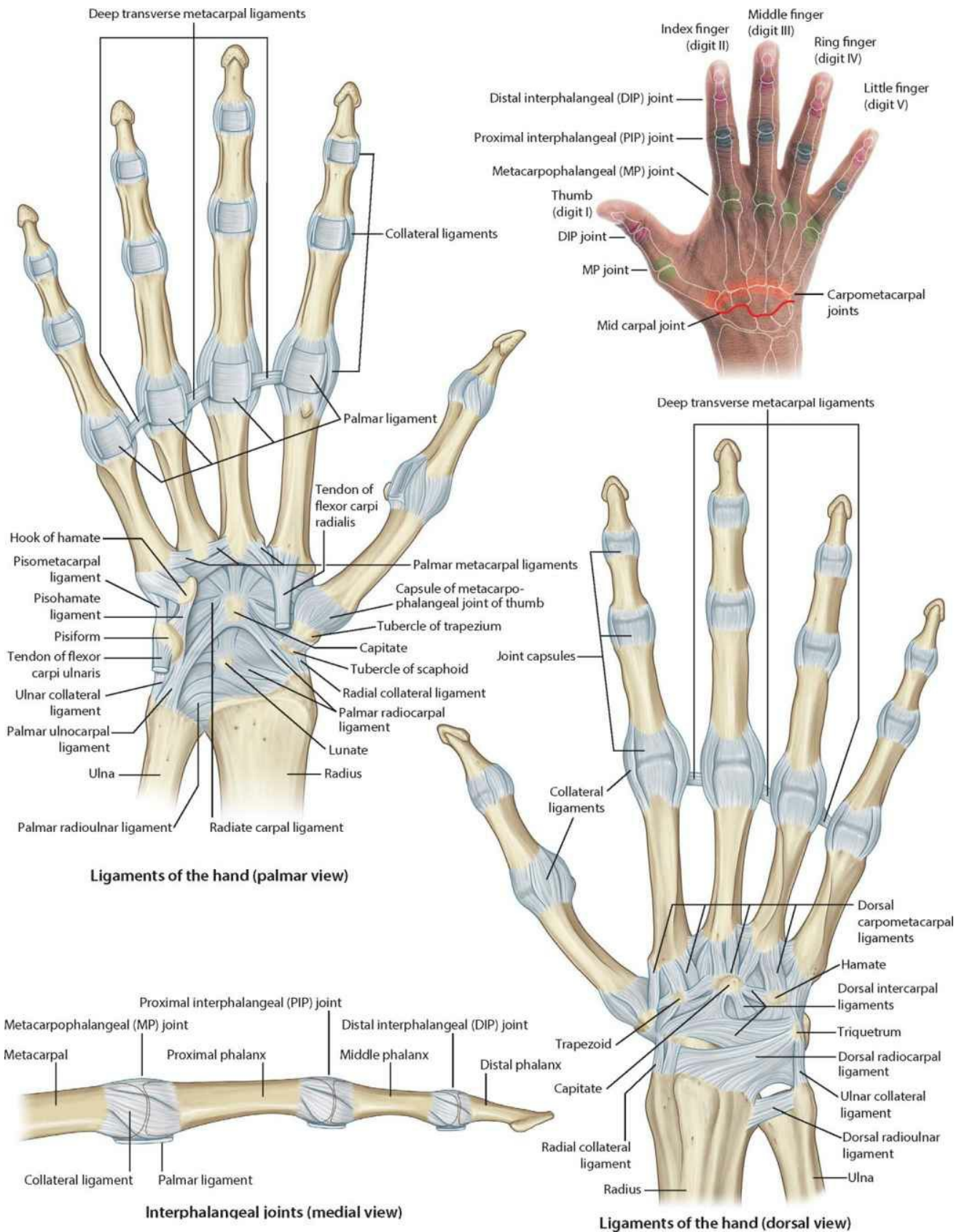
B. Radiograph, AP view



## **Bones of the hand**

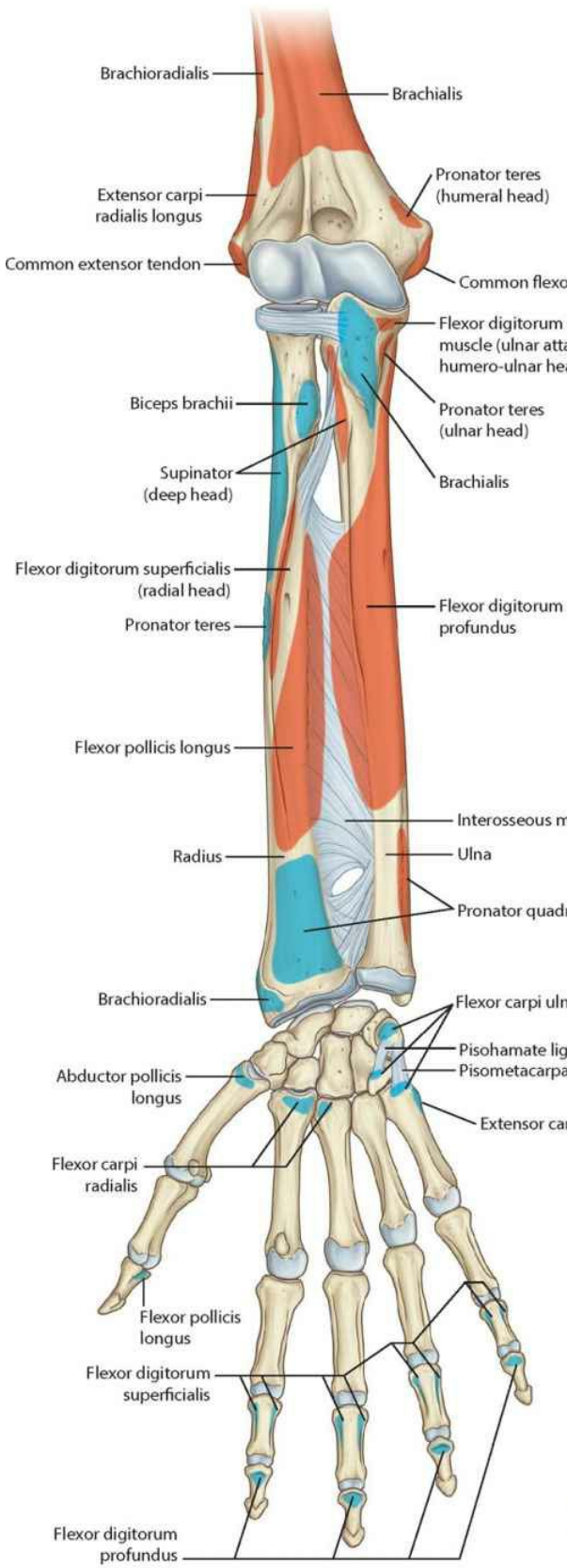


# **Joints and ligaments of the hand**

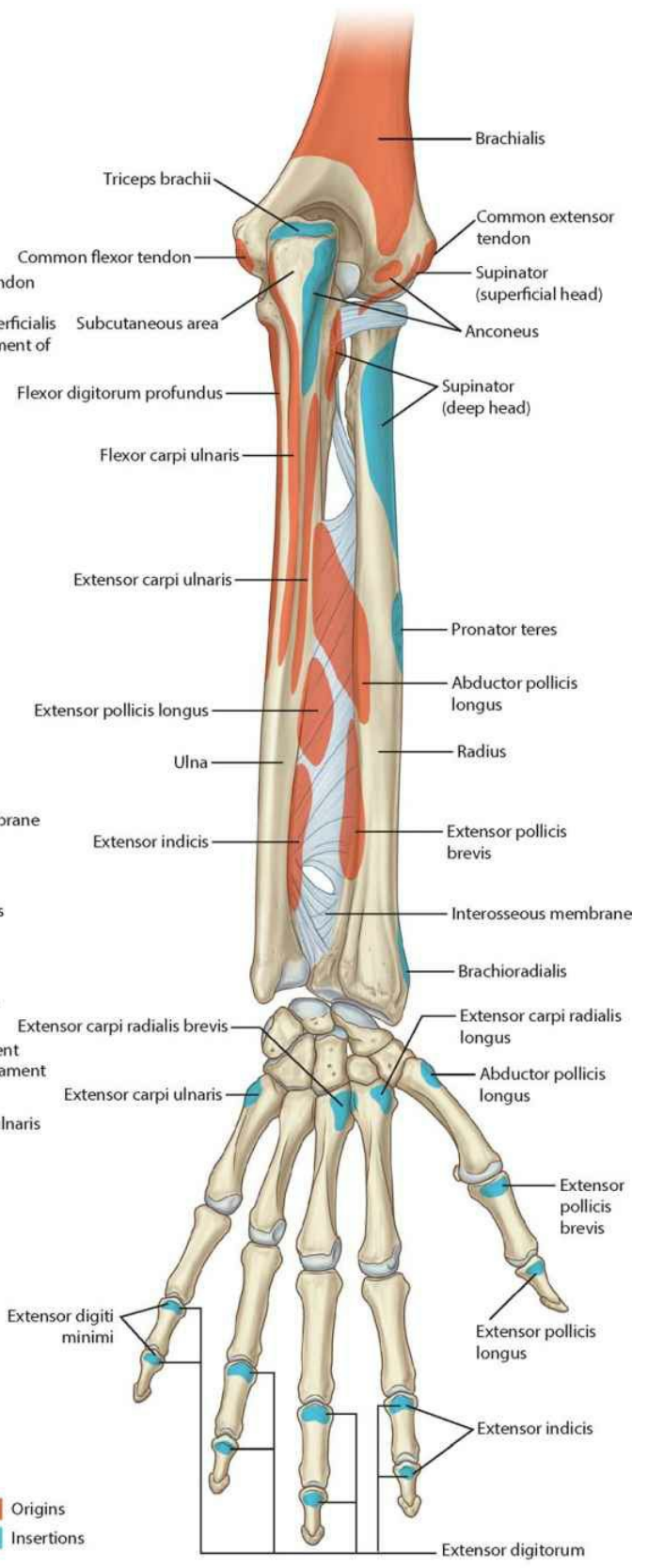


## **Muscle attachments of forearm**



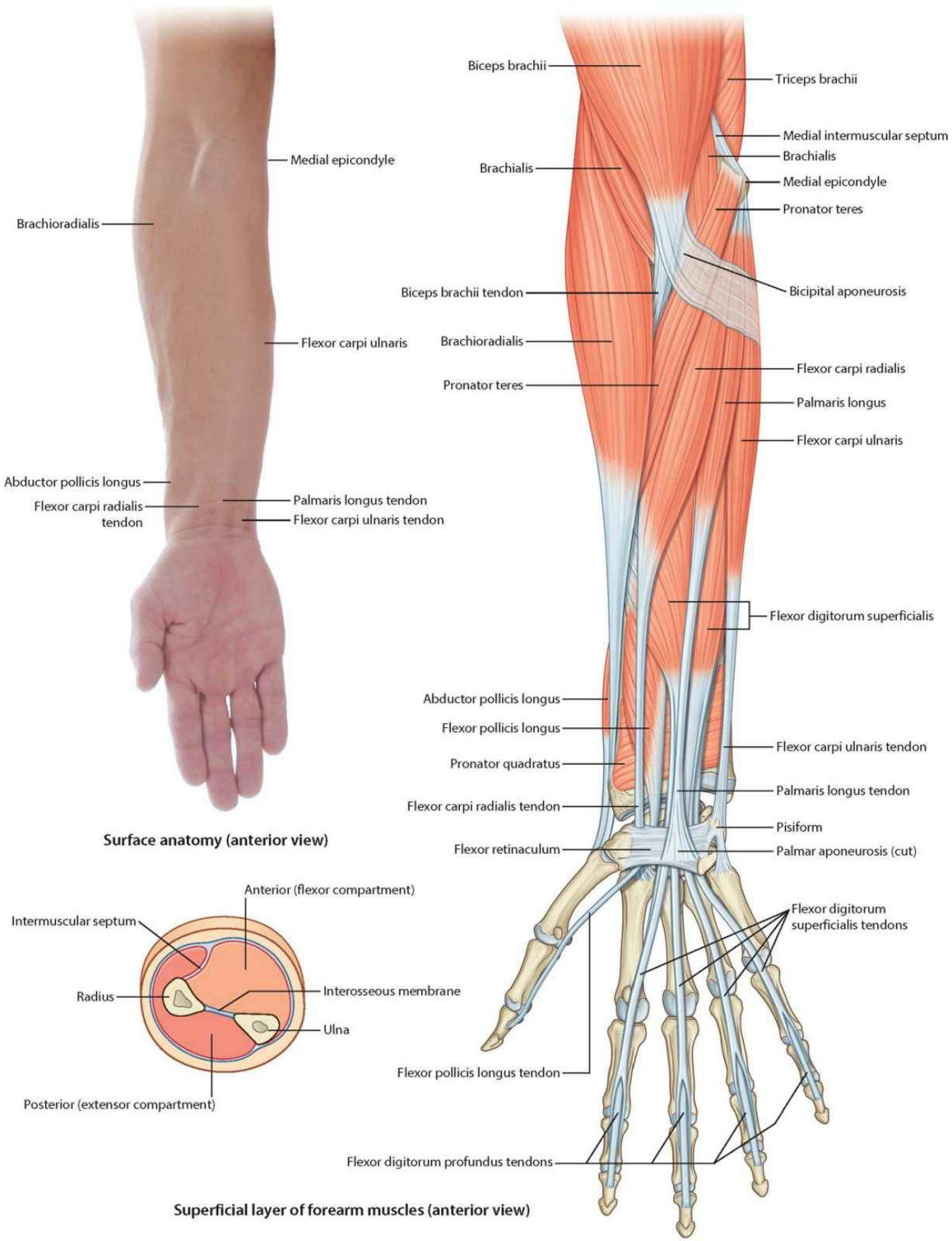


Muscle attachments of forearm (anterior view)

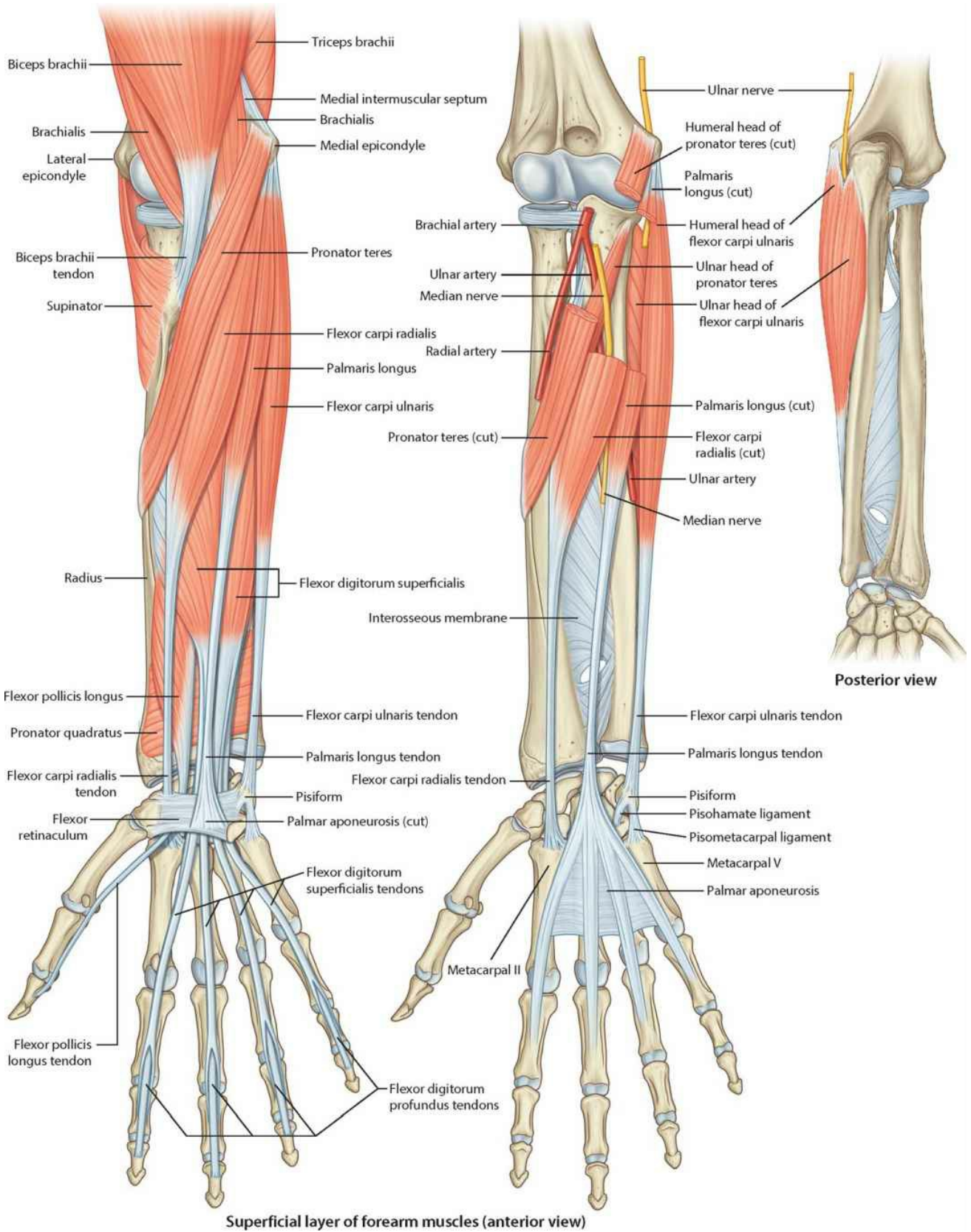


Muscle attachments of forearm (posterior view)

# **Anterior compartment of forearm: muscles**

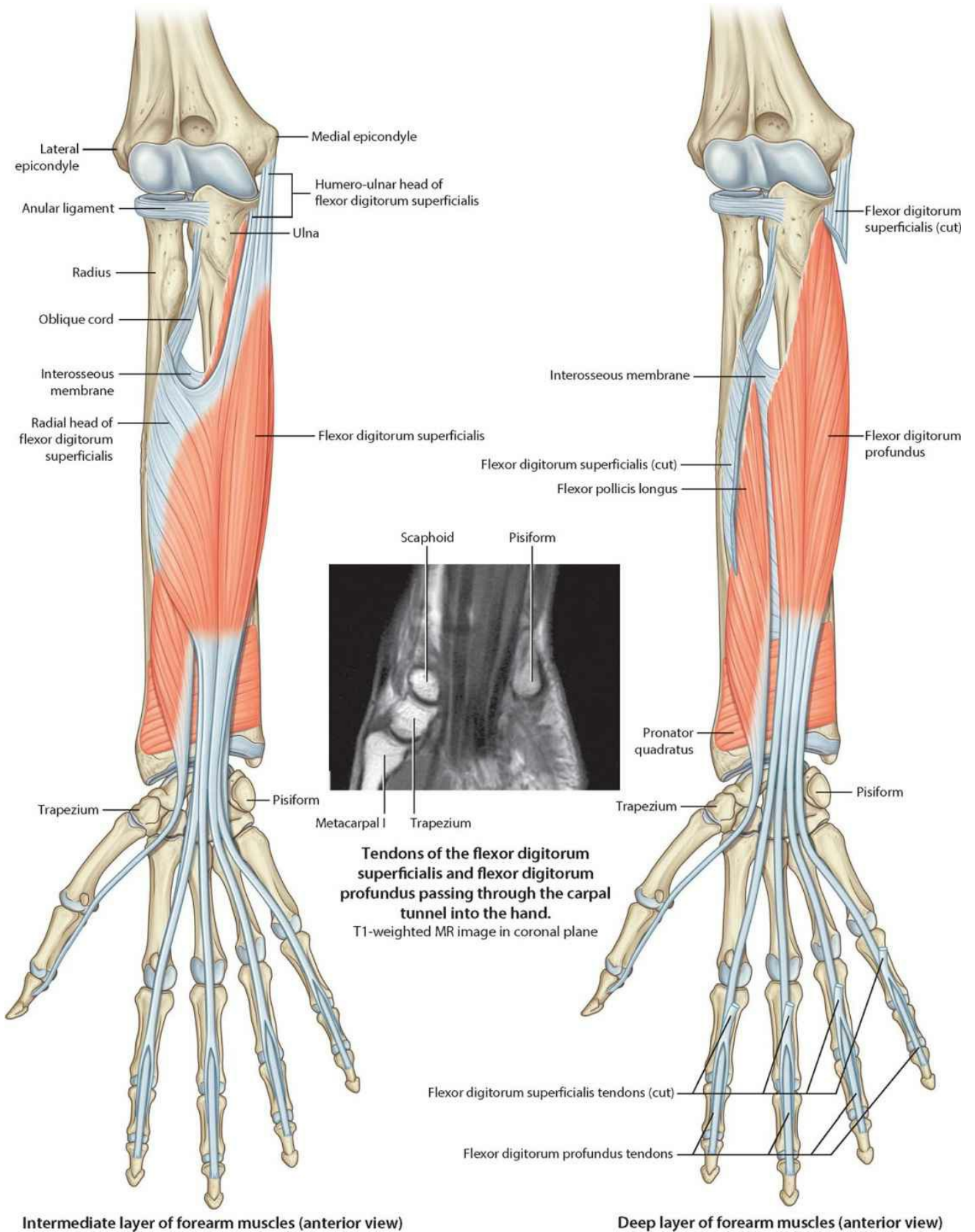






Superficial layer of forearm muscles (anterior view)



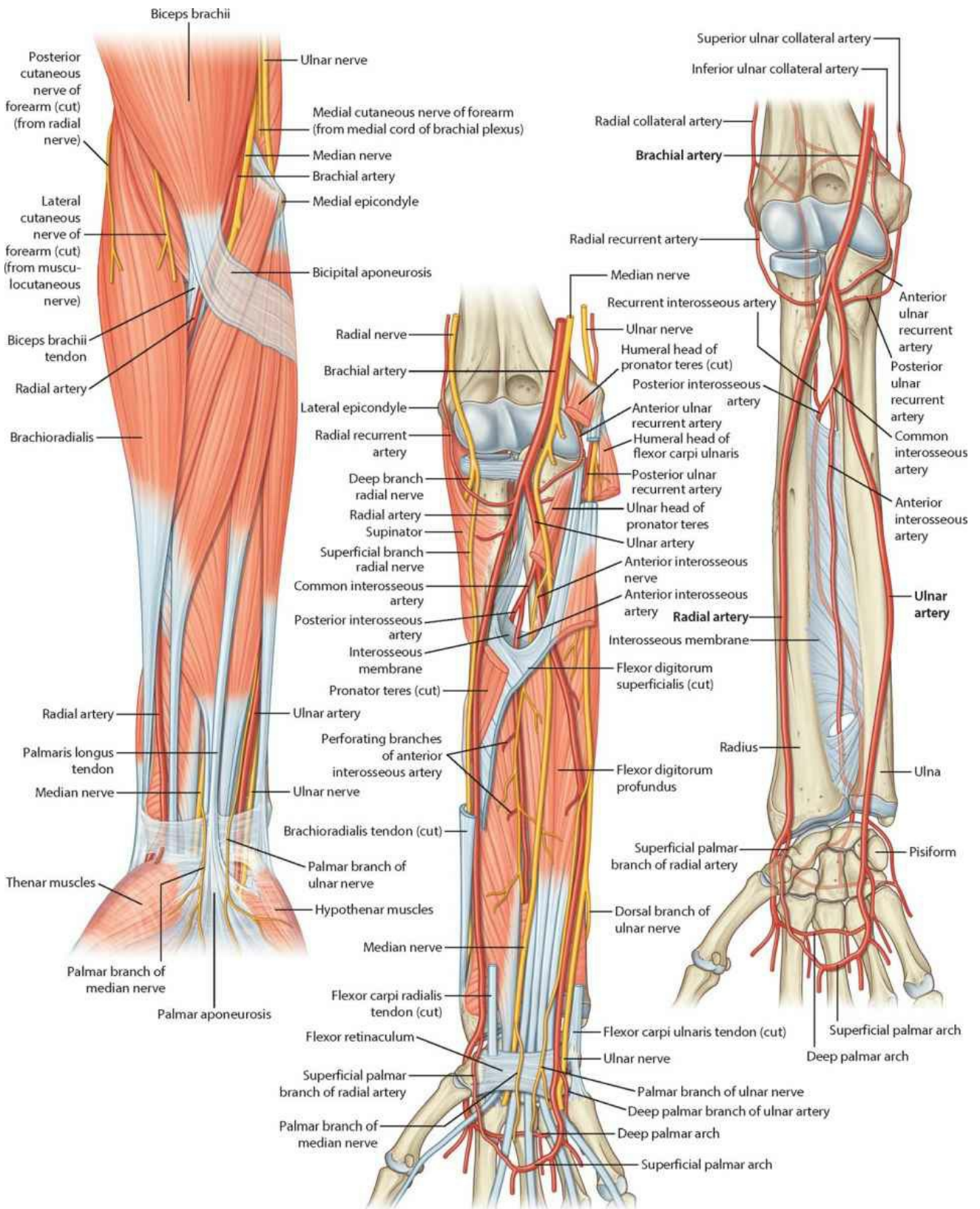


Intermediate layer of forearm muscles (anterior view)

Deep layer of forearm muscles (anterior view)

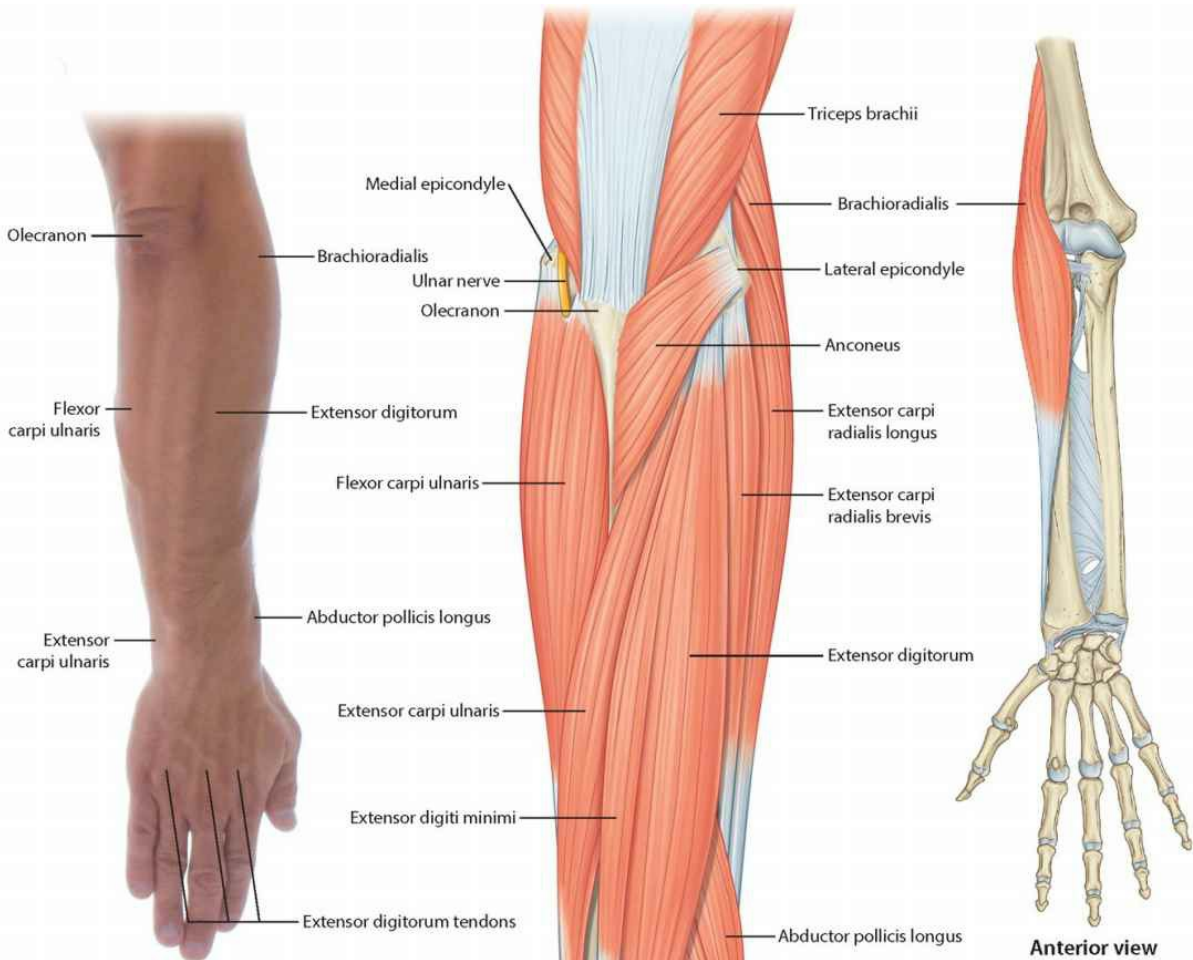
## **Anterior compartment of forearm: arteries and nerves**





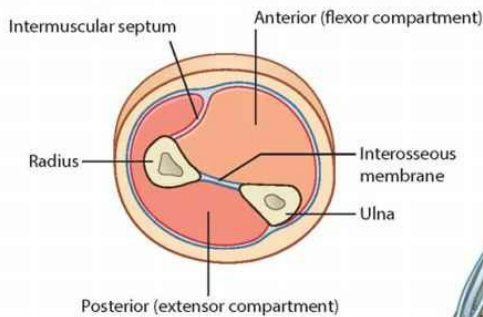
**Arteries and nerves of forearm (anterior view)**

# Posterior compartment of forearm: muscles

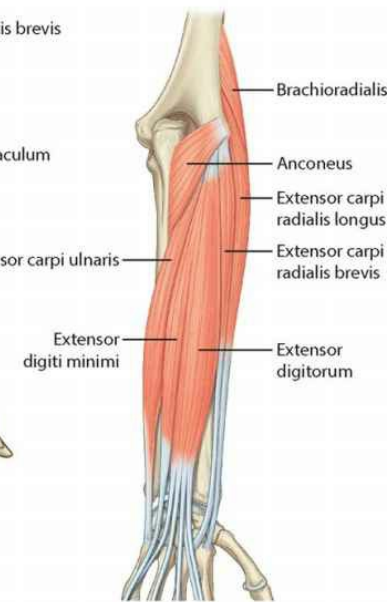


Surface anatomy (posterior view)

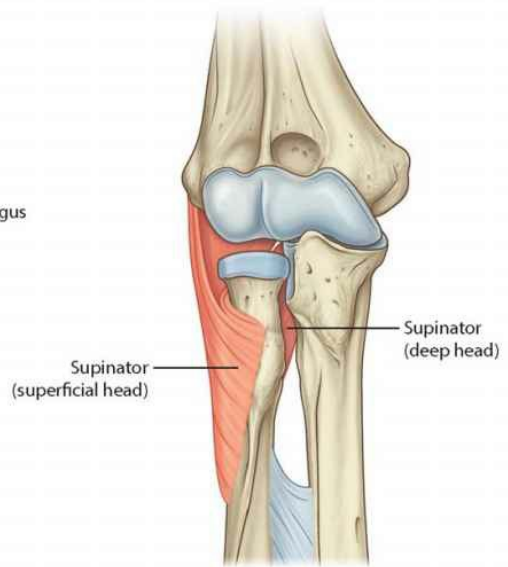
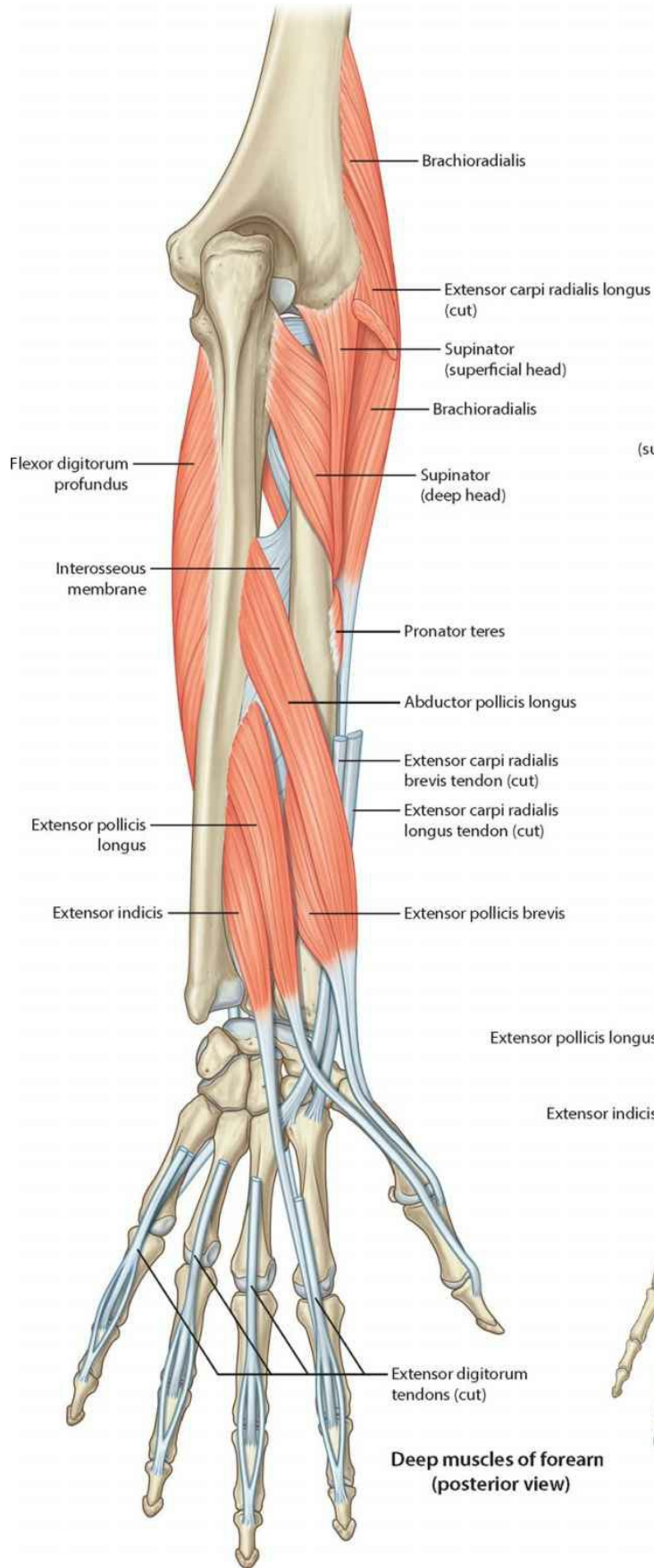
Anterior view



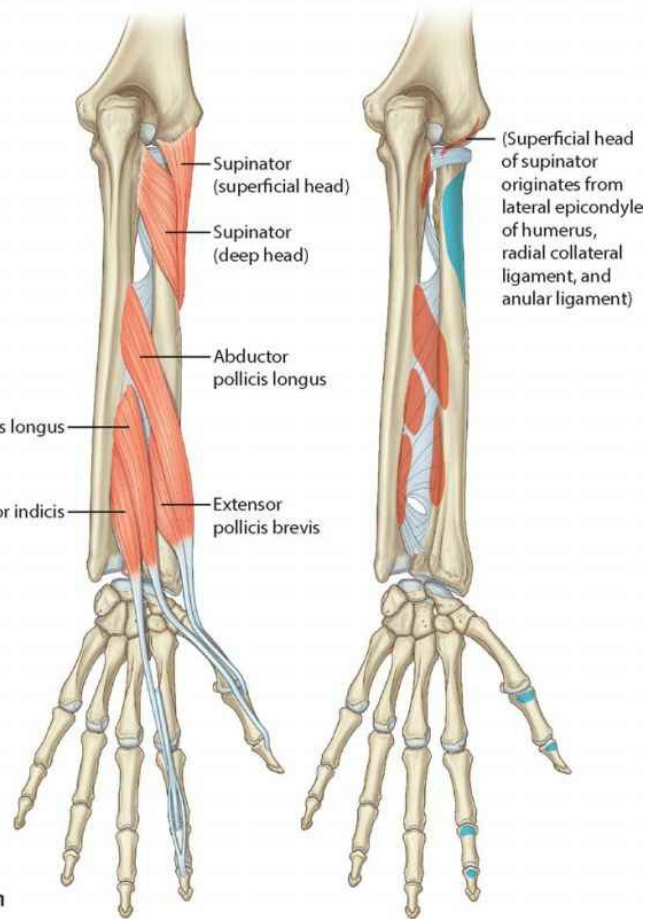
Superficial muscles of forearm (posterior view)



Superficial layer of muscles in the posterior compartment of forearm

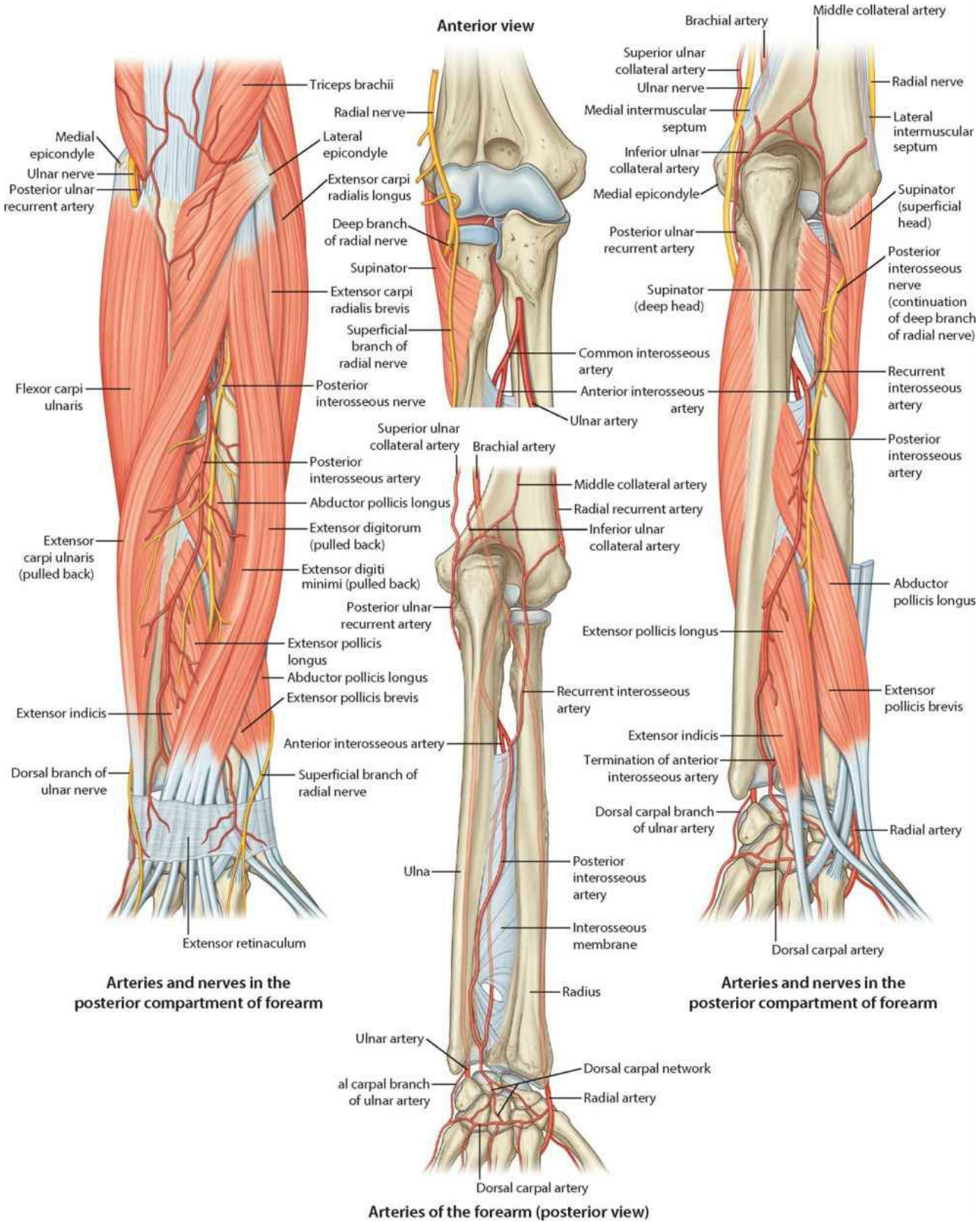


**Anterior view**

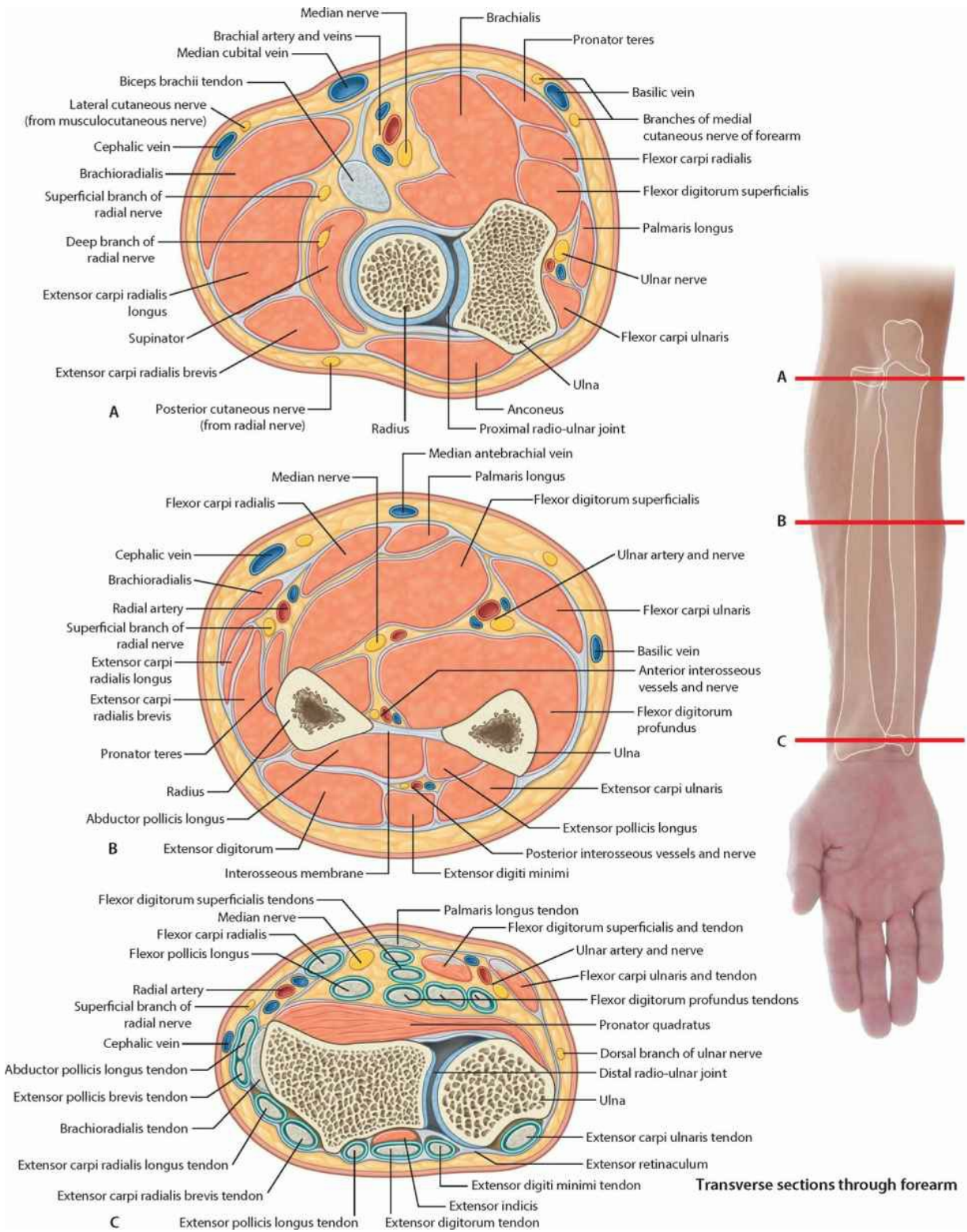


**Origin of deep layer of muscles in the posterior compartment of forearm**

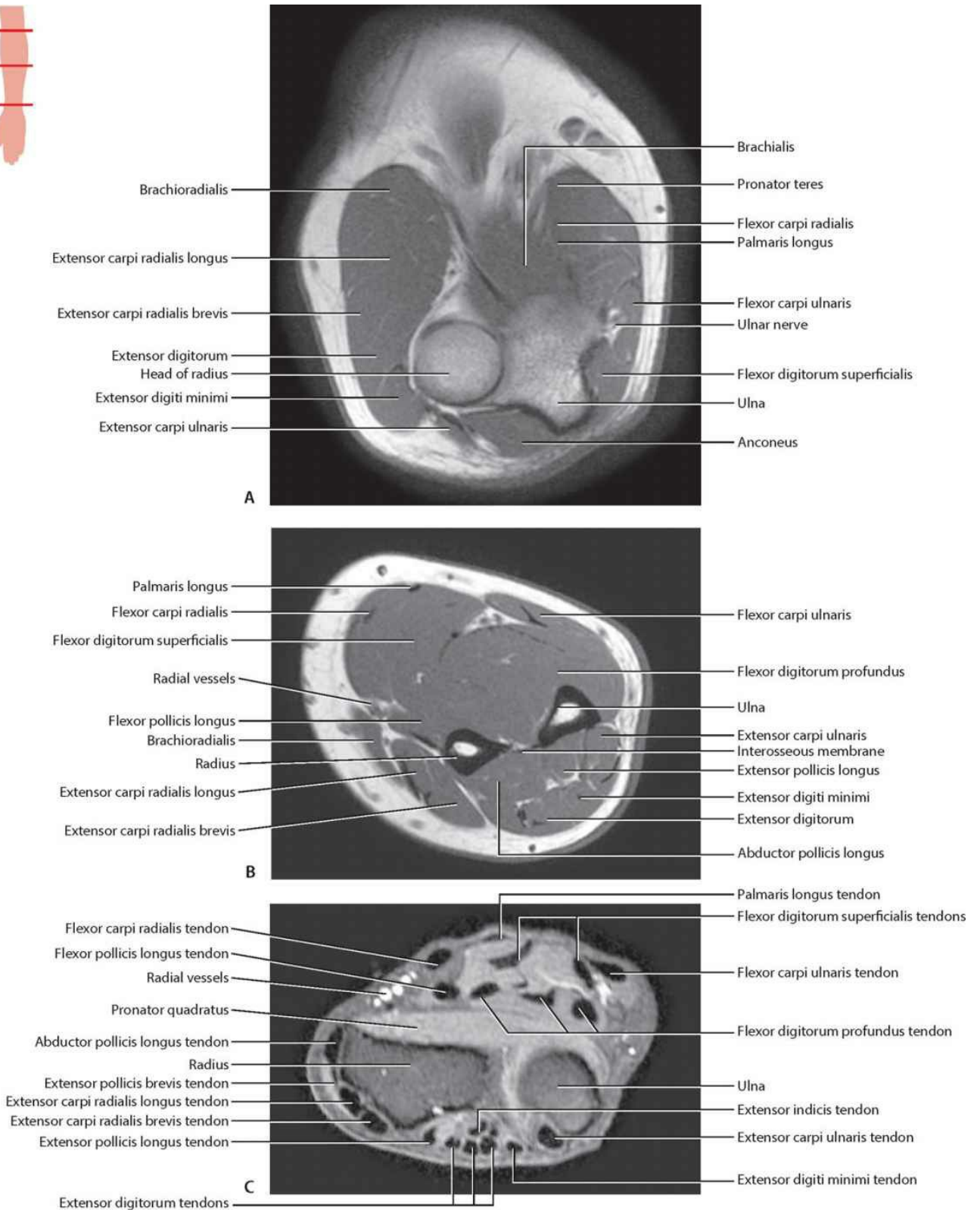
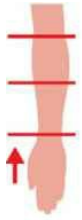
# Posterior compartment of forearm: arteries and nerves



## **Transverse sections: forearm**







**Transverse/axial sections through the forearm.**

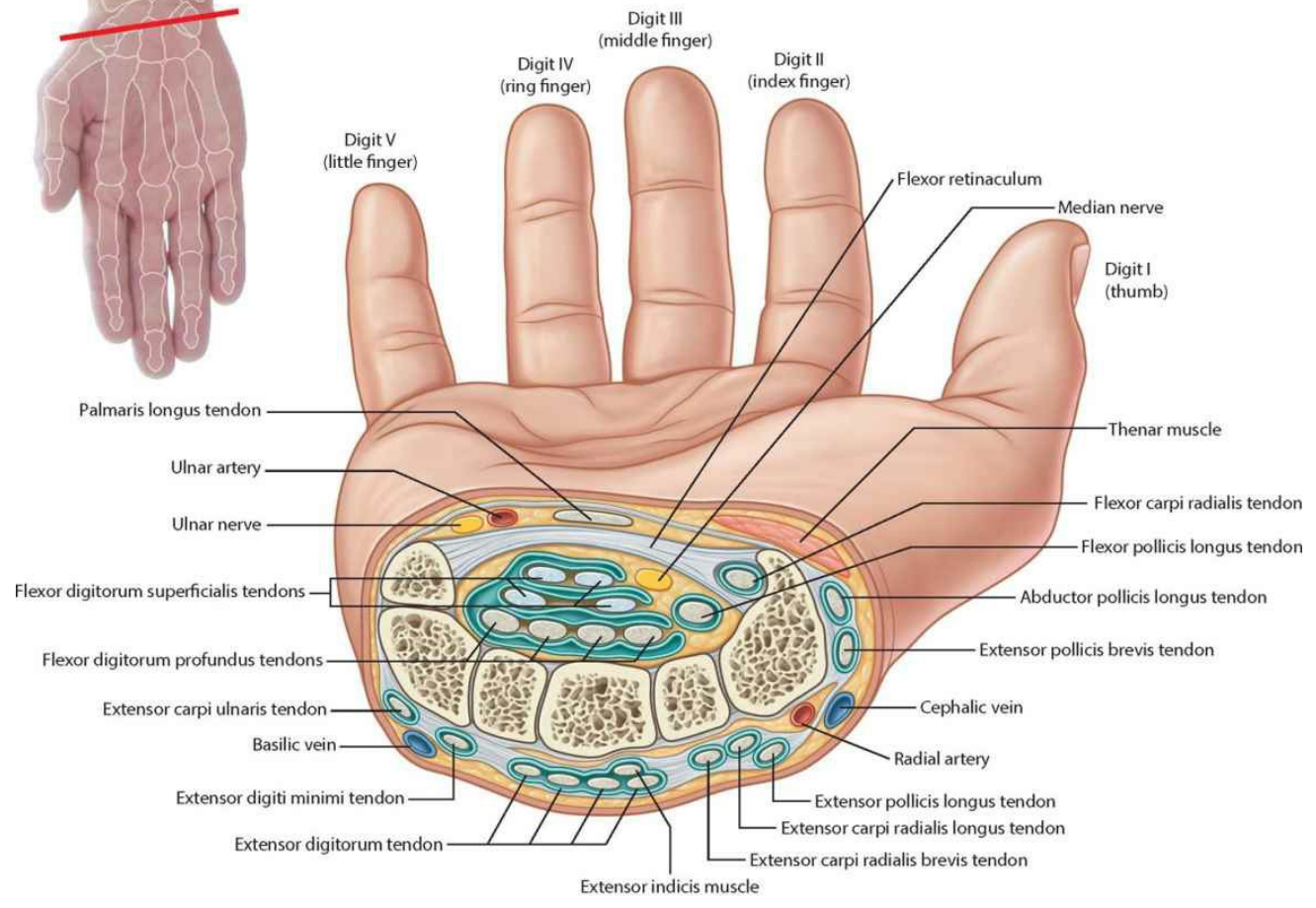
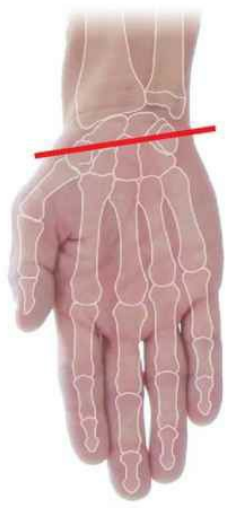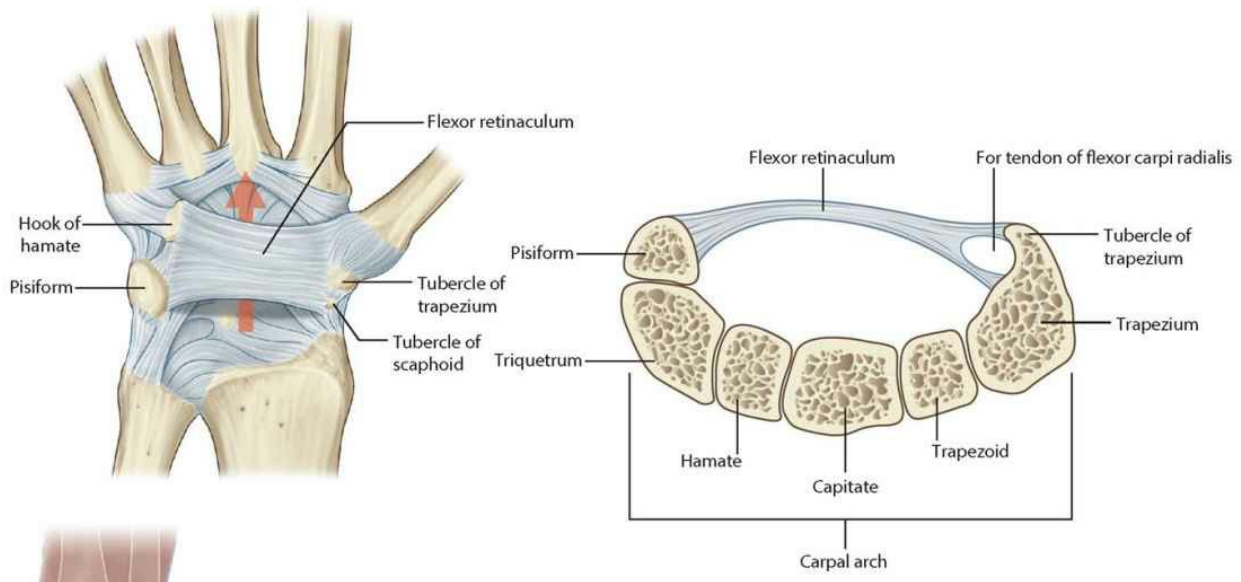
**A. Proximal/upper forearm.**

**B. Middle forearm.**

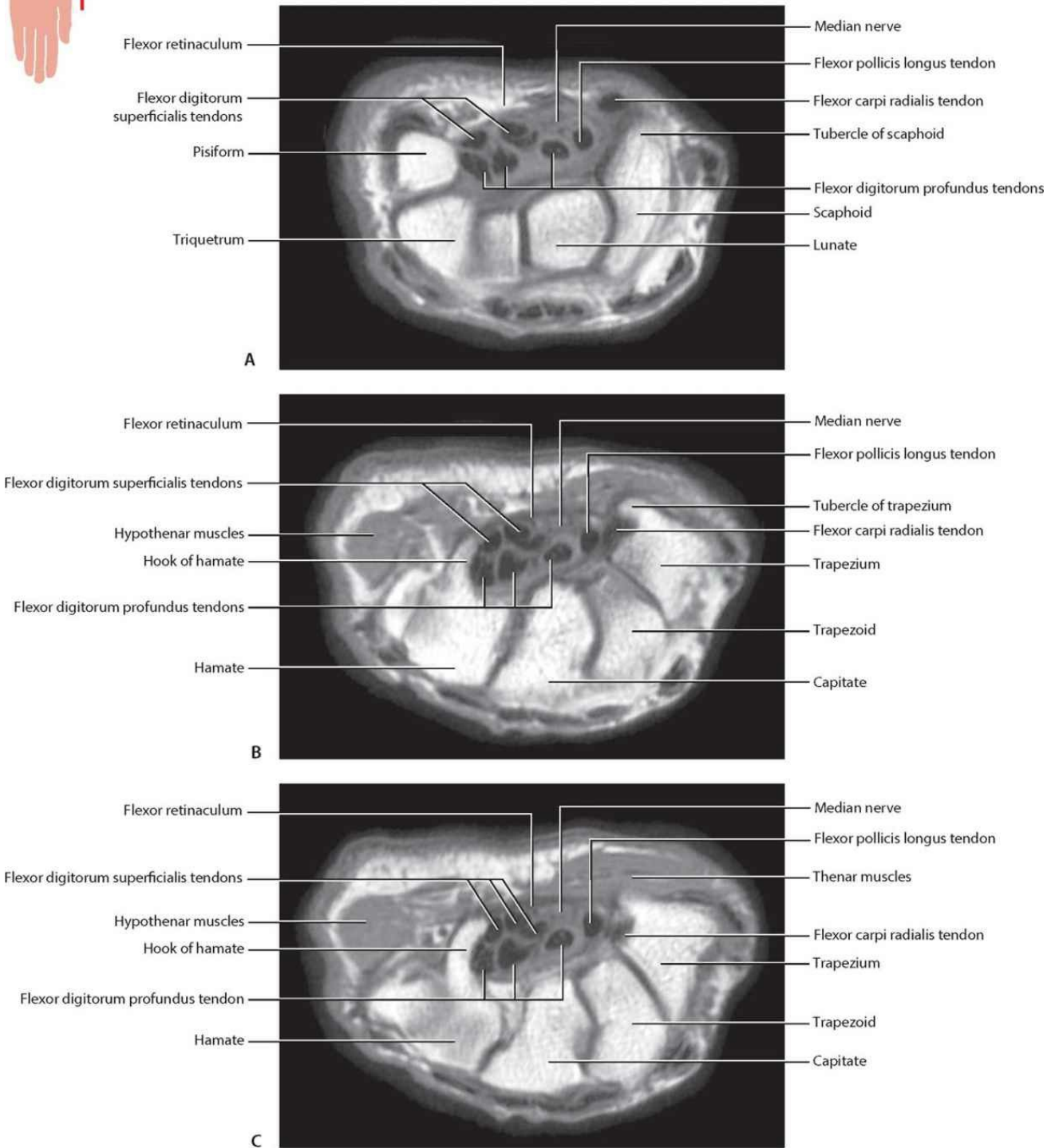
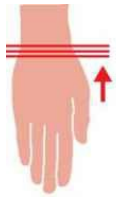
**C. Distal/lower forearm.**

T1-weighted MR image in axial plane

# Carpal tunnel



**Carpal tunnel, structures and relations**



**Transverse/axial sections through the carpal tunnel.**

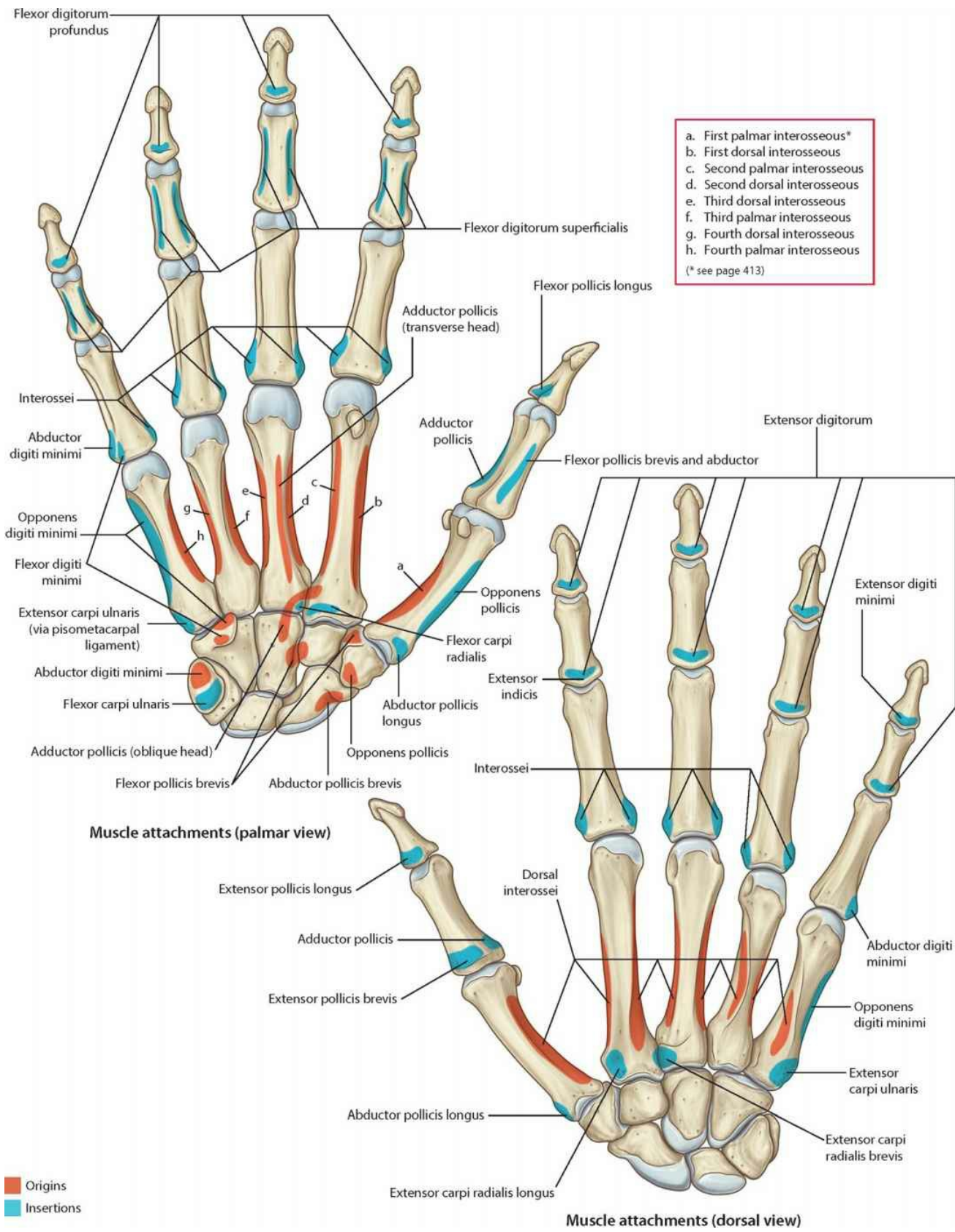
**A. Proximal end of carpal tunnel.**

**B. Middle portion of carpal tunnel.**

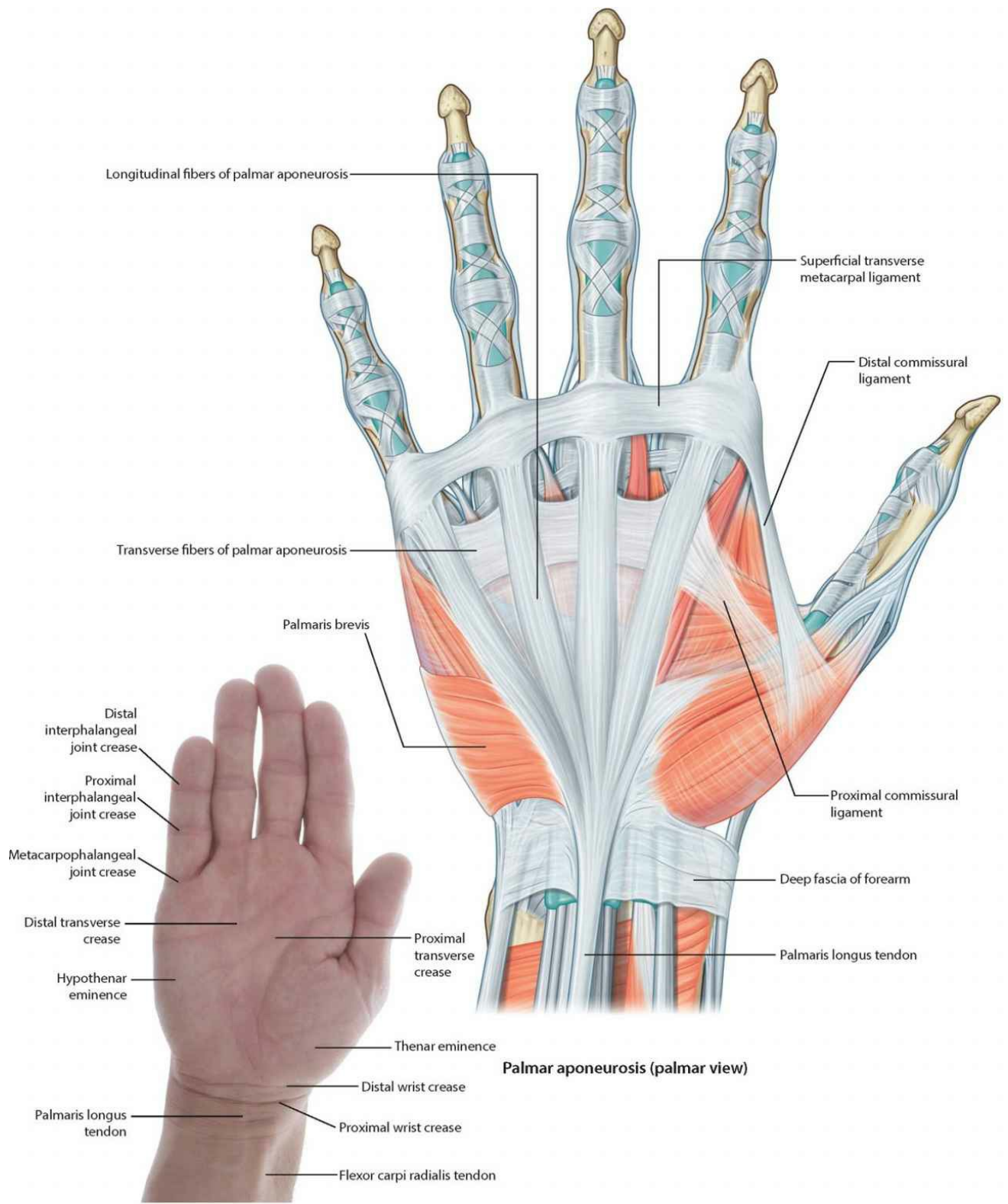
**C. Distal portion of carpal tunnel.**

T1-weighted MR images in axial plane

## **Muscle attachments of the hand**



# Superficial palmar region (palm) of hand

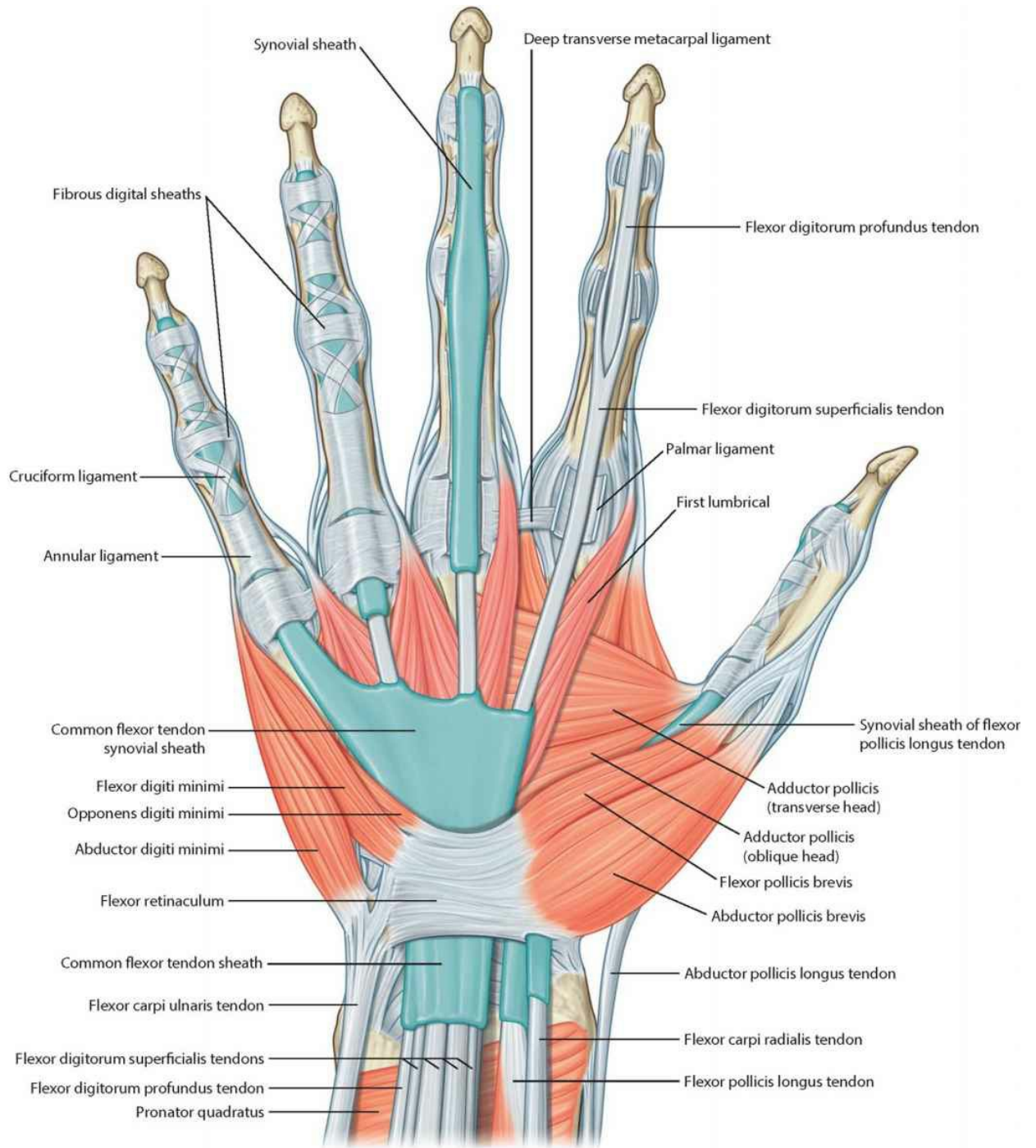


**Palmar aponeurosis (palmar view)**

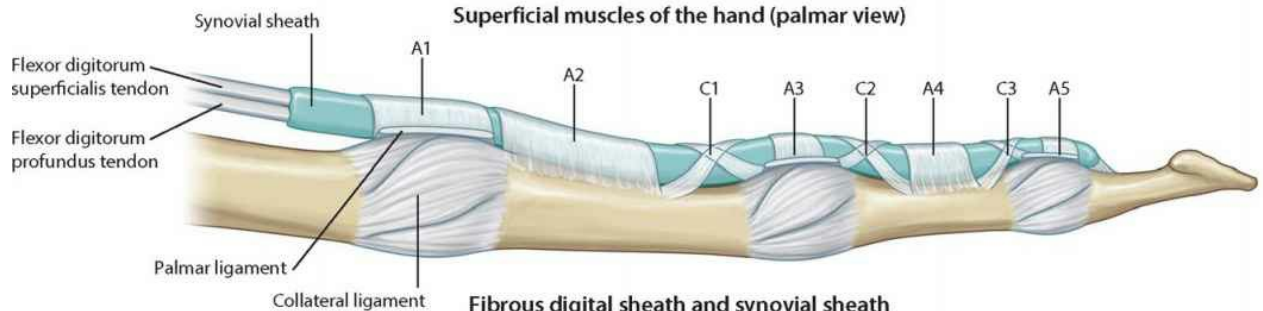
**Surface anatomy (palmar view)**



# Tendon sheaths of hand

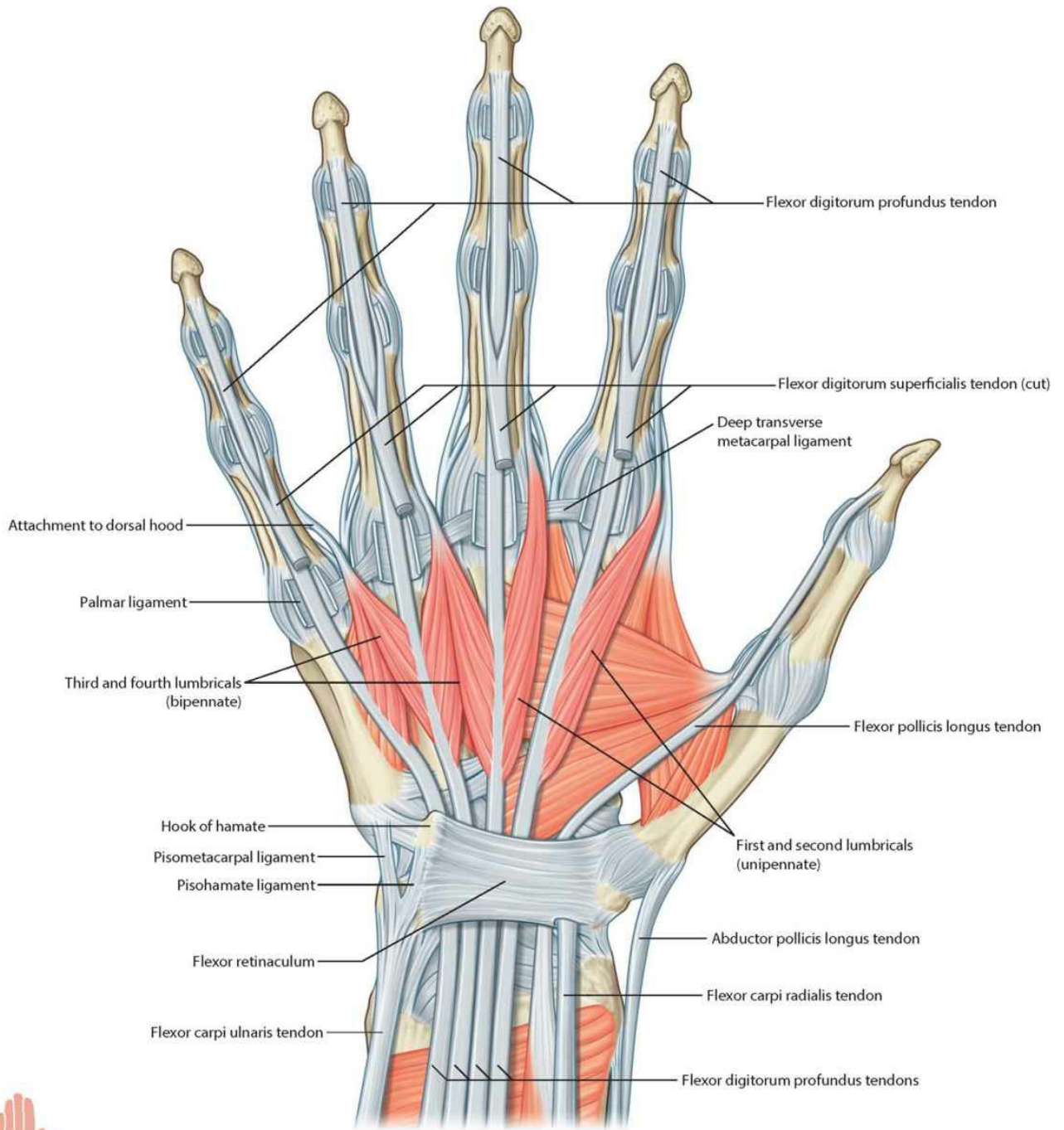


**Superficial muscles of the hand (palmar view)**

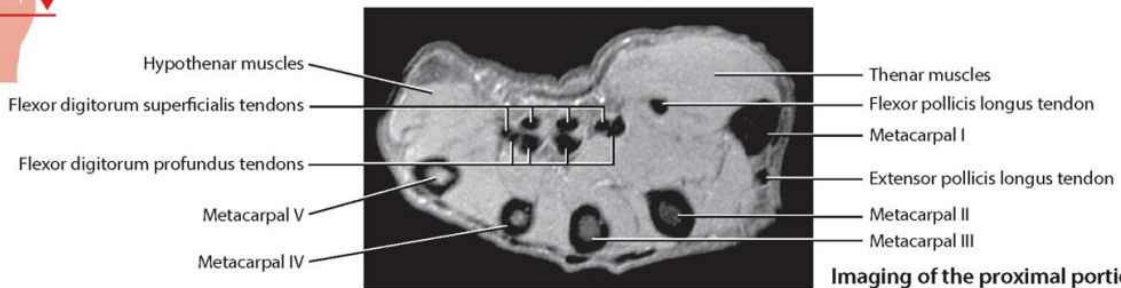
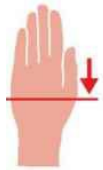


**Fibrous digital sheath and synovial sheath**  
Annular ligaments (A), cruciform ligaments (C)

# Lumbrical muscles

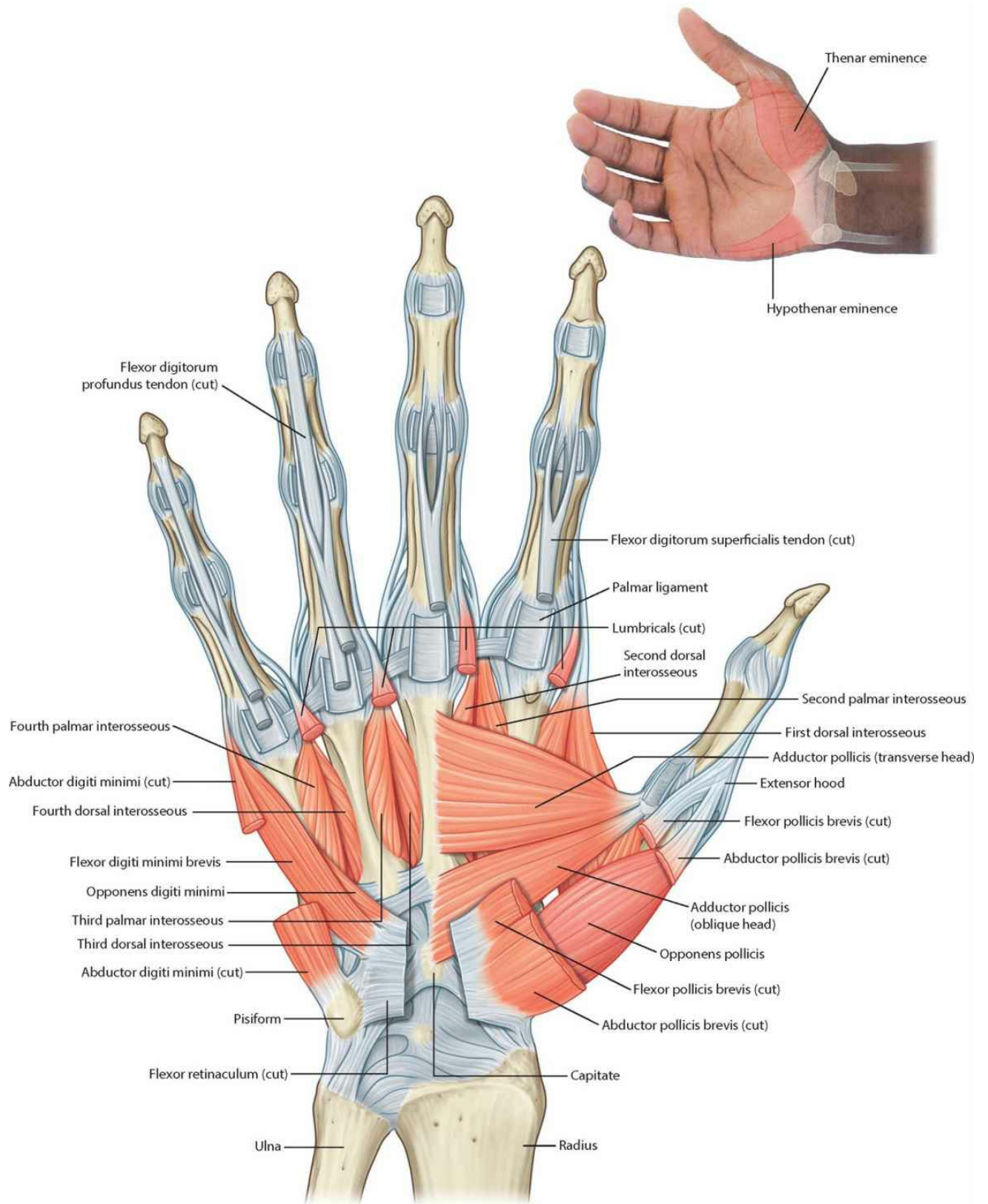


**Lumbrical muscles (palmar view)**



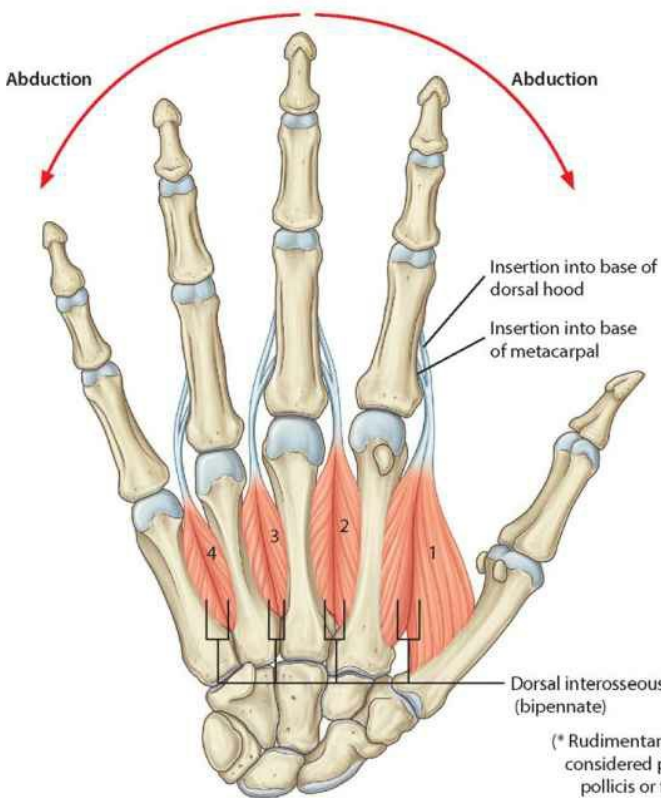
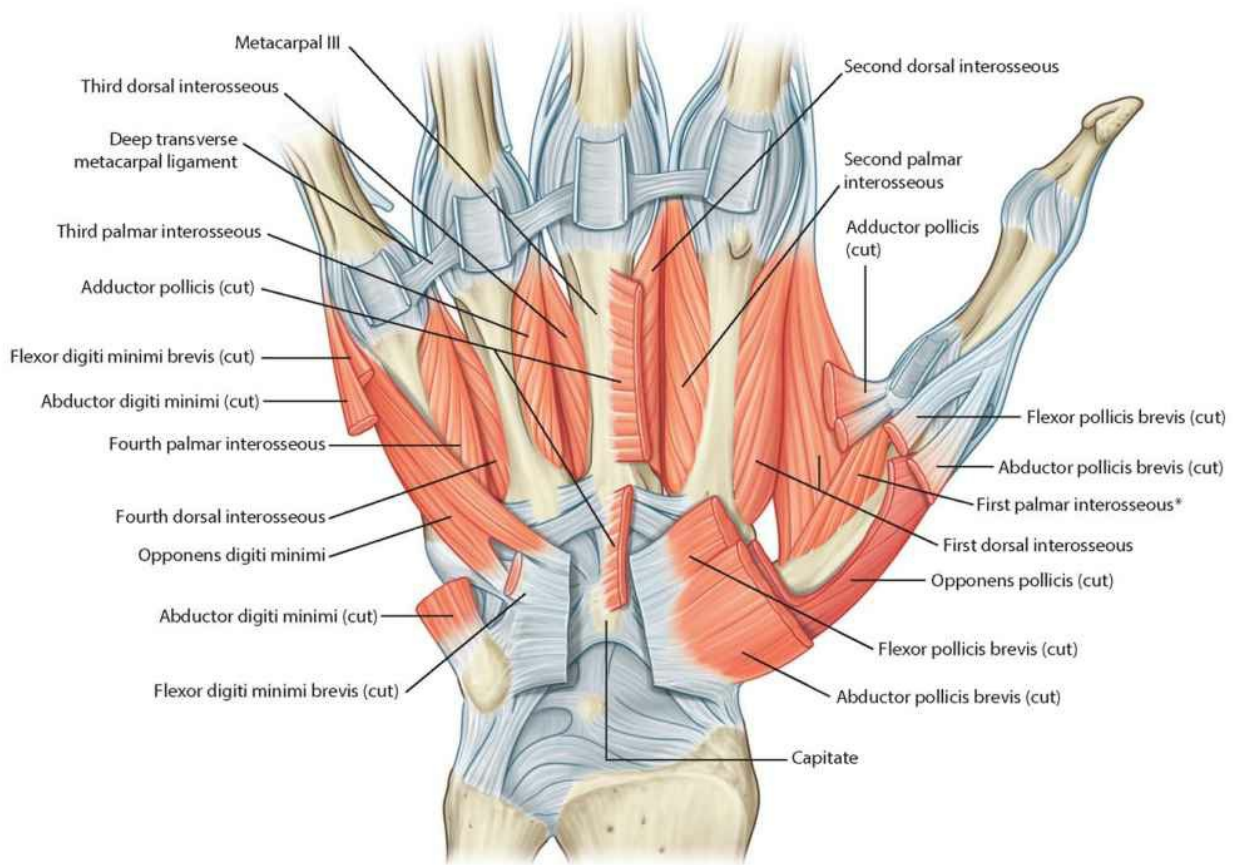
**Imaging of the proximal portion of the hand.**  
T1-weighted MR image in axial plane

# Intrinsic muscles of hand

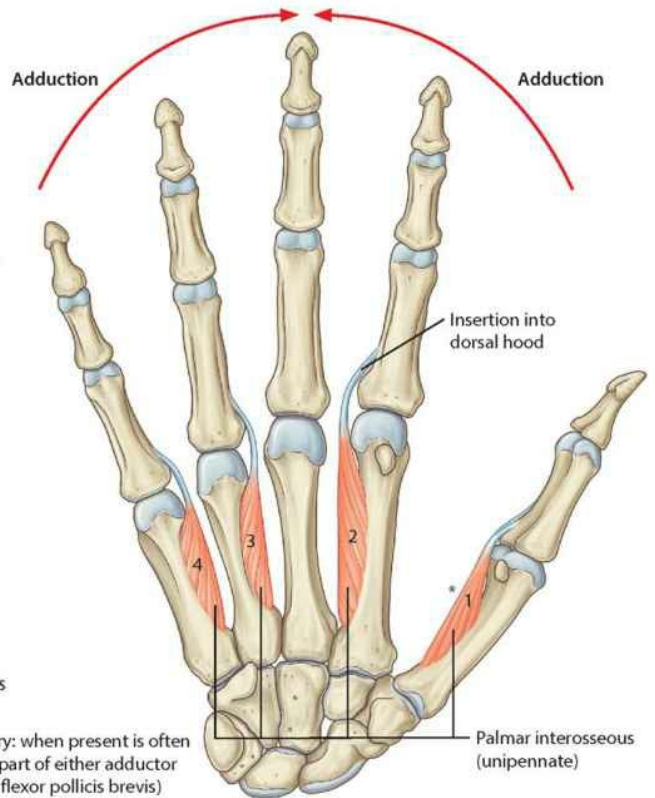


Deep muscles of the hand (palmar view)





Dorsal interossei (palmar view)

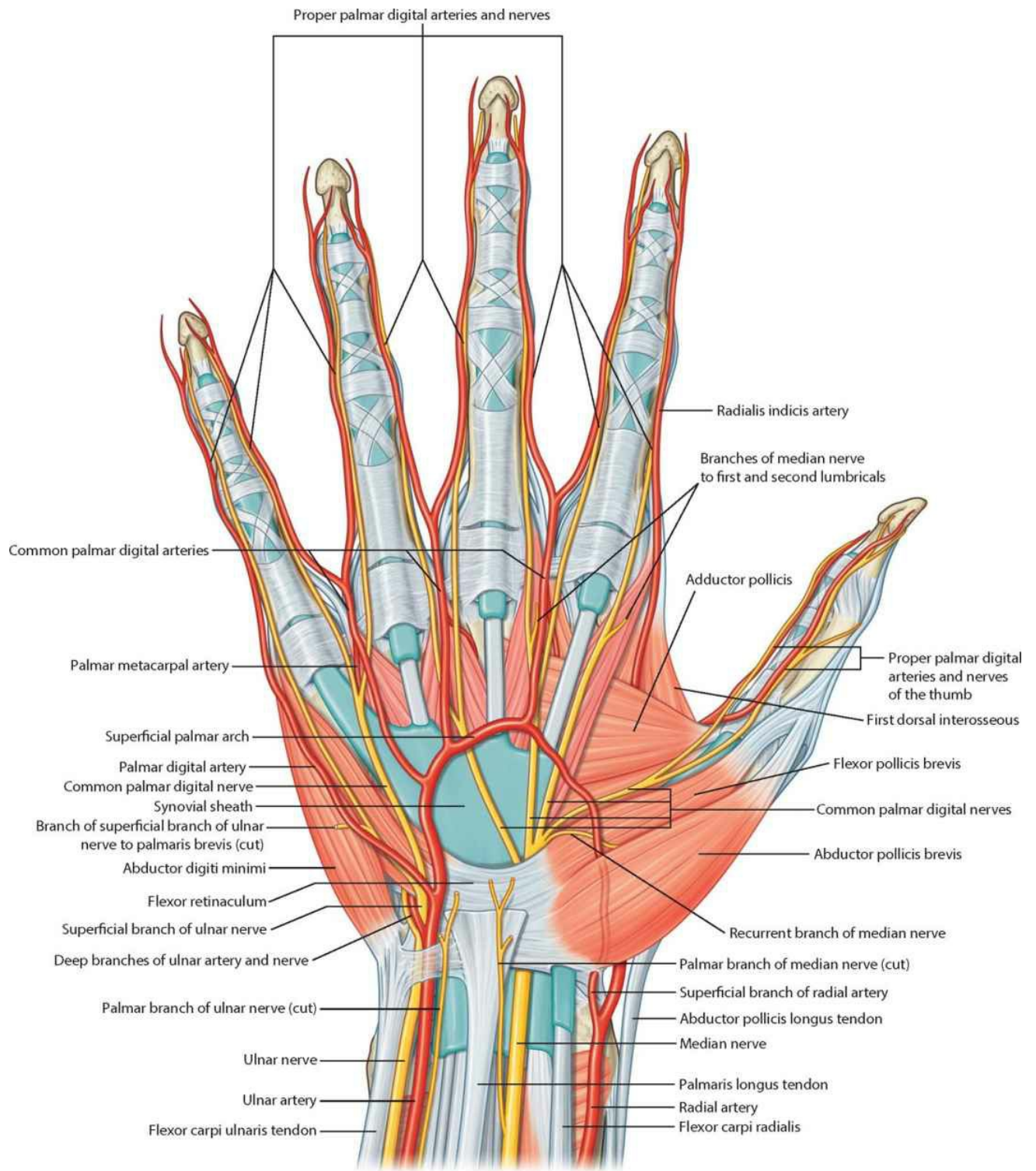


Palmar interossei (palmar view)

(\* Rudimentary: when present is often considered part of either adductor pollicis or flexor pollicis brevis)

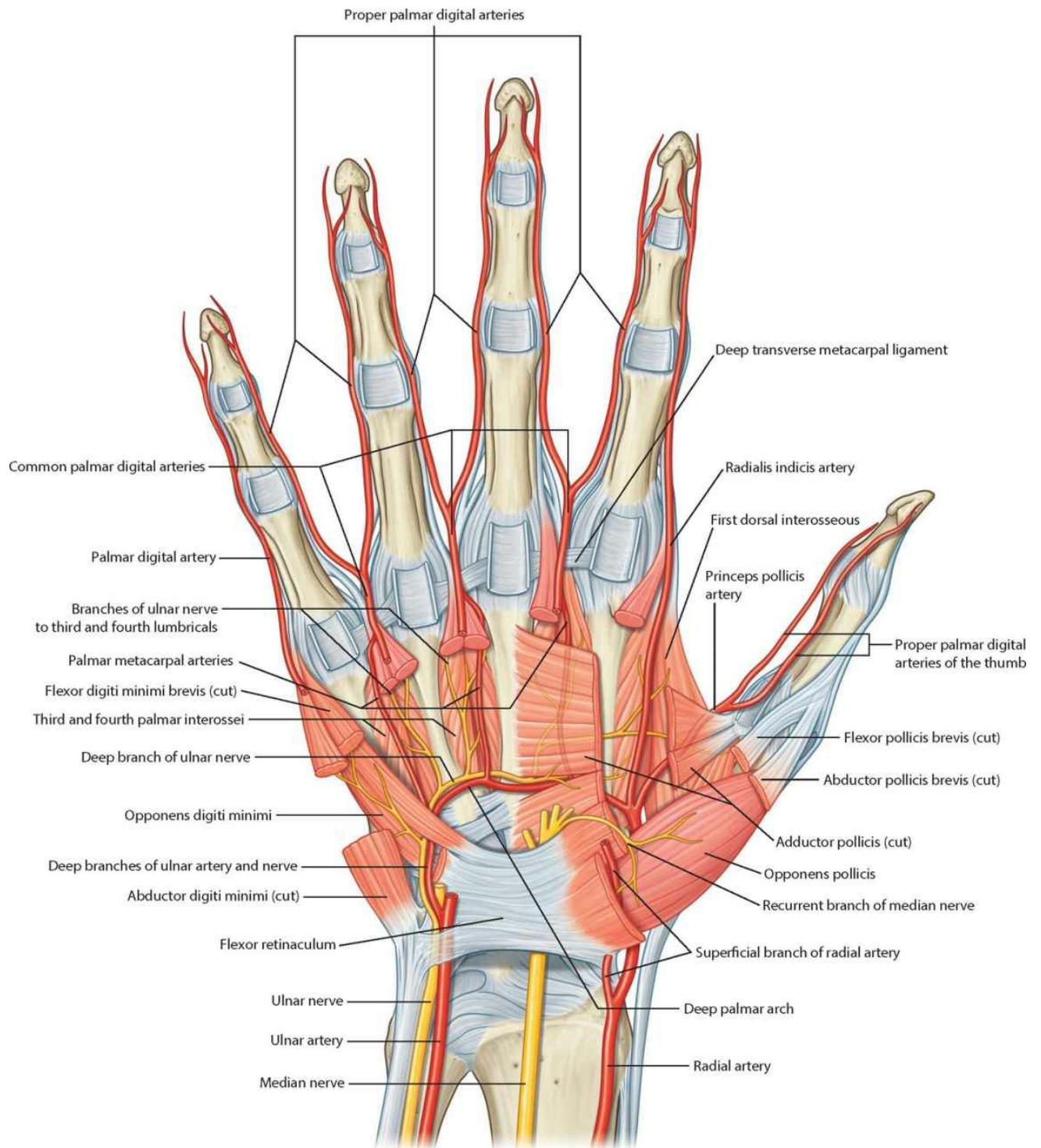


# Palmar region (palm) of hand: arteries and nerves



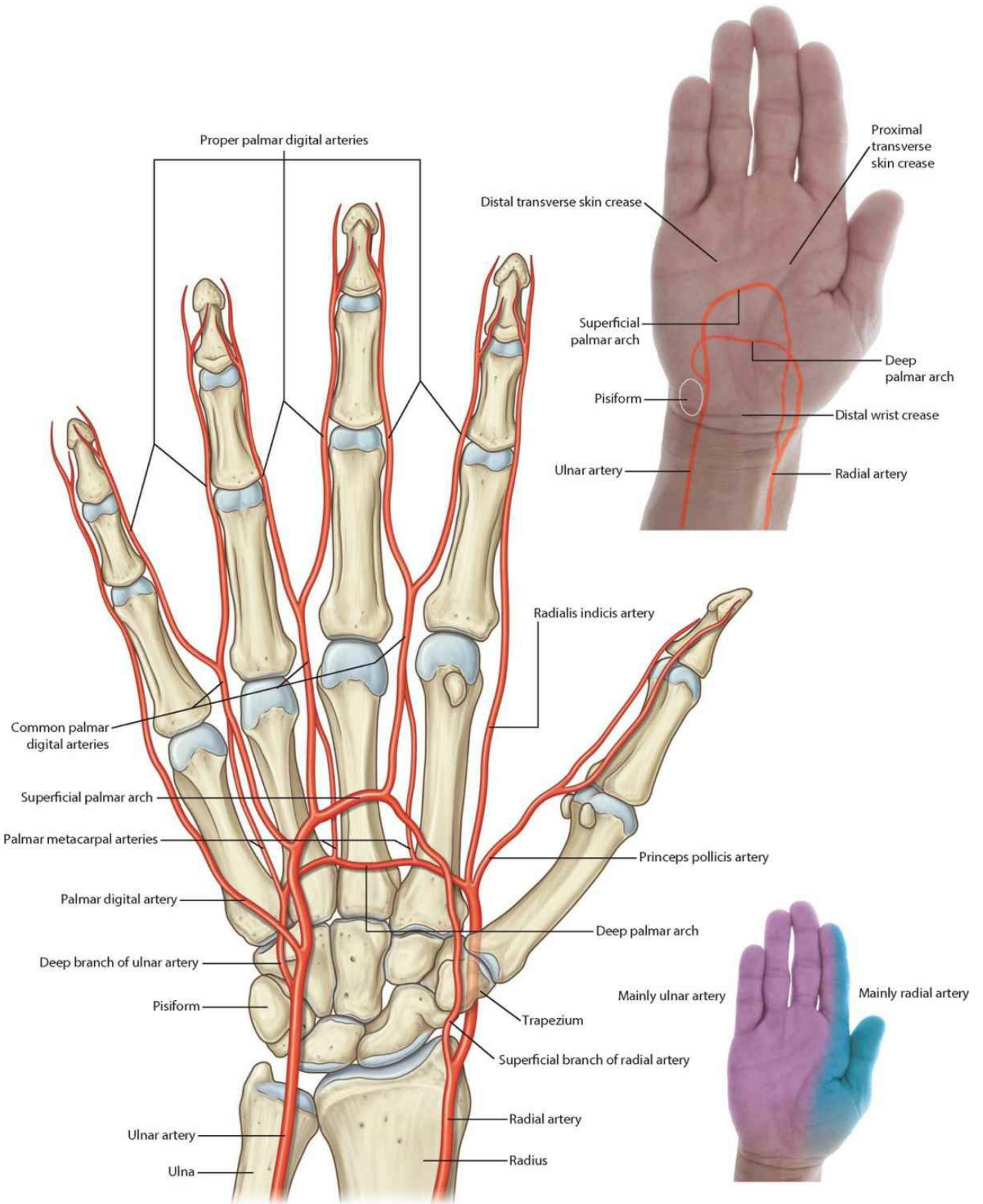
**Superficial arteries and nerves of the hand (palmar view)**





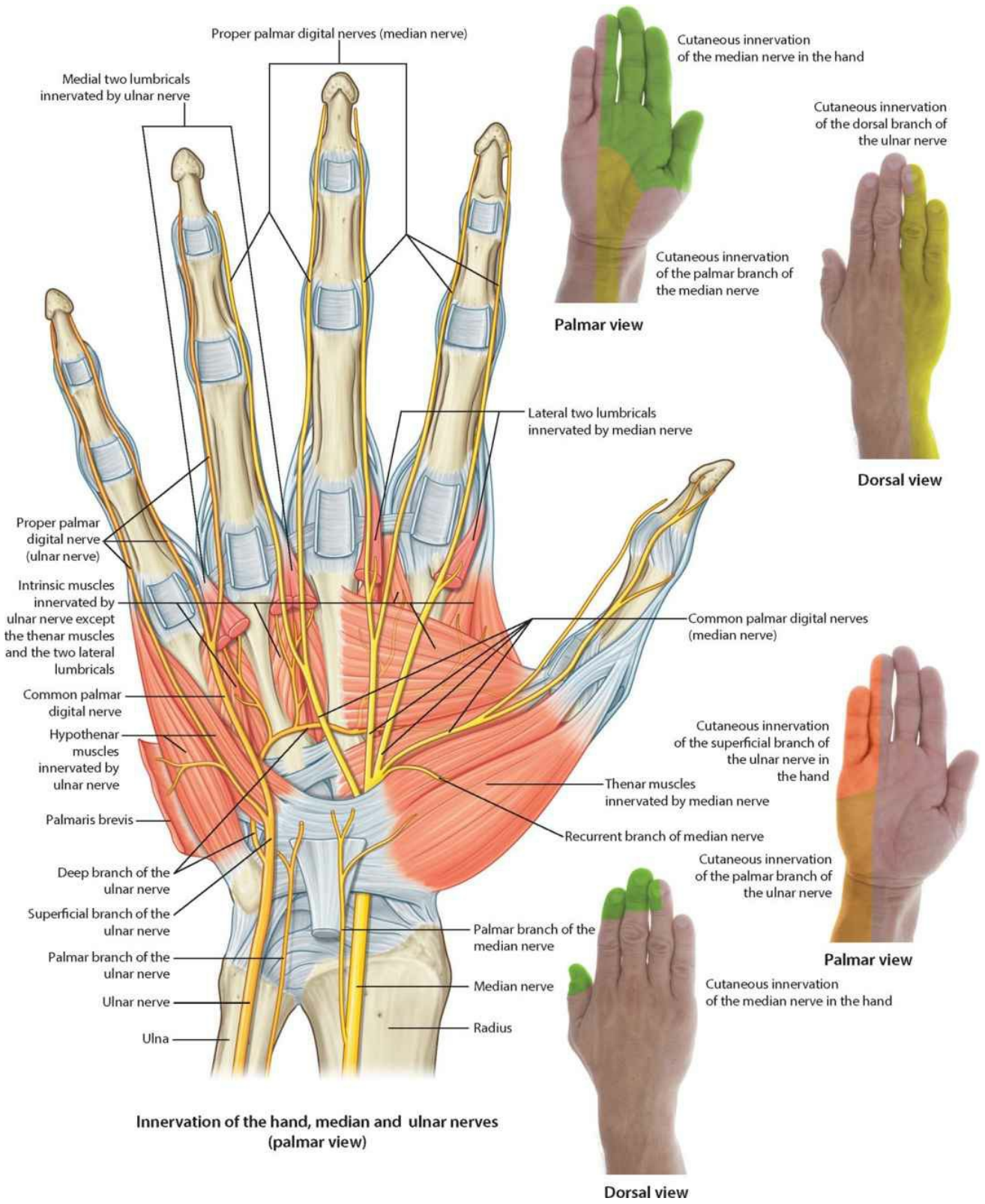
Deep arteries and nerves of the hand (palmar view)

# Arteries of the hand



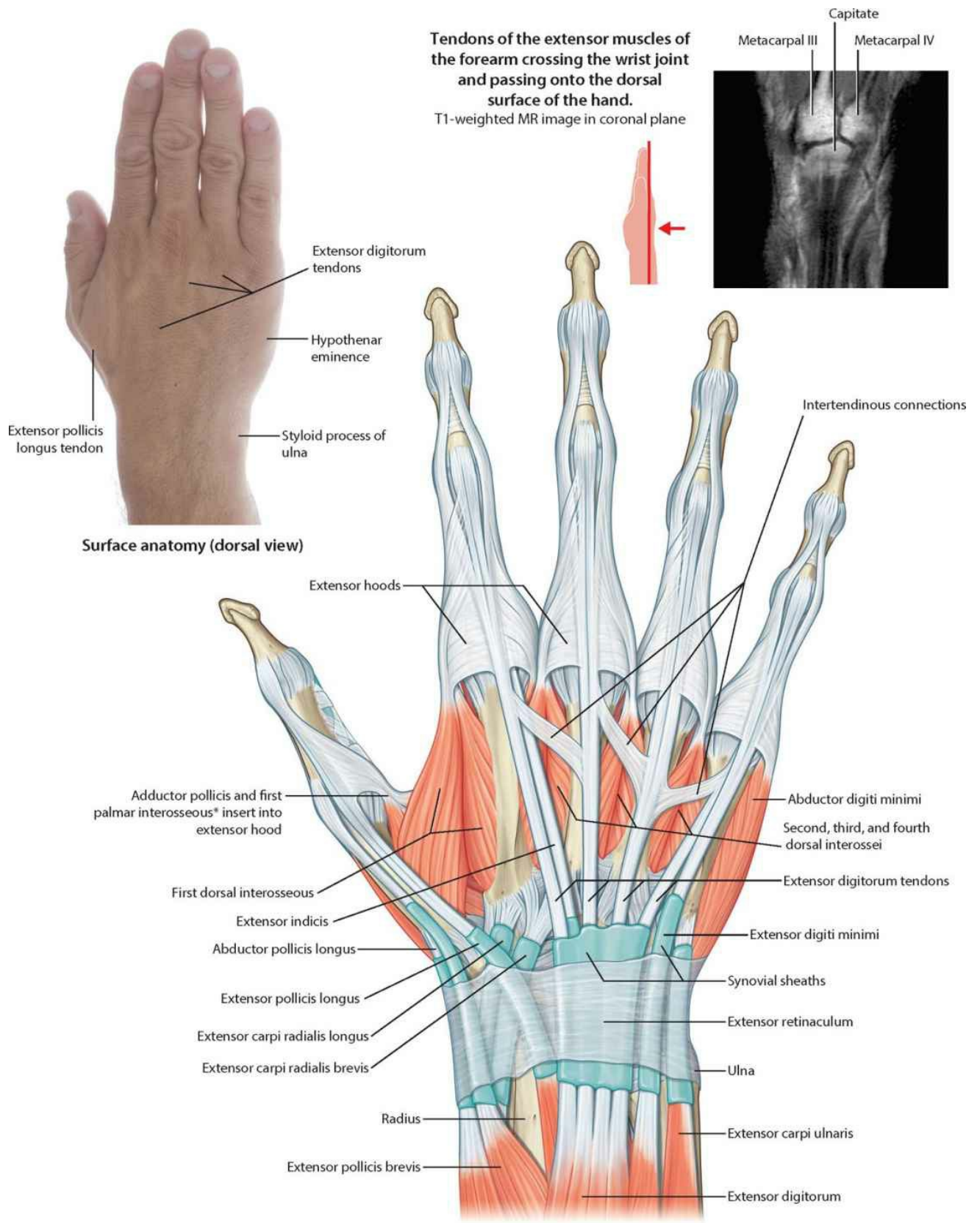
Arteries of the hand (palmar view)

# Innervation of the hand: median and ulnar nerves



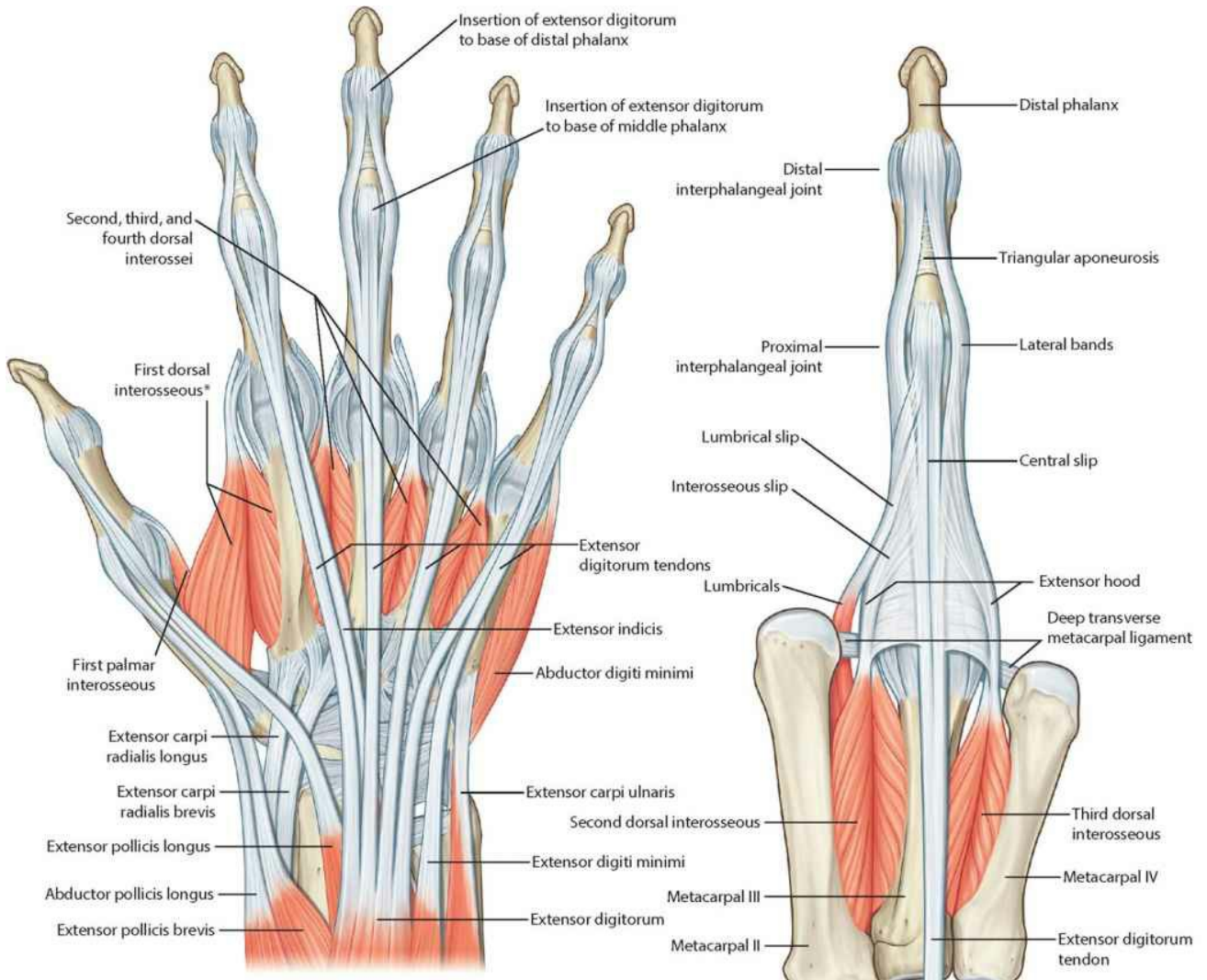


# Dorsum of hand



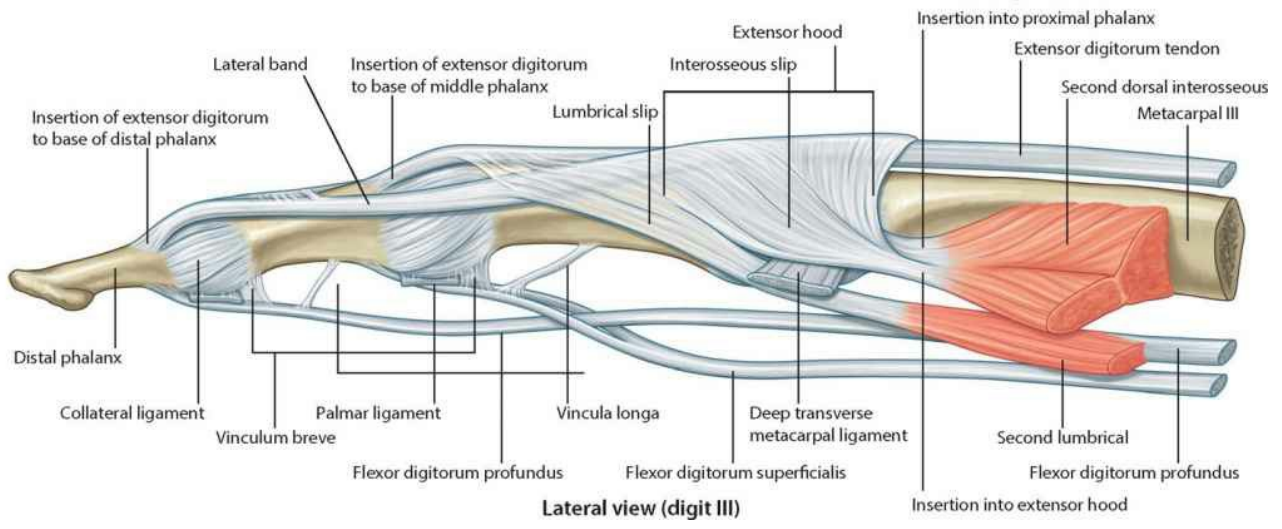
**Superficial structures of the hand (dorsal view)**  
(\* see page 449)

## Dorsal hoods



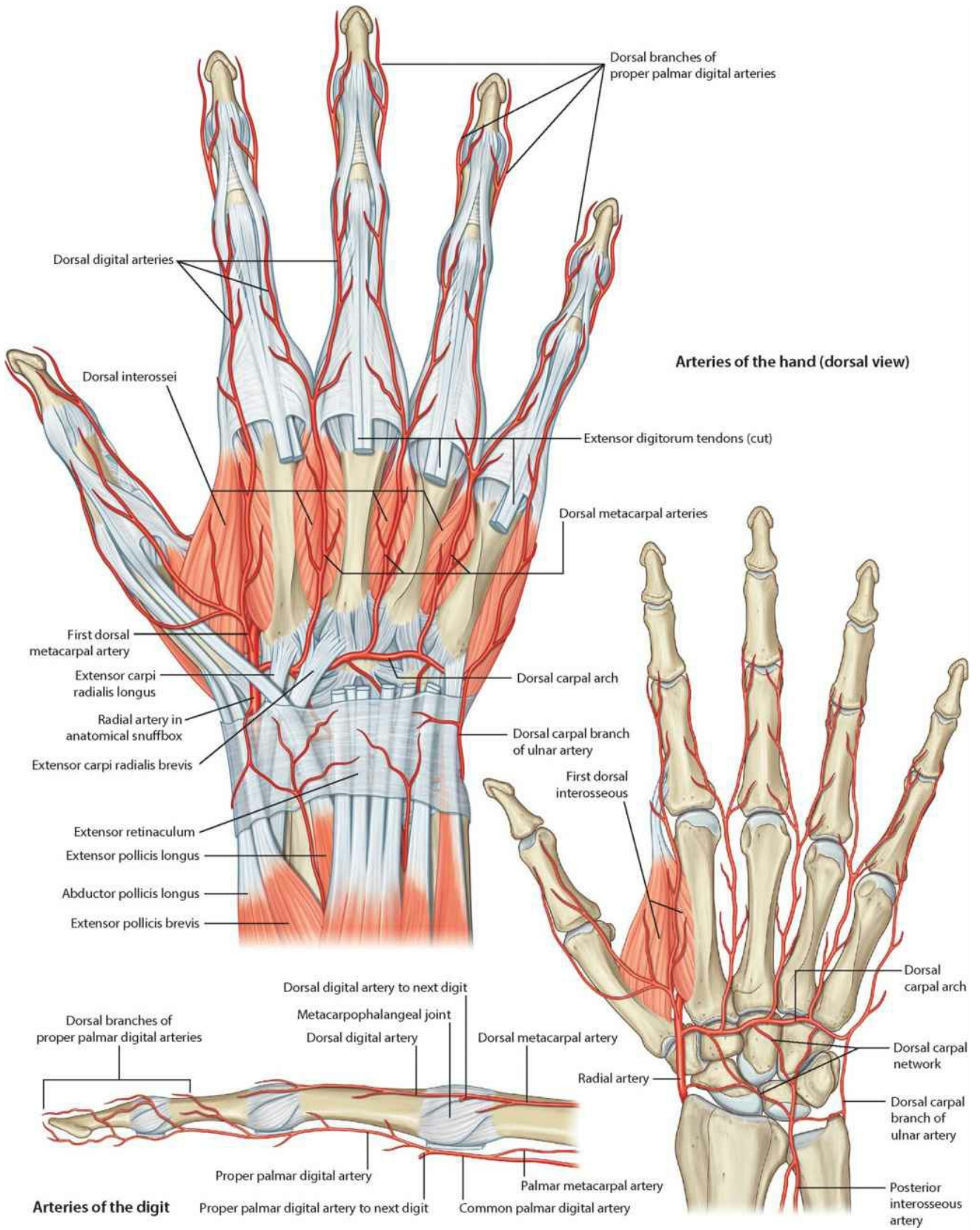
**Extensor tendons (dorsal view)**  
 (\* see page 413)

**Dorsal view (digit III)**

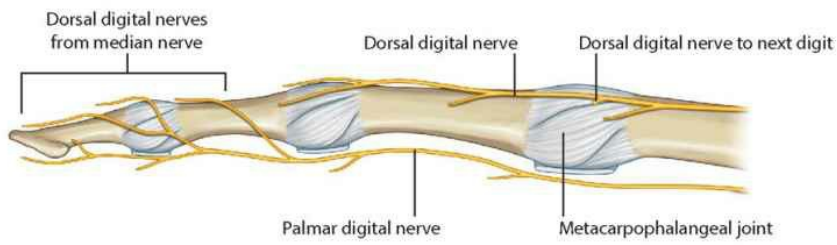


**Lateral view (digit III)**

## **Dorsum of hand: arteries**



## **Dorsum of hand: nerves**

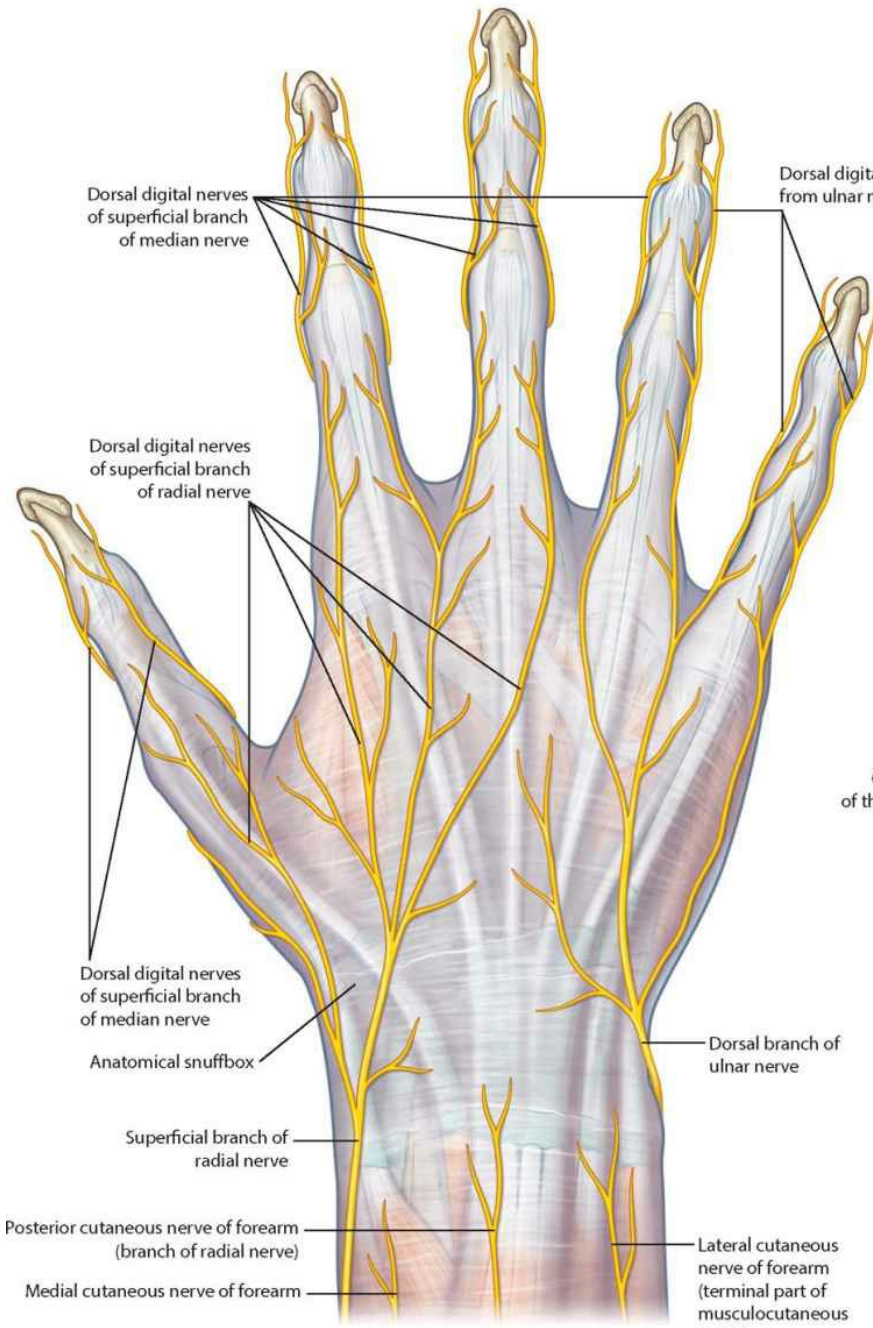


**Nerves of the digit**

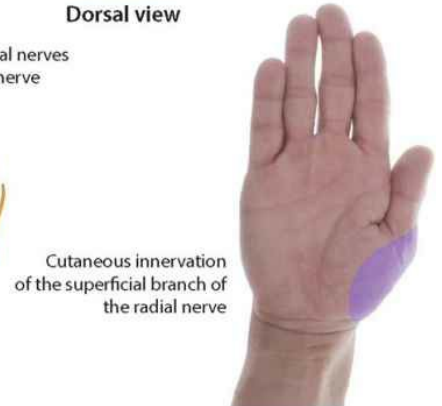


Cutaneous innervation of the superficial branch of the radial nerve

**Dorsal view**



**Nerves of the hand (dorsal view)**



Cutaneous innervation of the superficial branch of the radial nerve

**Palmar view**



Cutaneous innervation of the superficial branch of the median nerve

**Dorsal view**

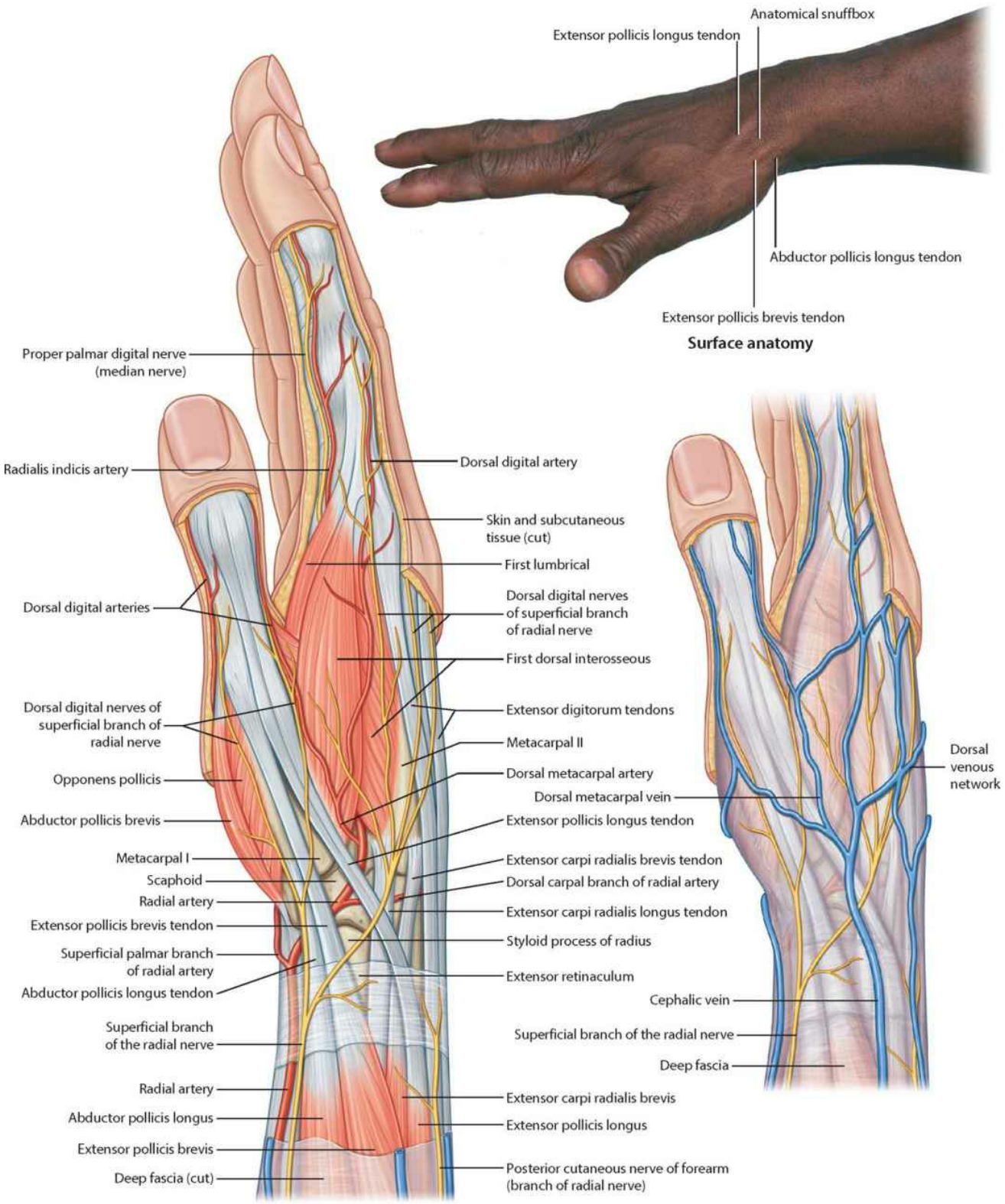


Cutaneous innervation of the dorsal branch of the ulnar nerve

**Dorsal view**

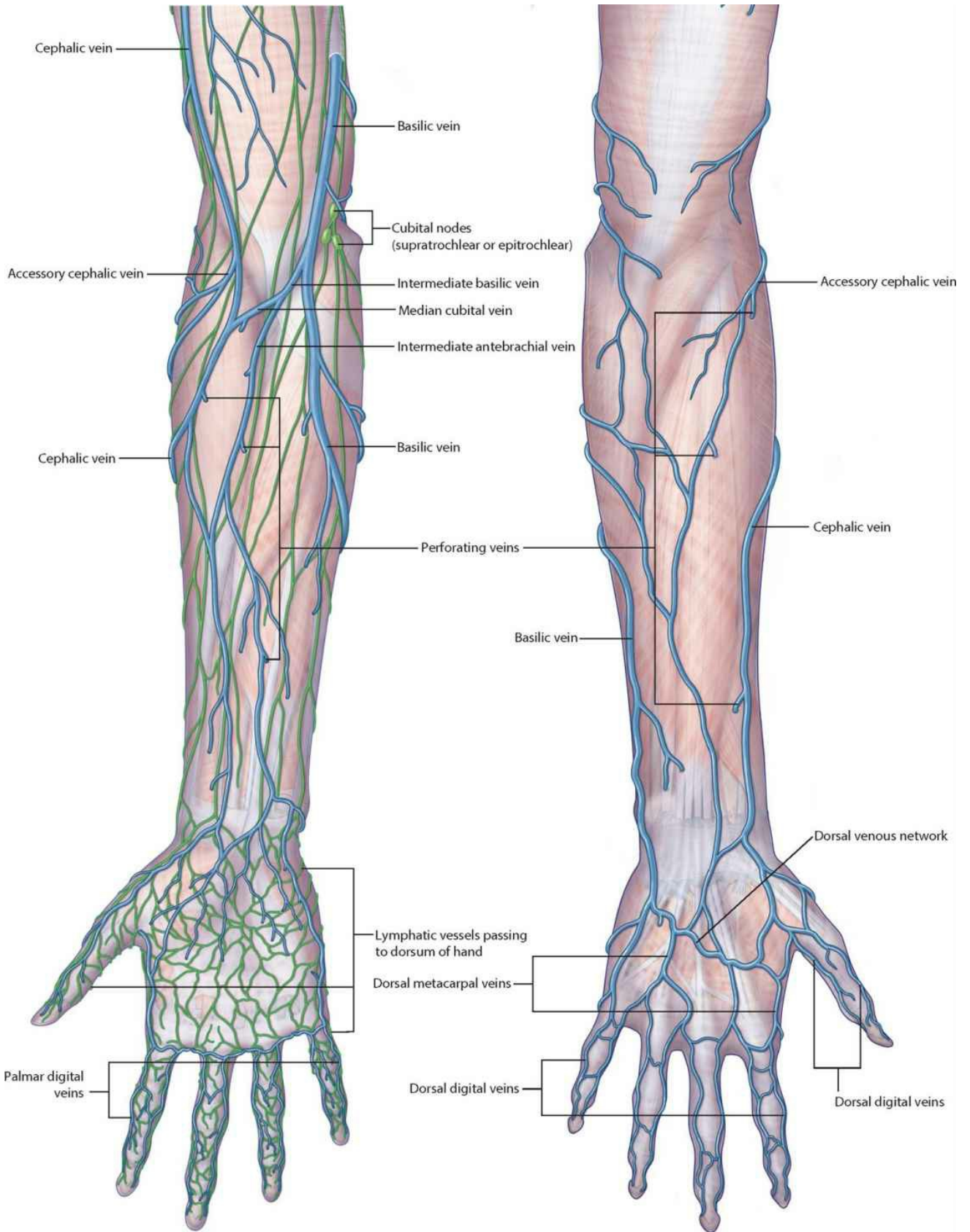


# Anatomical snuffbox



Anatomical snuffbox (lateral view)

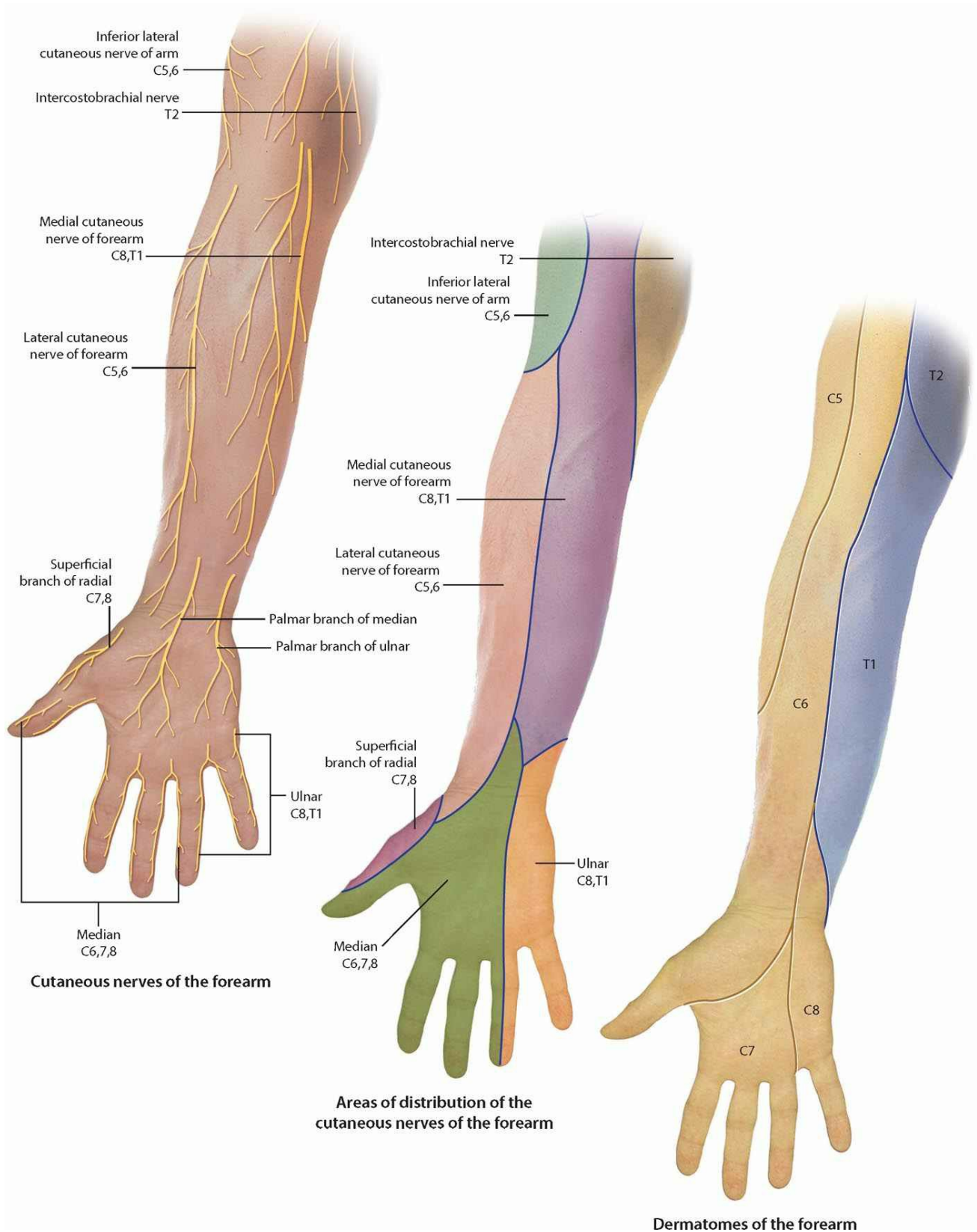
# Superficial veins and lymphatics of forearm



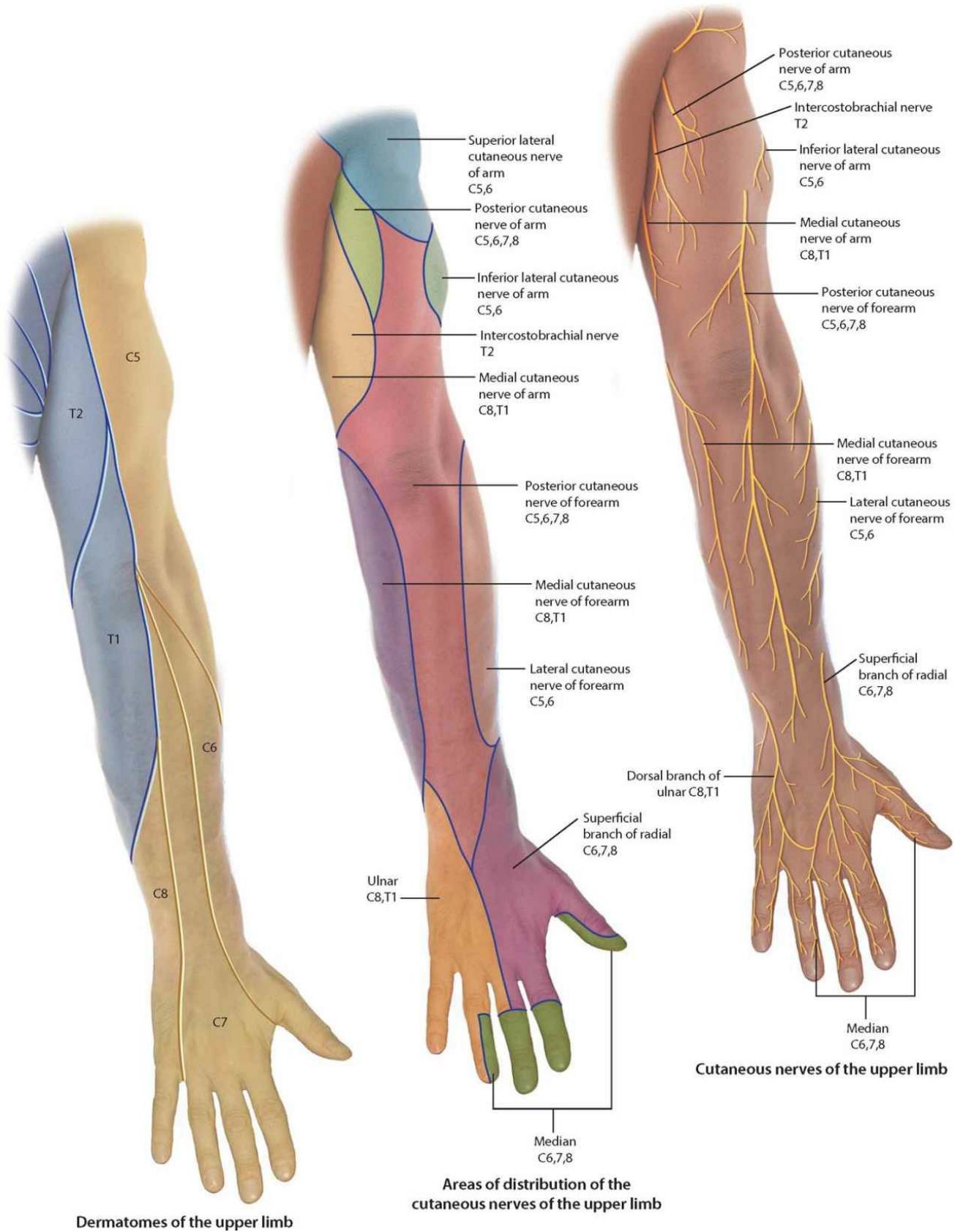
Superficial veins and lymphatics of the forearm (palmar view)

Superficial veins of the forearm (dorsal view)

## **Anterior cutaneous nerves of forearm**



# Posterior cutaneous nerves of upper limb



**Dermatomes of the upper limb**

**Areas of distribution of the cutaneous nerves of the upper limb**

**Cutaneous nerves of the upper limb**



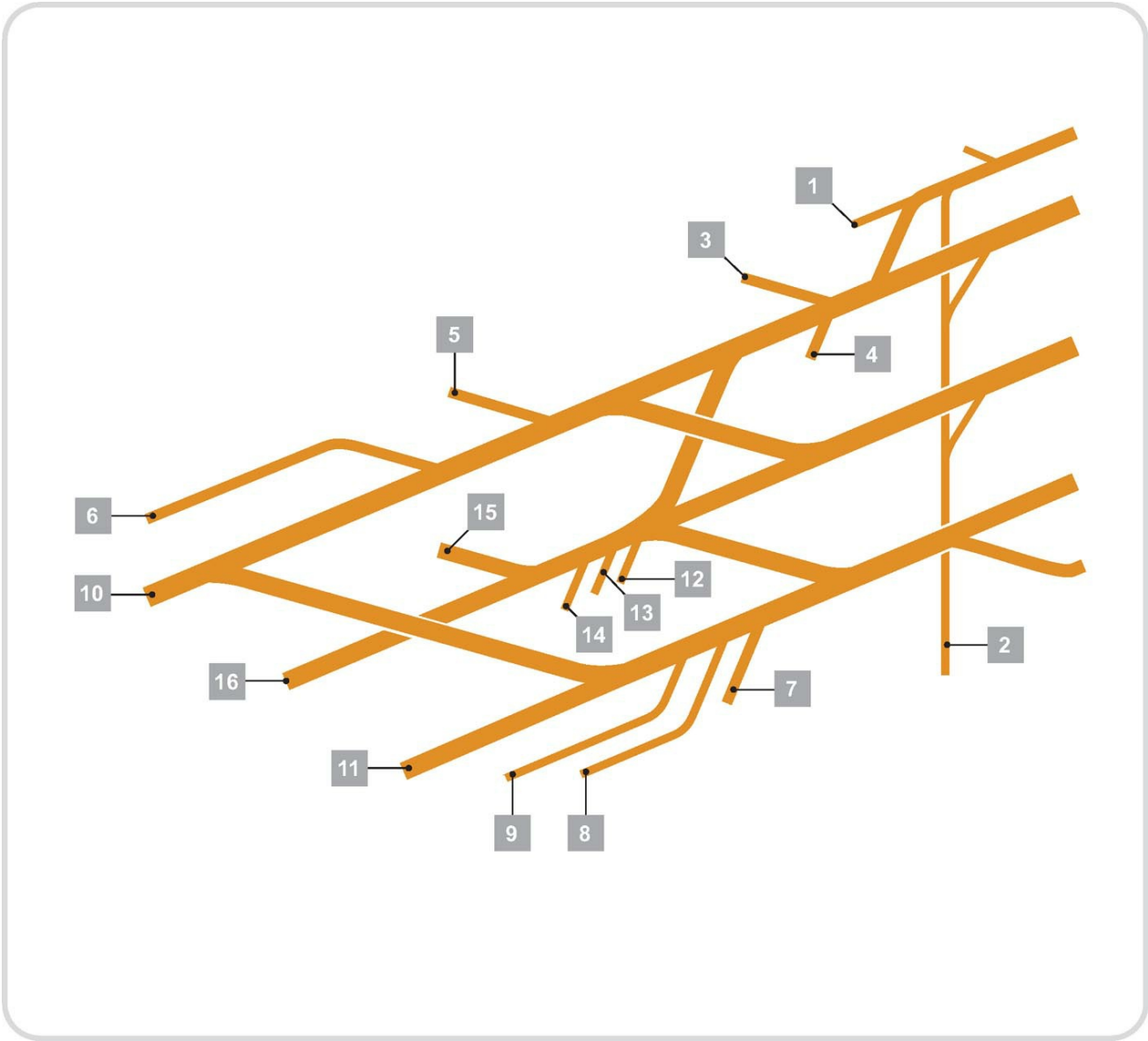
# Tables

## Branches of the brachial plexus

---

Branch		Origin	Spinal segments	Function: motor	Function: sensory
Dorsal scapular	1	C5 root	C5	Rhomboid major, rhomboid minor	
Long thoracic	2	C5 to C7 roots	C5 to C7	Serratus anterior	
Suprascapular	3	Superior trunk	C5, C6	Supraspinatus, infraspinatus	
Nerve to subclavius	4	Superior trunk	C5, C6	Subclavius	
Lateral pectoral	5	Lateral cord	C5 to C7	Pectoralis major	
Musculocutaneous	6	Lateral cord	C5 to C7	All muscles in the anterior compartment of the arm	Skin on lateral side of forearm
Medial pectoral	7	Medial cord	C8, T1 (also receives contributions from spinal segments C5 to C7 through a communication with the lateral pectoral nerve)	Pectoralis major, pectoralis minor	
Medial cutaneous of arm	8	Medial cord	Spinal segments: C8, T1		Skin on medial side of distal one-third of arm
Medial cutaneous of forearm	9	Medial cord	C8, T1		Skin on medial side of forearm
Median	10	Medial and lateral cords	(C5), C6 to T1	All muscles in the anterior compartment of the forearm (except flexor carpi ulnaris and medial half of flexor digitorum profundus), three thenar muscles of the thumb and two lateral lumbrical muscles	Skin over the palmar surface of the lateral three and one-half digits and over the lateral side of the palm and middle of the wrist
Ulnar	11	Medial cord	(C7), C8, T1	All intrinsic muscles of the hand (except three thenar muscles and two lateral lumbricals); also flexor carpi ulnaris and the medial half of flexor digitorum profundus in the forearm	Skin over the palmar surface of the medial one and one-half digits and associated palm and wrist, and skin over the dorsal surface of the medial one and one-half digits
Superior subscapular	12	Posterior cord	C5, C6	Subscapularis	
Thoraco dorsal	13	Posterior cord	C6 to C8	Latissimus dorsi	
Inferior subscapular	14	Posterior cord	C5, C6	Subscapularis, teres major	
Axillary	15	Posterior cord	C5, C6	Deltoid, teres minor	Skin over upper lateral part of arm
Radial	16	Posterior cord	C5 to C8, (T1)	All muscles in the posterior compartments of arm and forearm	Skin on the posterior aspects of the arm and forearm, the lower lateral surface of the arm, and the dorsal lateral surface of the hand

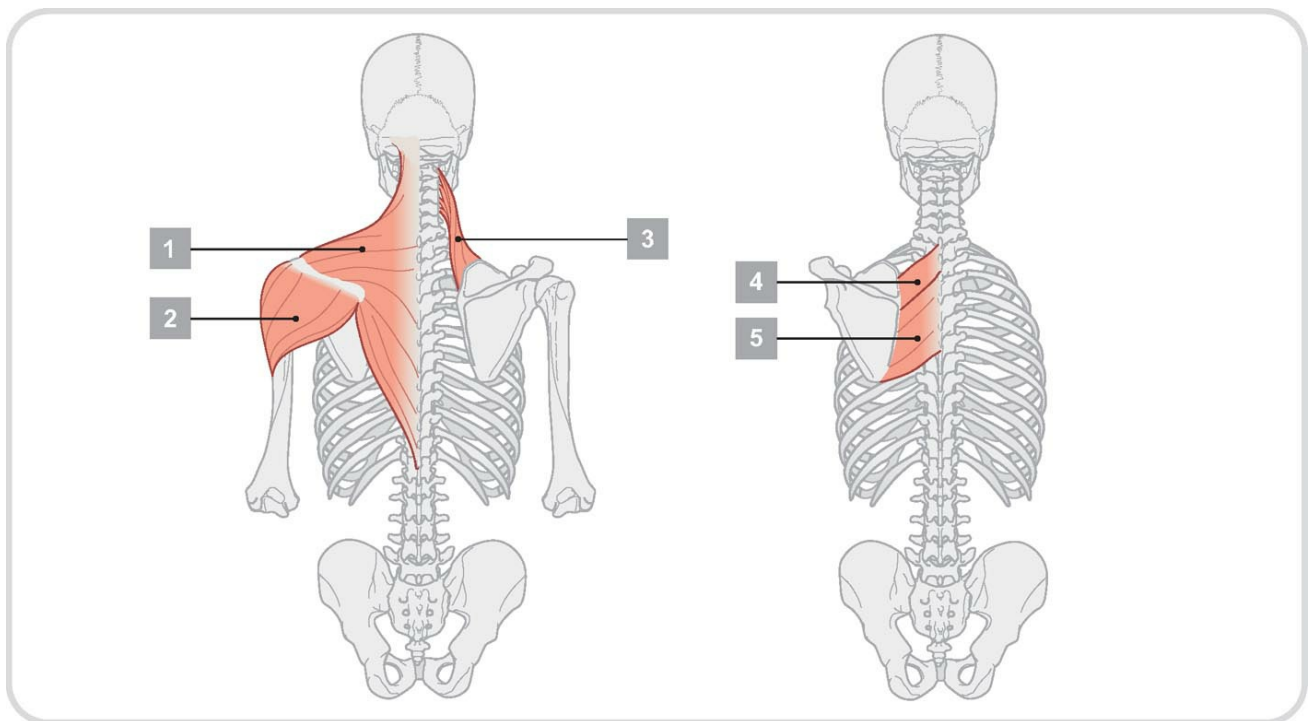




## Muscles of the shoulder

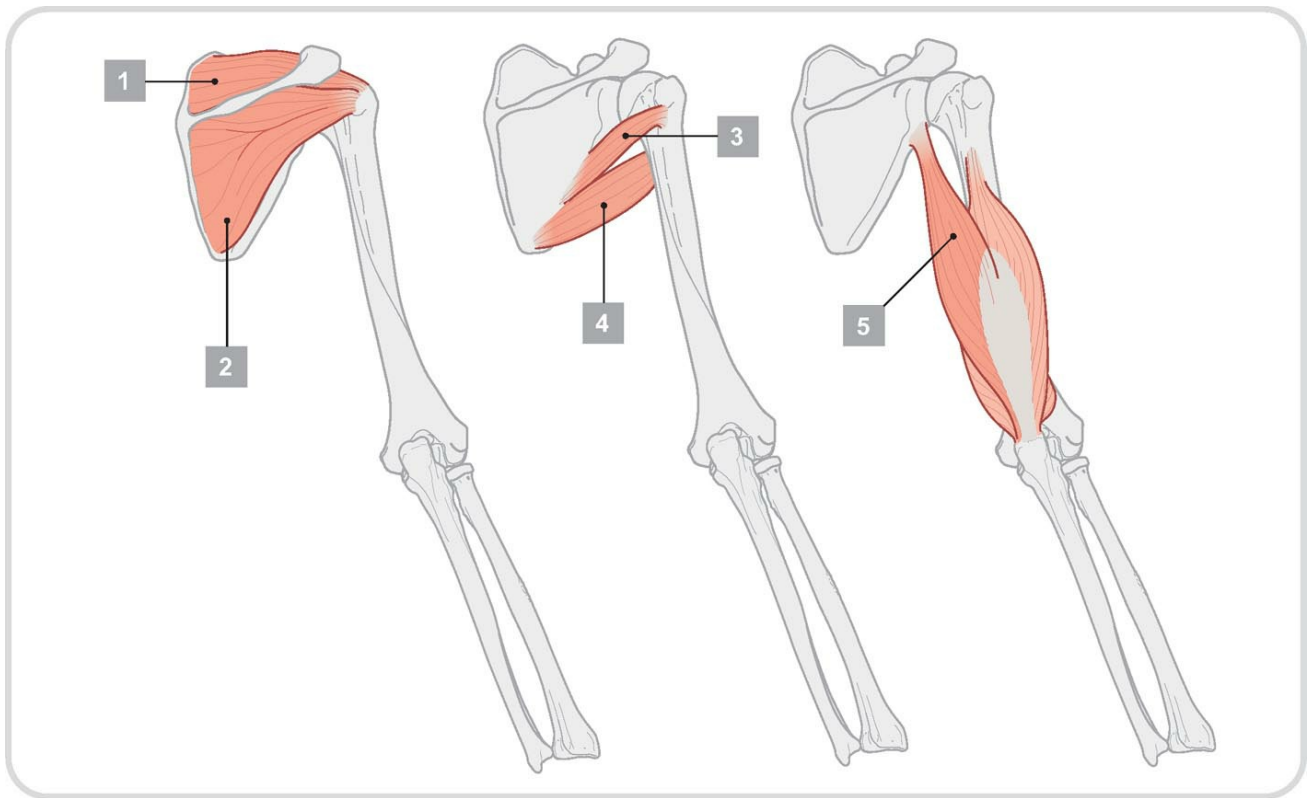
(muscles of the shoulder spinal segments indicated in bold are the major segments innervating the muscle)

Muscle		Origin	Insertion	Innervation	Function
<b>Trapezius</b>	<b>1</b>	Superior nuchal line, external occipital protuberance, medial margin of the ligamentum nuchae, spinous processes of CVII to TXII and the related supraspinous ligaments	Superior edge of the crest of the spine of the scapula, acromion, posterior border of lateral one-third of clavide	Motor spinal part of accessory nerve [XI]. Sensory (proprioception) anterior rami of C3 and C4	Powerful elevator of the scapula; rotates the scapula during abduction of humerus above horizontal; middle fibers retract scapula; lower fibers depress scapula
<b>Deltoid</b>	<b>2</b>	Inferior edge of the crest of the spine of the scapula, lateral margin of the acromion, anterior border of lateral one-third of clavide	Deltoid tuberosity of humerus	Axillary nerve [C5, C6]	Major abductor of arm (abducts arm beyond initial 15° done by supraspinatus); clavicular fibers assist in flexing the arm; posterior fibers assist in extending the arm
<b>Levator scapulae</b>	<b>3</b>	Transverse processes of C1 and C2 vertebrae and posterior tubercles of transverse processes of C3 and C4 vertebrae	Posterior surface of medial border of scapula from superior angle to root of spine of the scapula	Branches directly from anterior rami of <b>C3</b> and <b>C4</b> spinal nerves and by branches [ <b>C5</b> ] from the dorsal scapular nerve	Elevates the scapula
<b>Rhomboid minor</b>	<b>4</b>	Lower end of ligamentum nuchae and spinous processes of CVII and T1 vertebrae	Posterior surface of medial border of scapula at the root of the spine of the scapula	Dorsal scapular nerve [C4, C5]	Elevates and retracts the scapula
<b>Rhomboid major</b>	<b>5</b>	Spinous processes of T1–T4 vertebrae and intervening supraspinous ligaments	Posterior surface of medial border of scapula from the root of the spine of the scapula to the inferior angle	Dorsal scapular nerve [ <b>C4, C5</b> ]	Elevates and retracts the scapula



## Muscles of the posterior scapular region (spinal segments in bold are the major segments innervating the muscle)

Muscle		Origin	Insertion	Innervation	Function
Supraspinatus	1	Medial two-thirds of the supraspinous fossa of the scapula and the deep fascia that covers the muscle	Most superior facet on the greater tubercle of the humerus	Suprascapular nerve [C5, C6]	Rotator cuff muscle; participates in abduction of the glenohumeral joint; stabilization of glenohumeral joint
Infraspinatus	2	Medial two-thirds of the infraspinous fossa of the scapula and the deep fascia that covers the muscle	Middle facet on posterior surface of the greater tubercle of the humerus	Suprascapular nerve [C5, C6]	Rotator cuff muscle; lateral rotation of arm at the glenohumeral joint; stabilization of glenohumeral joint
Teres minor	3	Upper two-thirds of a flattened strip of bone on the posterior surface of the scapula immediately adjacent to the lateral border of the scapula	Inferior facet on the posterior surface of the greater tubercle of the humerus	Axillary nerve [C5, C6]	Rotator cuff muscle; lateral rotation of arm at the glenohumeral joint; stabilization of glenohumeral joint
Teres major	4	Elongate oval area on the posterior surface of the inferior angle of the scapula	Medial lip of the intertubercular sulcus on the anterior surface of the humerus	Inferior subscapular nerve [C5, C6, C7]	Medial rotation and extension of the arm at the glenohumeral joint
Long head of triceps brachii	5	Infraglenoid tubercle on scapula	Common tendon of insertion with medial and lateral heads on the olecranon process of ulna	Radial nerve [C6, C7, C8]	Extension of the forearm at the elbow joint; accessory adductor and extensor of the arm at the glenohumeral joint



## Muscles of the anterior wall of the axilla (spinal segments in bold are the major segments innervating the muscle)

Muscle		Origin	Insertion	Innervation	Function
<b>Pectoralis major</b>	1	Clavicular head—anterior surface of medial half of clavicle; sternocostal head—anterior surface of sternum; first seven costal cartilages; sternal end of sixth rib; aponeurosis of external obliqu	Lateral lip of intertubercular sulcus of humerus	Medial and lateral pectoral nerves; clavicular head [ <b>C5, C6</b> ]; sternocostal head [ <b>C6, C7, C8, T1</b> ]	Flexion, adduction, and medial rotation of arm at glenohumeral joint; clavicular head—flexion of extended arm; sternocostal head—extension of flexed arm
<b>Subclavius</b>	2	First rib at junction between rib and costal cartilage	Groove on inferior surface of middle one-third of clavicle	Nerve to subclavius [ <b>C5, C6</b> ]	Pulls tip of shoulder down; pulls clavicle medially to stabilize sternoclavicular joint
<b>Pectoralis minor</b>	3	Anterior surfaces and superior borders of ribs III to V; and from deep fascia overlying the related intercostal spaces	Coracoid process of scapula (medial border and upper surface)	Medial pectoral nerve [ <b>C5, C6, C7, C8, T1</b> ]	Pulls tip of shoulder down; protracts scapula

## Muscles of the medial wall of the axilla

<b>Serratus anterior</b>	4	Lateral surfaces of upper 8–9 ribs and deep fascia overlying the related intercostal spaces	Costal surface of medial border of scapula	Long thoracic nerve [ <b>C5, C6, C7</b> ]	Protraction and rotation of the scapula; keeps medial border and inferior angle of scapula opposed to thoracic wall
--------------------------	---	---	--	---	---

**Muscles of the lateral and posterior wall of the axilla**  
**(spinal segments enclosed in parentheses do not consistently innervate the muscle)**

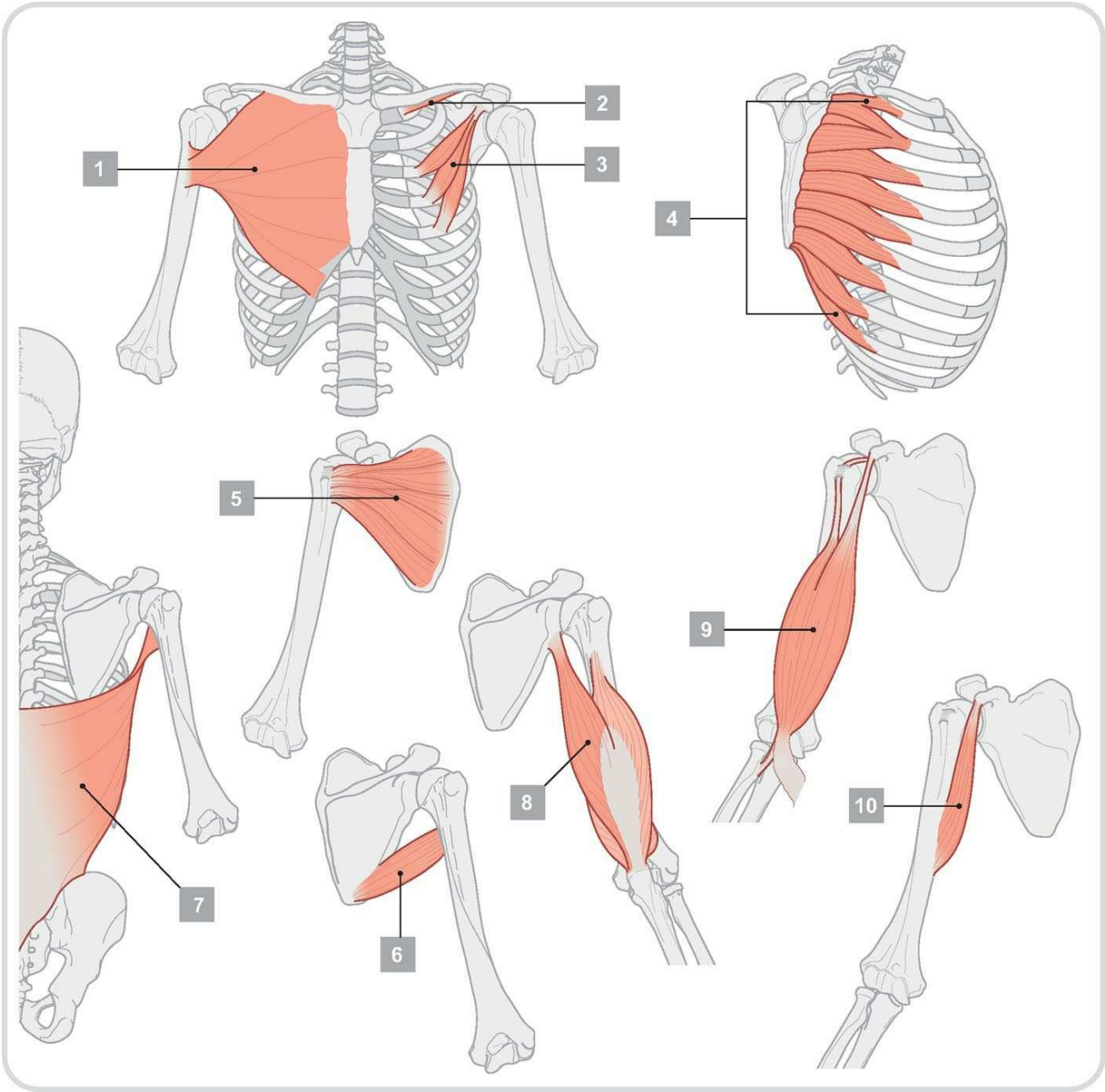
<b>Subscapularis</b>	5	Medial two-thirds of subscapular fossa	Lesser tubercle of humerus	Upper and lower subscapular nerves [C5, C6, (C7)]	Rotator cuff muscle; medial rotation of the arm at the glenohumeral joint; stabilization of glenohumeral joint
<b>Teres major</b>	6	Elongate oval area on the posterior surface of the inferior angle of the scapula	Medial lip of the intertubercular sulcus on the anterior surface of the humerus	Lower subscapular nerve [C5, C6, C7]	Medial rotation and extension of the arm at the glenohumeral joint
<b>Latissimus dorsi</b>	7	Spinous processes of lower six thoracic vertebrae and related interspinous ligaments; via the thoracolumbar fascia to the spinous processes of the lumbar vertebrae, related interspinous ligaments, and iliac crest; lower 3–4 ribs	Floor of intertubercular sulcus	Thoracodorsal nerve [C6, C7, C8]	Adduction, medial rotation, and extension of the arm at the glenohumeral joint
<b>Long head of triceps brachii</b>	8	Infraglenoid tubercle on scapula	Common tendon of insertion with medial and lateral heads on the olecranon process of ulna	Radial nerve [C6, C7, C8]	Extension of the forearm at the elbow joint; accessory adductor and extensor of the arm at the glenohumeral joint

**Muscles having parts that pass through the axilla**  
**(spinal segments in bold are the major segments innervating the muscle)**

Muscle		Origin	Insertion	Innervation	Function
<b>Biceps brachii</b>	<b>9</b>	Long head—supraglenoid tubercle of scapula; short head—apex of coracoid process	Tuberosity of radius	Musculocutaneous nerve [C5, C6]	Powerful flexor of the forearm at the elbow joint and supinator of the forearm; accessory flexor of the arm at the glenohumeral joint
<b>Coracobrachialis</b>	<b>10</b>	Apex of coracoid process	Linear roughening on midshaft of humerus on medial side	Musculocutaneous nerve [C5, C6, C7]	Flexor of the arm at the glenohumeral joint; adducts arm





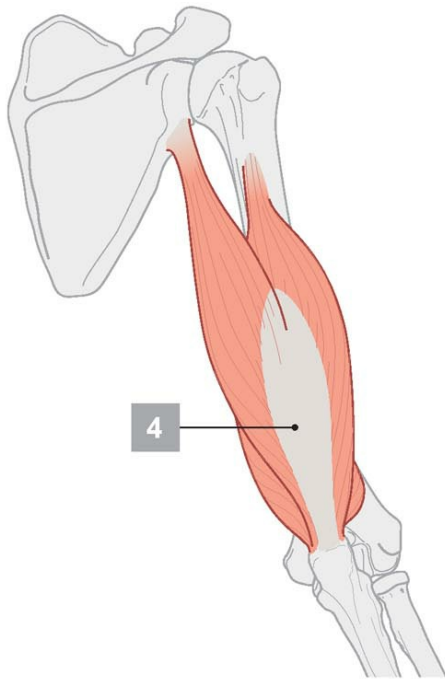
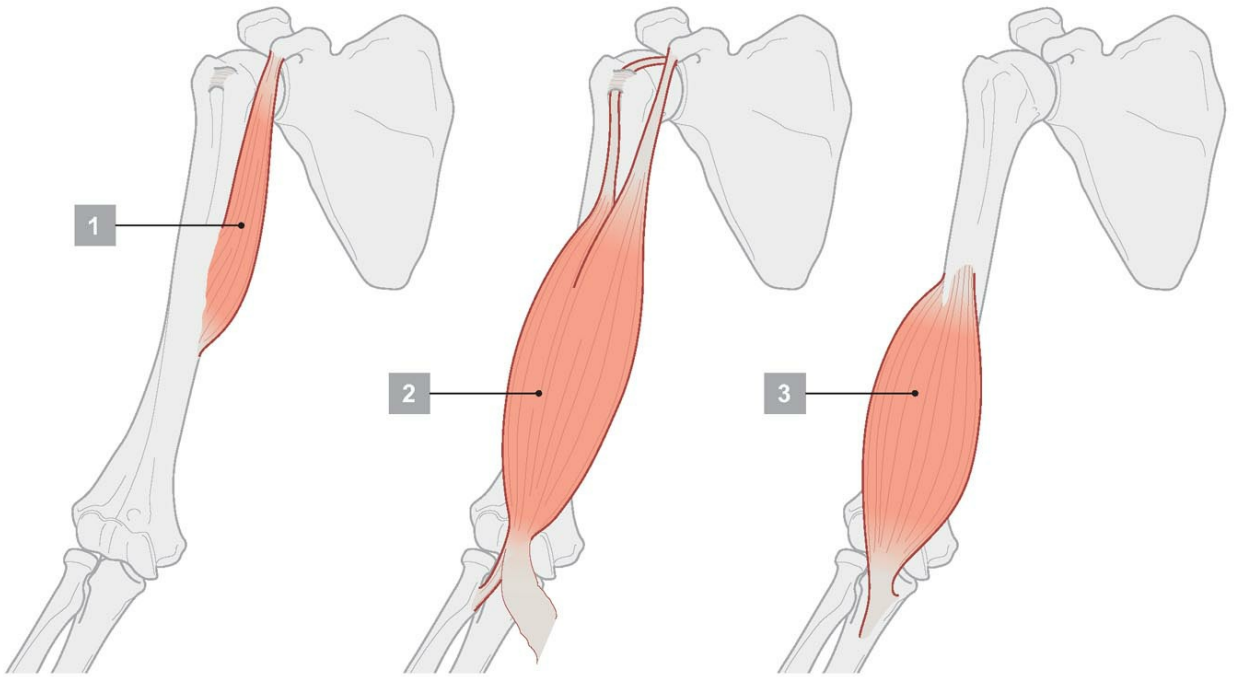


## Muscles of the anterior compartment of the arm (spinal segments in bold are the major segments innervating the muscle)

Muscle		Origin	Insertion	Innervation	Function
<b>Coracobrachialis</b>	<b>1</b>	Apex of coracoid process	Linear roughening on midshaft of humerus on medial side	Musculocutaneous nerve [C5, <b>C6</b> , C7]	Flexor of the arm at the glenohumeral joint
<b>Biceps brachii</b>	<b>2</b>	Long head-supraglenoid tubercle of scapula; short head-apex of coracoid process	Radial tuberosity	Musculocutaneous nerve [C5, <b>C6</b> ]	Powerful flexor of the forearm at the elbow joint and supinator of the forearm; accessory flexor of the arm at the glenohumeral joint
<b>Brachialis</b>	<b>3</b>	Anterior aspect of humerus (medial and lateral surfaces) and adjacent intermuscular septae	Tuberosity of the ulna	Musculocutaneous nerve [C5, <b>C6</b> ]; (small contribution by the radial nerve [C7] to lateral part of muscle)	Powerful flexor of the forearm at the elbow joint

## Muscle of the posterior compartment of the arm

<b>Triceps brachii</b>	<b>4</b>	Long head—infraglenoid tubercle of scapula; medial head—posterior surface of humerus;lateral head-posterior surface of humerus	Olecranon	Radial nerve [C6, <b>C7</b> , C8]	Extension of the forearm at the elbow joint. Long head can also extend and adduct the arm at the shoulder joint
------------------------	----------	--	-----------	-----------------------------------	---



## Superficial layer of muscles in the anterior compartment of the forearm (spinal segments indicated in bold are the major segments innervating the muscle)

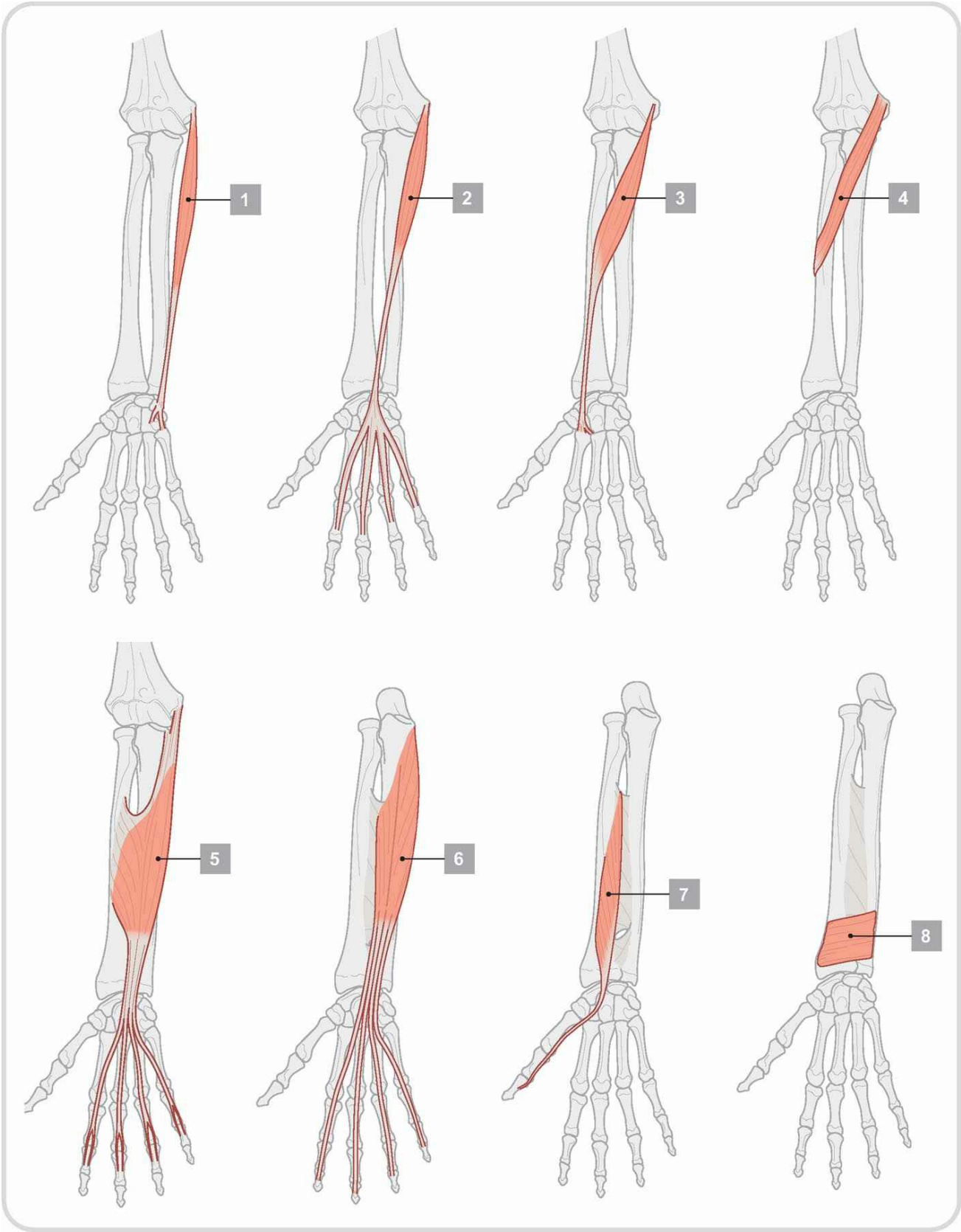
Muscle		Origin	Insertion	Innervation	Function
<b>Flexor carpi ulnaris</b>	<b>1</b>	Humeral head—medial epicondyle of humerus; ulnar head—olecranon and posterior border of ulna	Pisiform bone, and then via pisohamate and pisometacarpal ligaments into the hamate and base of metacarpal V	Ulnar nerve [ <b>C7, C8</b> , T1]	Flexes and adducts the wrist joint
<b>Palmaris longus</b>	<b>2</b>	Medial epicondyle of humerus	Palmar aponeurosis of hand	Median nerve [ <b>C7, C8</b> ]	Flexes wrist joint; because the palmar aponeurosis anchors skin of the hand, contraction of the muscle resists shearing forces when gripping
<b>Flexor carpi radialis</b>	<b>3</b>	Medial epicondyle of humerus	Base of metacarpals II and III	Median nerve [ <b>C6, C7</b> ]	Flexes and abducts the wrist
<b>Pronator teres</b>	<b>4</b>	Humeral head—medial epicondyle and adjacent supraepicondylar ridge; ulnar head—medial side of coronoid process	Roughening on lateral surface, midshaft, of radius	Median nerve [ <b>C6, C7</b> ]	Pronation

## Intermediate layer of muscles in the anterior compartment of the forearm

<b>Flexor digitorum superficialis</b>	<b>5</b>	Humero-ulnar head—medial epicondyle of humerus and adjacent margin of coronoid process; radial head—oblique line of radius	Four tendons, which attach to the palmar surfaces of the middle phalanges of the index, middle, ring, and little fingers	Median nerve [ <b>C8</b> , T1]	Flexes proximal interphalangeal joints of the index, middle, ring, and little fingers; can also flex metacarpophalangeal joints of the same fingers and the wrist joint
---------------------------------------	----------	--	--	-----------------------------------	---

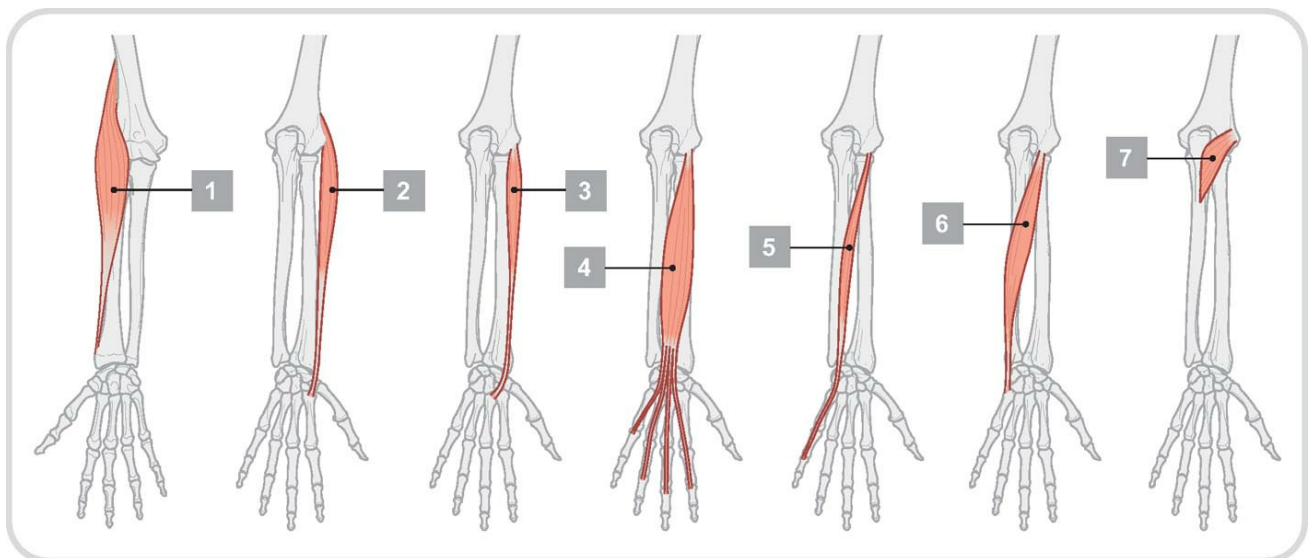
## Deep layer of muscles in the anterior compartment of the forearm

<b>Flexor digitorum profundus</b>	<b>6</b>	Anterior and medial surfaces of ulna and anterior medial half of interosseous membrane	Four tendons, which attach to the palmar surfaces of the distal phalanges of the index, middle, ring, and little fingers	Lateral half by median nerve (anterior interosseous nerve); medial half by ulnar nerve [C8, T1]	Flexes distal interphalangeal joints of the index, middle, ring, and little fingers; can also flex metacarpophalangeal joints of the same fingers and the wrist joint
<b>Flexor pollicis longus</b>	<b>7</b>	Anterior surface of radius and radial half of interosseous membrane	Palmar surface of base of distal phalanx of thumb	Median nerve (anterior interosseous nerve) [C7, C8]	Flexes interphalangeal joint of the thumb; can also flex metacarpophalangeal joint of the thumb
<b>Pronator quadratus</b>	<b>8</b>	Linear ridge on distal anterior surface of ulna	Distal anterior surface of radius	Median nerve (anterior interosseous nerve) [C7, C8]	Pronation



**Superficial layer of muscles in the posterior compartment of the forearm (spinal segments indicated in bold are the major segments innervating the muscle)**

Muscle		Origin	Insertion	Innervation	Function
<b>Brachioradialis</b>	<b>1</b>	Proximal part of lateral supraepicondylar ridge of humerus and adjacent intermuscular septum	Lateral surface of distal end of radius	Radial nerve [ <b>C5, C6</b> ] before division into superficial and deep branches	Accessory flexor of elbow joint when forearm is midpronated
<b>Extensor carpi radialis longus</b>	<b>2</b>	Distal part of lateral supraepicondylar ridge of humerus and adjacent intermuscular septum	Dorsal surface of base of metacarpal II	Radial nerve [ <b>C6, C7</b> ] before division into superficial and deep branches	Extends and abducts the wrist
<b>Extensor carpi radialis brevis</b>	<b>3</b>	Lateral epicondyle of humerus and adjacent intermuscular septum	Dorsal surface of base of metacarpals II and III	Deep branch of radial nerve [ <b>C7, C8</b> ] before penetrating supinator muscle	Extends and abducts the wrist
<b>Extensor digitorum</b>	<b>4</b>	Lateral epicondyle of humerus and adjacent intermuscular septum and deep fascia	Four tendons, which insert via extensor hoods into the dorsal aspects of the bases of the middle and distal phalanges of the index, middle, ring, and little fingers	Posterior interosseous nerve [ <b>C7, C8</b> ]	Extends the index, middle, ring, and little fingers; can also extend the wrist
<b>Extensor digiti minimi</b>	<b>5</b>	Lateral epicondyle of humerus and adjacent intermuscular septum together with extensor digitorum	Extensor hood of the little finger	Posterior interosseous nerve [ <b>C7, C8</b> ]	Extends the little finger
<b>Extensor carpi ulnaris</b>	<b>6</b>	Lateral epicondyle of humerus and posterior border of ulna	Tubercle on the base of the medial side of metacarpal V	Posterior interosseous nerve [ <b>C7, C8</b> ]	Extends and adducts the wrist
<b>Anconeus</b>	<b>7</b>	Lateral epicondyle of humerus	Olecranon and proximal posterior surface of ulna	Radial nerve [ <b>C6, C7, C8</b> ] (via branch to medial head of triceps brachii)	Abduction of the ulna in pronation; accessory extensor of the elbow joint

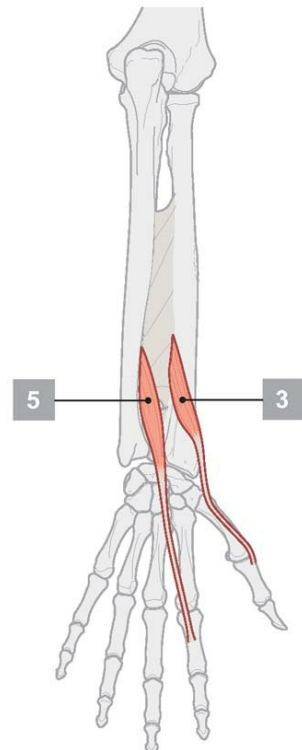
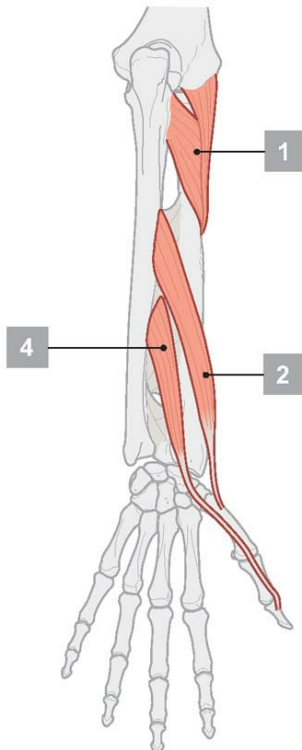


**Deep layer of muscles in the posterior compartment of the forearm (spinal segments indicated in bold are the major segments innervating the muscle)**

Muscle		Origin	Insertion	Innervation	Function
Supinator	1	Superficial part—lateral epicondyle of humerus, radial collateral and anular ligaments; deep part-supinator crest of the ulna	Lateral surface of radius superior to the anterior oblique line	Posterior interosseous nerve [ <b>C6</b> , <b>C7</b> ]	Supination
Abductor pollicis longus	2	Posterior surfaces of ulna and radius (distal to the attachments of supinator and anconeus), and intervening interosseous membrane	Lateral side of base of metacarpal I	Posterior interosseous nerve [ <b>C7</b> , <b>C8</b> ]	Abducts carpometacarpal joint of thumb; accessory extensor of the thumb
Extensor pollicis brevis	3	Posterior surface of radius (distal to abductor pollicis longus) and the adjacent interosseous membrane	Dorsal surface of base of proximal phalanx of the thumb	Posterior interosseous nerve [ <b>C7</b> , <b>C8</b> ]	Extends metacarpophalangeal joint of the thumb; can also extend the carpometacarpal joint of the thumb
Extensor pollicis longus	4	Posterior surface of ulna (distal to the abductor pollicis longus) and the adjacent interosseous membrane	Dorsal surface of base of distal phalanx of thumb	Posterior interosseous nerve [ <b>C7</b> , <b>C8</b> ]	Extends interphalangeal joint of the thumb; can also extend carpometacarpal and metacarpophalangeal joints of the thumb
Extensor indicis	5	Posterior surface of ulna (distal to extensor pollicis longus) and adjacent interosseous membrane	Extensor hood of index finger	Posterior interosseous nerve [ <b>C7</b> , <b>C8</b> ]	Extends index finger



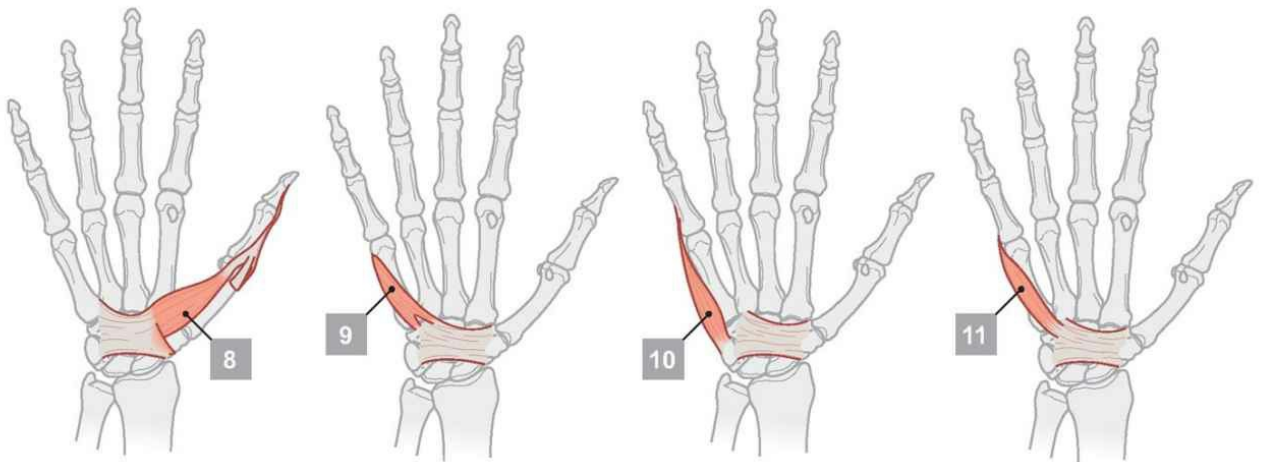
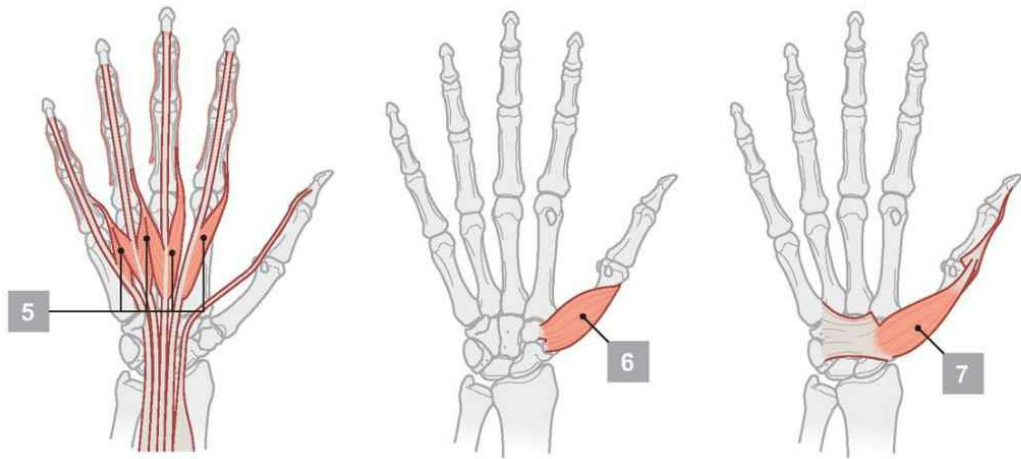
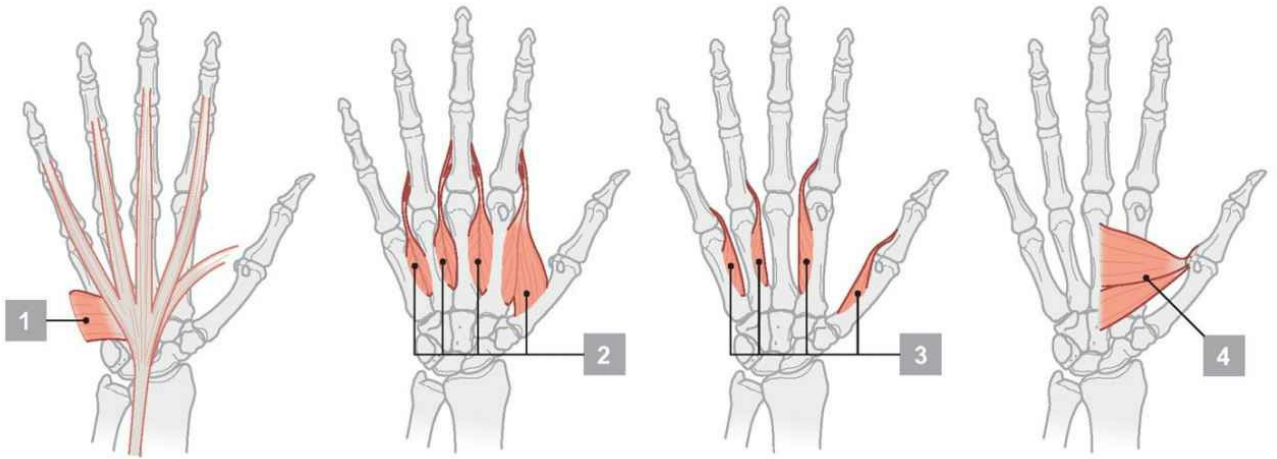




## Intrinsic muscles of the hand

(spinal segments indicated in bold are the major segments innervating the muscle)

Muscle		Origin	Insertion	Innervation	Function
Palmaris brevis	<b>1</b>	Palmar aponeurosis and flexor retinaculum	Dermis of skin on the medial margin of the hand	Superficial branch of the ulnar nerve [CS, <b>T1</b> ]	Improves grip
Dorsal interossei (four muscles)	<b>2</b>	Adjacent sides of metacarpals	Extensor hood and base of proximal phalanges of index, middle, and ring fingers	Deep branch of ulnar nerve [CS, <b>T1</b> ]	Abduction of index, middle, and ring fingers at the metacarpophalangeal joints
Palmar interossei (four muscles: the first palmar interosseous associated with the thumb is rudimentary. When present it is often considered part of either adductor pollicis or flexor pollicis brevis)	<b>3</b>	Sides of metacarpals	Extensor hoods of the thumb, index, ring, and little fingers and the proximal phalanx of thumb	Deep branch of ulnar nerve [CS, <b>T1</b> ]	Adduction of the thumb, index, ring, and little fingers at the metacarpophalangeal joints
Adductor pollicis	<b>4</b>	Transverse head—metacarpal III; oblique head—capitate and bases of metacarpals II and III	Base of proximal phalanx and extensor hood of thumb	Deep branch of ulnar nerve [CS, <b>T1</b> ]	Adducts thumb
Lumbricals (four muscles)	<b>5</b>	Tendons of flexor digitorum profundus	Extensor hoods of index, ring, middle, and little fingers	Medial two by the deep branch of the ulnar nerve; lateral two by digital branches of the median nerve	Flex metacarpophalangeal joints while extending interphalangeal joints





# HEAD AND NECK

---

# CONTENTS

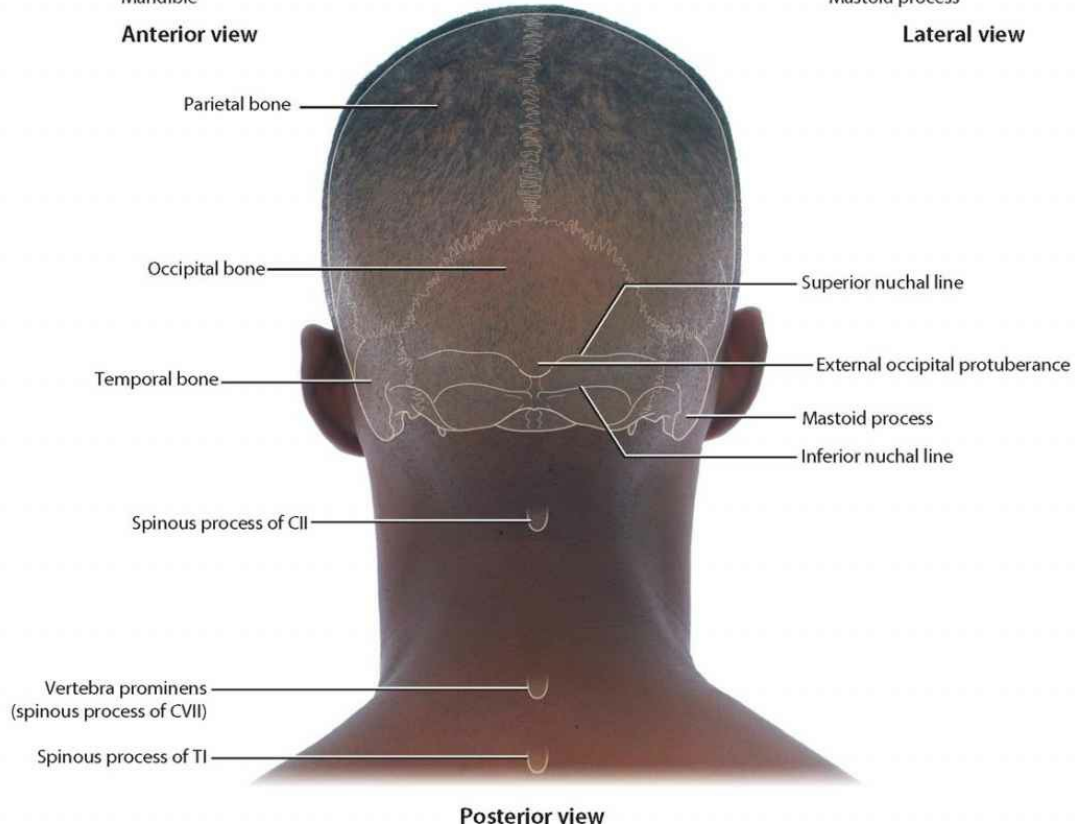
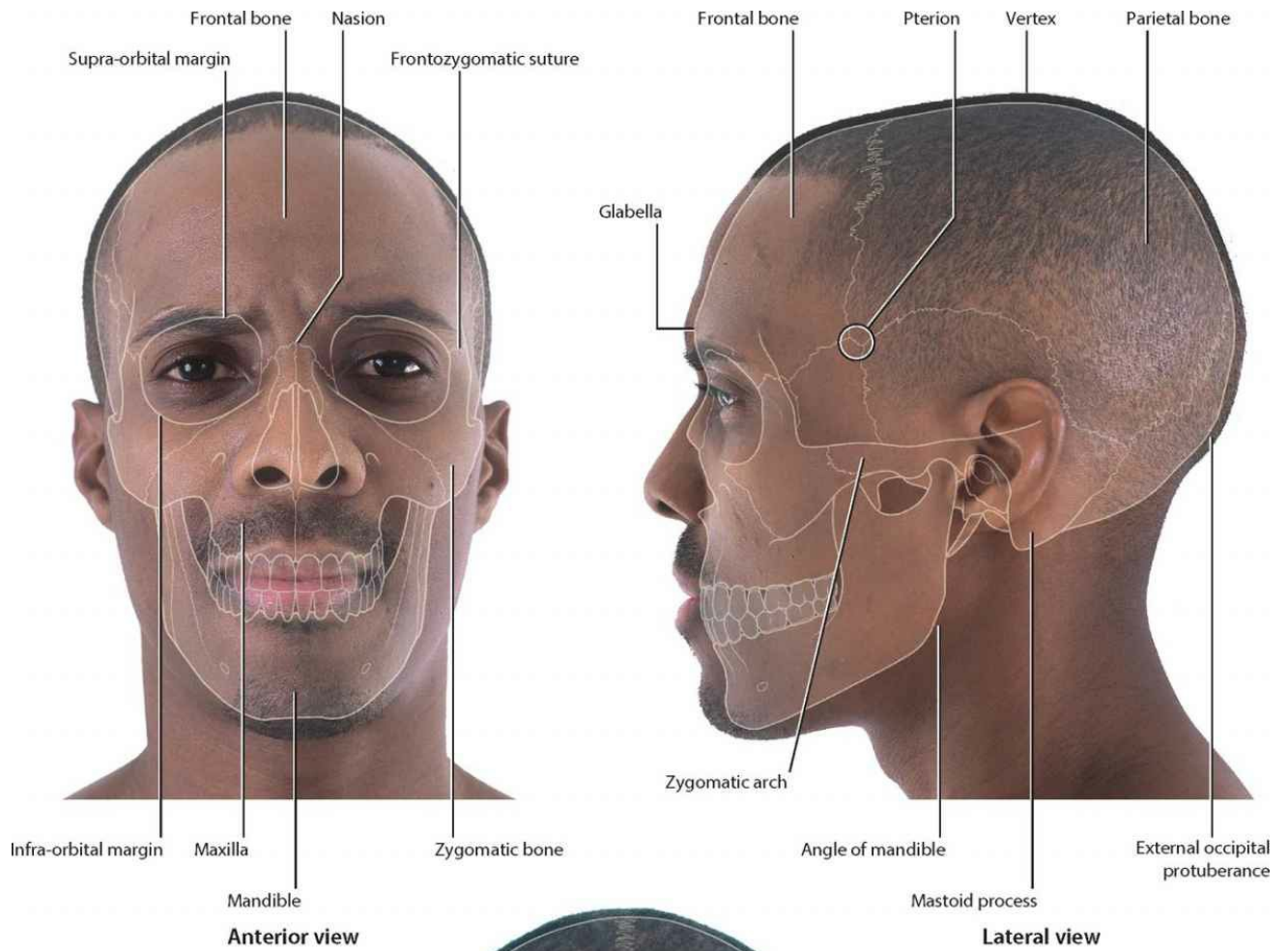
Surface anatomy with bones	478
Bones of the skull	479
Skull: anterior view	480
Skull: lateral view	482
Skull: posterior view	484
Skull: superior view and roof	485
Skull: inferior view	486
Skull: cranial cavity	487
Ethmoid, lacrimal bone, inferior concha, and vomer	488
Maxilla and palatine bone	489
Skull: muscle attachments	490
Scalp and meninges	492
Dural partitions	493
Dural arteries and nerves	494
Dural venous sinuses	495
Brain	496
Brain: imaging	498
Cranial nerves	500
Arterial supply to brain	502
Cutaneous distribution of trigeminal nerve [V]	505
Facial muscles	506
Vasculature, facial nerve [VII] and lymphatics	508
Deep arteries and veins of parotid region	509
Bony orbit	510
Section through orbit and structures of eyelid	511
Eyelids and lacrimal apparatus	512
Innervation of the lacrimal gland	513
Muscles of the eyeball	514
Innervation of the orbit and eyeball	515

Eye movements [516](#)  
Vasculature of orbit [517](#)  
Eyeball [518](#)  
Eye imaging [519](#)  
Ear surface and sensory innervation [522](#)  
Ear [523](#)  
Middle ear [524](#)  
Internal ear [526](#)  
Ear imaging [527](#)  
Temporal and infratemporal fossae [528](#)  
Bones of the temporal and infratemporal fossae [529](#)  
Temporal and infratemporal fossae [530](#)  
Temporomandibular joint [532](#)  
Mandibular division of the trigeminal nerve [V] [533](#)  
Parasympathetic innervation [534](#)  
Arteries and veins of temporal and infratemporal fossae [535](#)  
Pterygopalatine fossa [536](#)  
Neck surface anatomy [538](#)  
Bones of the neck [539](#)  
Compartments and fascia of the neck [540](#)  
Superficial veins of the neck [541](#)  
Muscles of the neck [542](#)  
Nerves in the neck [544](#)  
Cranial nerves in the neck [545](#)  
Cervical plexus and sympathetic trunk [546](#)  
Arteries of the neck [548](#)  
Root of the neck: arteries [550](#)  
Lymphatics of the neck [552](#)  
Pharynx [554](#)  
Muscles of the pharynx [556](#)  
Innervation of the pharynx [558](#)  
Vasculature of the pharynx [559](#)

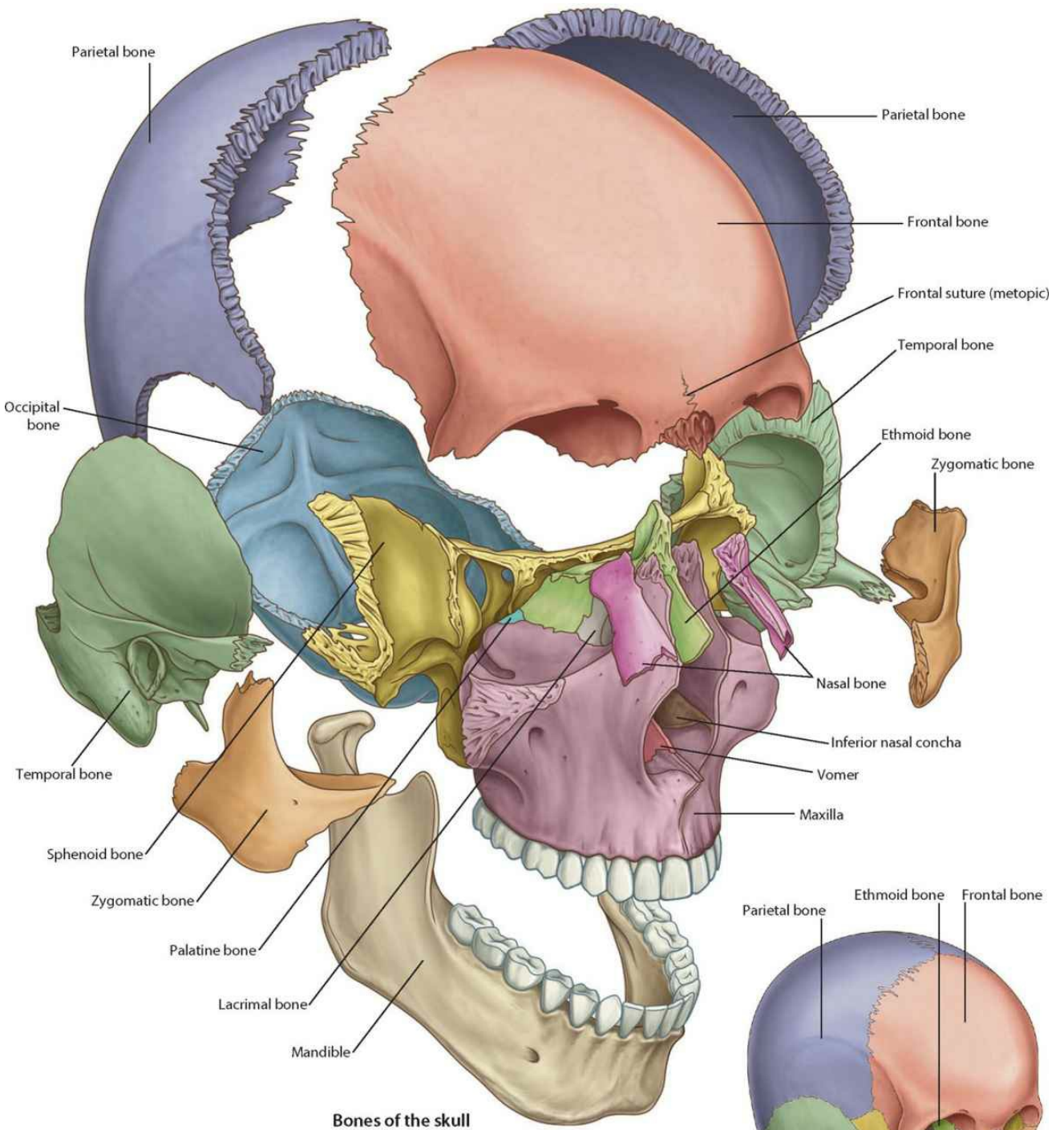


Larynx [560](#)  
Laryngeal cavity [562](#)  
Muscles of the larynx [563](#)  
Innervation of the larynx [564](#)  
Thyroid gland [565](#)  
Vasculature of the thyroid gland [566](#)  
Nose and paranasal sinuses [568](#)  
Nasal cavity: bones [569](#)  
Nasal cavity: mucosal linings [570](#)  
Vasculature and innervation of the nasal cavity [571](#)  
Sinus imaging [572](#)  
Oral cavity: bones [574](#)  
Teeth [575](#)  
Teeth: imaging [576](#)  
Anatomy of teeth [577](#)  
Vessels and nerves supplying teeth [578](#)  
Innervation of teeth and gums [579](#)  
Muscles and salivary glands of the oral cavity [580](#)  
Vessels and nerves of the tongue [581](#)  
Tongue [582](#)  
Hard and soft palate [583](#)  
Palate [584](#)  
Innervation of oral cavity [585](#)  
Cranial nerves [586](#)  
Visceral motor pathways in the head [588](#)  
Tables [589](#)

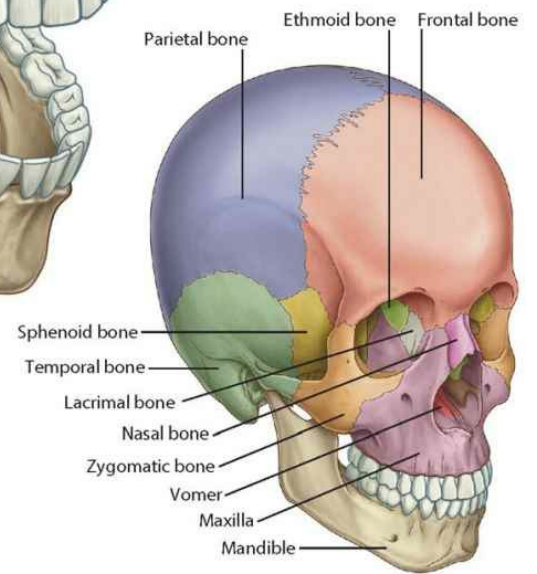
# Surface anatomy with bones



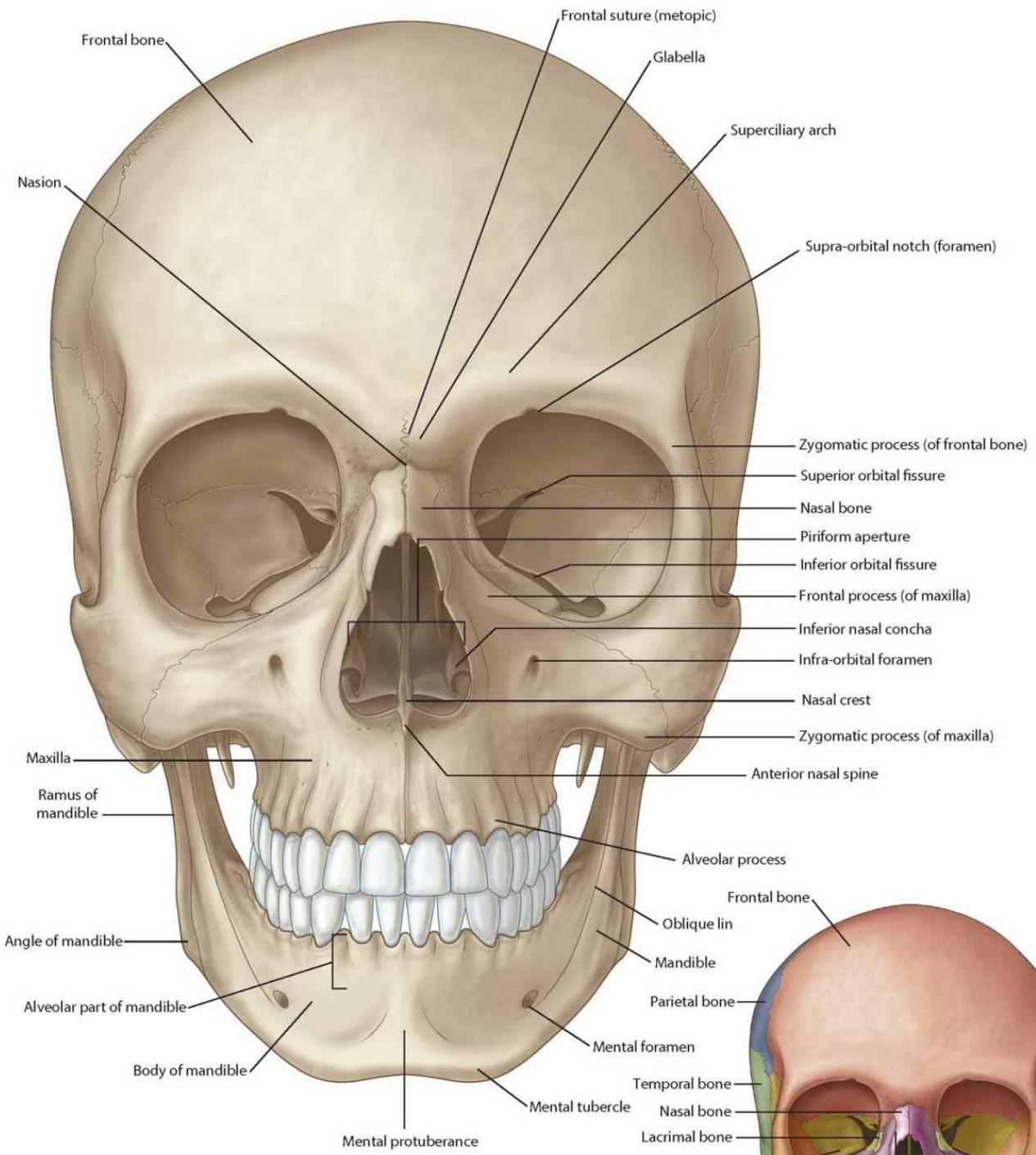
# Bones of the skull



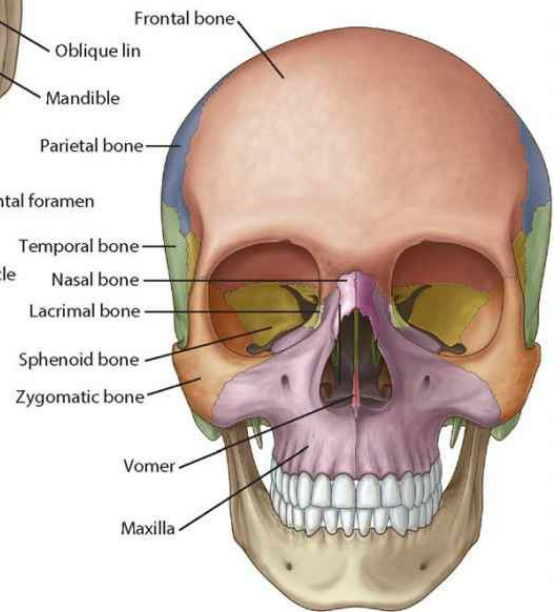
**Bones of the skull**

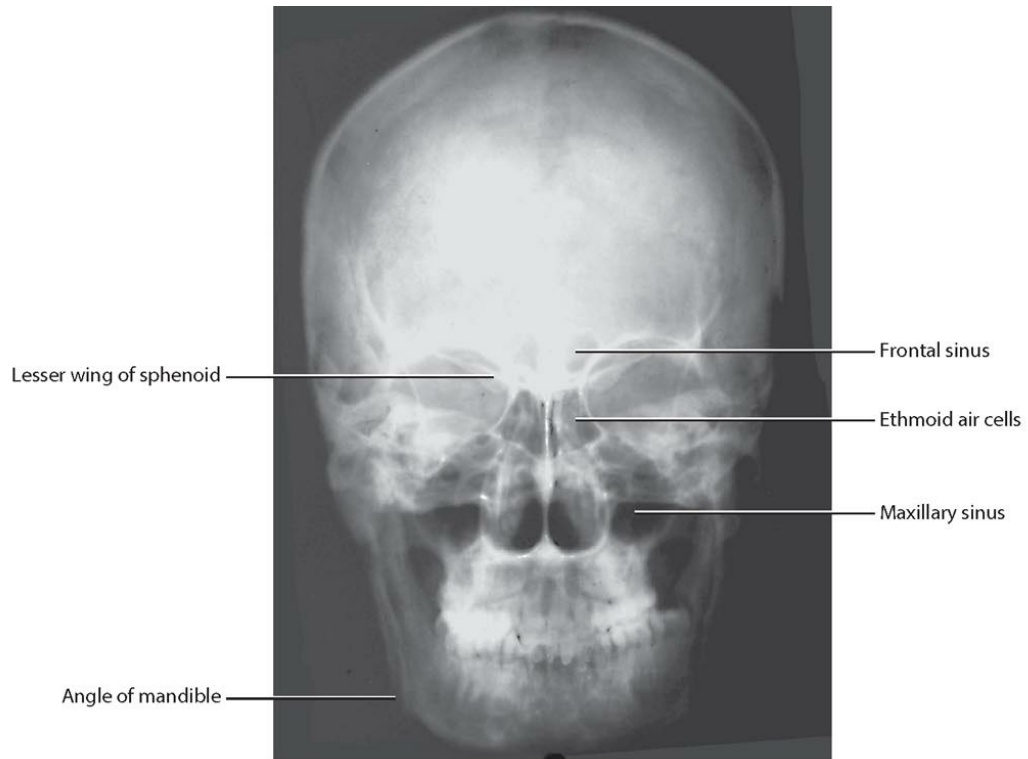


## Skull: anterior view

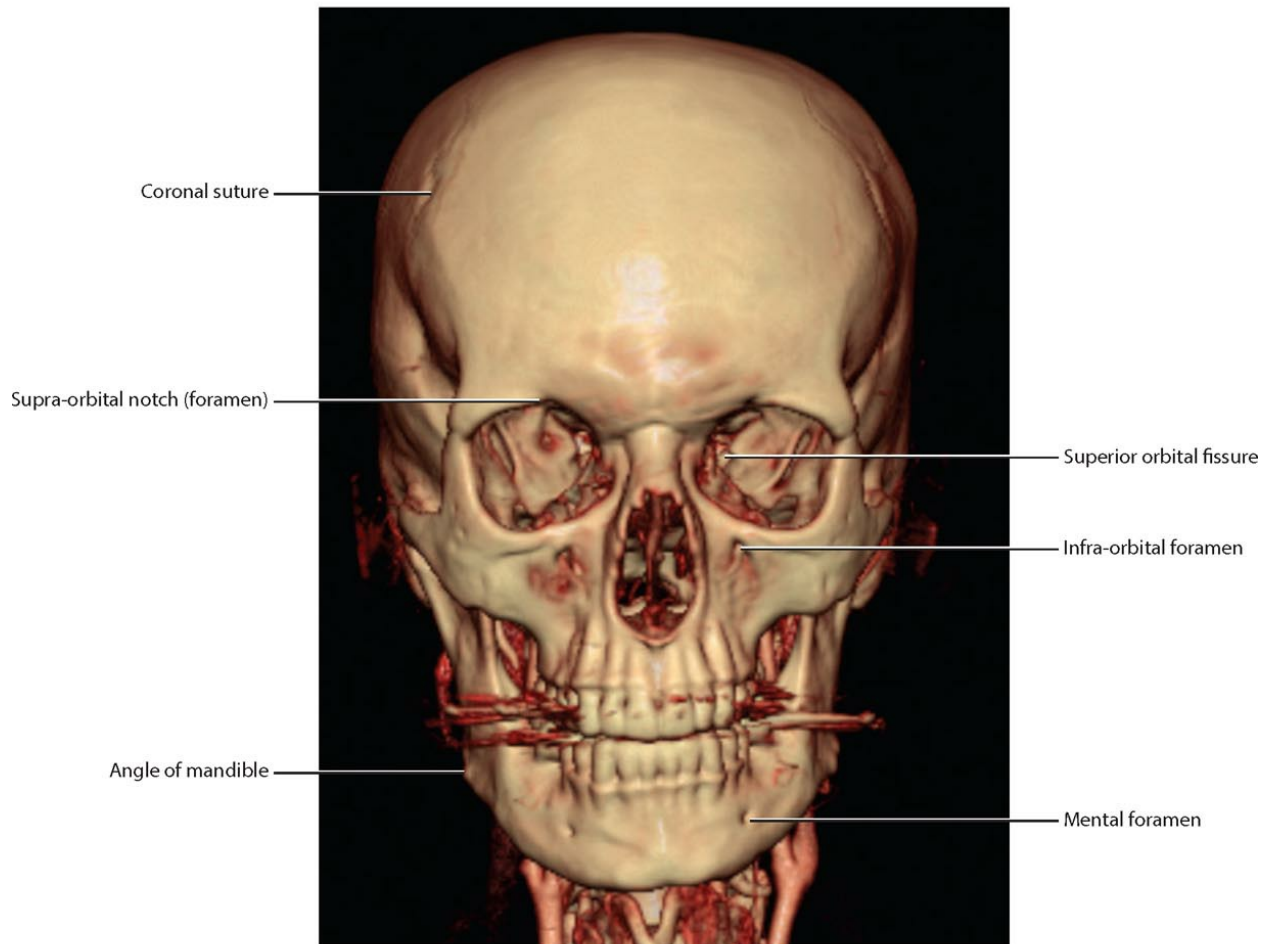


**Anterior view of the skull**





**Anterior view of the skull.**  
Radiograph, AP view

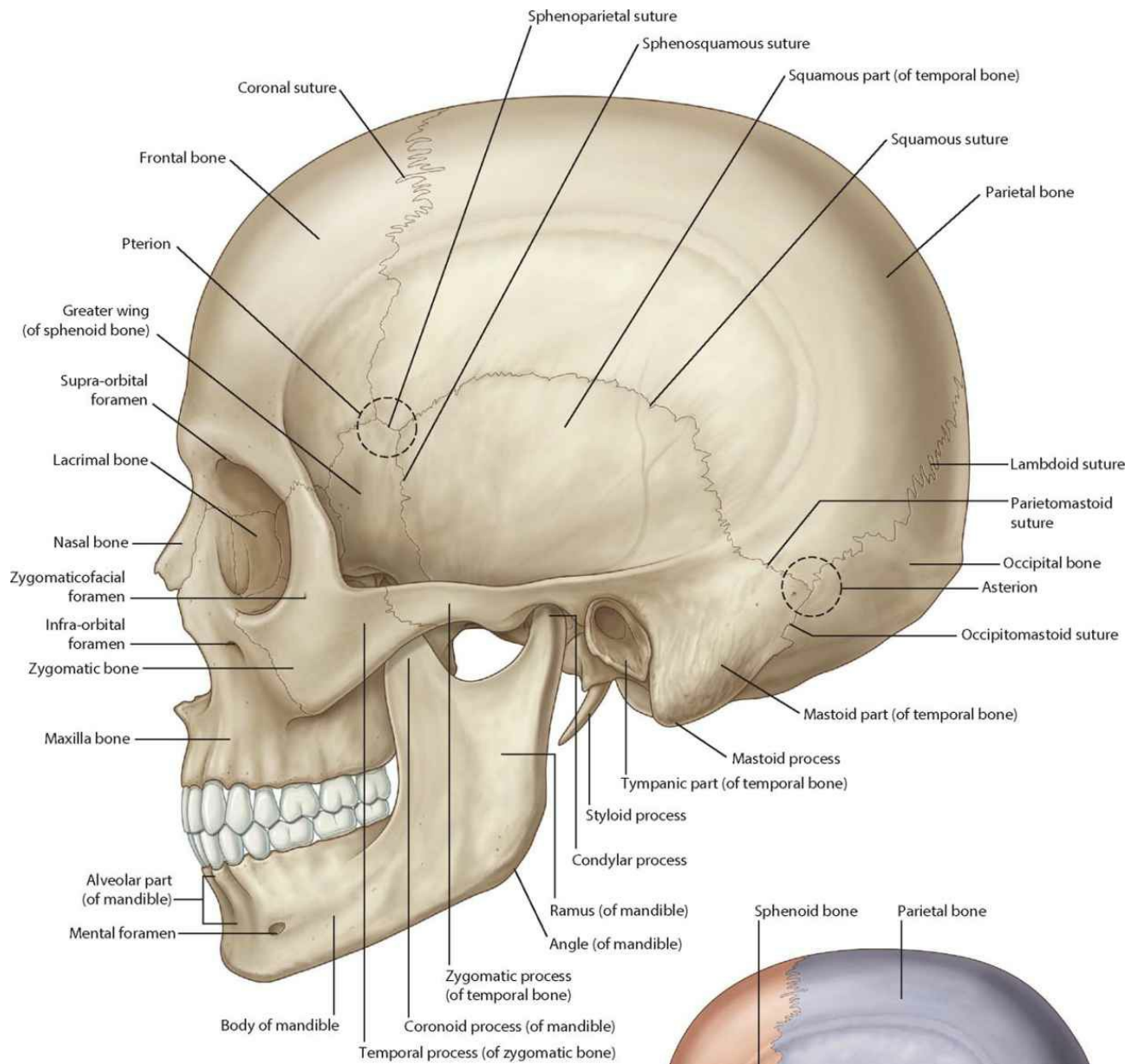


**Anterior view of the skull.**  
Volume-rendered anterior view using multidetector computed tomography

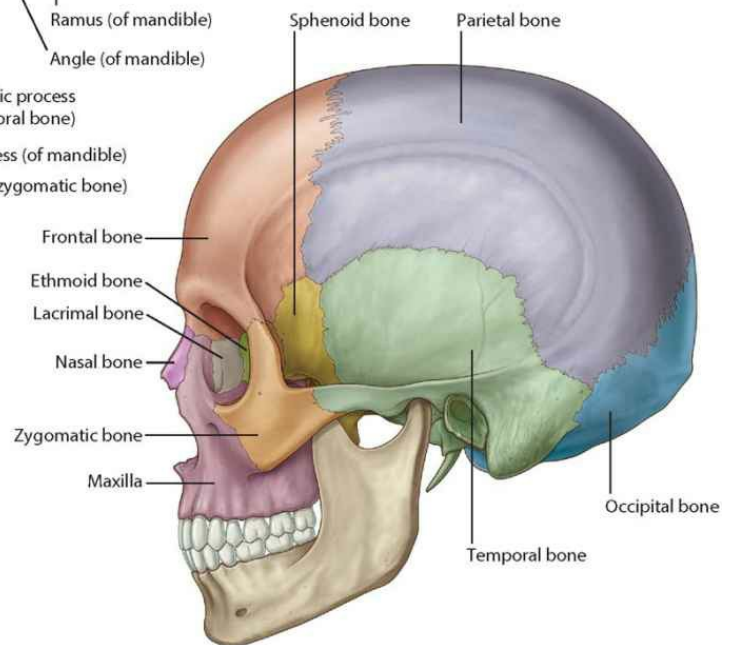


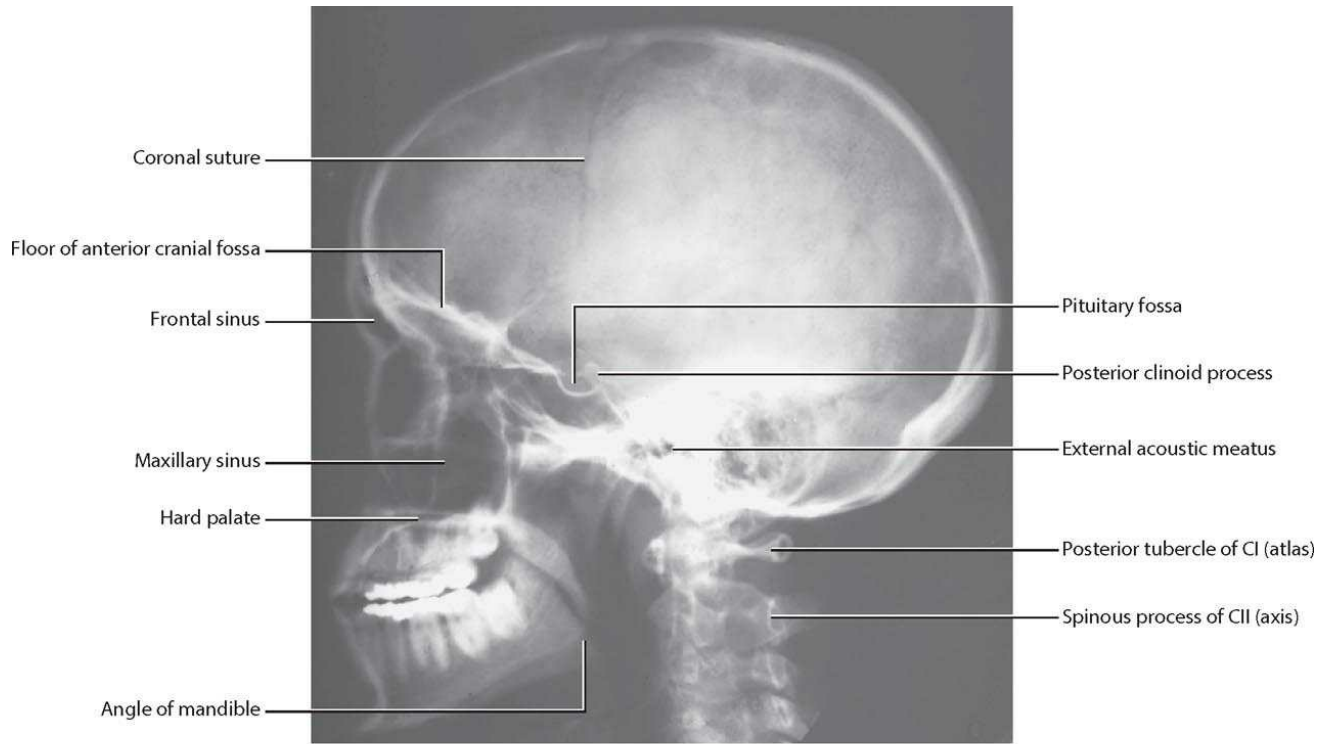


## Skull: lateral view

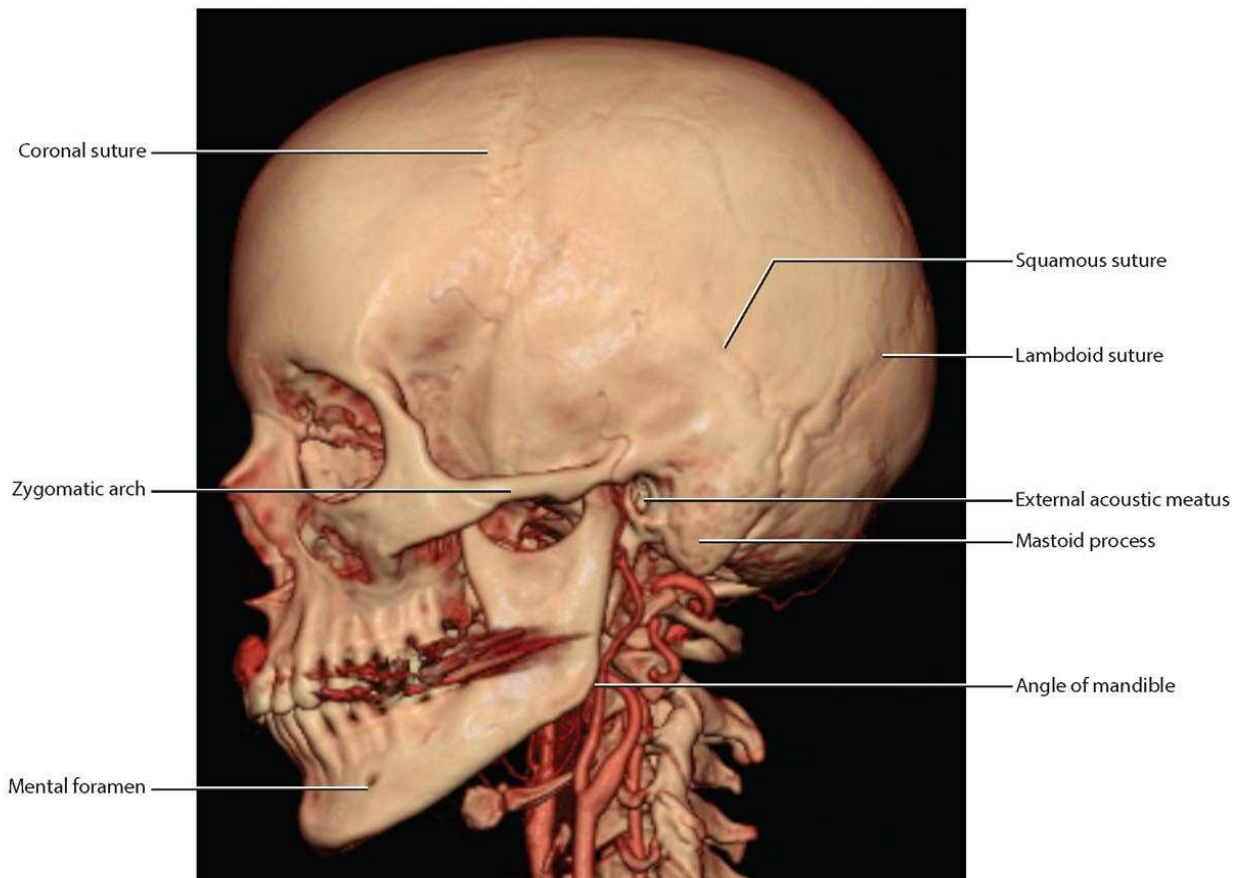


**Lateral view of the skull**





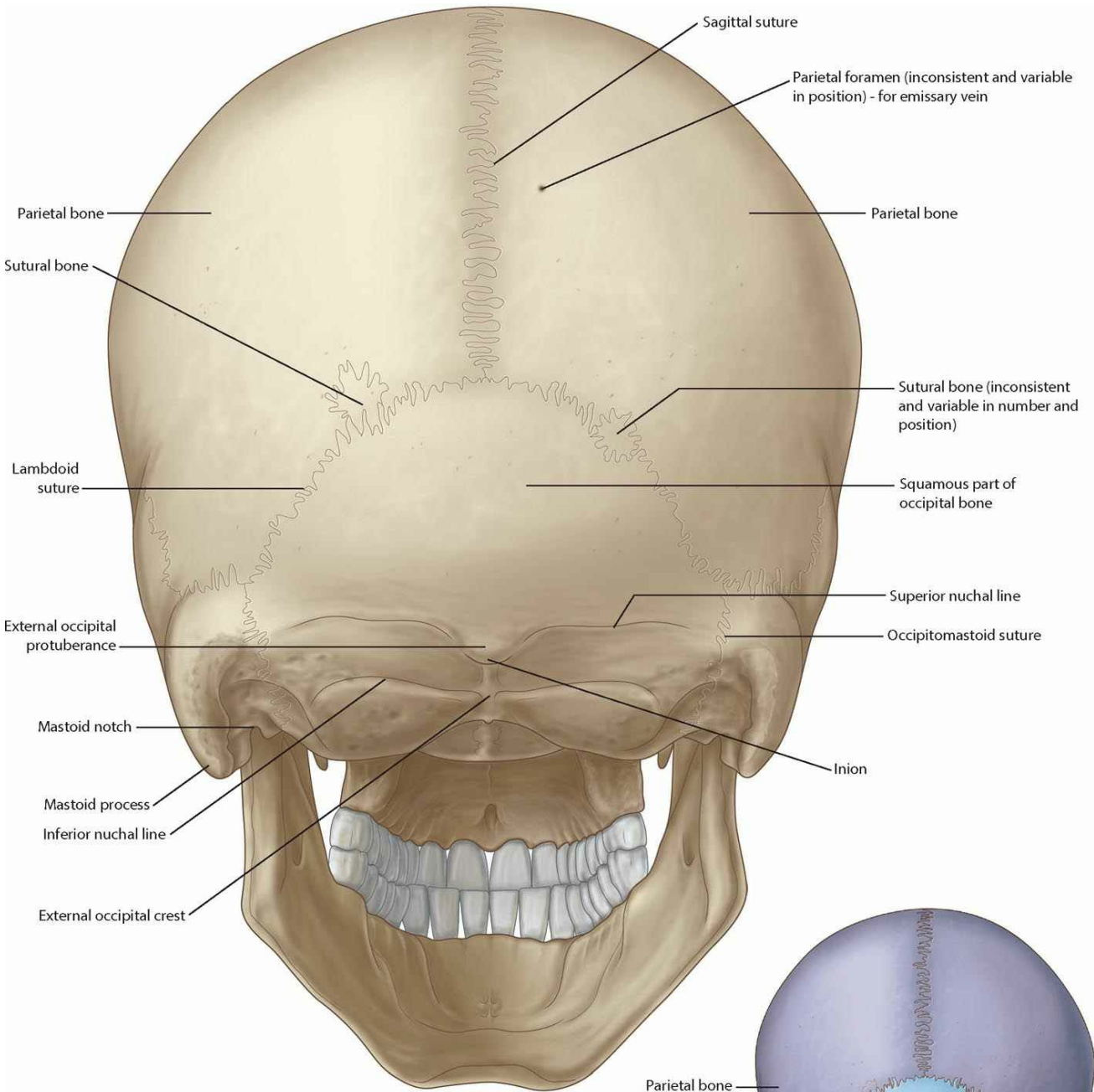
**Lateral view of the skull.**  
Radiograph, lateral view



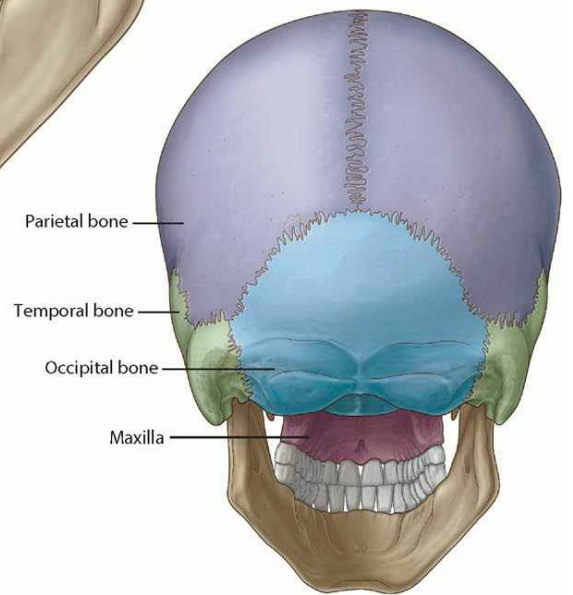
**Lateral view of the skull.**  
Volume-rendered lateral view using multidetector computed tomography



## Skull: posterior view

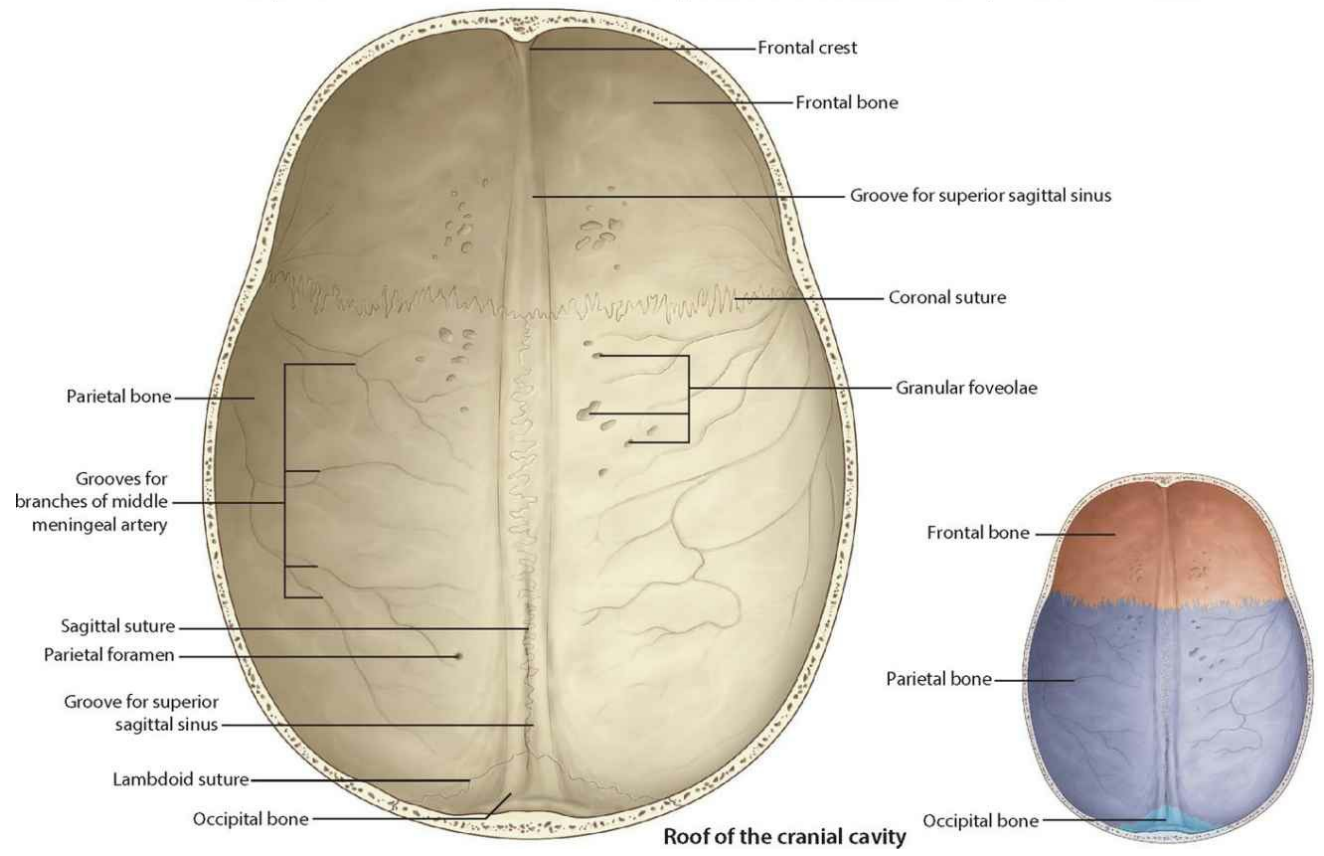
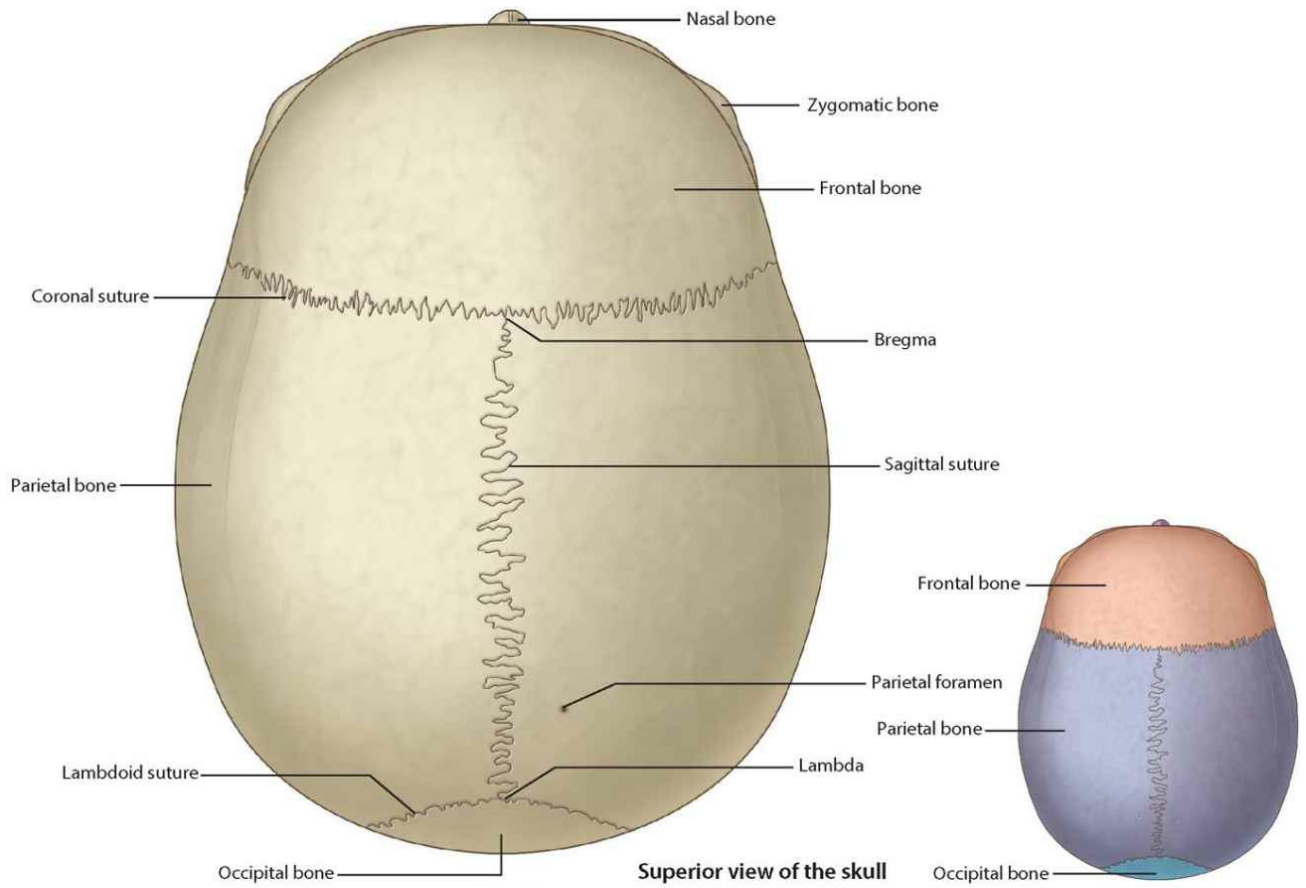


Posterior view of the skull

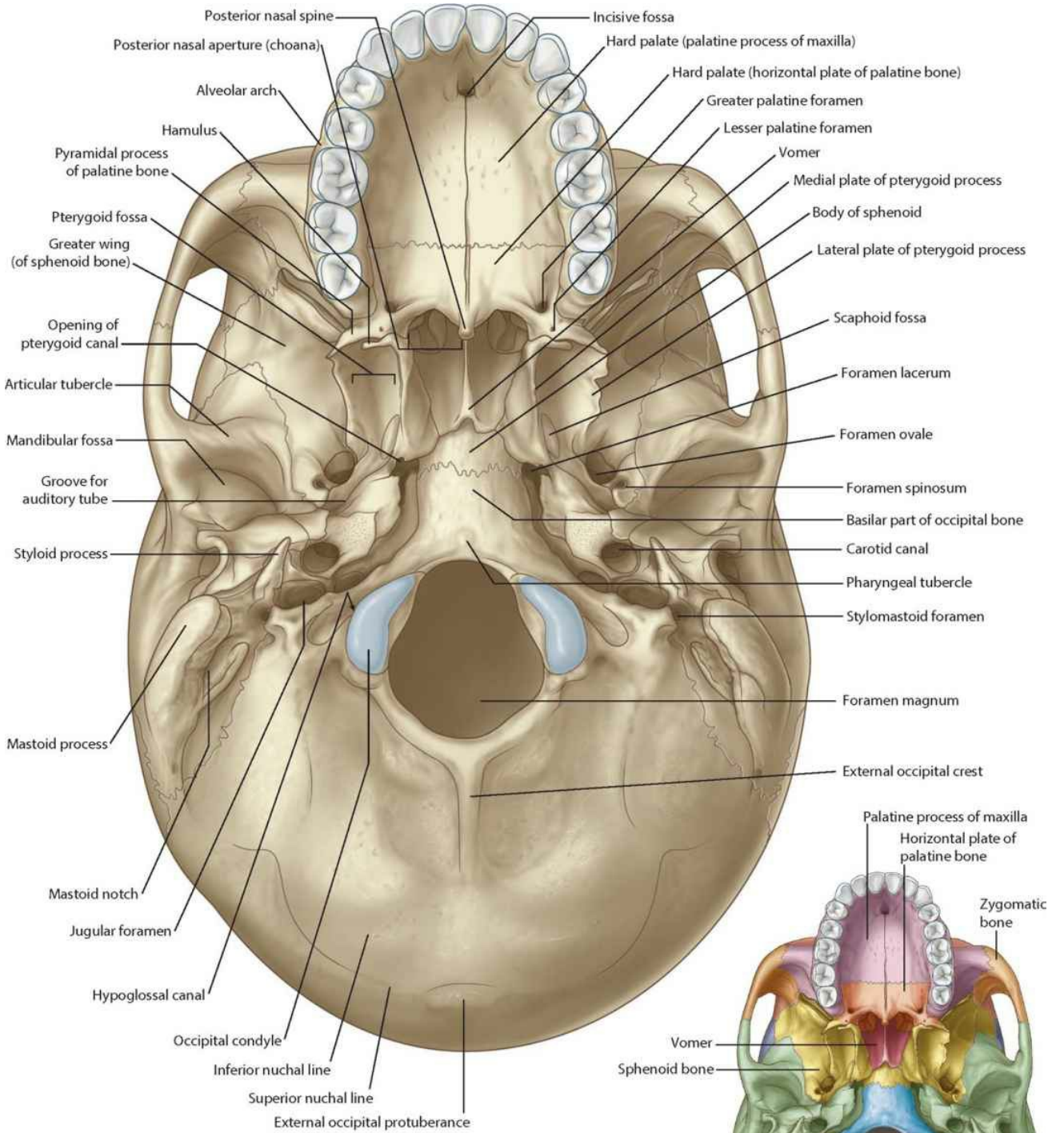


## **Skull: superior view and roof**

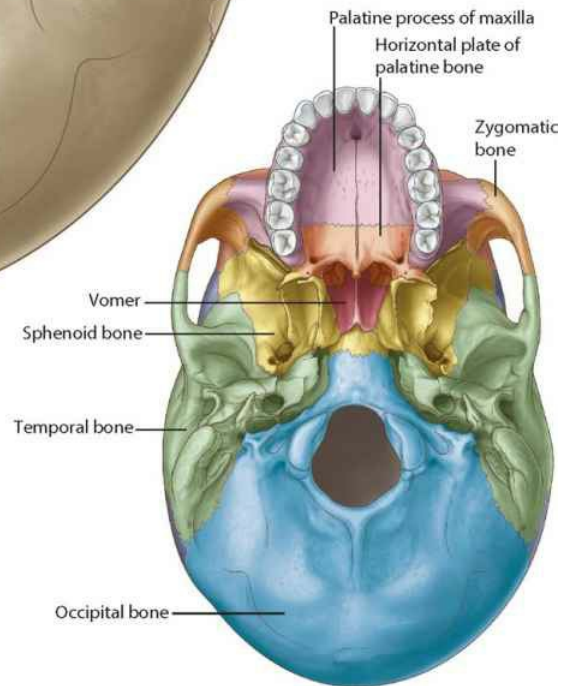




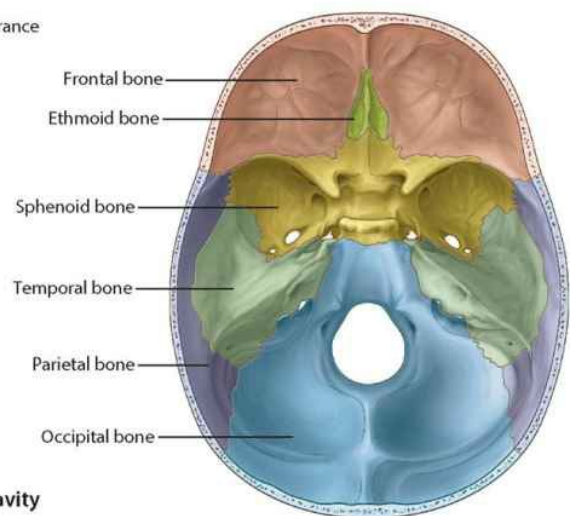
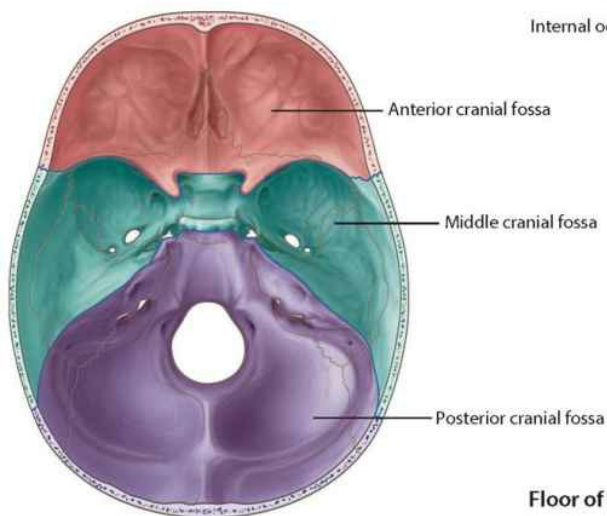
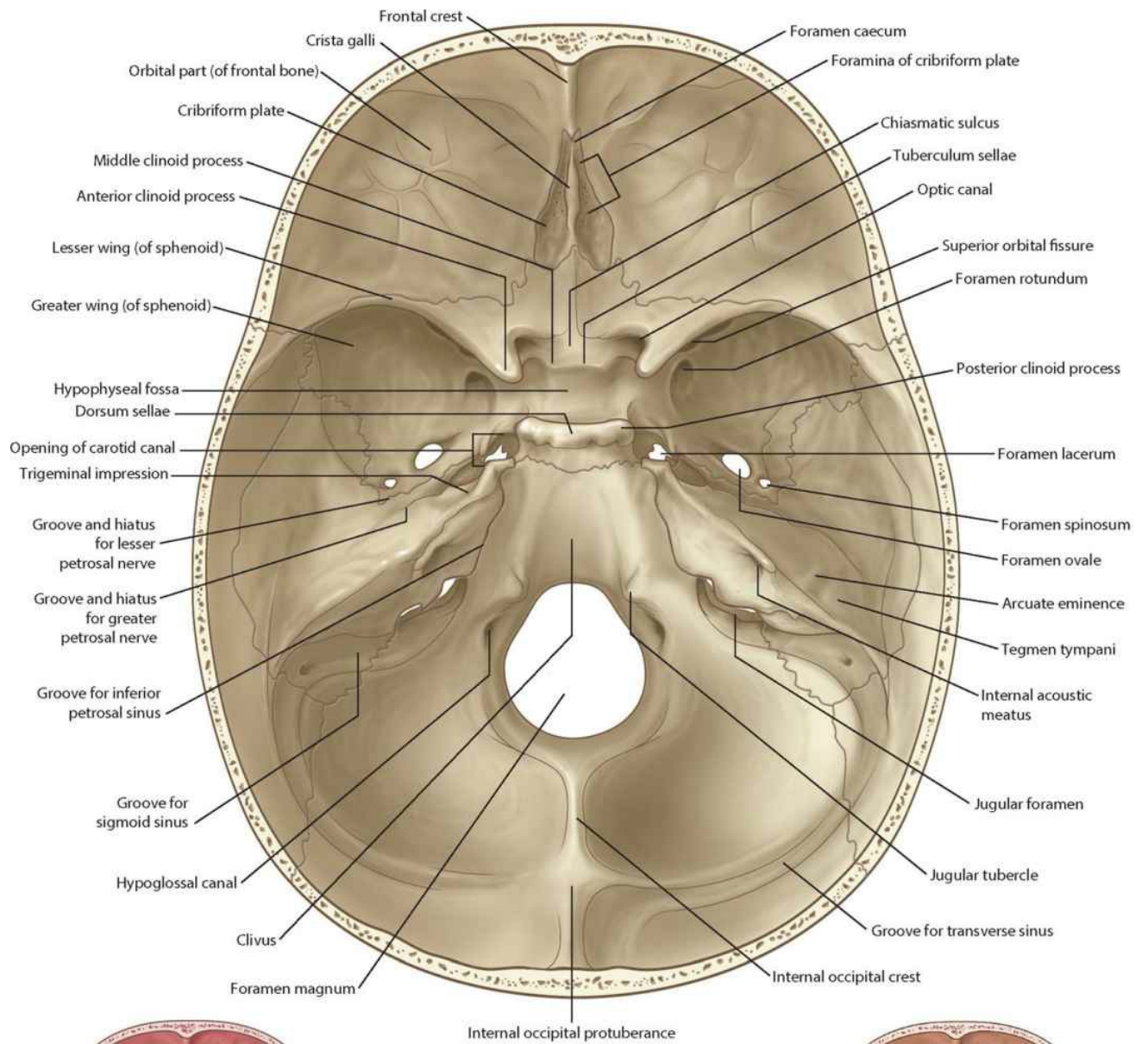
## Skull: inferior view



Inferior view of skull

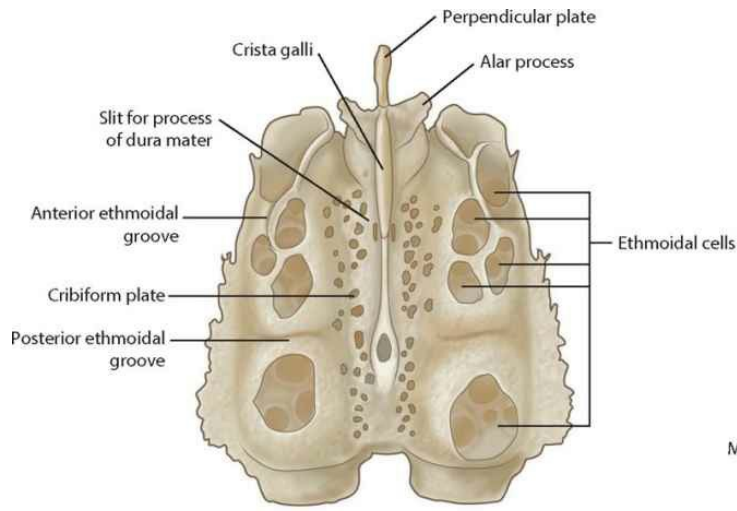


## Skull: cranial cavity

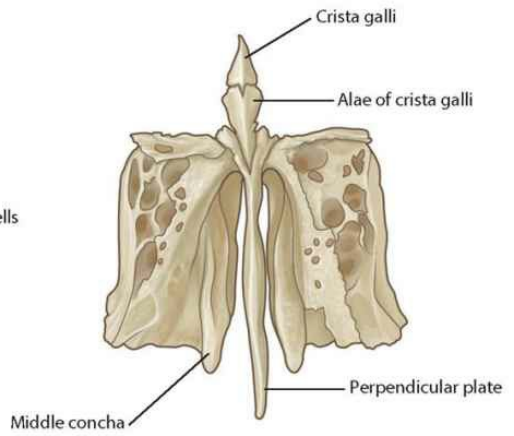


**Floor of the cranial cavity**

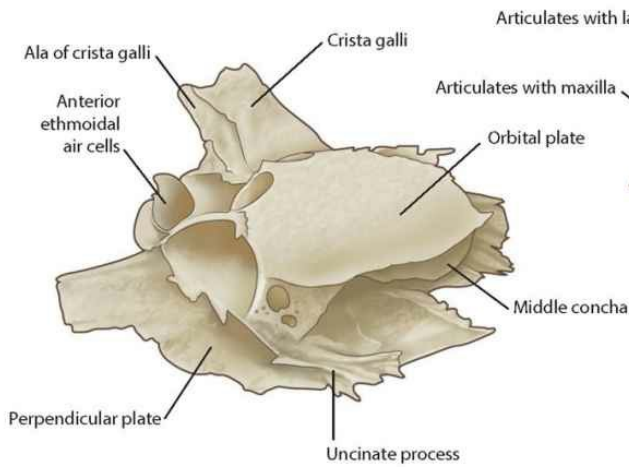
# **Ethmoid, lacrimal bone, inferior concha, and vomer**



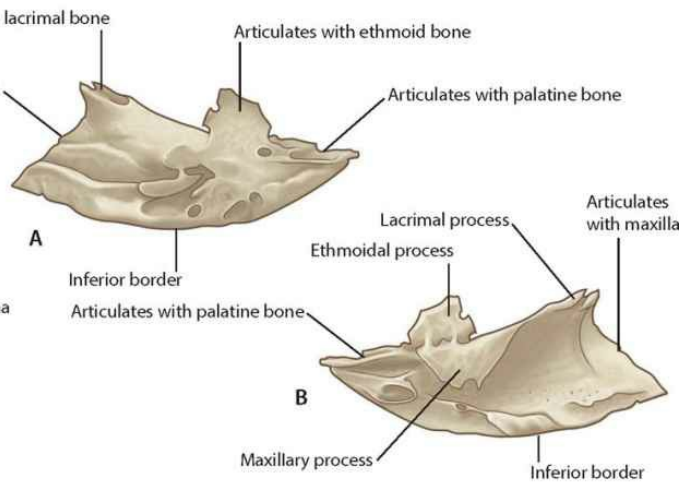
**Ethmoid bone (superior view)**



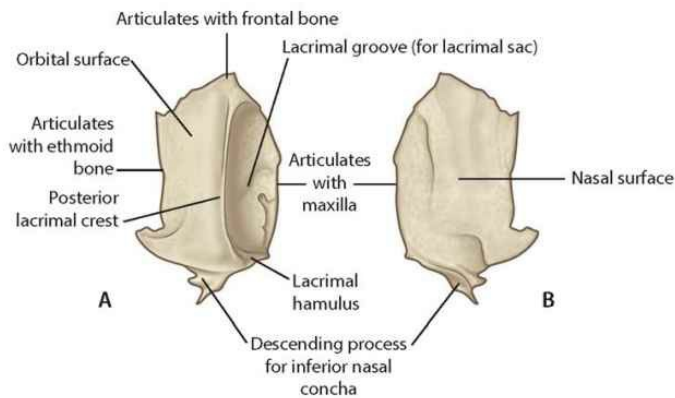
**Ethmoid bone (posterior view)**



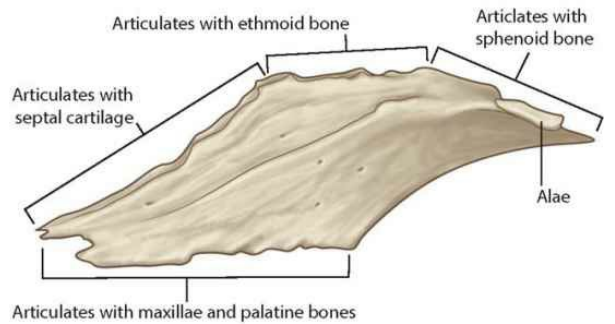
**Ethmoid bone (lateral view)**



**Right inferior concha  
A. Medial view B. Lateral view**



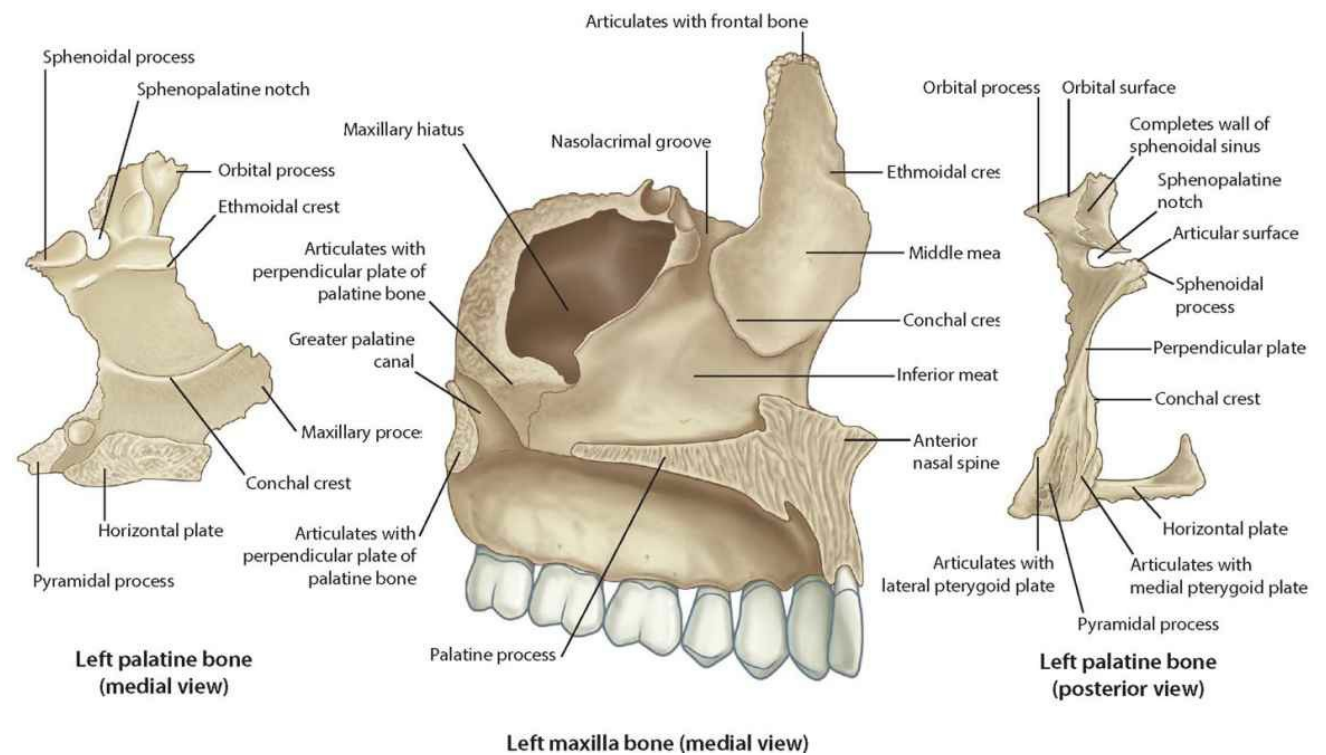
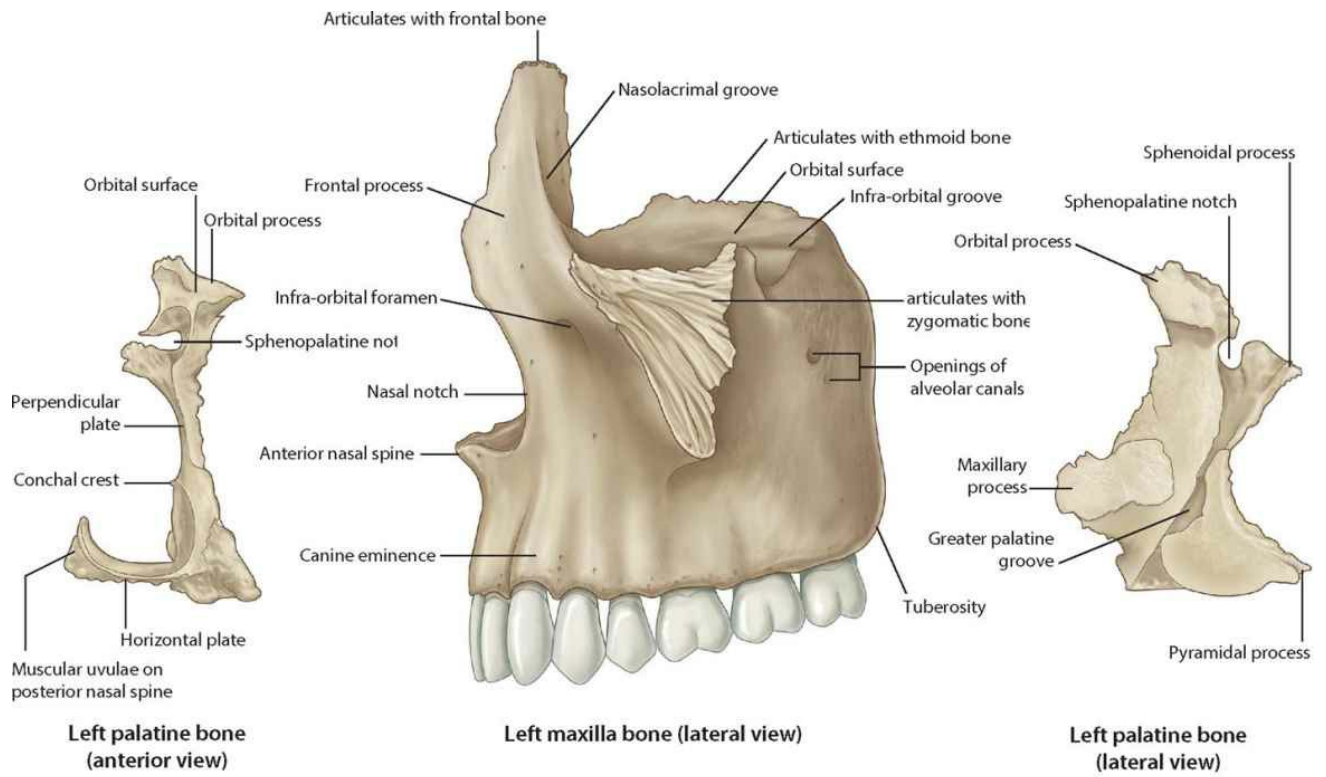
**Right lacrimal bone  
A. Lateral view B. Medial view**



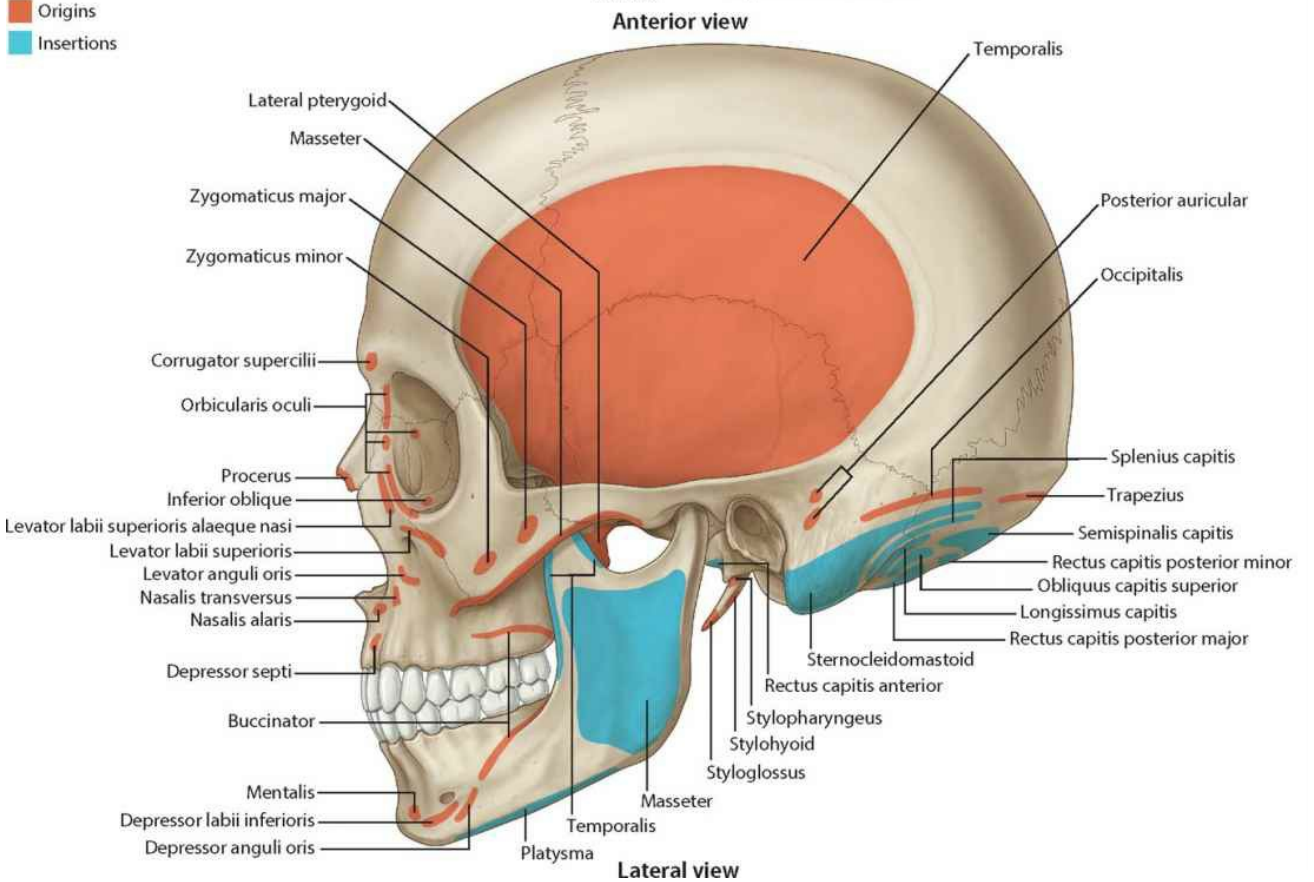
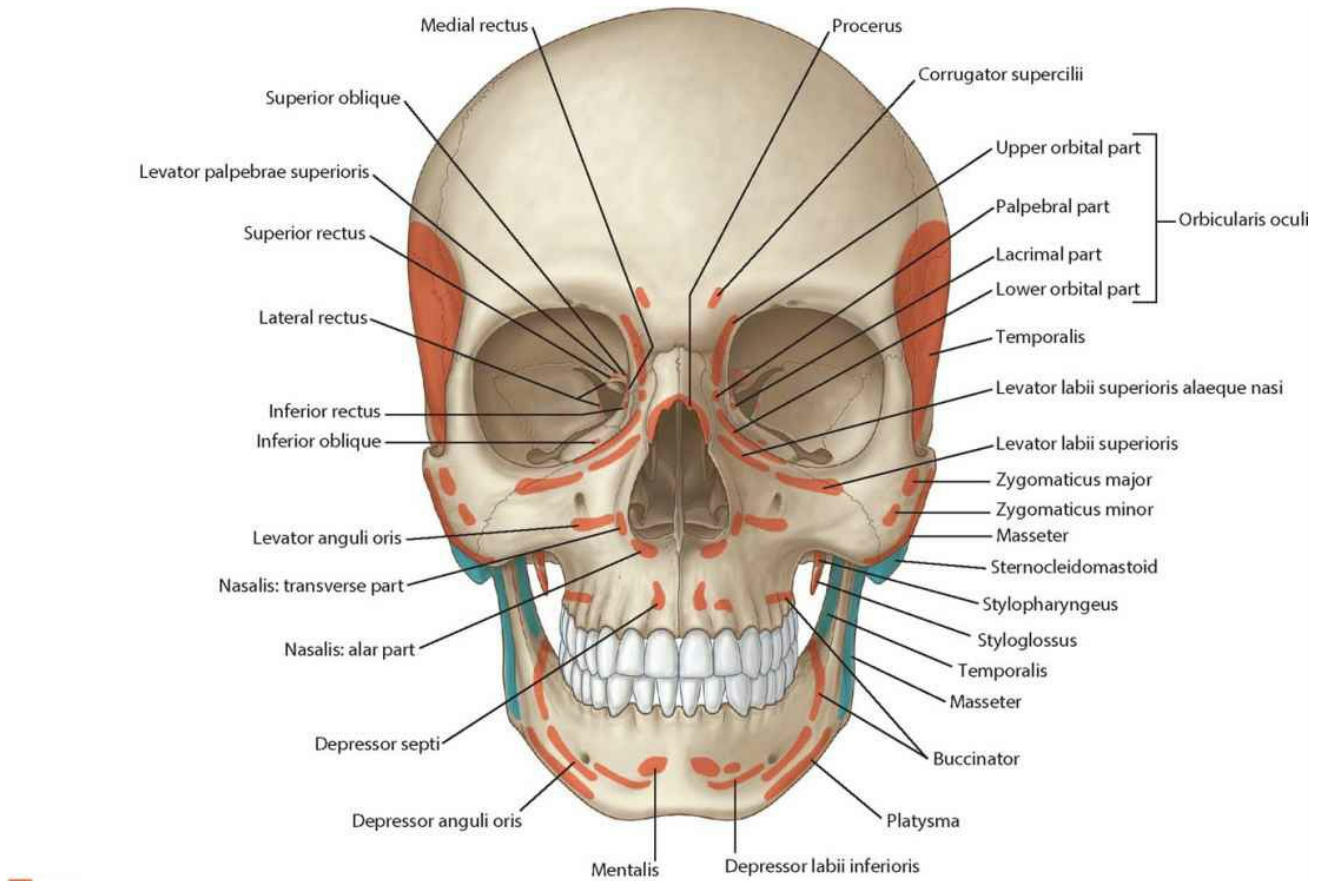
**Vomer (lateral view)**

# Maxilla and palatine bone

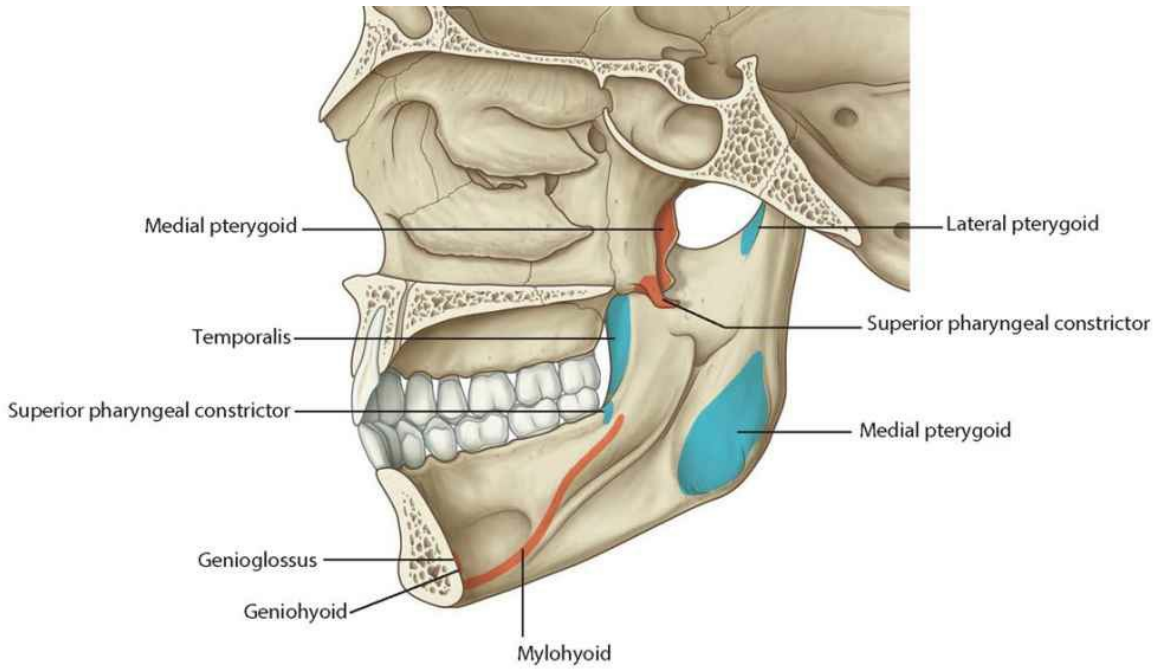




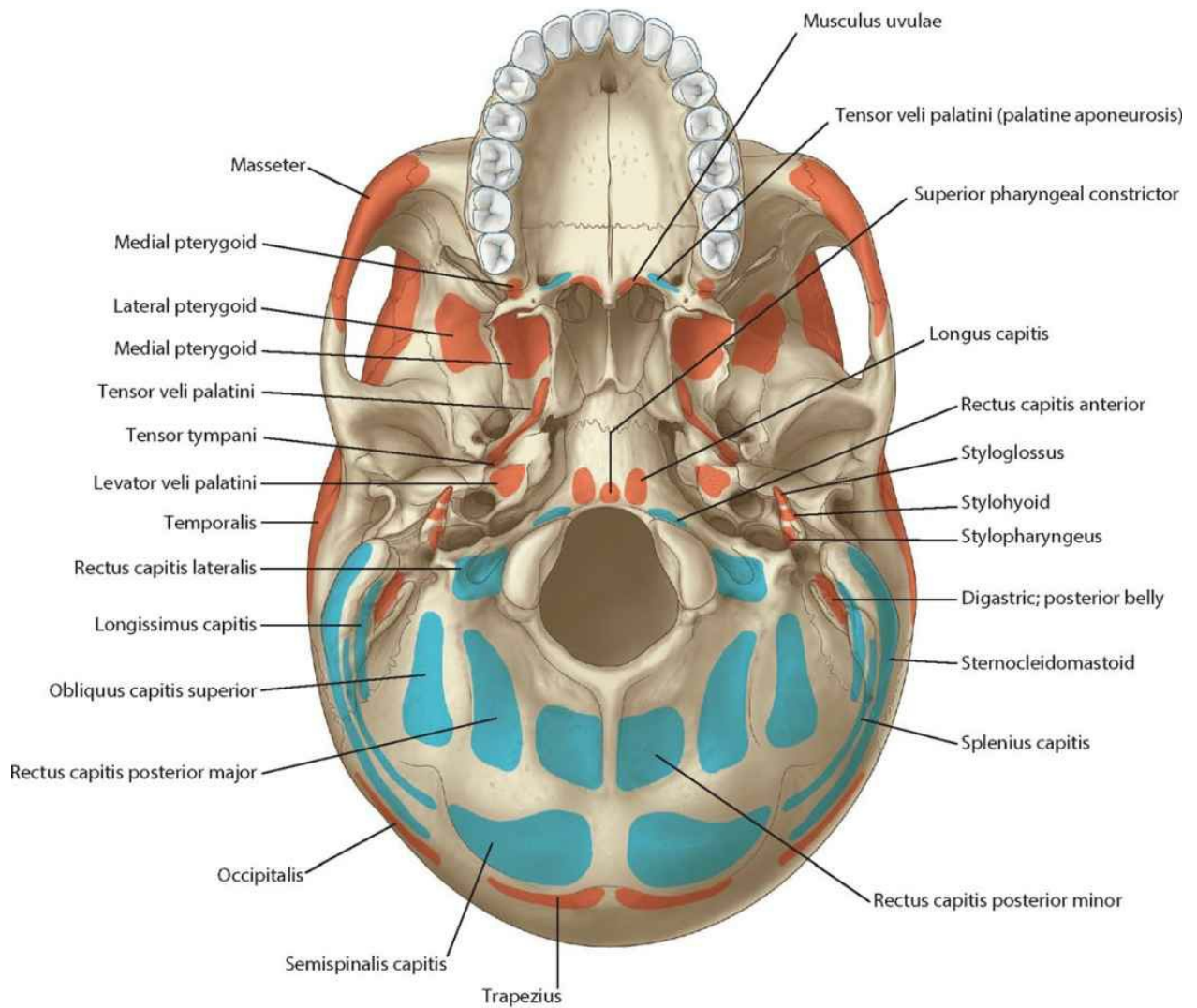
## **Skull: muscle attachments**







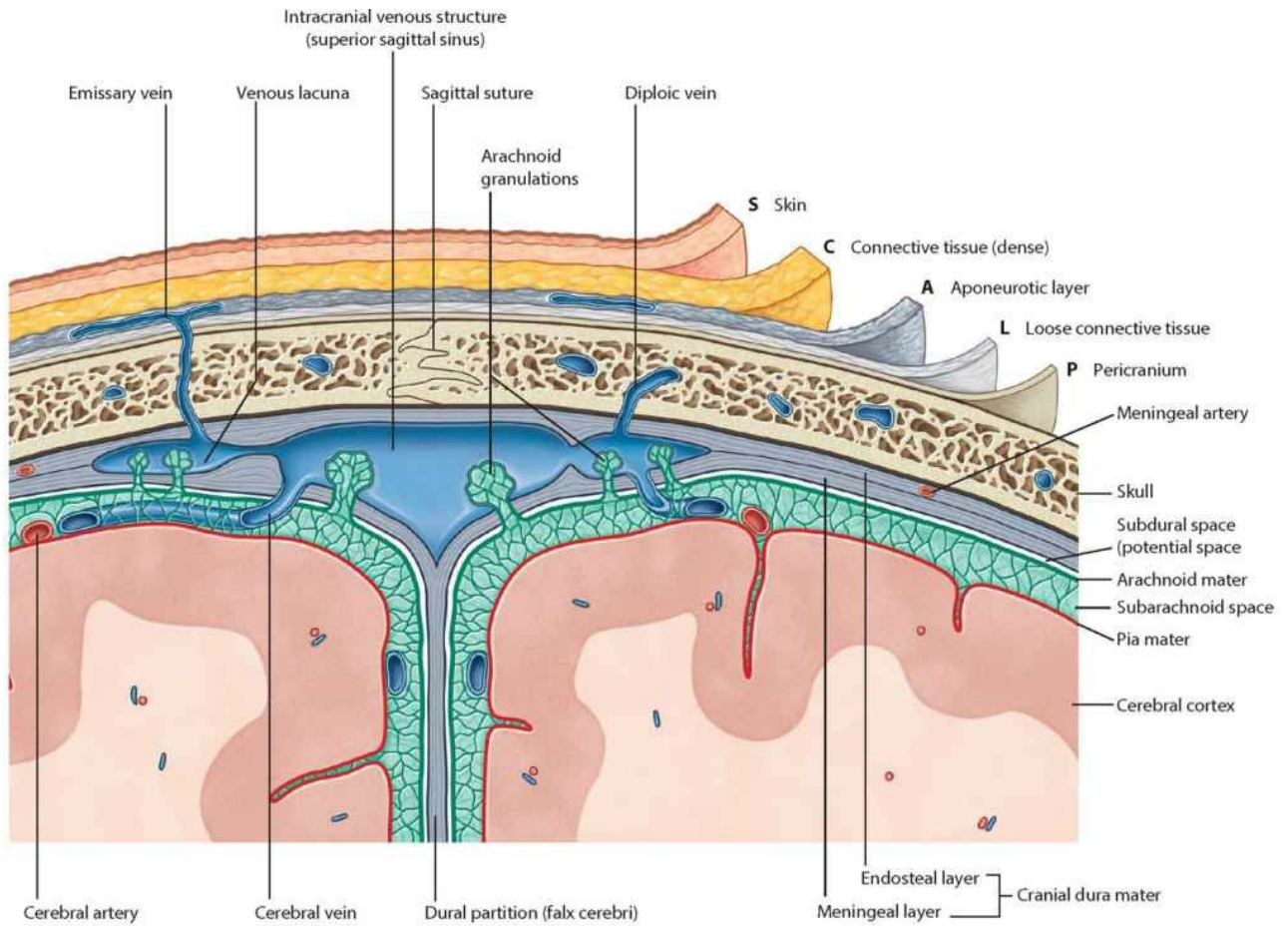
**Medial view**



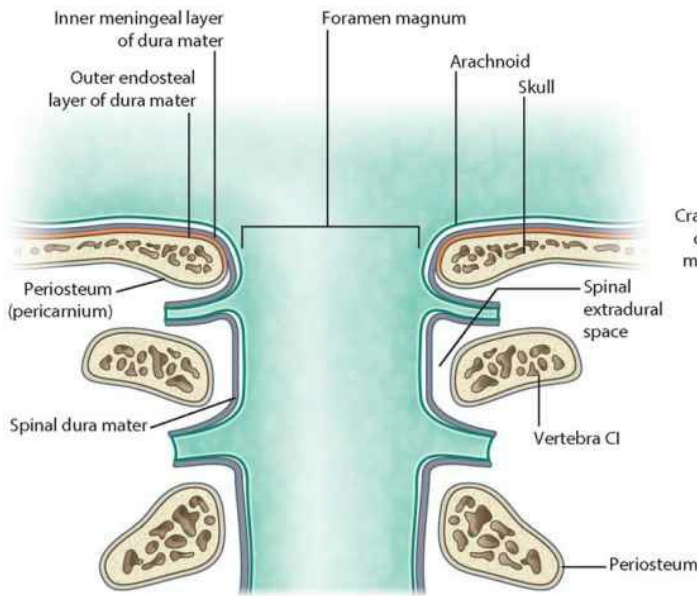
**Inferior view**



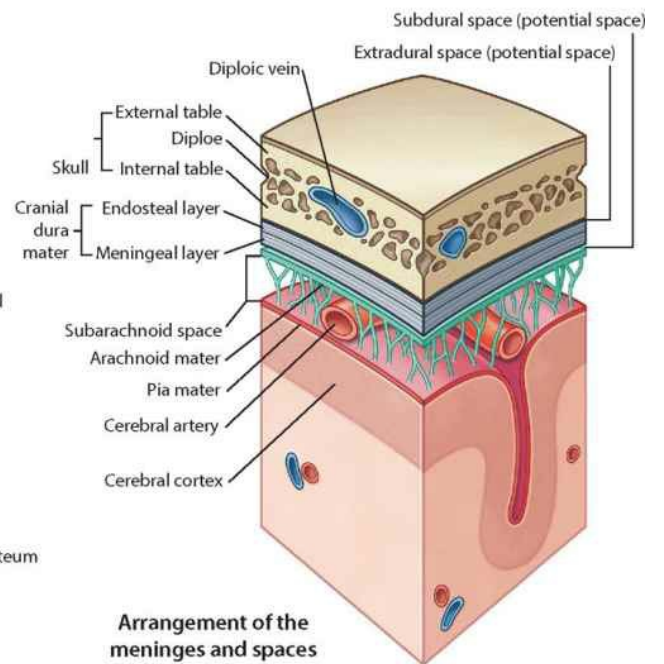
# Scalp and meninges



### Scalp and cranial meninges



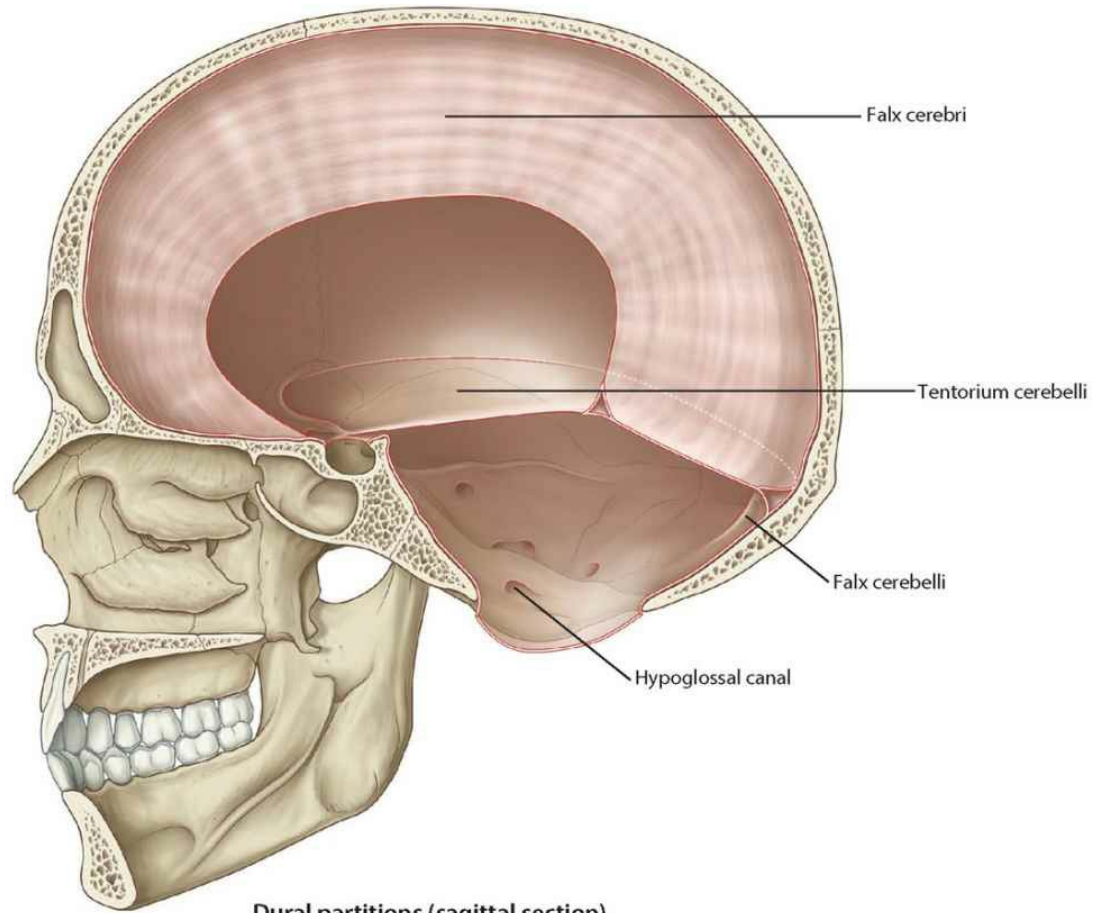
Continuity of cranial meninges with spinal meninges



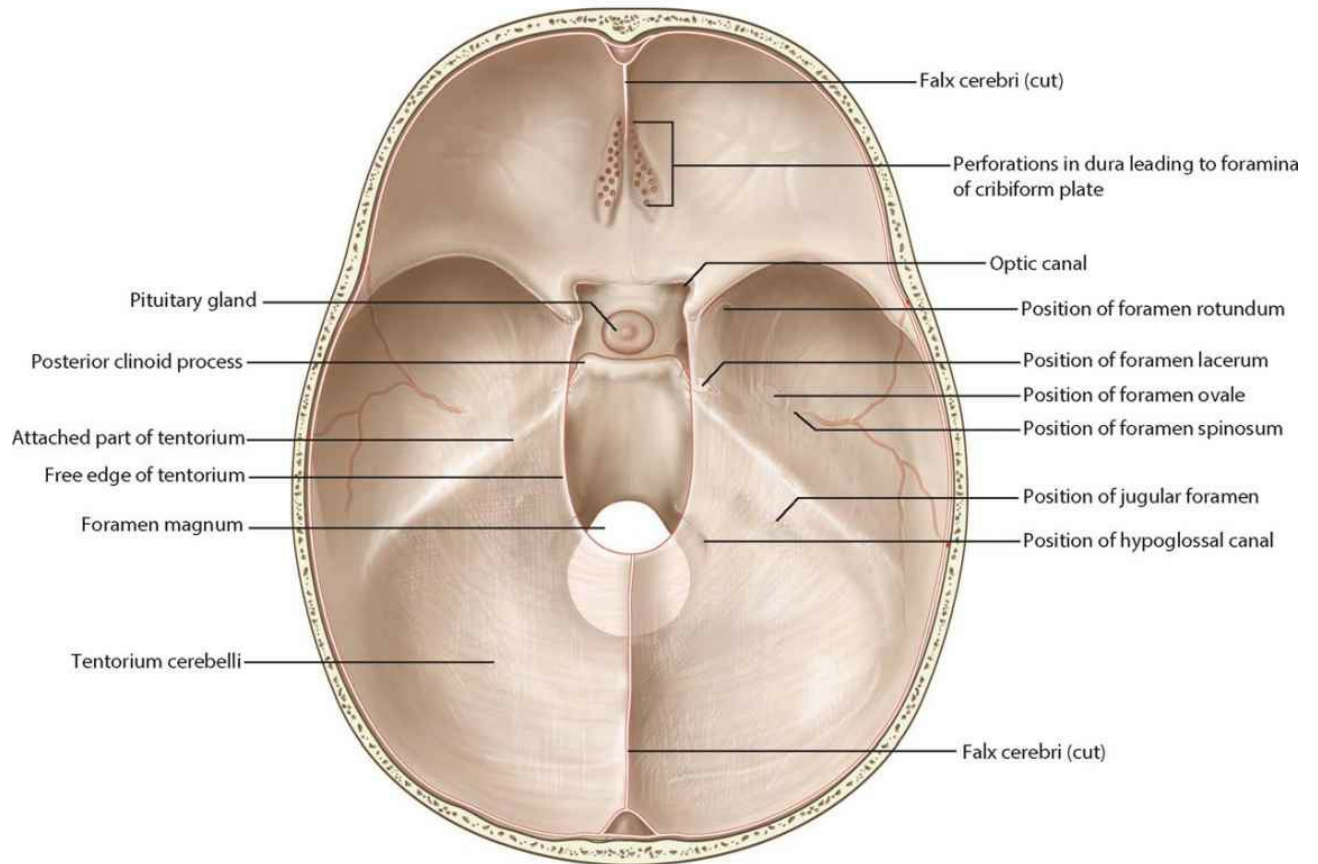
Arrangement of the meninges and spaces



# Dural partitions



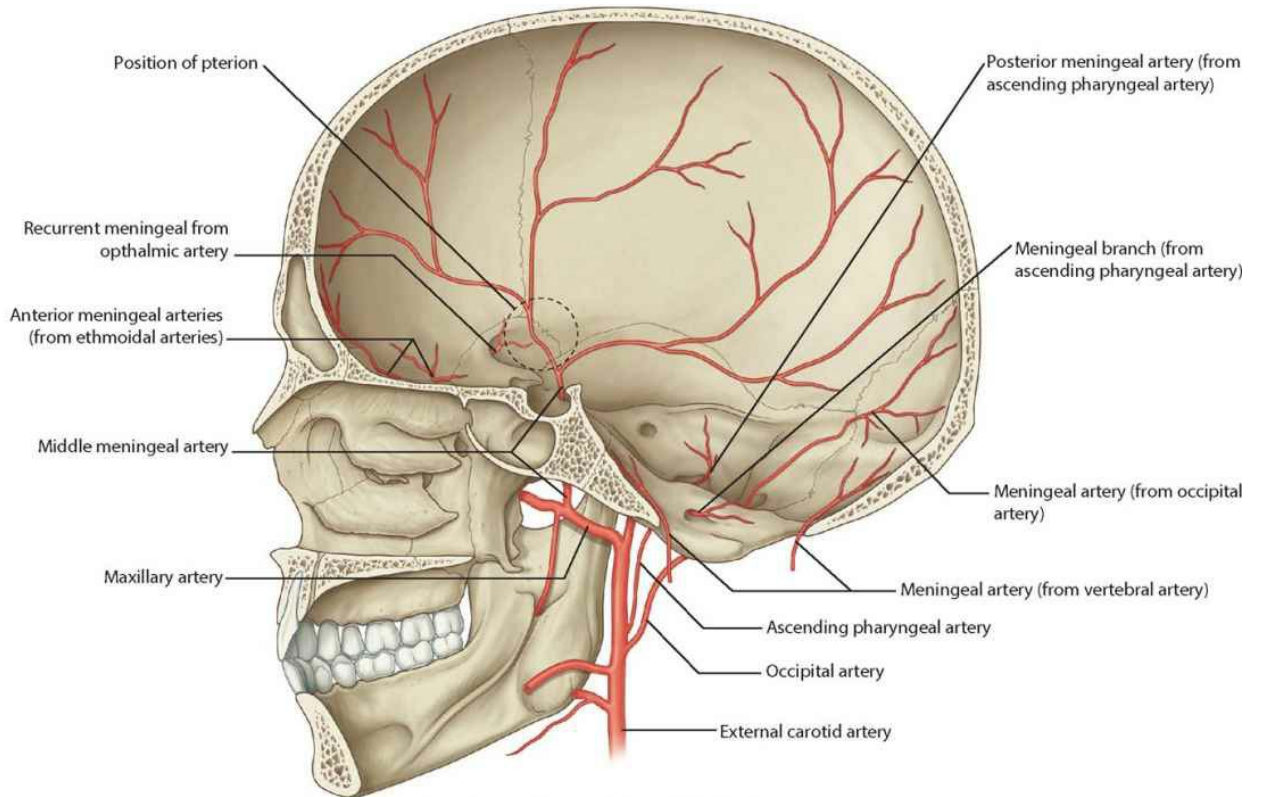
**Dural partitions (sagittal section)**



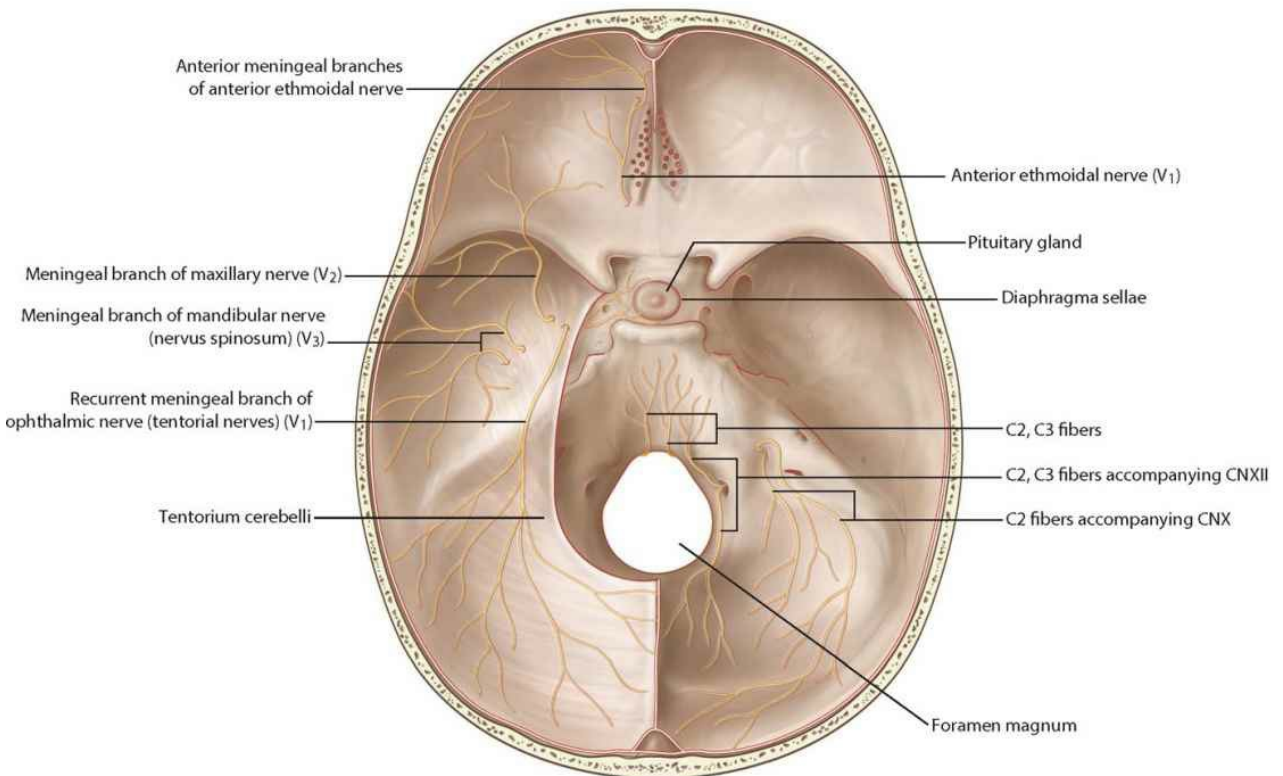
**Cranial cavity (superior view)**



## Dural arteries and nerves

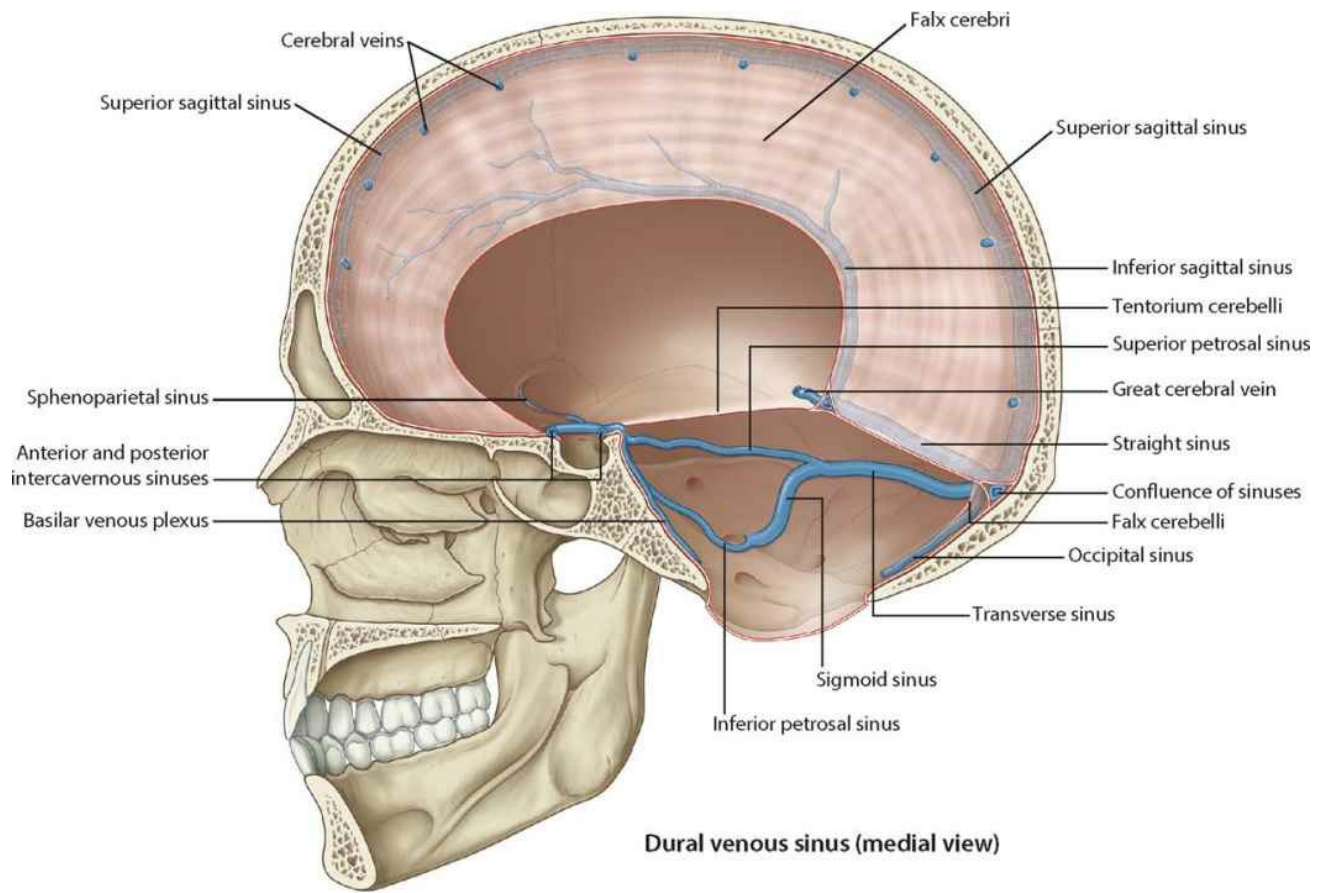


**Dural arterial supply (medial view)**

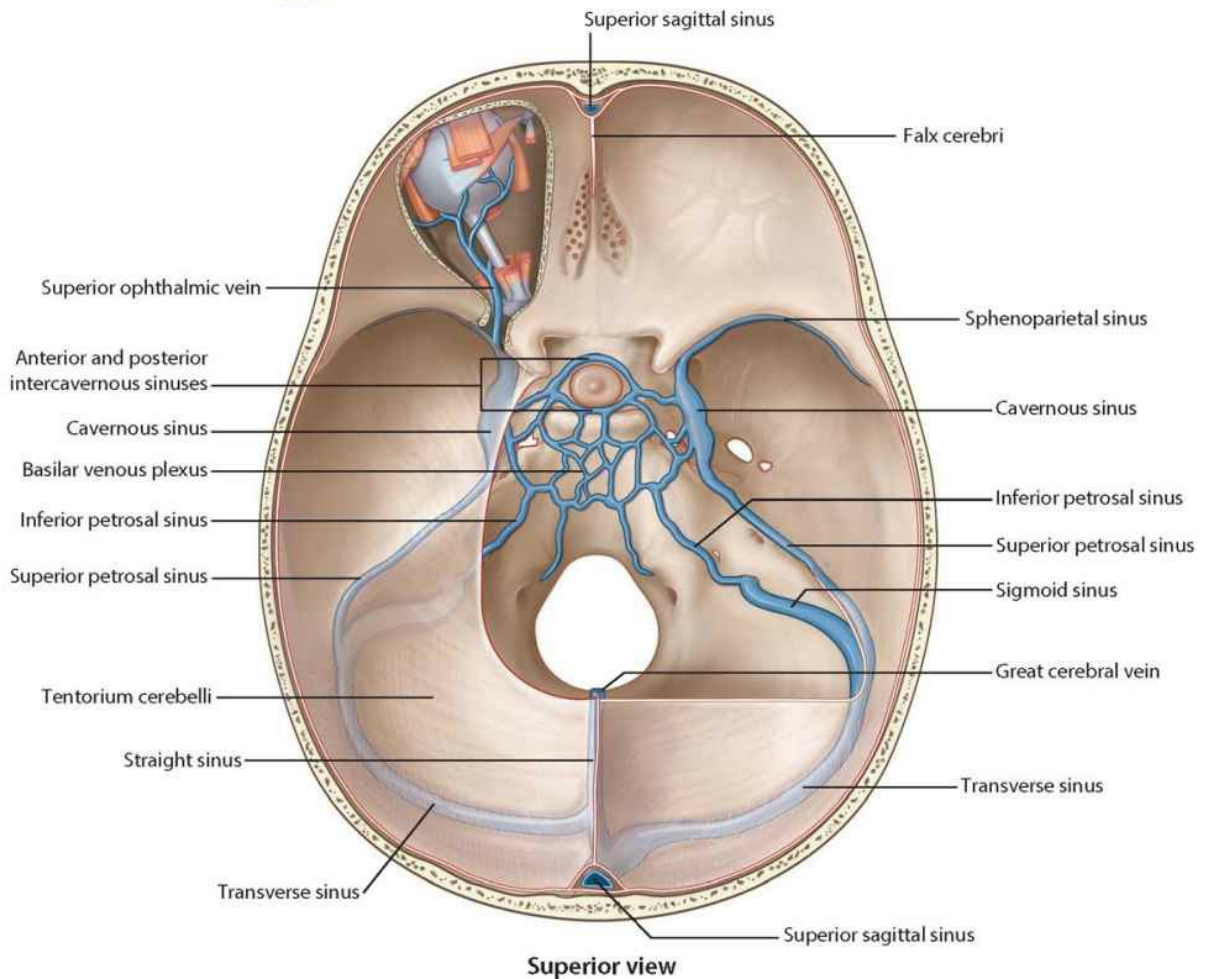


**Dural innervation (superior view)**

# Dural venous sinuses



**Dural venous sinus (medial view)**

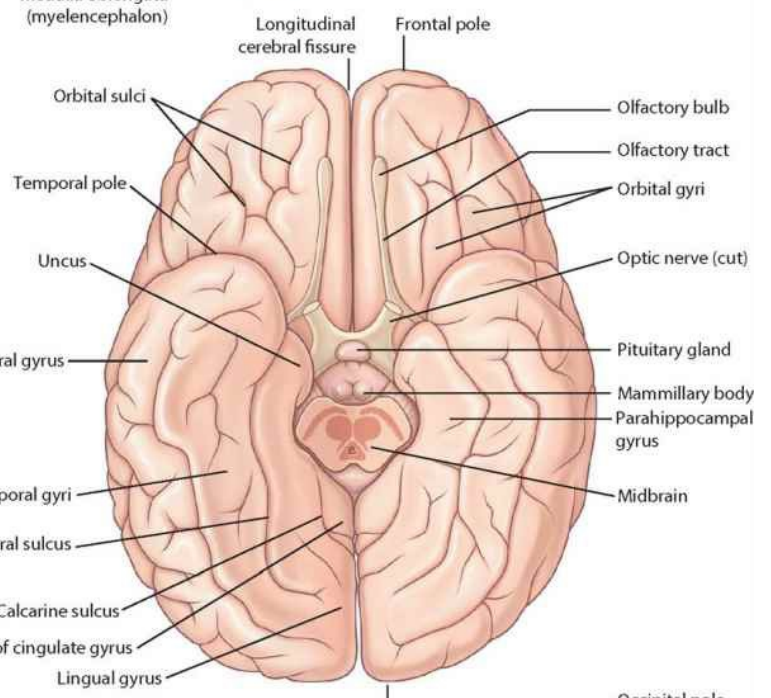
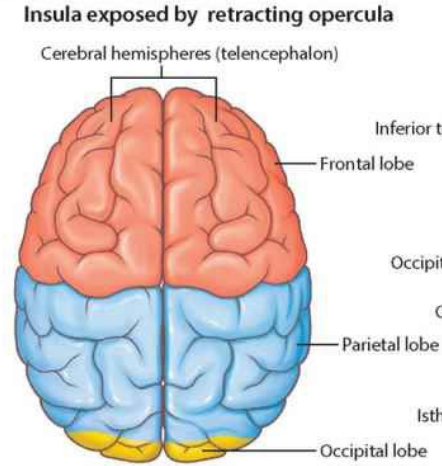
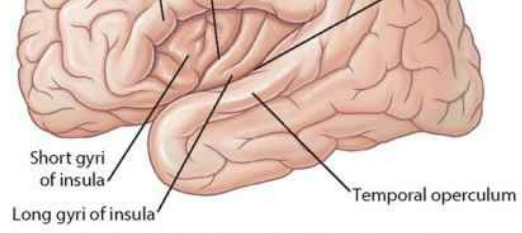
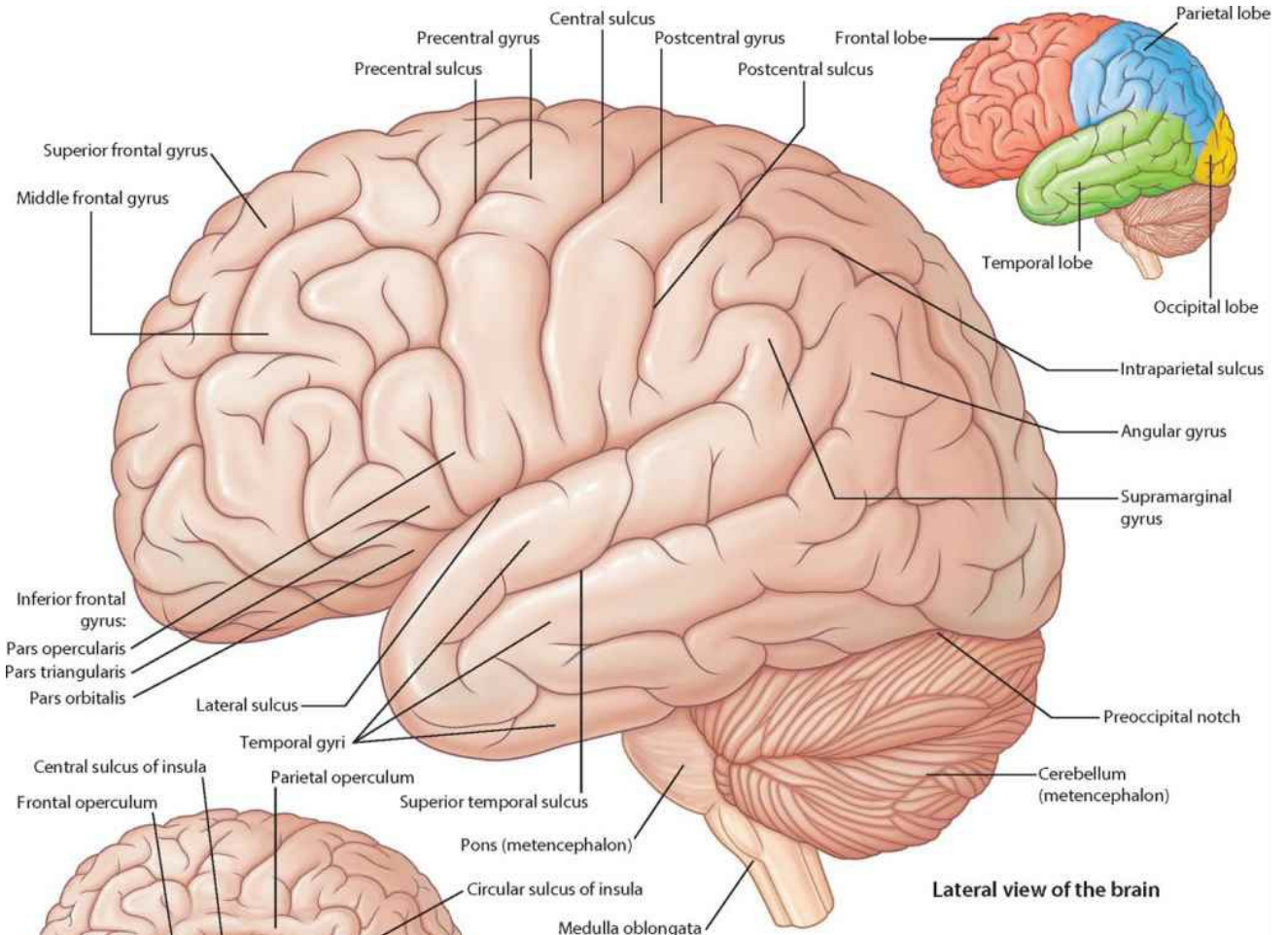


**Superior view**

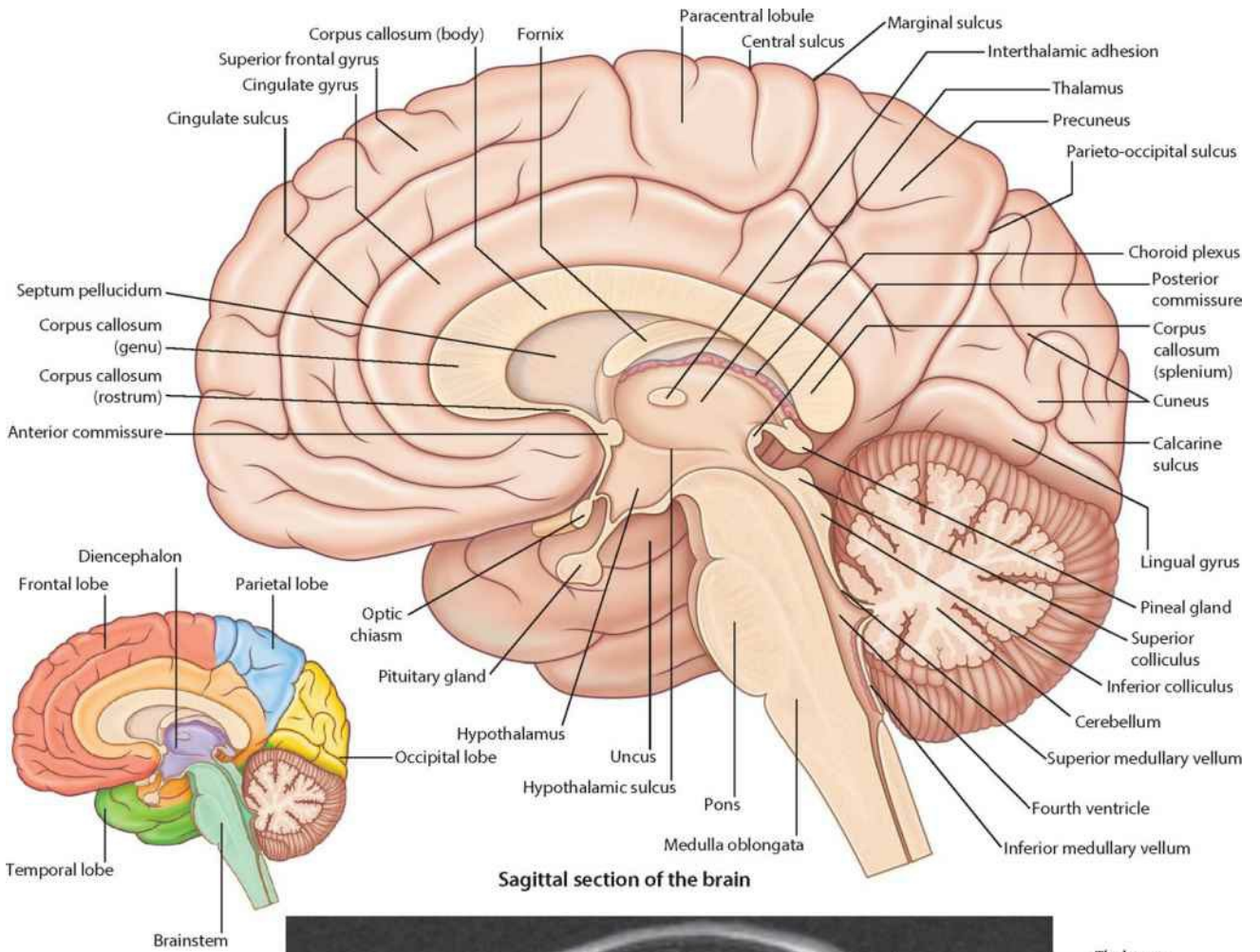




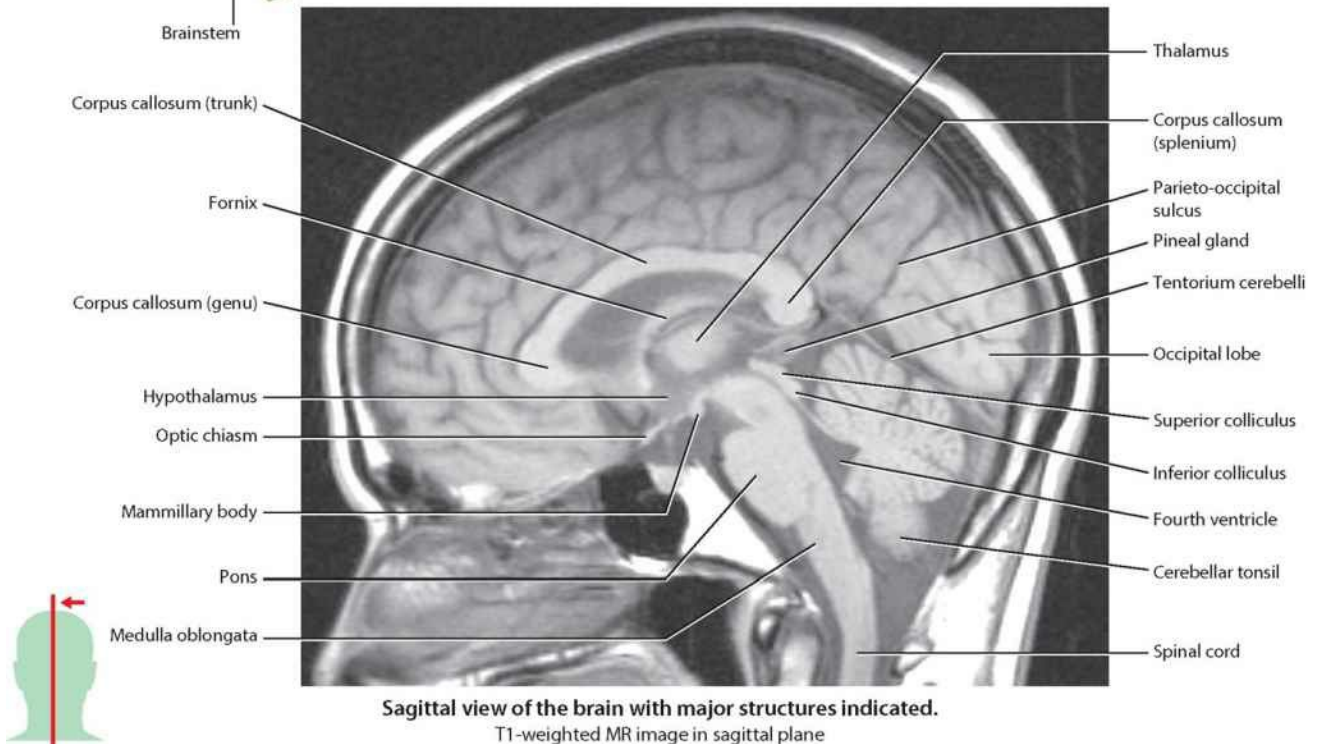
# Brain








Sagittal section of the brain

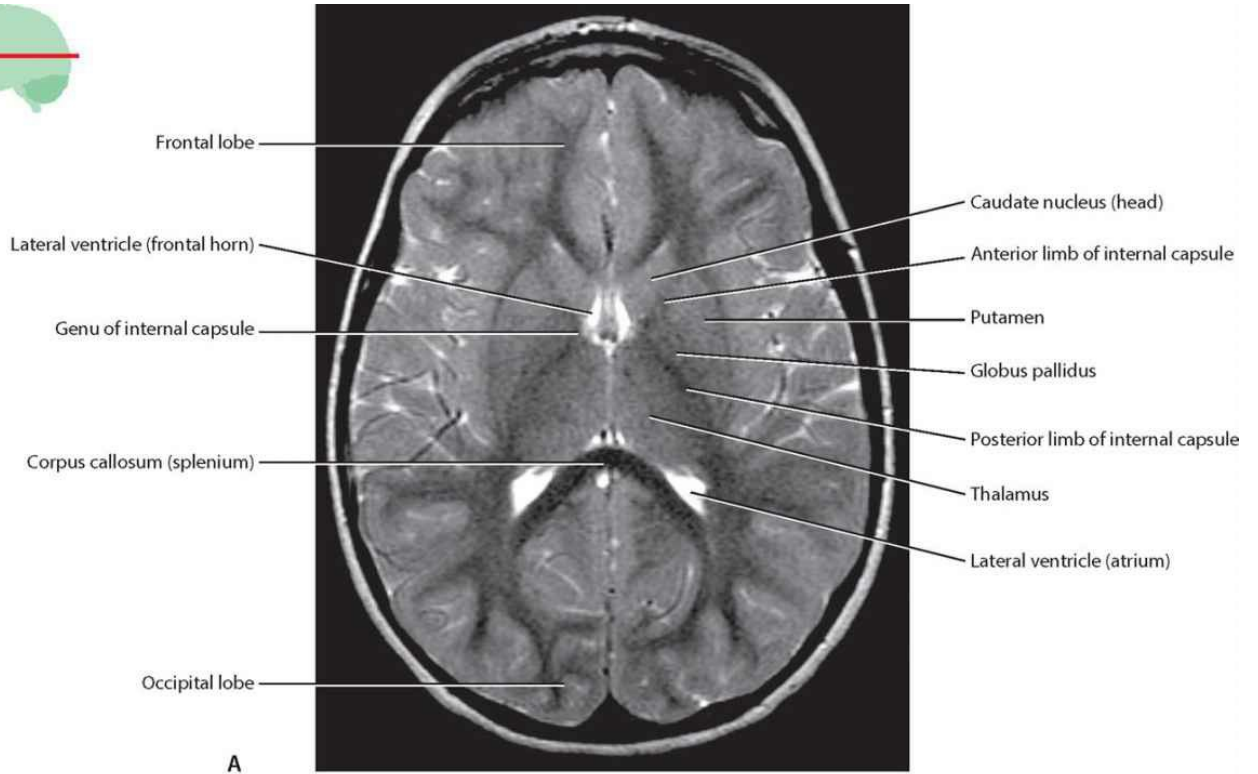
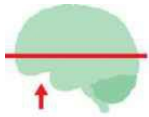


Sagittal view of the brain with major structures indicated.

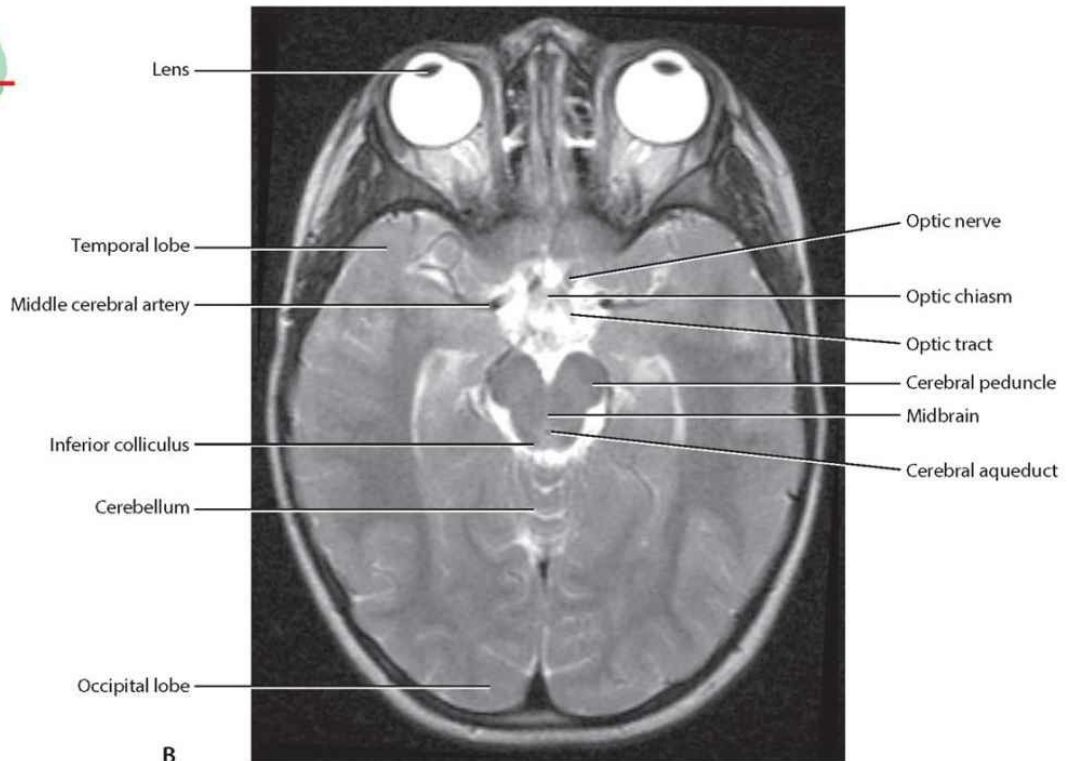
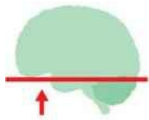
T1-weighted MR image in sagittal plane



# Brain: imaging



A



B

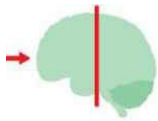
**Axial or horizontal sections through the brain with major structures indicated.**

**A. Section showing structures related to the internal capsule.**

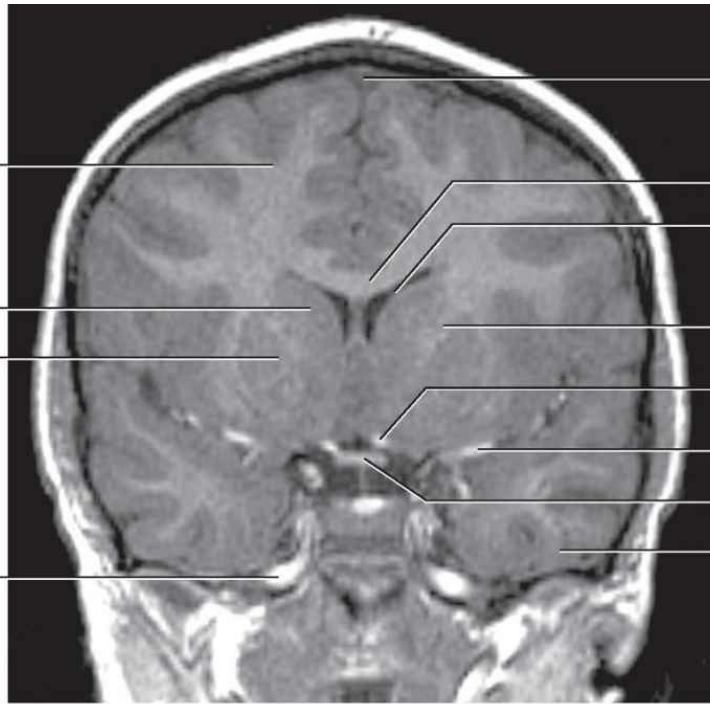
**B. Section showing structures related to the midbrain.**

T1-weighted MR image in axial plane



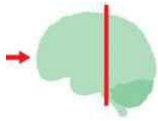


Frontal lobe  
Caudate nucleus (head)  
Putamen  
Internal carotid artery

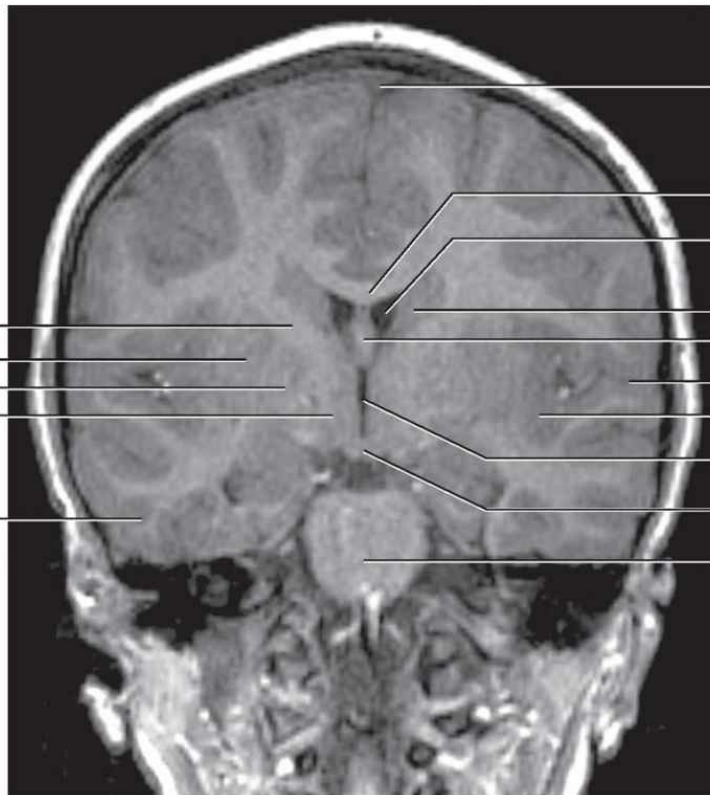


Superior sagittal sinus  
Corpus callosum (body)  
Lateral ventricle (anterior horn)  
Internal capsule (anterior limb)  
Anterior cerebral artery  
Middle cerebral artery  
Optic chiasm  
Temporal lobe

A



Internal capsule  
Putamen  
Globus pallidus  
Thalamus  
Temporal lobe



Superior sagittal sinus  
Corpus callosum (body)  
Lateral ventricle (body)  
Caudate nucleus (body)  
Fornix  
Lateral sulcus (Sylvian fissure)  
Insula  
Third ventricle  
Hypothalamus  
Pons

B

**Coronal sections through the brain with major structures indicated.**

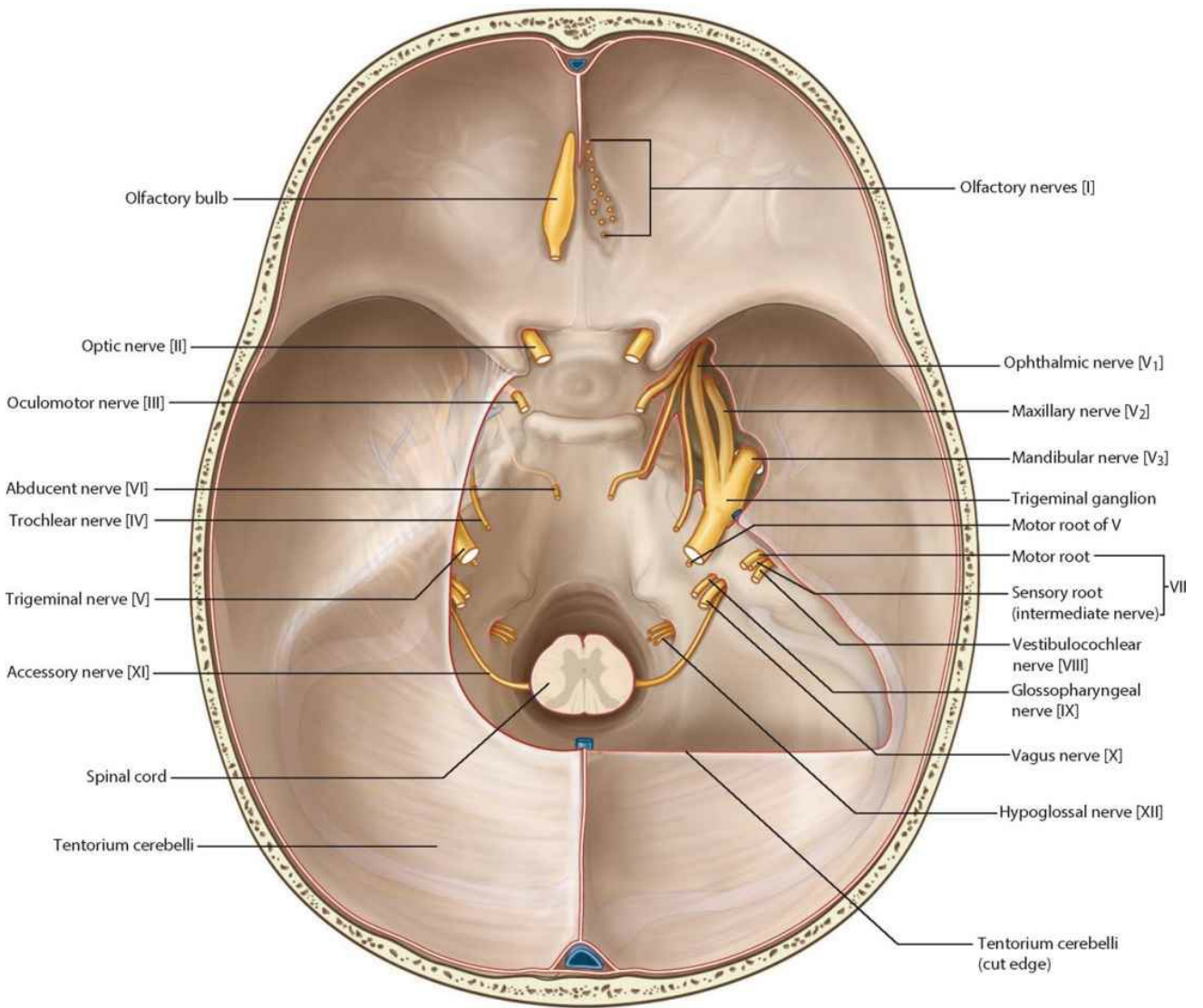
**A. Section showing structures related to the optic chiasm.**

**B. Section showing structures related to the third ventricle.**

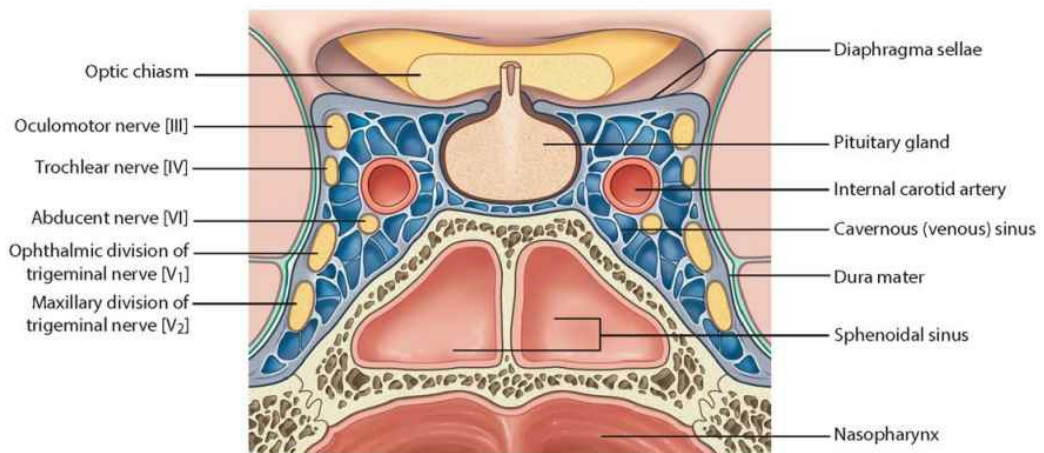
T1-weighted MR image in coronal plane



# Cranial nerves

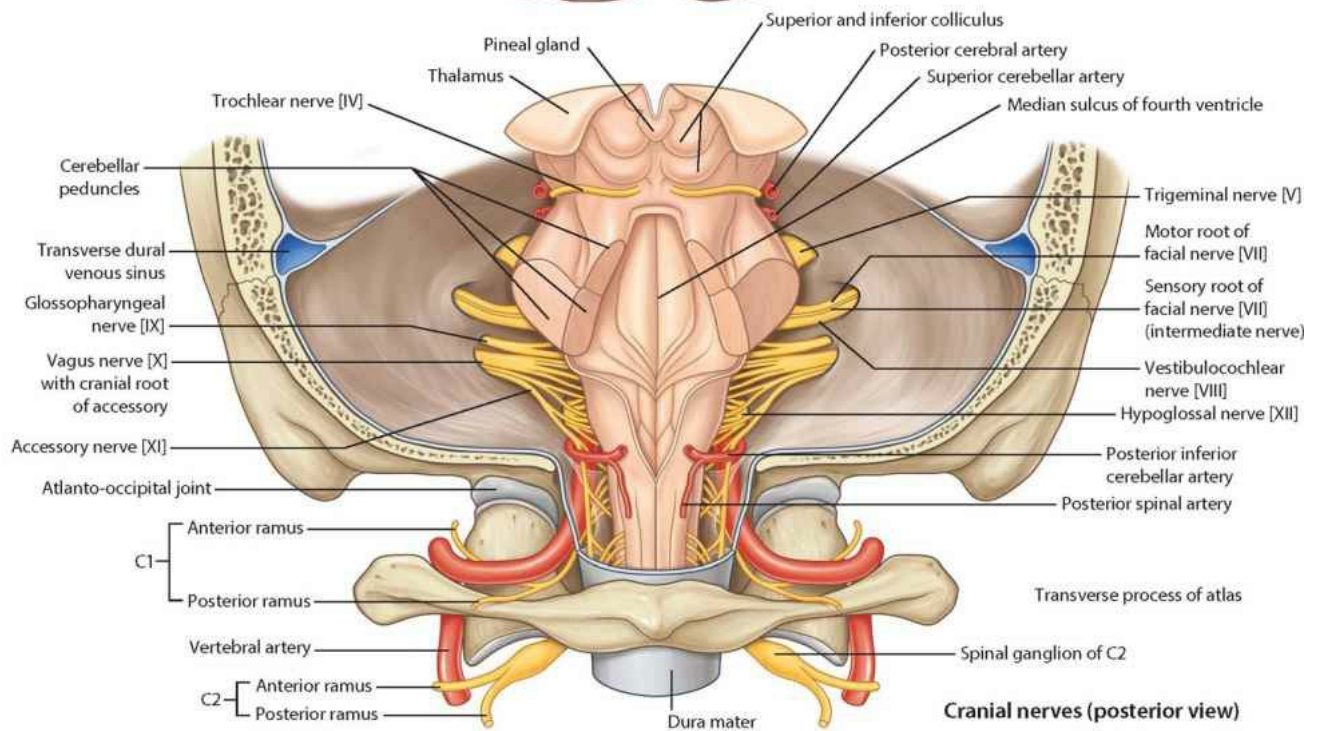
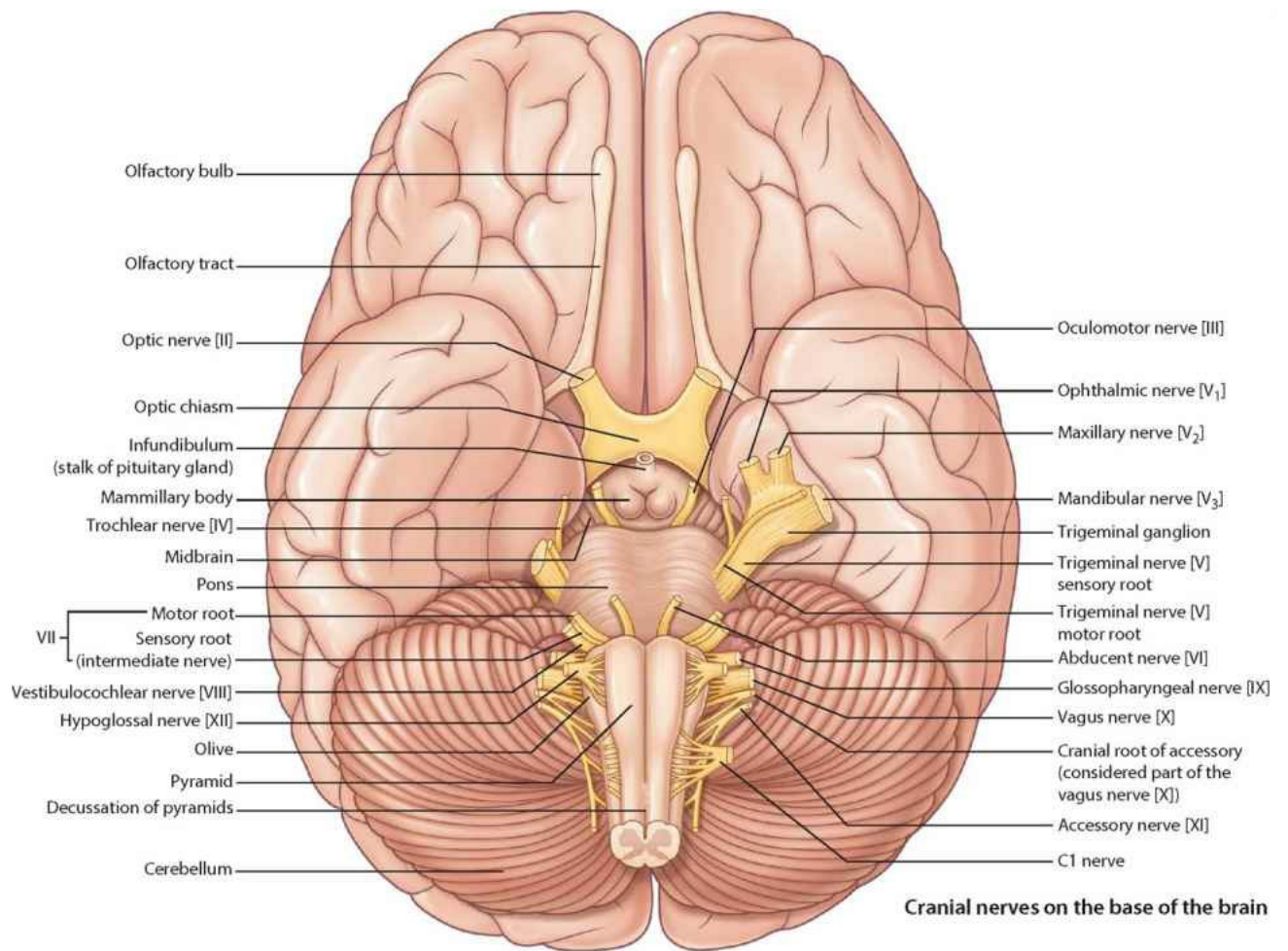


**Cranial nerves exiting the cranial cavity**

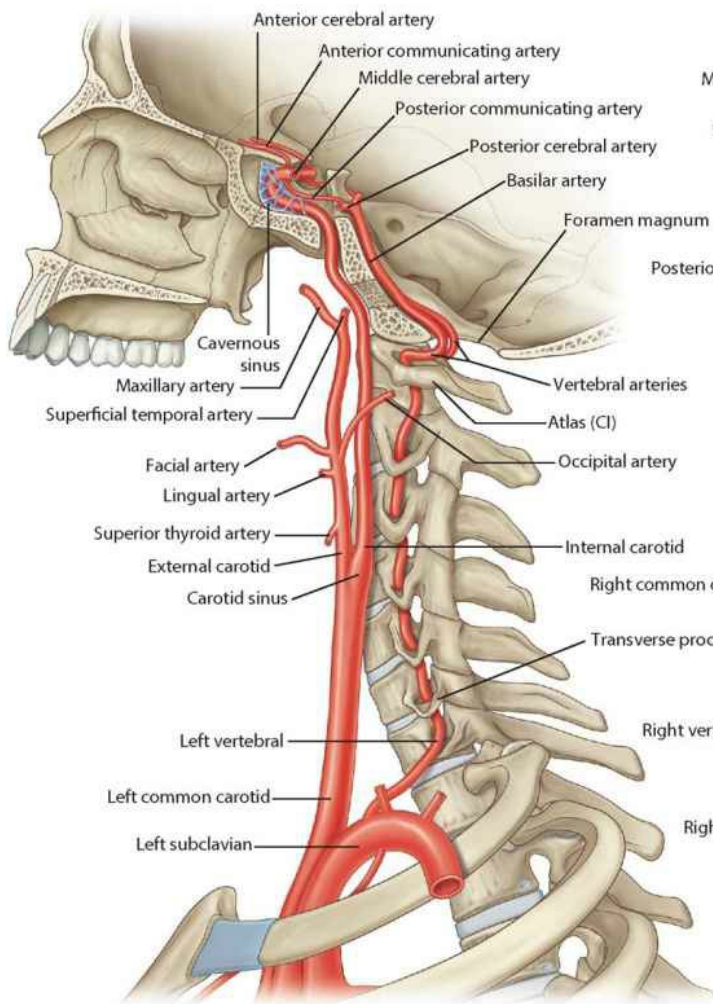


**Cranial nerves in the cavernous sinus**





# Arterial supply to brain



Arteries to brain (lateral view)

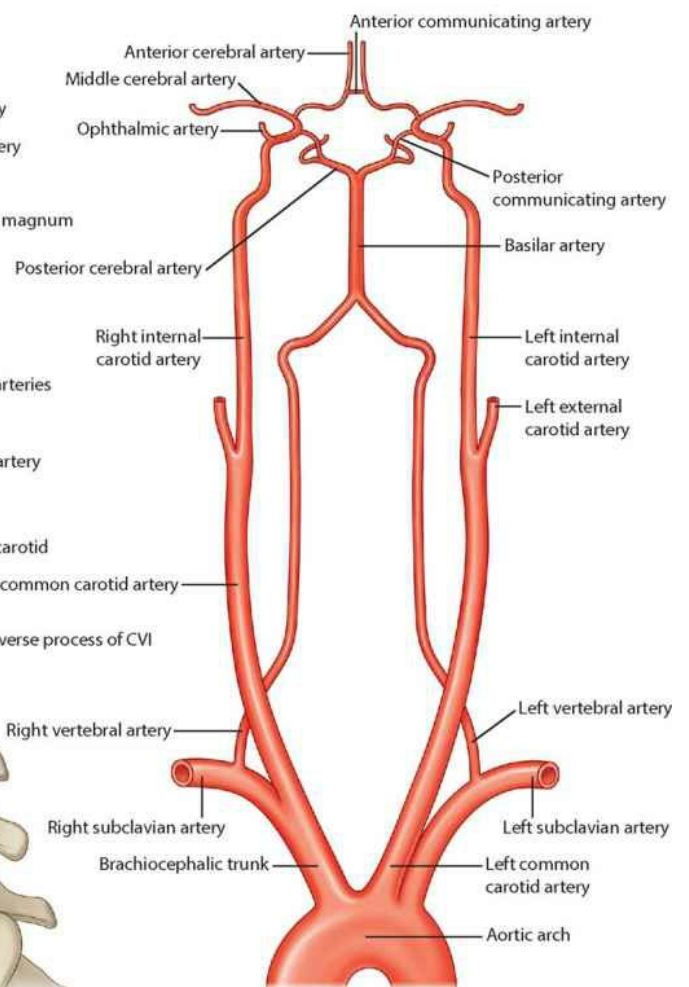
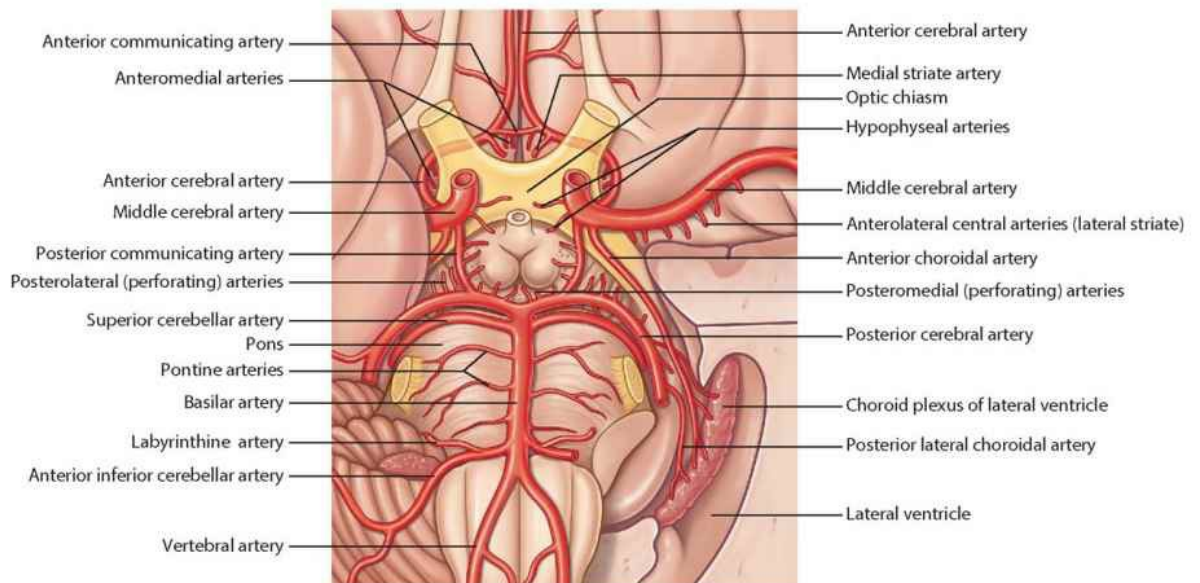
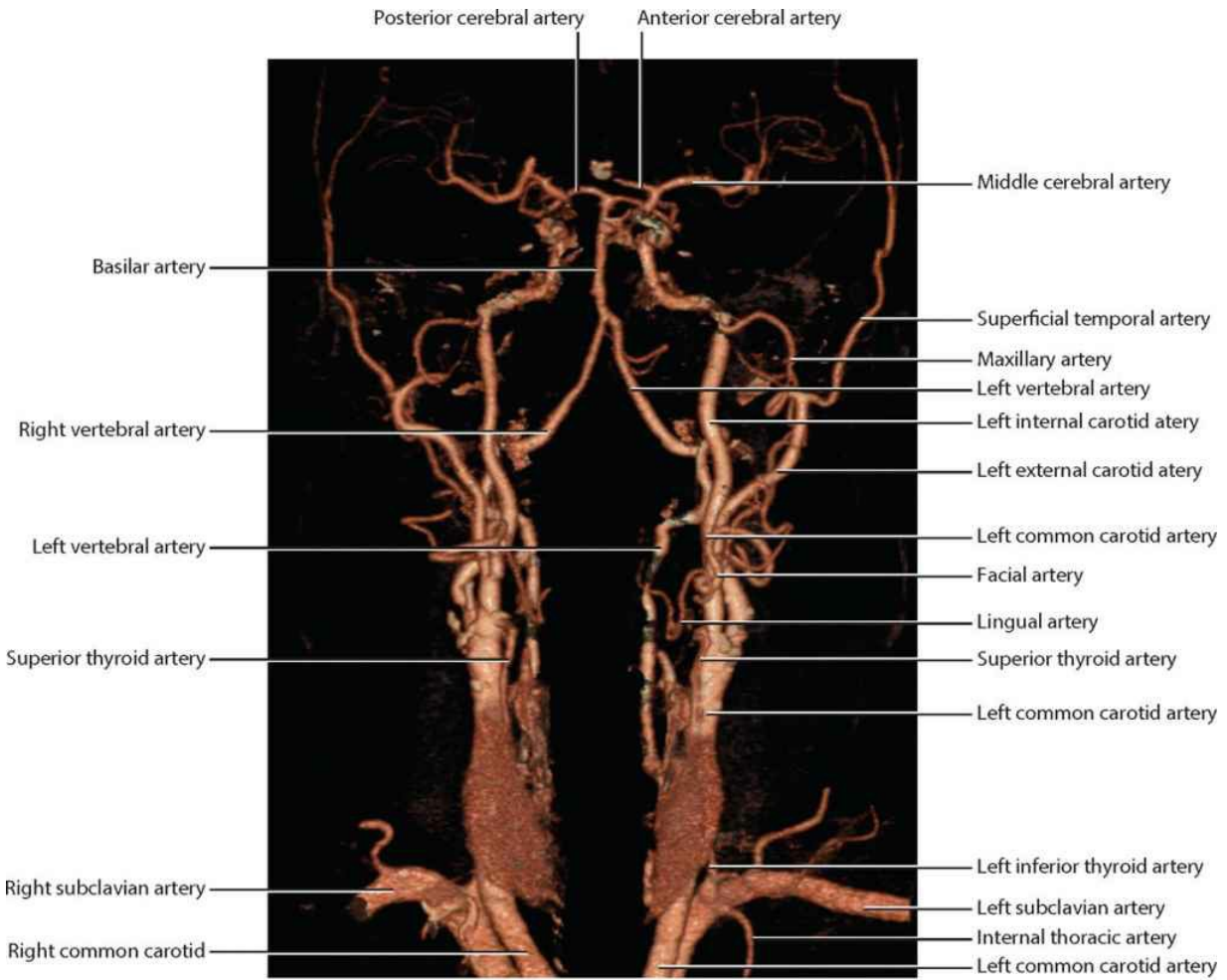


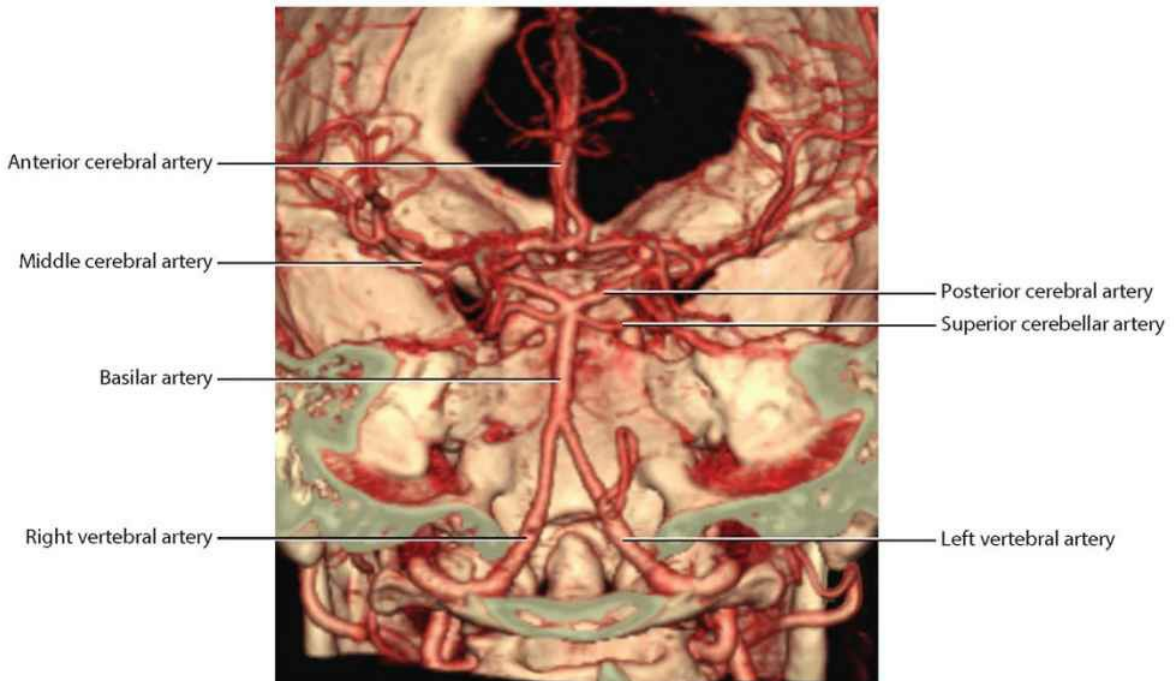Diagram showing blood supply to brain



Cerebral arterial circle (of Willis)



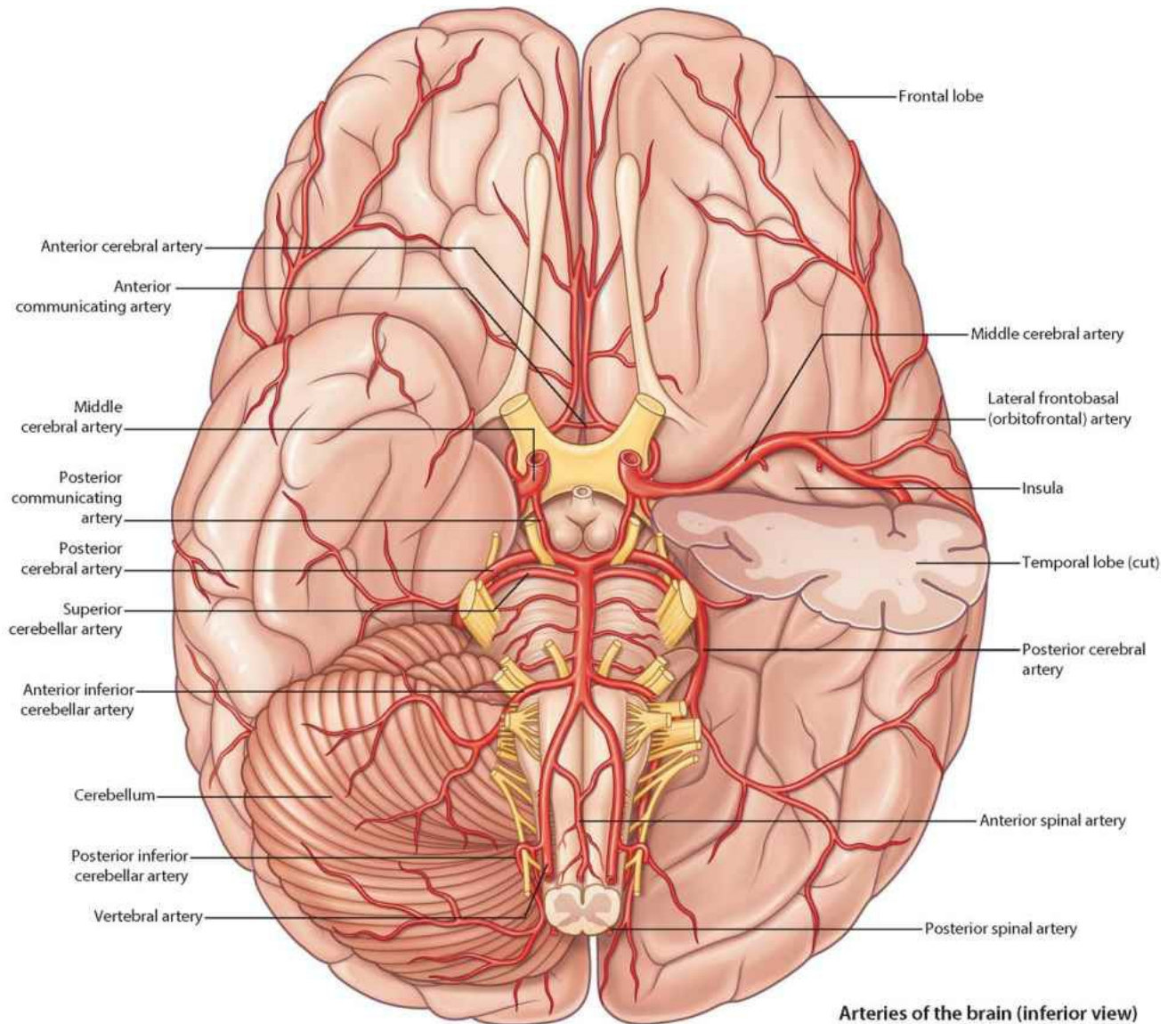
**Anterior view of the carotid and vertebral arterial systems.**  
 Volume-rendered anterior view using multidetector computed tomography



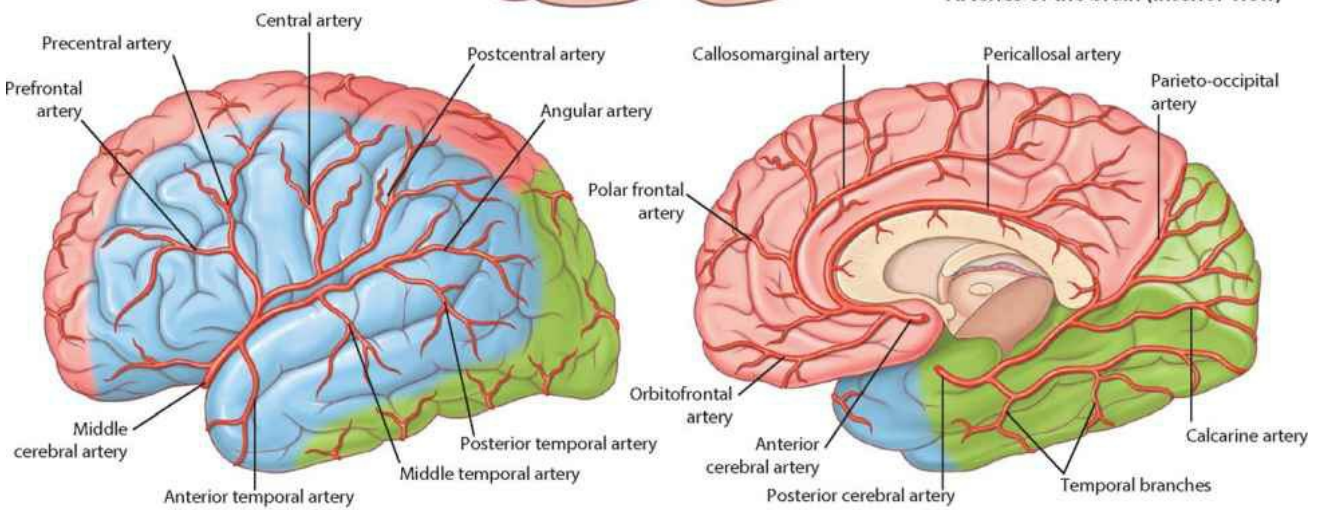
**Posterior view of the cerebral arterial circle (of Willis).**  
 Volume-rendered posterior view using multidetector computed tomography







Arteries of the brain (inferior view)



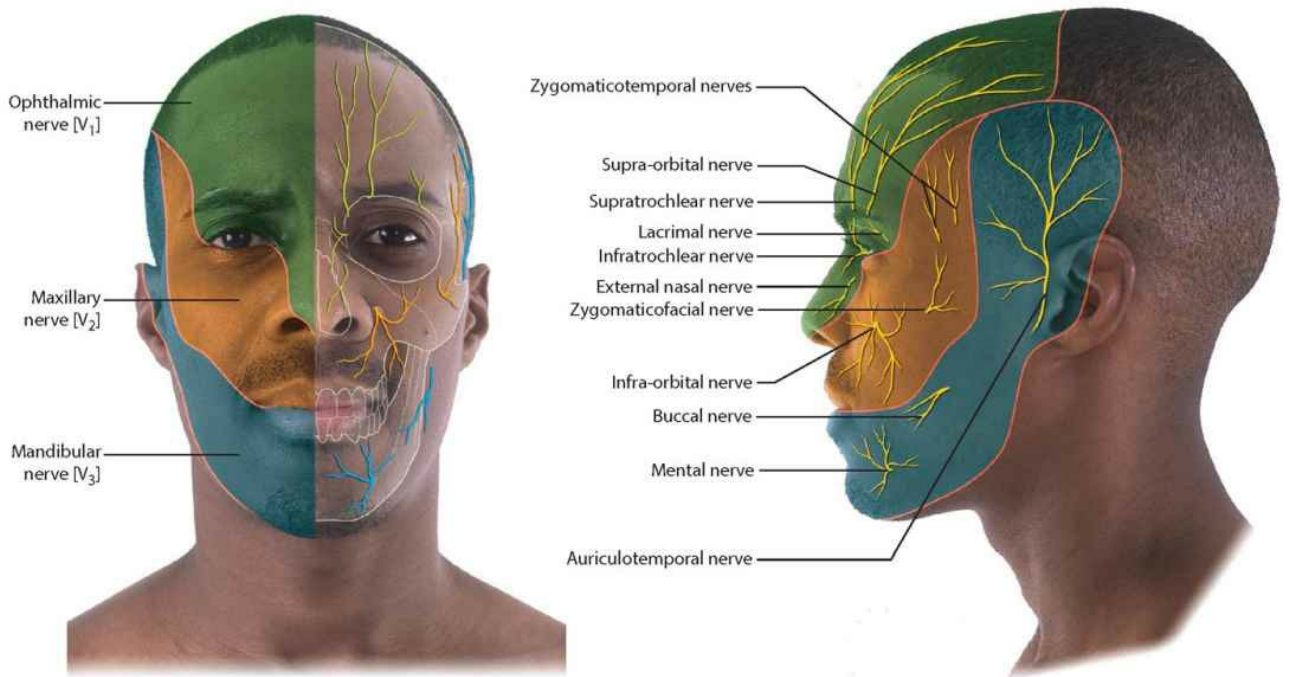
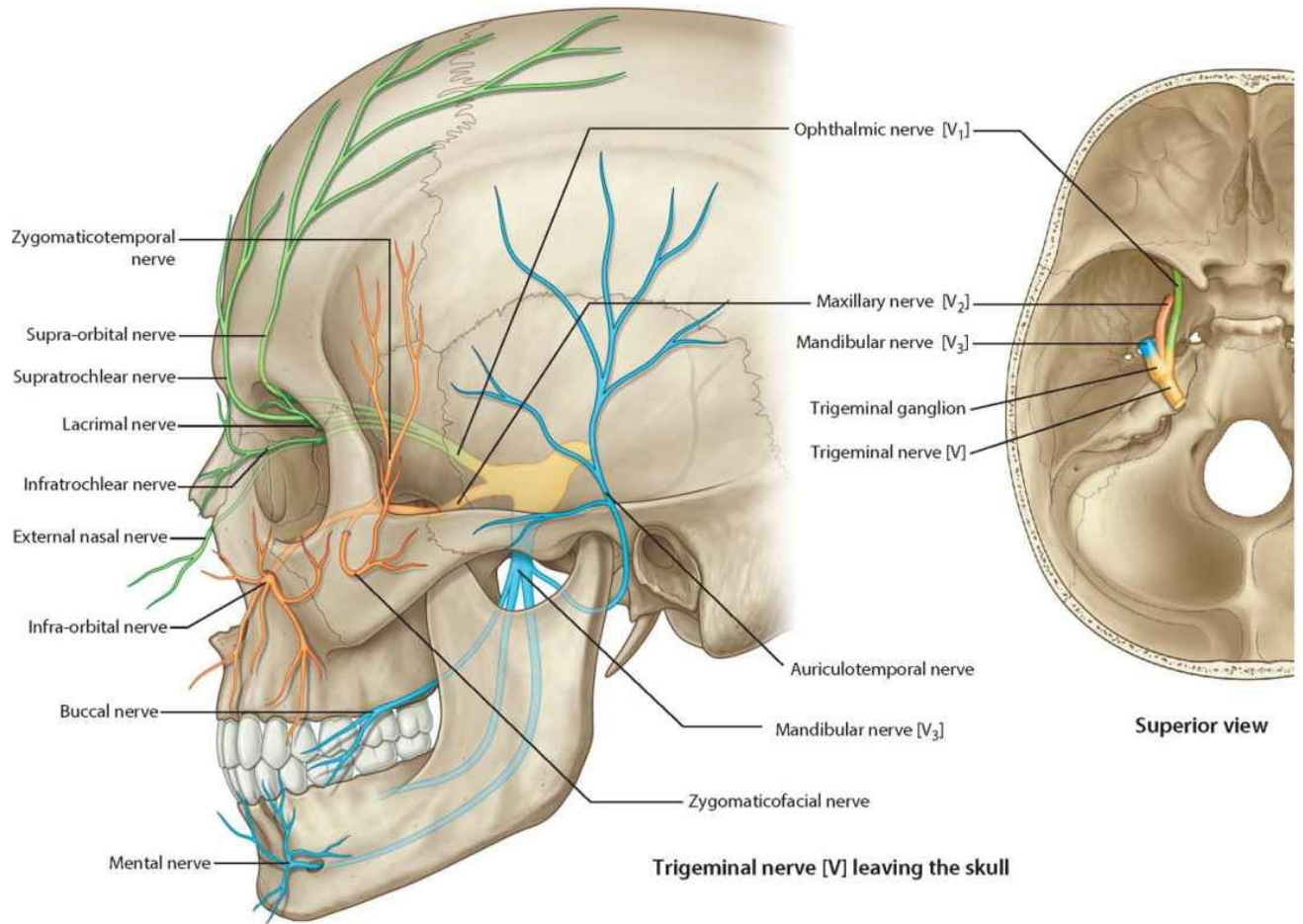
Lateral view

Blood supply to the cerebral hemispheres.

Medial view

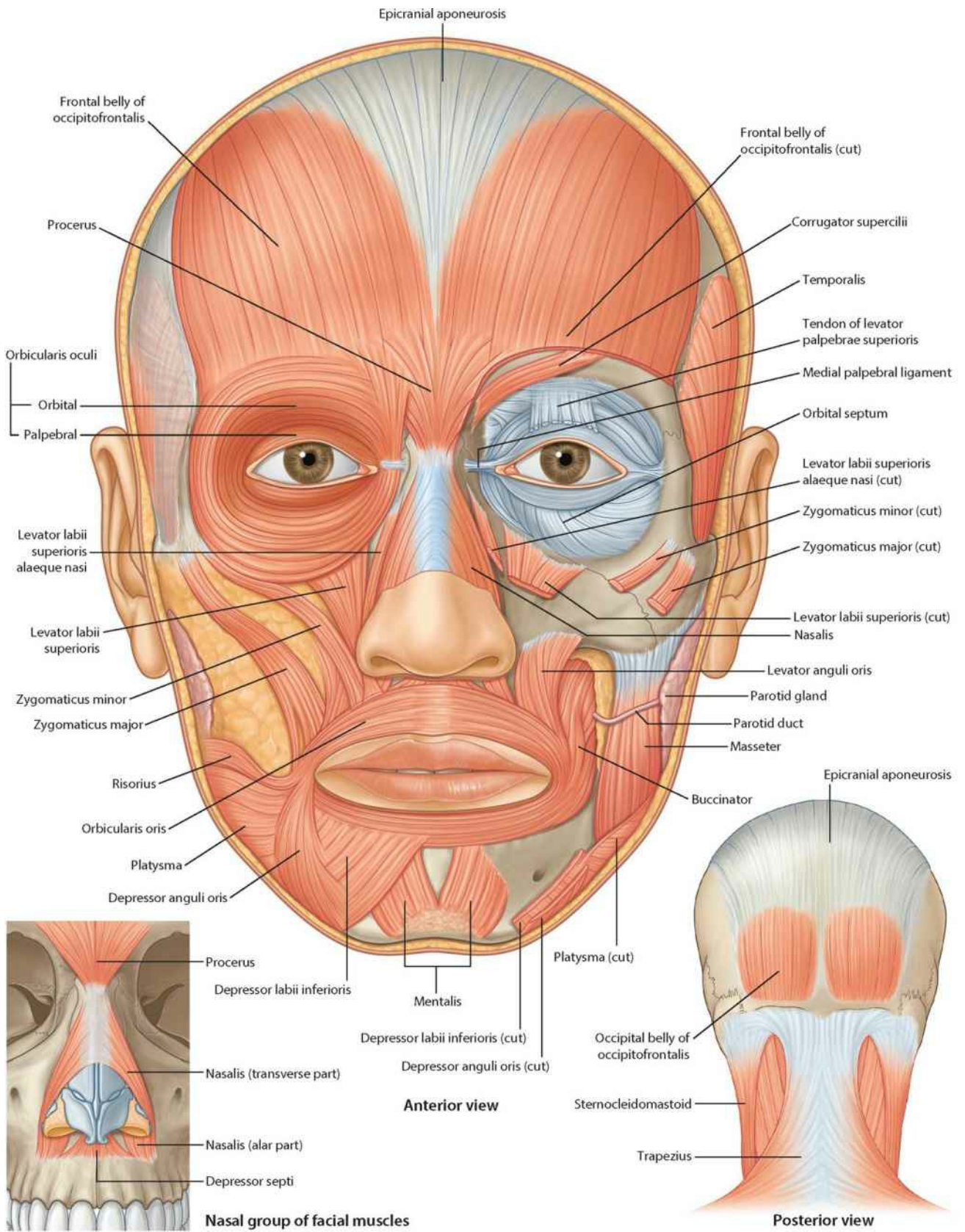
Anterior cerebral artery (pink), middle cerebral artery (blue), posterior cerebral artery (green)

# Cutaneous distribution of trigeminal nerve [V]

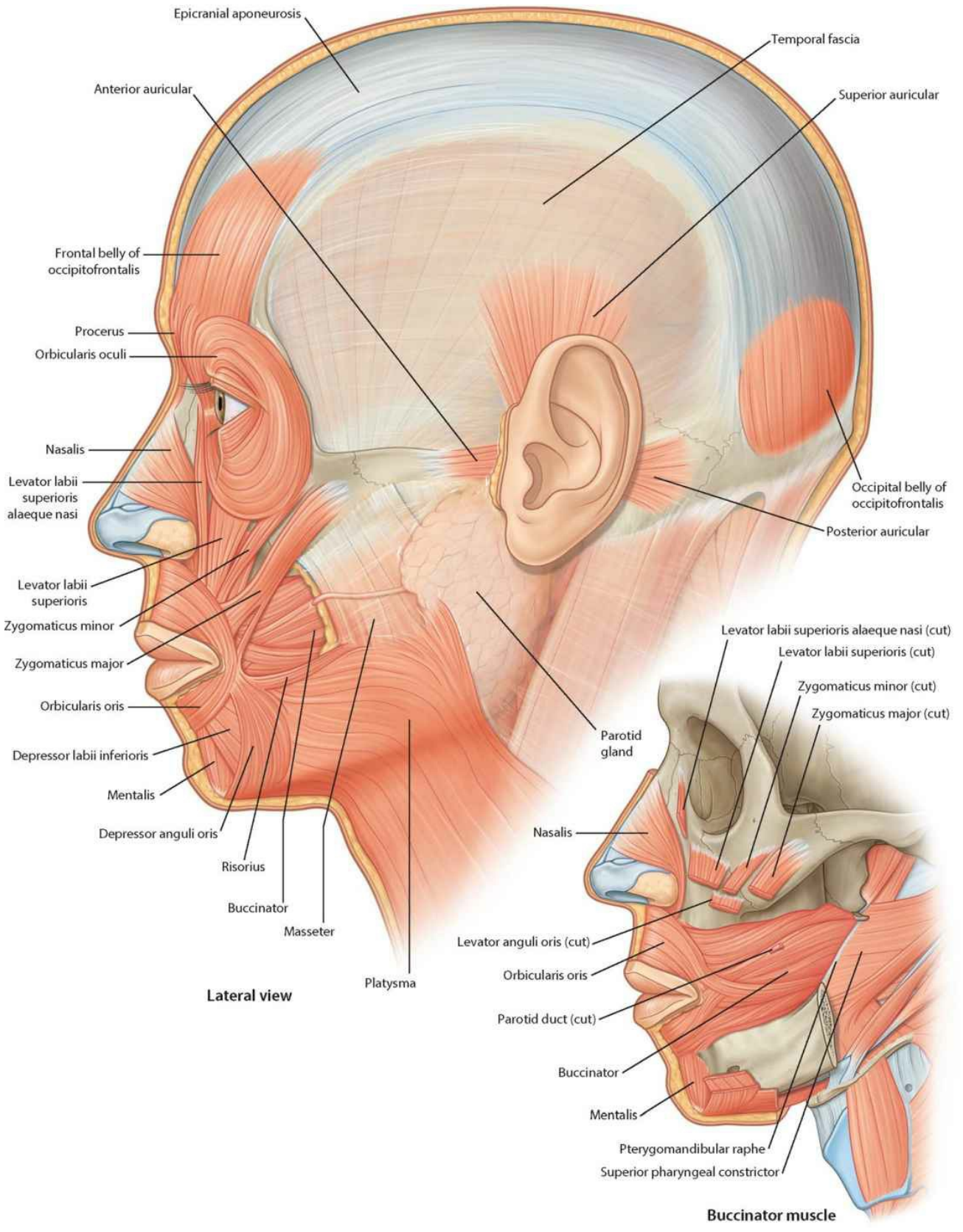


**Cutaneous distribution of the trigeminal nerve [V]**

# Facial muscles





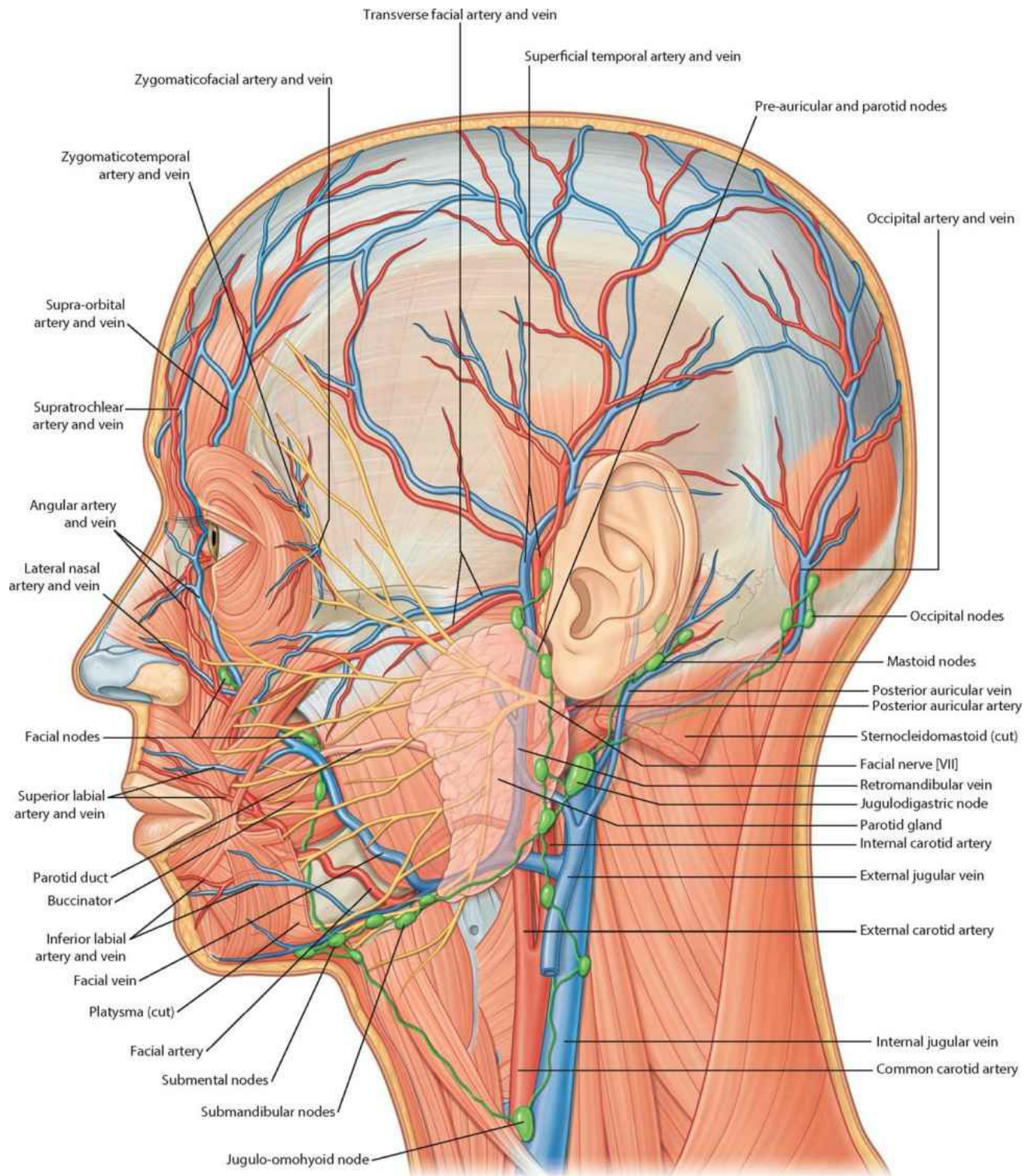


**Lateral view**

**Buccinator muscle**

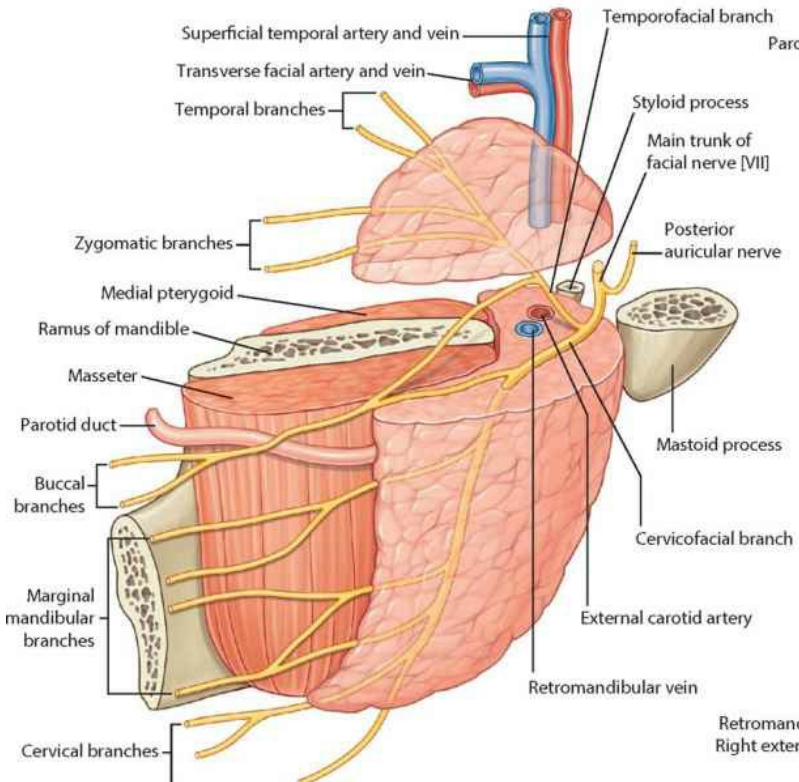
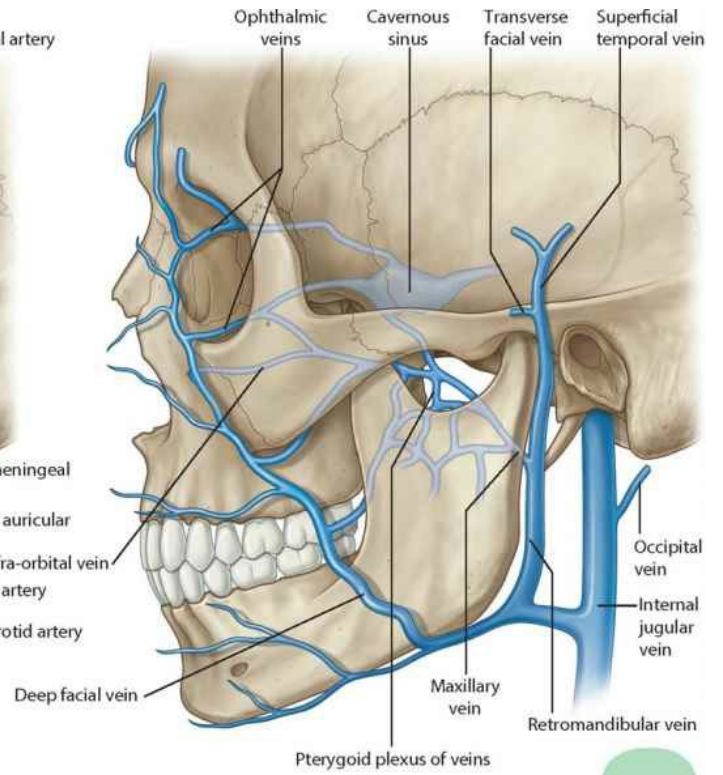
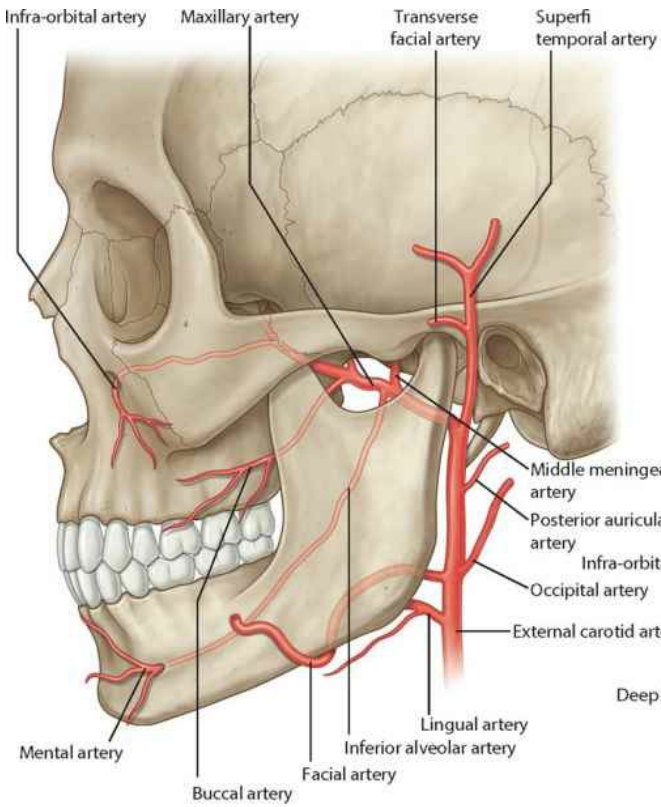
# Vasculature, facial nerve [VII] and lymphatics



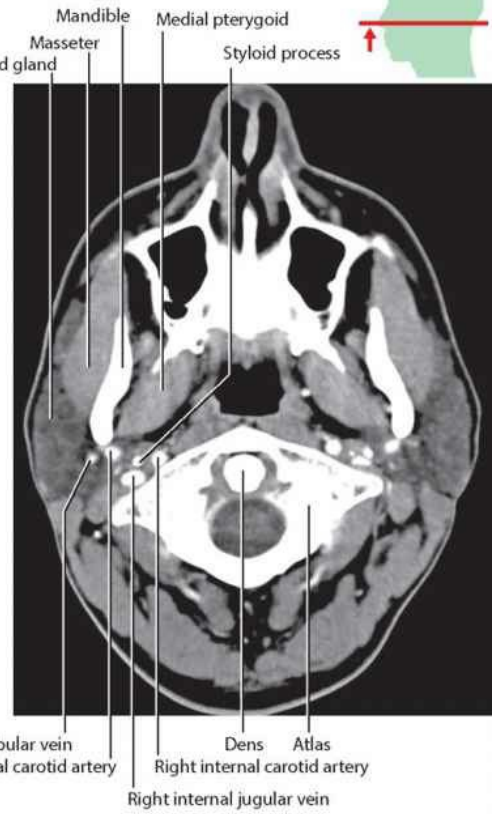


Vasculature, facial nerve [VII] and lymphatics of the face

# Deep arteries and veins of parotid region

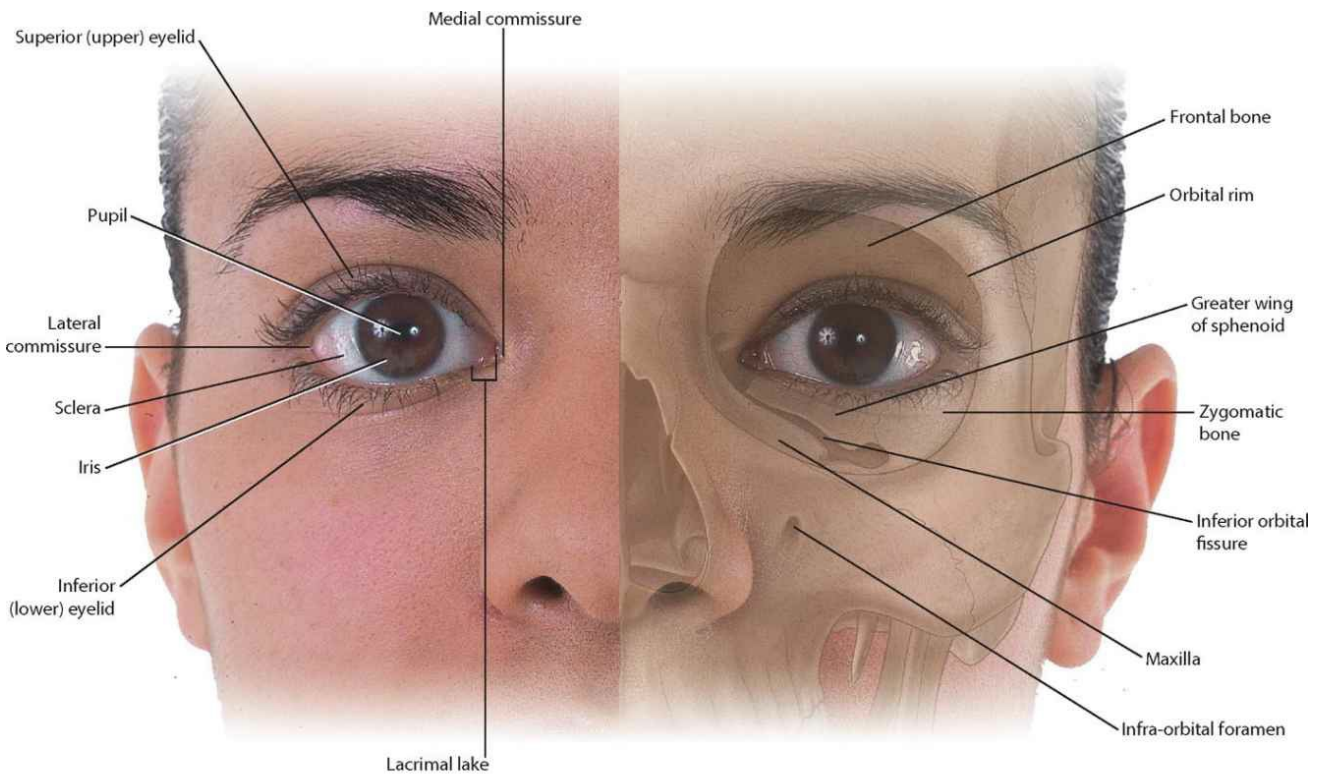


**Parotid gland and facial nerve [VII]**

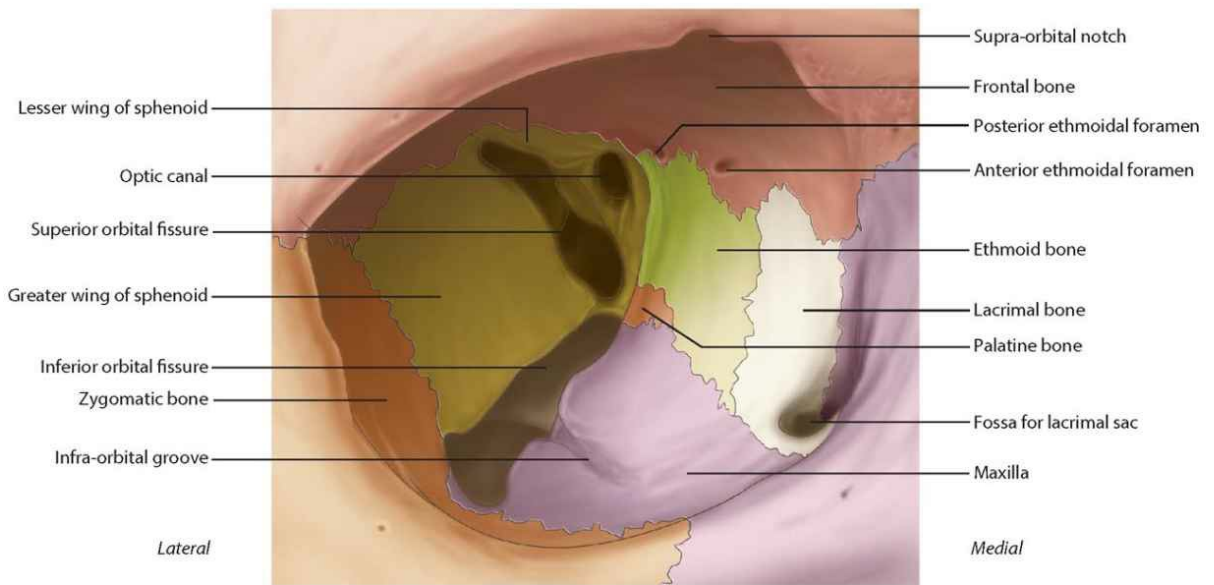


**Axial section through the parotid gland showing its relationship to surrounding structures. CT image in axial plane**

# Bony orbit

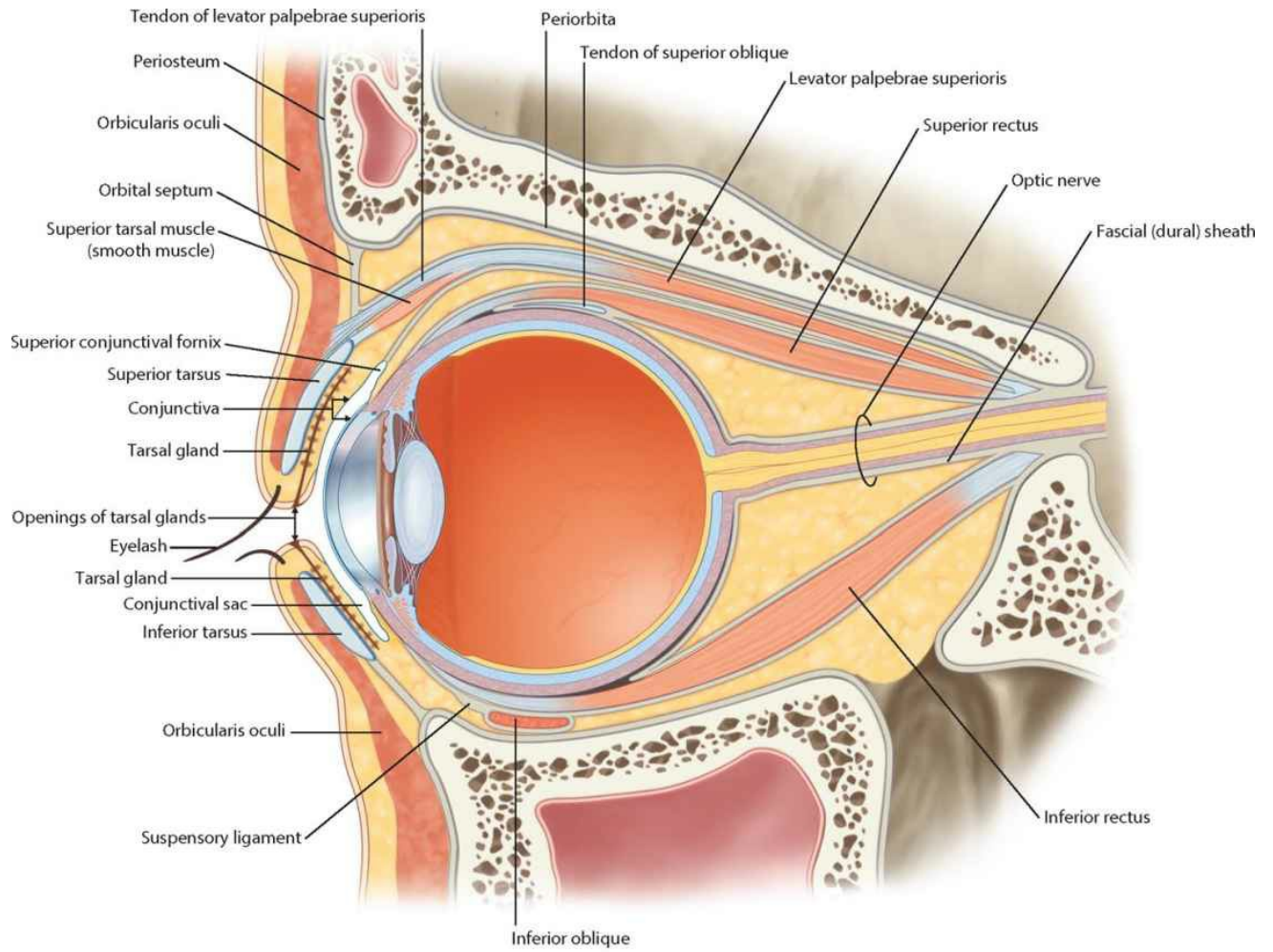


**Surface anatomy**

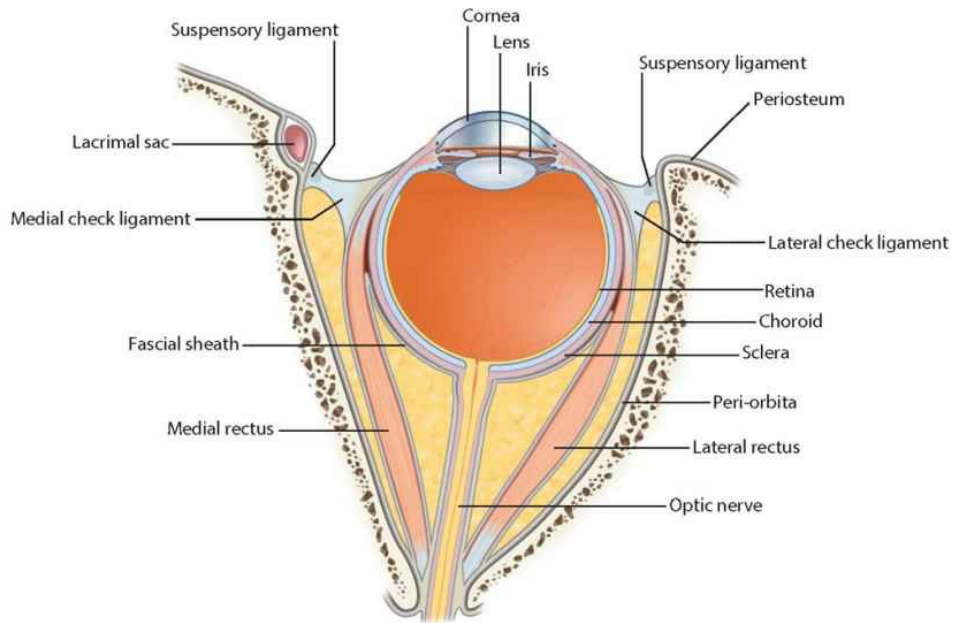


**Bones of the right orbit**

# Section through orbit and structures of eyelid



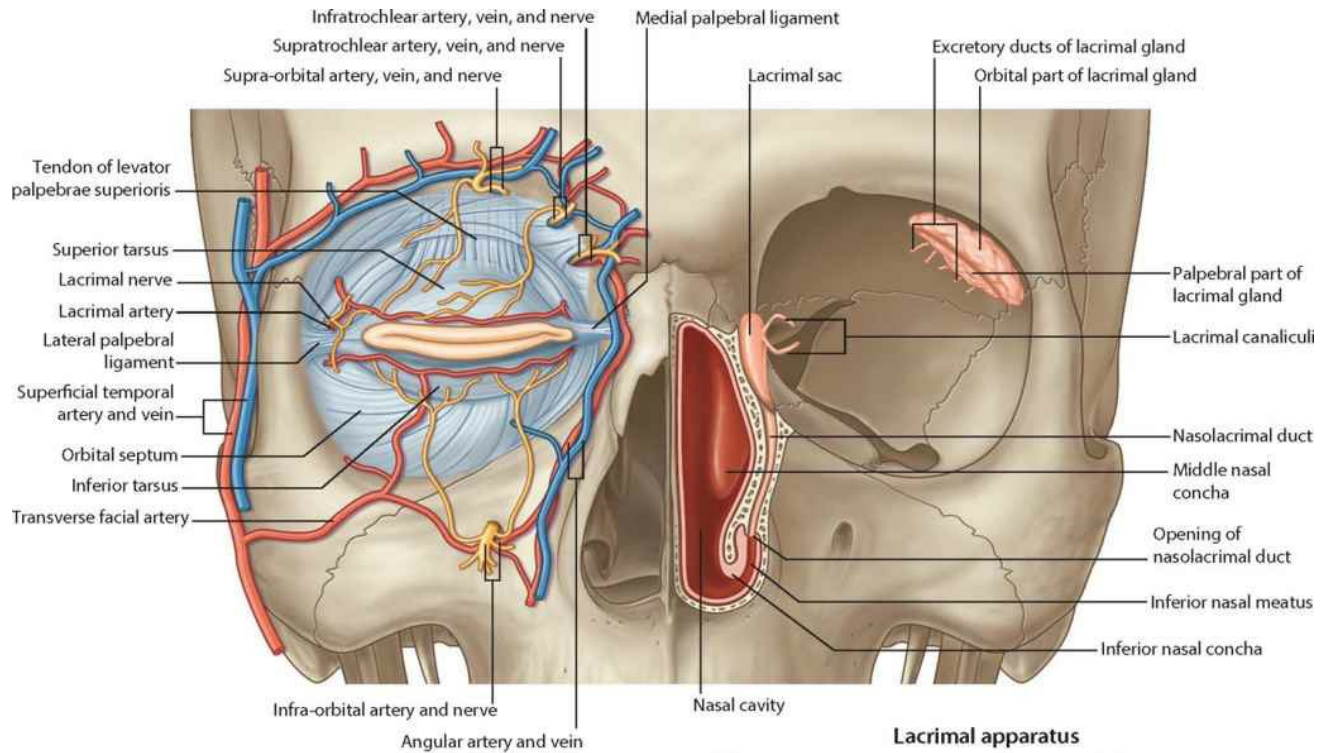
**Sagittal section through orbit and eyeball**



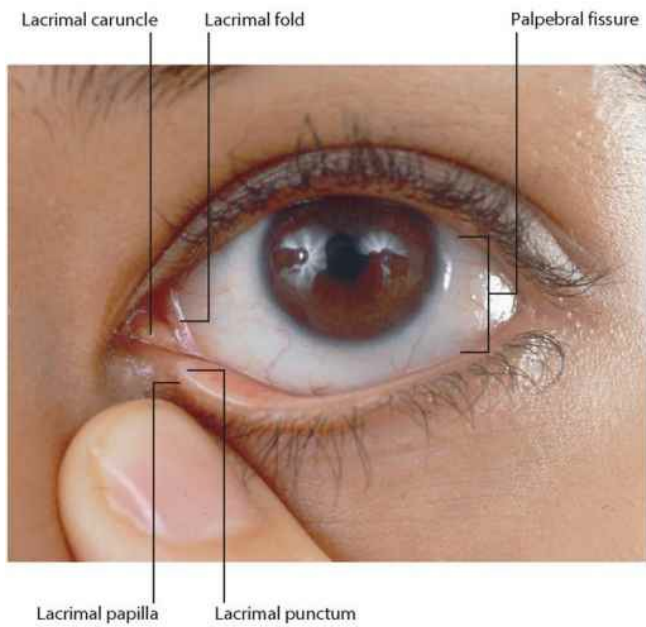
**Horizontal (axial) section through orbit and eyeball**

# **Eyelids and lacrimal apparatus**

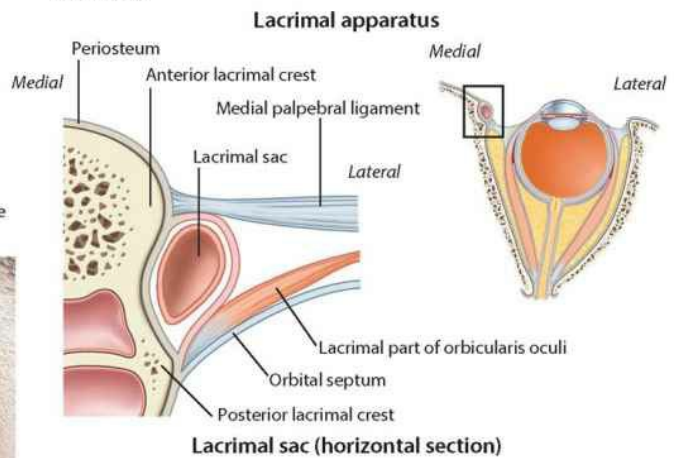




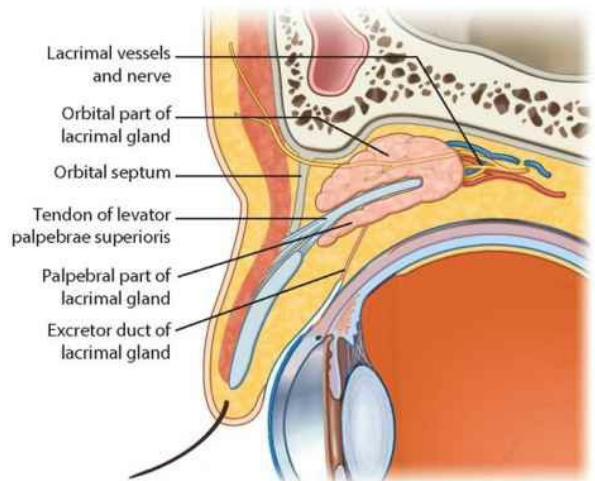
**Vasculature and nerves of the eyelids**



**Lacrimal papilla and punctum of left eye**

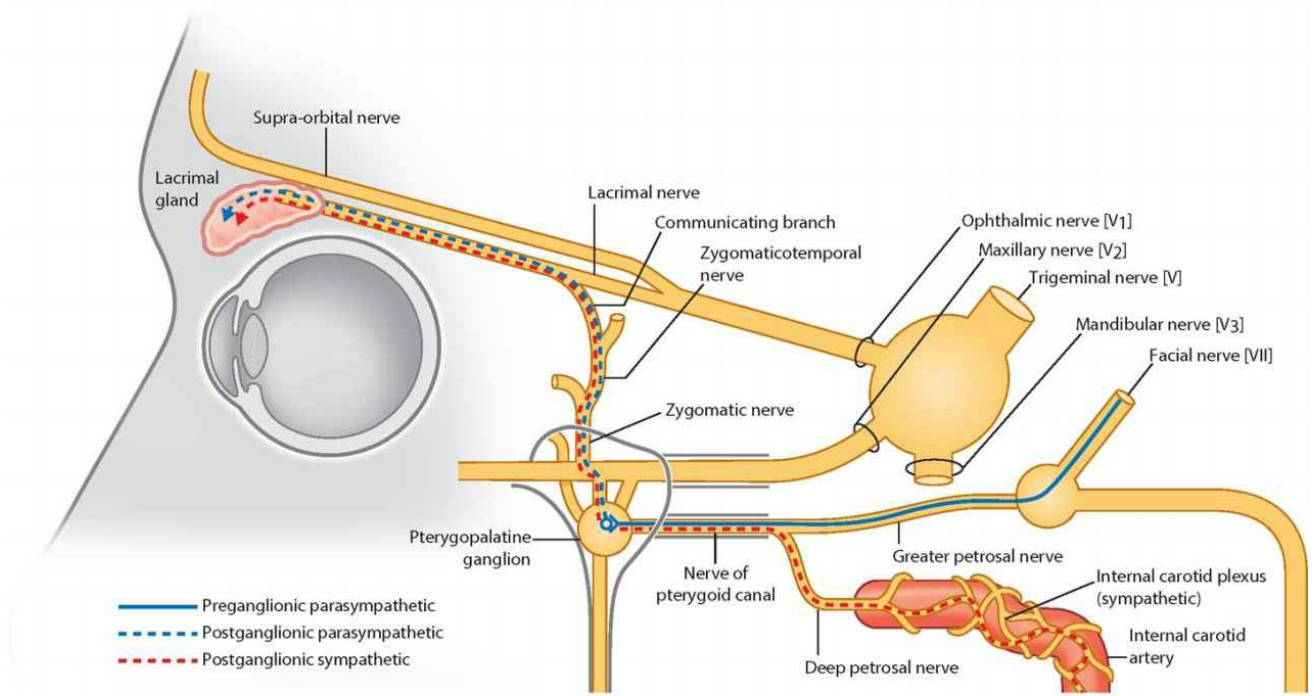


**Lacrimal sac (horizontal section)**

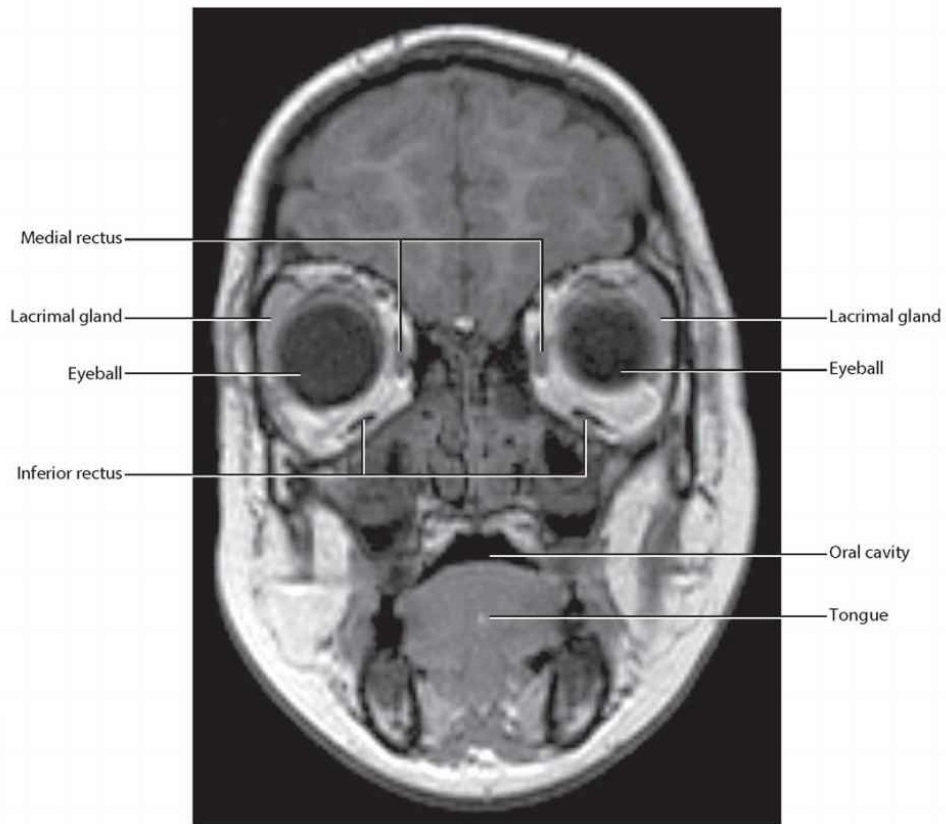


**Lacrimal gland and levator palpebrae superioris (parasagittal section)**

# Innervation of the lacrimal gland



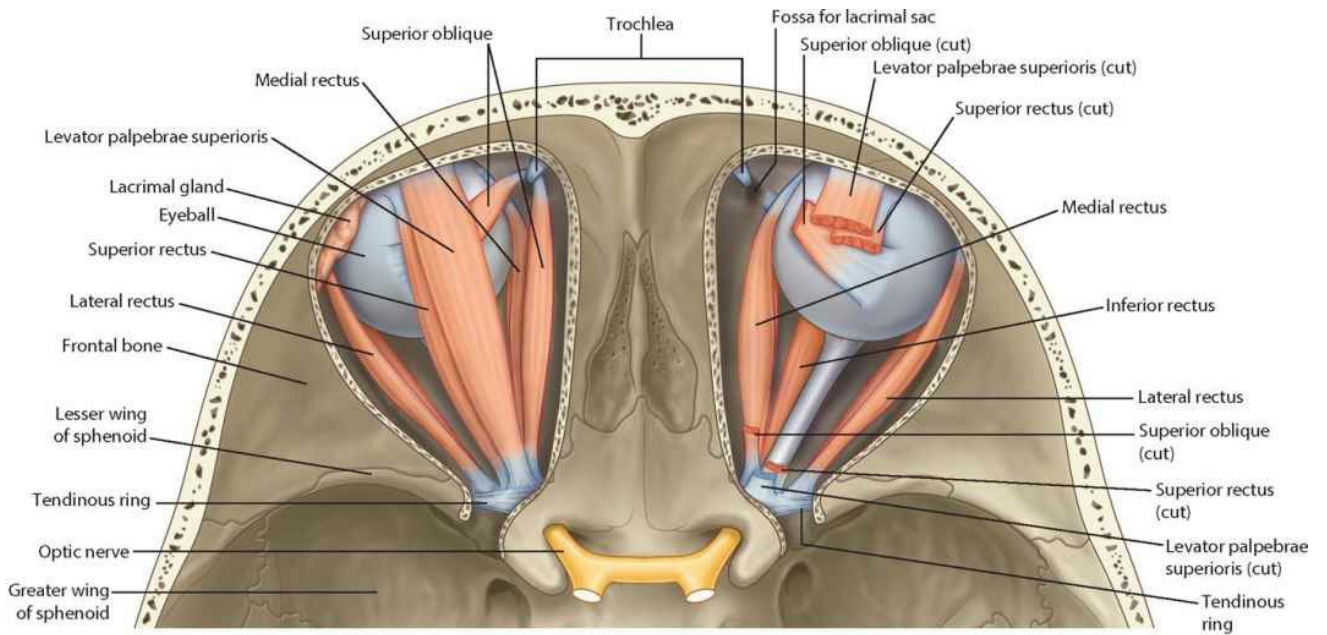
Visceral efferent (motor) innervation of the lacrimal gland



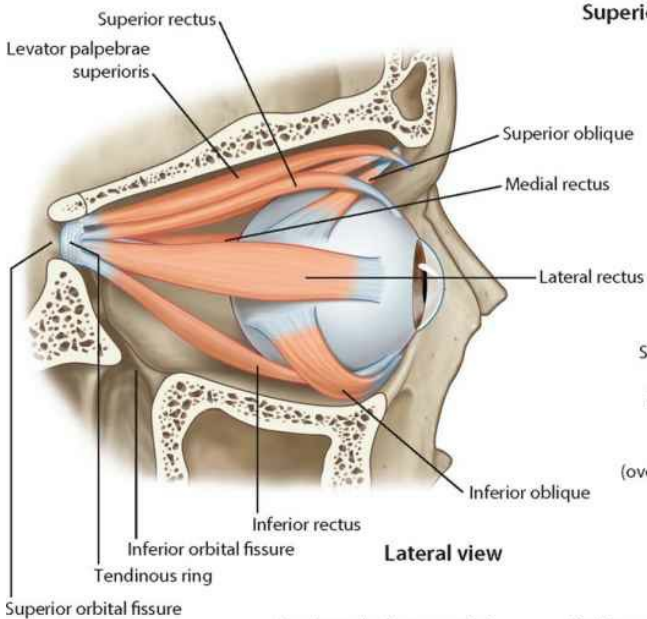
Coronal section through the orbit showing the lacrimal gland and its relationship to surrounding structures.

T1-weighted MR image in coronal plane

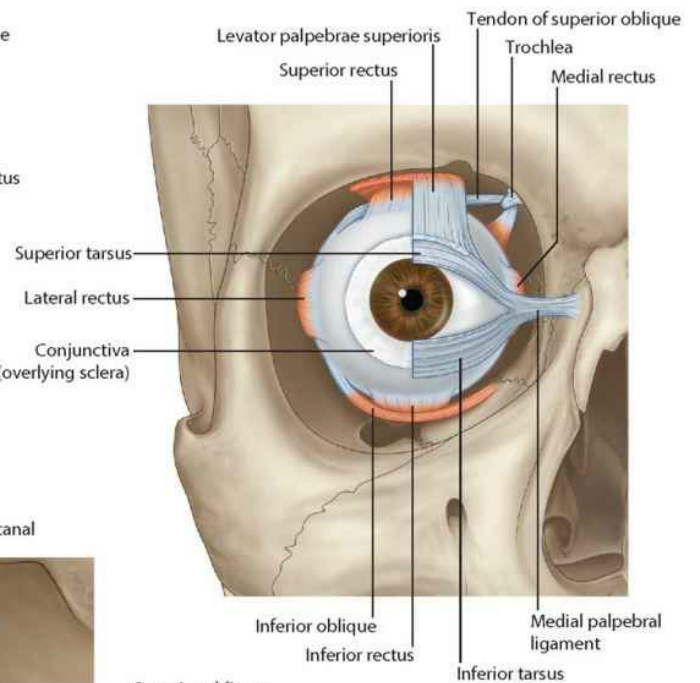
# Muscles of the eyeball



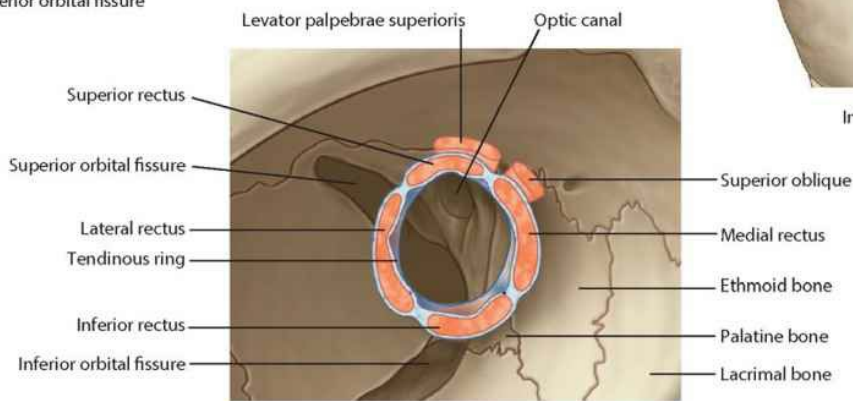
Superior view



Lateral view

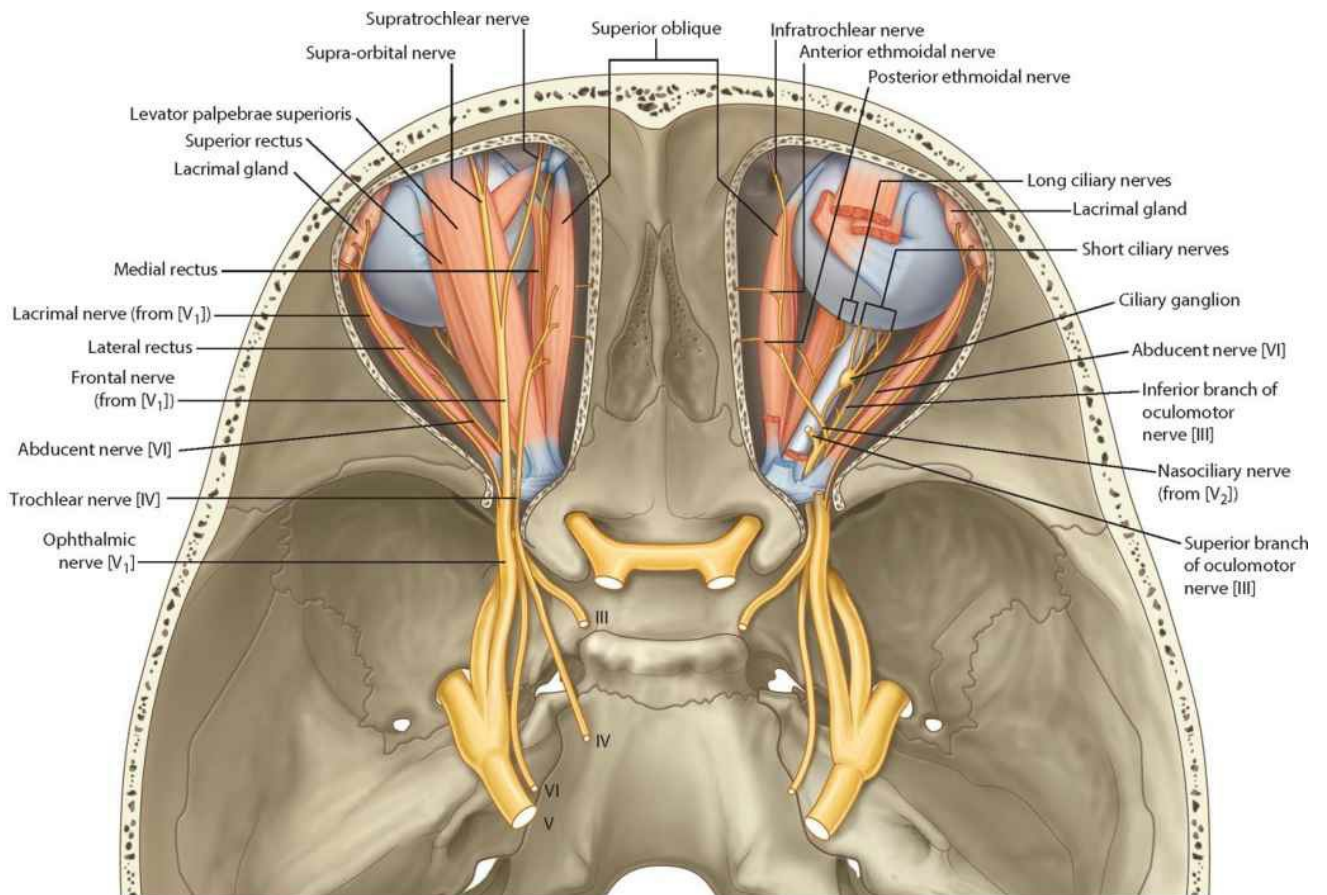


Anterior view

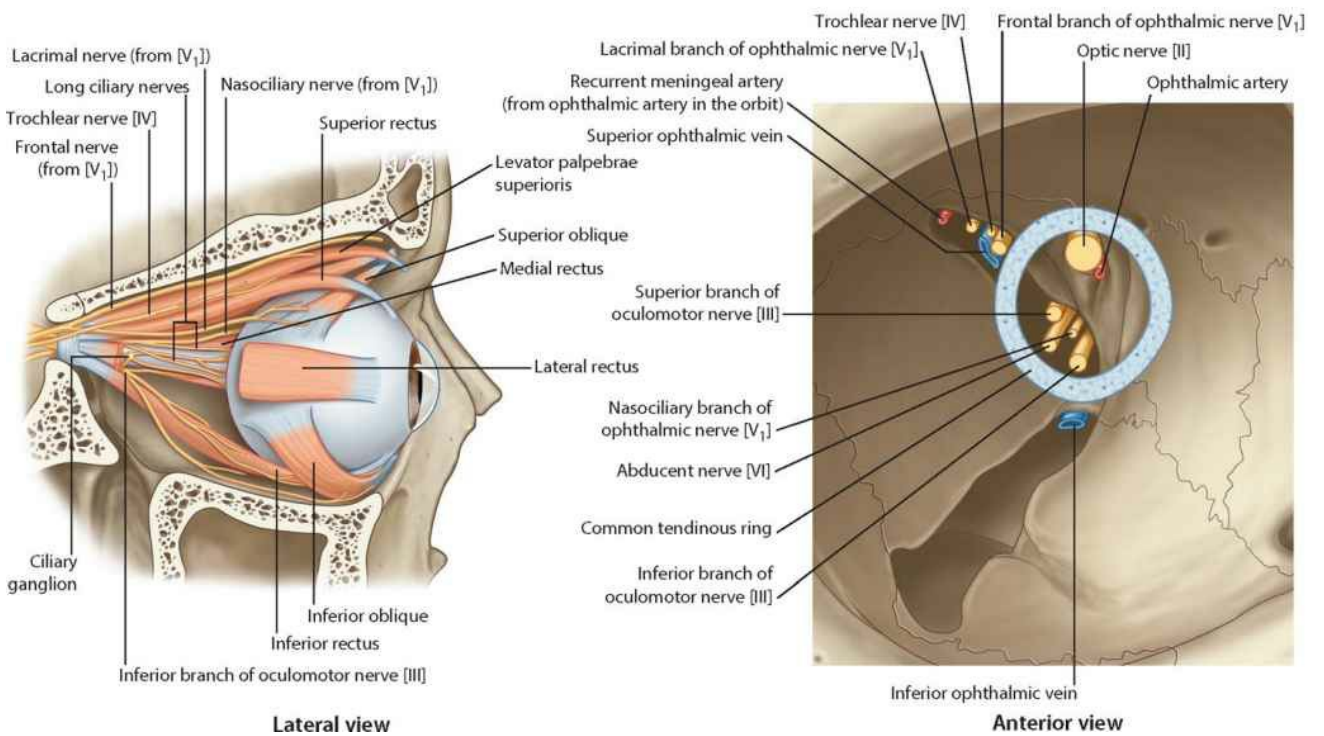


Origins of muscles of the eyeball

# Innervation of the orbit and eyeball



**Superior view**

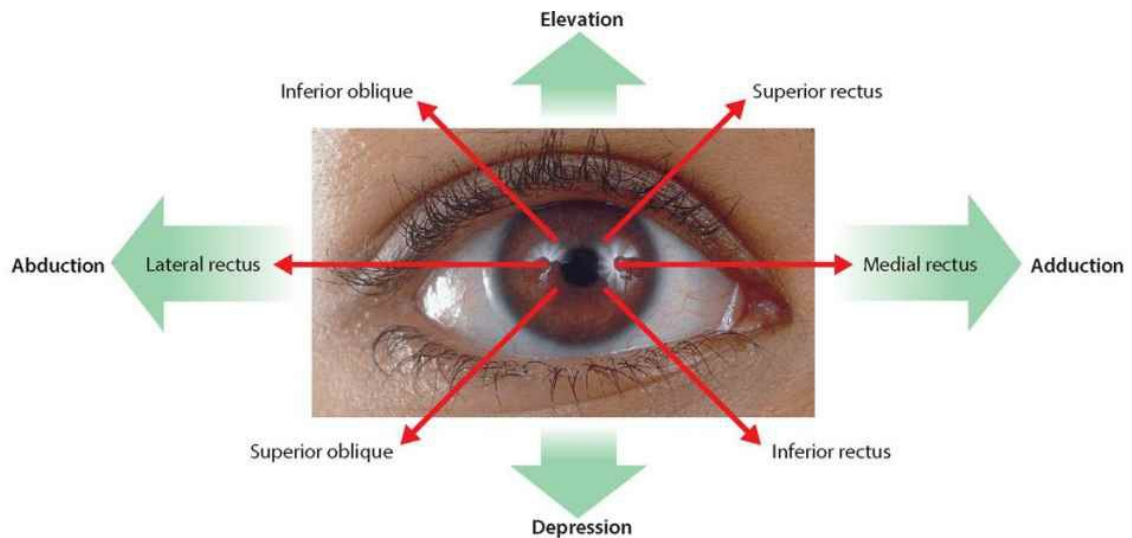


**Lateral view**

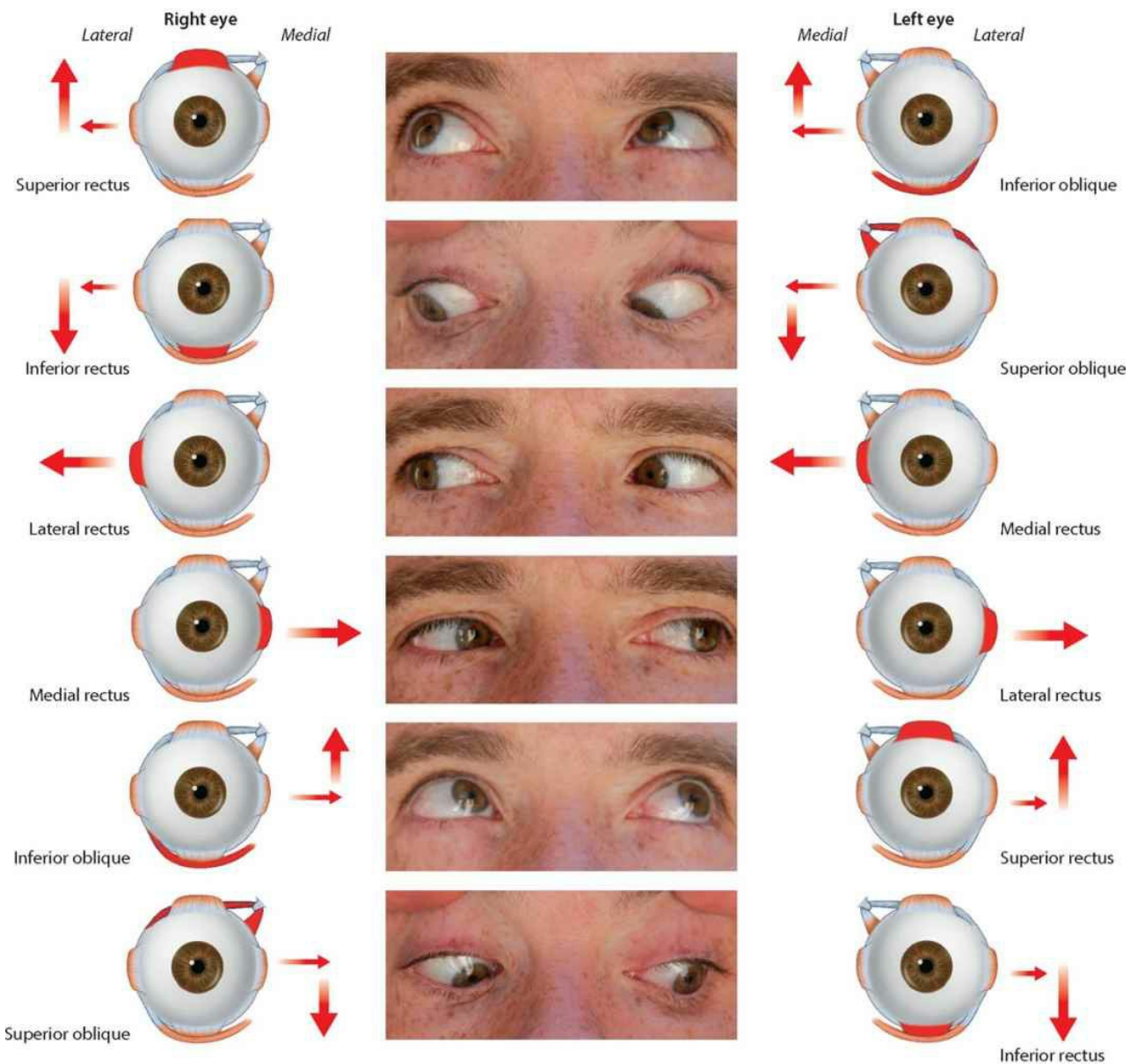
**Anterior view**

# Eye movements





**Actions of individual muscles (anatomical action)**

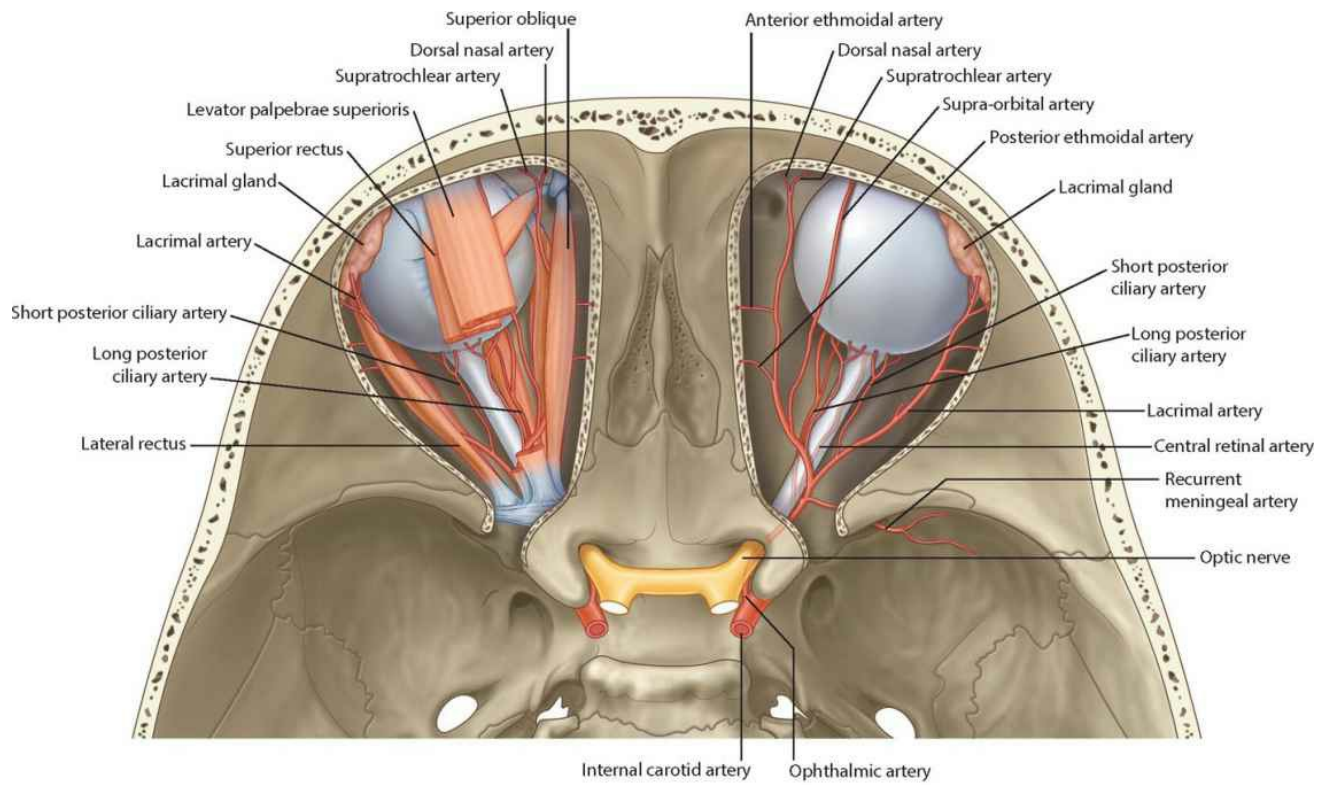


**Movement of eyes when testing specific muscle (clinical testing).**

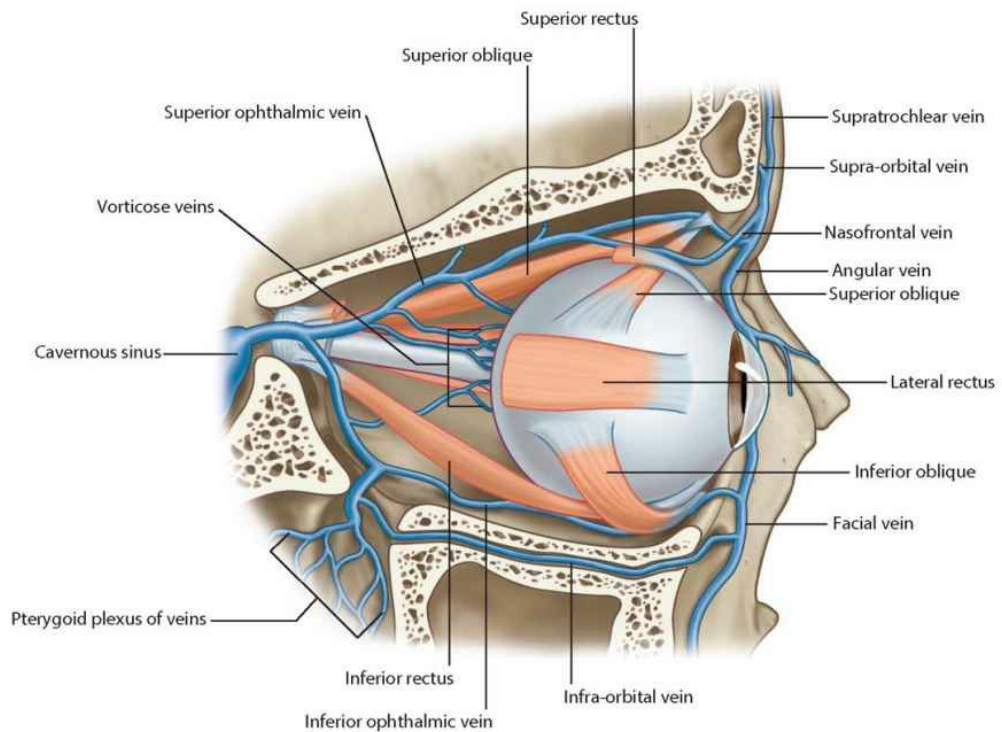
For testing some muscles, a patient is "asked" to first move the eye into a position (small arrow) where the indicated muscle can best be tested. The large arrow indicates the direction the patient is then "asked" to move the eye to test the muscle



# Vasculature of orbit

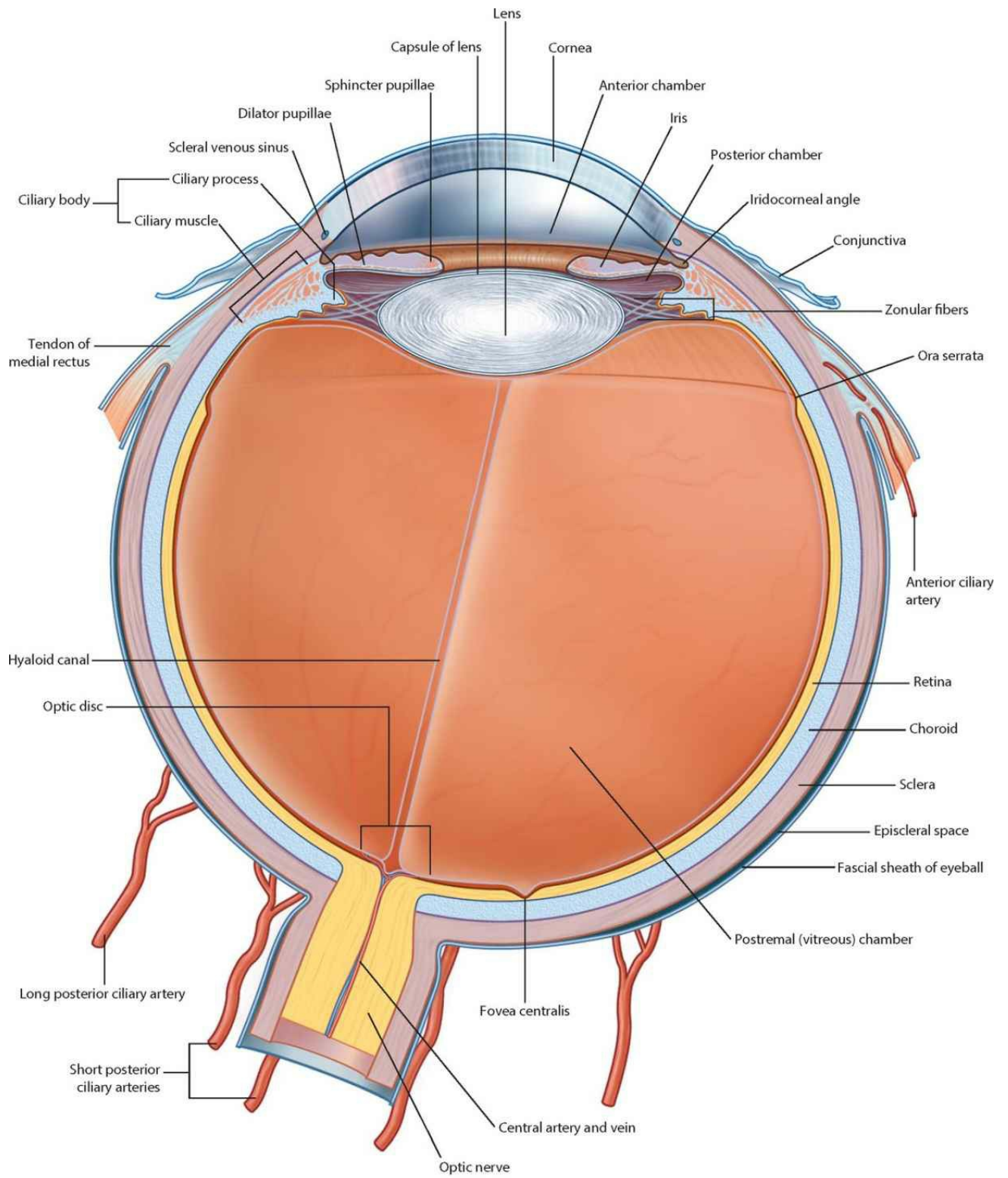


**Arteries of the orbit and eyeball (superior view)**



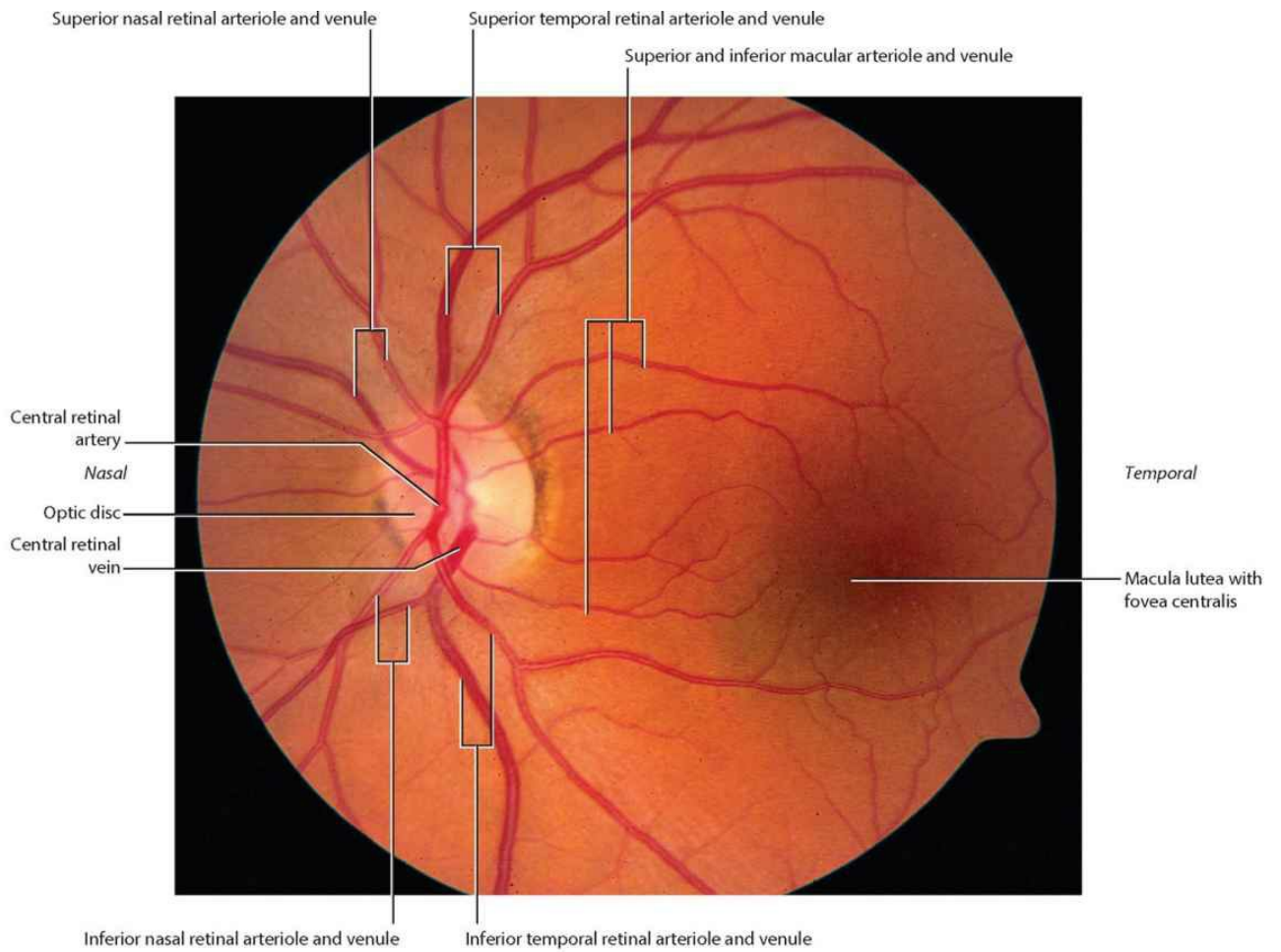
**Veins of the orbit and eyeball (lateral view)**

# Eyeball

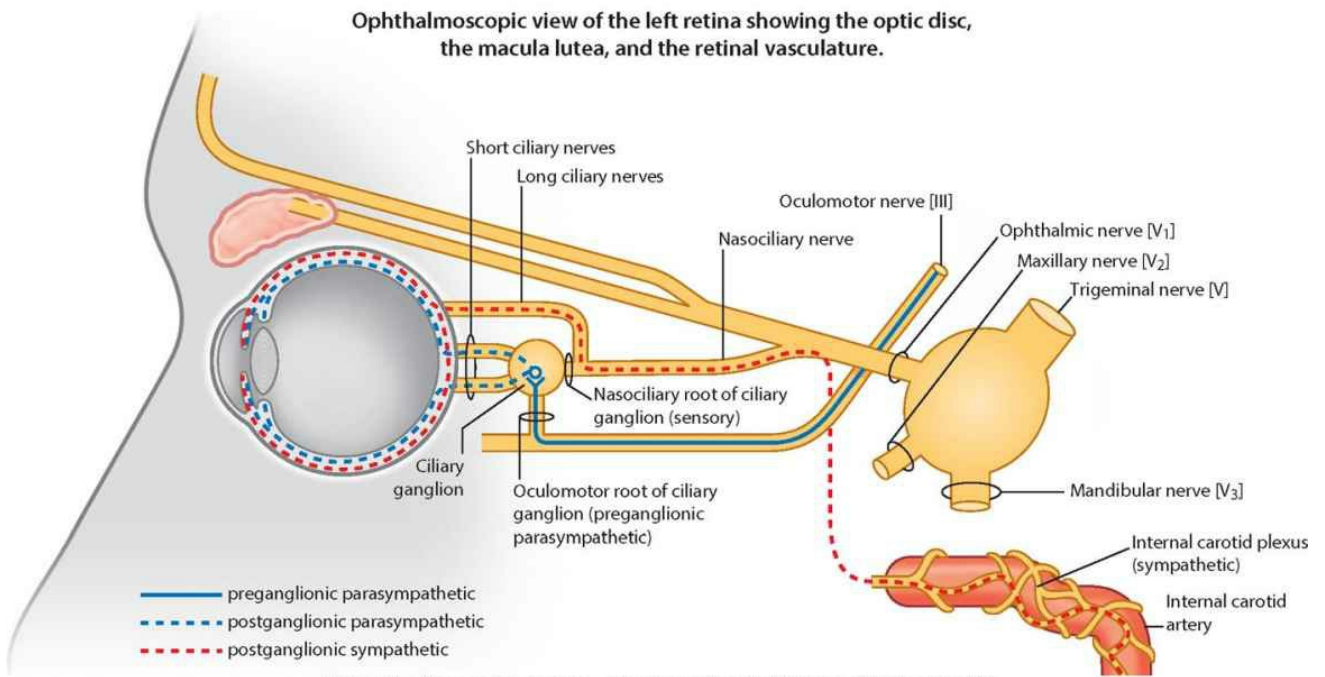


**Eyeball (horizontal section)**

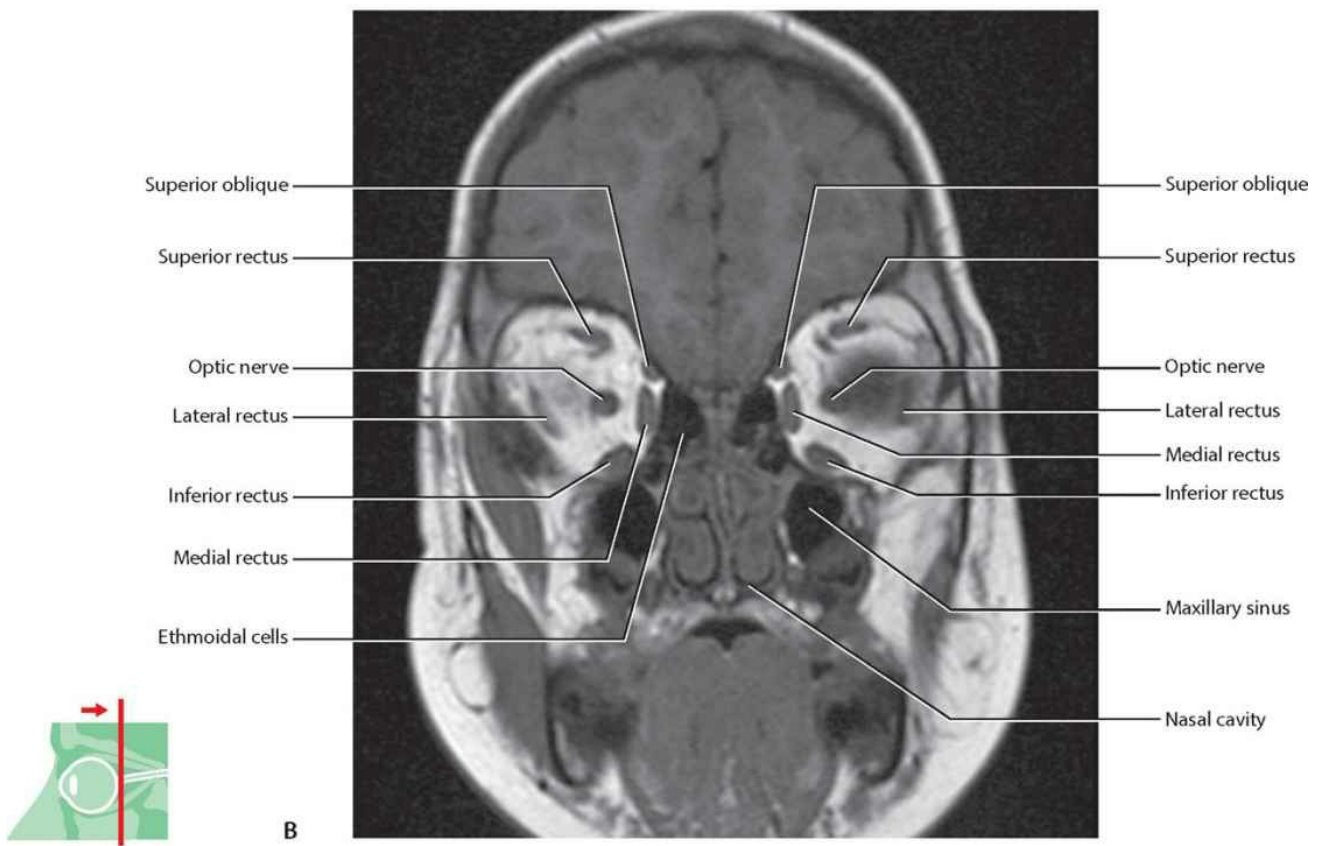
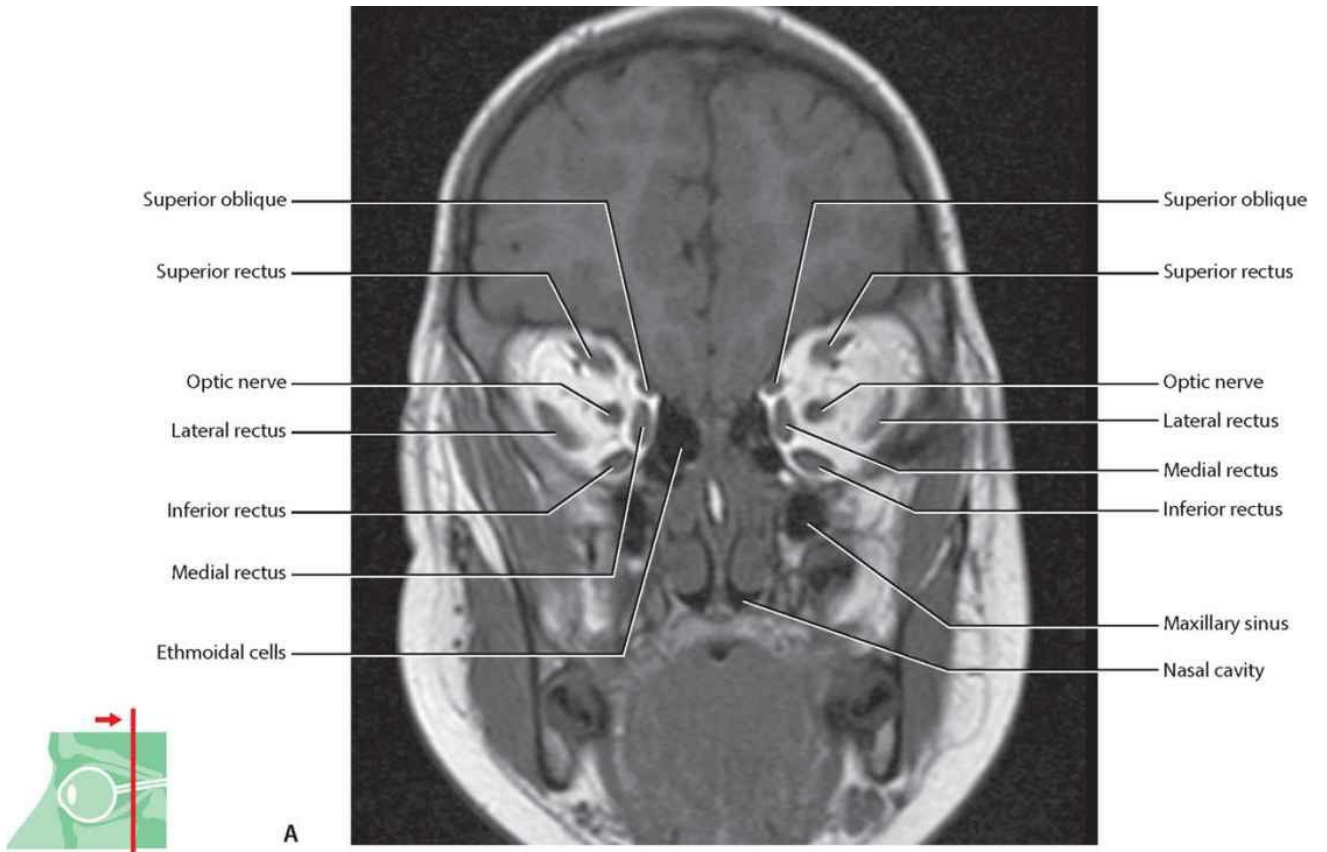
# Eye imaging



**Ophthalmoscopic view of the left retina showing the optic disc, the macula lutea, and the retinal vasculature.**





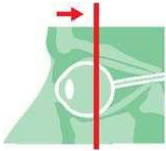


A through D – Coronal sections that pass through the orbit from posterior to anterior showing the extrinsic (extra-ocular) muscles and their relationships with each other and with other structures.  
T1-weighted MR images in coronal plane

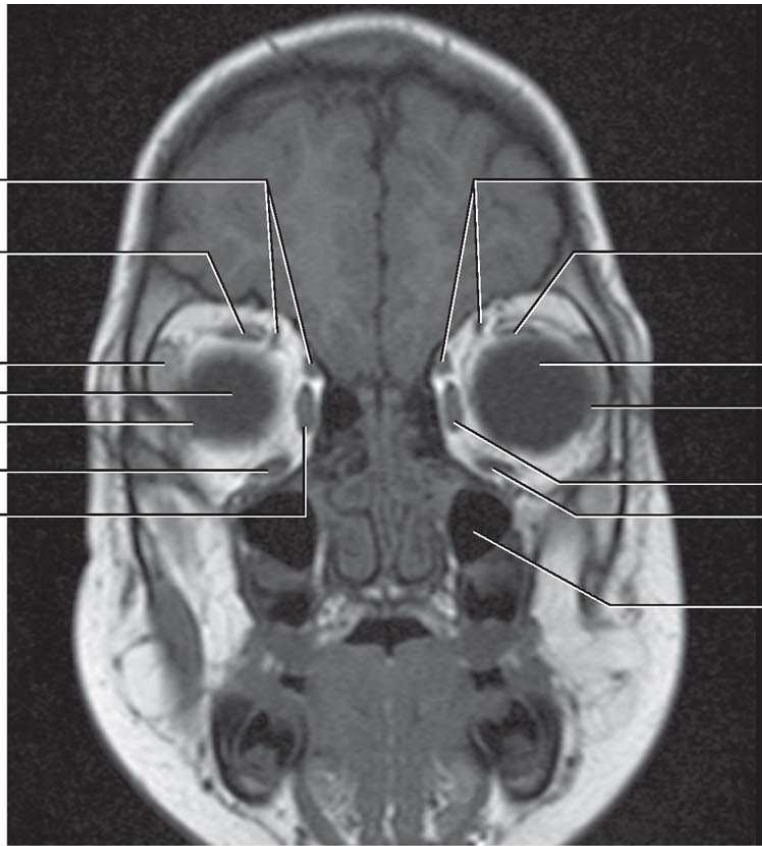


Superior oblique  
 Superior rectus  
 Lacrimal gland  
 Eyeball  
 Lateral rectus  
 Inferior rectus  
 Medial rectus

Superior oblique  
 Superior rectus  
 Eyeball  
 Lateral rectus  
 Medial rectus  
 Inferior rectus  
 Maxillary sinus

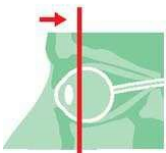


C

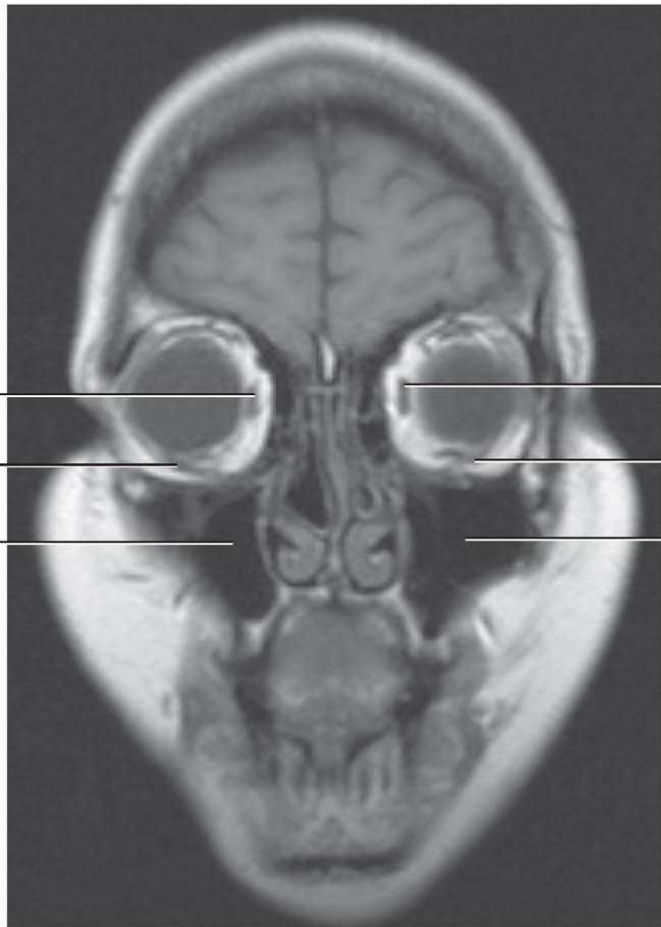

Medial rectus  
 Inferior oblique  
 Maxillary sinus

Medial rectus  
 Inferior oblique  
 Maxillary sinus

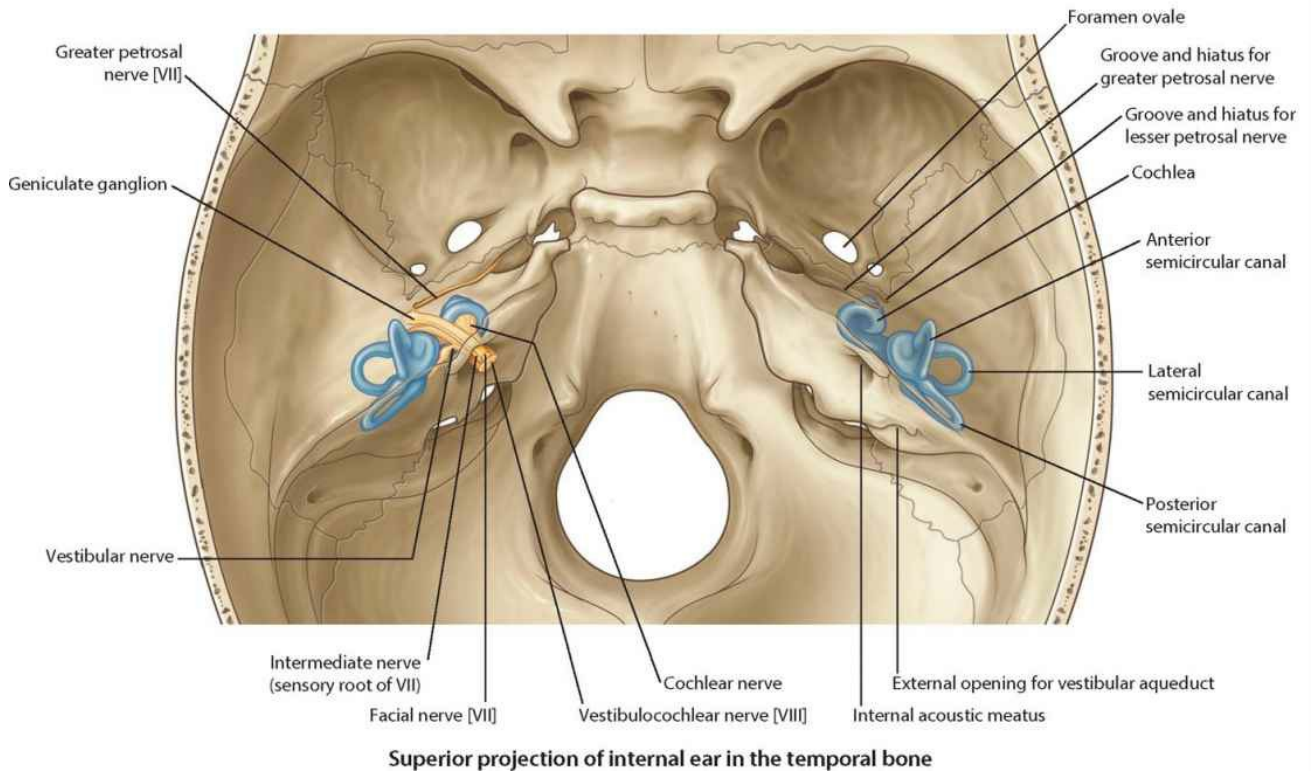
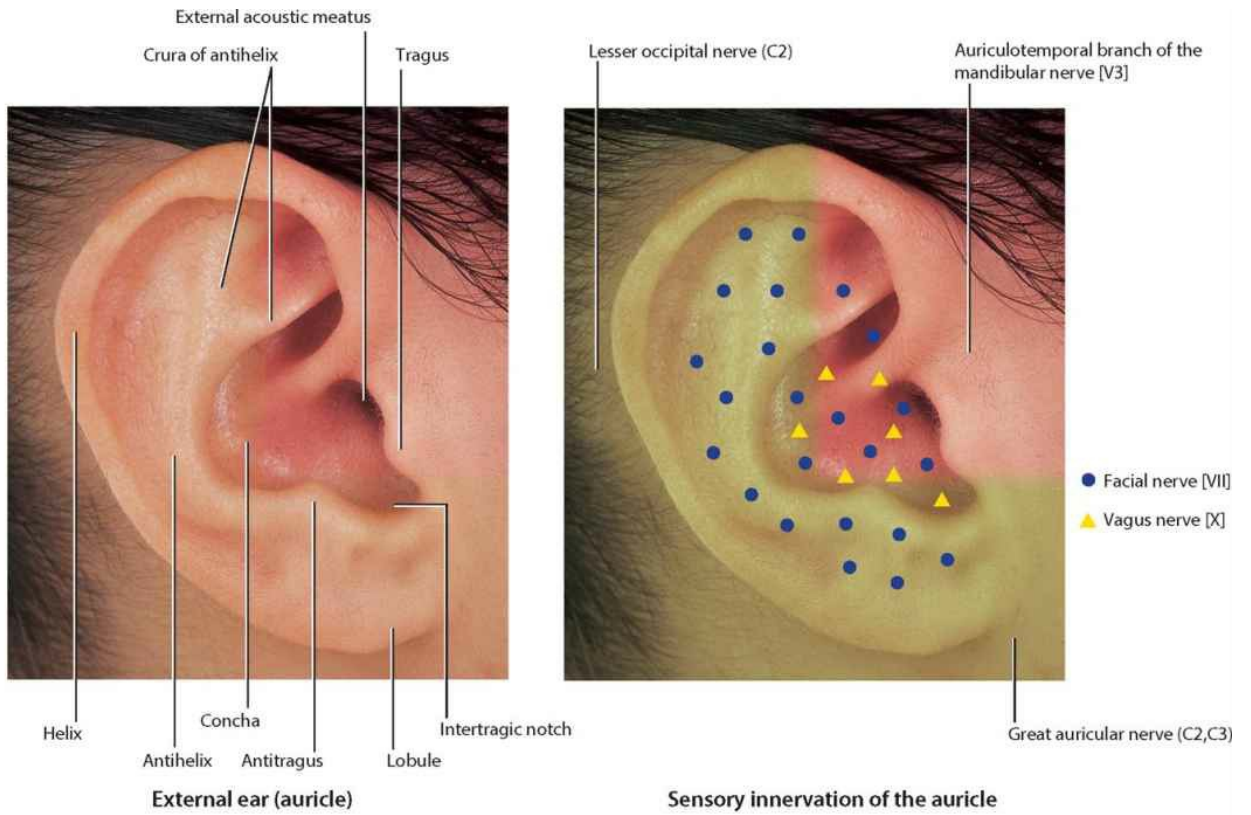


D

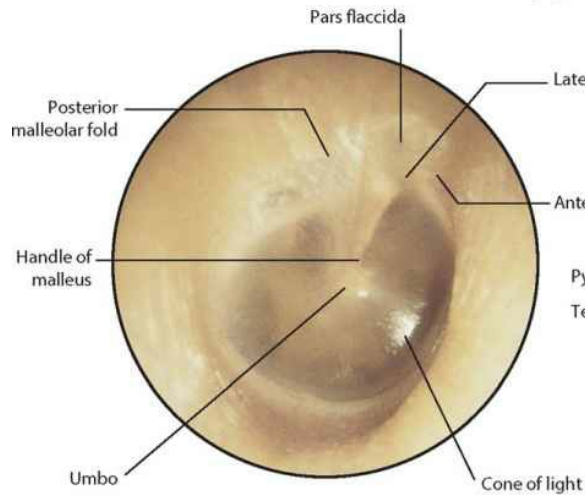
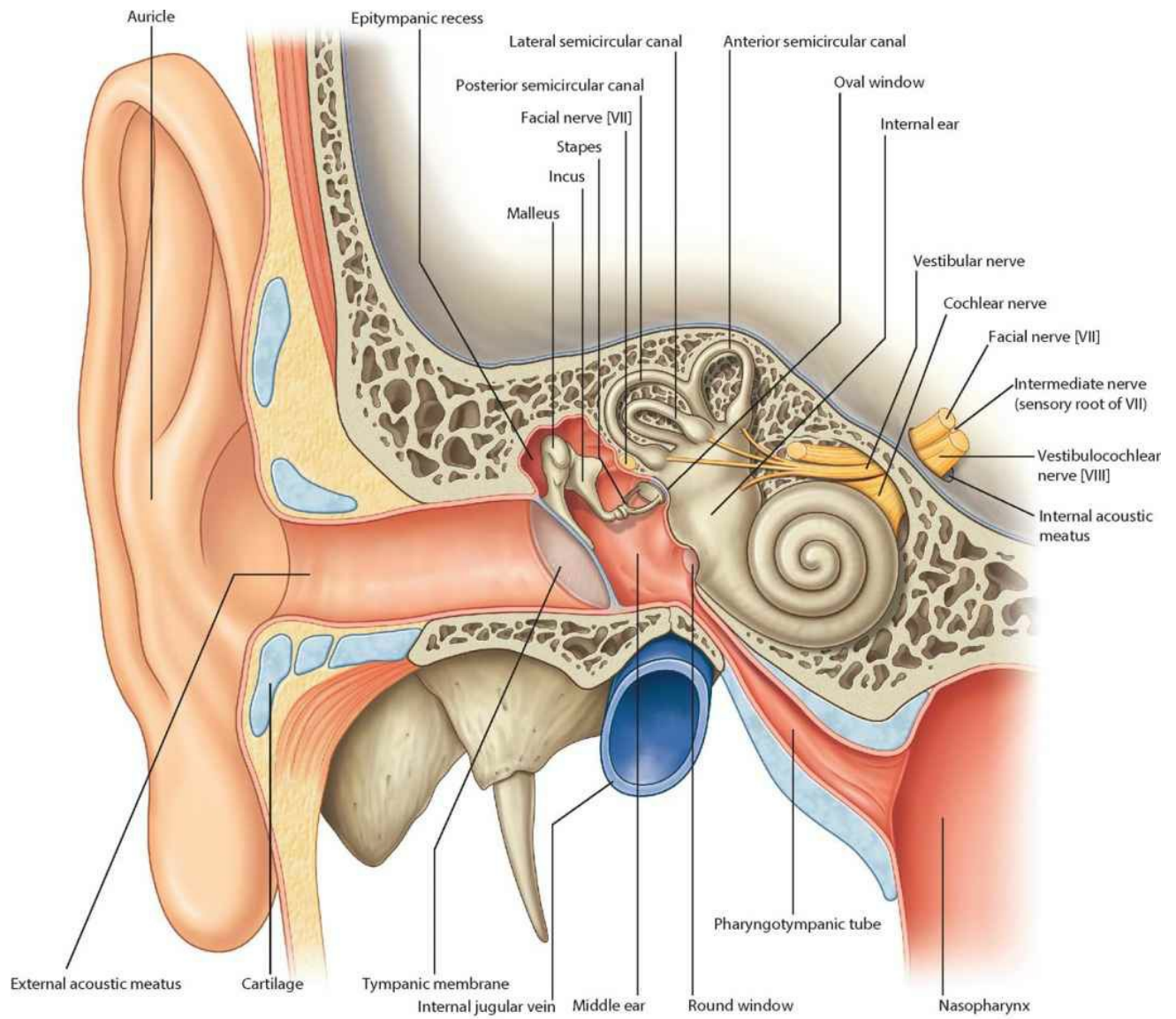




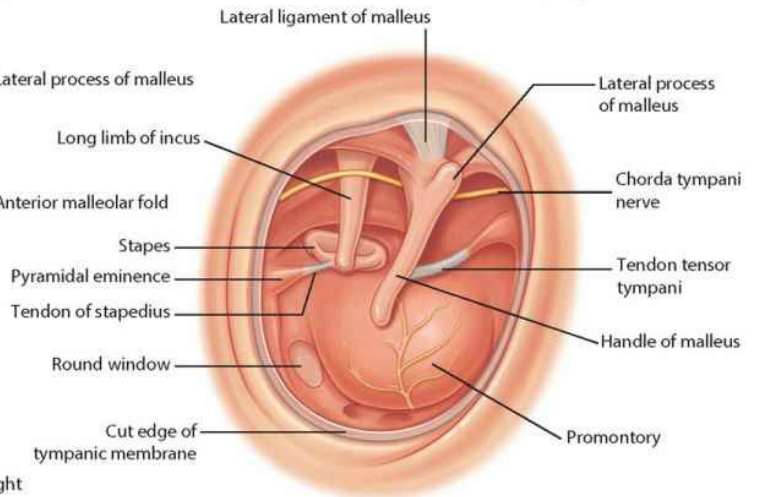
# Ear surface and sensory innervation



**Ear**



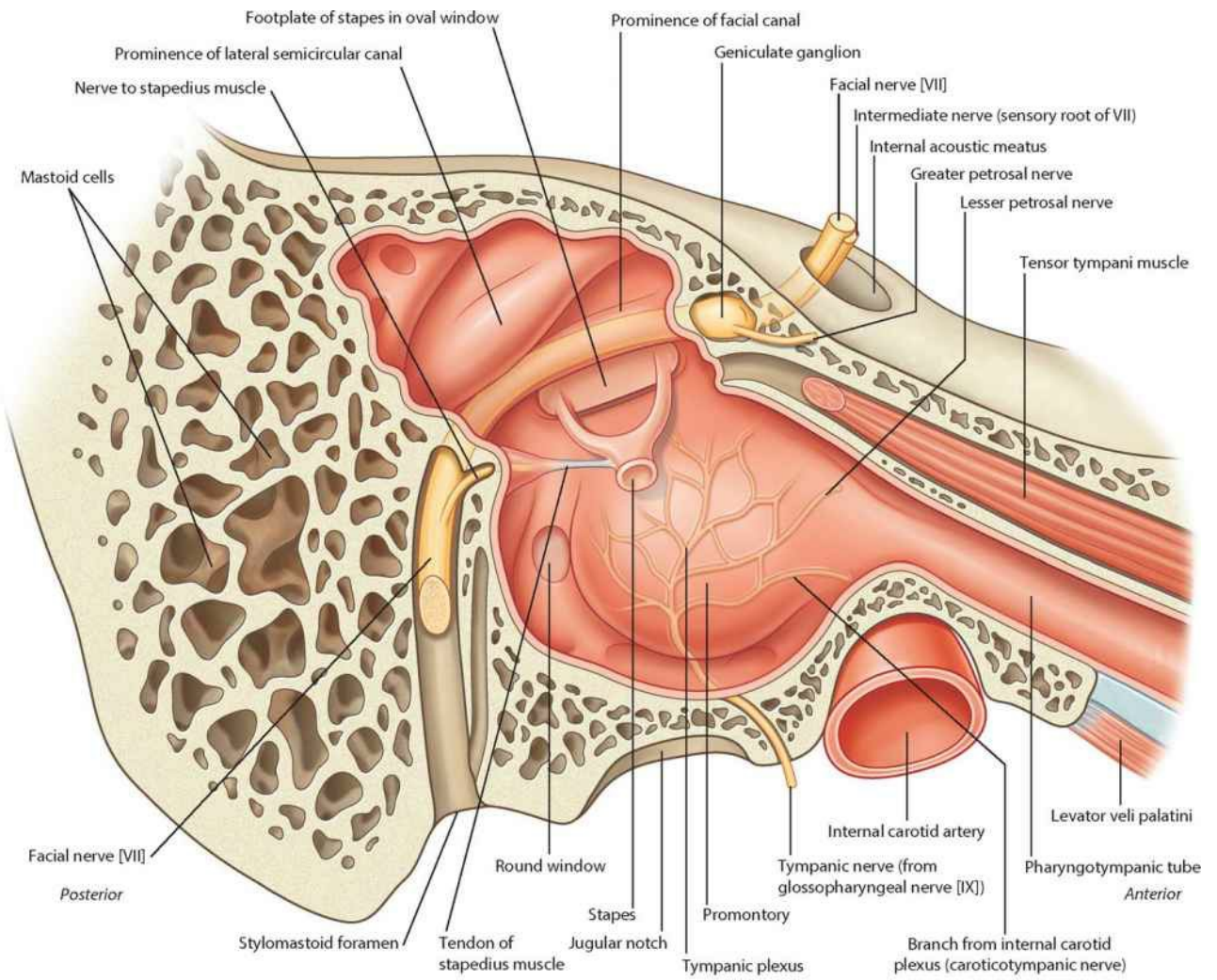
**Right tympanic membrane**



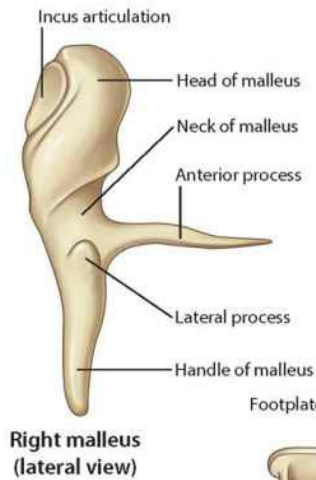**View into right tympanic cavity (tympanic membrane removed)**



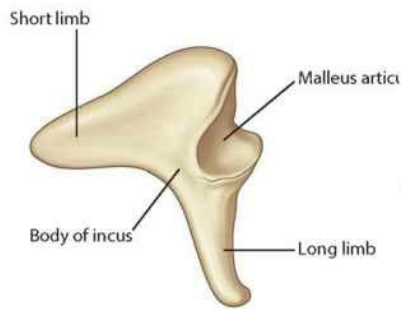
## Middle ear



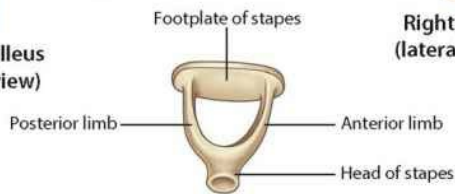
**Right medial wall of the middle ear**



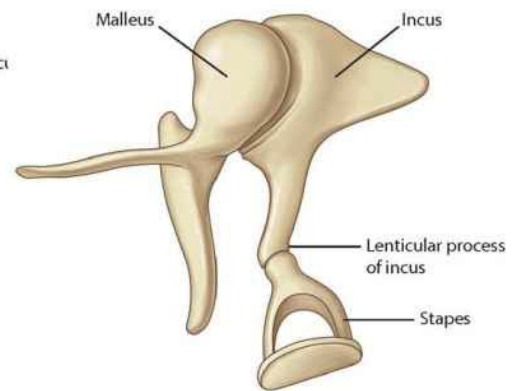
**Right malleus (lateral view)**



**Right incus (lateral view)**

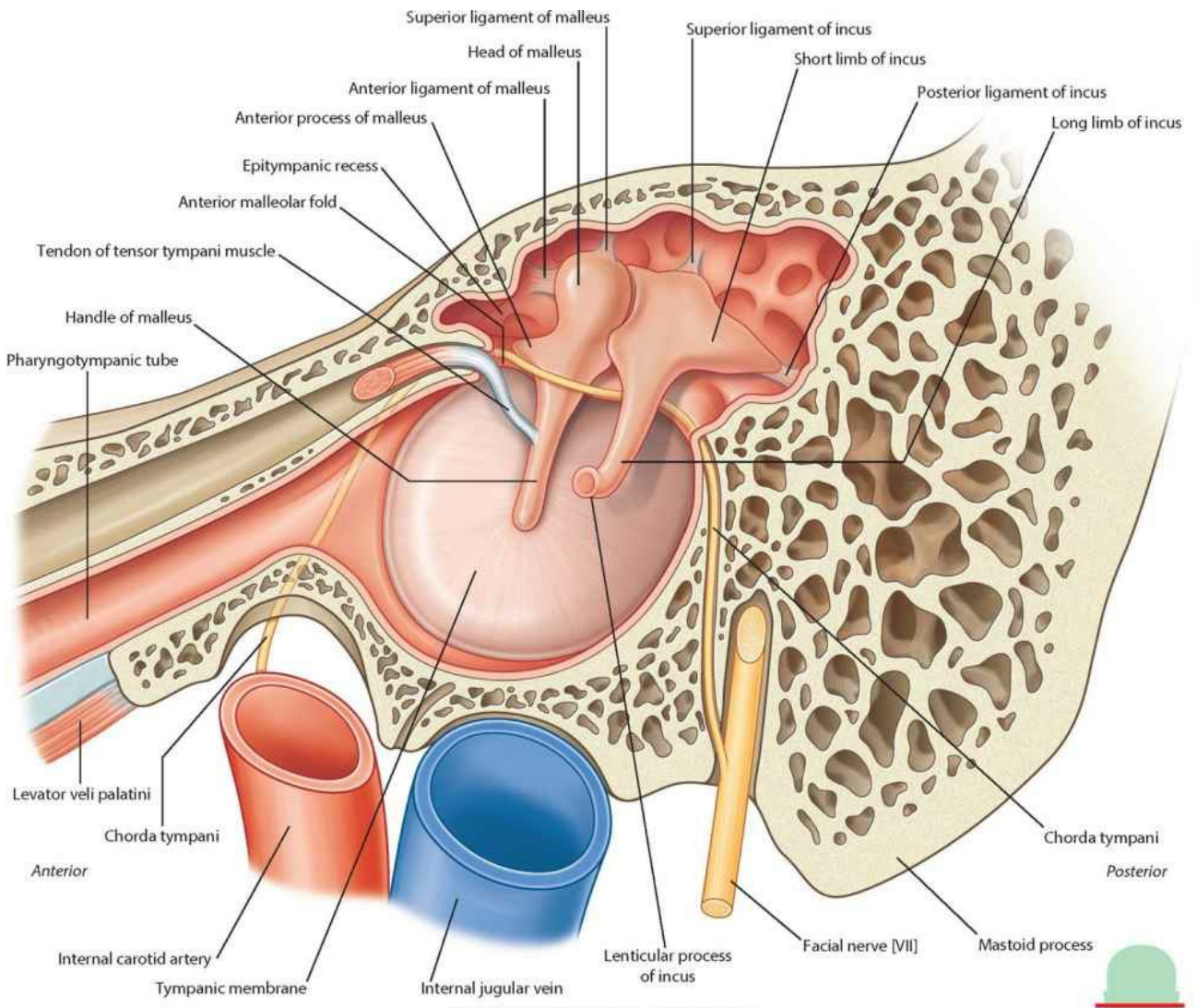


**Right stapes (superolateral view)**

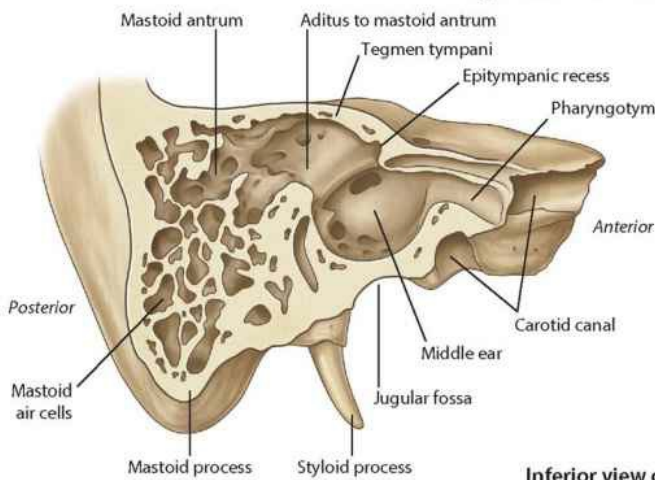


**Right auditory ossicles articulated (medial view)**

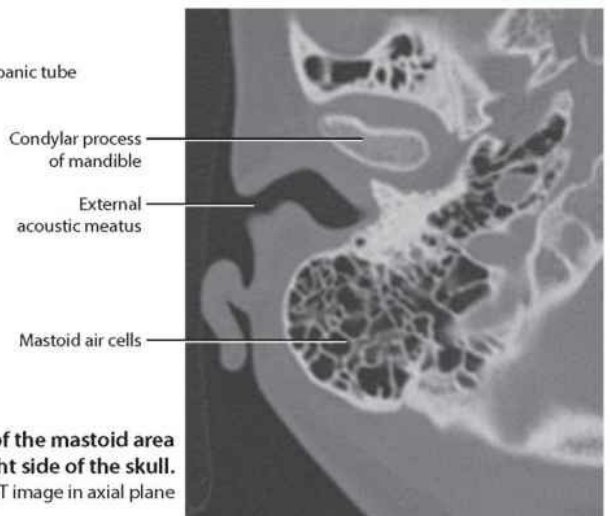




**Right lateral wall of the middle ear**

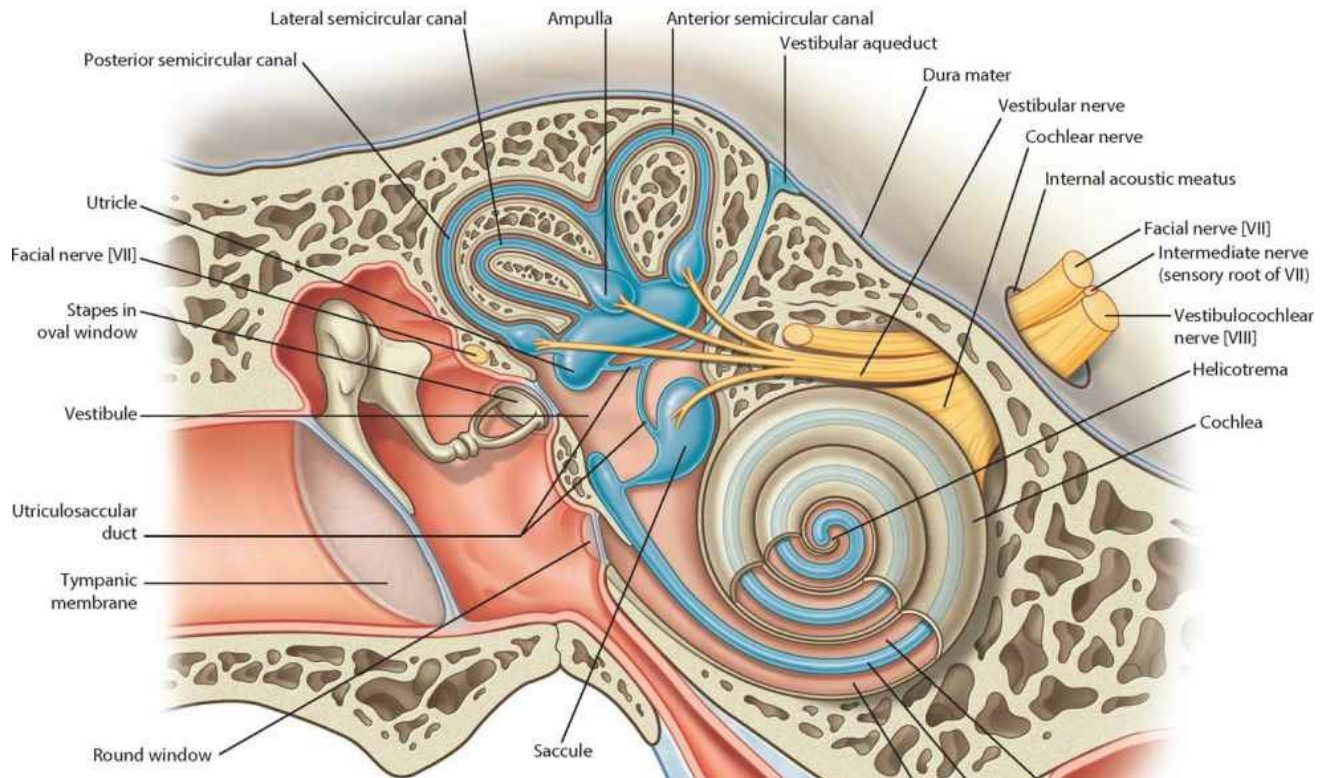


**Right mastoid antrum and surrounding bone**

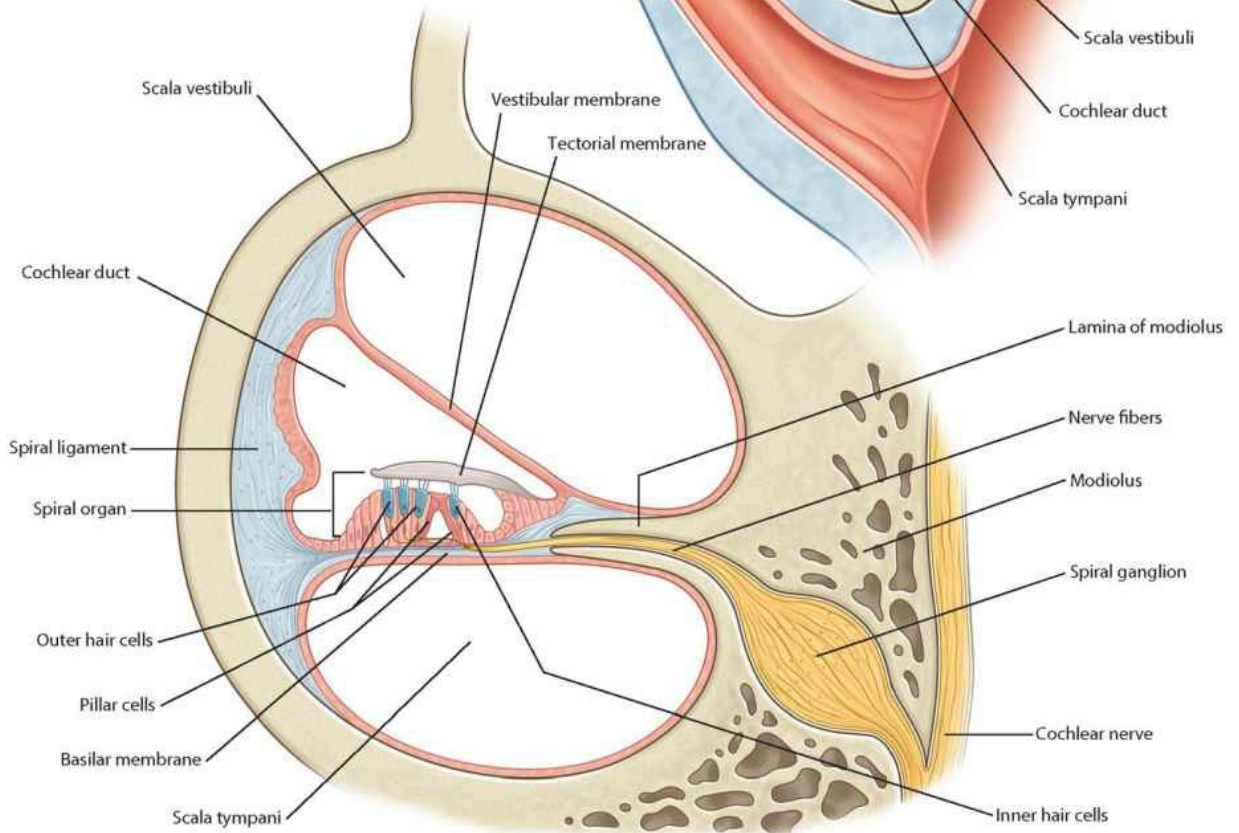


**Inferior view of the mastoid area on the right side of the skull.**  
 CT image in axial plane

# Internal ear

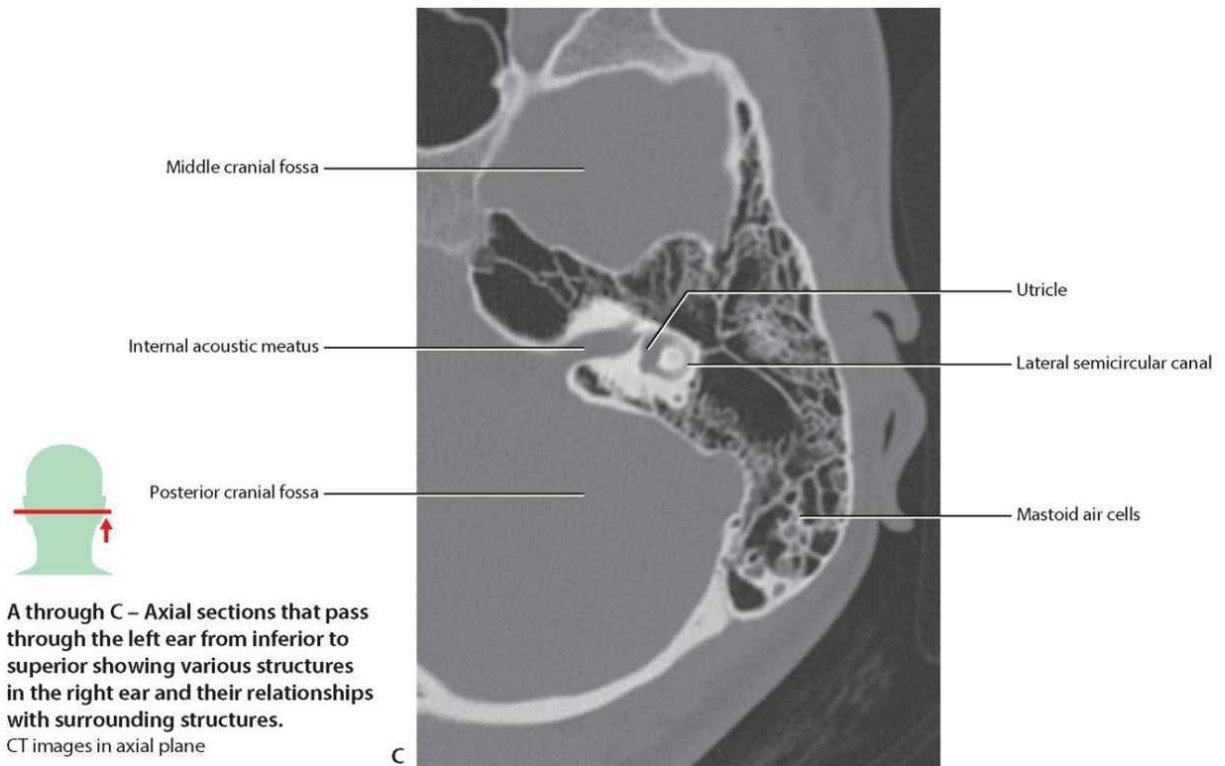
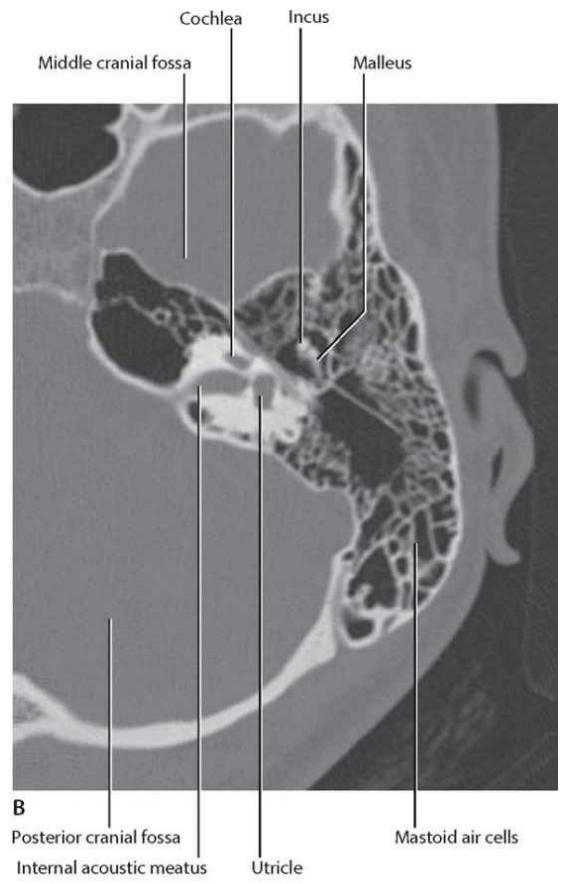
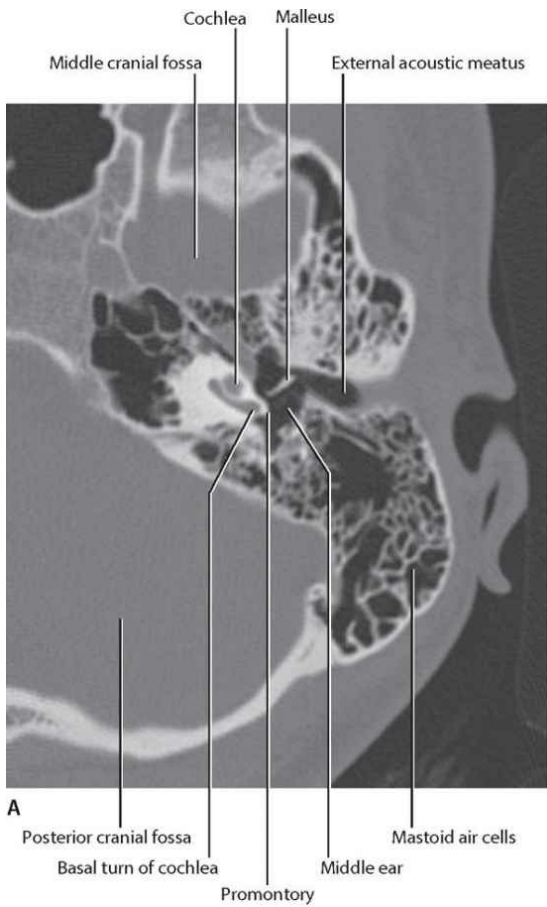


**Structures of the internal ear (right)**



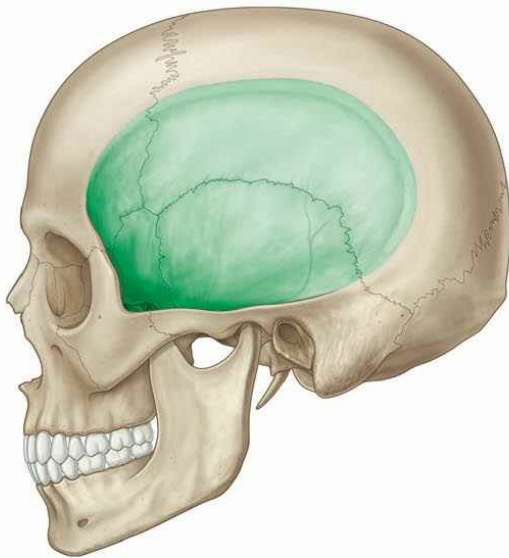
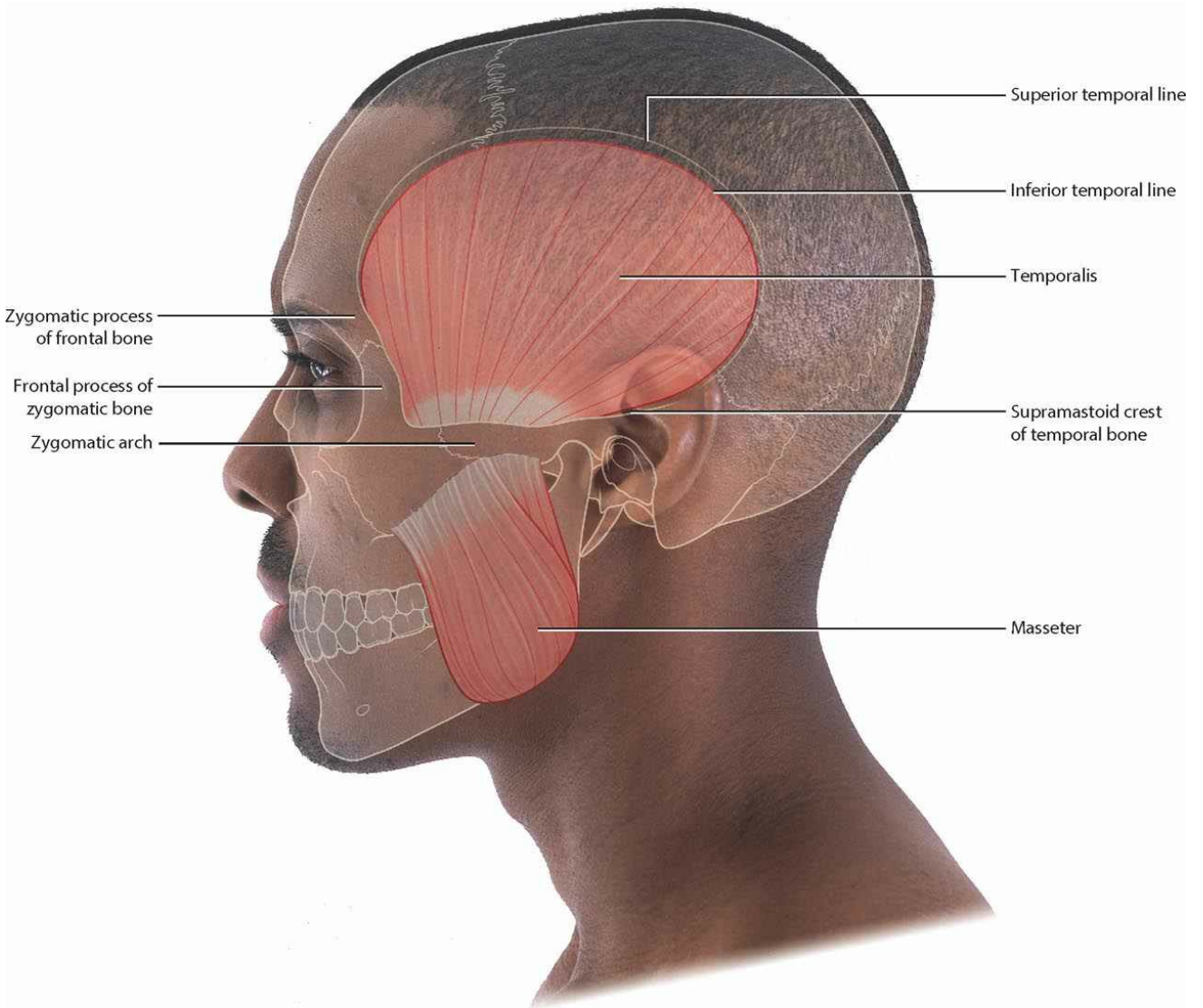
**Cross section through cochlea**

# Ear imaging

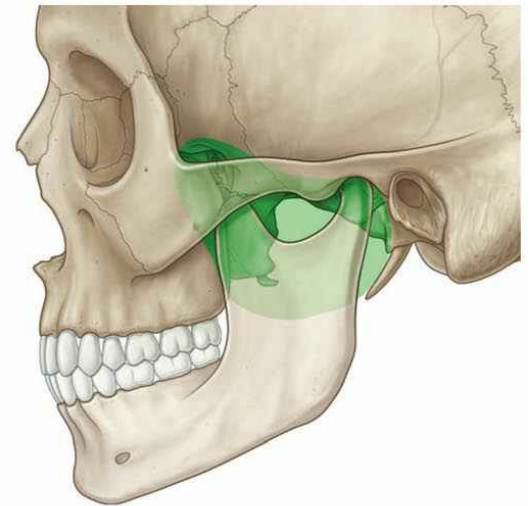




# Temporal and infratemporal fossae

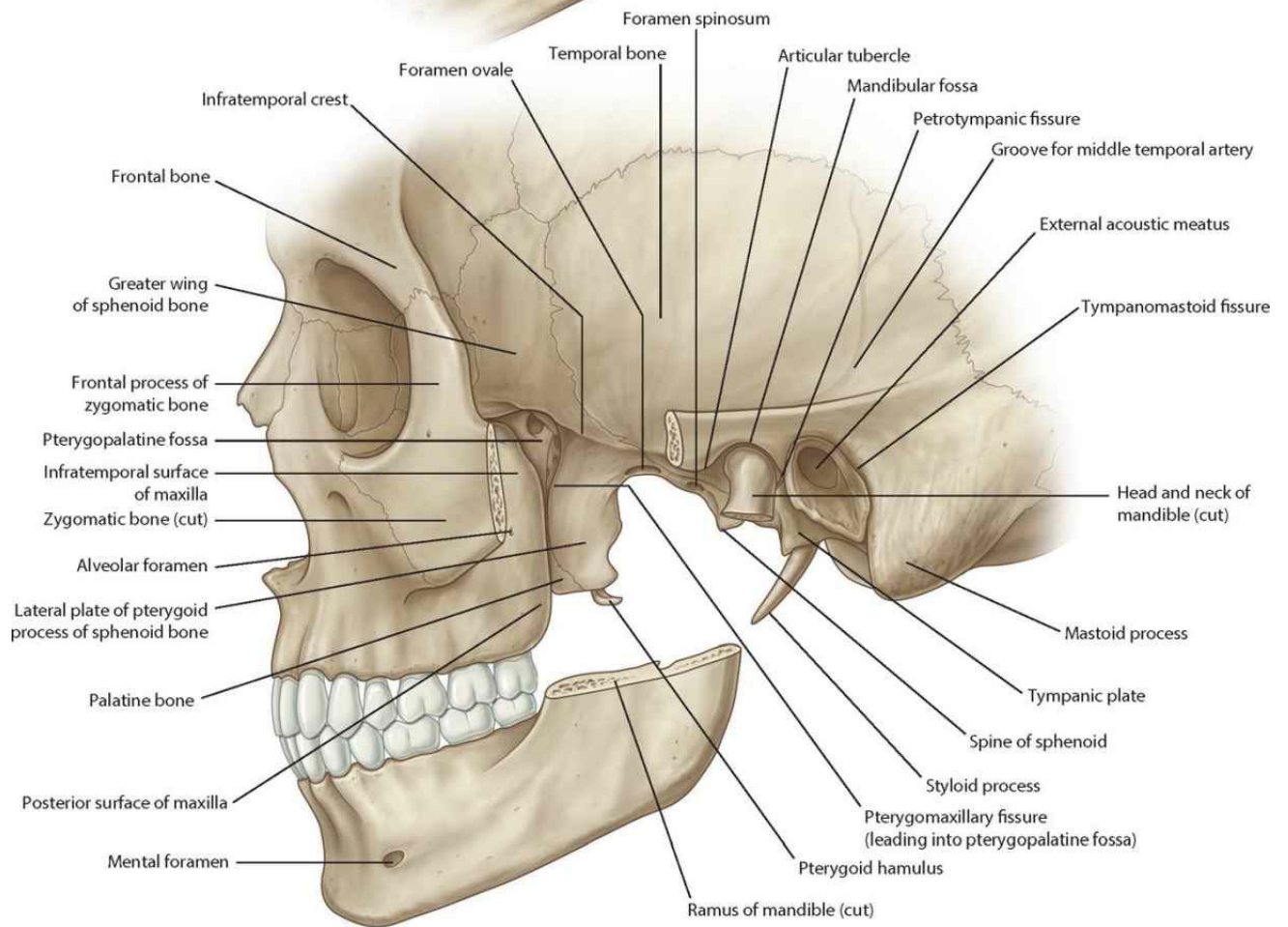
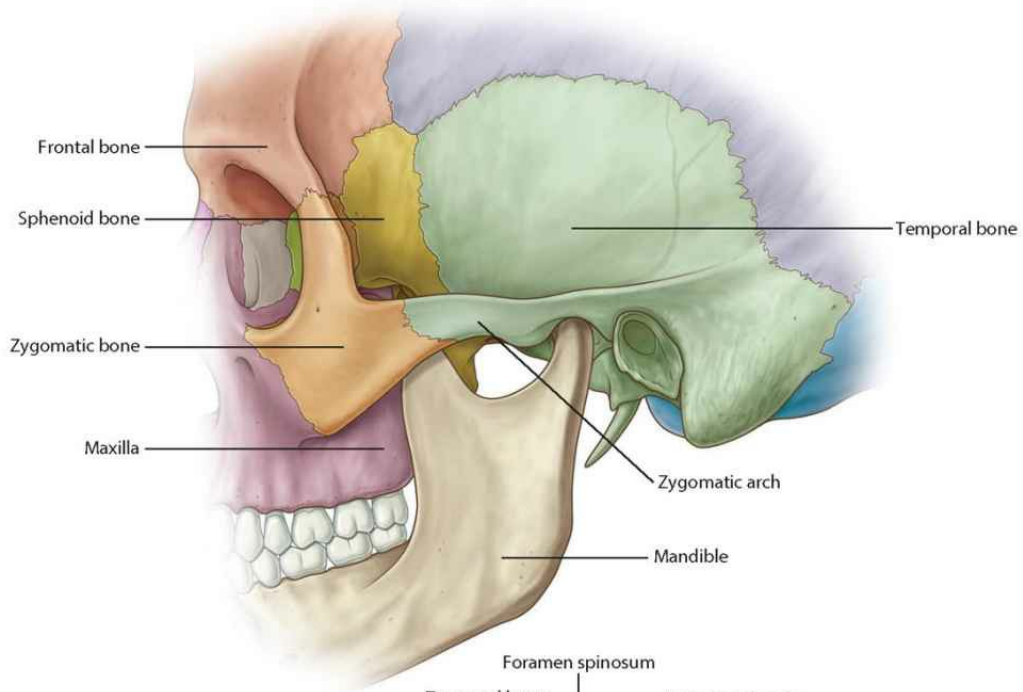


Temporal fossa



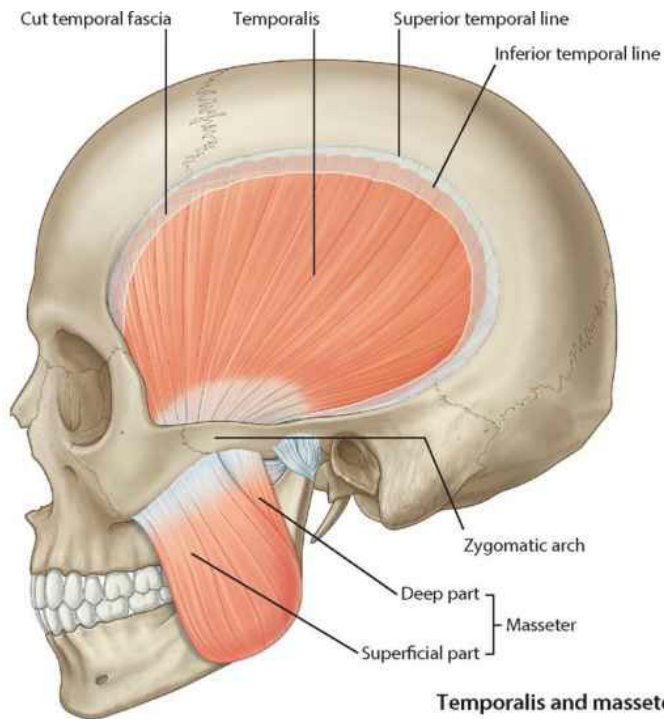
Infratemporal fossa

# **Bones of the temporal and infratemporal fossae**

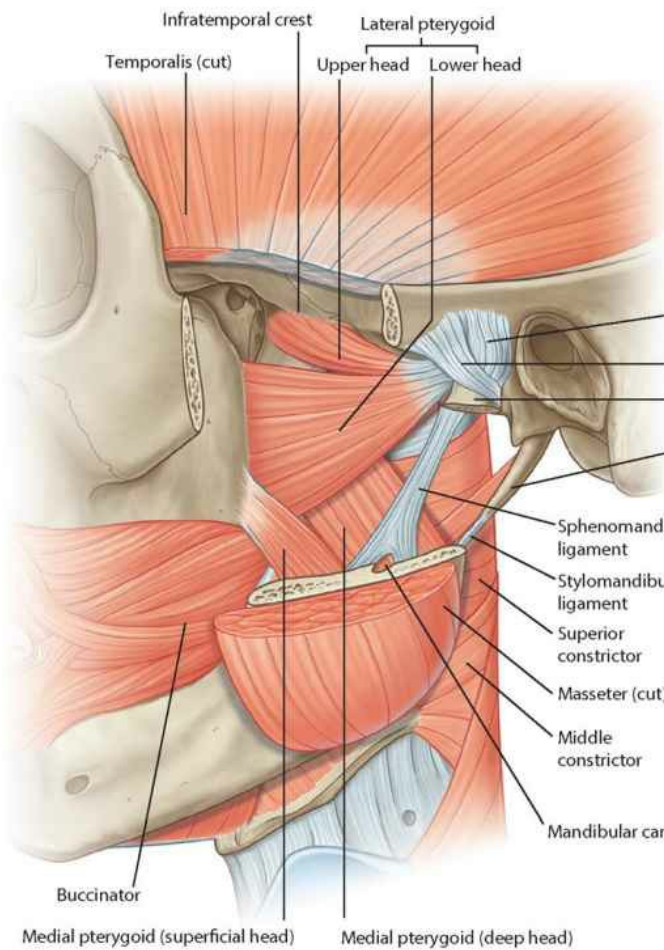
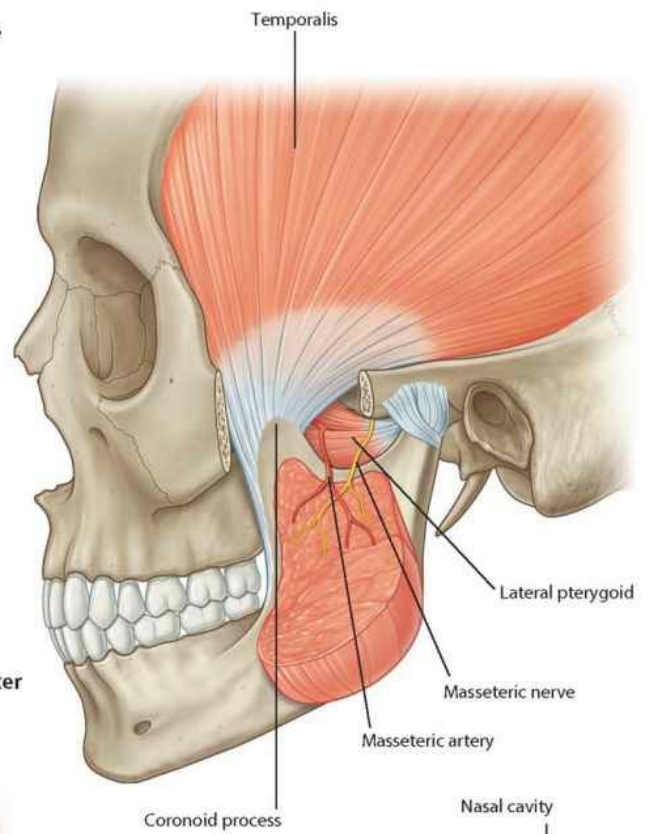


**Bones of the temporal and infratemporal fossae**

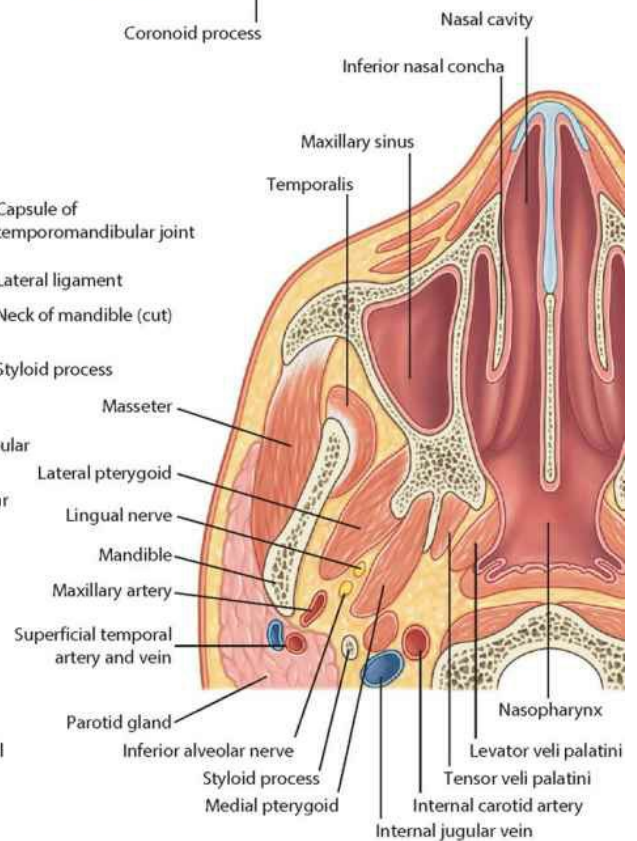
# Temporal and infratemporal fossae



**Temporalis and masseter**



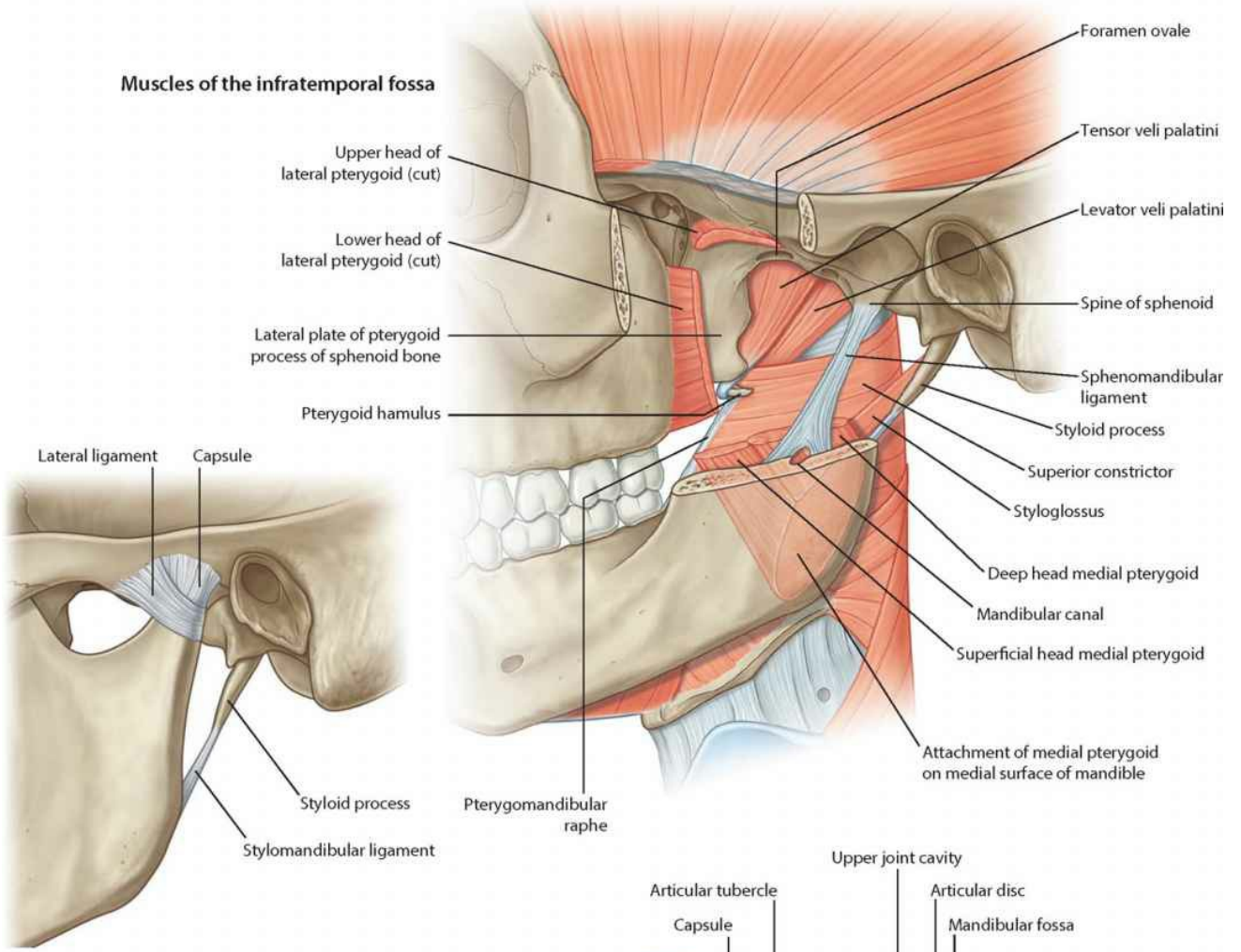
**Muscles of the infratemporal fossa**



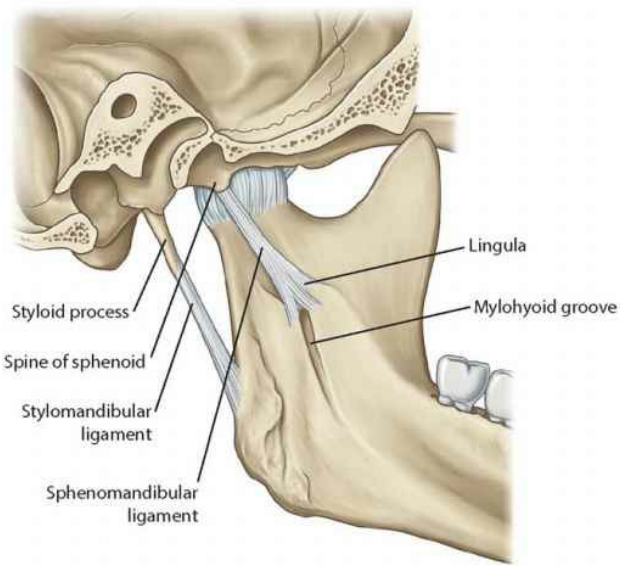
**Horizontal (axial) through infratemporal fossa (inferior view)**



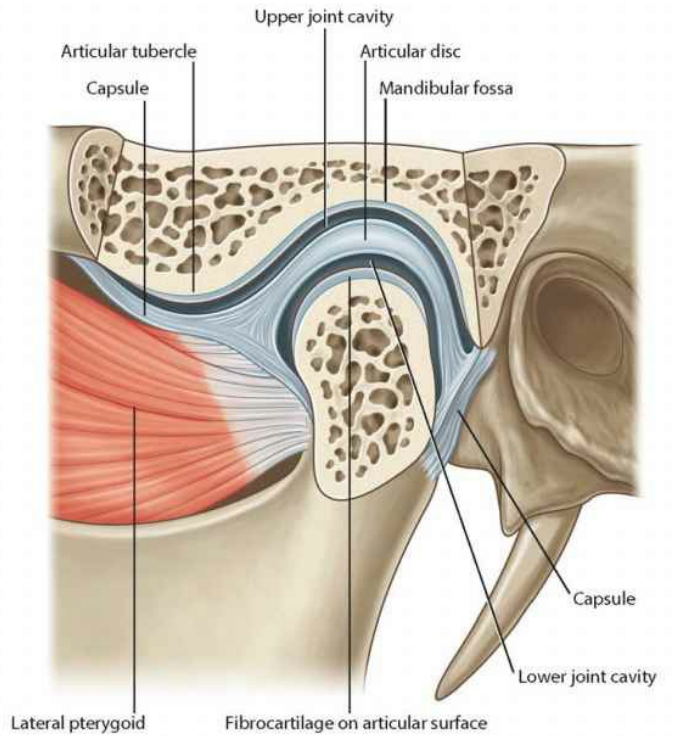
**Muscles of the infratemporal fossa**



**Temporomandibular joint (lateral view)**



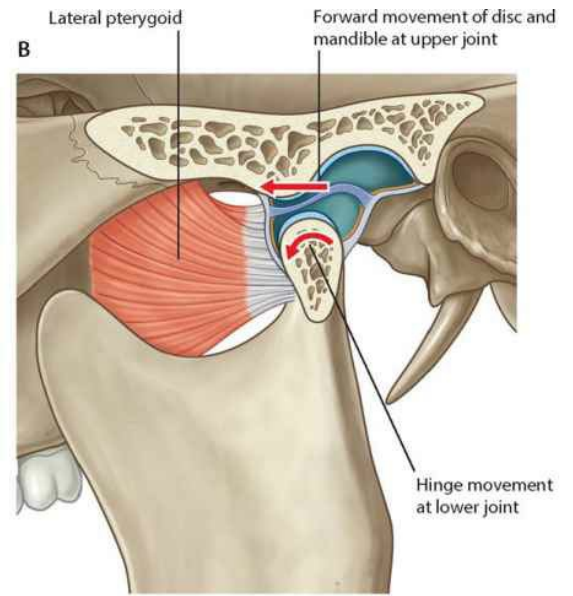
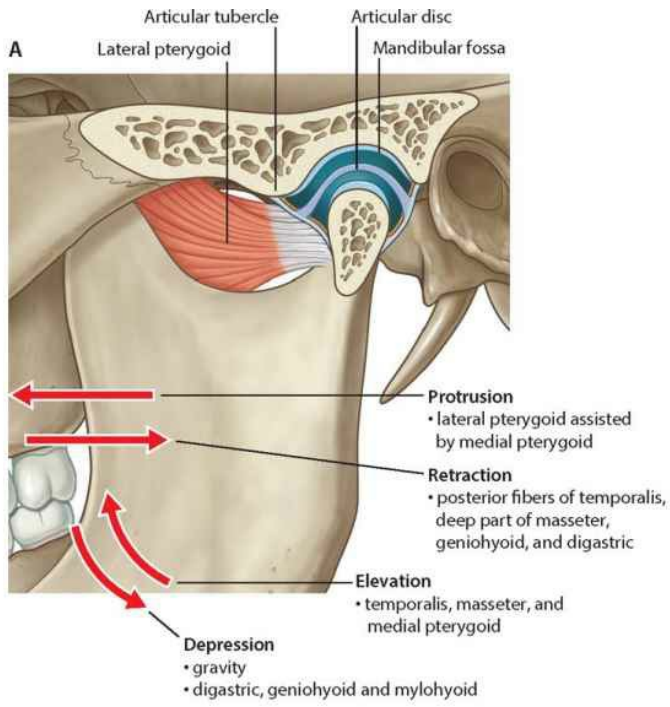
**Temporomandibular joint (medial view)**



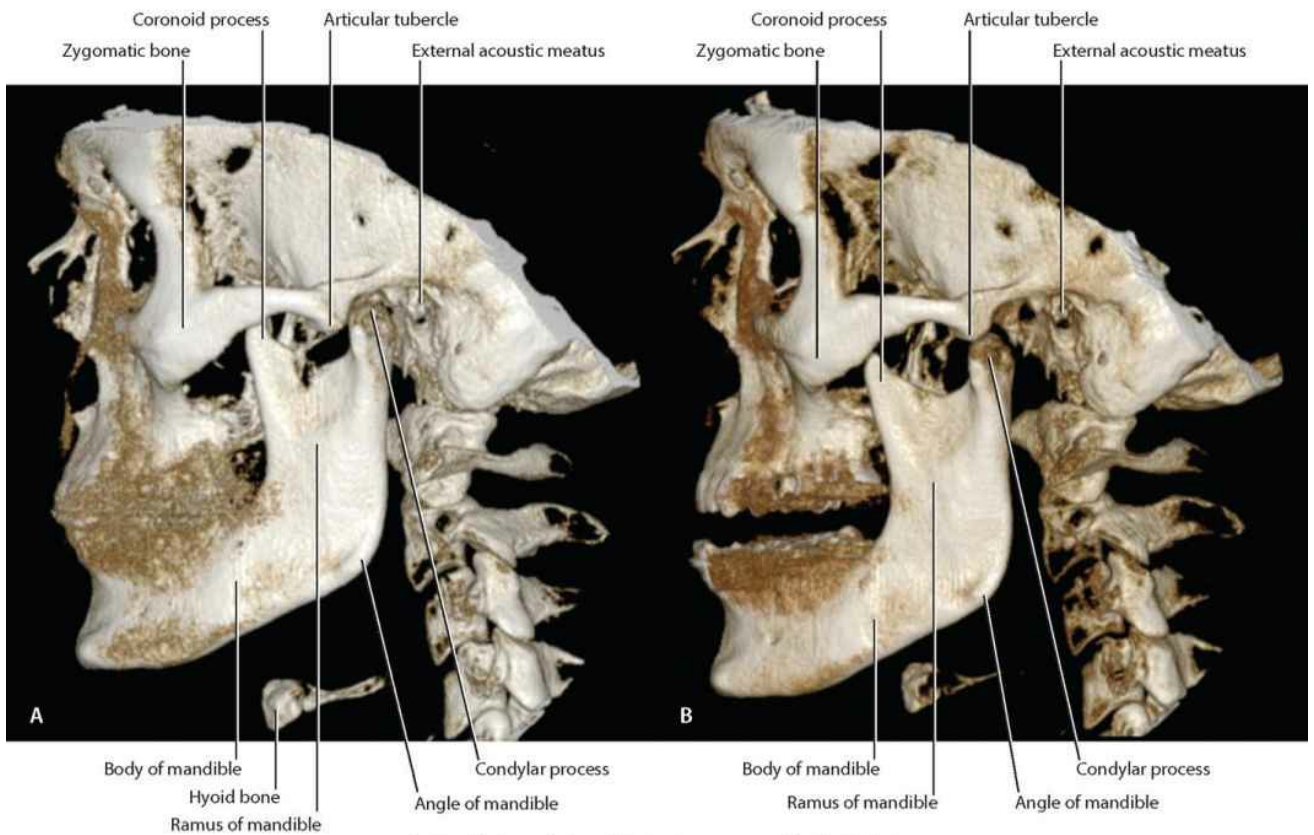
**Sagittal section through temporomandibular joint**



# Temporomandibular joint



**Movements of the temporomandibular joint.**  
A. Mouth closed. B. Mouth open

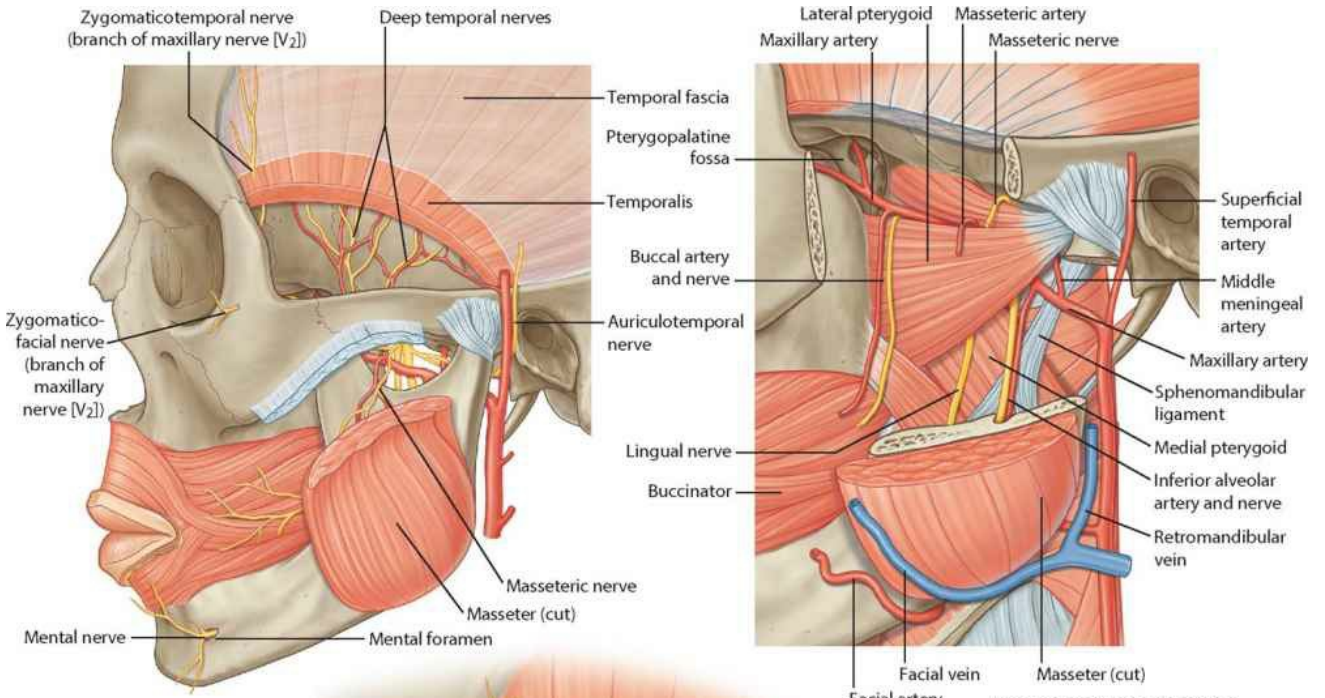


**Lateral view of the right temporomandibular joint.**

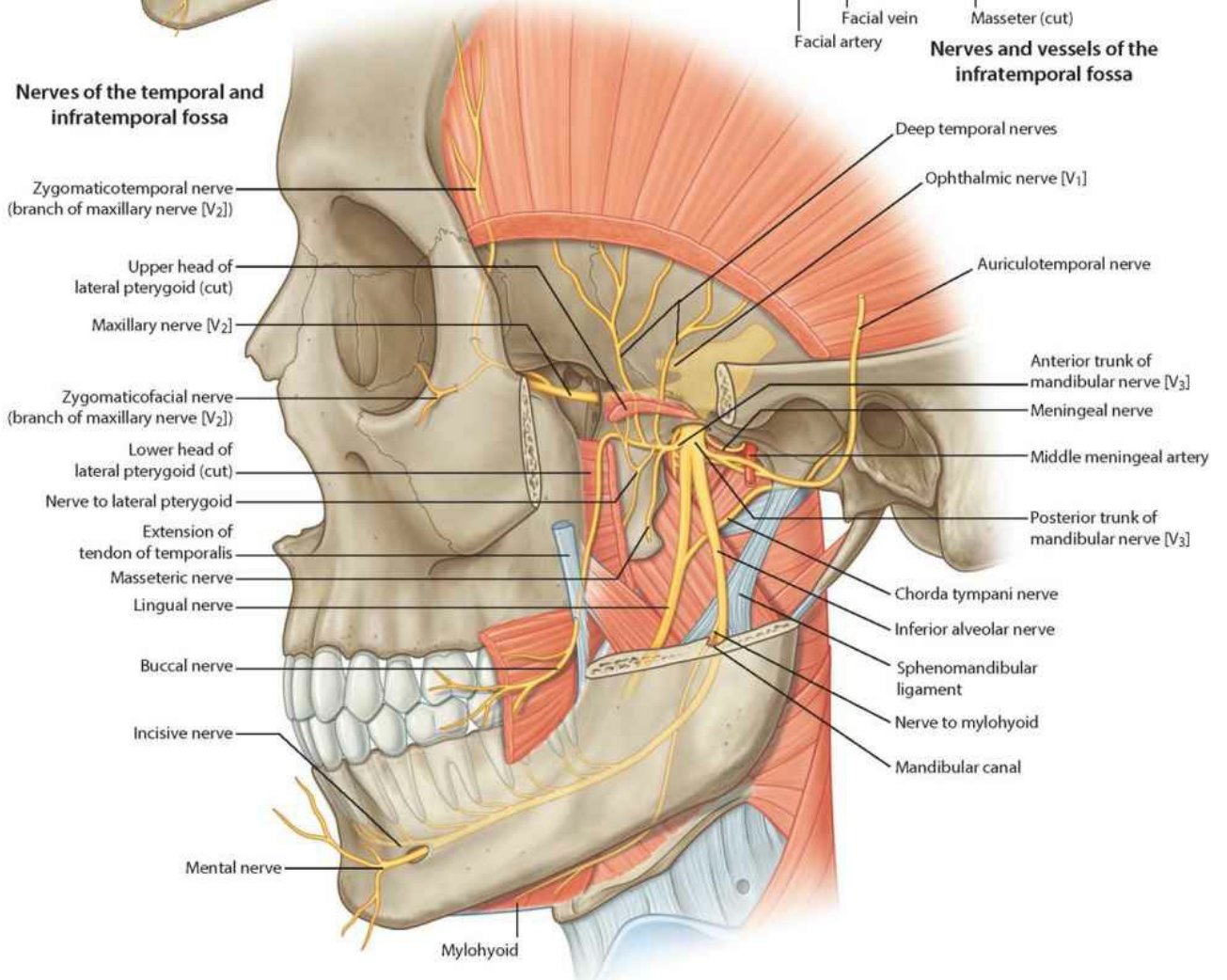
**A. Mouth closed. B. Mouth open.**

Image taken with Cone Beam Computerized Tomography (CBCT) technology viewed in the radiographic mode

# Mandibular division of the trigeminal nerve [V]

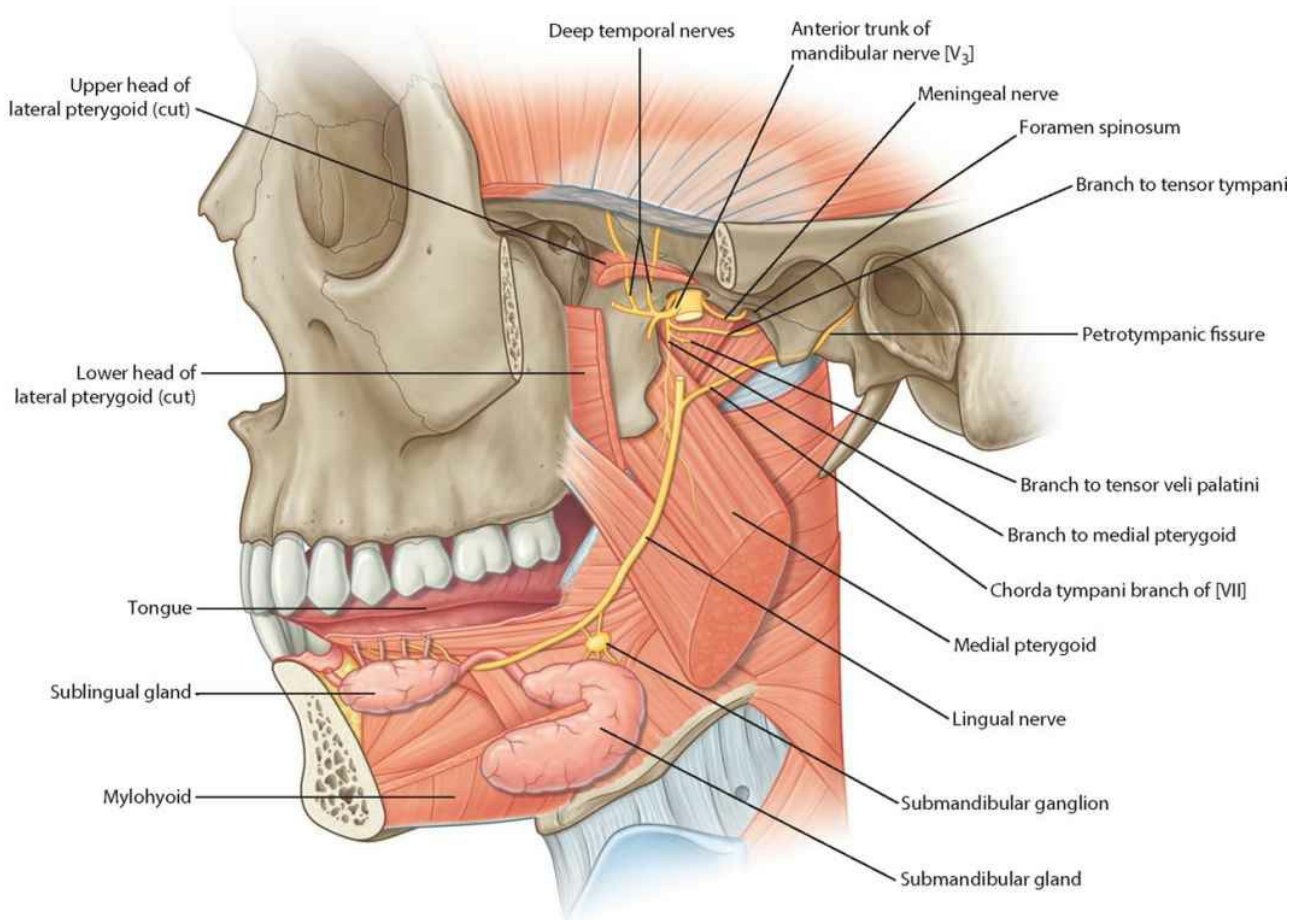


**Nerves of the temporal and infratemporal fossa**

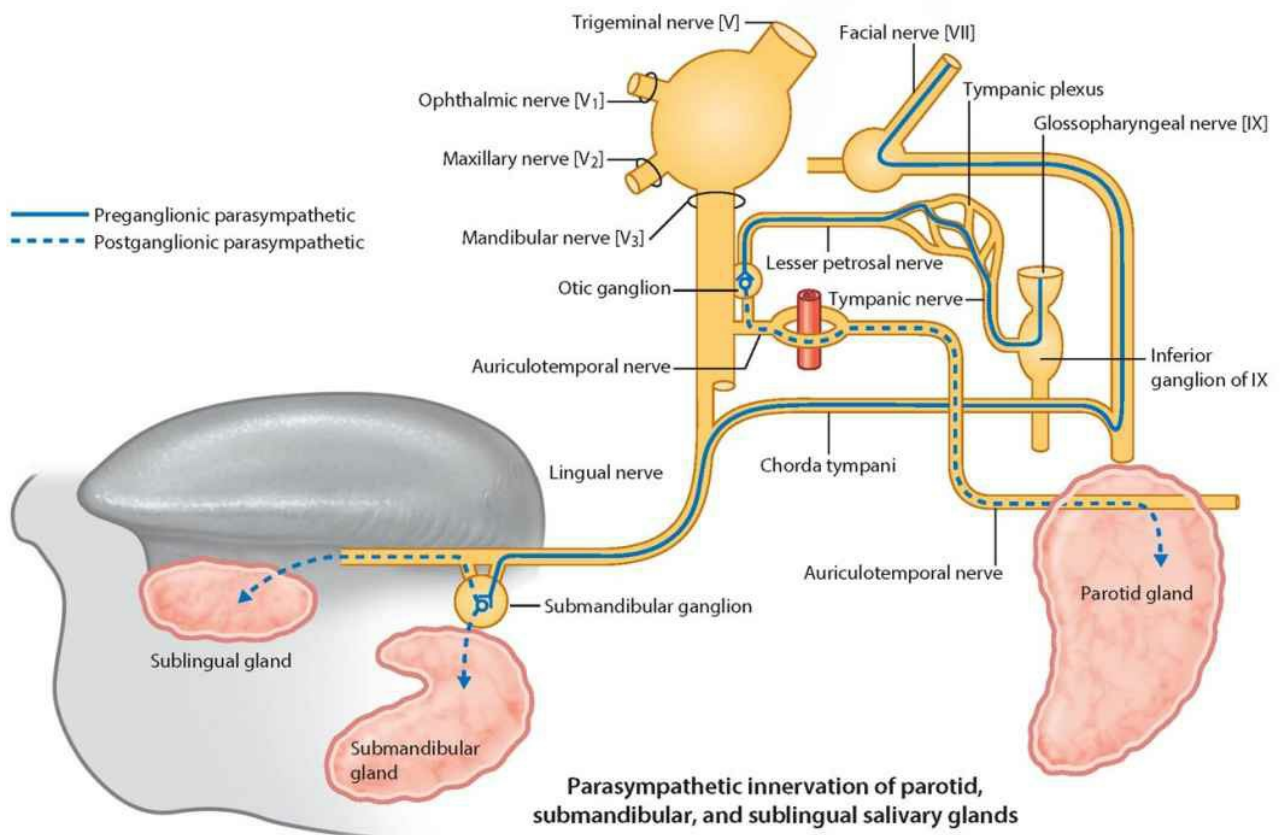


**Nerves and vessels of the infratemporal fossa**

# Parasympathetic innervation



**Nerves of the infratemporal fossa**

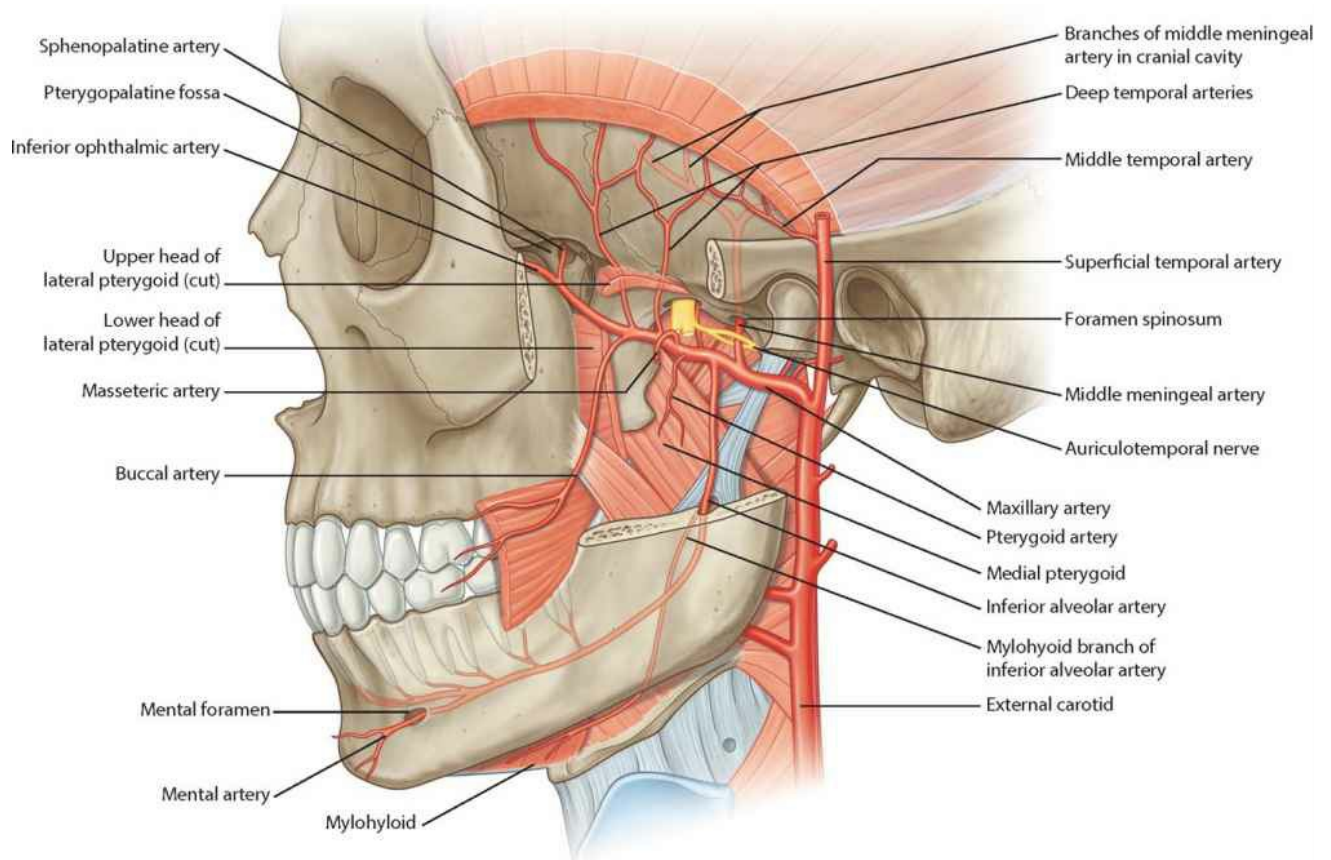


**Parasympathetic innervation of parotid, submandibular, and sublingual salivary glands**

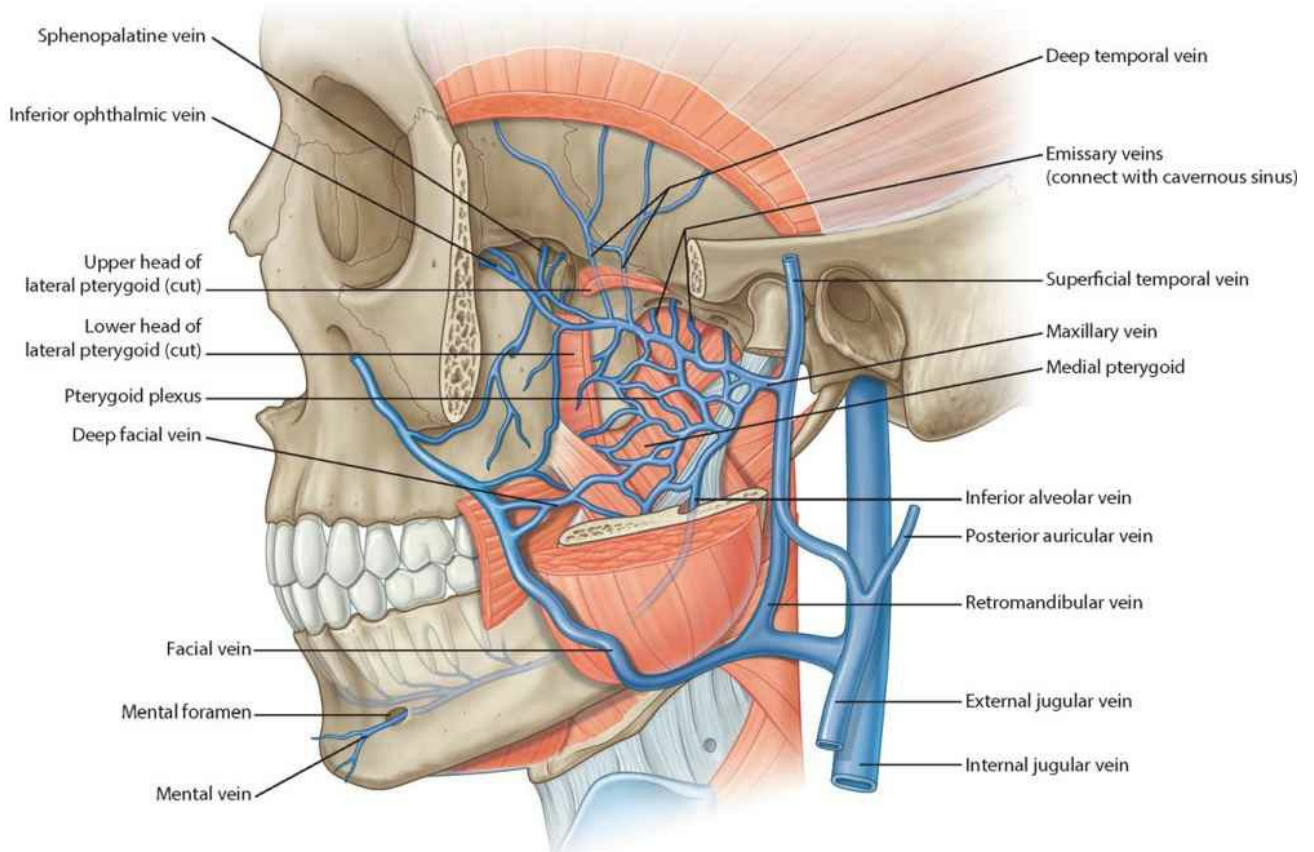


# **Arteries and veins of temporal and infratemporal fossae**



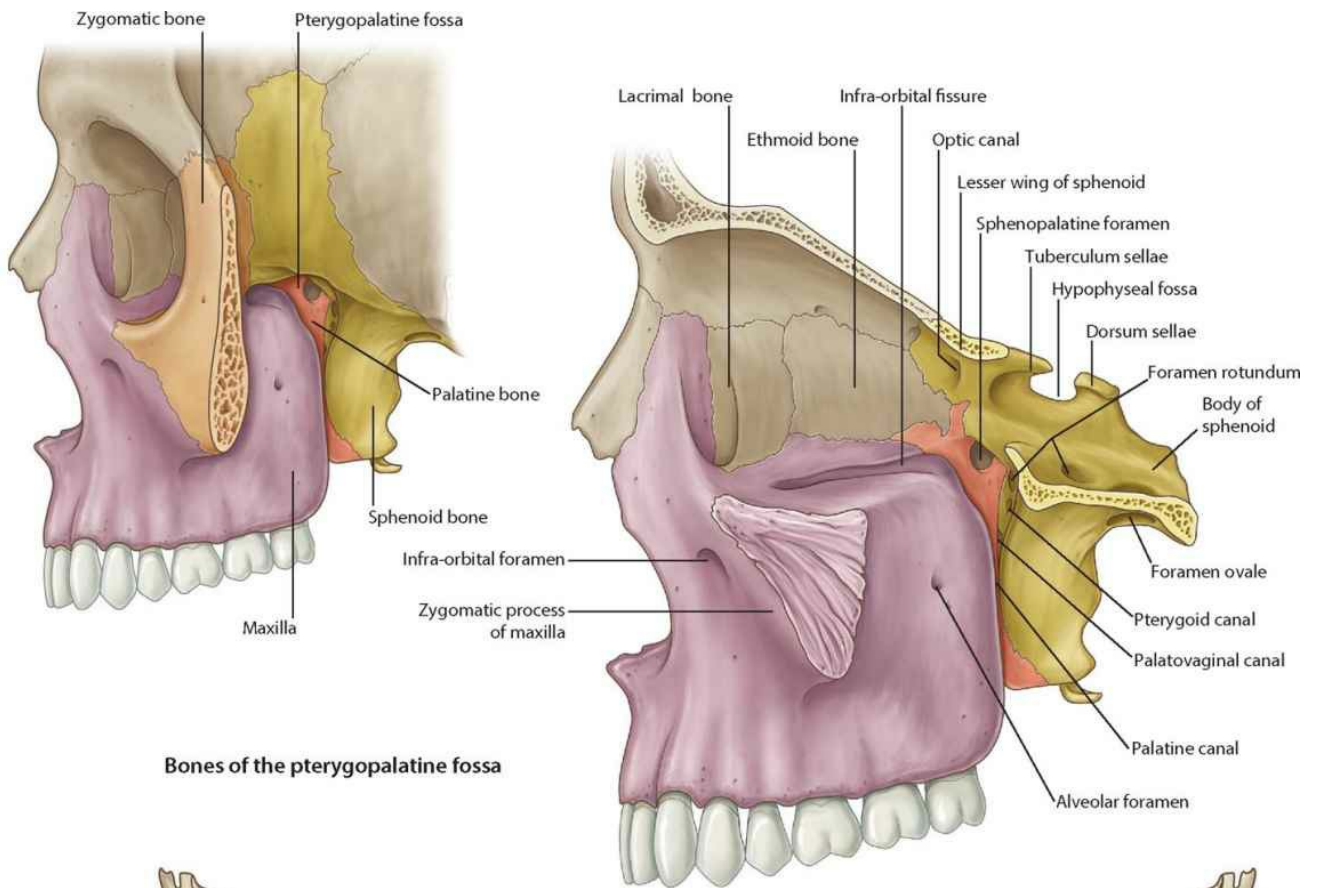


**Arteries of the temporal and infratemporal fossae**

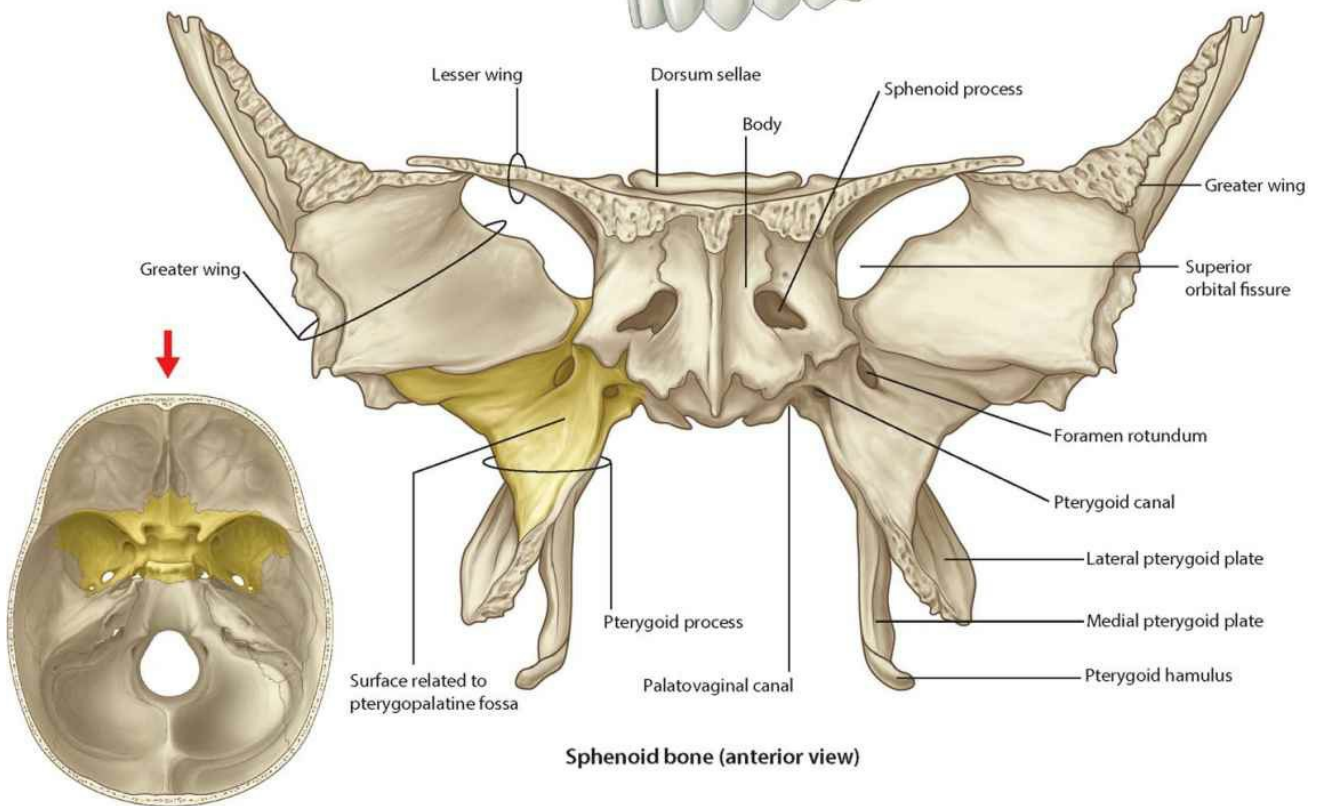


**Veins of the temporal and infratemporal fossae**

# Pterygopalatine fossa

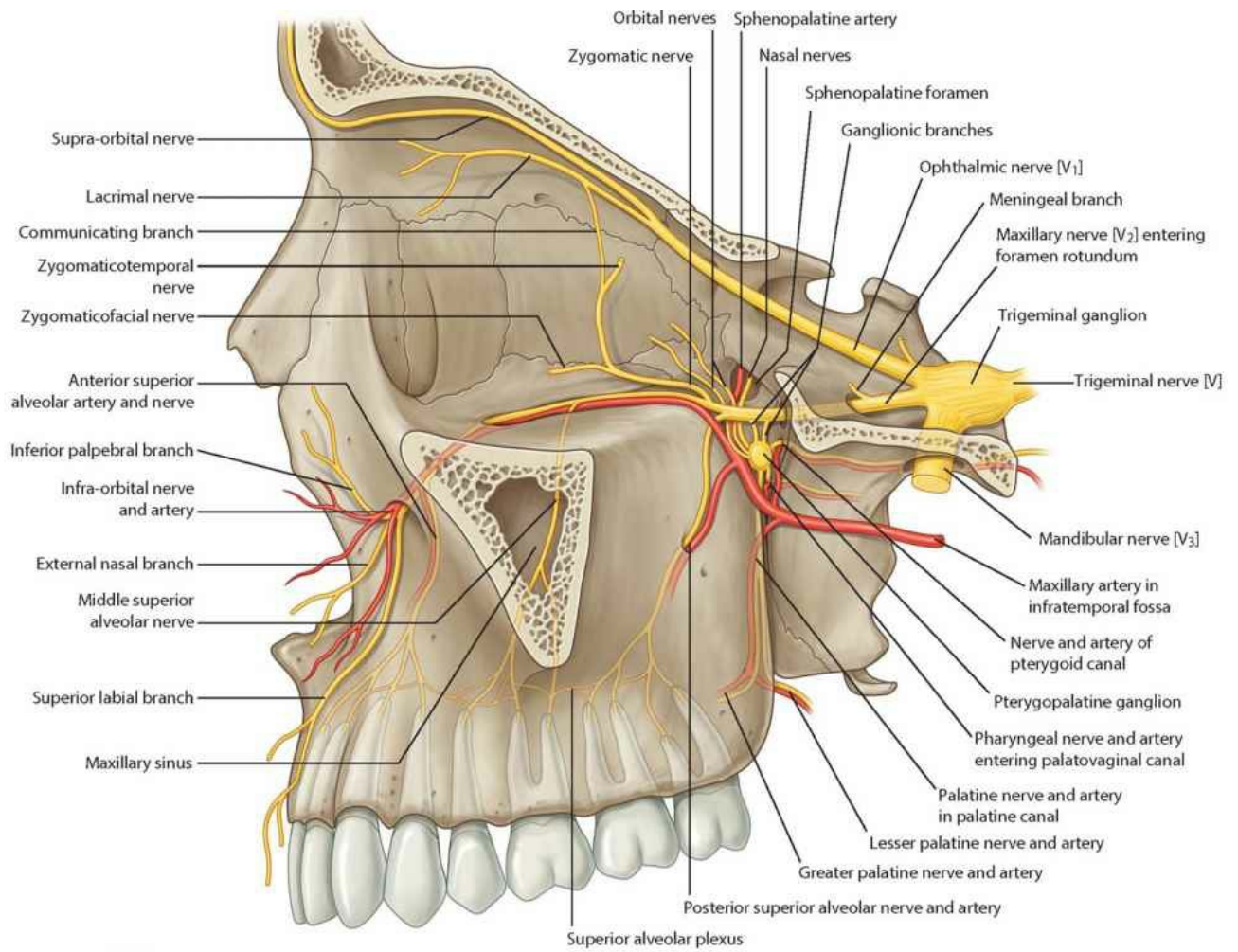


**Bones of the pterygopalatine fossa**

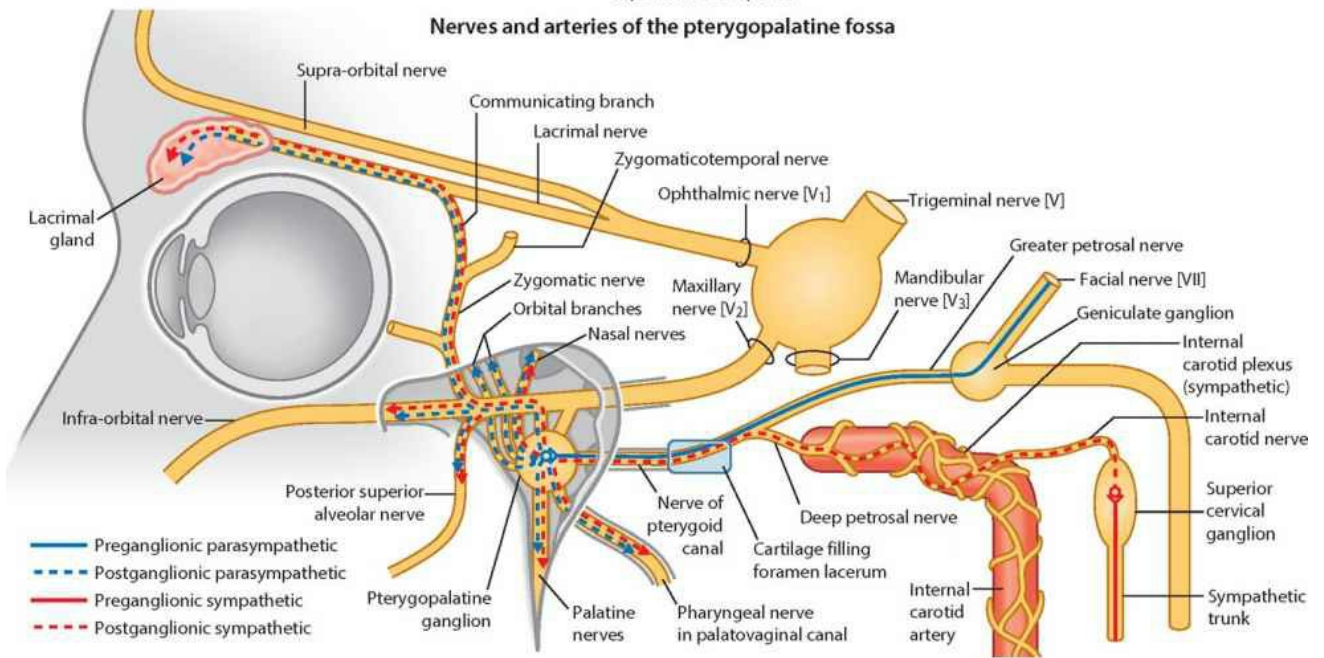


**Sphenoid bone (anterior view)**



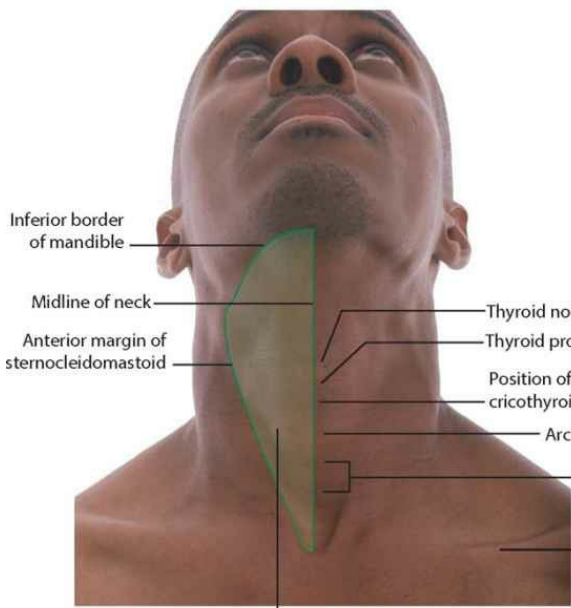


### Nerves and arteries of the pterygopalatine fossa

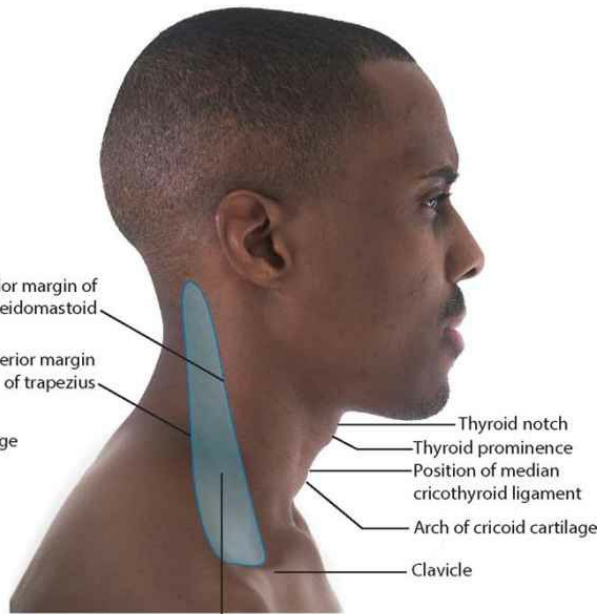


### Visceral efferent (motor) pathways through the pterygopalatine fossa

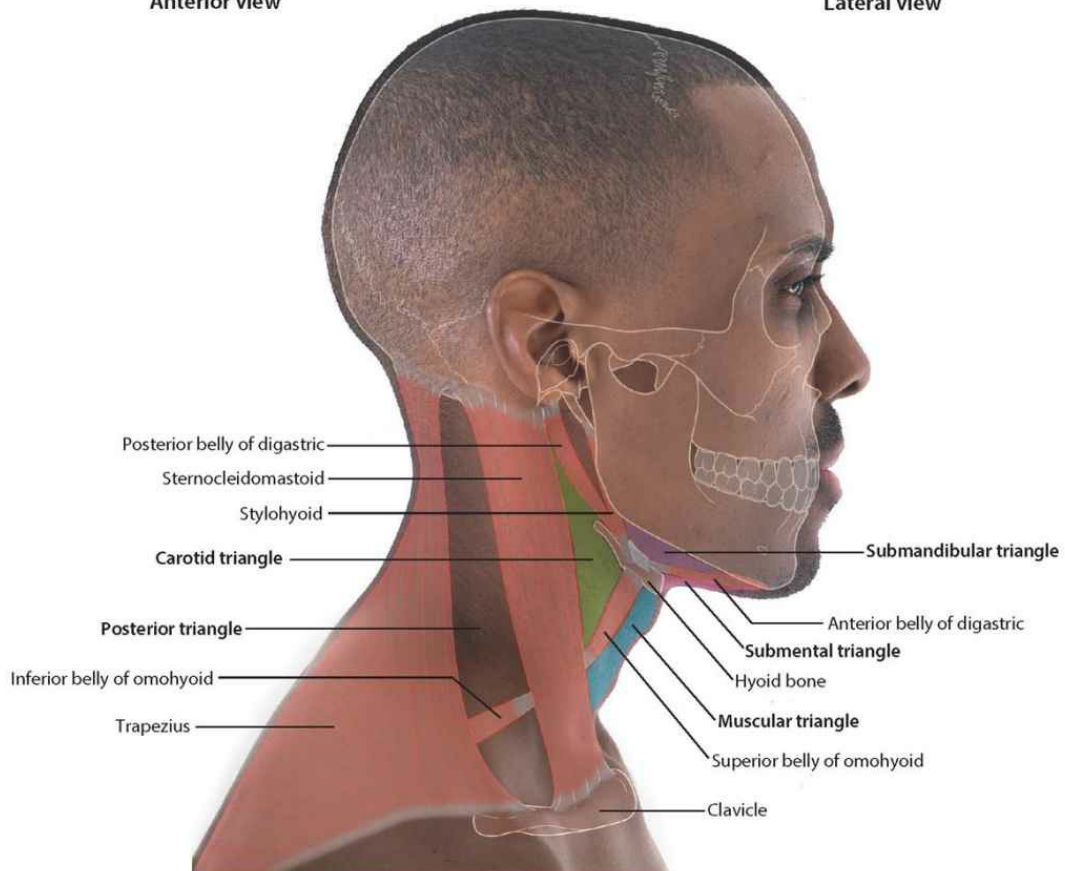
# Neck surface anatomy



**Anterior triangle**  
 associated with structures coursing between head and thorax  
**Anterior view**



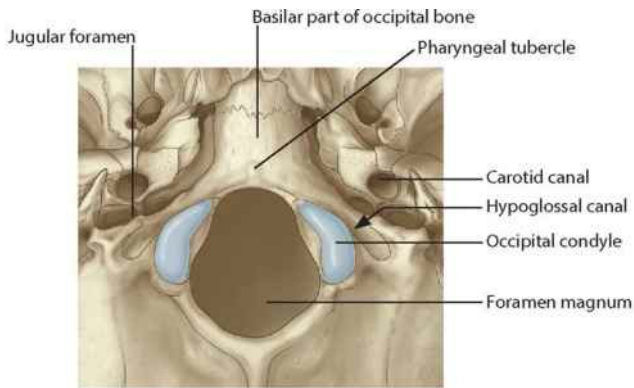
**Posterior triangle**  
 associated with structures coursing between thorax/neck and upper limb  
**Lateral view**



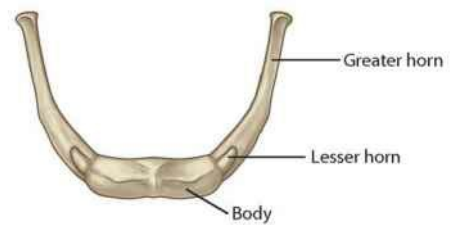
**Boundaries and subdivisions of the anterior triangle and boundaries of the posterior triangle**

# Bones of the neck

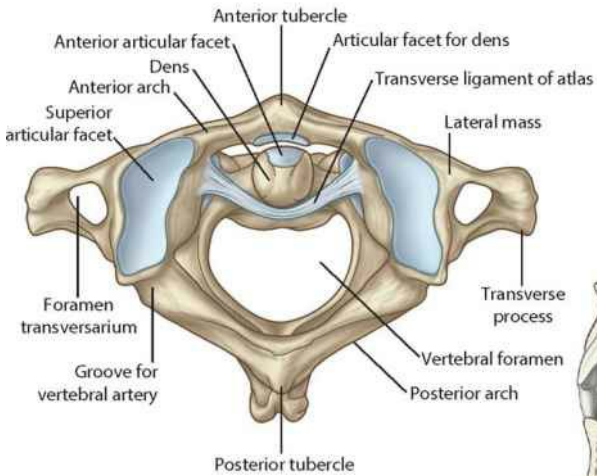




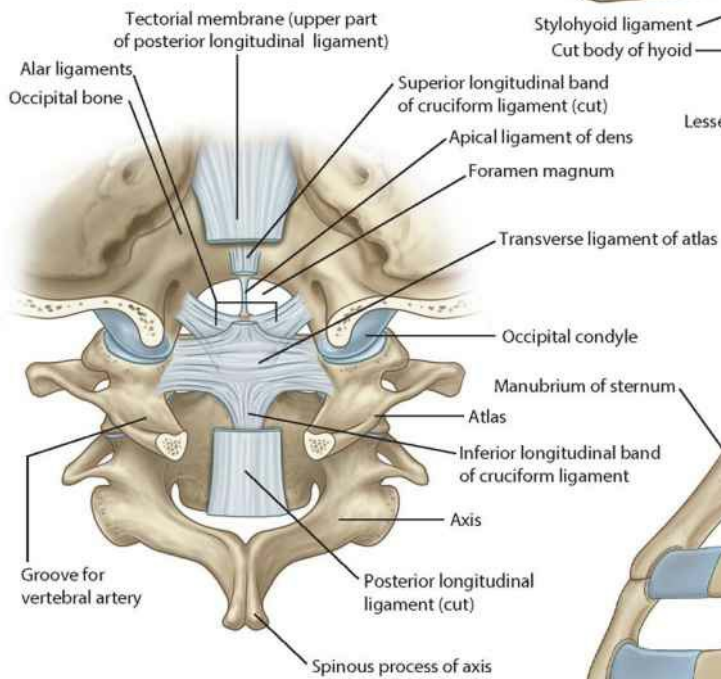
**Occipital condyles of skull (inferior view)**



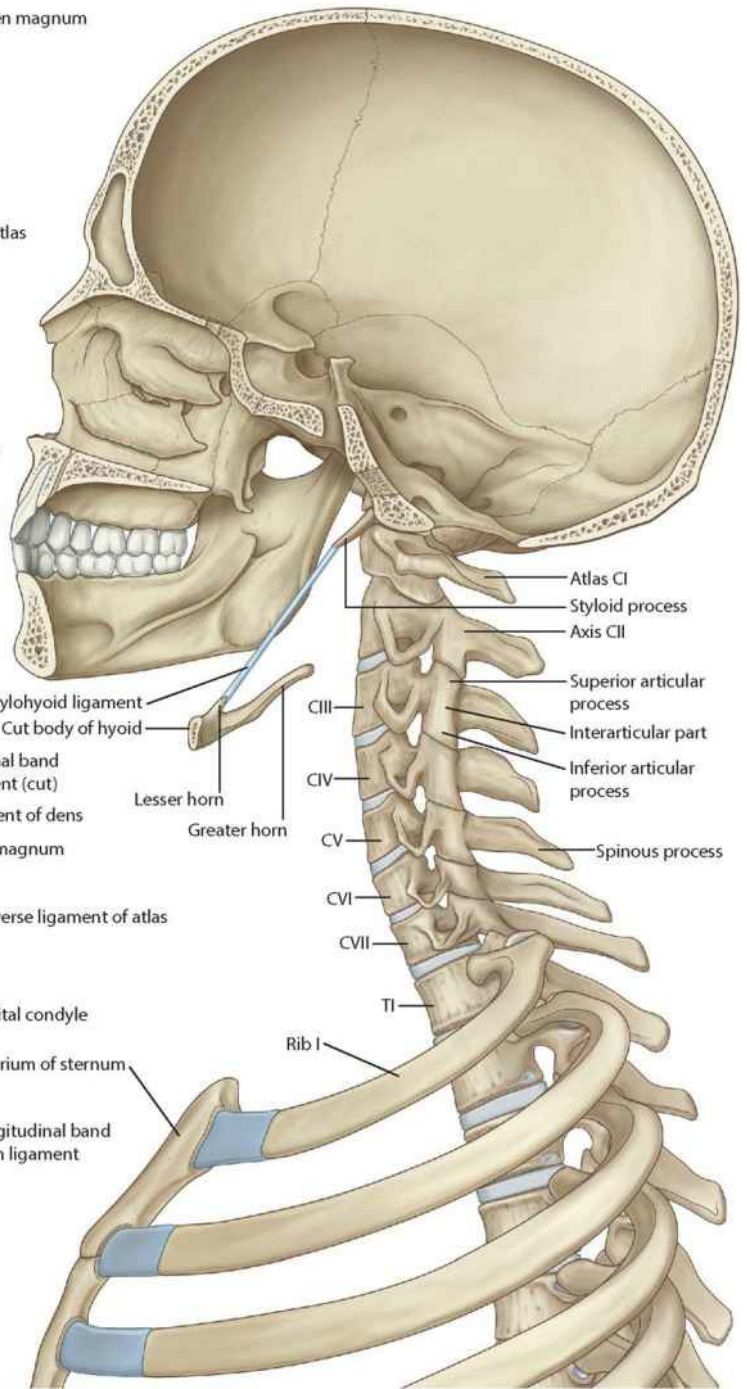
**Hyoid bone (superior view)**



**Atlas and axis (superior view)**

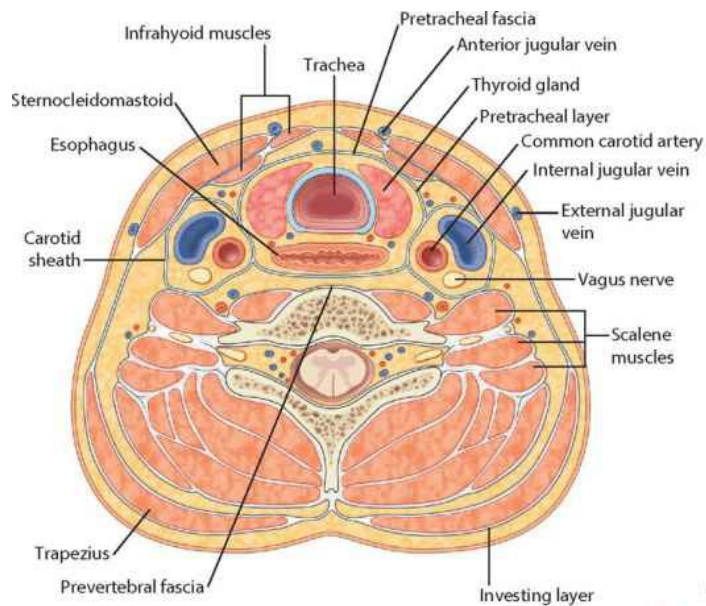


**Atlanto-occipital joint (posterior view)**

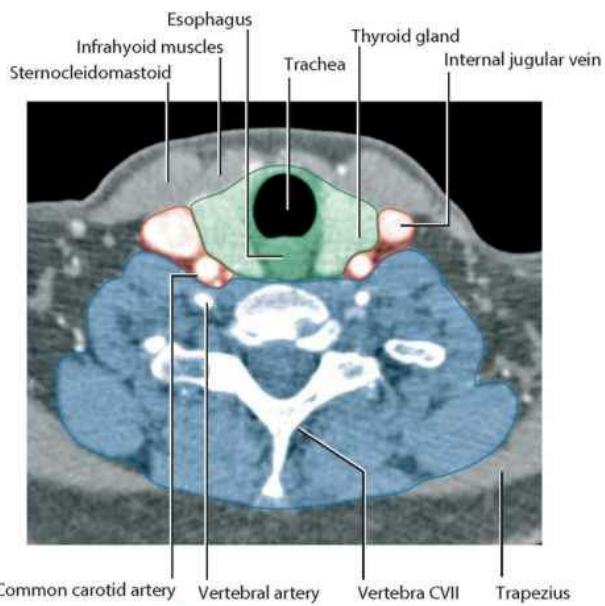


**Bones of the neck (lateral view)**

# Compartments and fascia of the neck

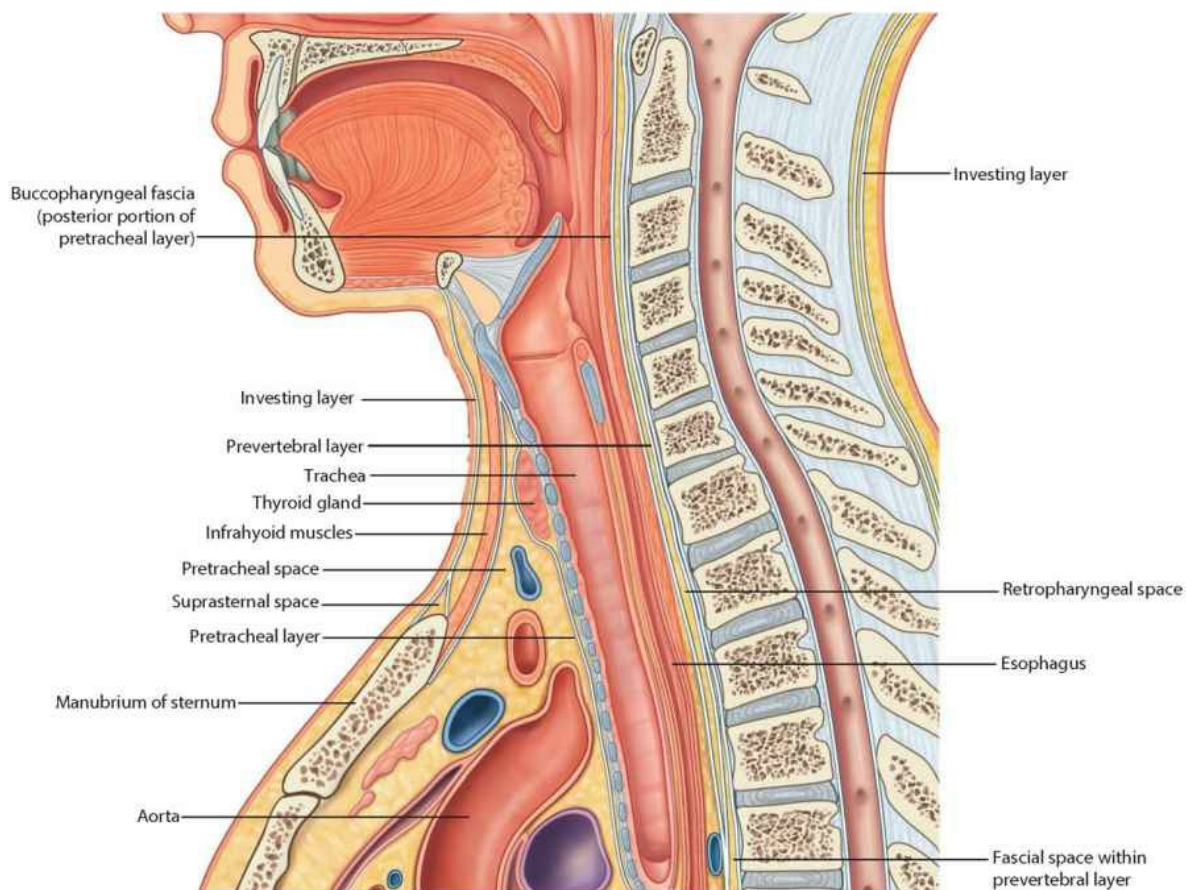


**Fascia of the neck (transverse view)**



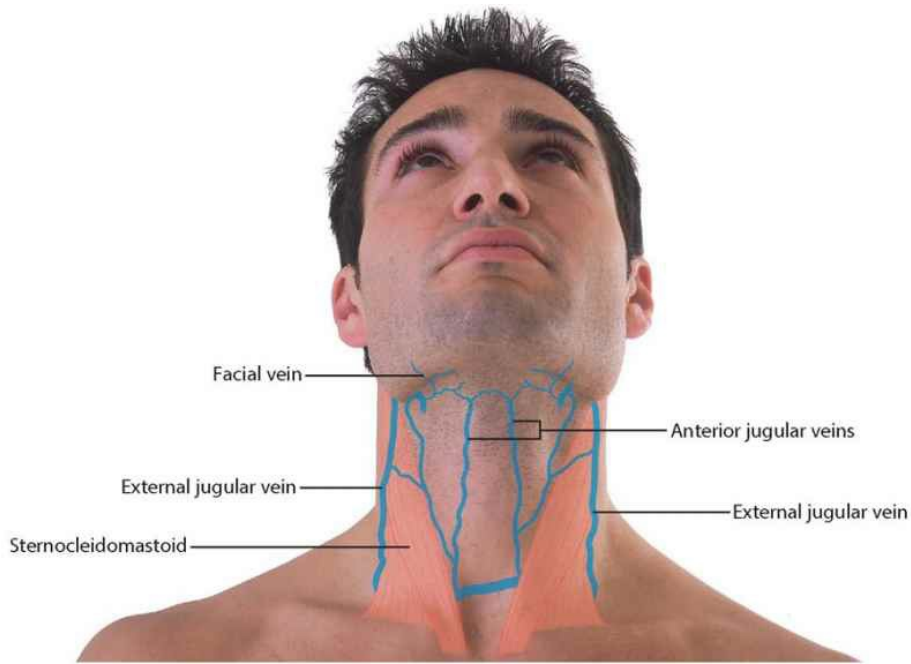
■ Visceral compartment ■ Vascular compartment ■ Vertebral compartment

**Fascia compartments of the neck.**  
CT image, with contrast, in axial plane

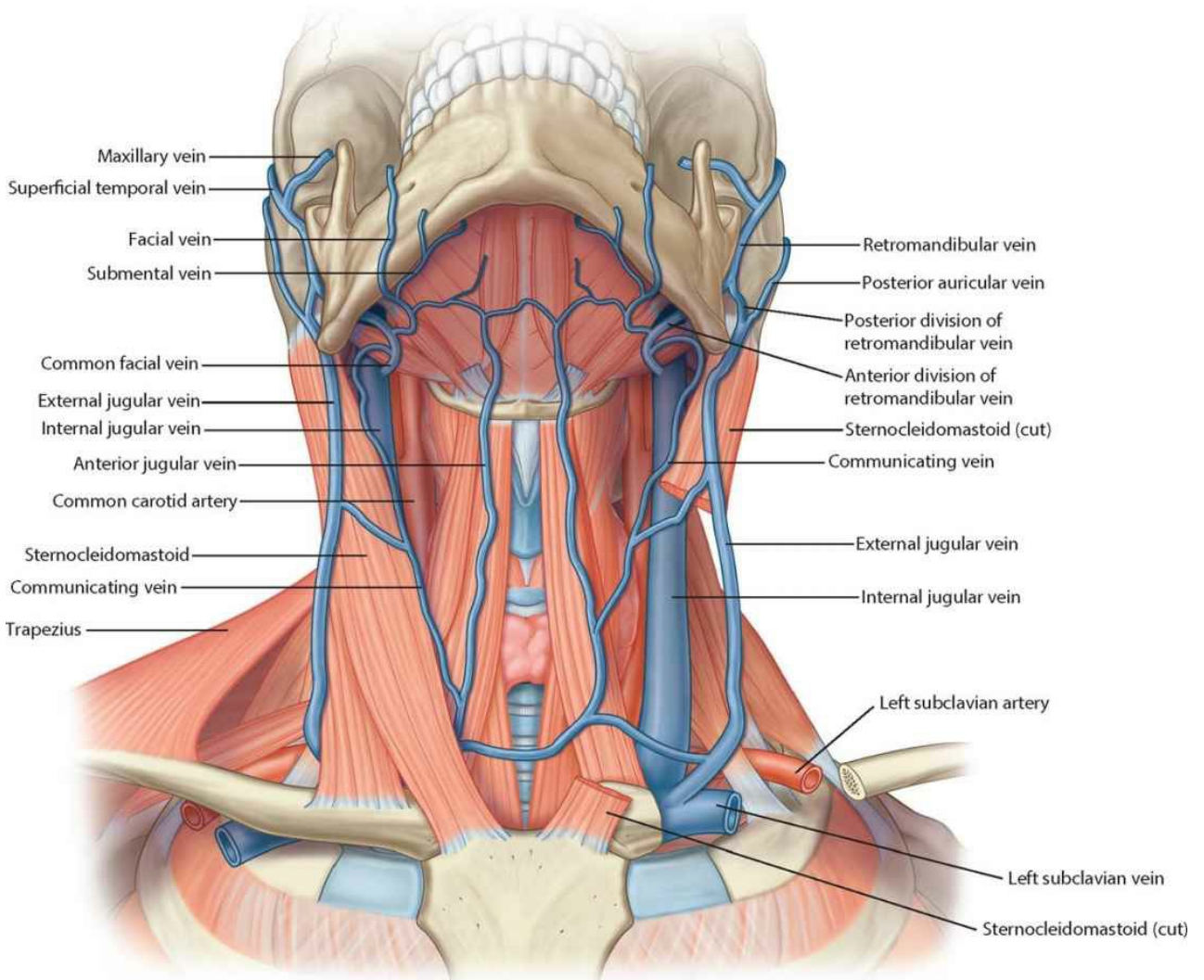


**Fascia of the neck (sagittal view)**

# Superficial veins of the neck



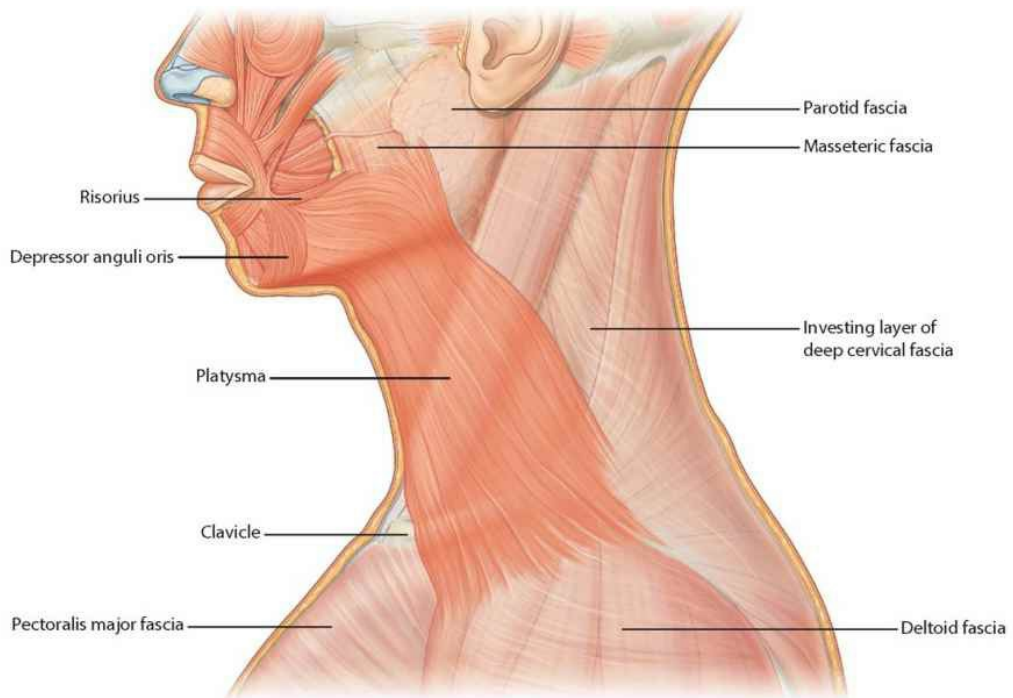
**Palpable veins of the neck  
(or visible)**



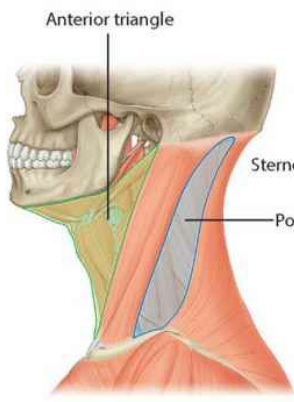
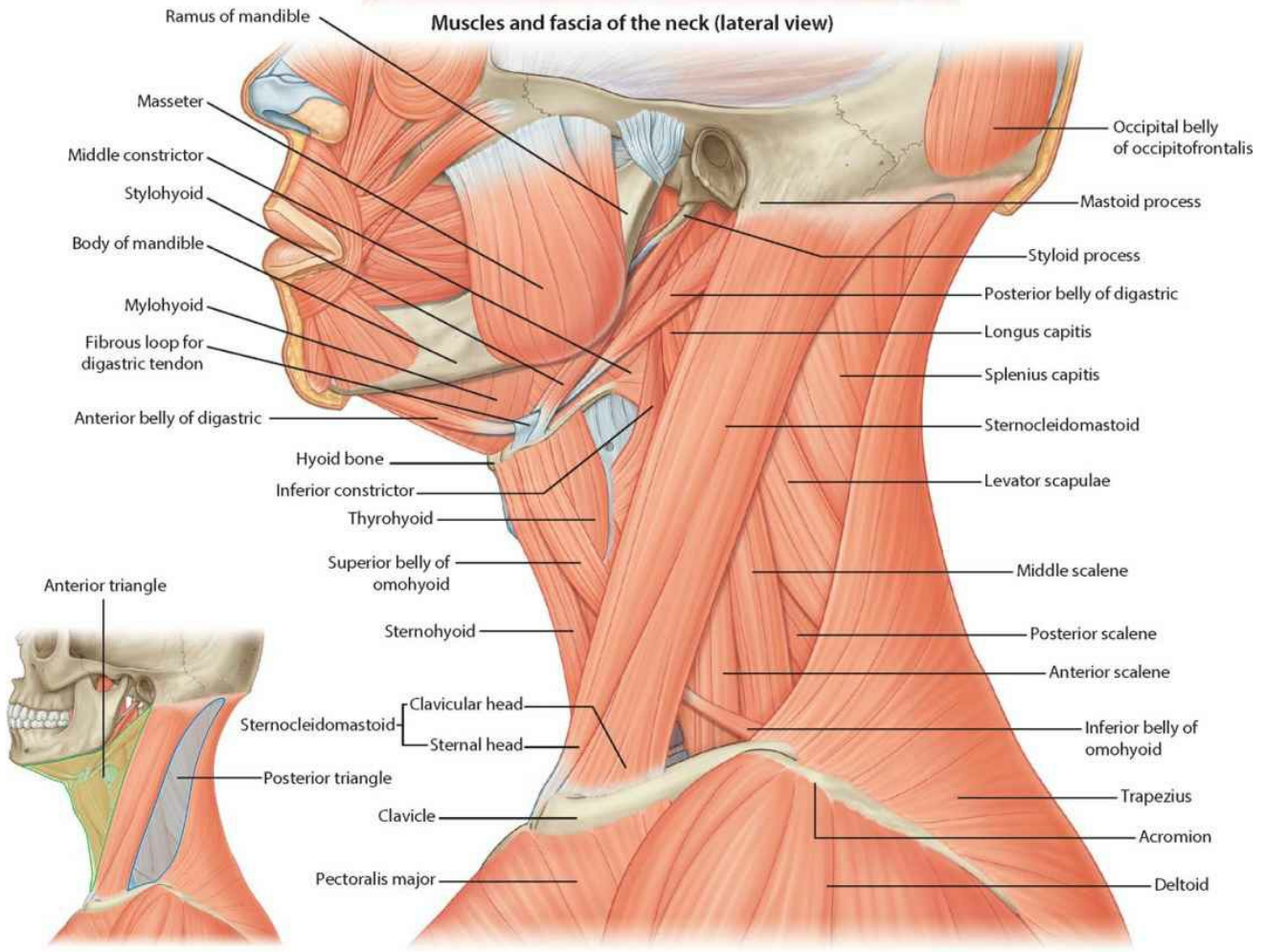
**Superficial veins of the neck**



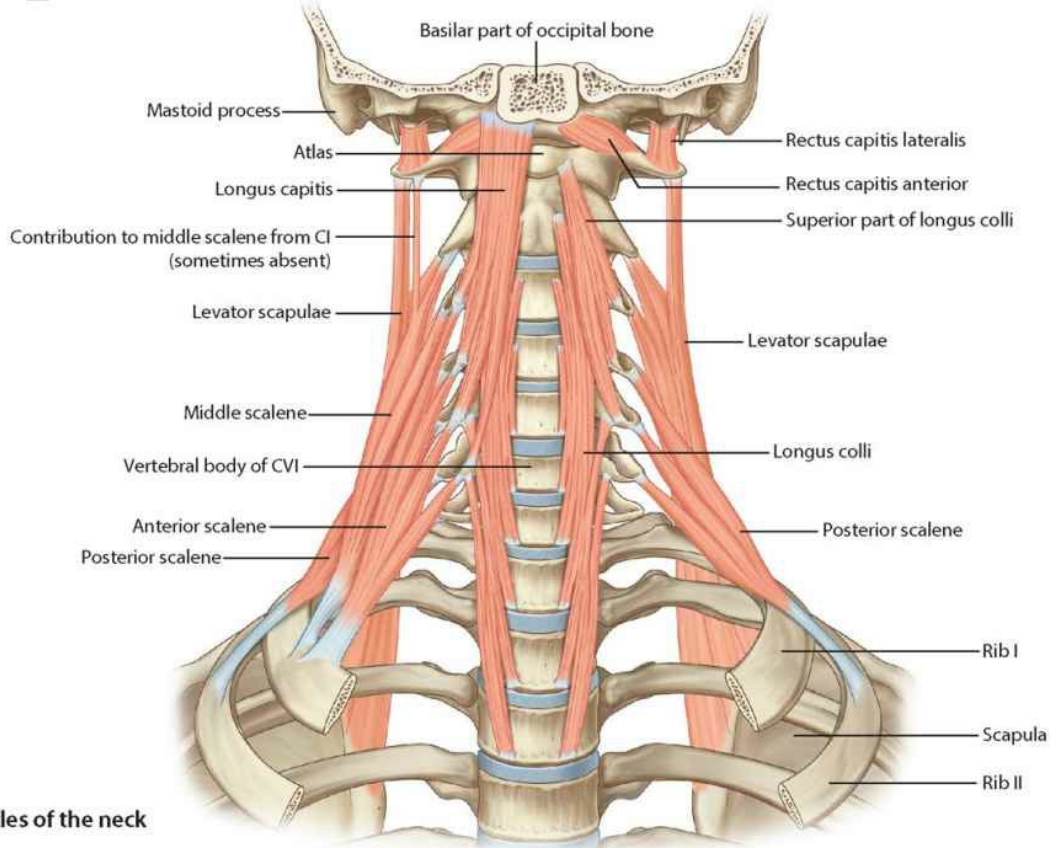
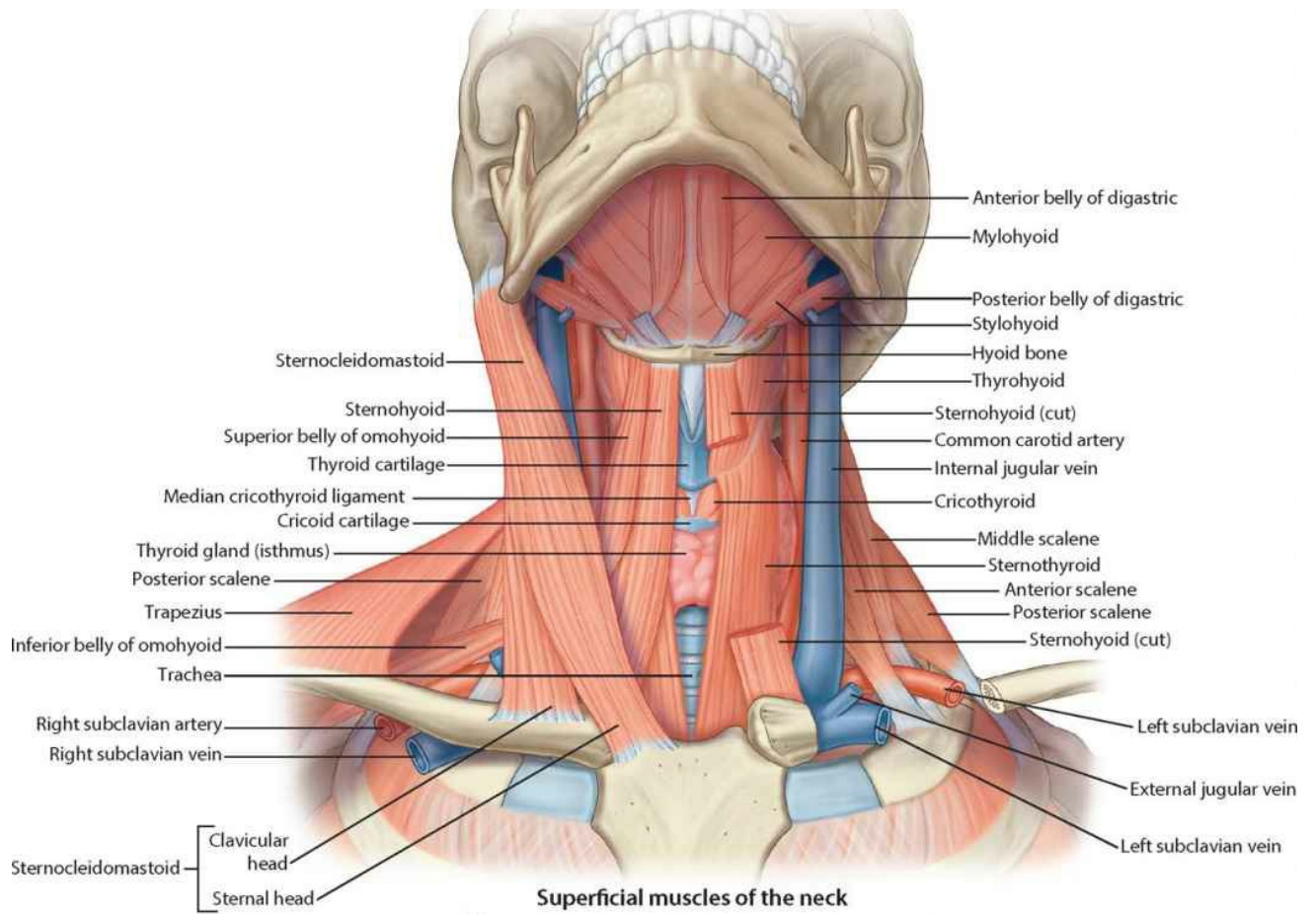
# Muscles of the neck



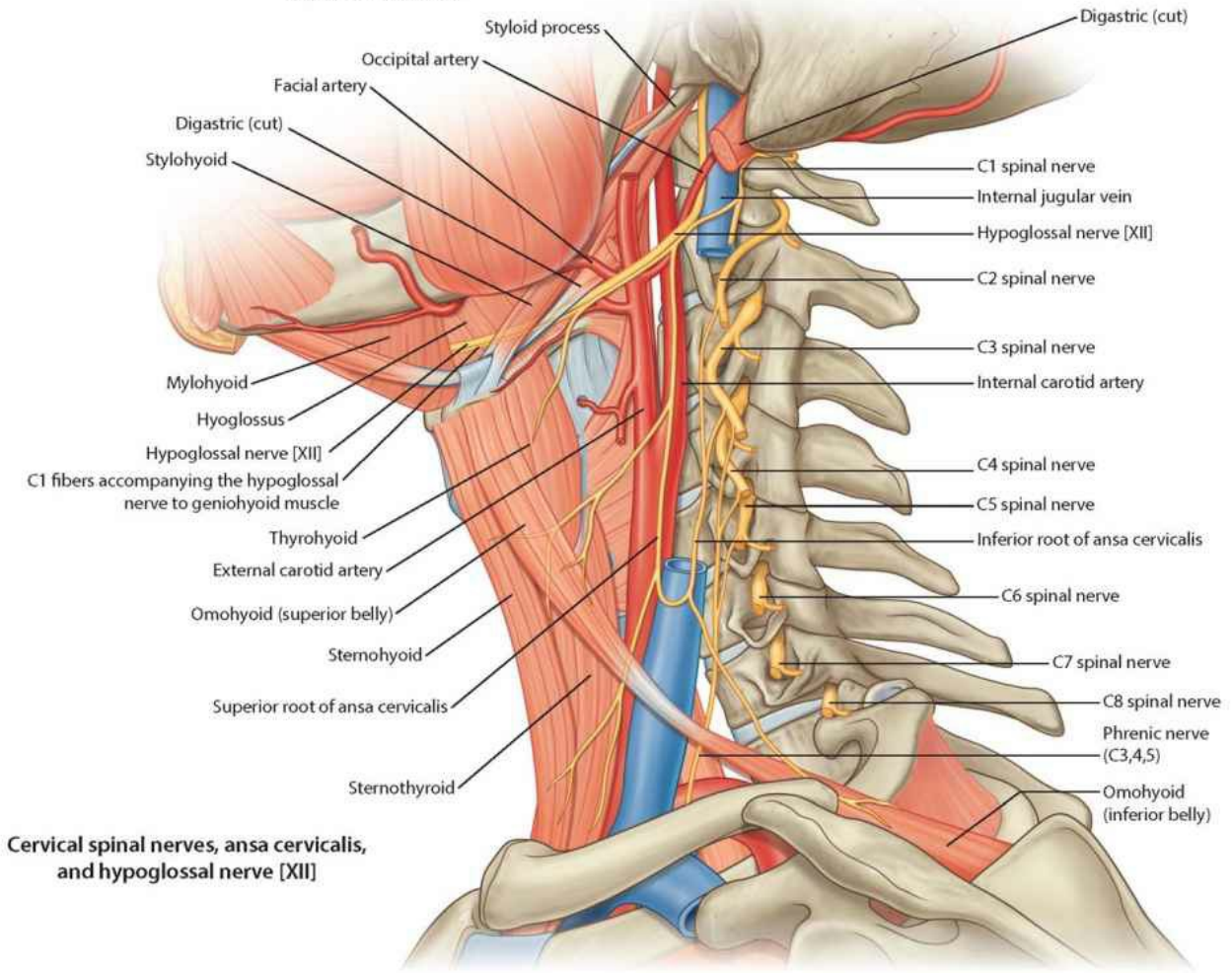
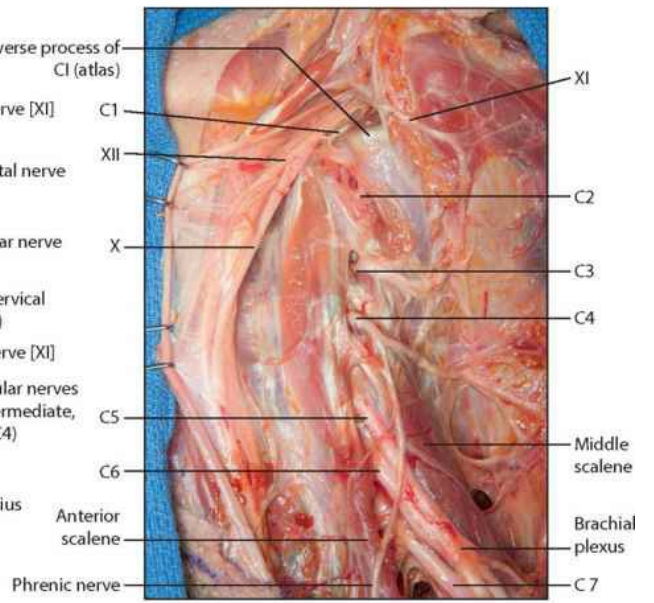
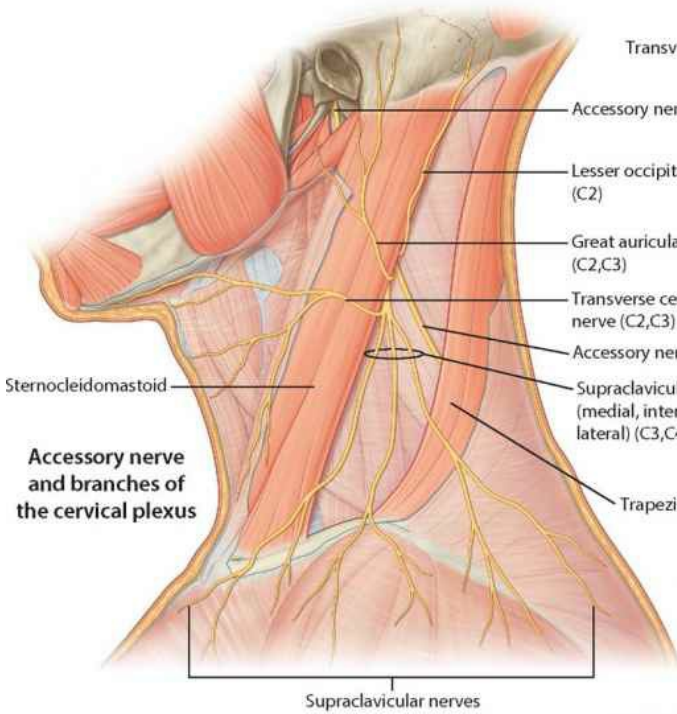
**Muscles and fascia of the neck (lateral view)**



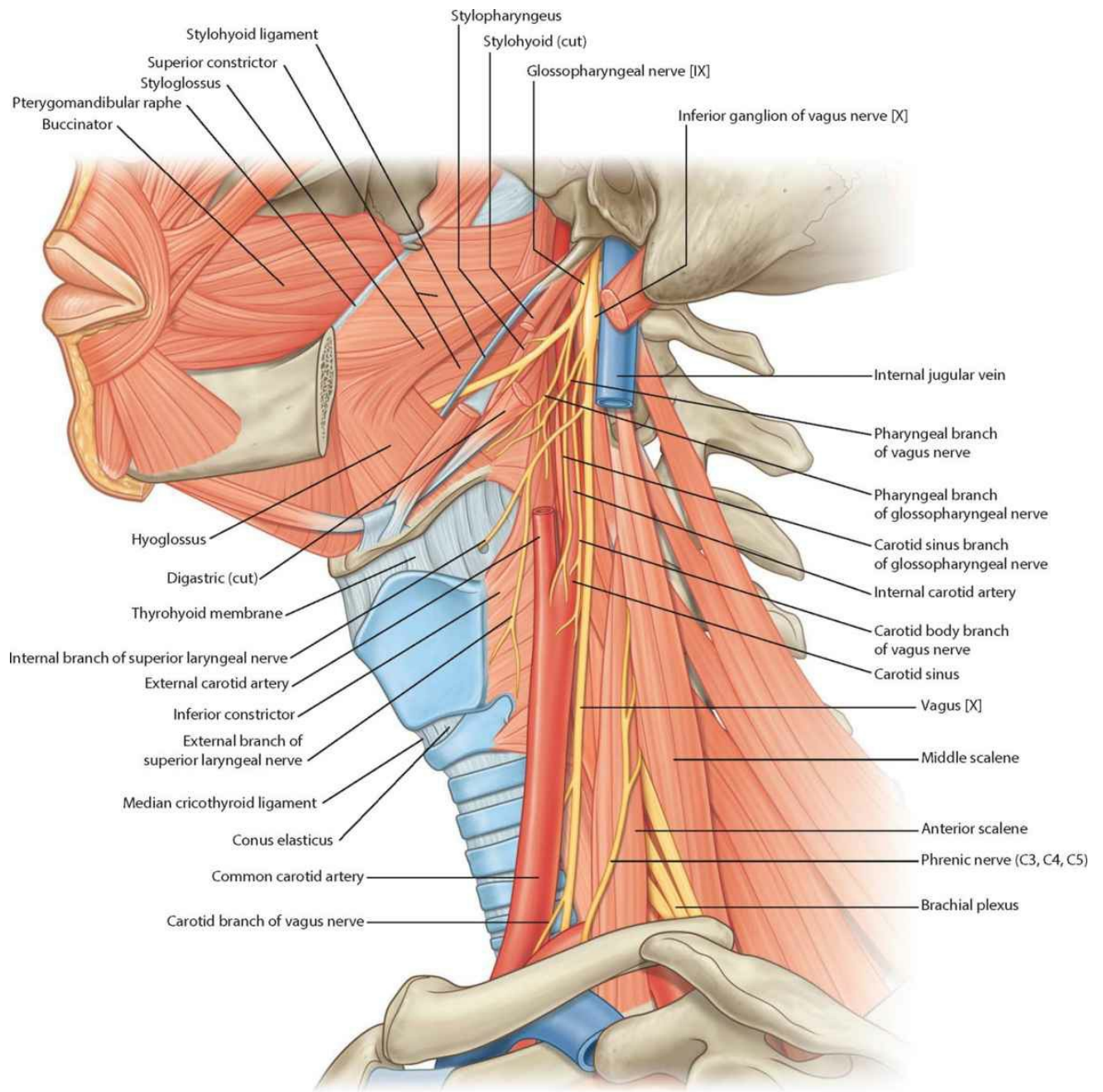




# Nerves in the neck

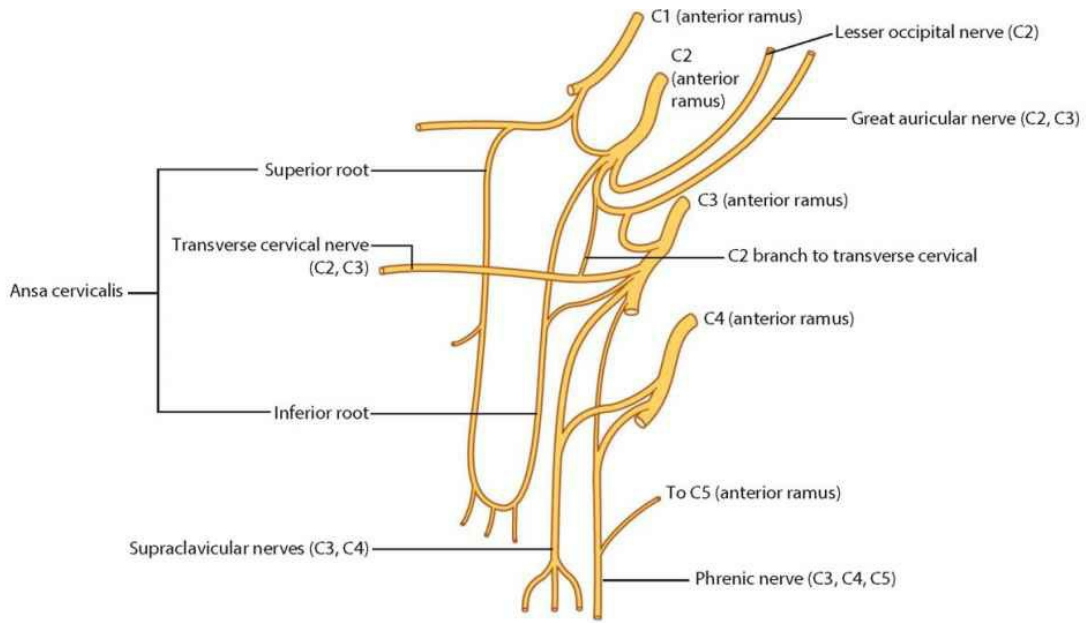


# Cranial nerves in the neck

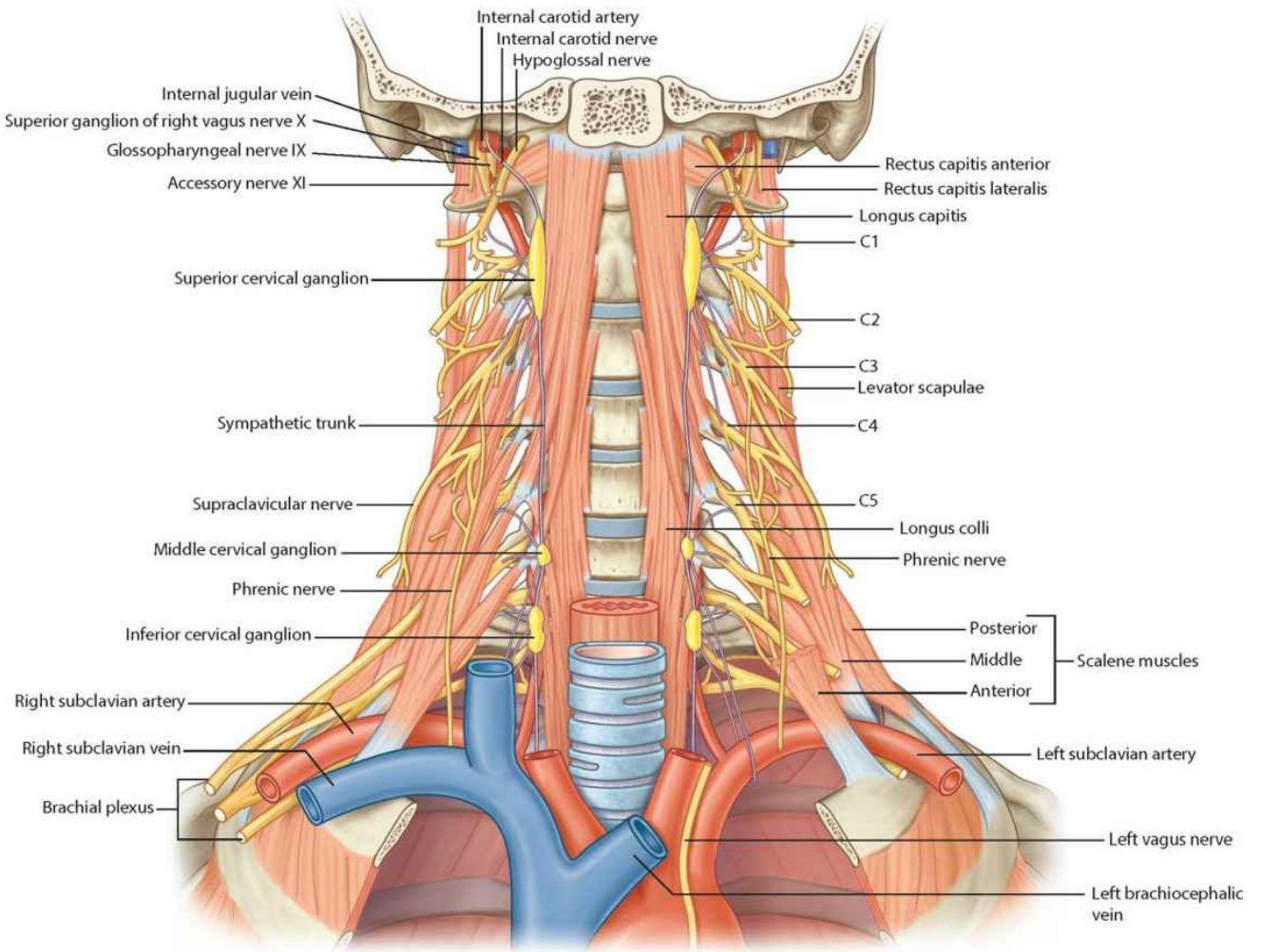


**Branches of glossopharyngeal [IX] and vagus nerves [X] in neck**

# Cervical plexus and sympathetic trunk



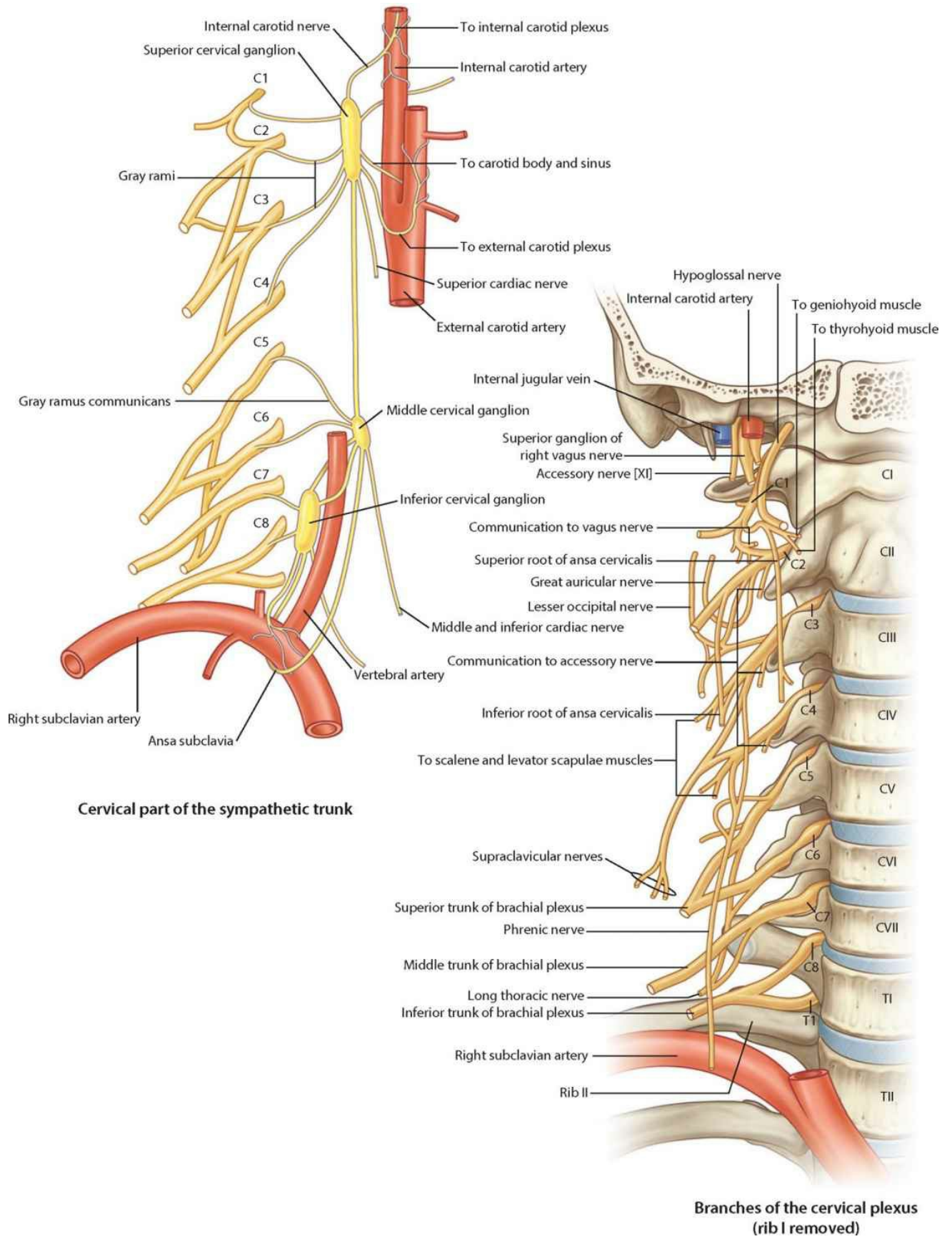
**Cervical plexus**



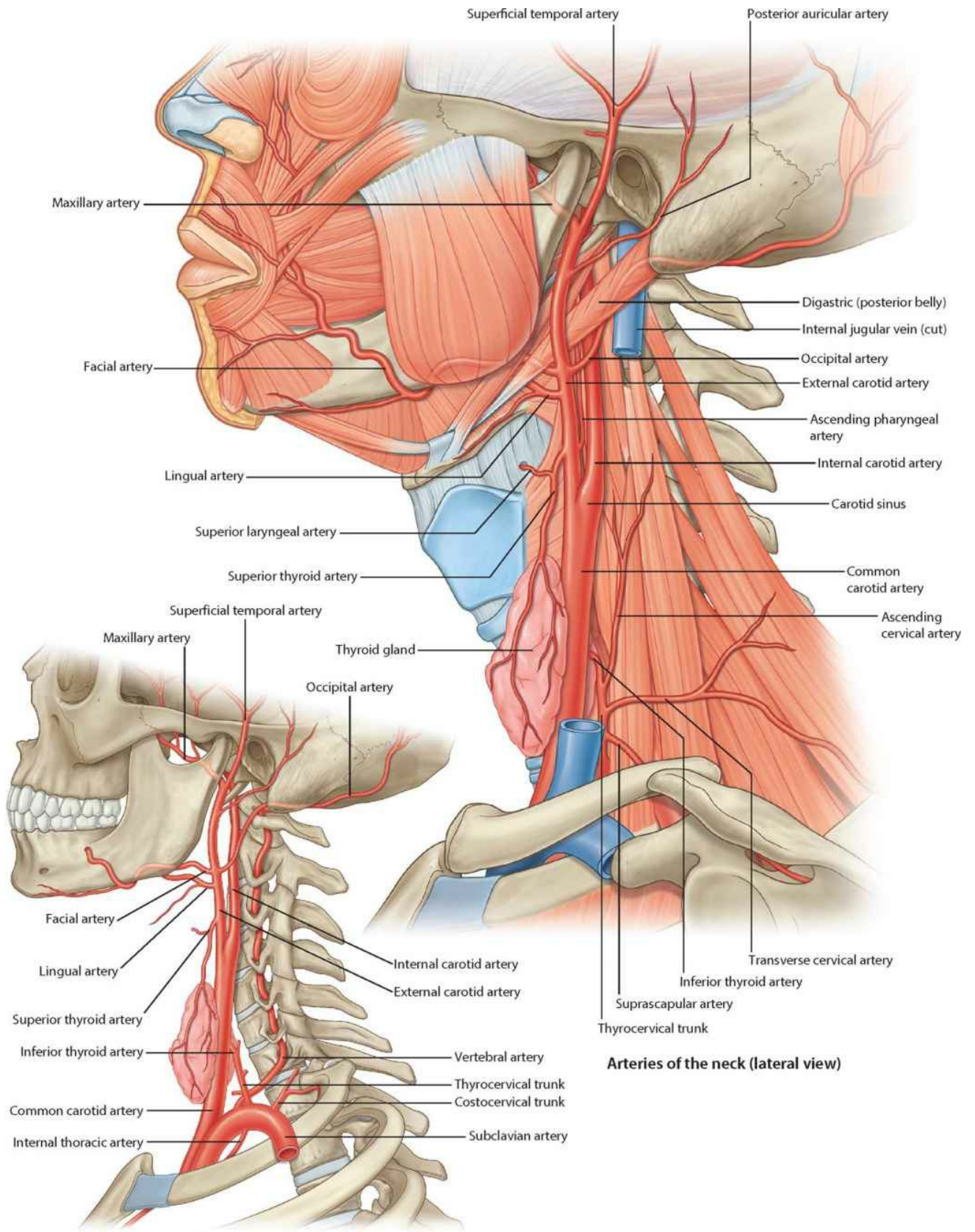
**Components of the sympathetic nervous system in the root of the neck**





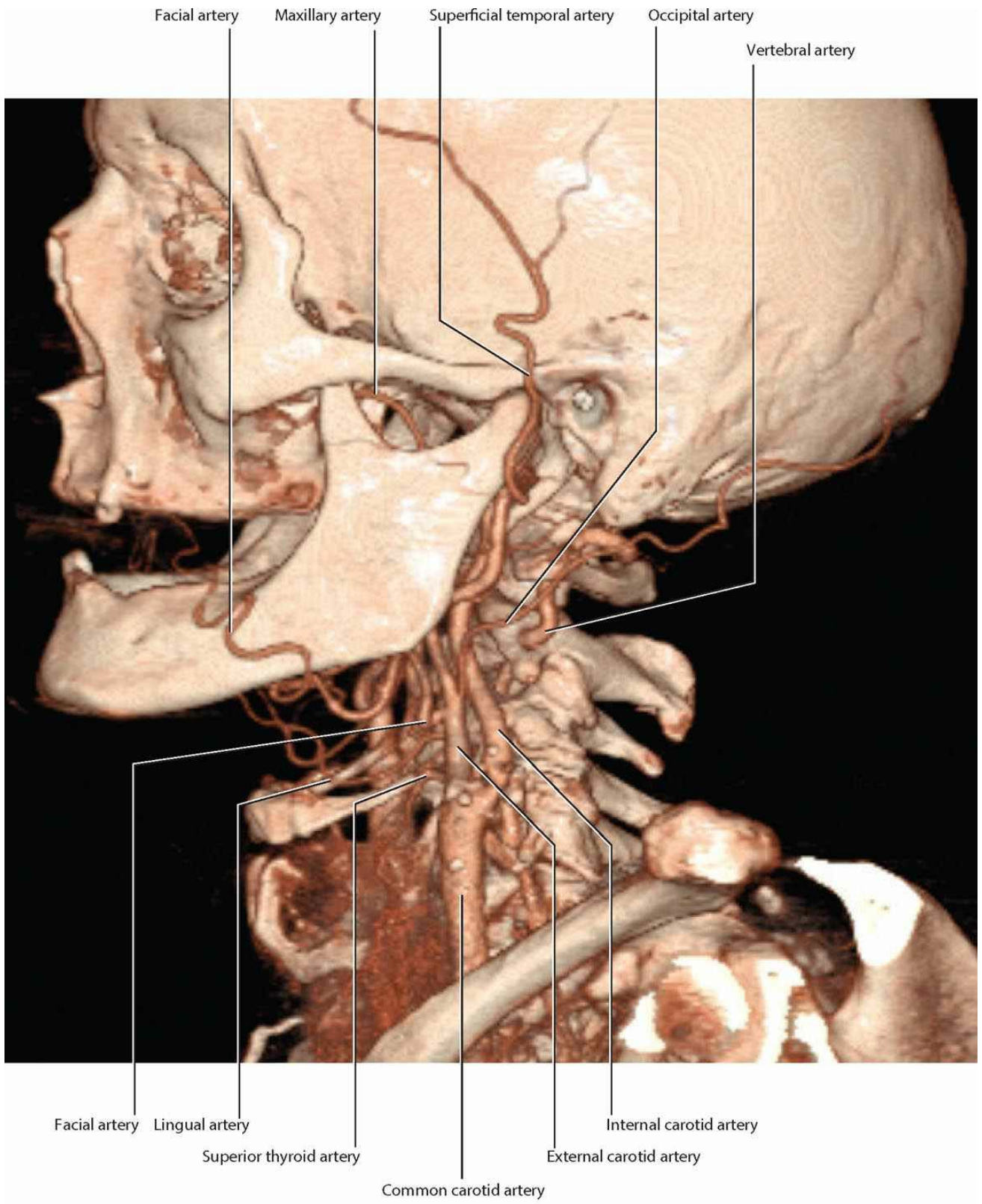


# Arteries of the neck



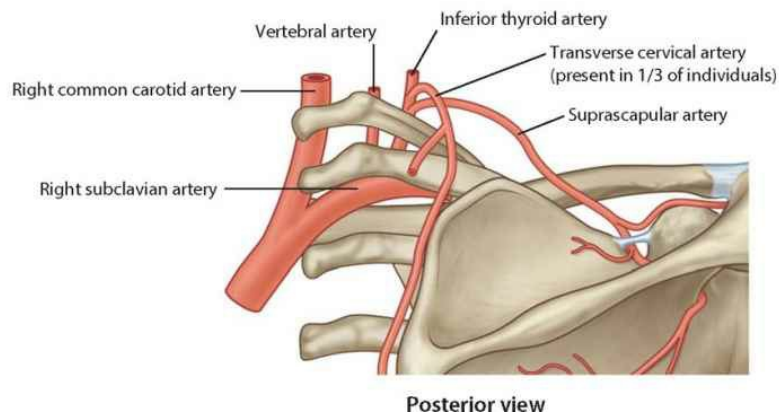
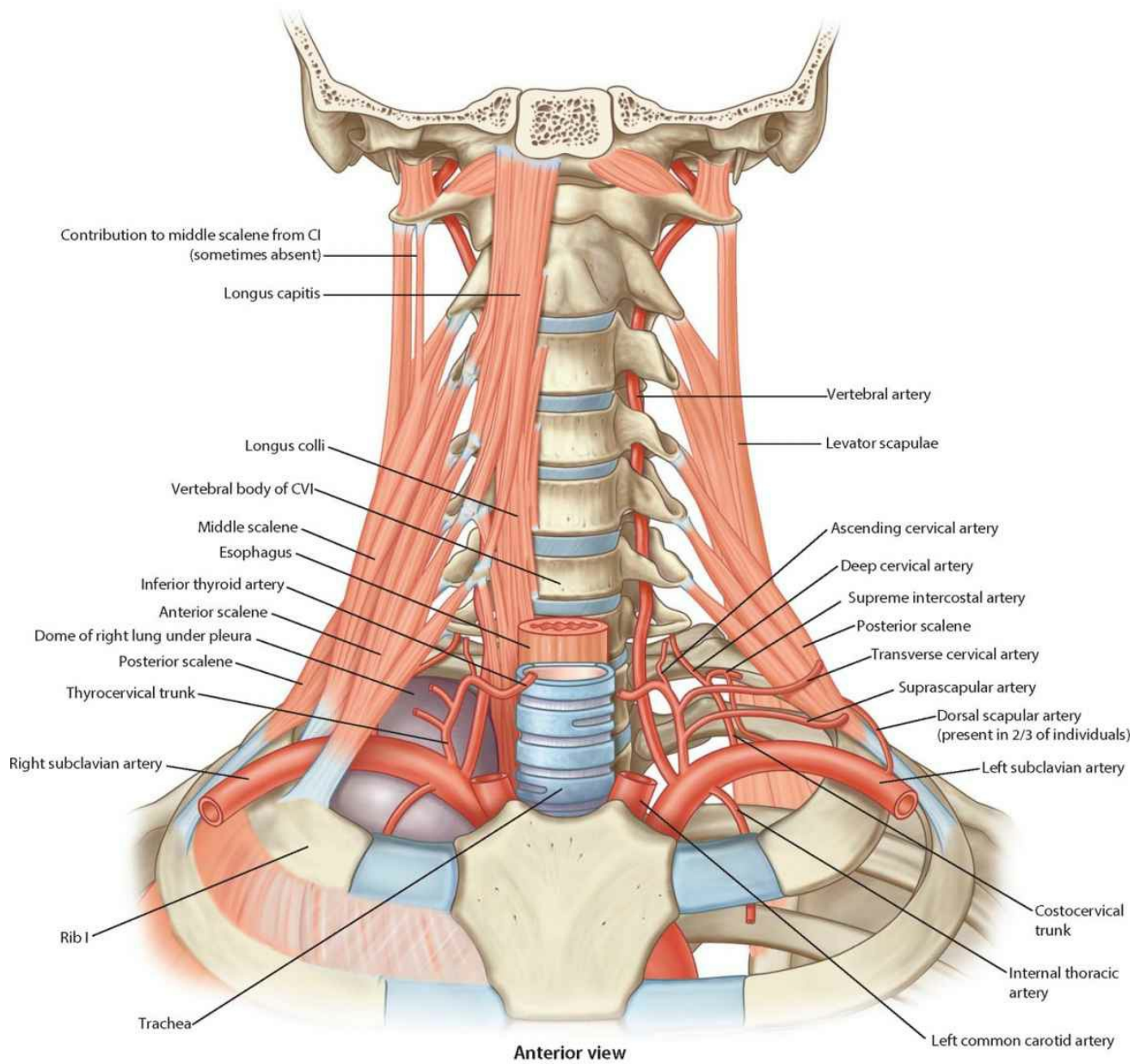
**Arteries of the neck (lateral view)**





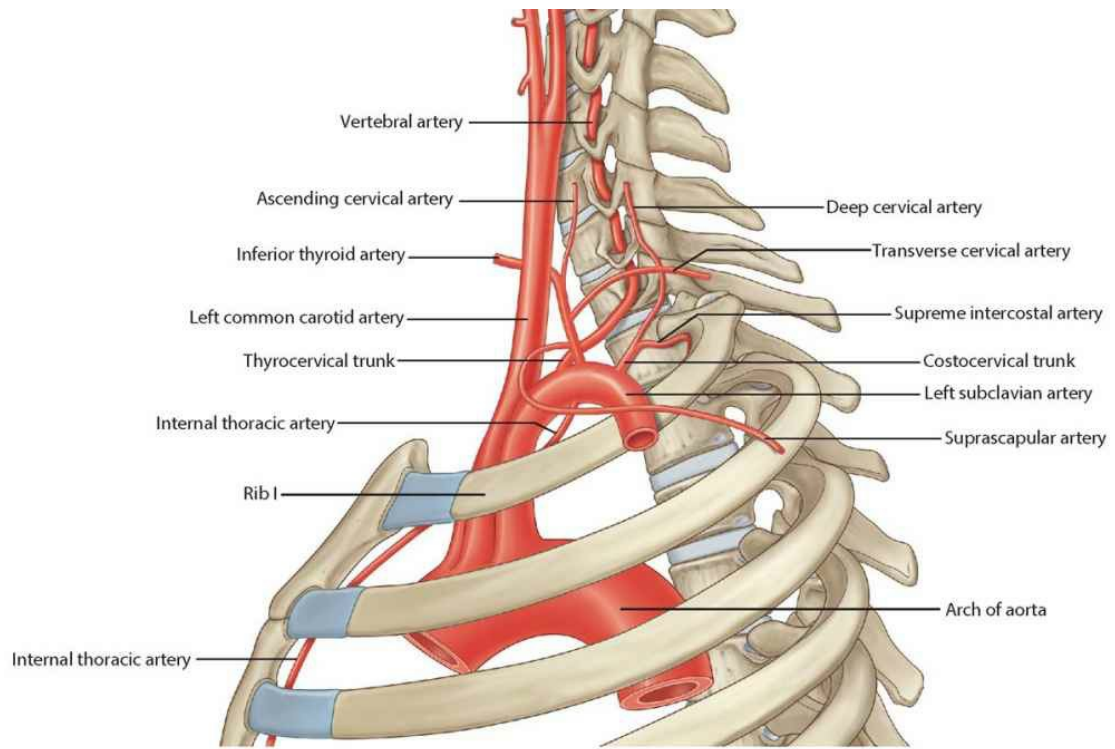
**Lateral view of the branches of the external carotid artery.**  
 Volume-rendered angiographic image with contrast using multidetector CT

## Root of the neck: arteries

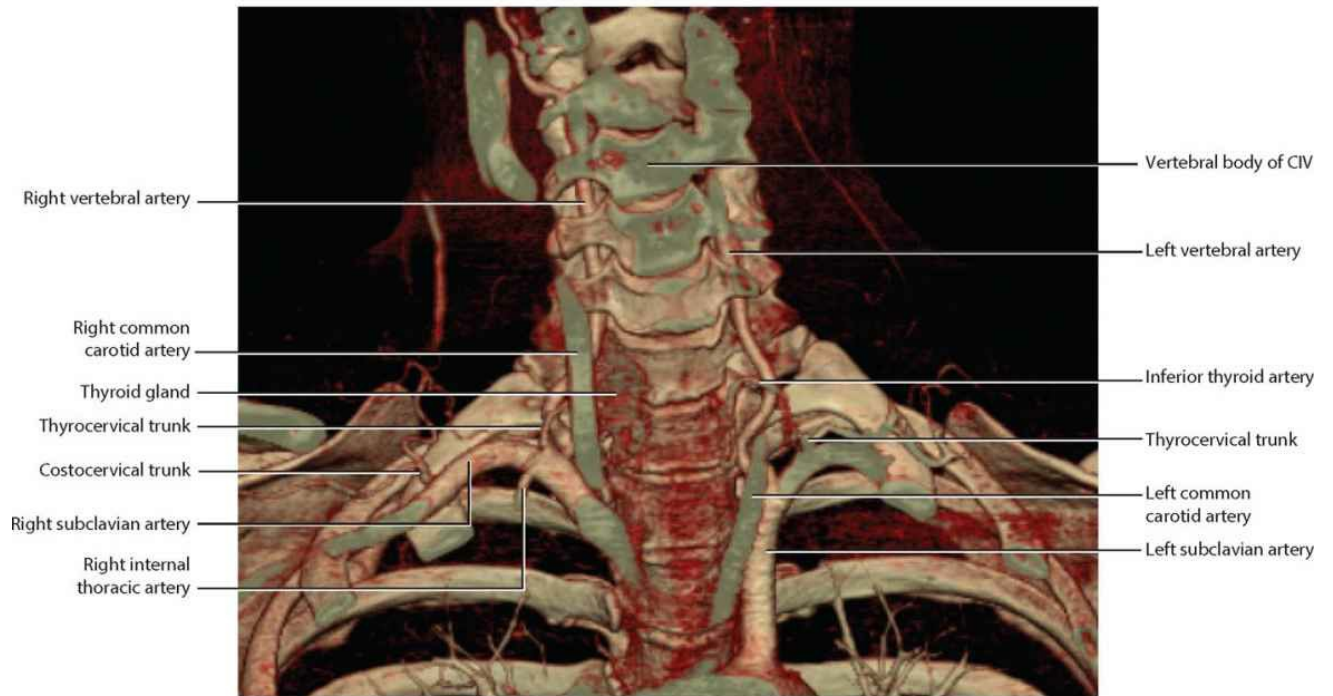





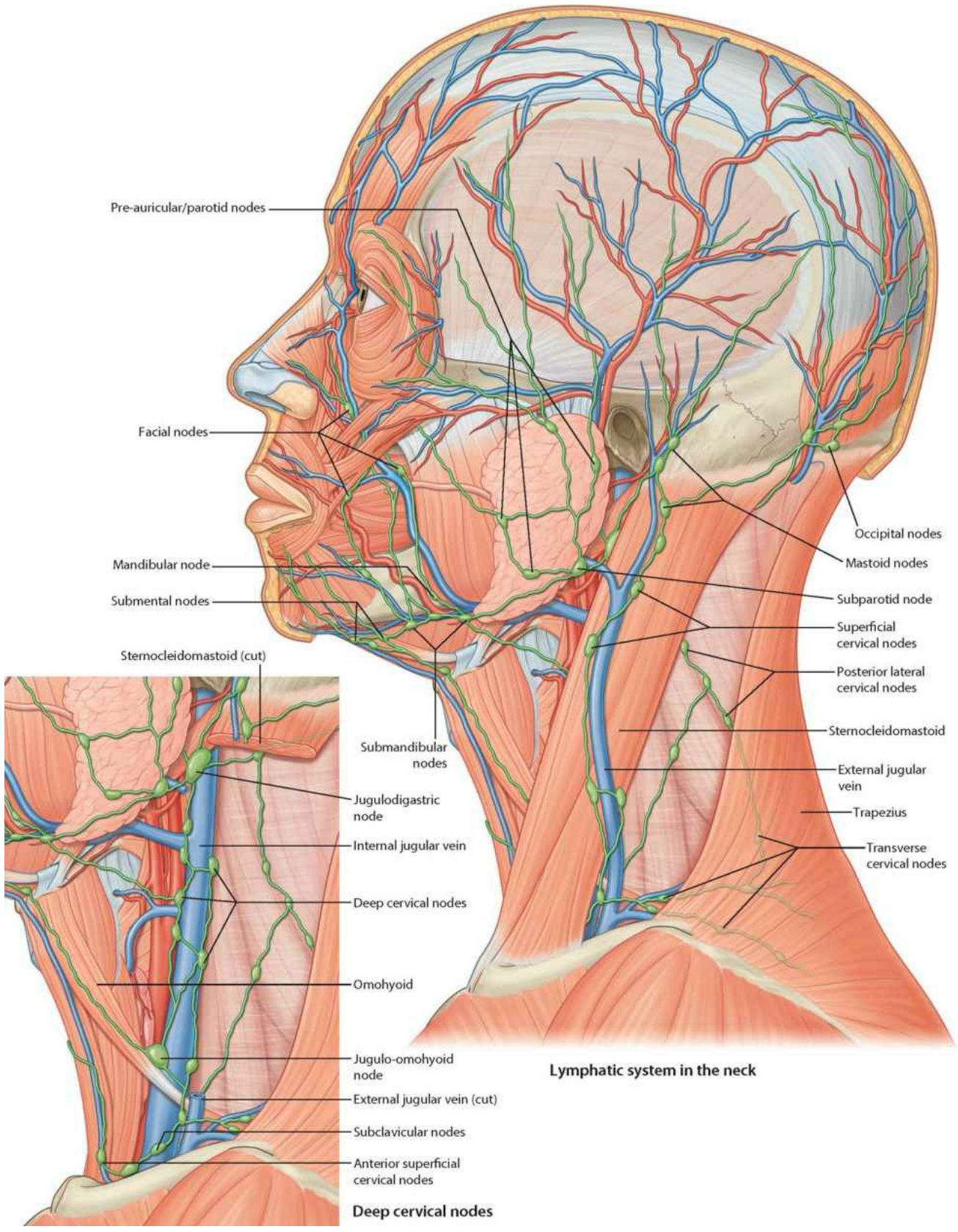


Lateral view

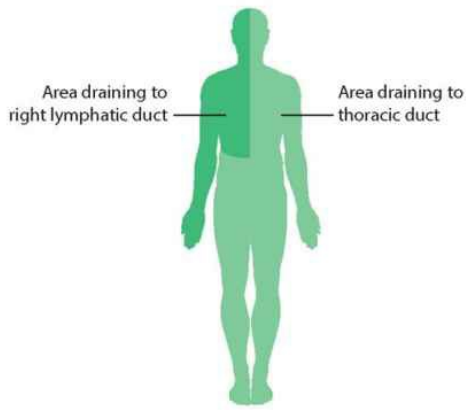


Anterior view of the root of the neck showing the branches of the subclavian arteries.  
Volume-rendered angiographic image with contrast using multidetector CT

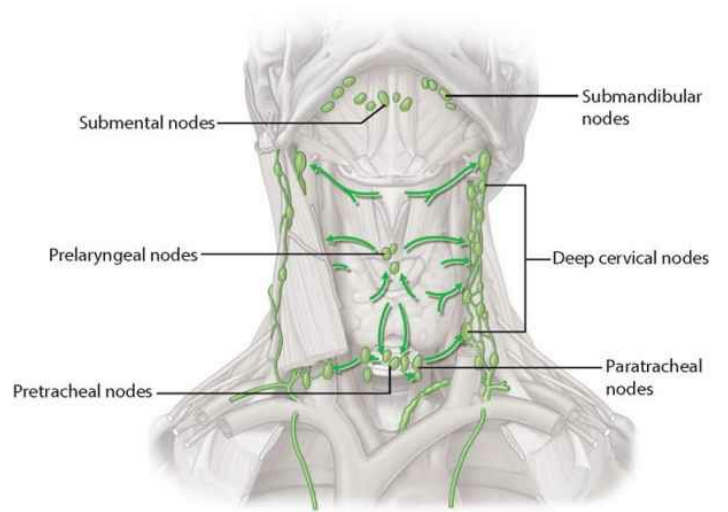
# Lymphatics of the neck



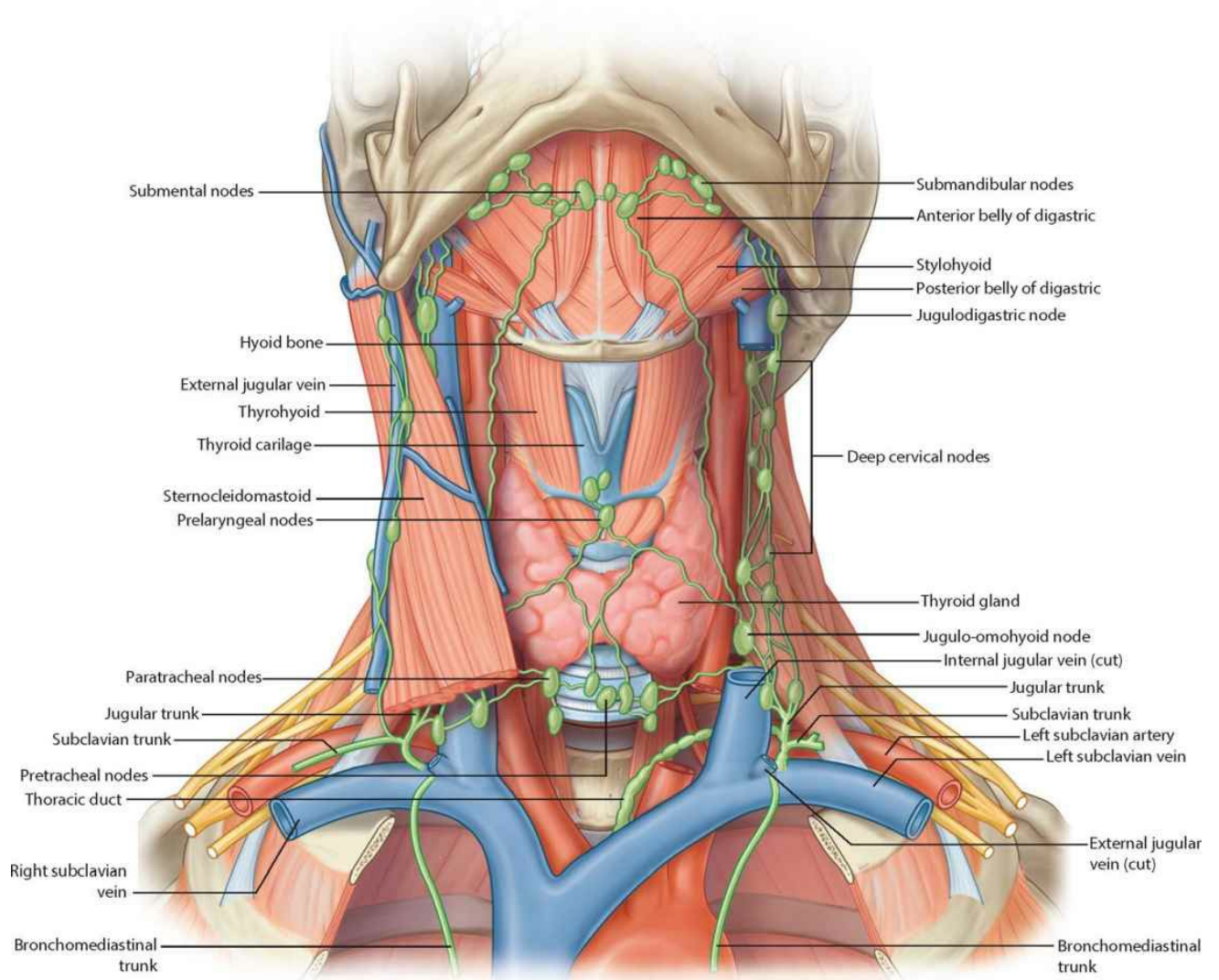




Areas of lymphatic drainage

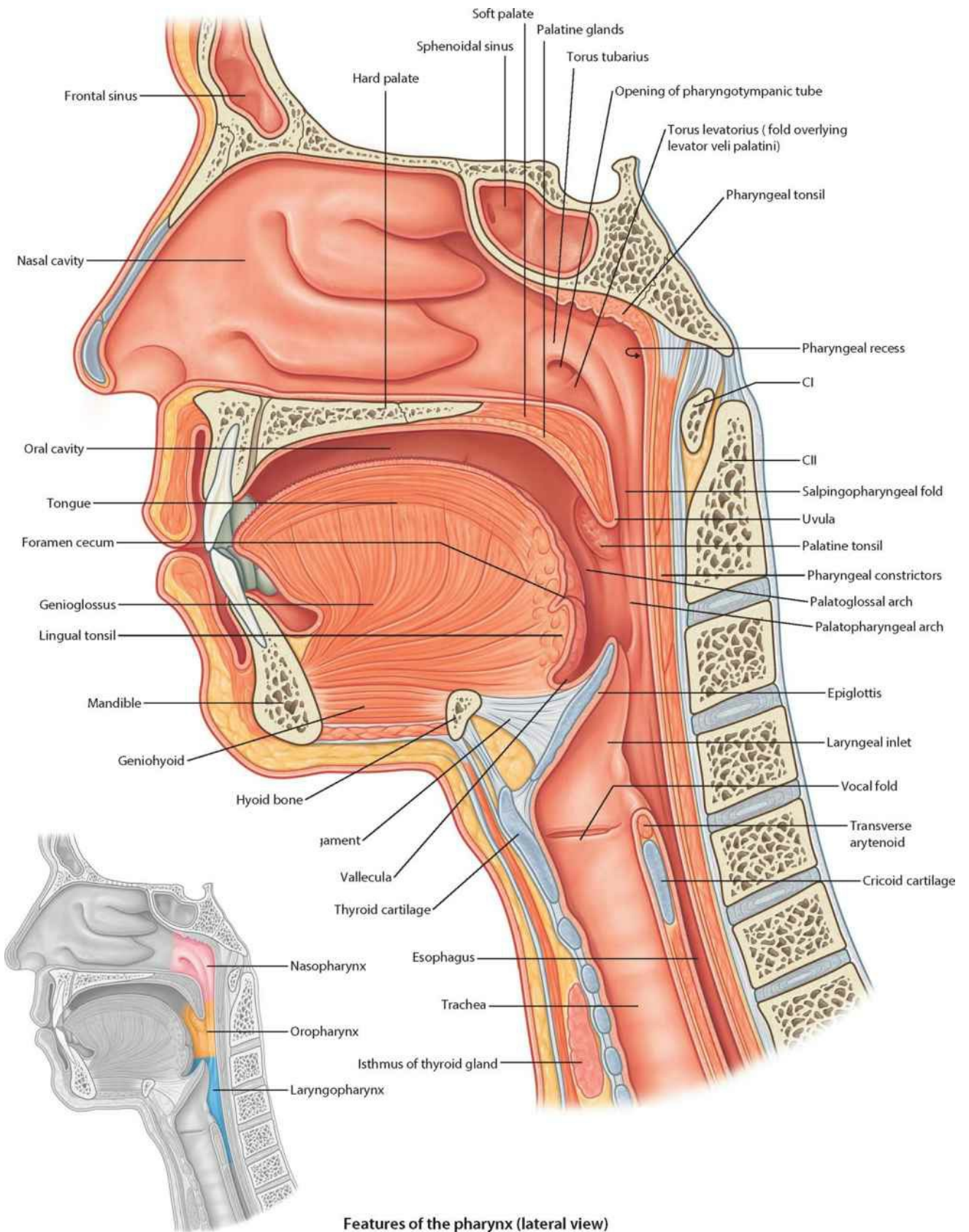


Lymphatic drainage of the thyroid gland, larynx, and trachea



Lymphatic system in the neck

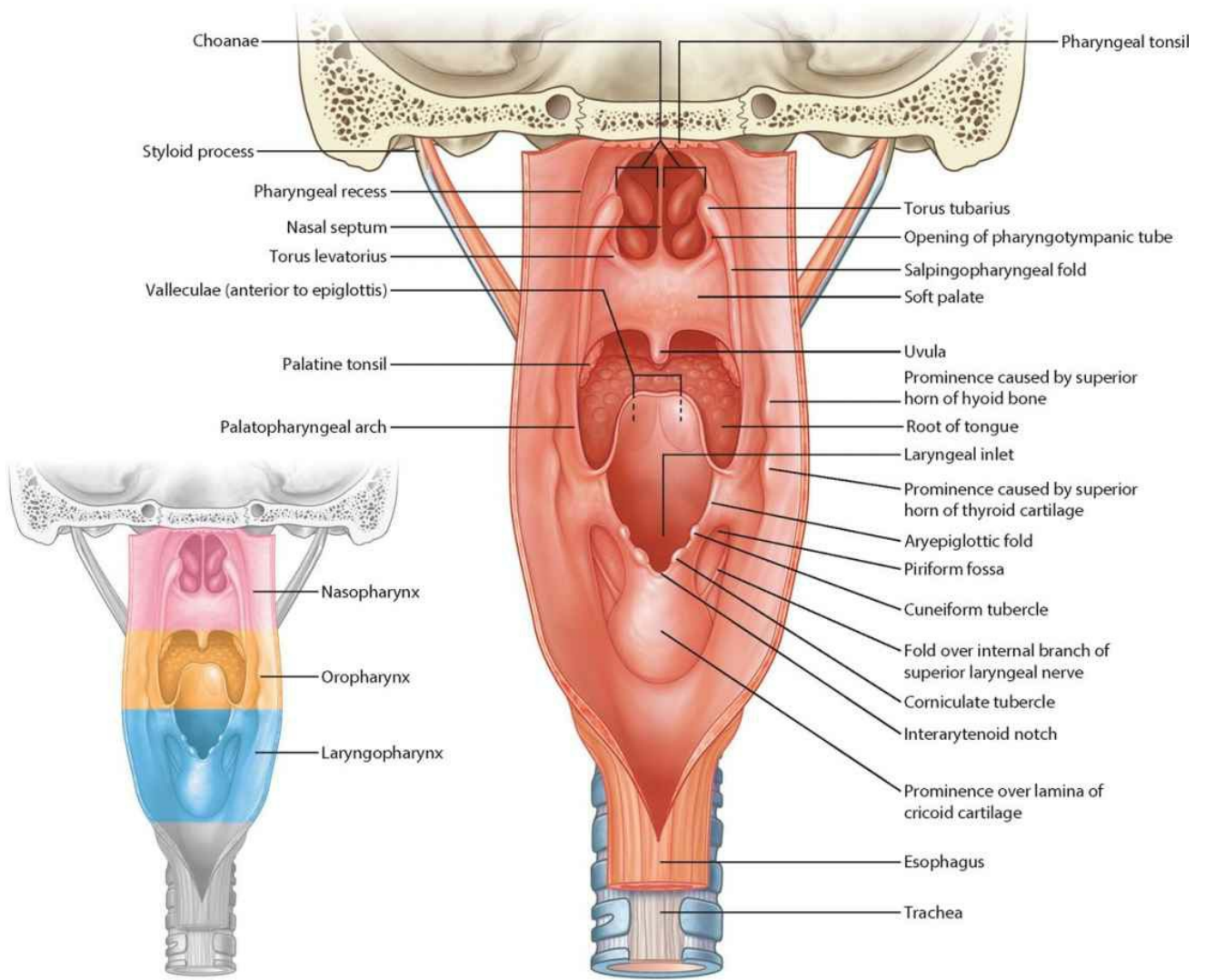
# Pharynx



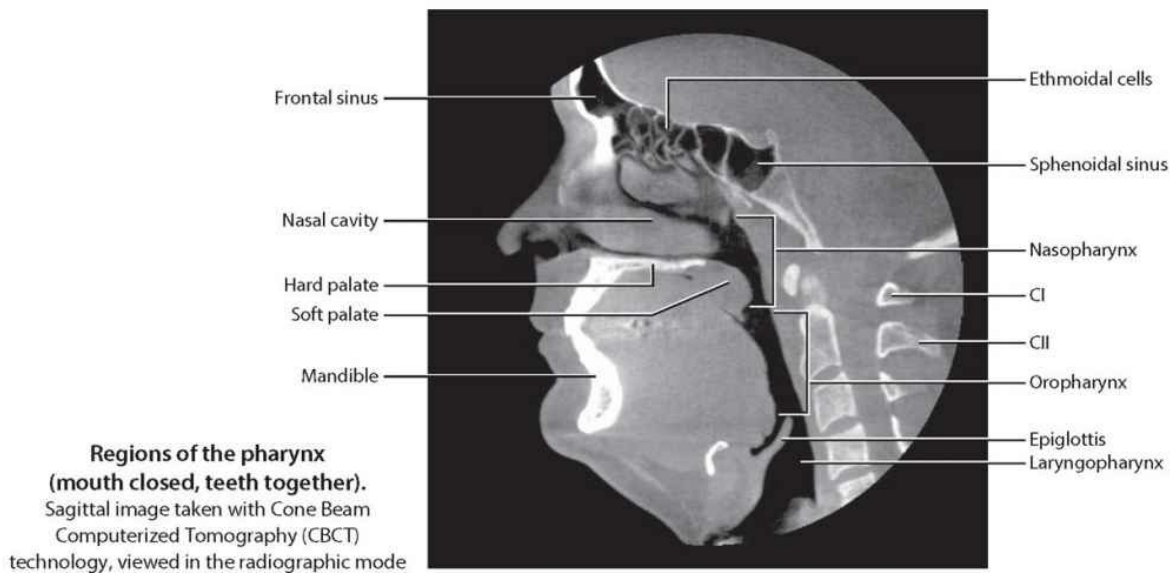
**Features of the pharynx (lateral view)**





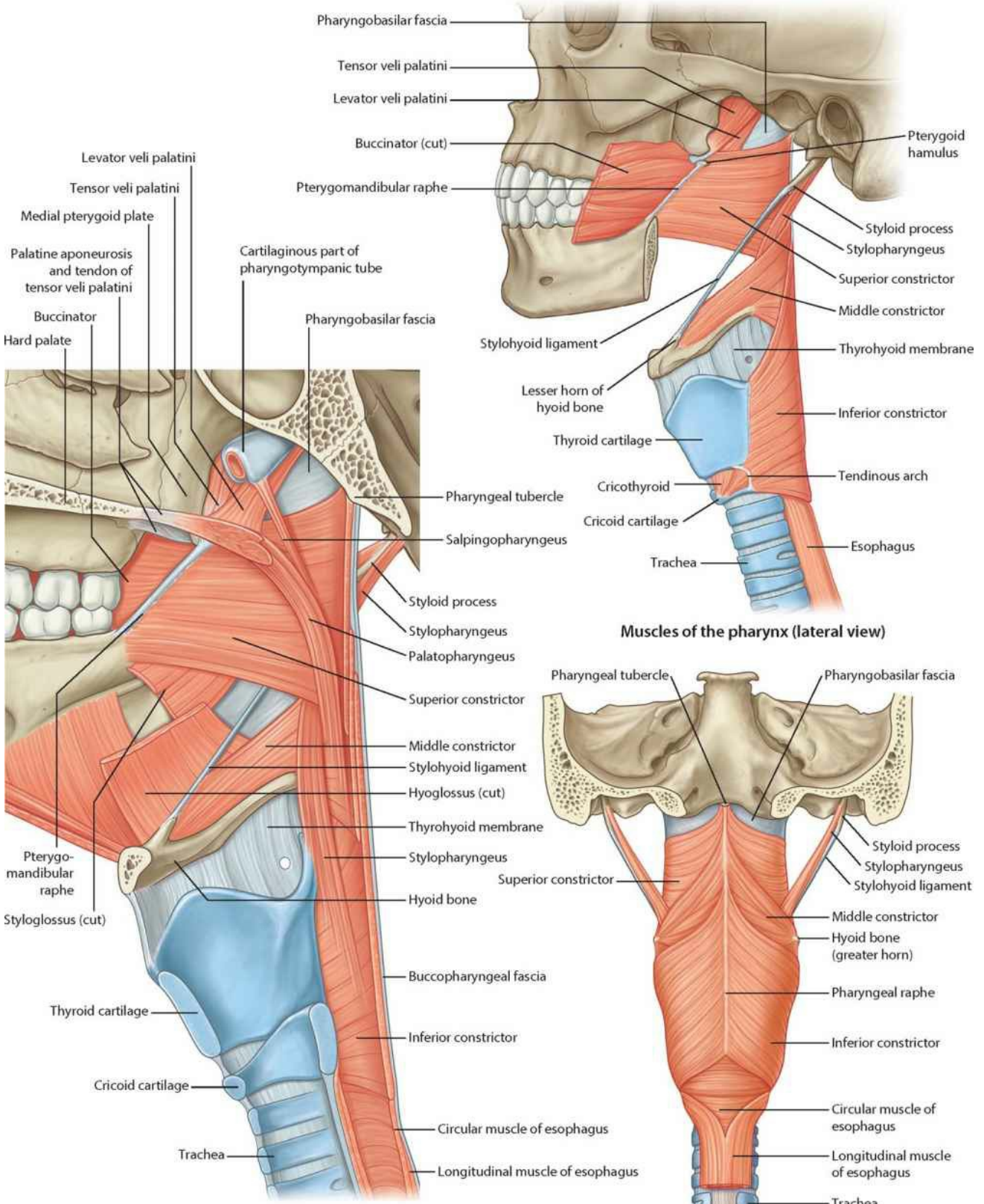


**Features of the pharynx**  
(posterior view with the pharyngeal wall opened)



**Regions of the pharynx**  
(mouth closed, teeth together).  
Sagittal image taken with Cone Beam  
Computerized Tomography (CBCT)  
technology, viewed in the radiographic mode

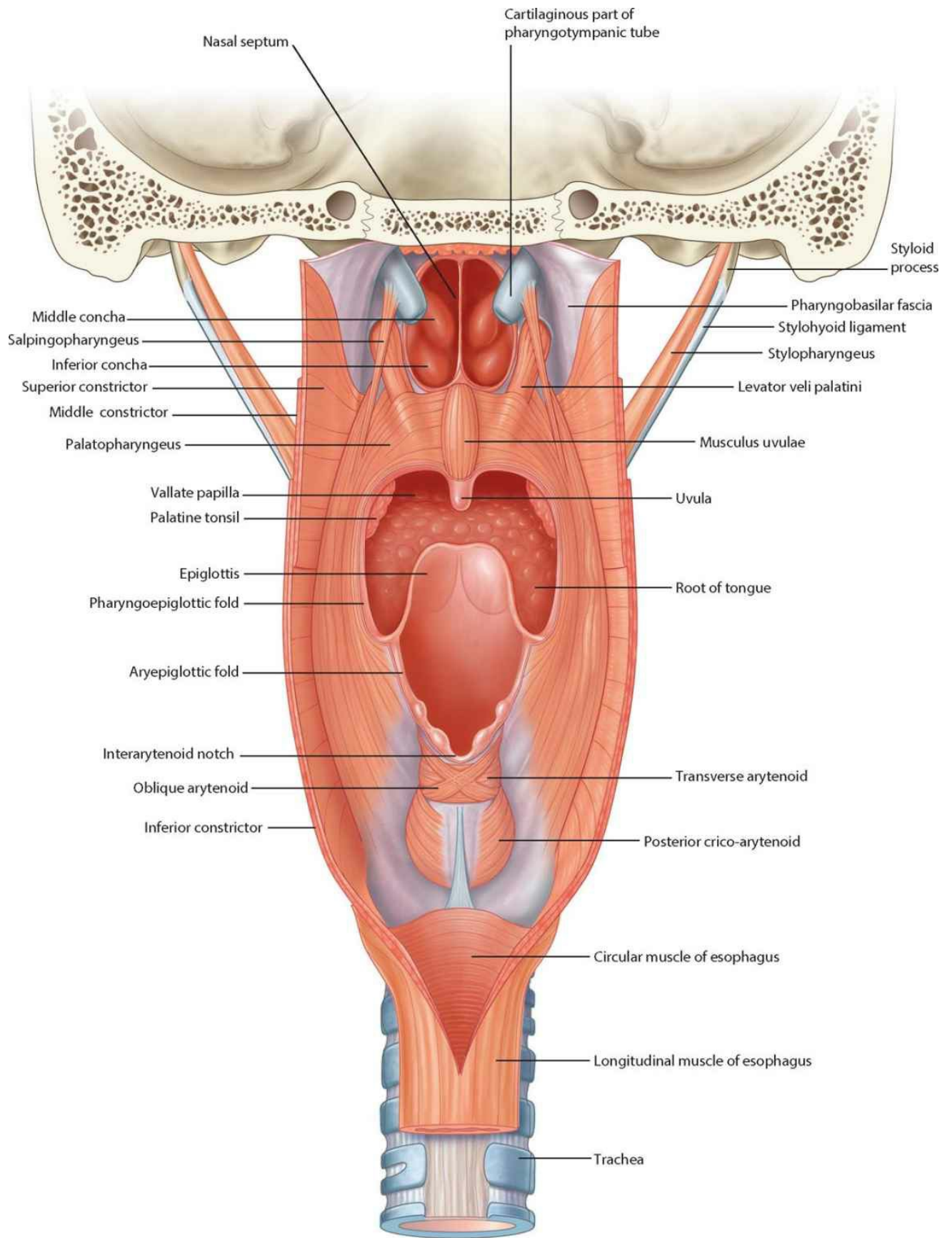
# Muscles of the pharynx



Muscles of the pharynx (lateral view)

Sagittal section through pharynx

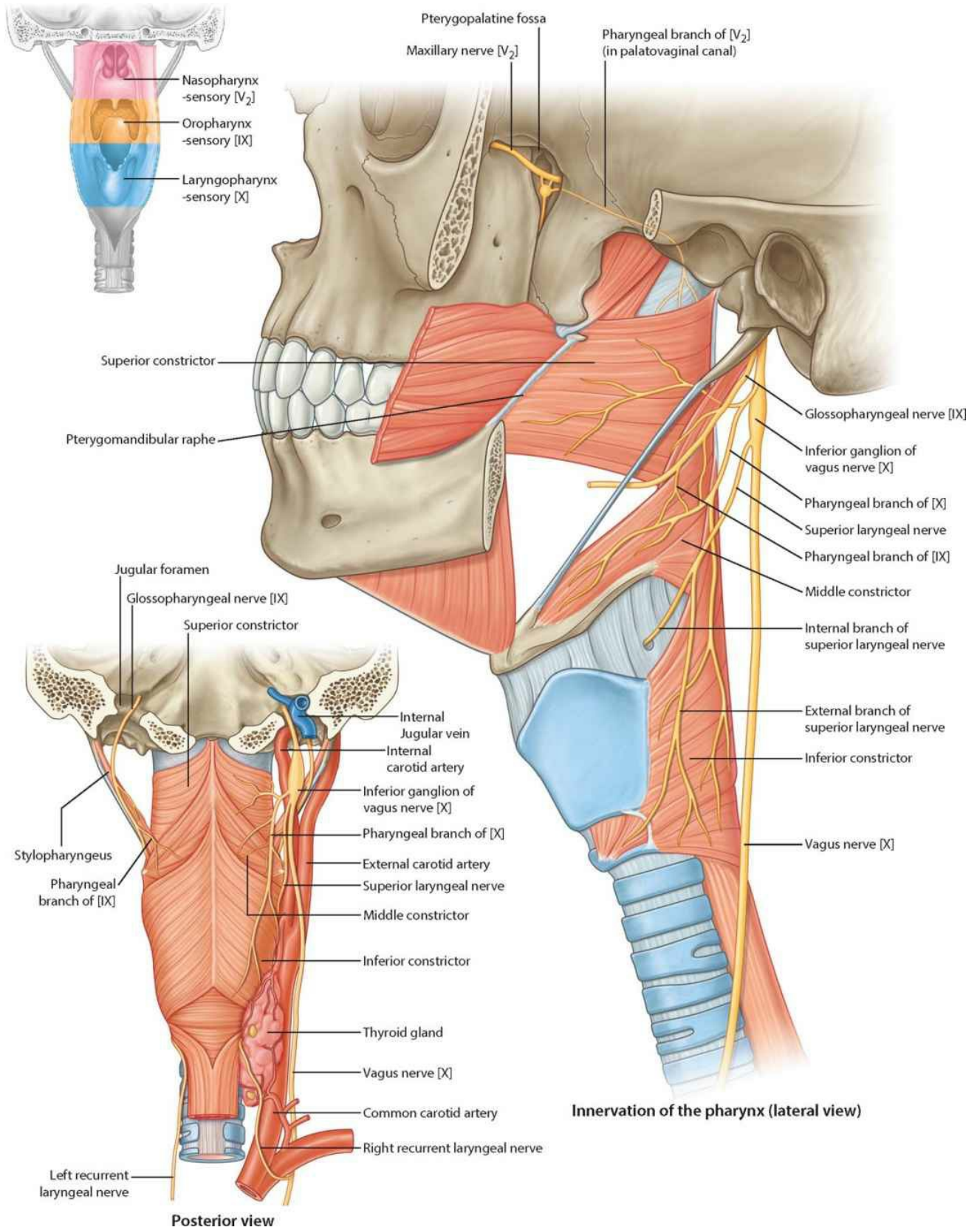
Posterior view



**Muscles of the posterior wall of the pharynx**

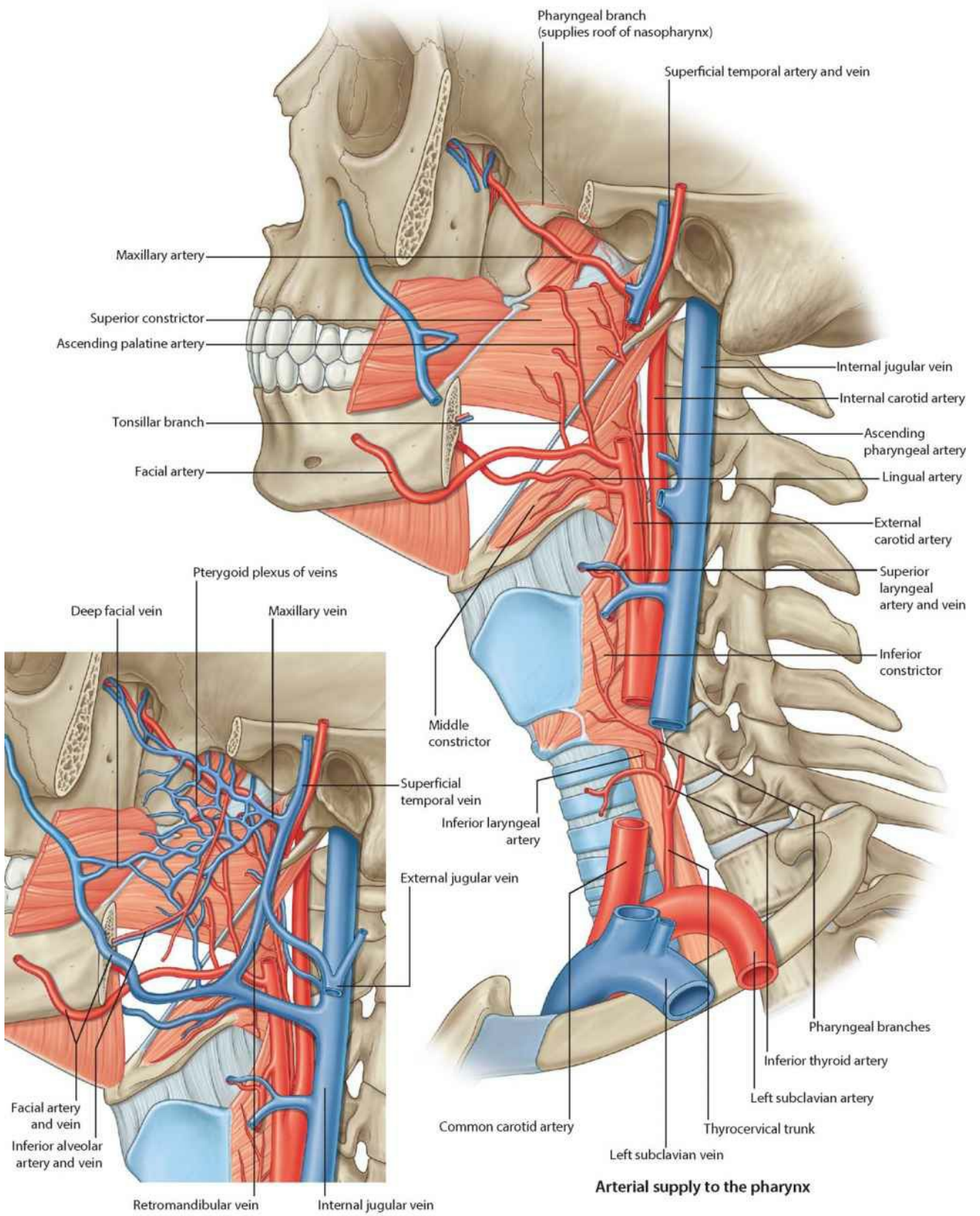


# Innervation of the pharynx



# Vasculature of the pharynx

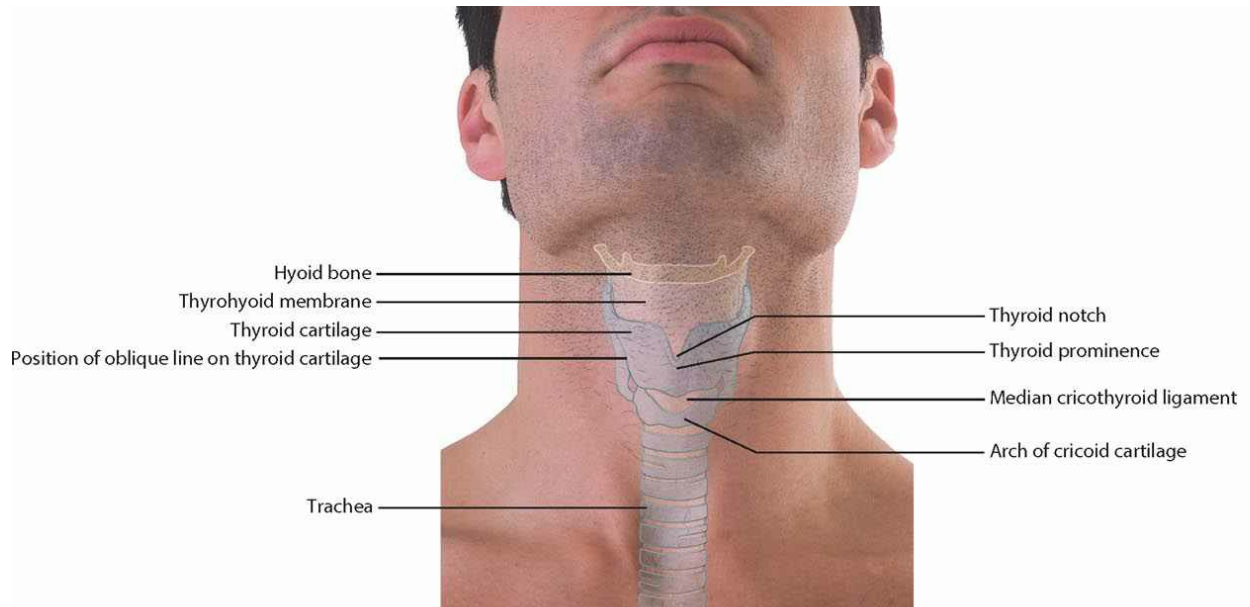




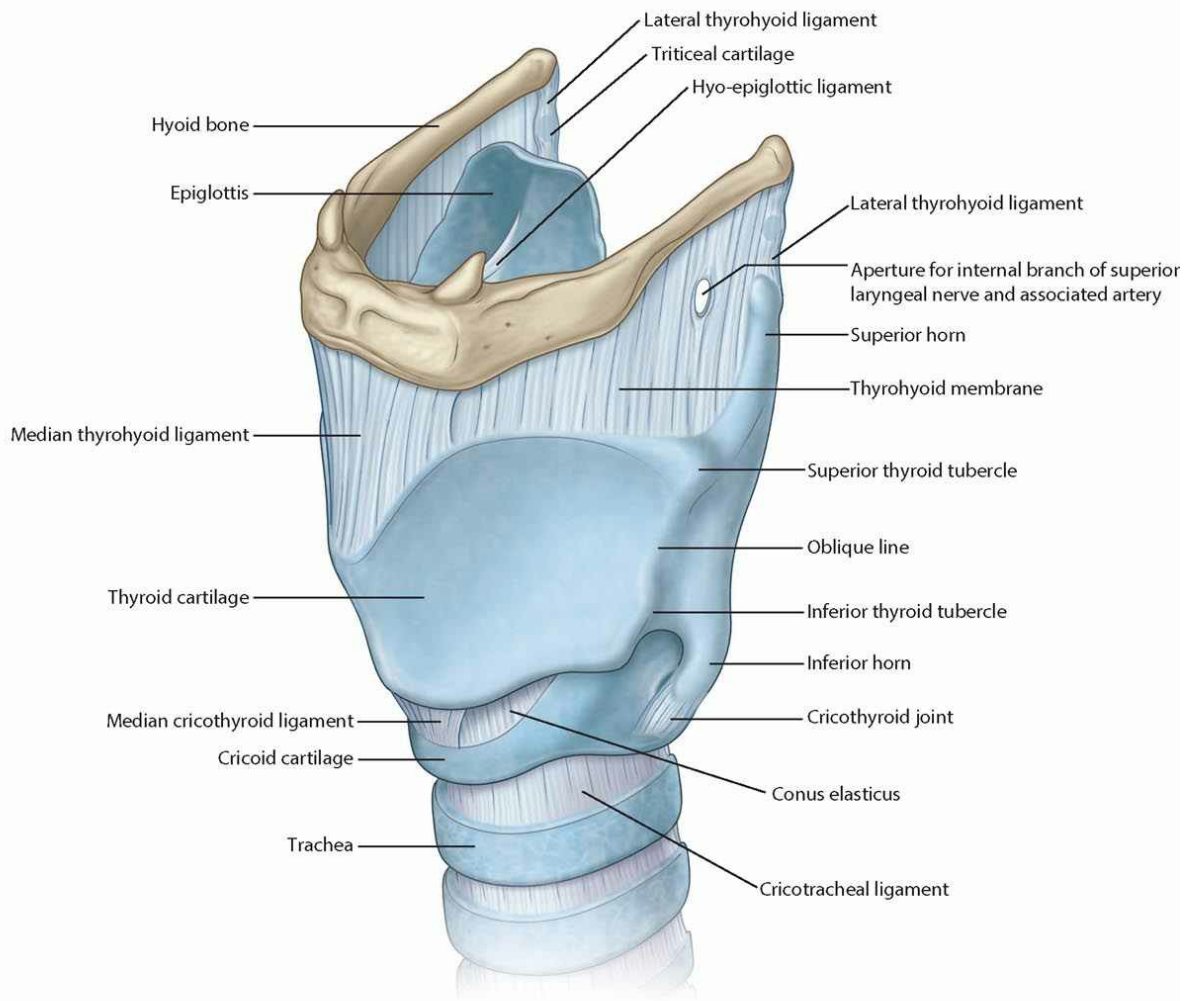
**Venous drainage of the pharynx**

**Arterial supply to the pharynx**

# Larynx

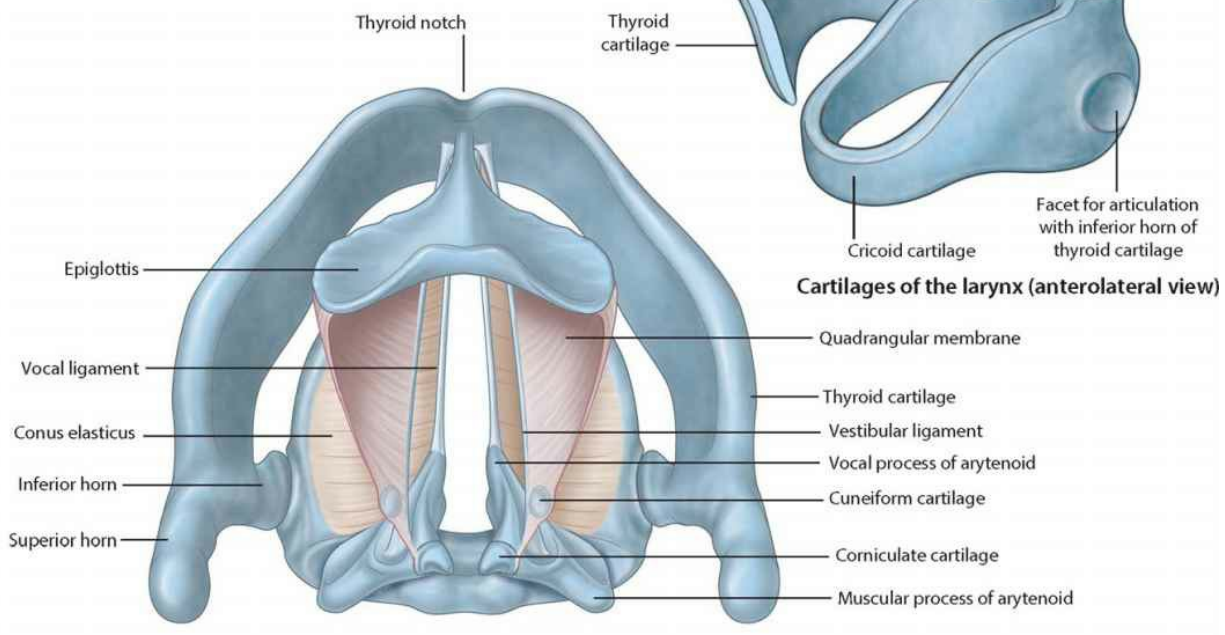
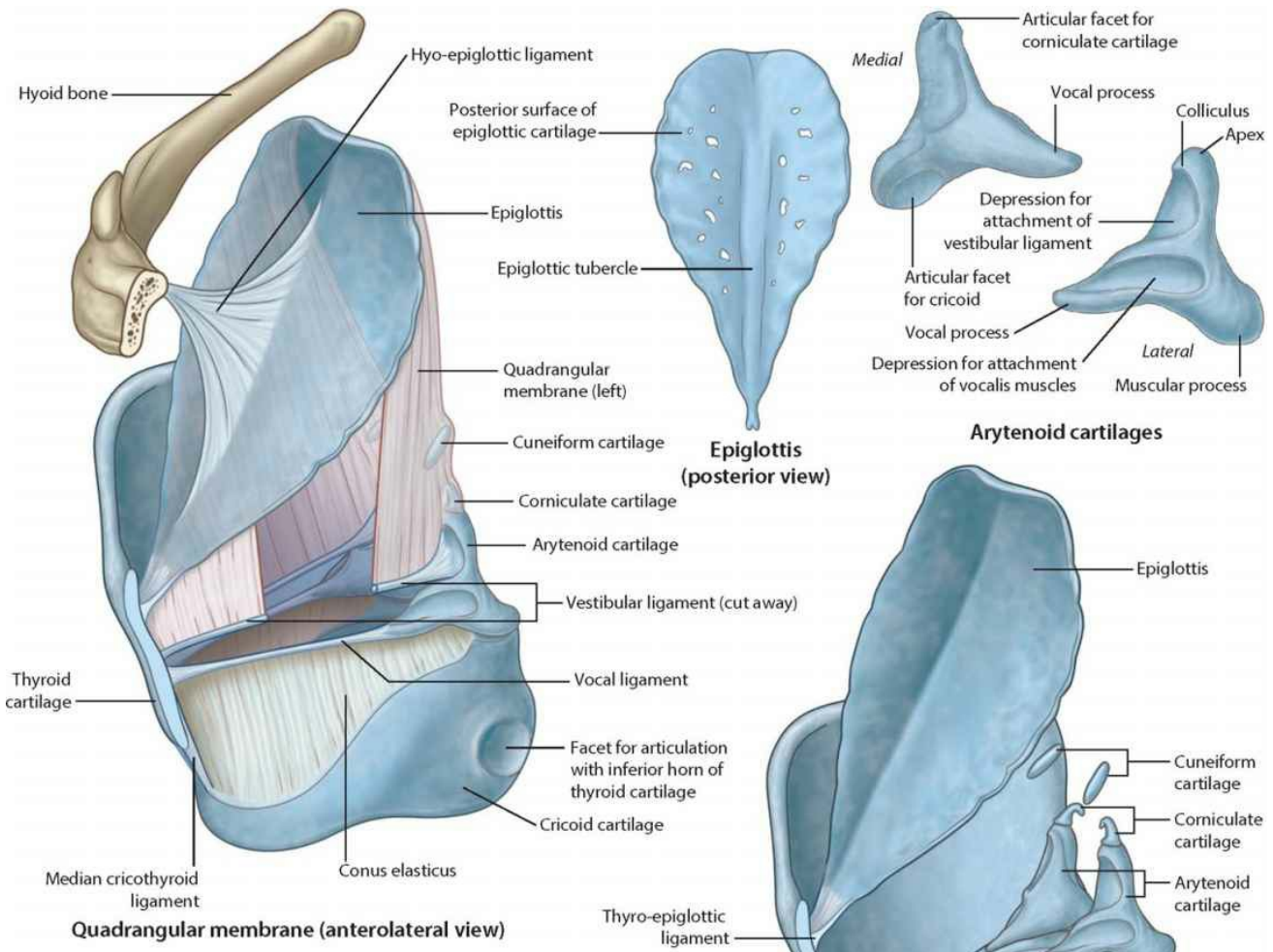


**Position of larynx in the neck as it relates to the surface**



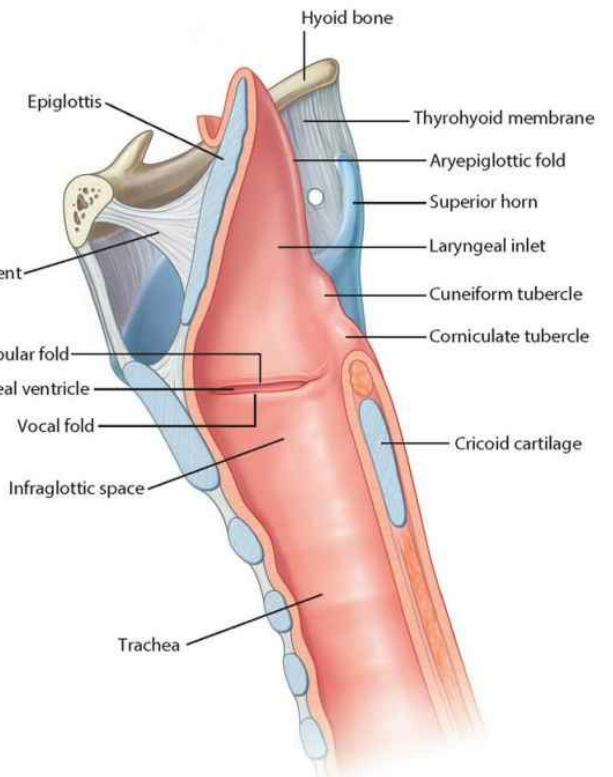
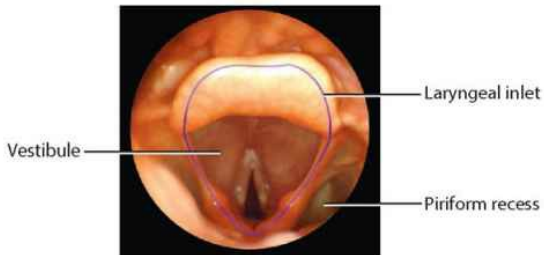
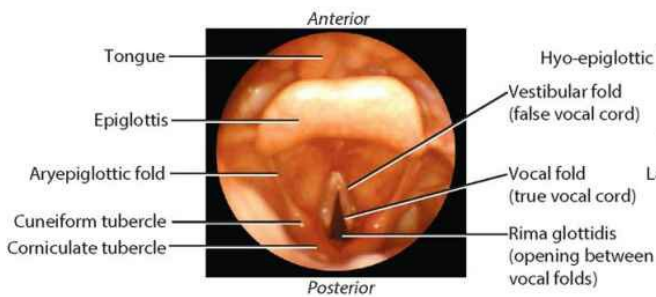
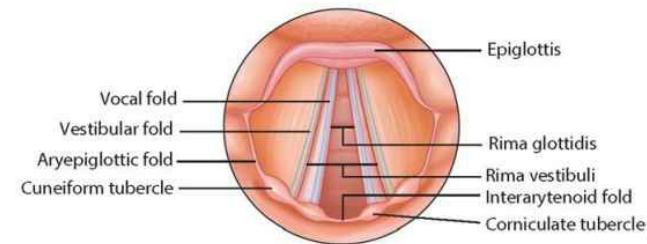
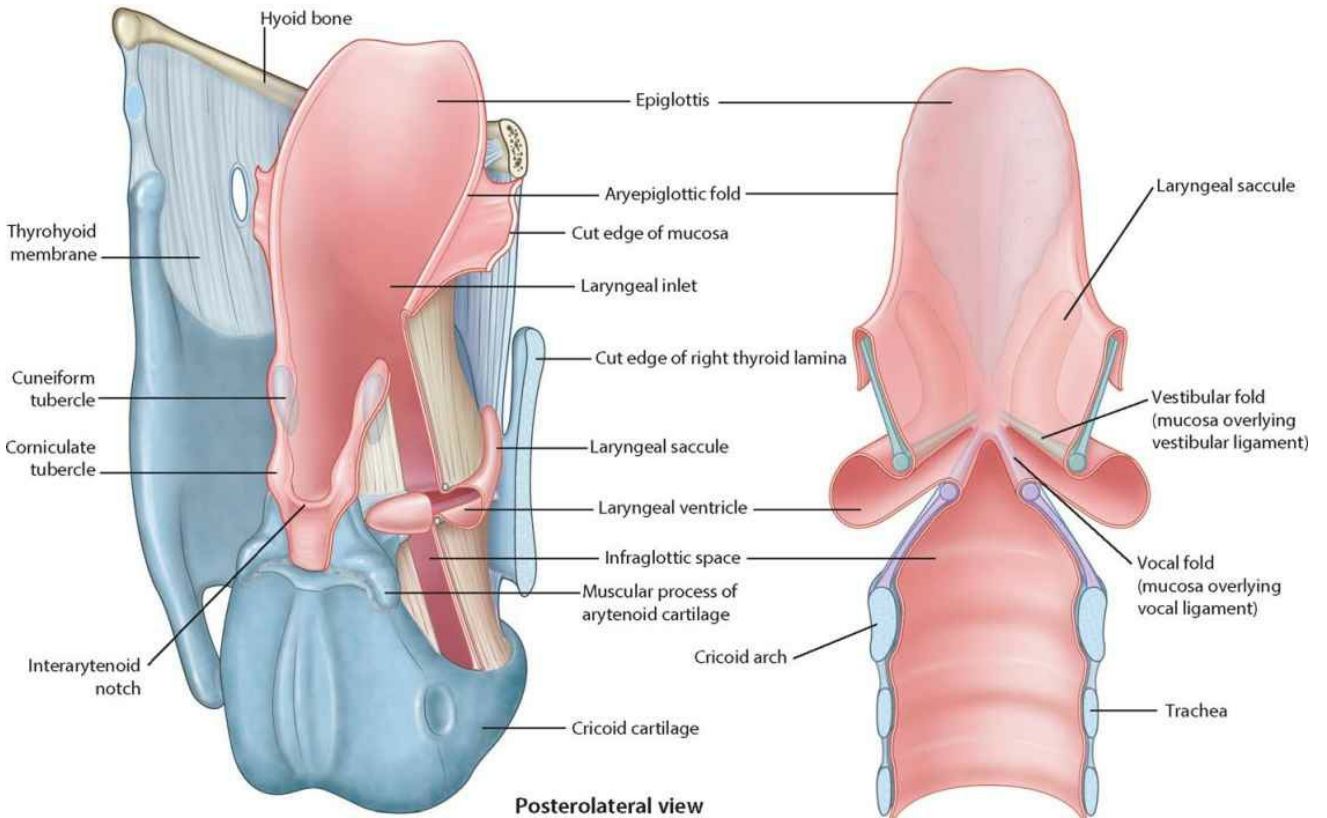
**External features of the larynx (anterolateral view)**





Fibro-elastic membrane of the larynx (superior view)

# Laryngeal cavity

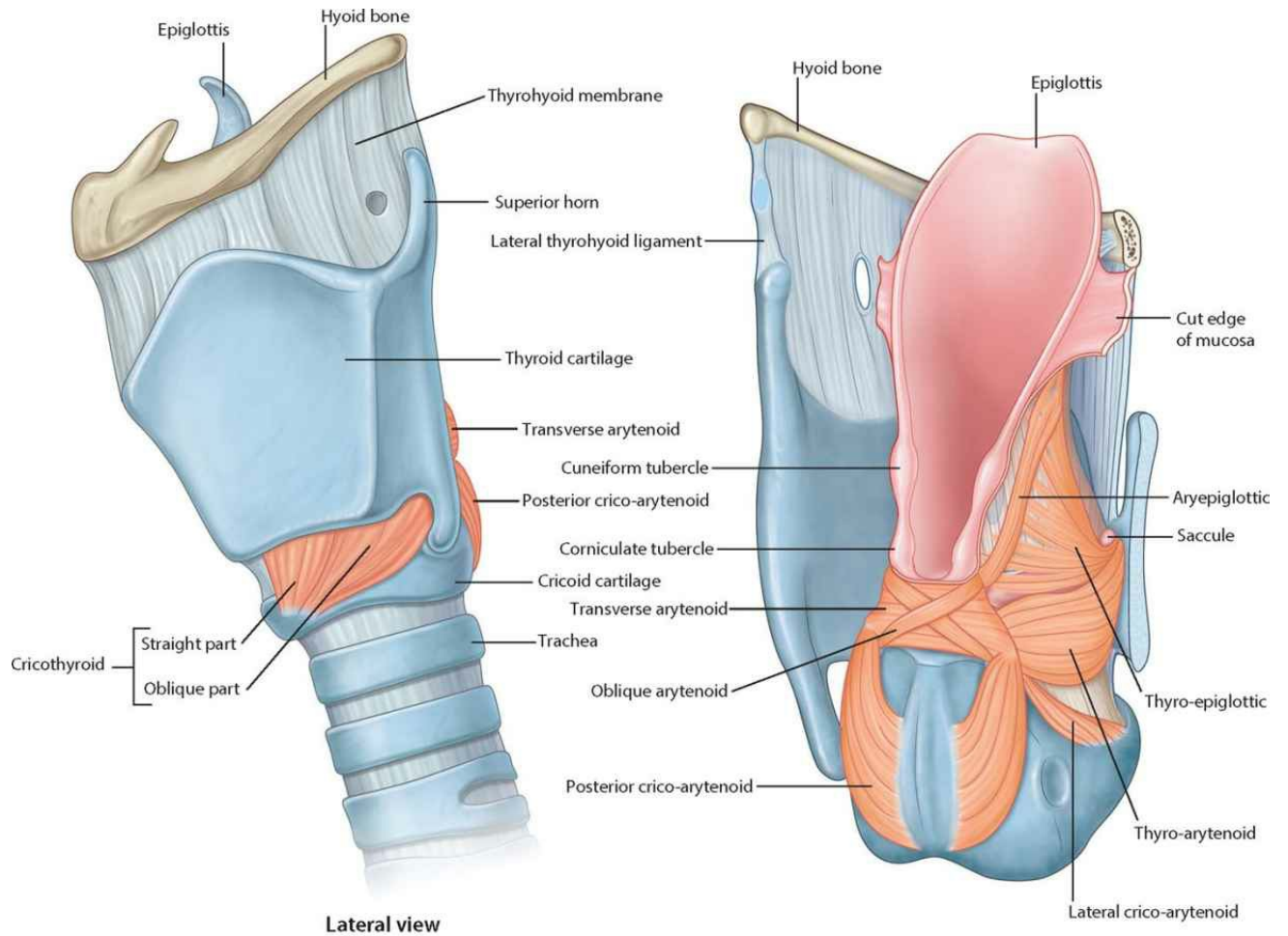


Superior view through the laryngeal inlet

Sagittal section through laryngeal cavity

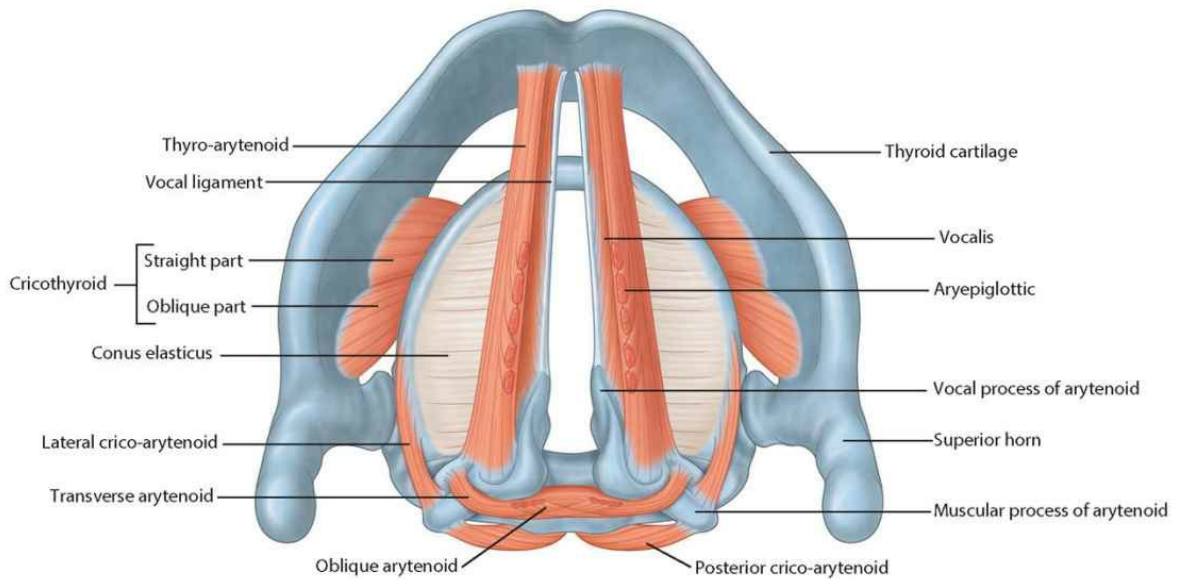
# Muscles of the larynx





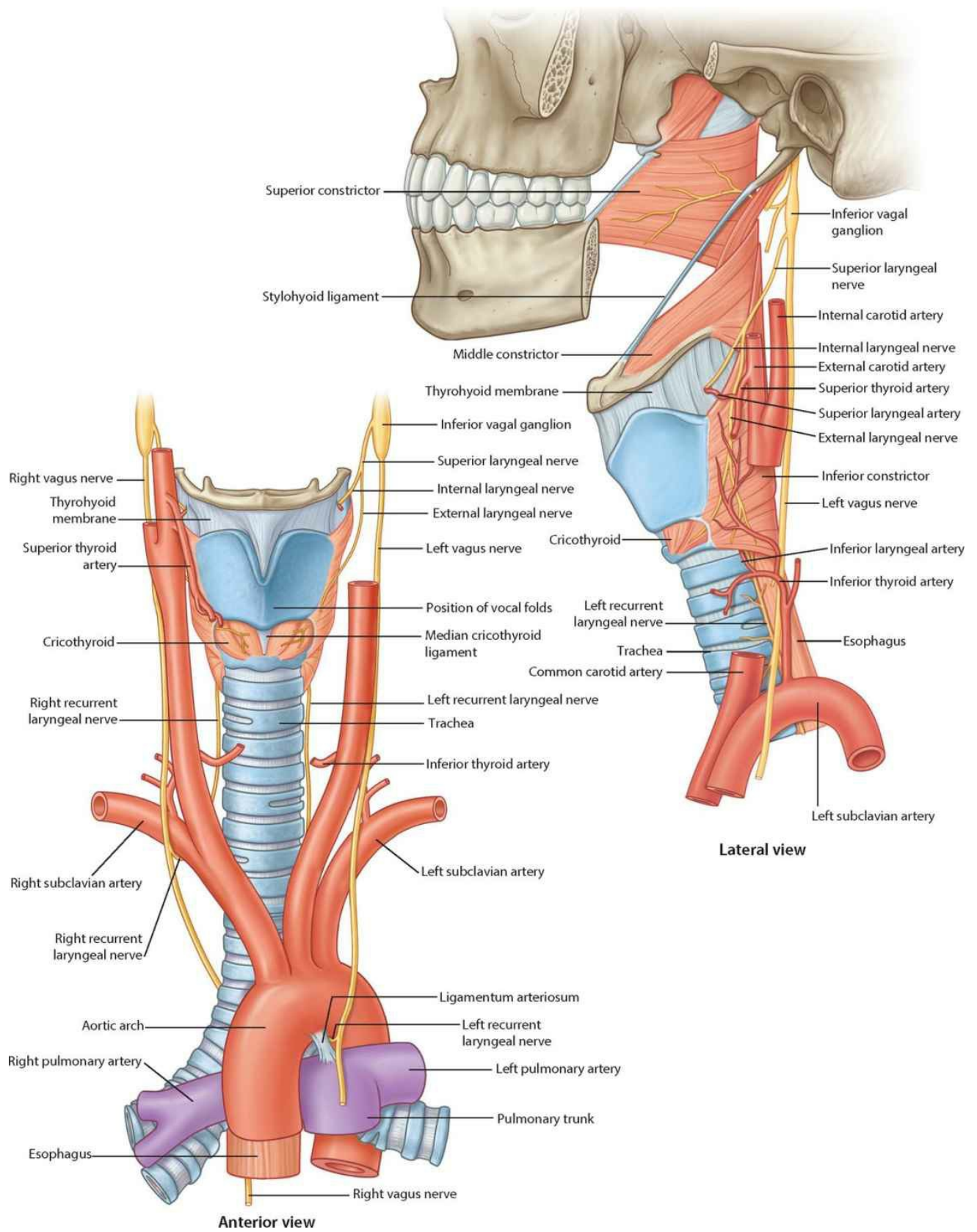
Lateral view

Posterolateral view

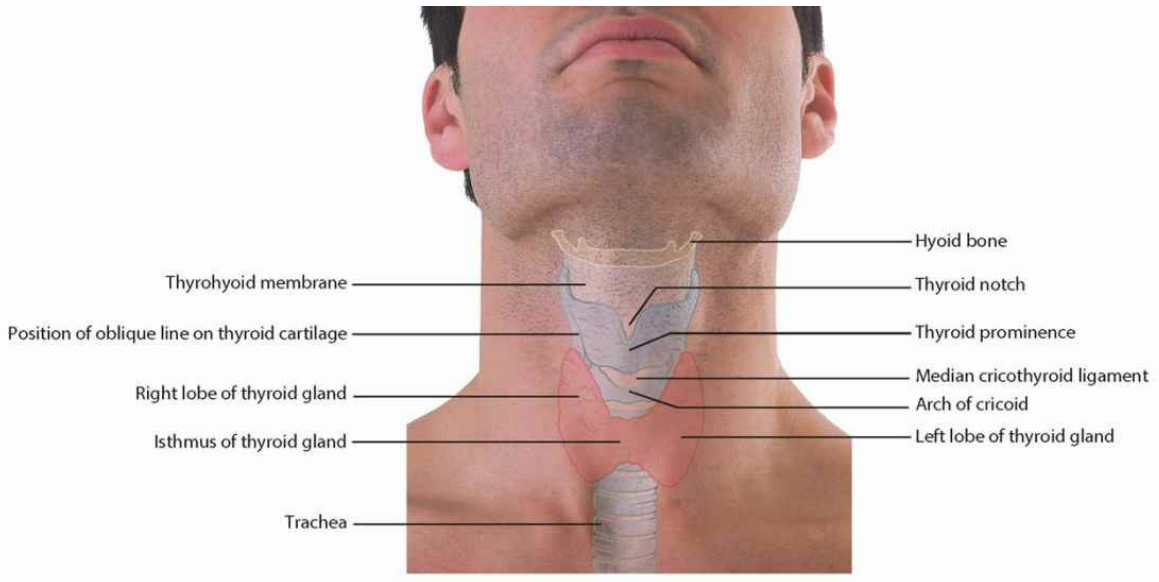


Superior view

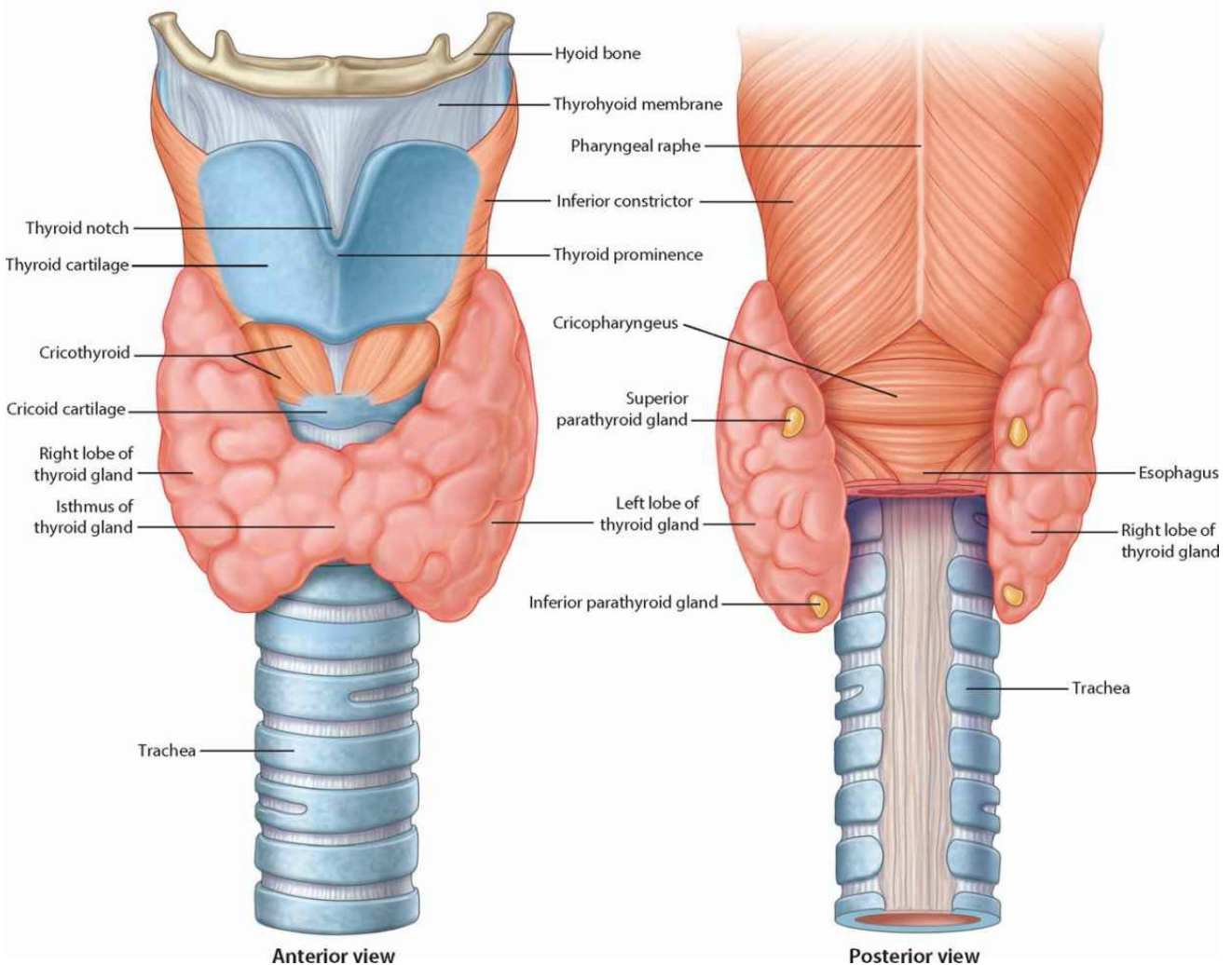
# Innervation of the larynx



# Thyroid gland



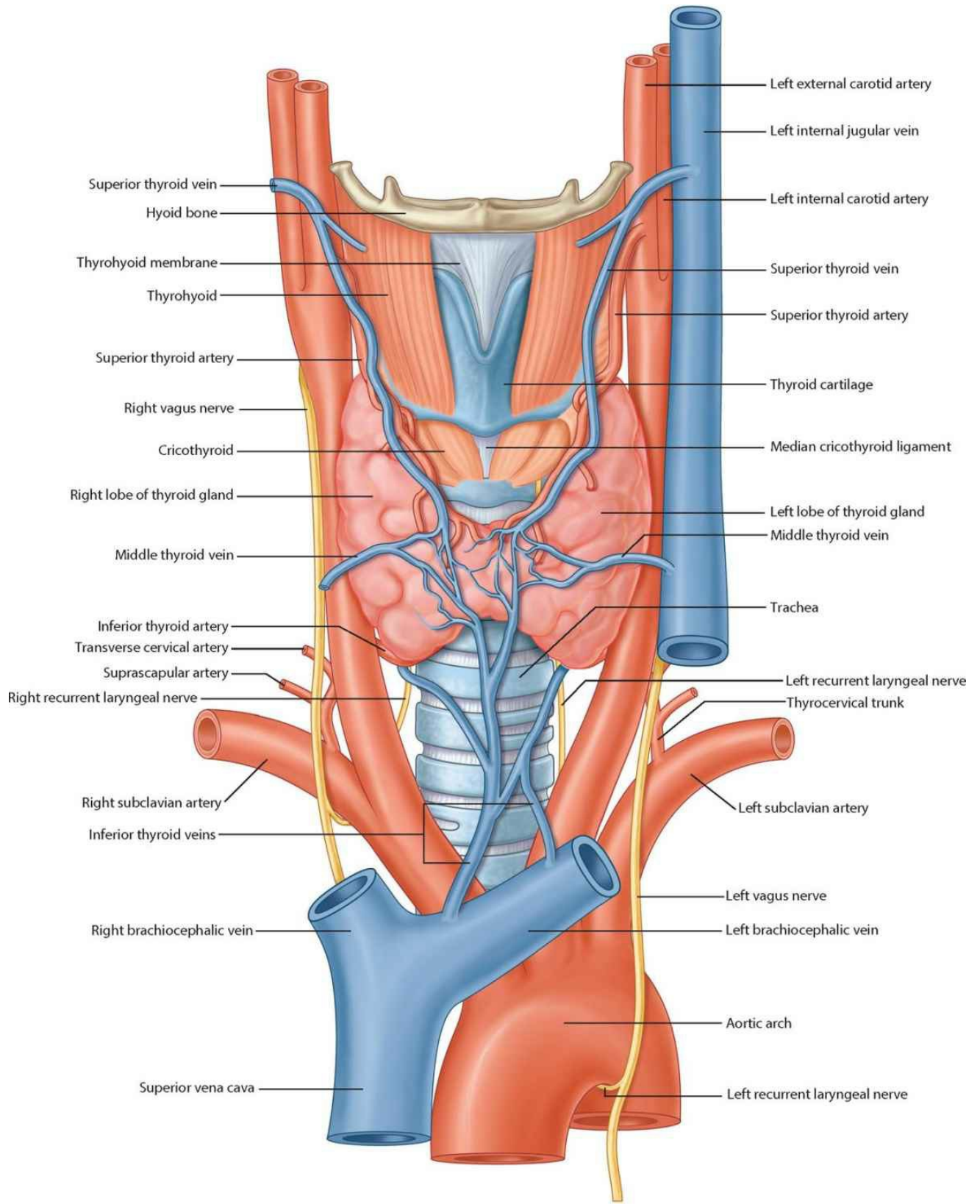
**Thyroid gland as it relates to surface**



**Anterior view**

**Posterior view**

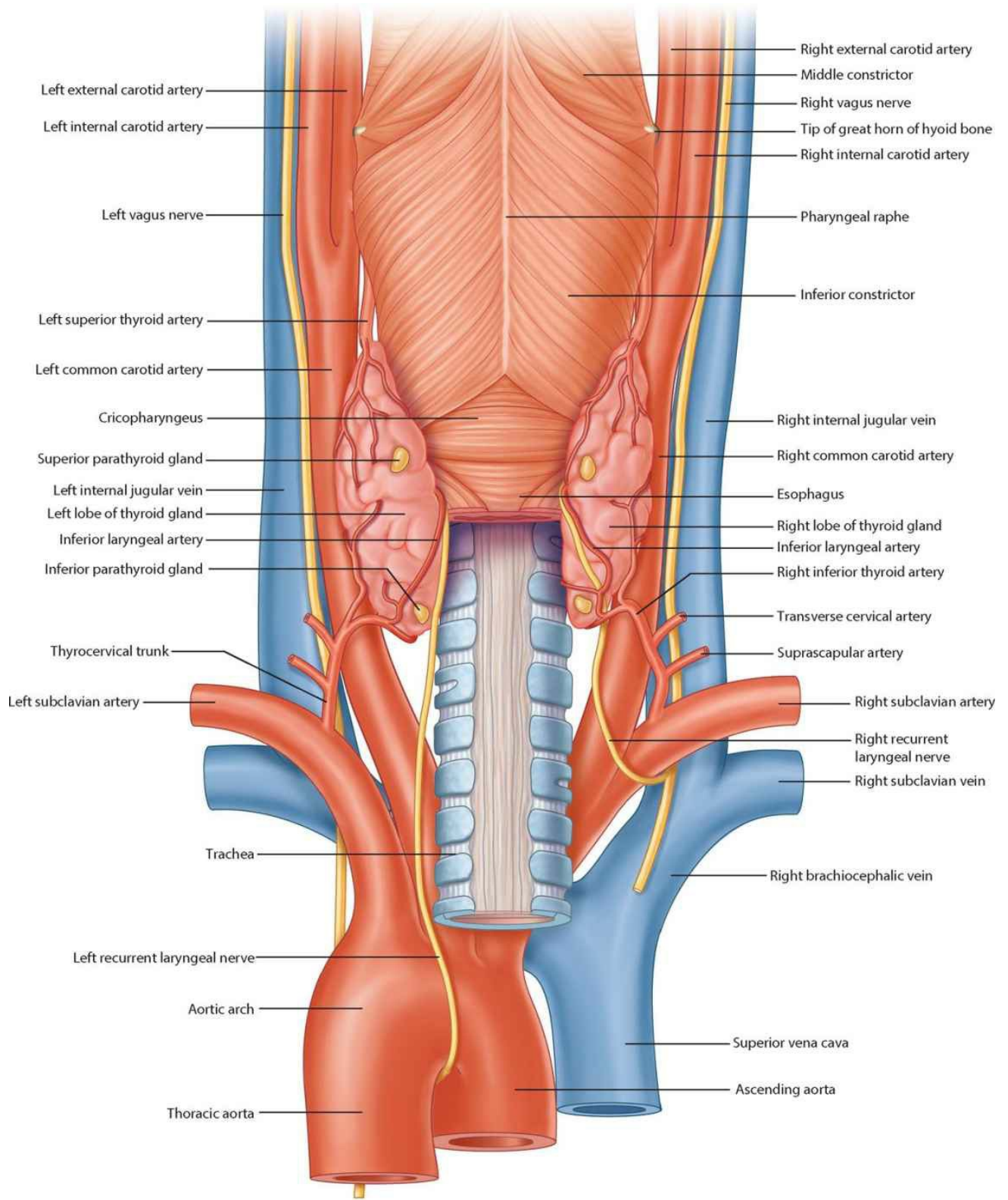
# Vasculature of the thyroid gland



Anterior view





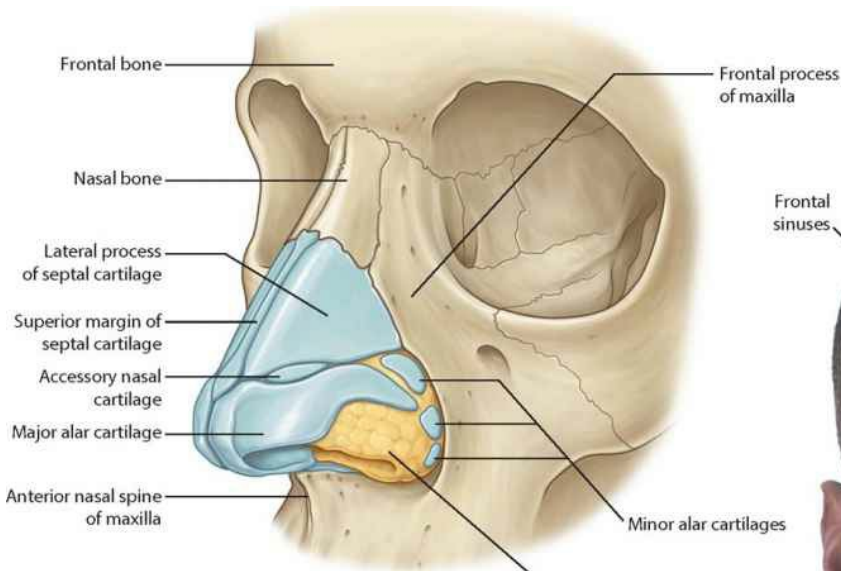


- Left external carotid artery
- Left internal carotid artery
- Left vagus nerve
- Left superior thyroid artery
- Left common carotid artery
- Cricopharyngeus
- Superior parathyroid gland
- Left internal jugular vein
- Left lobe of thyroid gland
- Inferior laryngeal artery
- Inferior parathyroid gland
- Thyrocervical trunk
- Left subclavian artery
- Trachea
- Left recurrent laryngeal nerve
- Aortic arch
- Thoracic aorta

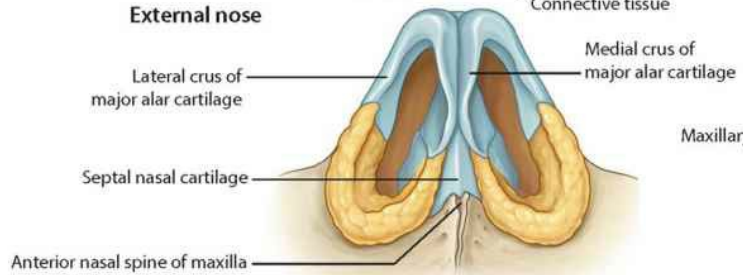
- Right external carotid artery
- Middle constrictor
- Right vagus nerve
- Tip of great horn of hyoid bone
- Right internal carotid artery
- Pharyngeal raphe
- Inferior constrictor
- Right internal jugular vein
- Right common carotid artery
- Esophagus
- Right lobe of thyroid gland
- Inferior laryngeal artery
- Right inferior thyroid artery
- Transverse cervical artery
- Suprascapular artery
- Right subclavian artery
- Right recurrent laryngeal nerve
- Right subclavian vein
- Right brachiocephalic vein
- Superior vena cava
- Ascending aorta

Posterior view

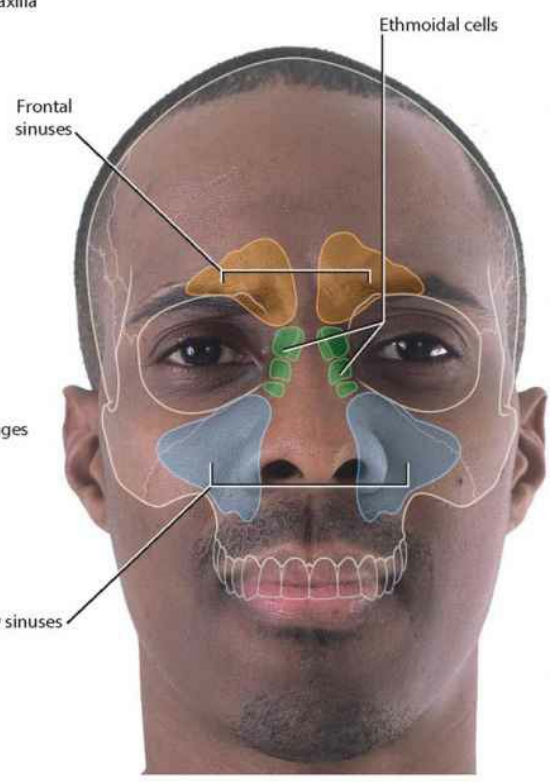
# Nose and paranasal sinuses



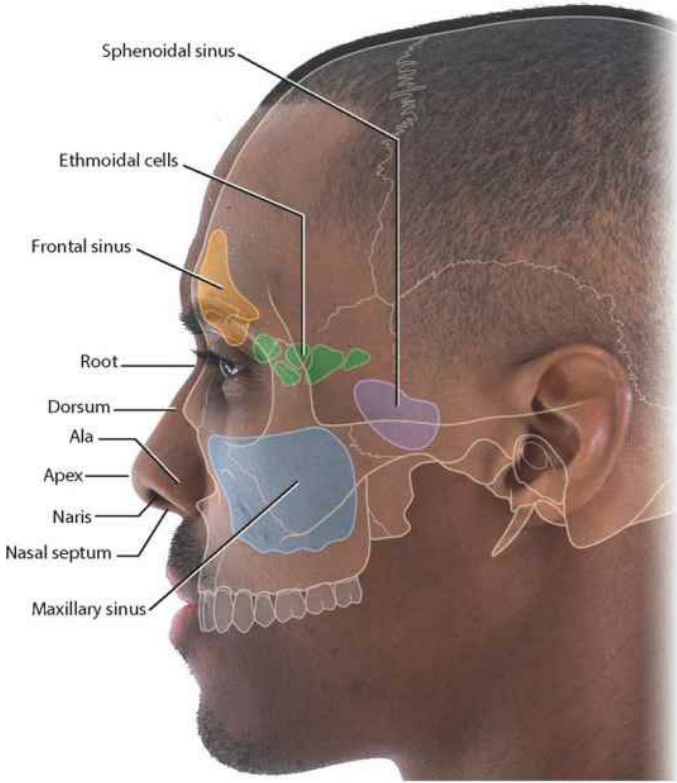
**External nose**



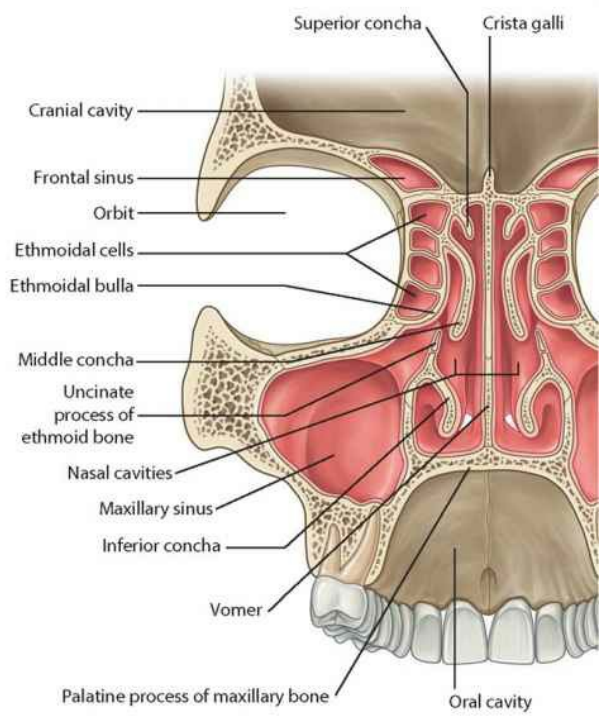
**Inferior view**



**Paranasal sinuses (anterior view)**

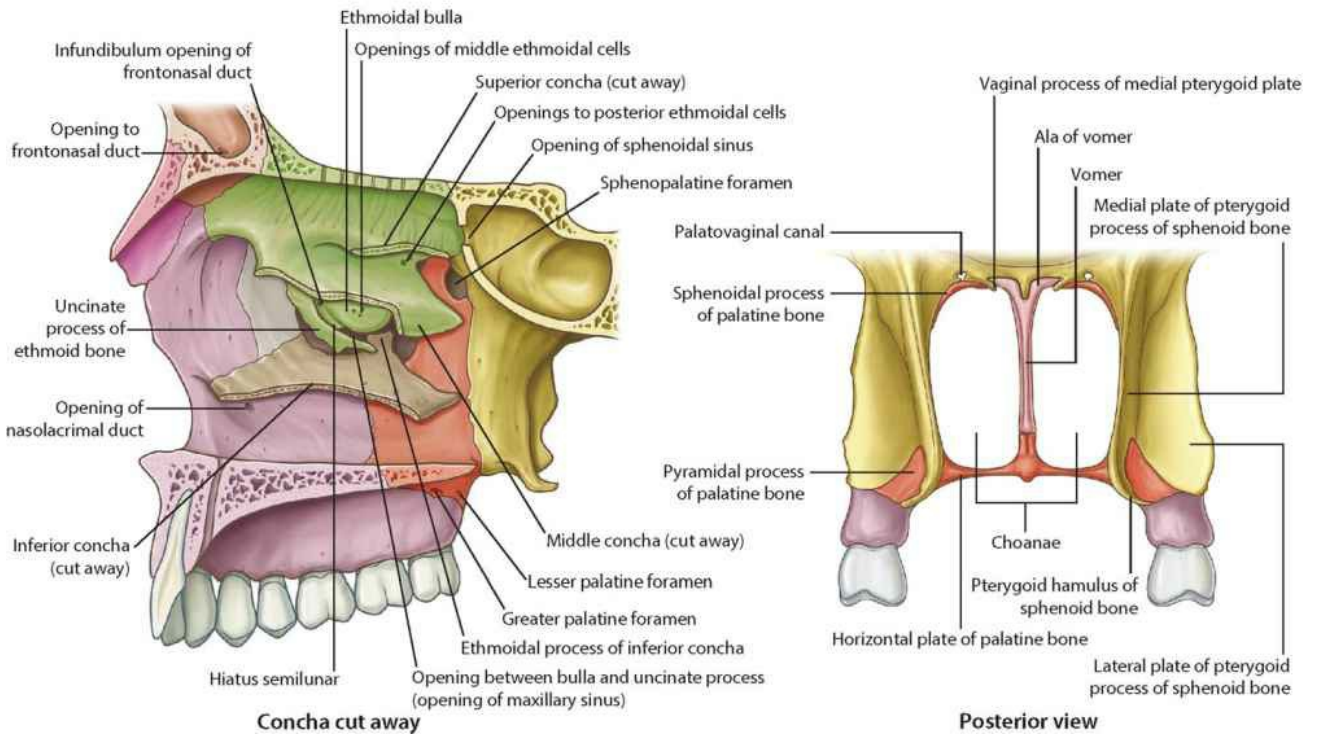
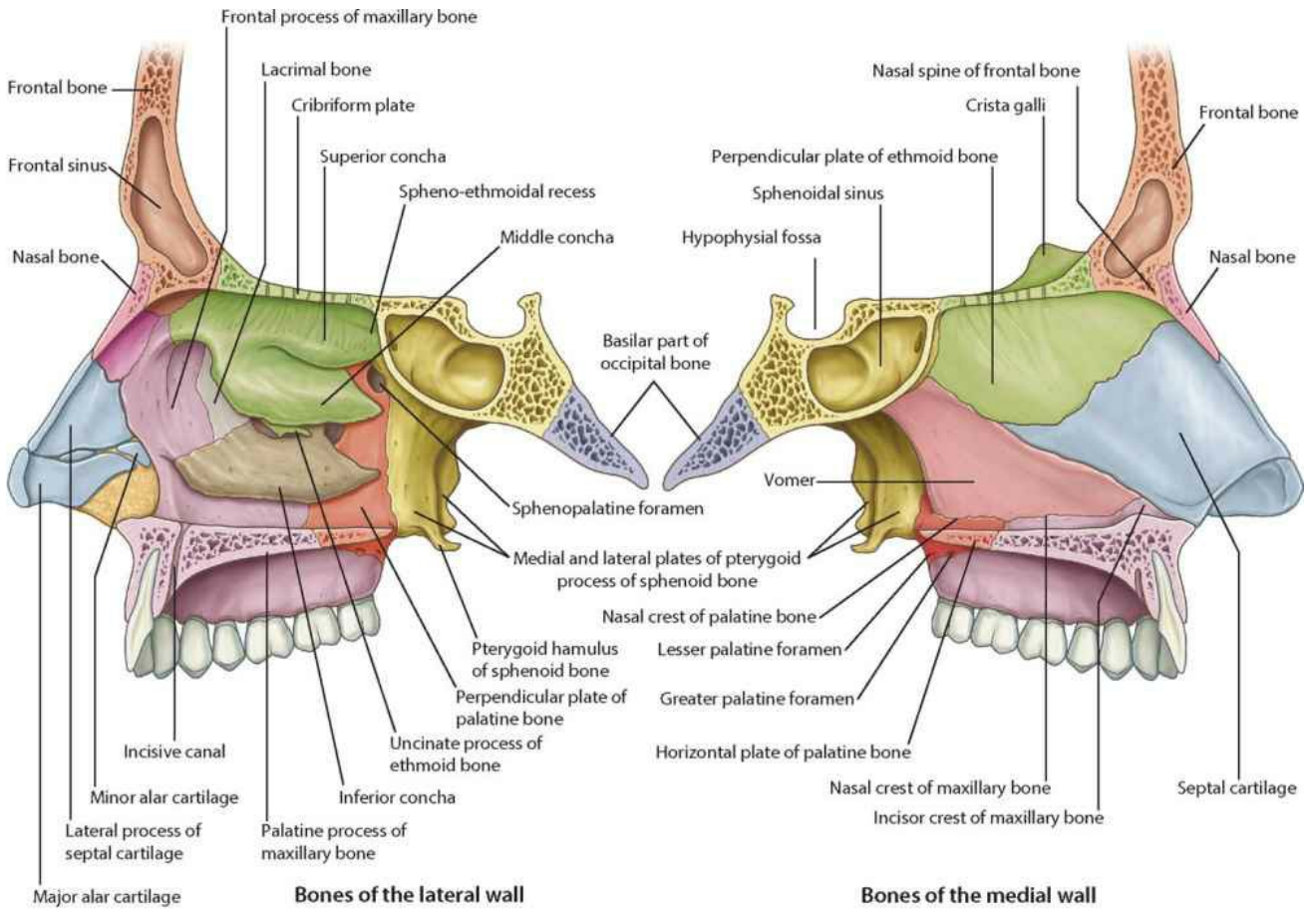


**Surface anatomy of nose and paranasal sinuses (lateral view)**

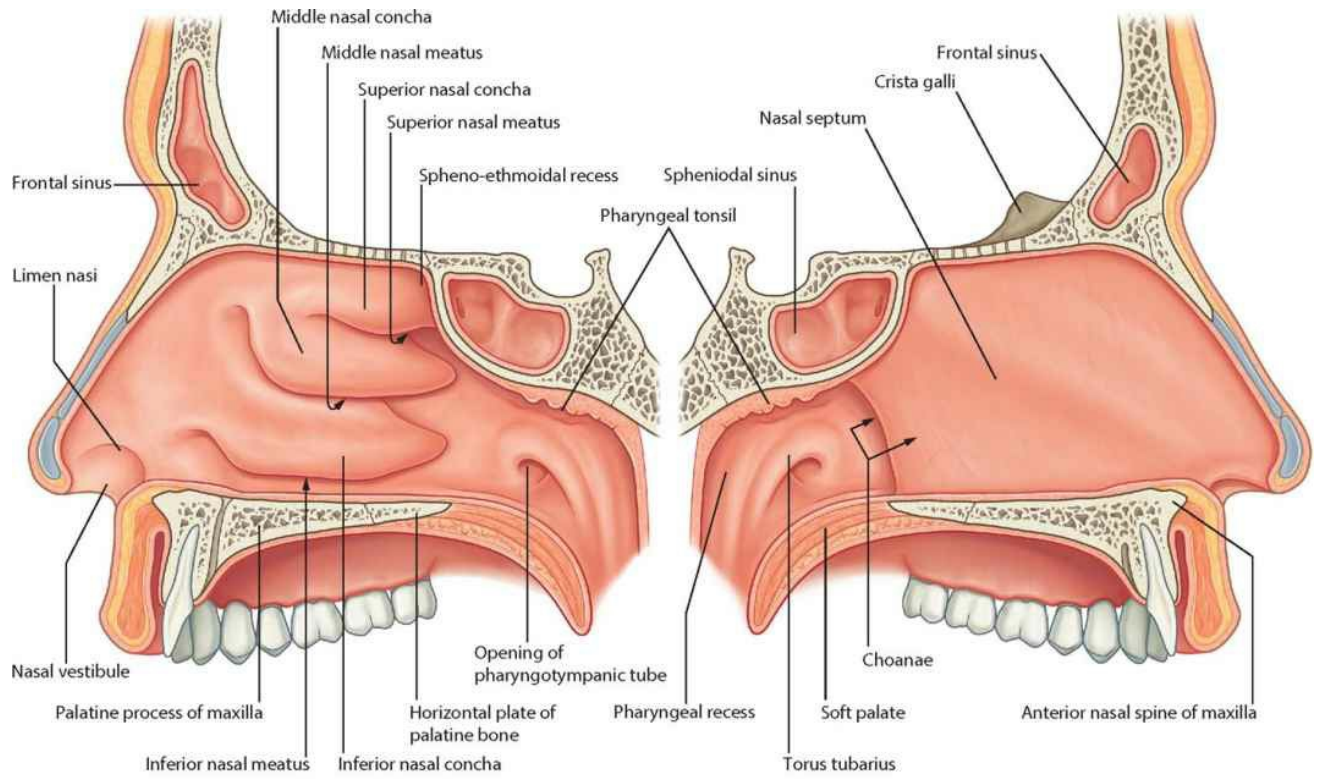


**Coronal section through nasal cavity (posterior view)**

## Nasal cavity: bones

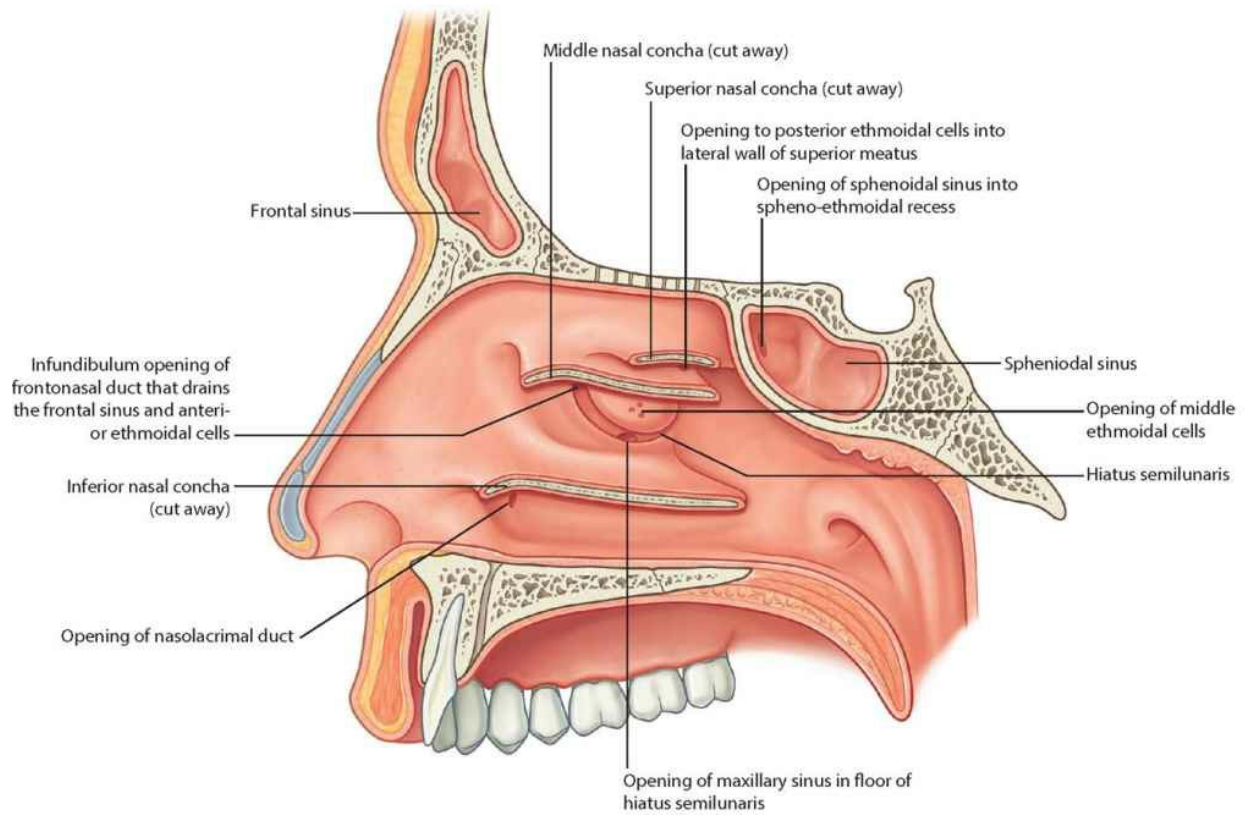


## Nasal cavity: mucosal linings



**Lateral wall of the nasal cavity**

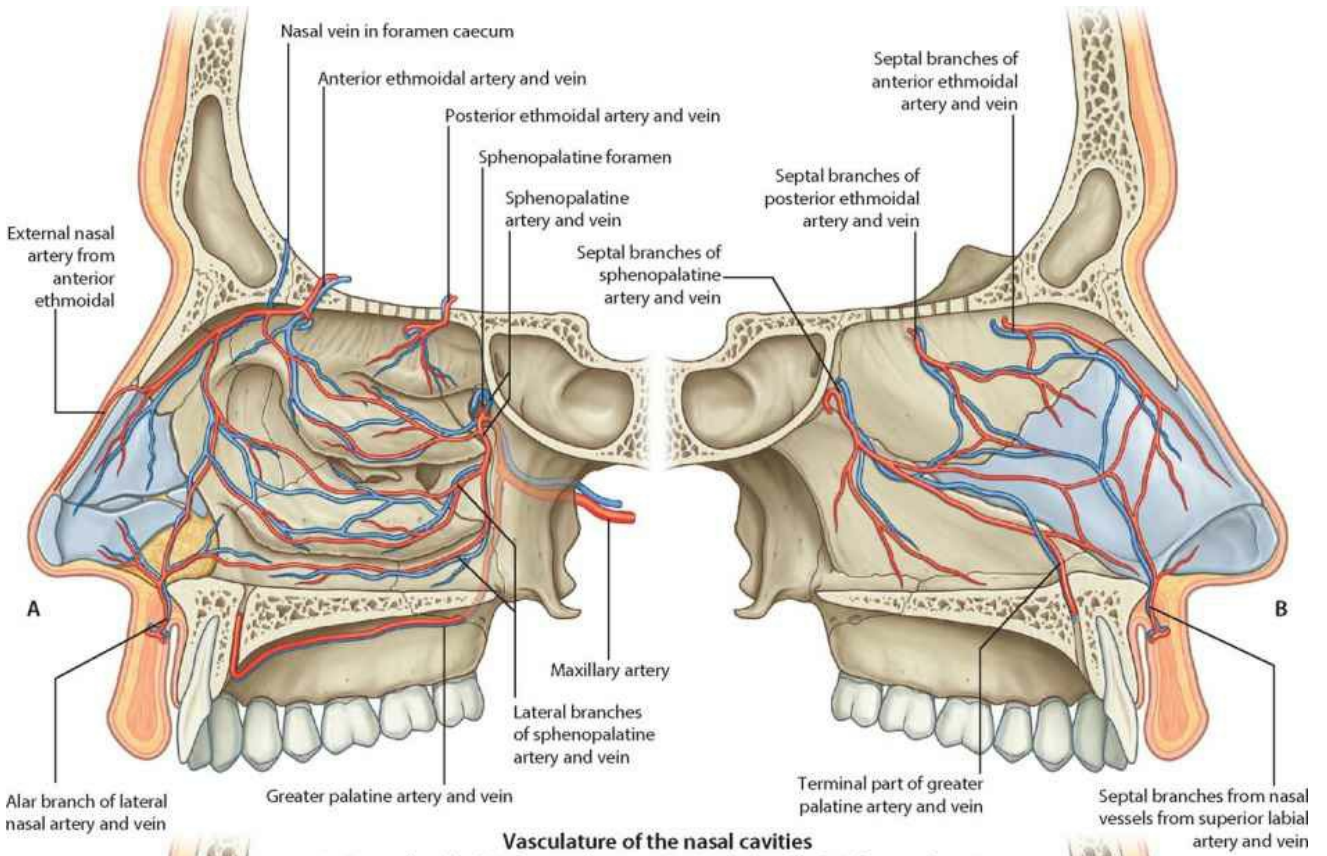
**Medial wall of the nasal cavity**



**Lateral wall of the nasal cavity, concha cut away**

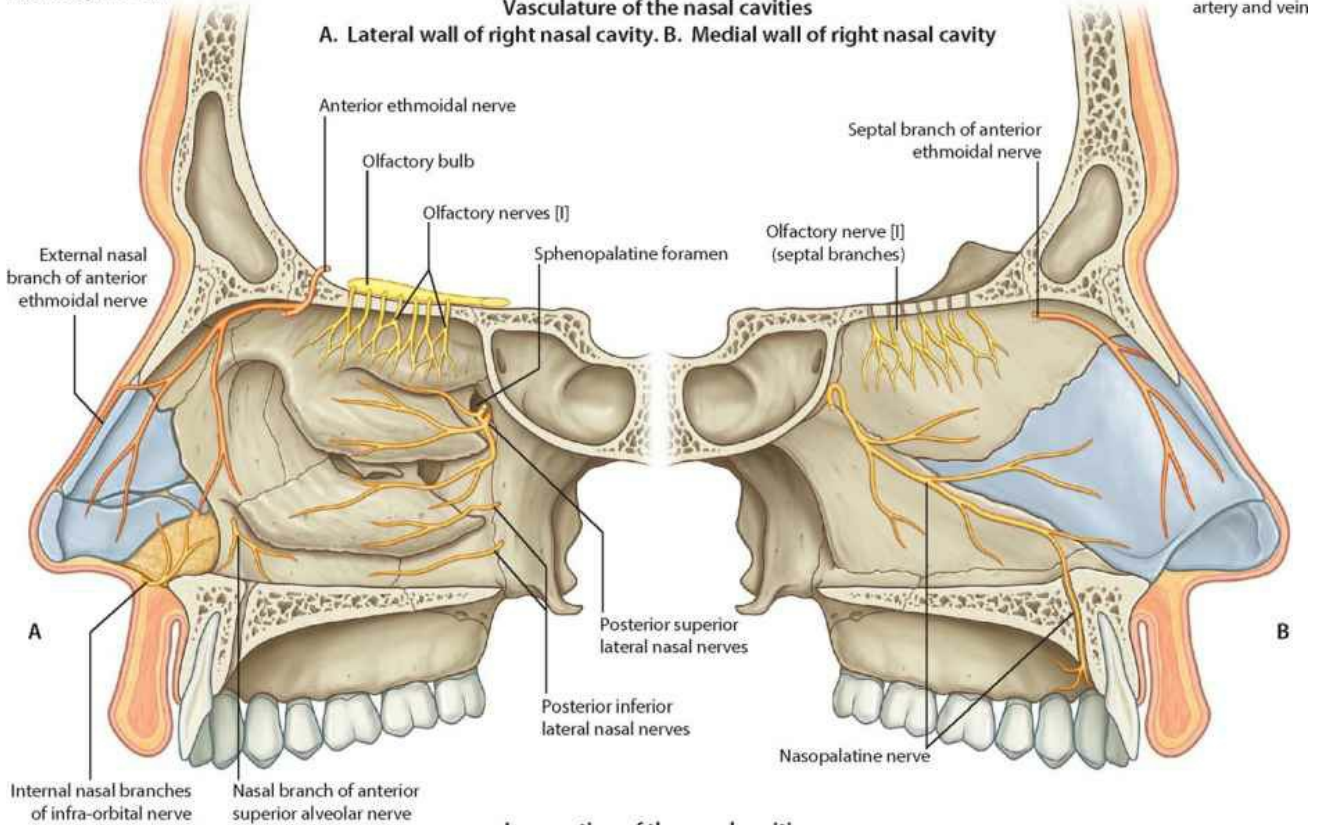
# **Vasculature and innervation of the nasal cavity**





**Vasculature of the nasal cavities**

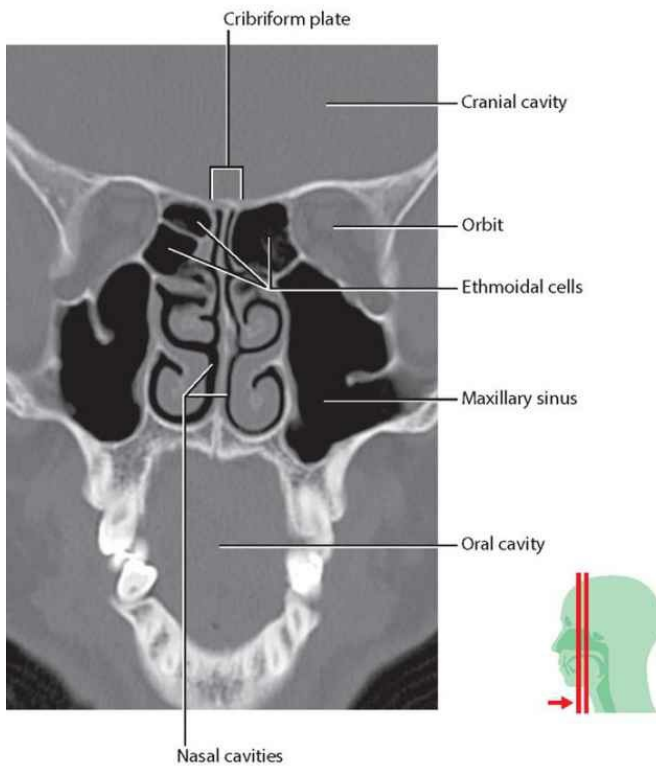
**A. Lateral wall of right nasal cavity. B. Medial wall of right nasal cavity**



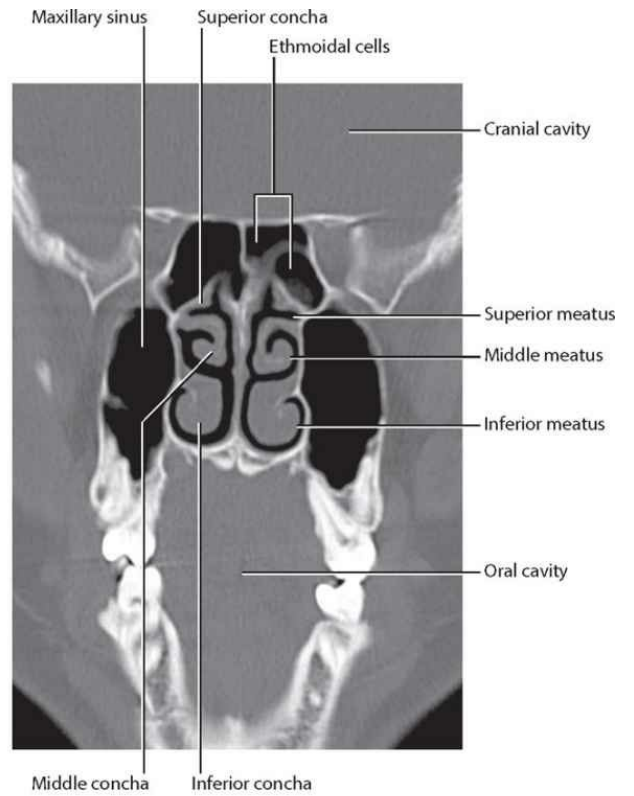
**Innervation of the nasal cavities**

**A. Lateral wall of right nasal cavity. B. Medial wall of right nasal cavity**

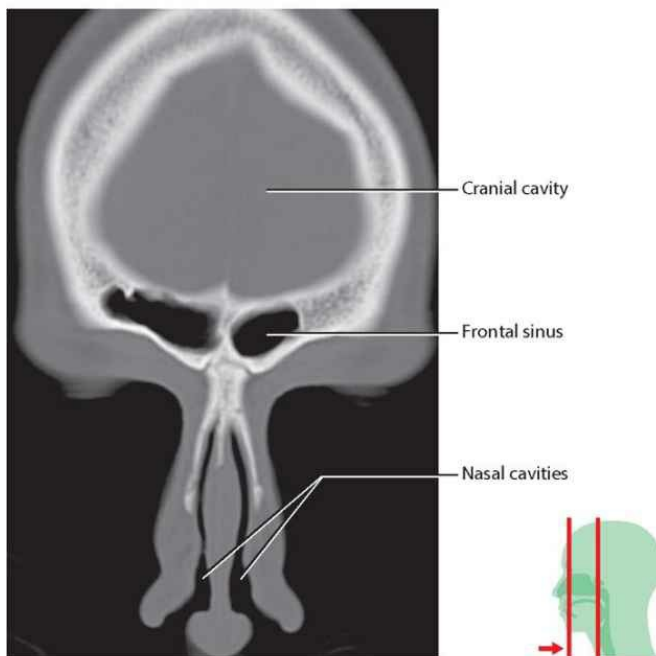
# Sinus imaging



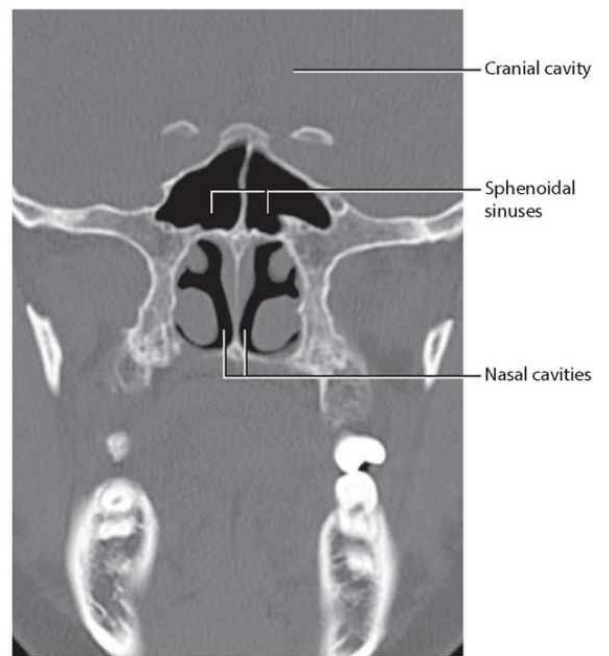
**Anterior view of the maxillary sinus and ethmoidal cells.**  
CT image in coronal plane



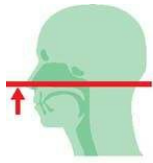
**Anterior view looking into the nasal cavity showing the relationship of various structures.**  
CT image in coronal plane



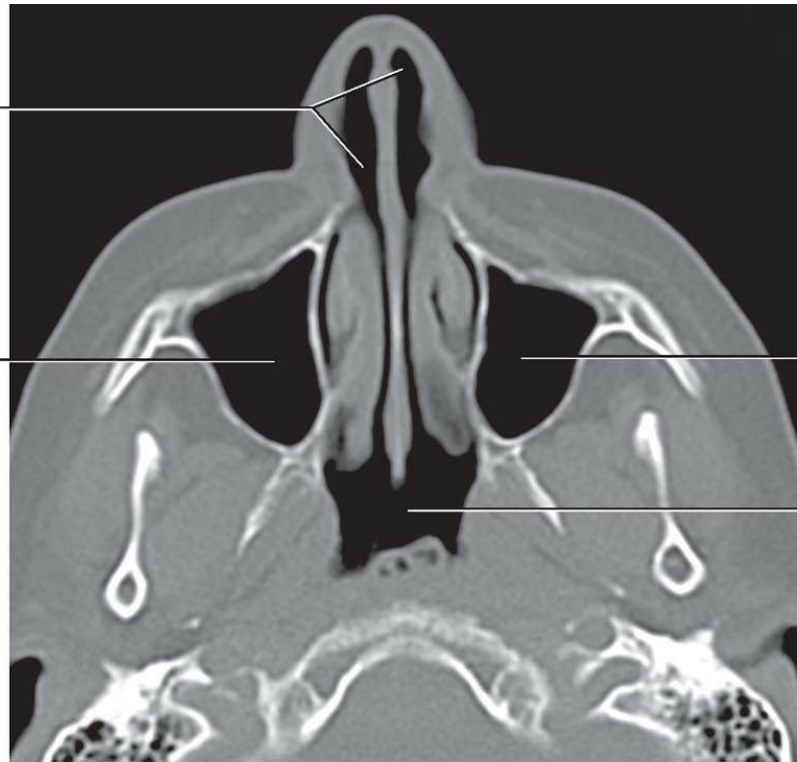**Anterior view of the frontal sinuses.**  
CT image in coronal plane



**Anterior view of the sphenoidal sinuses showing their relationship to the nasal cavity.**  
CT image in coronal plane



Nasal cavities



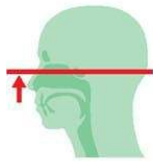
Maxillary sinus

Maxillary sinus

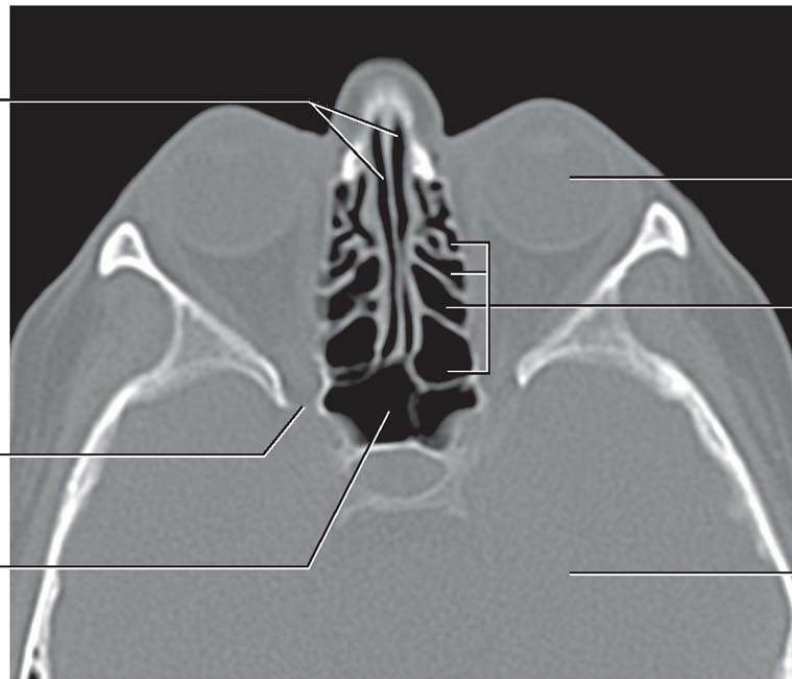
Nasopharynx

**Axial section showing the relationship between the nasal cavity, nasopharynx, and maxillary sinuses.**

CT image in axial plane



Nasal cavities



Orbit

Ethmoidal cells

Cranial cavity

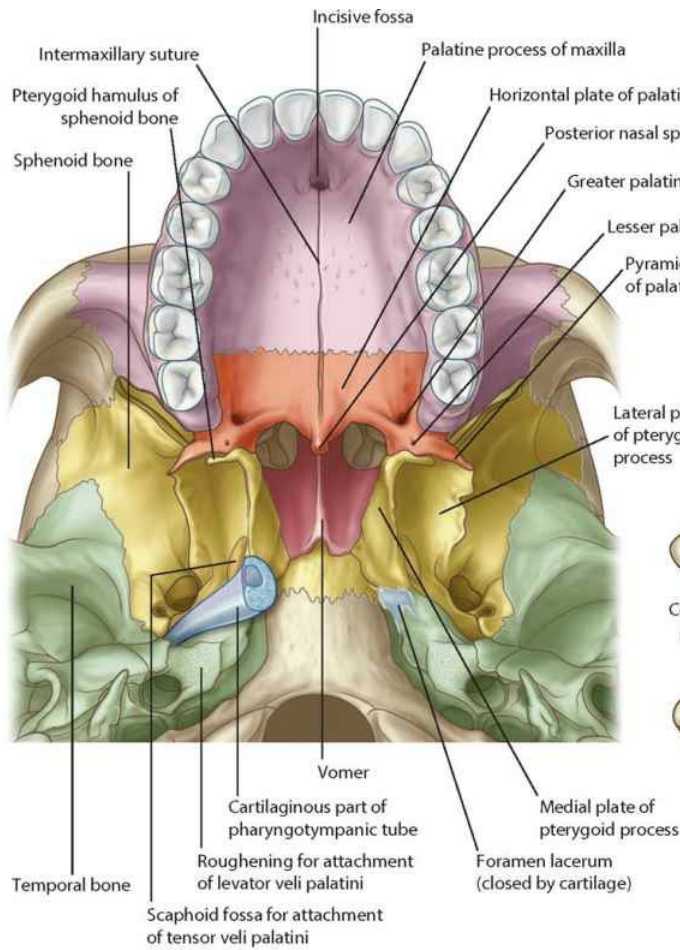
Superior orbital fissure

Sphenoidal sinus

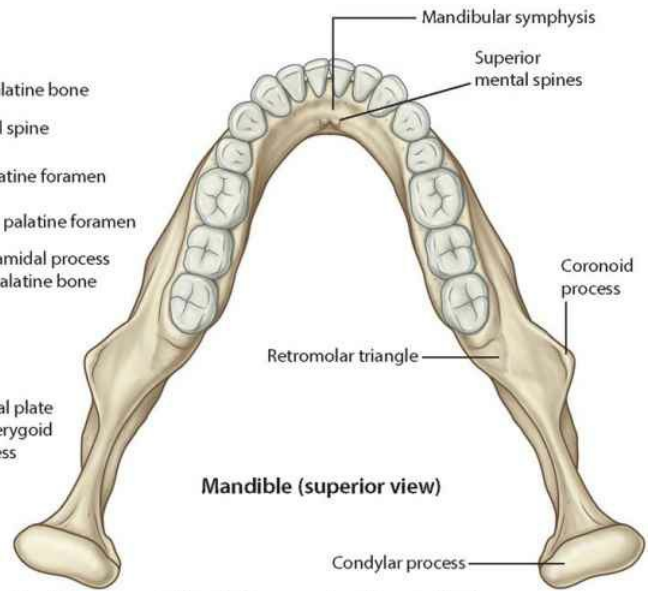
**Axial section showing the ethmoidal cells and the sphenoidal sinuses and the relationship of these structures to the orbit.**

CT image in axial plane

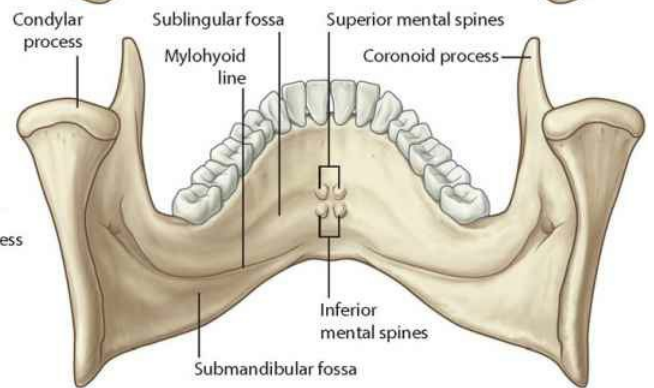
## Oral cavity: bones



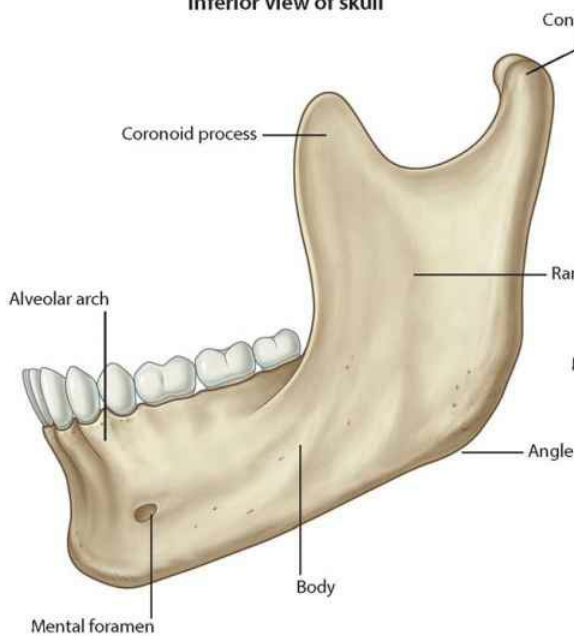
**Inferior view of skull**



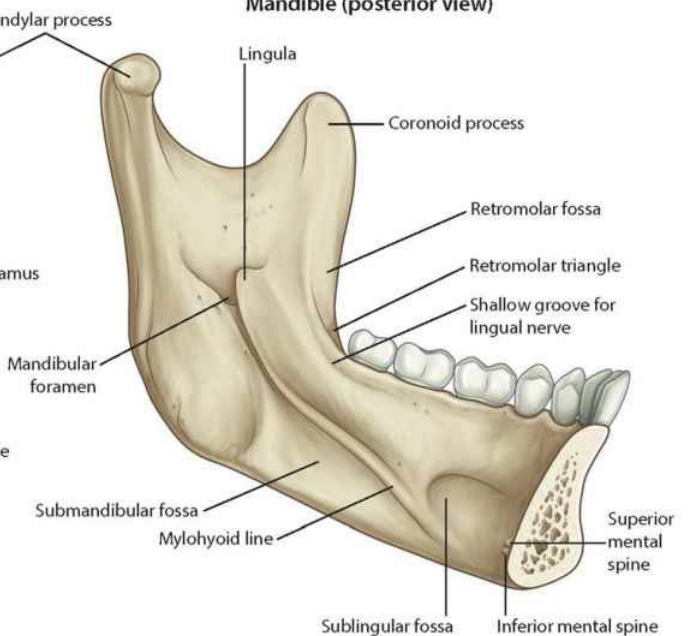
**Mandible (superior view)**



**Mandible (posterior view)**

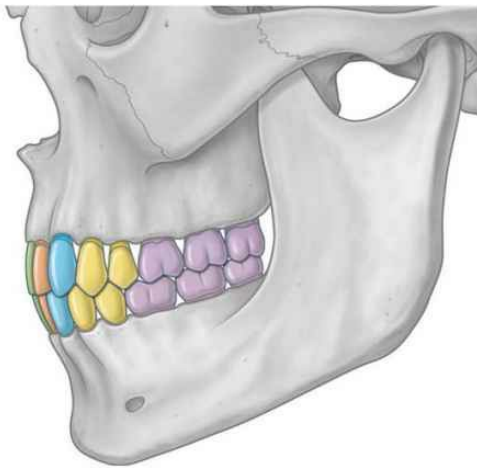


**Mandible (lateral view)**

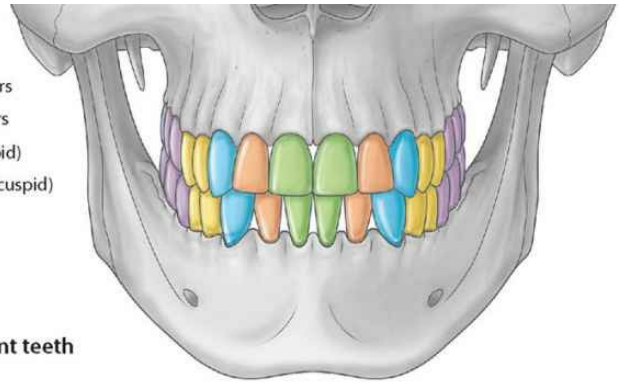


**Mandible (medial view)**

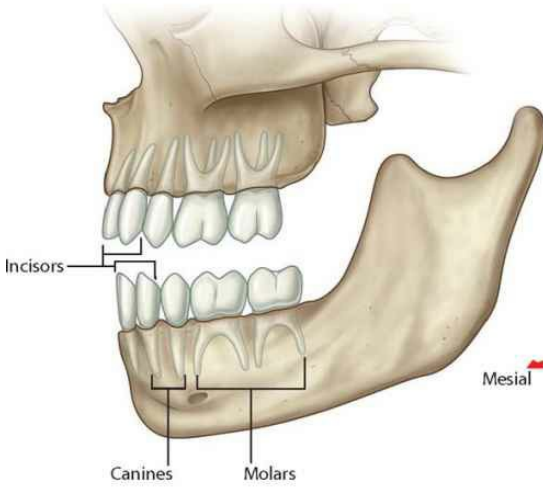
# Teeth



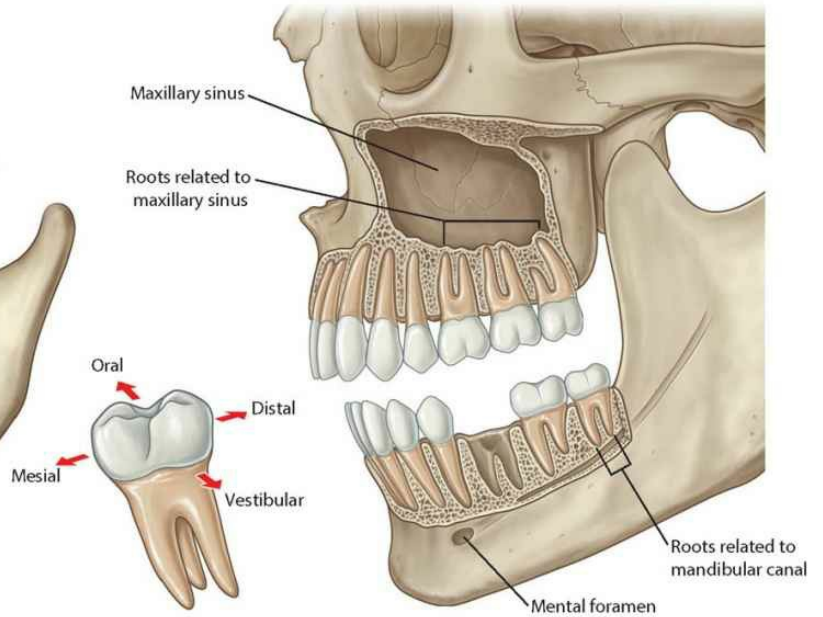
- Green Central incisors
- Orange Lateral incisors
- Blue Canines (cuspid)
- Yellow Premolars (bicuspid)
- Purple Molars



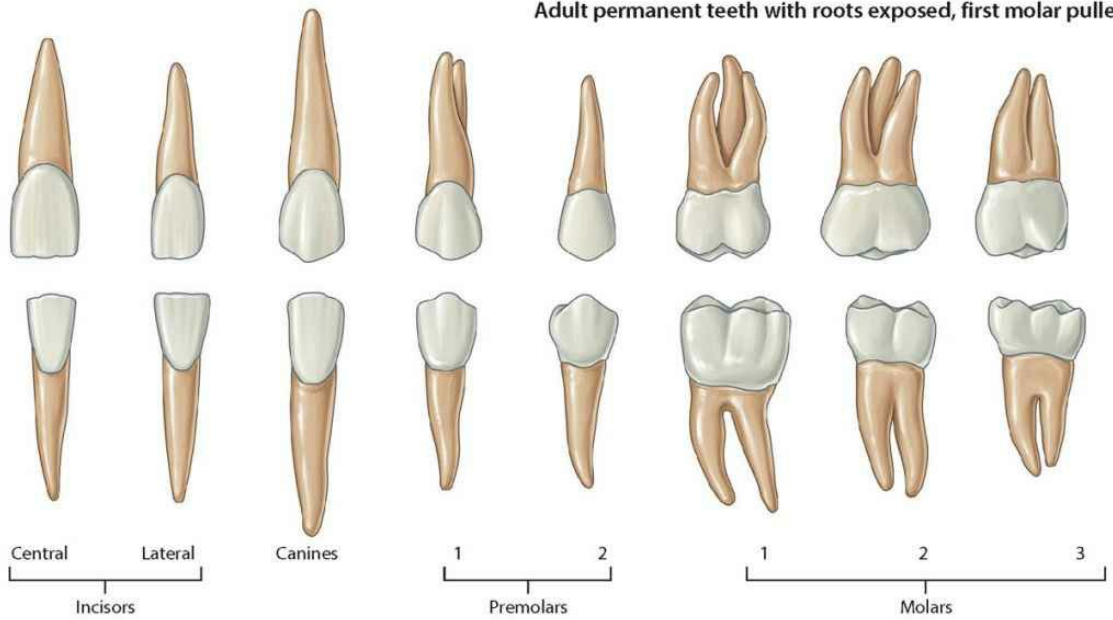
Adult permanent teeth



Deciduous (baby) teeth



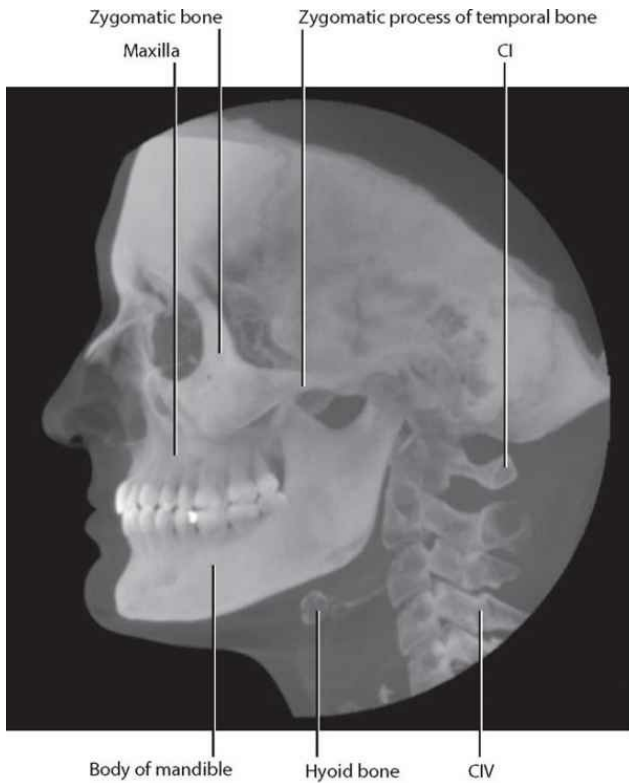
Adult permanent teeth with roots exposed, first molar pulled out



Adult upper and lower permanent teeth (vestibular view)

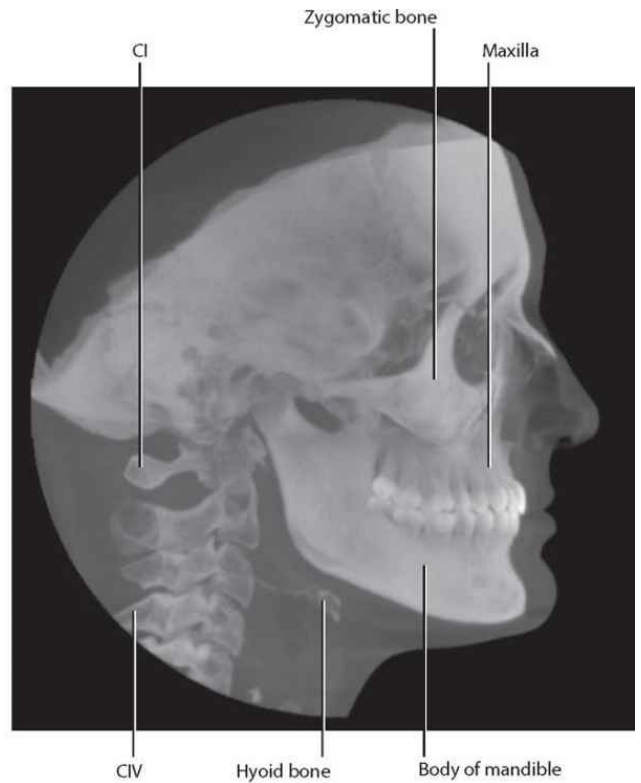


# Teeth: imaging



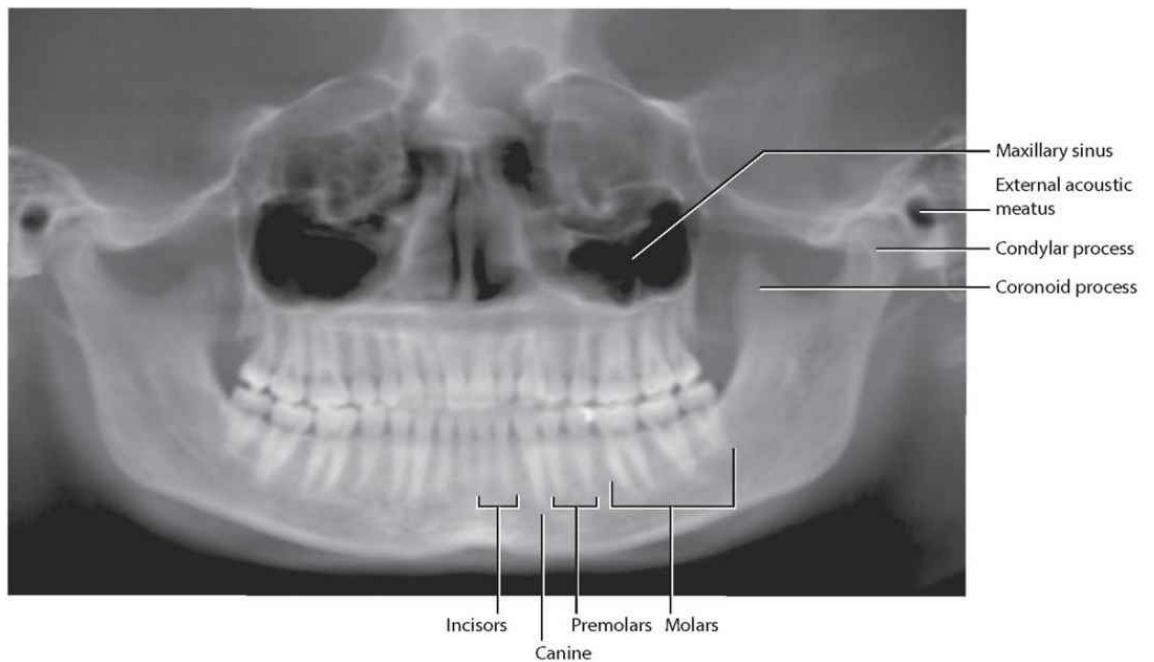
**View of the left side of the face showing the craniofacial structures including the teeth.**

Image taken with Cone Beam Computerized Tomography (CBCT) technology, viewed in the Maximum Intensity Projection (MIP) mode, which combines a radiographic view with a view of surface structures



**View of the right side of the face showing the craniofacial structures including the teeth.**

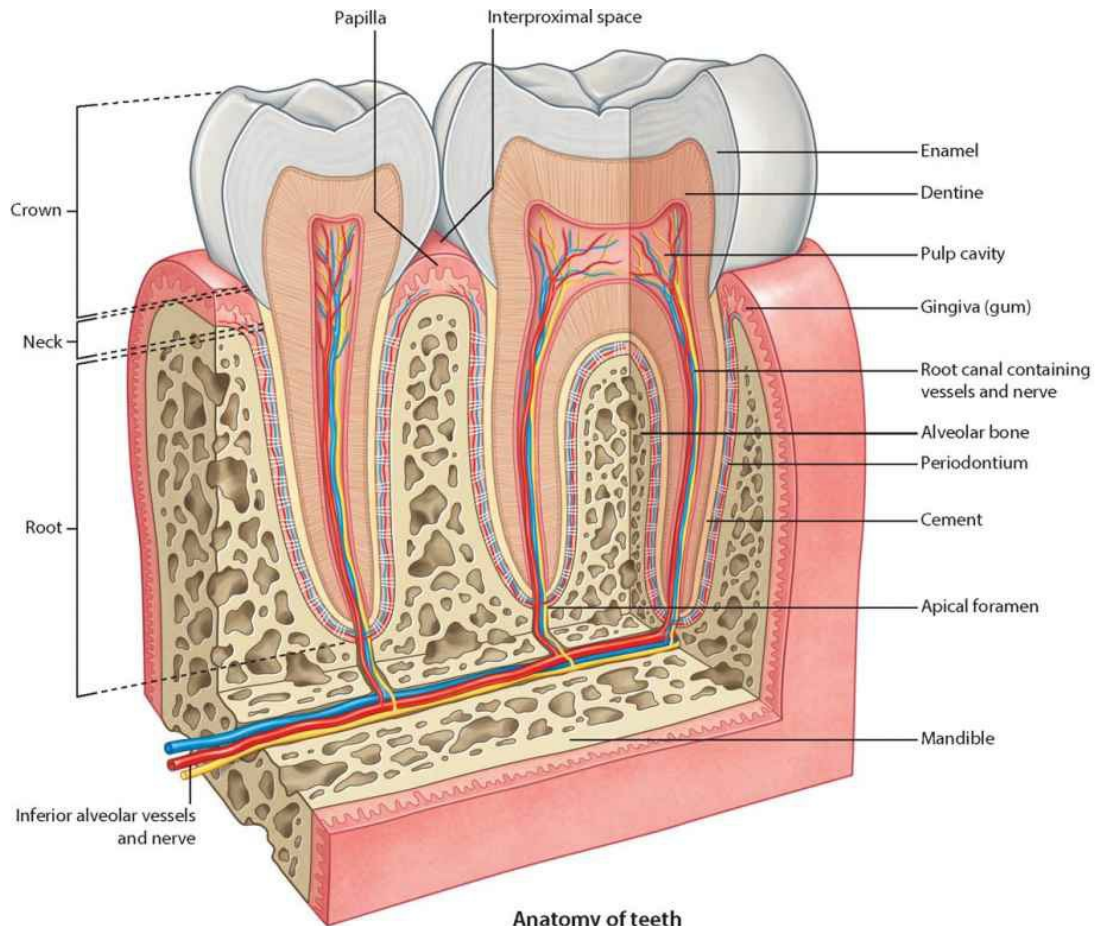
Image taken with Cone Beam Computerized Tomography (CBCT) technology, viewed in the Maximum Intensity Projection (MIP) mode, which combines a radiographic view with a view of surface structures



**Panoramic view of the teeth (dentition), which also shows the maxillary sinuses and mandibular condylar processes.**

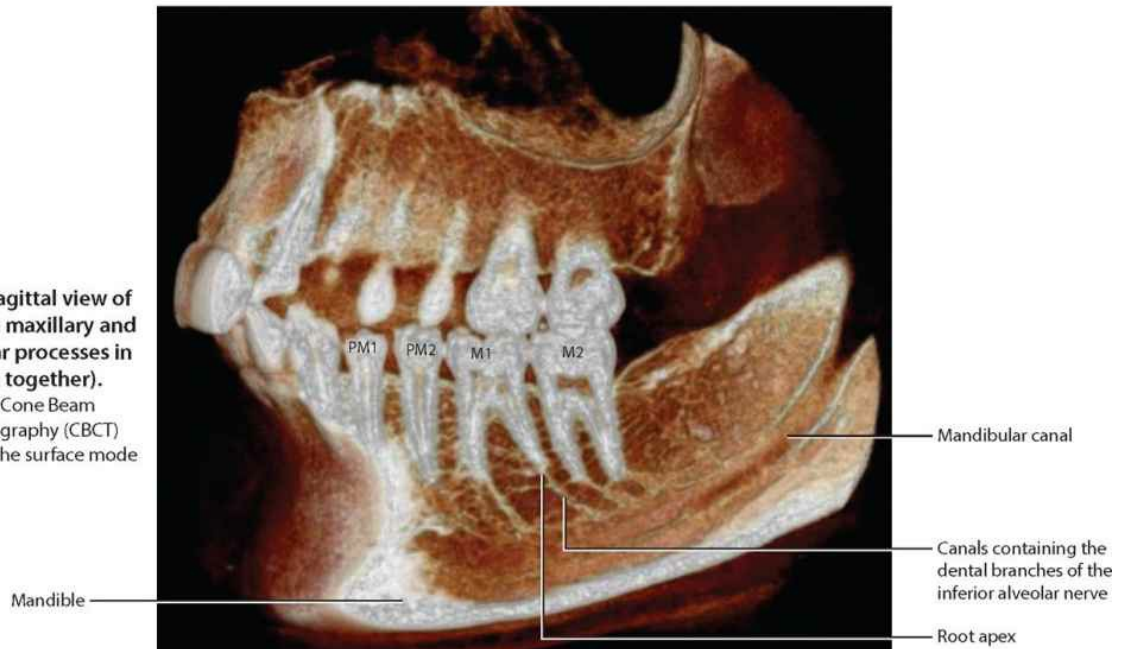
Image taken with Cone Beam Computerized Tomography (CBCT) technology

# Anatomy of teeth

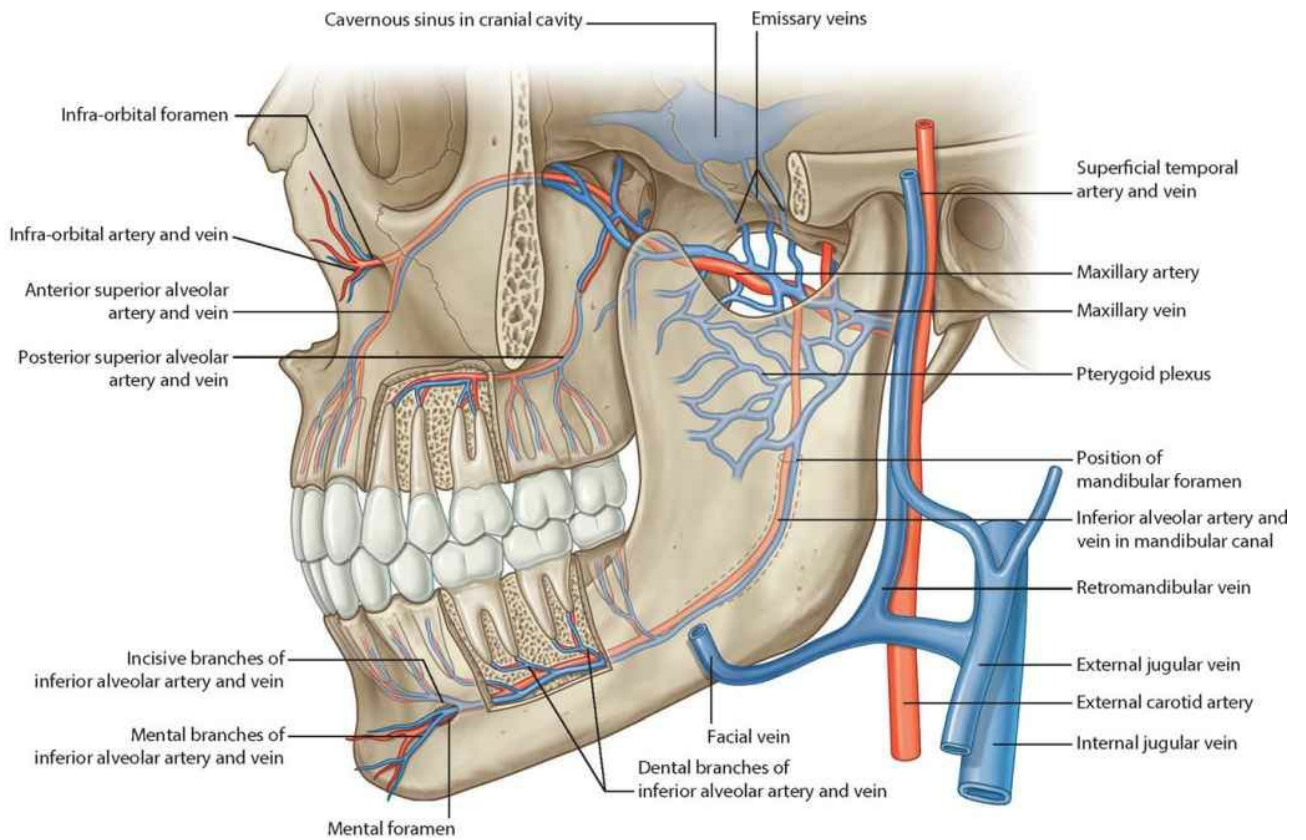


Anatomy of teeth

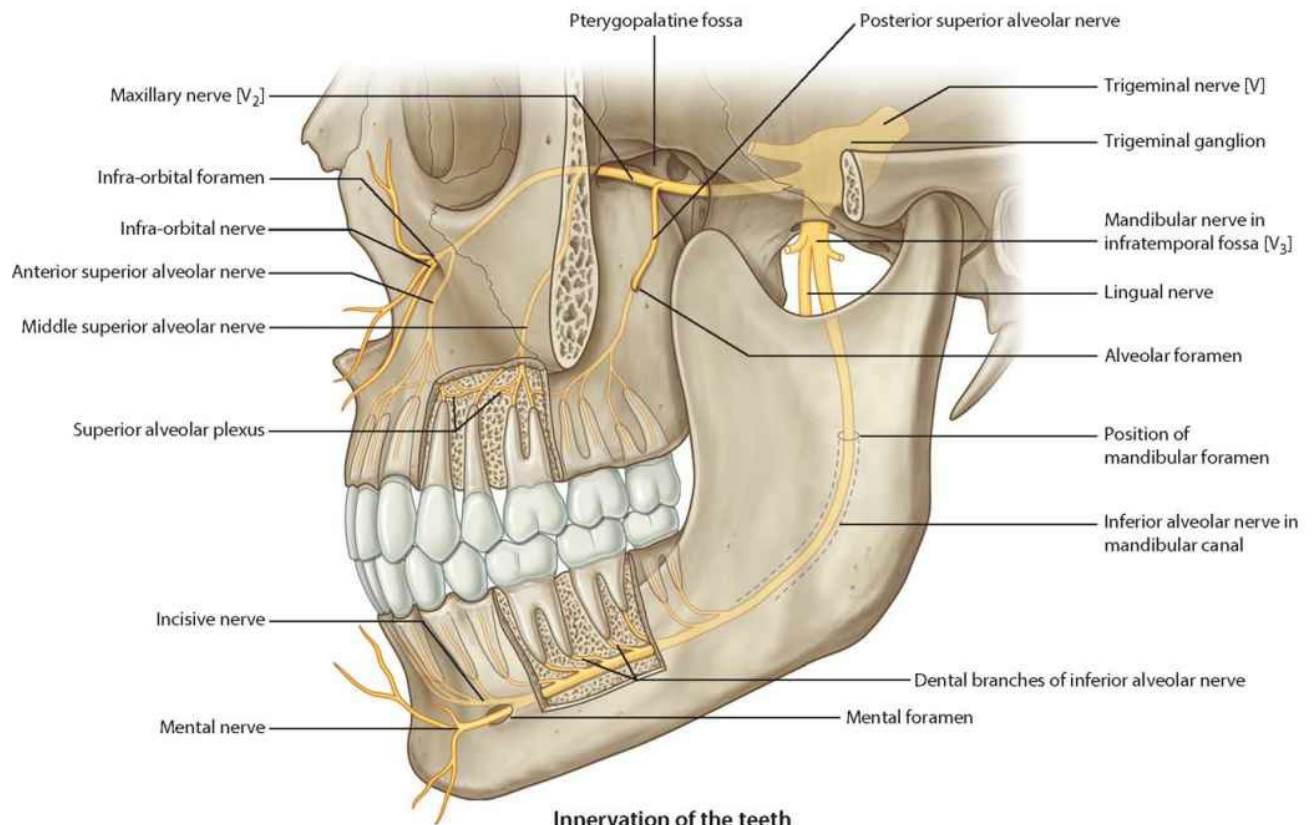
Inside, lingual or sagittal view of the right side of the maxillary and mandibular alveolar processes in occlusion (teeth together). Image taken with Cone Beam Computerized Tomography (CBCT) technology viewed in the surface mode



# Vessels and nerves supplying teeth

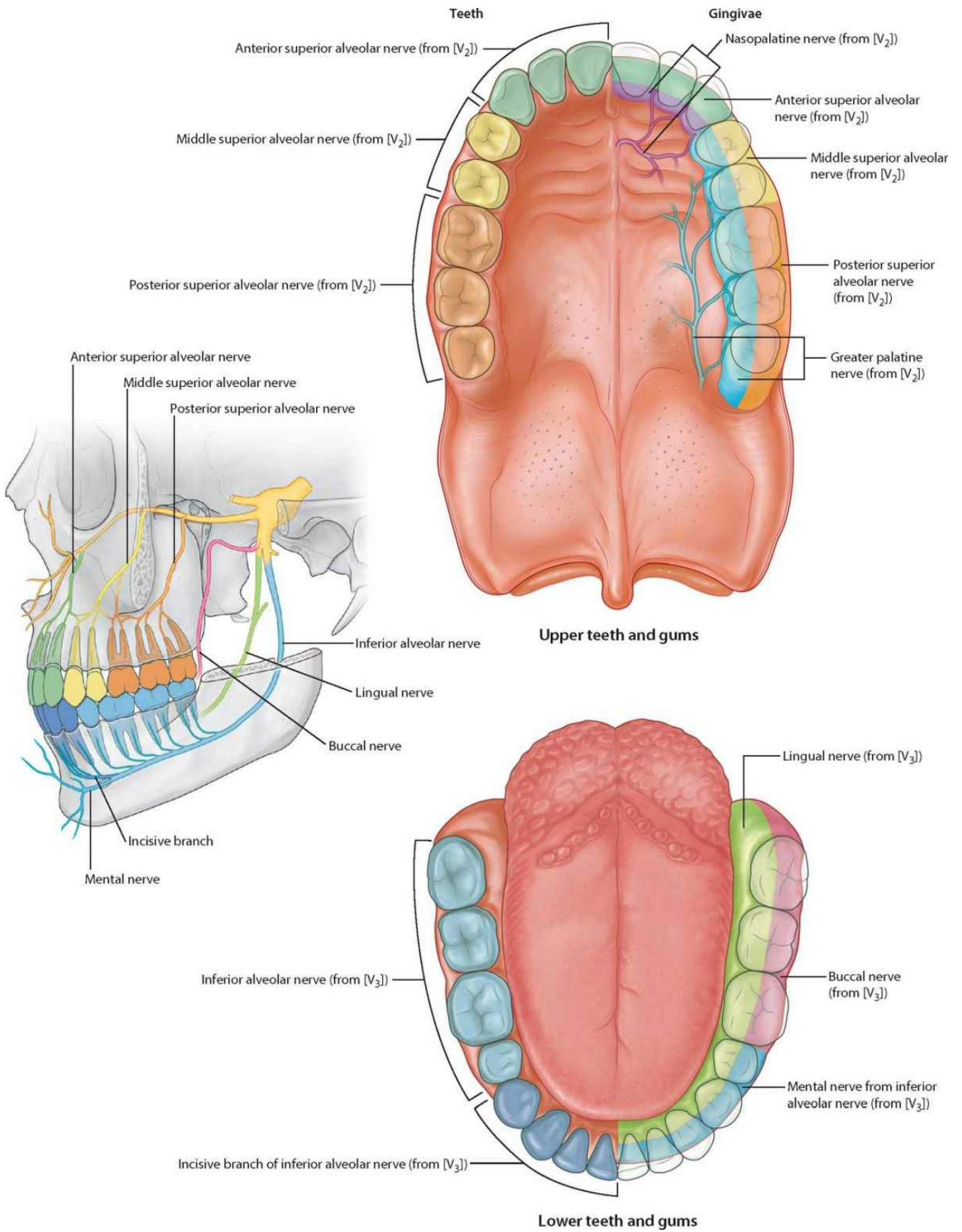


**Arteries and veins supplying teeth**



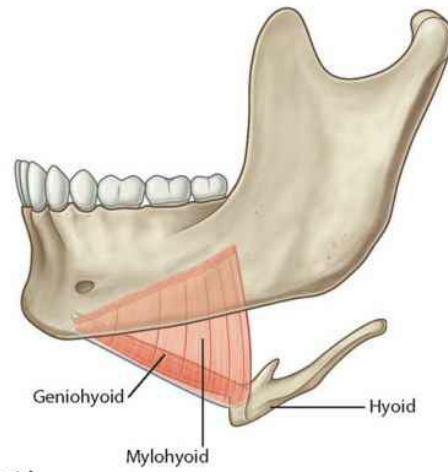
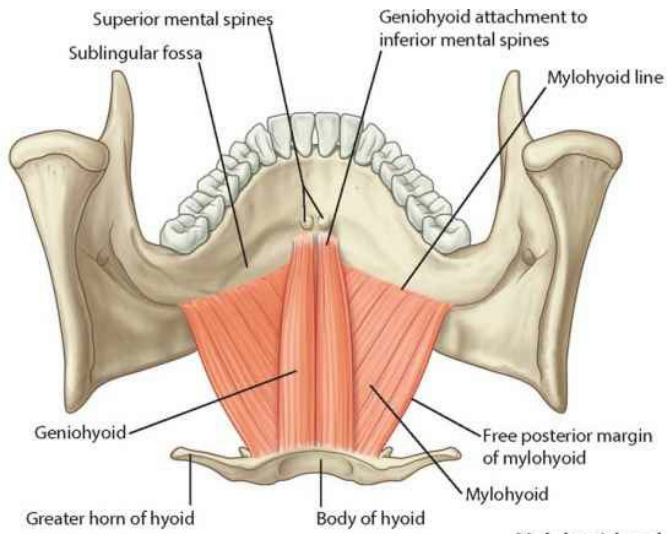
**Innervation of the teeth**

# Innervation of teeth and gums

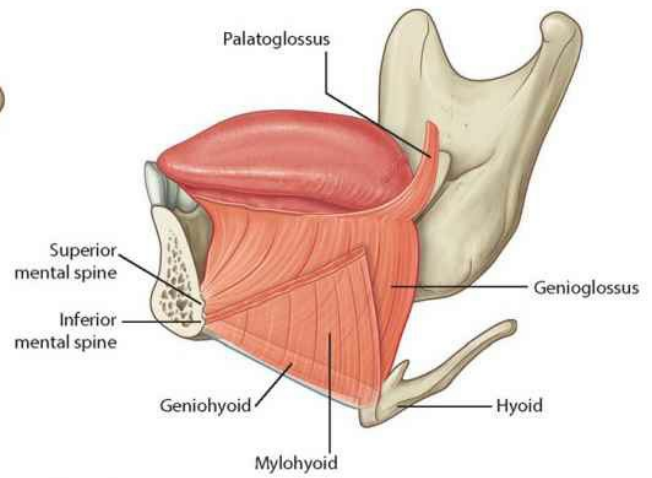
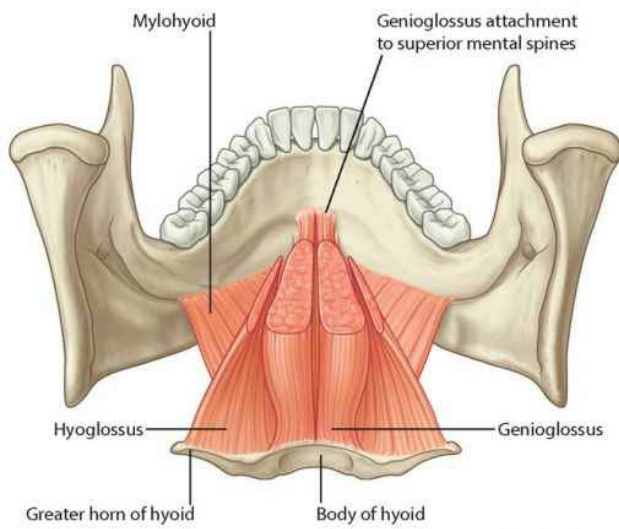




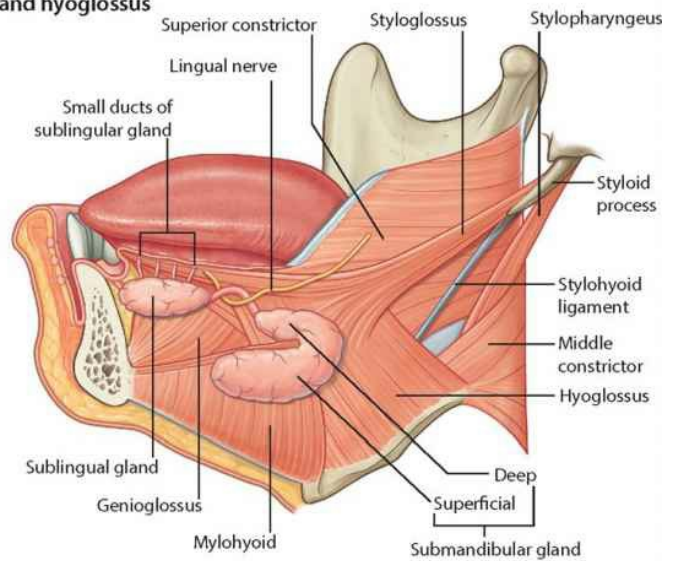
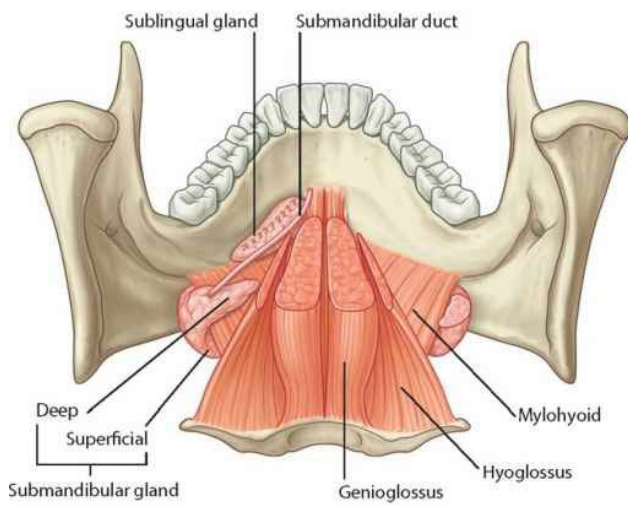
# **Muscles and salivary glands of the oral cavity**



**Mylohyoid and geniohyoid**



**Genioglossus and hyoglossus**

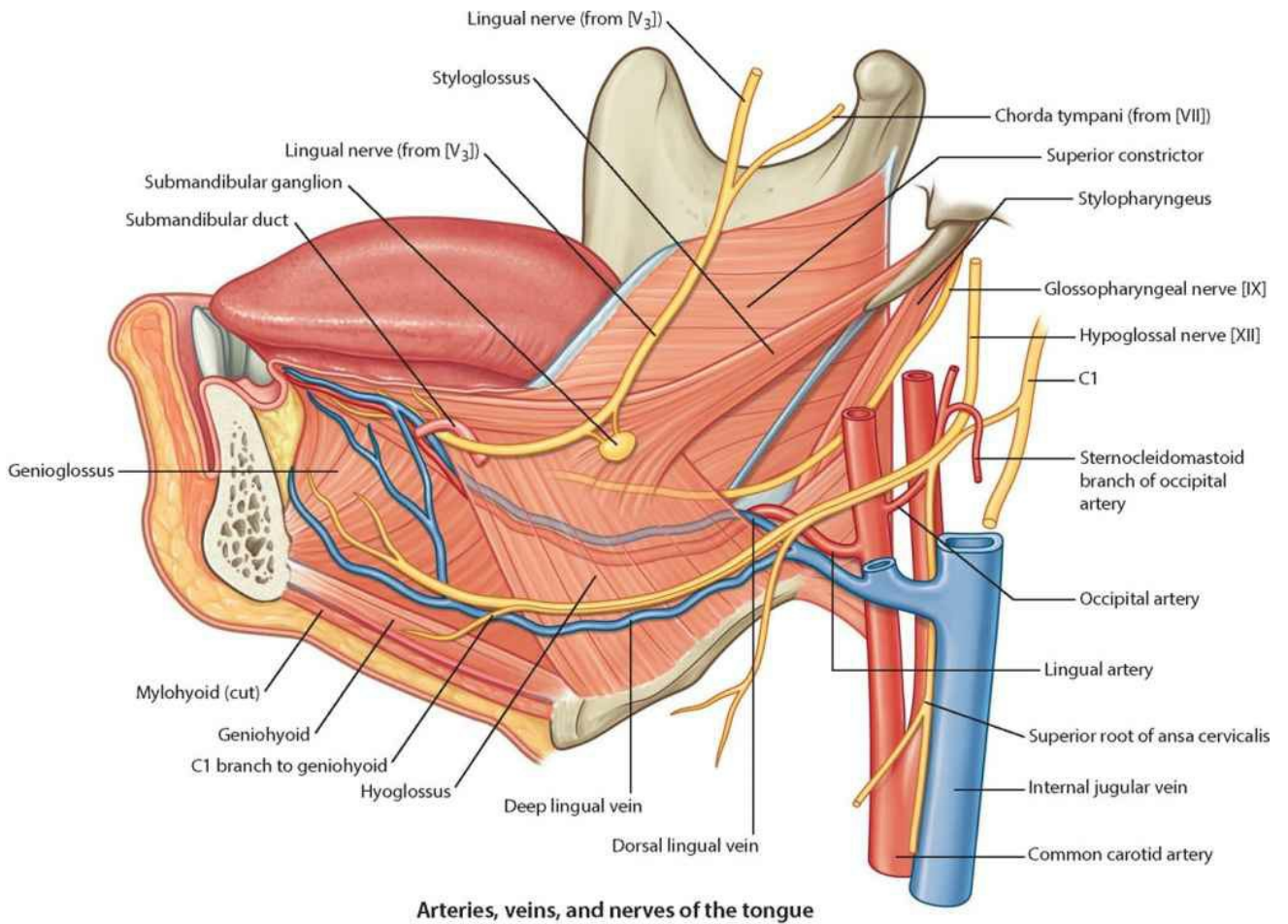


**Posterior view**

**Submandibular and sublingual glands**

**Lateral view**

# Vessels and nerves of the tongue

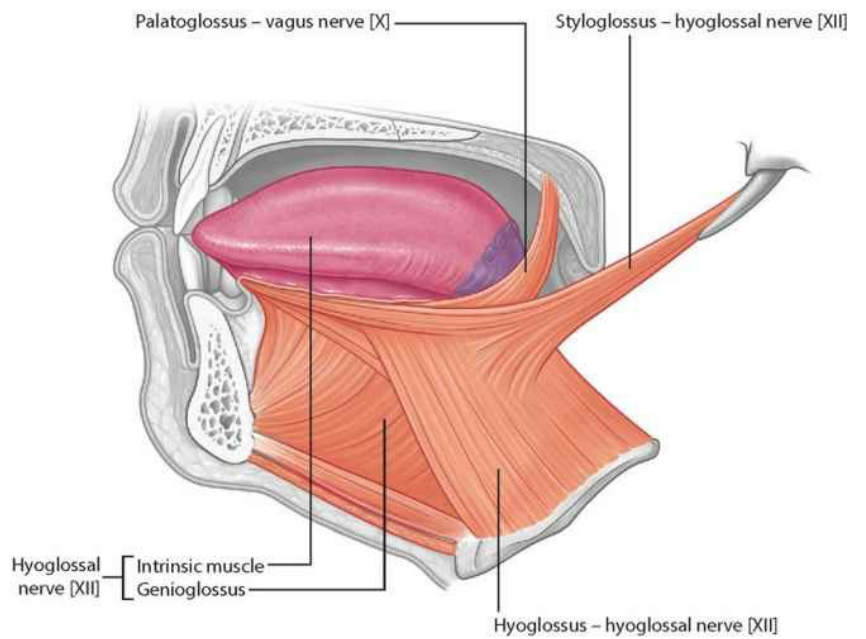


**Arteries, veins, and nerves of the tongue**

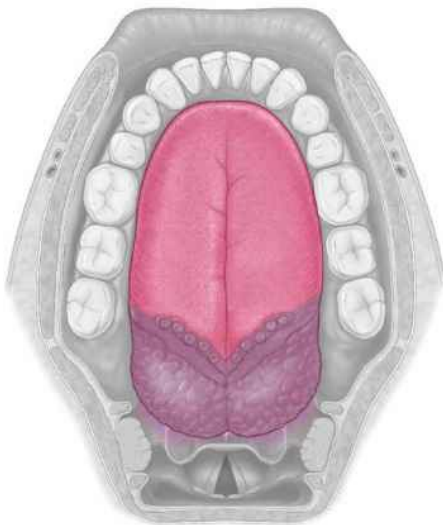
**Sensory**

- Anterior two-thirds (oral)
  - general sensation
  - Mandibular nerve [V3] via lingual nerve
  - special sensation (taste)
  - Facial nerve [VII] via chorda tympani
- Posterior one-third (pharyngeal)
  - general and special sensation (taste)
  - Glossopharyngeal nerve [IX]

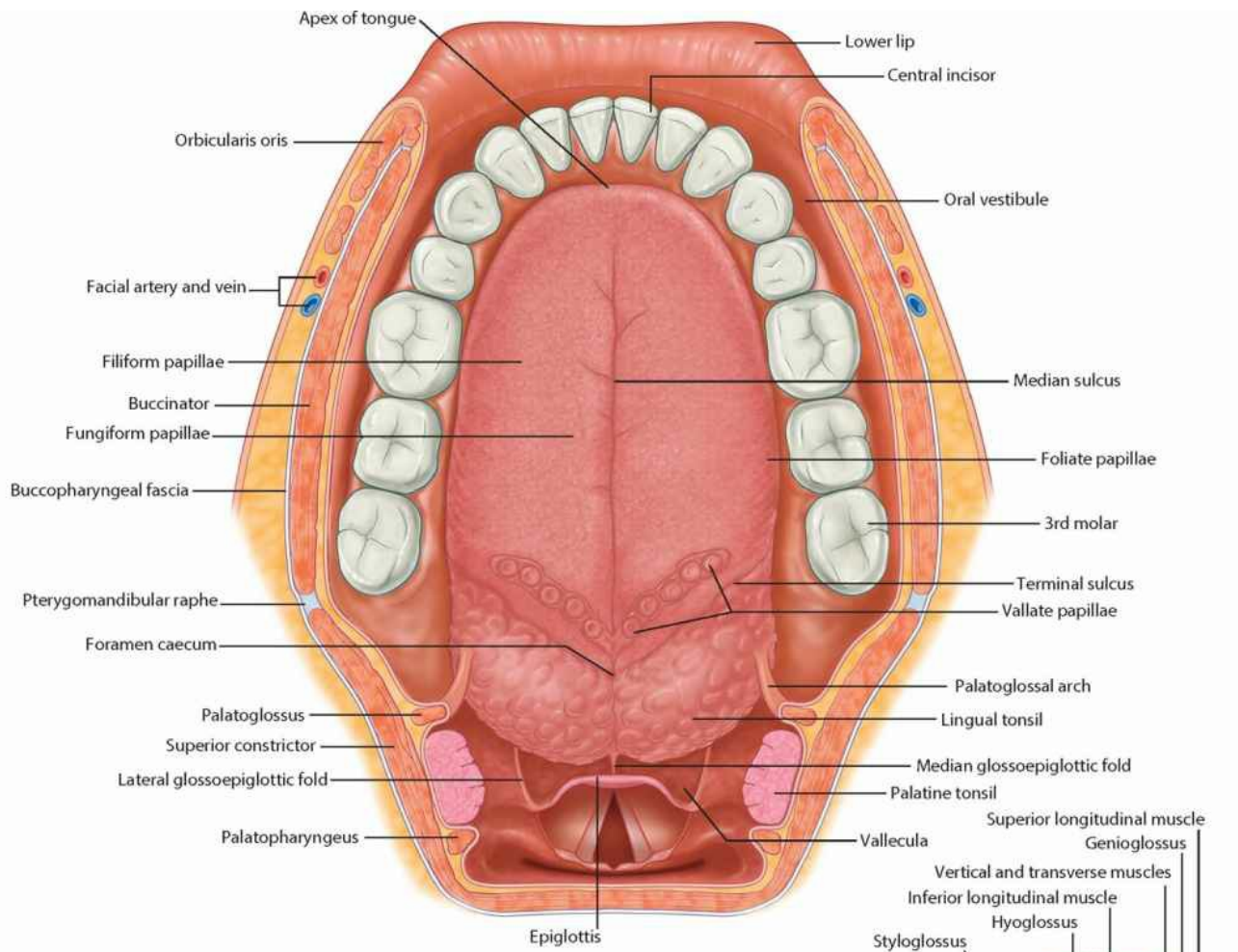
**Motor**



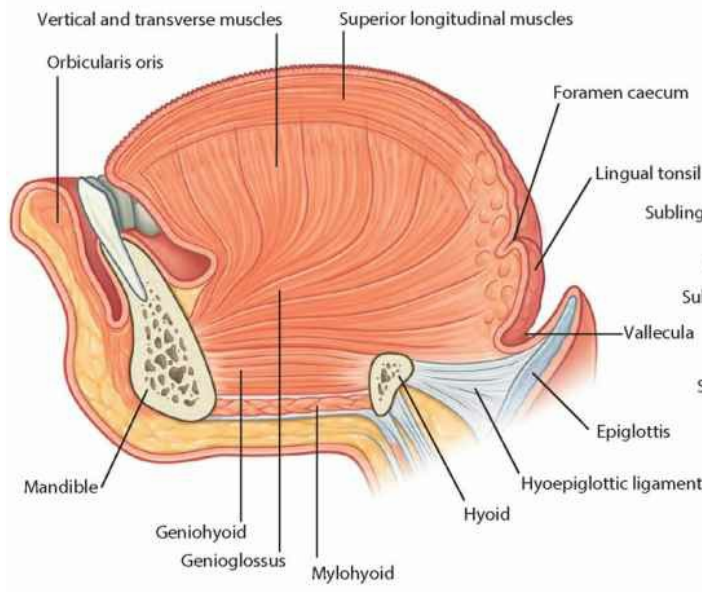
**Innervation of the tongue**



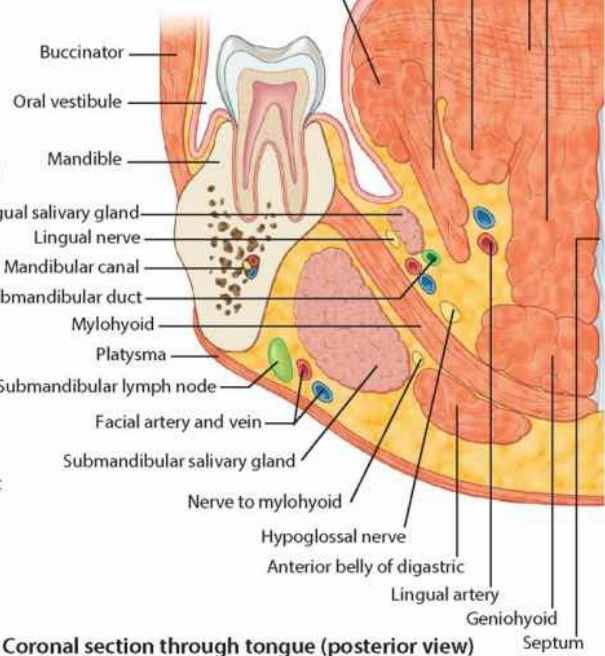
# Tongue



**Horizontal section showing superior view of tongue**

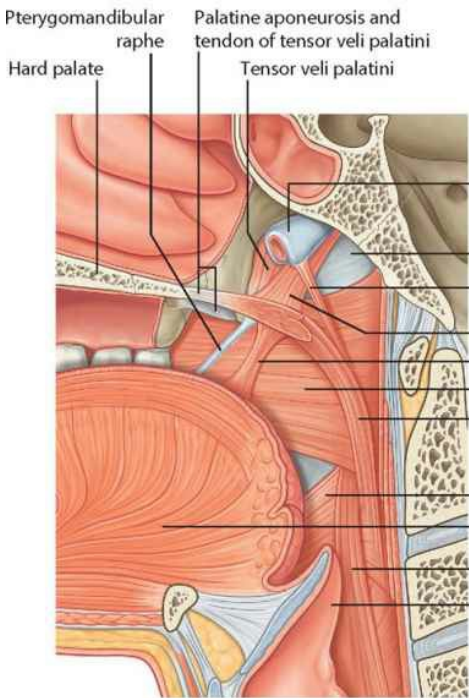
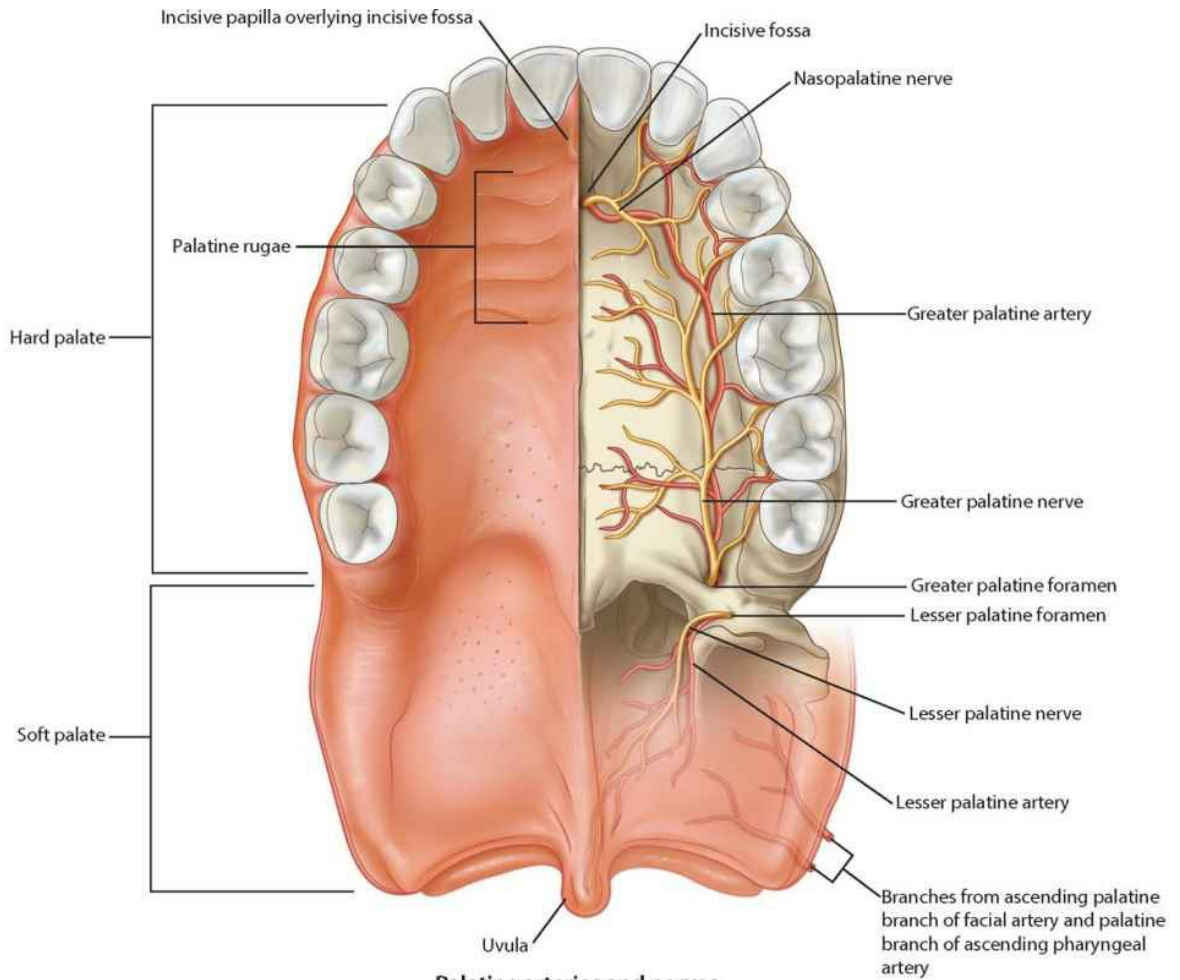


**Paramedian sagittal section through tongue**

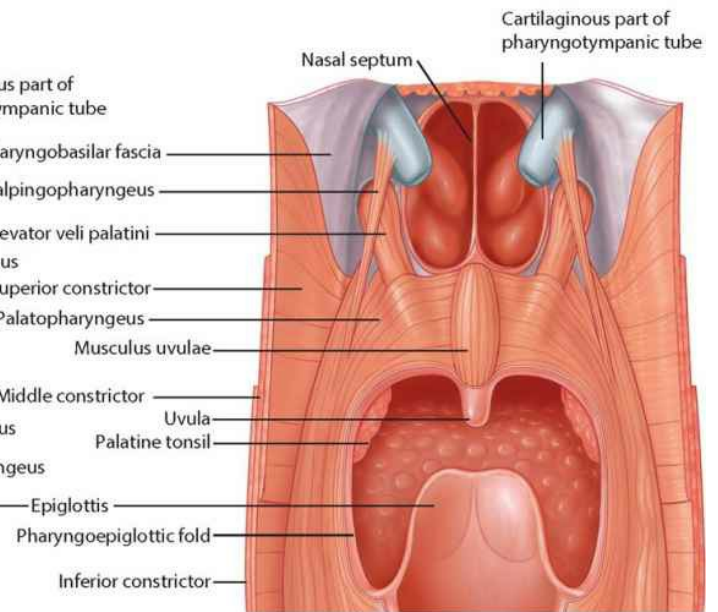


**Coronal section through tongue (posterior view)**

## Hard and soft palate



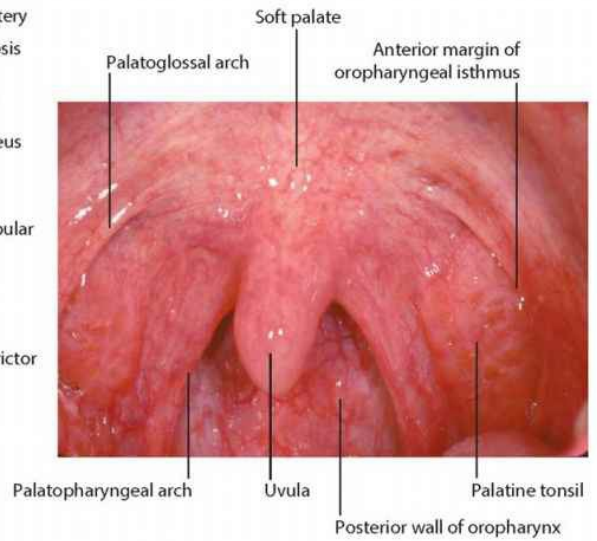
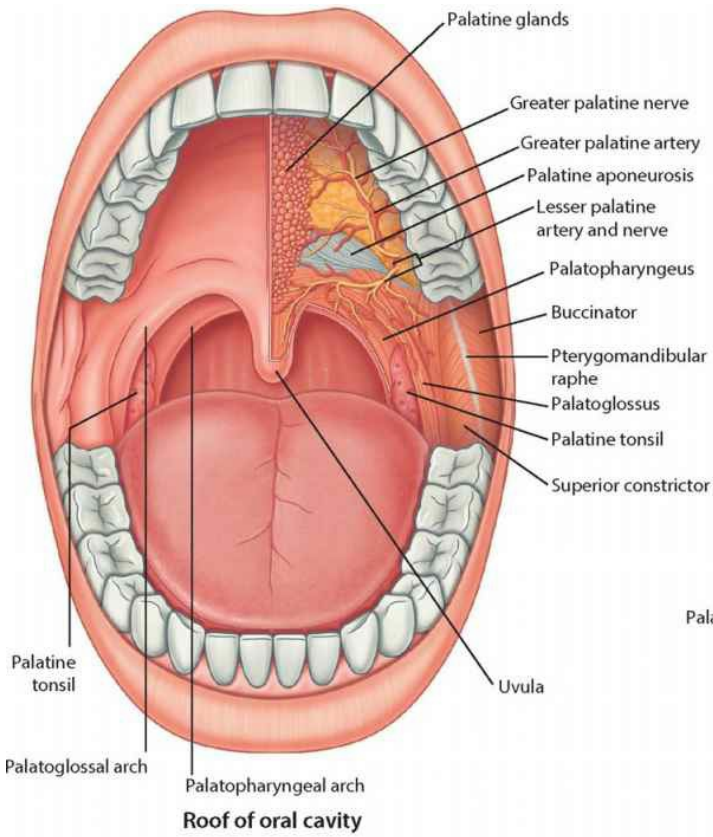
**Muscles of the soft palate (sagittal section)**



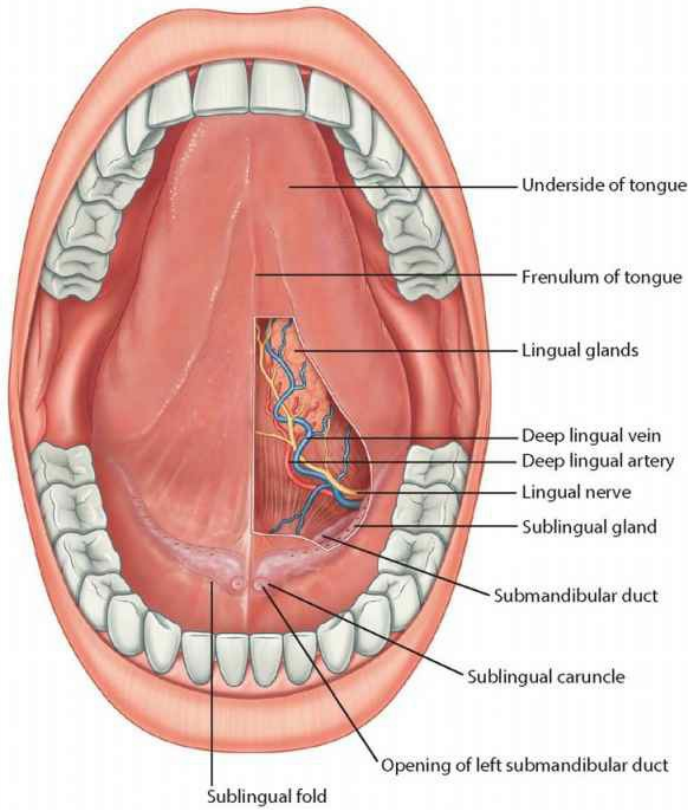
**Muscles of the soft palate (posterior view)**



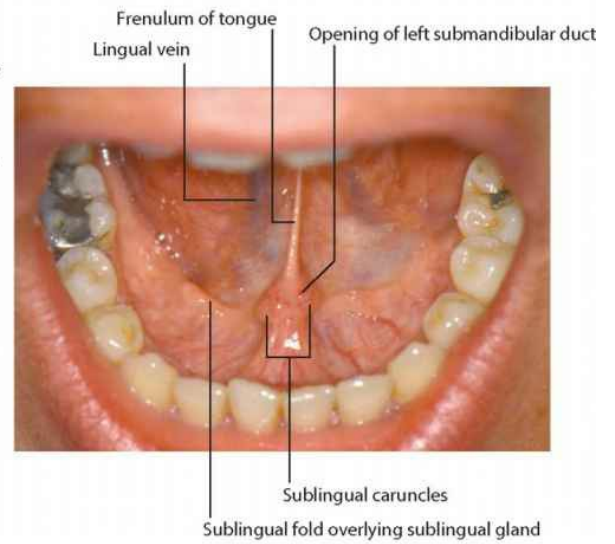
# Palate



**Open mouth showing soft palate**

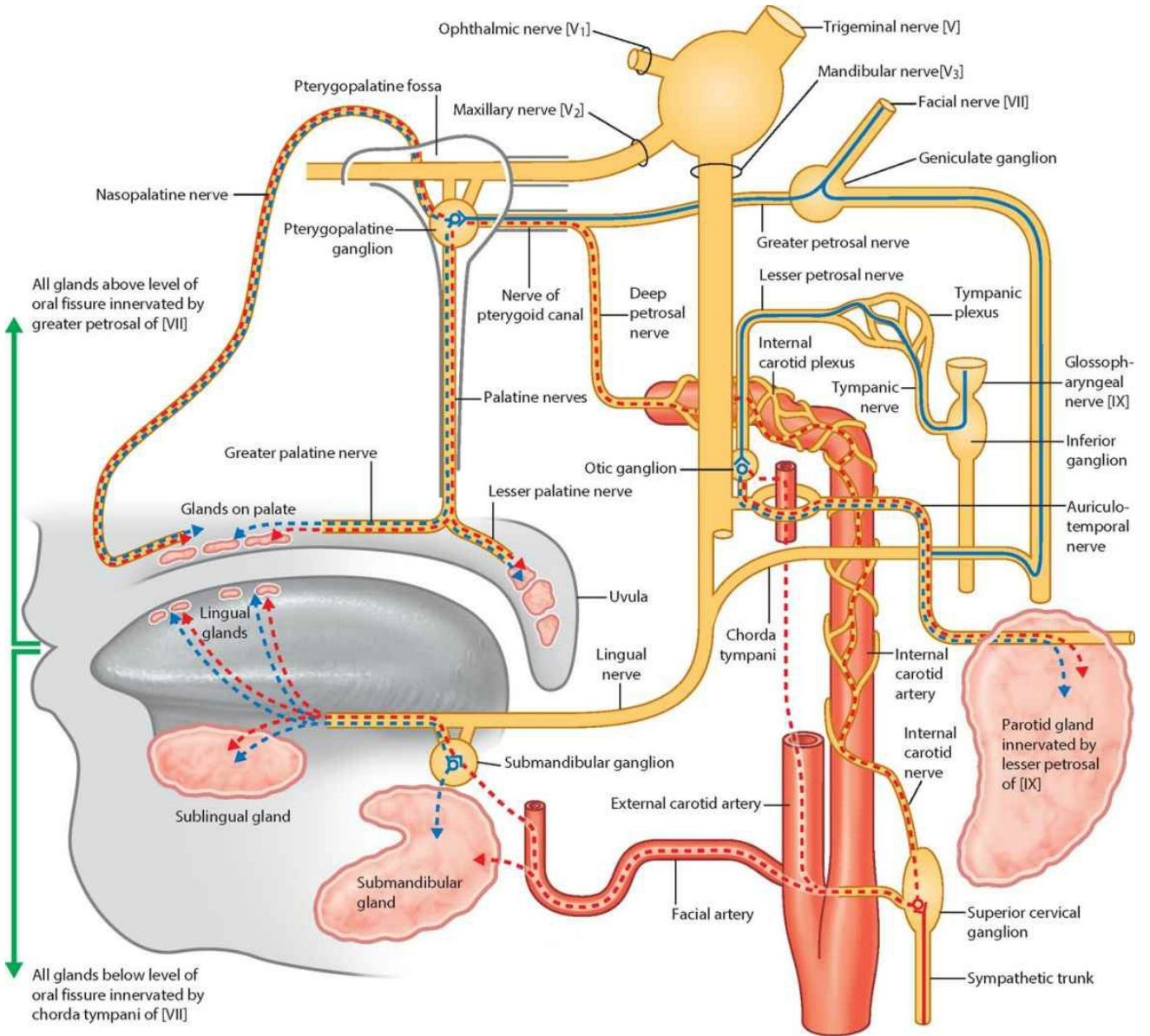


**Inferior surface of tongue and floor of oral cavity**



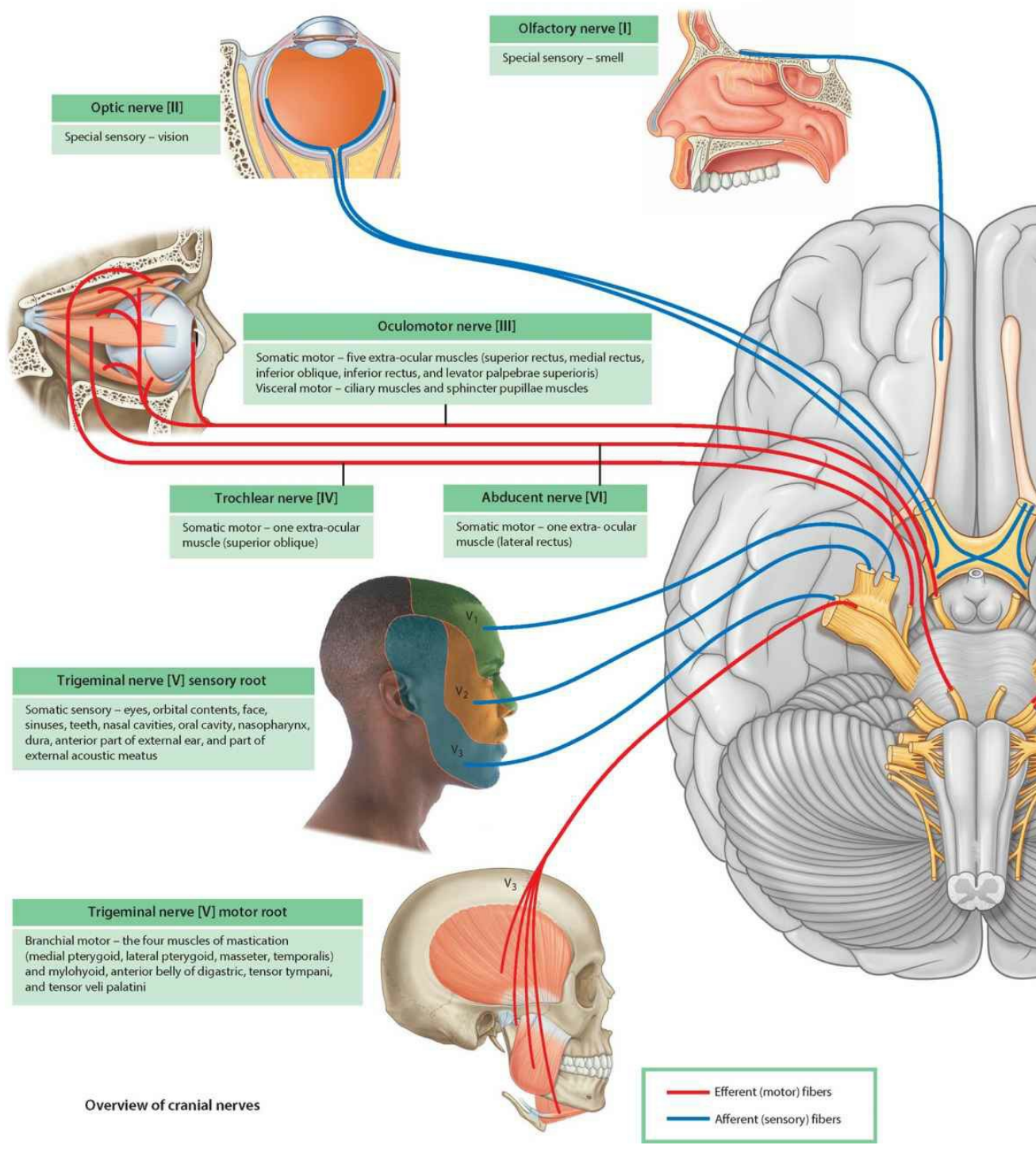
**Sublingual glands (anterosuperior view)**

# Innervation of oral cavity

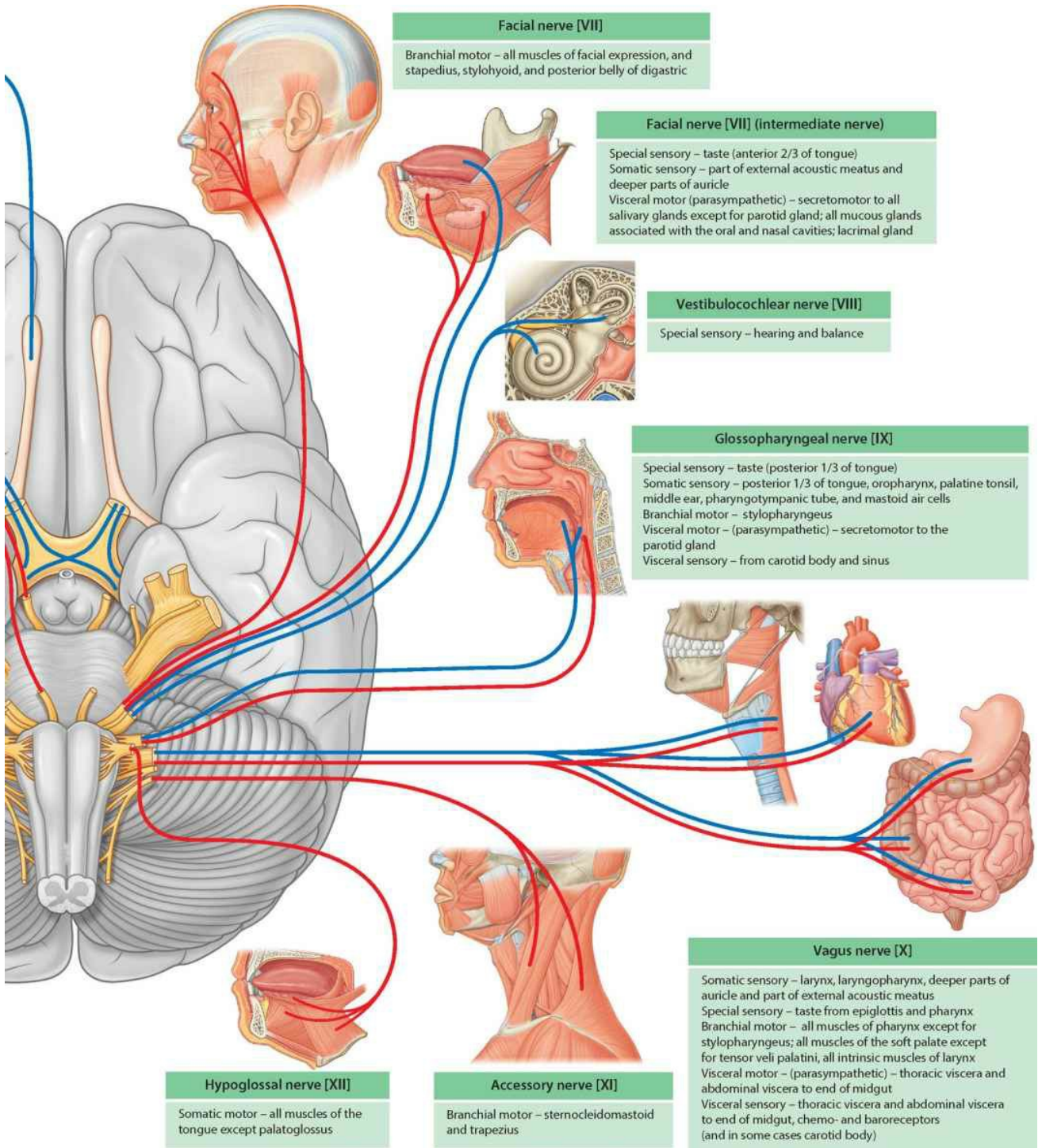


Visceral efferent (motor) innervation of glands related to the oral cavity

# Cranial nerves







**Facial nerve [VII]**  
 Branchial motor – all muscles of facial expression, and stapedius, stylohyoid, and posterior belly of digastric

**Facial nerve [VII] (intermediate nerve)**  
 Special sensory – taste (anterior 2/3 of tongue)  
 Somatic sensory – part of external acoustic meatus and deeper parts of auricle  
 Visceral motor (parasympathetic) – secretomotor to all salivary glands except for parotid gland; all mucous glands associated with the oral and nasal cavities; lacrimal gland

**Vestibulocochlear nerve [VIII]**  
 Special sensory – hearing and balance

**Glossopharyngeal nerve [IX]**  
 Special sensory – taste (posterior 1/3 of tongue)  
 Somatic sensory – posterior 1/3 of tongue, oropharynx, palatine tonsil, middle ear, pharyngotympanic tube, and mastoid air cells  
 Branchial motor – stylopharyngeus  
 Visceral motor – (parasympathetic) – secretomotor to the parotid gland  
 Visceral sensory – from carotid body and sinus

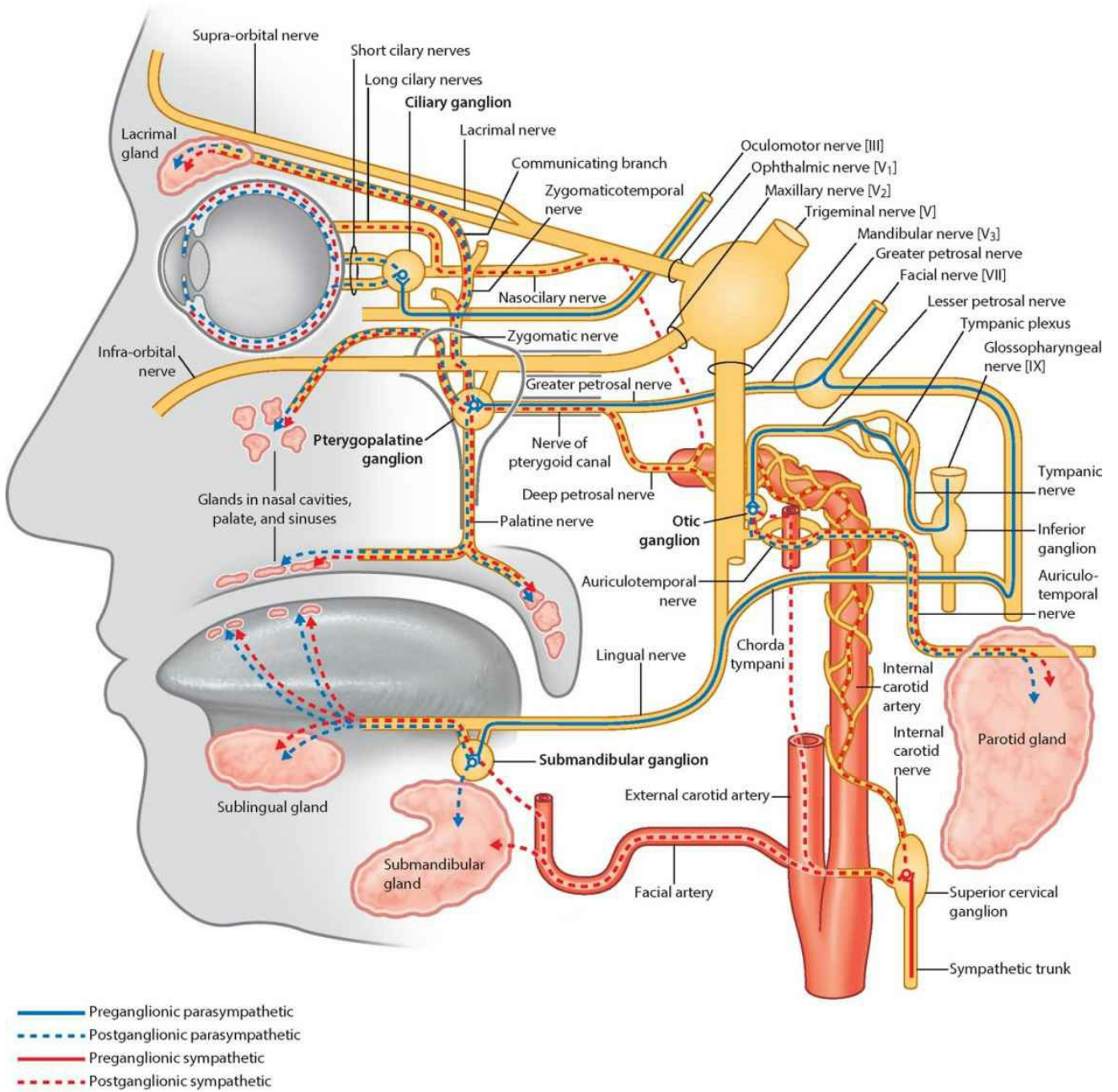
**Vagus nerve [X]**  
 Somatic sensory – larynx, laryngopharynx, deeper parts of auricle and part of external acoustic meatus  
 Special sensory – taste from epiglottis and pharynx  
 Branchial motor – all muscles of pharynx except for stylopharyngeus; all muscles of the soft palate except for tensor veli palatini, all intrinsic muscles of larynx  
 Visceral motor – (parasympathetic) – thoracic viscera and abdominal viscera to end of midgut  
 Visceral sensory – thoracic viscera and abdominal viscera to end of midgut, chemo- and baroreceptors (and in some cases carotid body)

**Hypoglossal nerve [XII]**  
 Somatic motor – all muscles of the tongue except palatoglossus

**Accessory nerve [XI]**  
 Branchial motor – sternocleidomastoid and trapezius



# Visceral motor pathways in the head



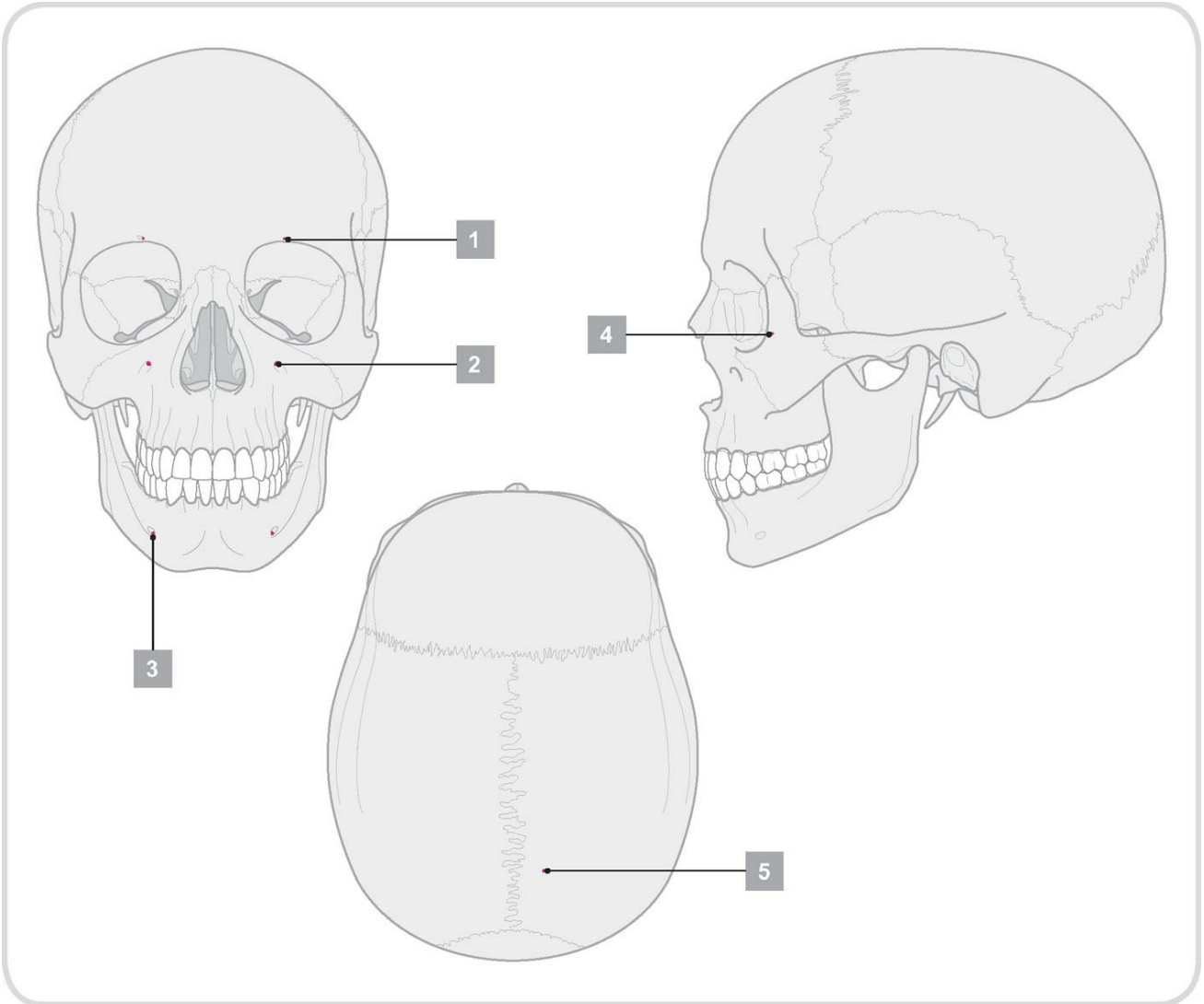
Summary of visceral efferent (motor) pathways in the head

## Tables

### External foramina of the skull

---

Foramen		Structures passing through foramen
<i>Anterior view</i>		
<b>Supra-orbital foramen</b>	<b>1</b>	Supra-orbital nerve and vessels
<b>Infra-orbital foramen</b>	<b>2</b>	Infra-orbital nerve and vessels
<b>Mental foramen</b>	<b>3</b>	Mental nerve and vessels
<i>Lateral view</i>		
<b>Zygomaticofacial foramen</b>	<b>4</b>	Zygomaticofacial nerve
<i>Superior view</i>		
<b>Parietal foramen</b>	<b>5</b>	Emissary veins



## External foramina of the skull

---

Foramen		Structures passing through foramen
<i>Inferior view</i>		
<b>Incisive foramina</b>	1	Nasopalatine nerve; sphenopalatine vessels
<b>Greater palatine foramen</b>	2	Greater palatine nerve and vessels
<b>Lesser palatine foramina</b>	3	Lesser palatine nerves and vessels
<b>Pterygoid canal</b>	4	Pterygoid nerve and vessels
<b>Foramen ovale</b>	5	Mandibular nerve [V <sub>3</sub> ]; lesser petrosal nerve
<b>Foramen spinosum</b>	6	Middle meningeal artery
<b>Foramen lacerum</b>	7	Filled with cartilage
<b>Carotid canal</b>	8	Internal carotid artery and nerve plexus
<b>Foramen magnum</b>	9	Continuation of brain and spinal cord; vertebral arteries and nerve plexuses; anterior spinal artery; posterior spinal arteries; roots of accessory nerve [XI]; meninges
<b>Condylar canal</b>	10	Emissary veins
<b>Hypoglossal canal</b>	11	Hypoglossal nerve [XII] and vessels
<b>Jugular foramen</b>	12	Internal jugular vein; inferior petrosal sinus; glossopharyngeal nerve [IX]; vagus nerve [X]; accessory nerve [XI]
<b>Stylomastoid foramen</b>	13	Facial nerve [VII]

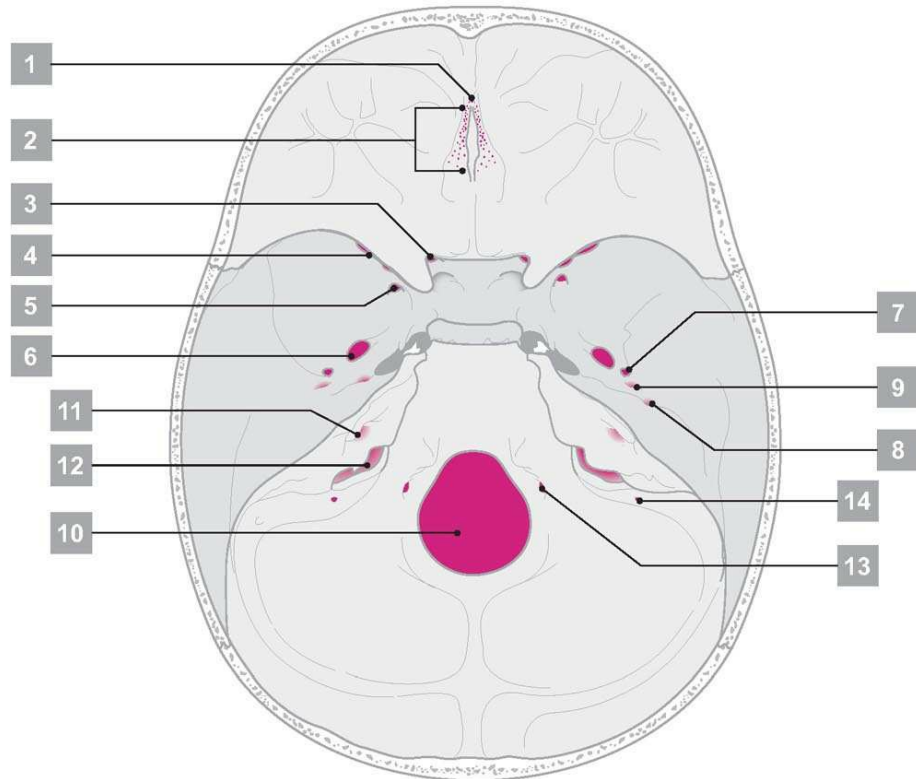
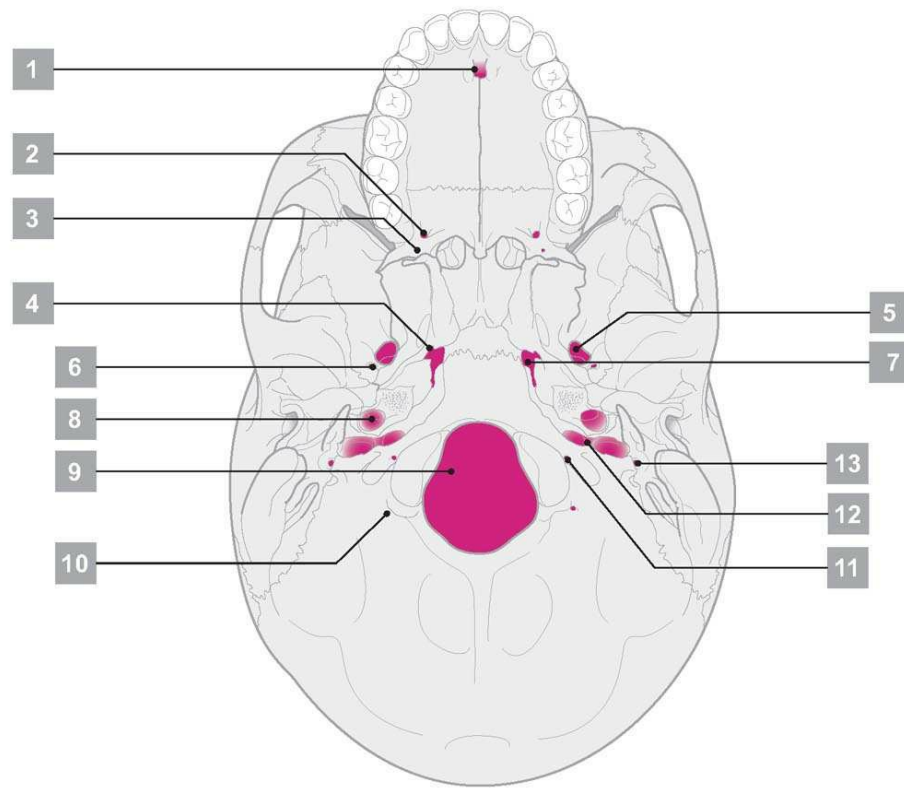
## Internal foramina of the skull

---

<i>Anterior cranial fossa</i>		
-------------------------------	--	--

<b>Foramen cecum</b>	<b>1</b>	Emissary veins to nasal cavity
<b>Olfactory foramina in cribriform plate</b>	<b>2</b>	Olfactory nerves [I]
<i>Middle cranial fossa</i>		
<b>Optic canal</b>	<b>3</b>	Optic nerve [II]; ophthalmic artery
<b>Superior orbital fissure</b>	<b>4</b>	Oculomotor nerve [III]; trochlear nerve [IV]; ophthalmic division of the trigeminal nerve [V <sub>1</sub> ]; abducent nerve [VI]; ophthalmic veins
<b>Foramen rotundum</b>	<b>5</b>	Maxillary division of the trigeminal nerve [V <sub>2</sub> ]
<b>Foramen ovale</b>	<b>6</b>	Mandibular division of the trigeminal nerve [V <sub>3</sub> ]; lesser petrosal nerve
<b>Foramen spinosum</b>	<b>7</b>	Middle meningeal artery
<b>Hiatus for the greater petrosal nerve</b>	<b>8</b>	Greater petrosal nerve
<b>Hiatus for the lesser petrosal nervex</b>	<b>9</b>	Lesser petrosal nerve
<i>Posterior cranial fossa</i>		
<b>Foramen magnum</b>	<b>10</b>	End of brainstem/beginning of spinal cord; vertebral arteries; spinal roots of the accessory nerve; meninges
<b>Internal acoustic meatus</b>	<b>11</b>	Facial nerve [VII]; vestibulocochlear nerve [VIII]; labyrinthine artery
<b>Jugular foramen</b>	<b>12</b>	Glossopharyngeal nerve [IX]; vagus nerve [X]; accessory nerve [XI]; inferior petrosal sinus, sigmoid sinus (forming internal jugular vein)
<b>Hypoglossal canal</b>	<b>13</b>	Hypoglossal nerve [XII]; meningeal branch of the ascending pharyngeal artery
<b>Condylar canal</b>	<b>14</b>	Emissary vein

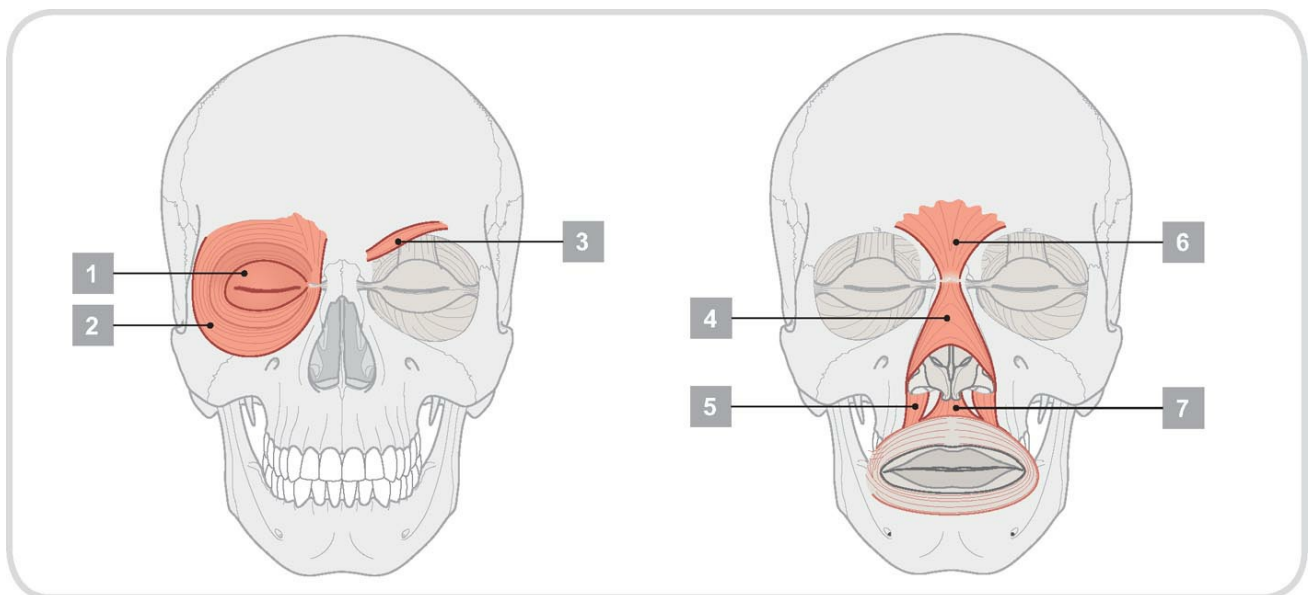






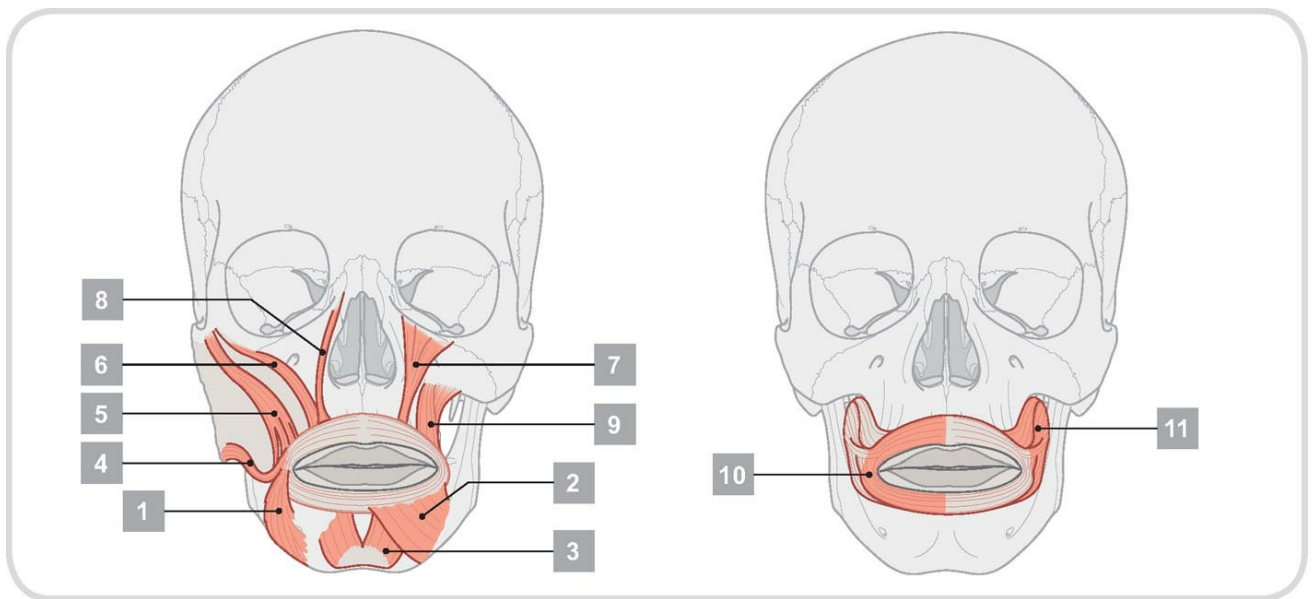
# Muscles of the face

Muscle		Origin	Insertion	Innervation	Function
<b>Orbital group</b>					
Orbicularis oculi—Palpebral part	1	Medial palpebral ligament	Lateral palpebral raphe	Facial nerve [VII]	Closes the eyelids gently
—Orbital part	2	Nasal part of frontal bone; frontal process of maxilla; medial palpebral ligament	Fibers form an uninterrupted ellipse around orbit	Facial nerve [VII]	Closes the eyelids forcefully
Corrugator supercillii	3	Medial end of the superciliary arch	Skin of the medial half of eyebrow	Facial nerve [VII]	Draws the eyebrows medially and downward
<b>Nasal group</b>					
Nasalis					
—Transverse part	4	Maxilla just lateral to nose	Aponeurosis across dorsum of nose with muscle fibers from the other side	Facial nerve [VII]	Compresses nasal aperture
—Alar part	5	Maxilla over lateral incisor	Alar cartilage of nose	Facial nerve [VII]	Draws cartilage downward and laterally opening nostril
Procerus	6	Nasal bone and upper part of lateral nasal cartilage	Skin of lower forehead between eyebrows	Facial nerve [VII]	Draws down medial angle of eyebrows producing transverse wrinkles over bridge of nose
Depressor septi	7	Maxilla above medial incisor	Mobile part of the nasal septum	Facial nerve [VII]	Pulls nose inferiorly



## Muscles of the face

Muscle		Origin	Insertion	Innervation	Function
Oral group					
Depressor anguli oris	1	Oblique line of mandible below canine, premolar, and first molar teeth	Skin at the corner of mouth and blending with orbicularis oris	Facial nerve [VII]	Draws corner of mouth down and laterally
Depressor labii inferioris	2	Anterior part of oblique line of mandible	Lower lip at midline; blends with muscle from opposite side	Facial nerve [VII]	Draws lower lip downward and laterally
Mentalis	3	Mandible inferior to incisor teeth	Skin of chin	Facial nerve [VII]	Raises and protrudes lower lip as it wrinkles skin on chin
Risorius	4	Fascia over masseter muscle	Skin at the corner of the mouth	Facial nerve [VII]	Retracts corner of mouth
Zygomaticus major	5	Posterior part of lateral surface of zygomatic bone	Skin at the corner of the mouth	Facial nerve [VII]	Draws the corner of the mouth upward and laterally
Zygomaticus minor	6	Anterior part of lateral surface of zygomatic bone	Upper lip just medial to corner of mouth	Facial nerve [VII]	Draws the upper lip upward
Levator labii superioris	7	Infra-orbital margin of maxilla	Skin of upper lateral half of upper lip	Facial nerve [VII]	Raises upper lip; helps form nasolabial furrow
Levator labii superioris alaeque nasi	8	Frontal process of maxilla	Alar cartilage of nose and upper lip	Facial nerve [VII]	Raises upper lip and opens nostril
Levator anguli oris	9	Maxilla below infra-orbital foramen	Skin at the corner of mouth	Facial nerve [VII]	Raises corner of mouth; helps form nasolabial furrow
Orbicularis oris	10	From muscles in area; maxilla and mandible in midline	Forms ellipse around mouth	Facial nerve [VII]	Closes lips; protrudes lips
Buccinator	11	Posterior parts of maxilla and mandible; pterygomandibular raphe	Blends with orbicularis oris and into lips	Facial nerve [VII]	Presses the cheek against teeth; compresses distended cheeks

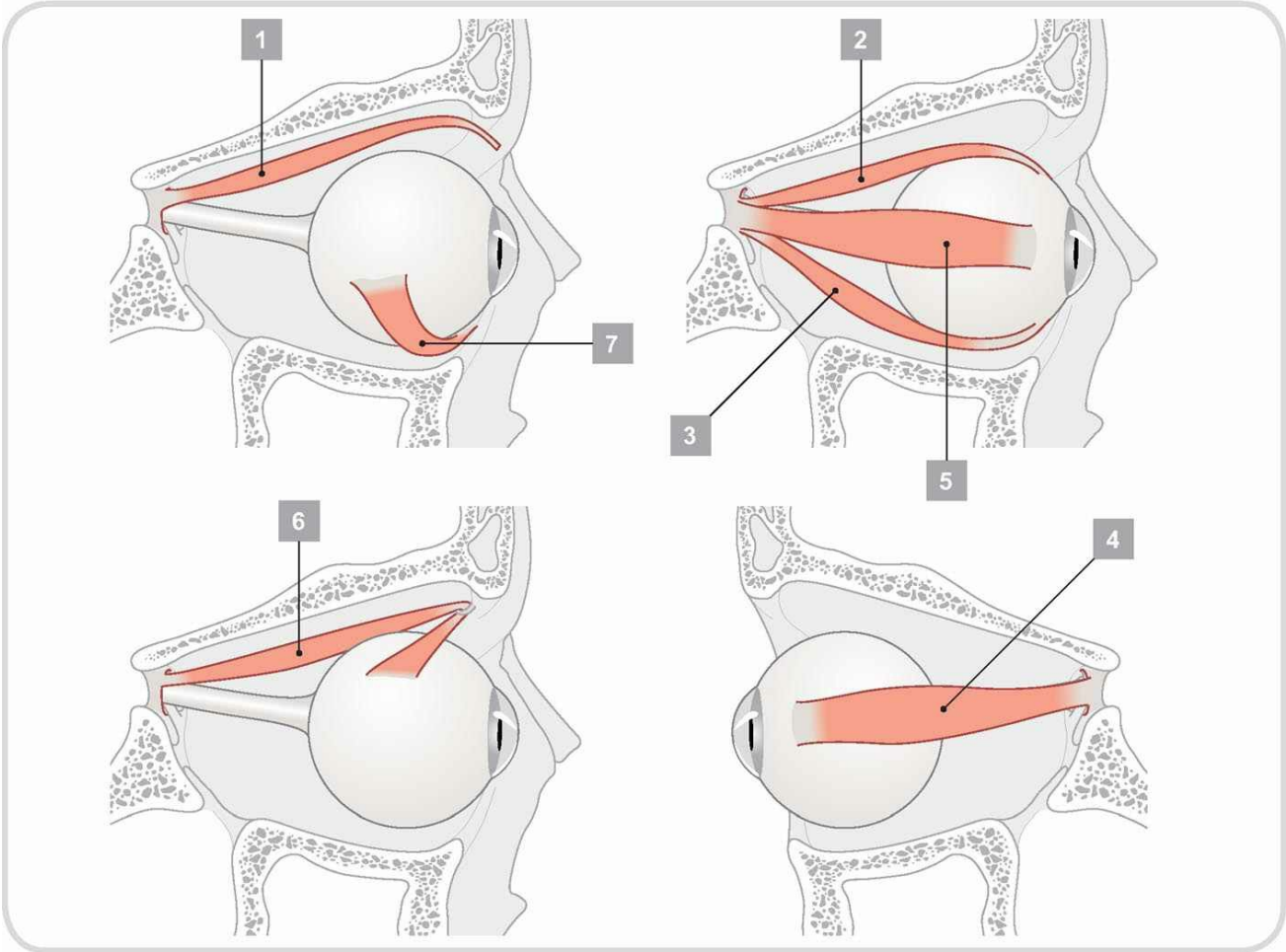
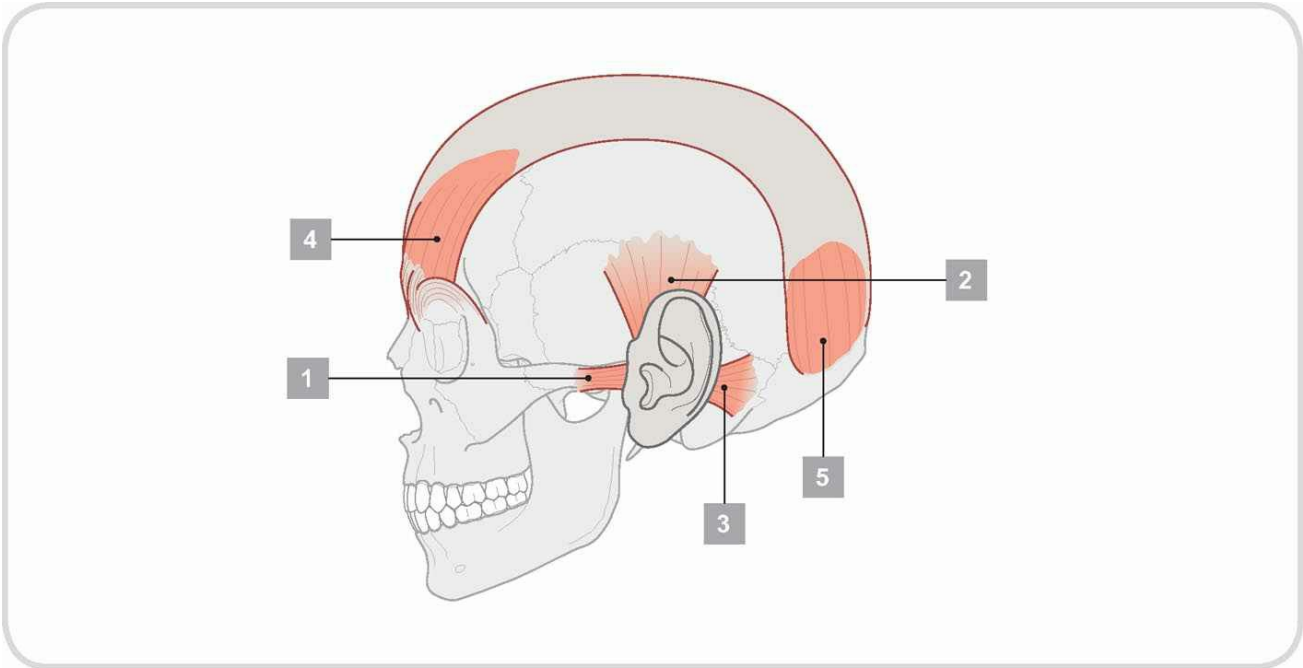


## Muscles of the face

Muscle		Origin	Insertion	Innervation	Function
Other muscles or groups					
Anterior auricular	1	Anterior part of temporal fascia	Into helix of ear	Facial nerve [VII]	Draws ear upward
Superior auricular	2	Epicranial aponeurosis	Upper part of auricle	Facial nerve [VII]	and forward Elevates ear
Posterior auricular	3	on side of head Mastoid process of	Convexity of concha of ear	Facial nerve [VII]	Draws ear upward
Occipitofrontalis					
—Frontal belly	4	temporal bone Skin of eyebrows	Into galea aponeurotica	Facial nerve [VII]	and backward Wrinkles forehead;
—Occipital belly	5	Lateral part of superior nuchal line of occipital bone and mastoid process of temporal bone	Into galea aponeurotica	Facial nerve [VII]	raises eyebrows Draws scalp backward

## Extrinsic (extra-ocular) muscles

Muscle		Origin	Insertion	Innervation	Function
<b>Levator palpebrae superioris</b>	1	Lesser wing of sphenoid anterior to optic canal	Anterior surface of tarsal plate; a few fibers to skin and superior conjunctival fornix	Oculomotor nerve [III] – superior branch	Elevation of upper eyelid
<b>Superior rectus</b>	2	Superior part of common tendinous ring	Anterior half of eyeball superiorly	Oculomotor nerve [III] – superior branch	Elevation, adduction, medial rotation of eyeball
<b>Inferior rectus</b>	3	Inferior part of common tendinous ring	Anterior half of eyeball inferiorly	Oculomotor nerve [III] – inferior branch	Depression, adduction, lateral rotation of eyeball
<b>Medial rectus</b>	4	Medial part of common tendinous ring	Anterior half of eyeball medially	Oculomotor nerve [III] – inferior branch	Adduction of eyeball
<b>Lateral rectus</b>	5	Lateral part of common tendinous ring	Anterior half of eyeball laterally	Abducent nerve [VI]	Abduction of eyeball
<b>Superior oblique</b>	6	Body of sphenoid, superior and medial to optic canal	Outer posterior quadrant of eyeball (superior surface)	Trochlear nerve [IV]	Depression, abduction, medial rotation of eyeball
<b>Inferior oblique</b>	7	Medial floor of orbit posterior to rim; maxilla lateral to nasolacrimal groove	Outer posterior quadrant of eyeball (inferior surface)	Oculomotor nerve [III] – inferior branch	Elevation, abduction, lateral rotation of eyeball

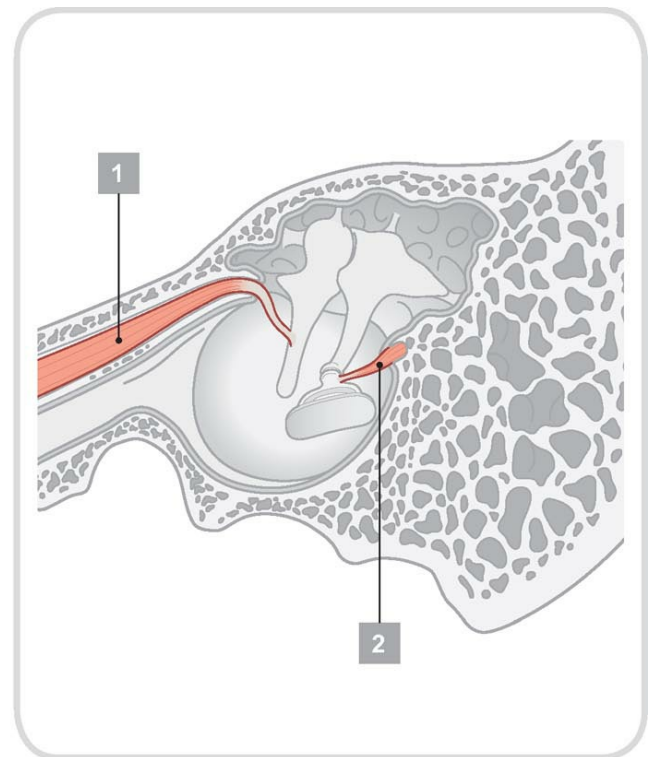
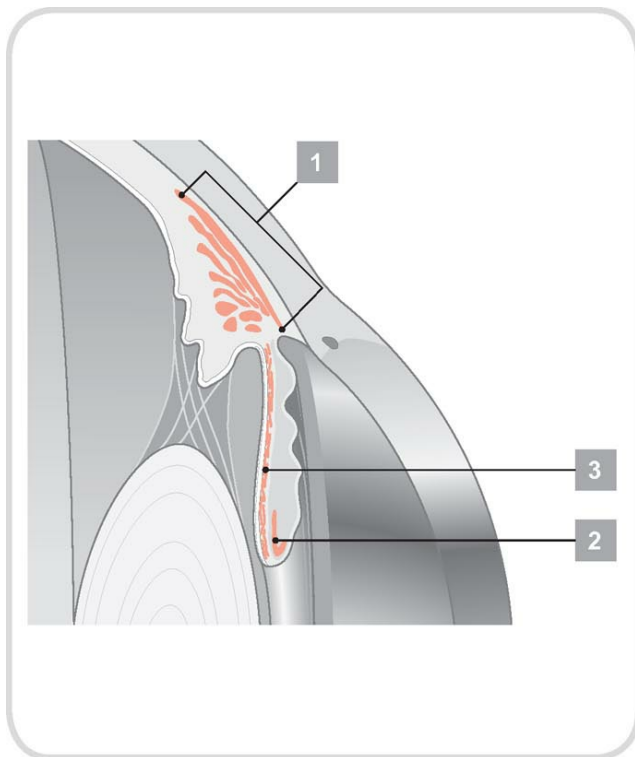


## Intrinsic muscles of the eye

Muscle		Location	Innervation	Function
Ciliary	1	Muscle fibers in the ciliary body	Parasympathetics from the oculomotor nerve [III]	Constricts ciliary body, relaxes tension on lens, lens become more rounded
Sphincter pupillae	2	Circularly arranged fibers in the iris	Parasympathetics from the oculomotor nerve [III]	Constricts pupil
Dilator pupillae	3	Radially arranged fibers in the iris	Sympathetics from the superior cervical ganglion (T1)	Dilates pupil

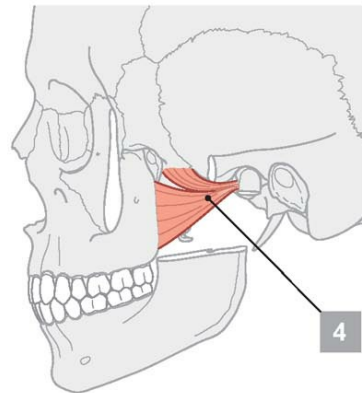
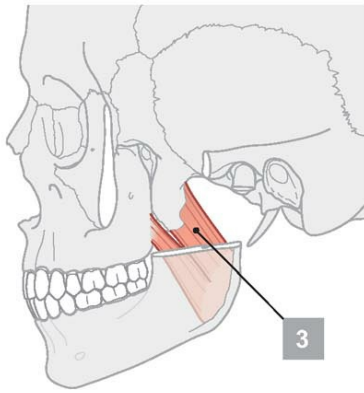
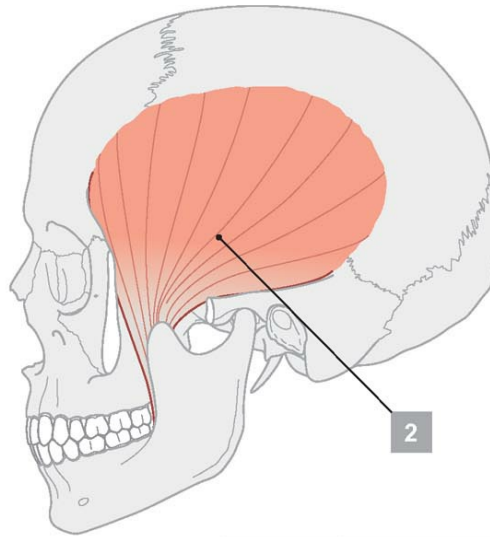
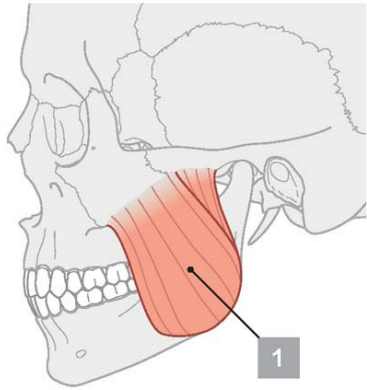
## Muscles of the middle ear

Muscle		Origin	Insertion	Innervation	Function
Tensor tympani	1	Cartilaginous part of pharyngotympanic tube, greater wing of sphenoid, its own bony canal	Upper part of handle of malleus	Branch from mandibular nerve [V <sub>3</sub> ]	Contraction pulls handle of malleus medially, tensing tympanic membrane
Stapedius	2	Attached to inside of pyramidal eminence	Neck of stapes	Branch of facial nerve [VII]	Contraction pulls stapes posteriorly, preventing excessive oscillation



## Muscles of mastication

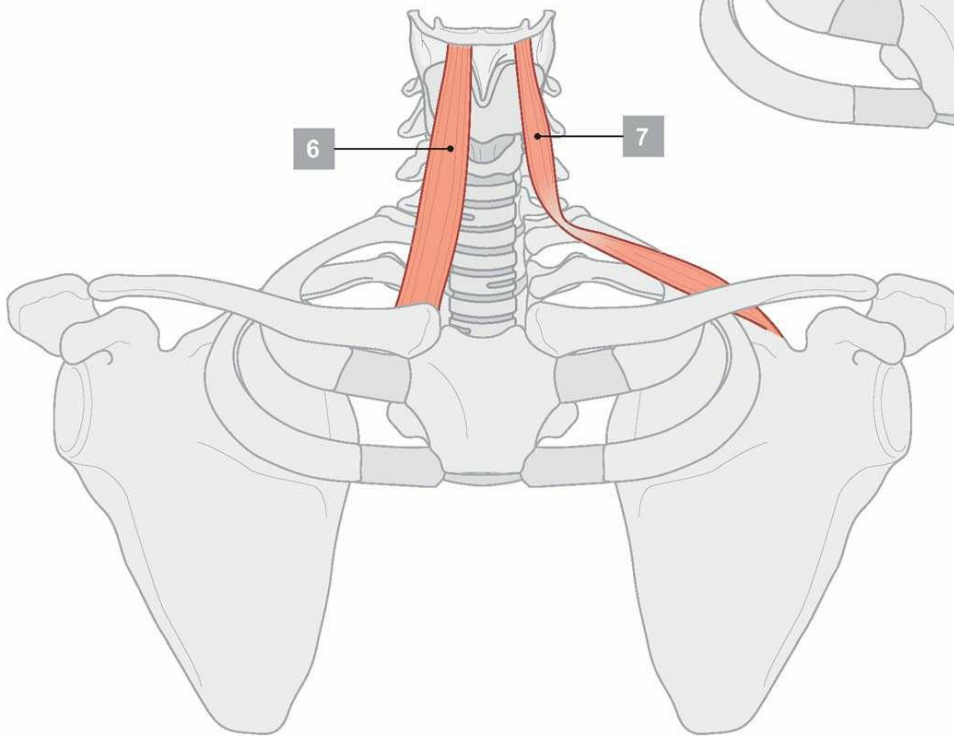
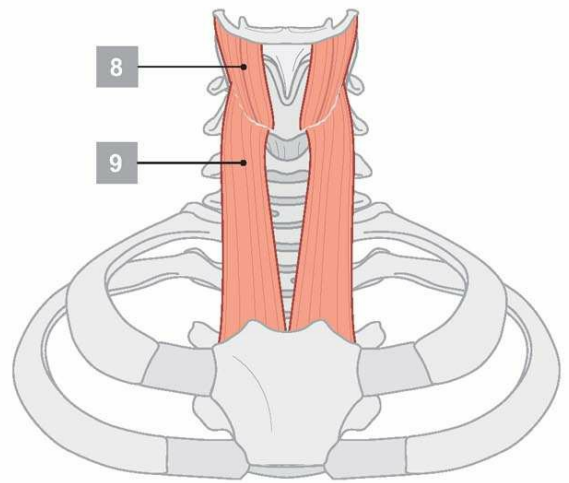
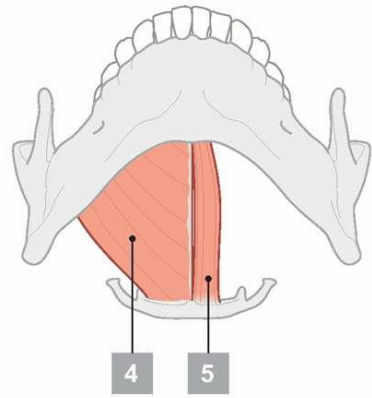
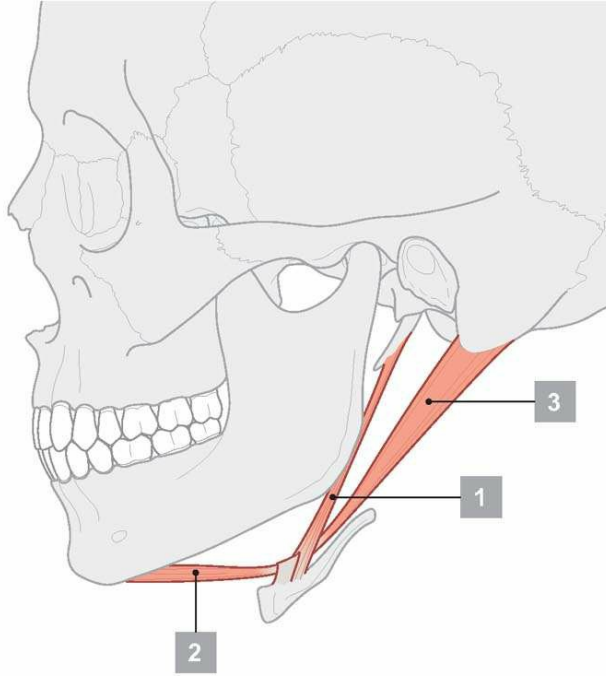
Muscle		Origin	Insertion	Innervation	Function
<b>Masseter</b>	1	Zygomatic arch and maxillary process of the zygomatic bone	Lateral surface of ramus of mandible	Masseteric nerve from the anterior trunk of the mandibular nerve [V <sub>3</sub> ]	Elevation of mandible
<b>Temporalis</b>	2	Bone of temporal fossa and temporal fascia	Coronoid process of mandible and anterior margin of ramus of mandible almost to last molar tooth	Deep temporal nerves from the anterior trunk of the mandibular nerve [V <sub>3</sub> ]	Elevation and retraction of mandible
<b>Medial pterygoid</b>	3	Deep head—medial surface of lateral plate of pterygoid process and pyramidal process of palatine bone; superficial head—tuberosity of the maxilla and pyramidal process of palatine bone	Medial surface of mandible near angle	Nerve to medial pterygoid from the mandibular nerve [V <sub>3</sub> ].	Elevation and side-to-side movements of the mandible
<b>Lateral pterygoid</b>	4	Upper head—roof of infratemporal fossa; lower head—lateral surface of lateral plate of the pterygoid process	Capsule of temporomandibular joint in the region of attachment to the articular disc and to the pterygoid fovea on the neck of mandible	Nerve to lateral pterygoid directly from the anterior trunk of the mandibular nerve [V <sub>3</sub> ] or from the buccal branch	Protrusion and side-to-side movements of the mandible





## Anterior triangle of neck (suprahyoid and infrahyoid muscles)

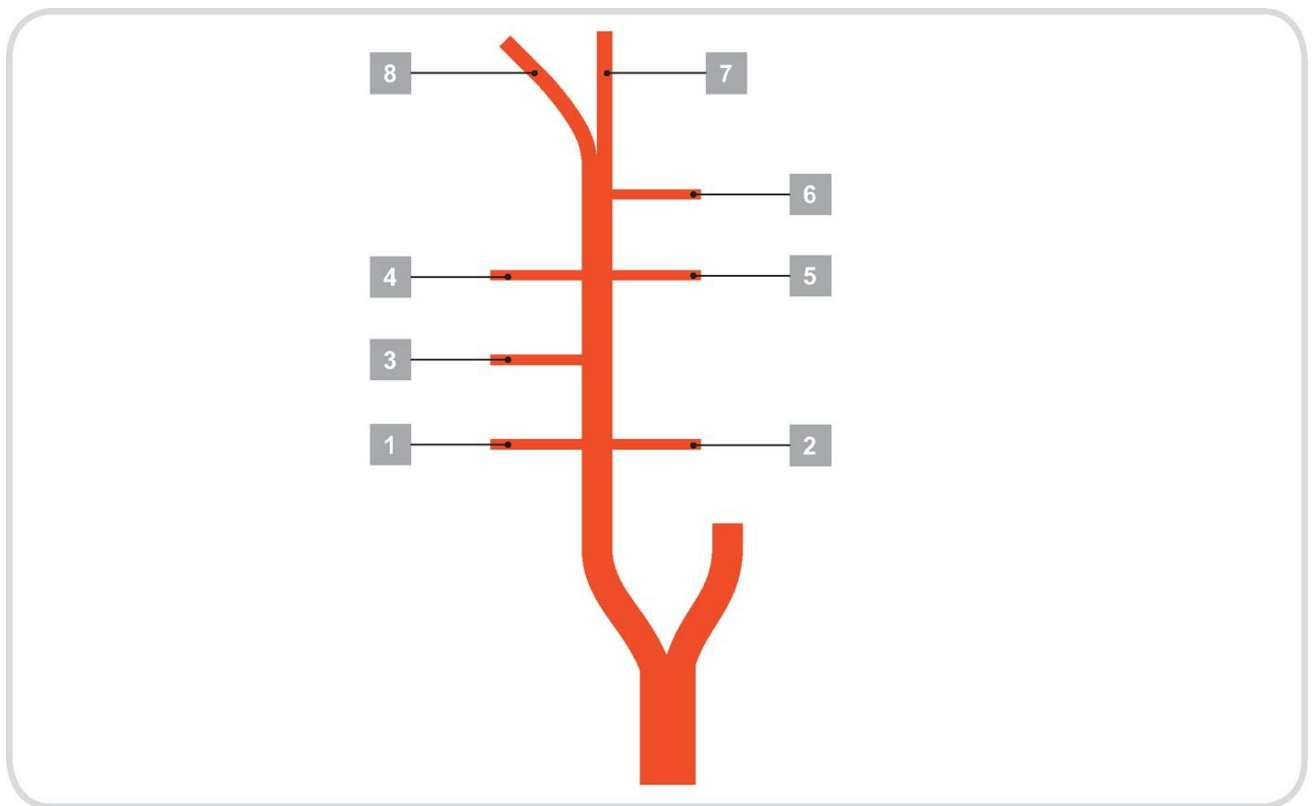
Muscle		Origin	Insertion	Innervation	Function
<b>Stylohyoid</b>	1	Base of styloid process	Lateral area of body of hyoid bone	Facial nerve [VII]	Pulls hyoid bone upward in a posterosuperior direction
<b>Digastric— Anterior belly</b>	2	Digastric fossa on lower inside of mandible	Attachment of tendon between two bellies to body of hyoid bone	Mylohyoid nerve from inferior alveolar branch of mandibular nerve [V <sub>3</sub> ]	Opens mouth by lowering mandible; raises hyoid bone
<b>—Posterior belly</b>	3	Mastoid notch on medial side of mastoid process of temporal bone		Facial nerve [VII]	Pulls hyoid bone upward and back
<b>Mylohyoid</b>	4	Mylohyoid line on mandible	Body of hyoid bone and fibers from muscle on opposite side	Mylohyoid nerve from inferior alveolar branch of mandibular nerve [V <sub>3</sub> ]	Support and elevation of floor of mouth; elevation of hyoid
<b>Geniohyoid</b>	5	Inferior mental spine on inner surface of mandible	Anterior surface of body of hyoid bone	Branch from anterior ramus of C1 (carried along the hypoglossal nerve [XII])	Fixed mandible elevates and pulls hyoid bone forward; fixed hyoid bone pulls mandible downward and inward
<b>Sternohyoid</b>	6	Posterior aspect of sternoclavicular joint and adjacent manubrium of sternum	Body of hyoid bone medial to attachment of omohyoid muscle	Anterior rami of C1 to C3 through the ansa cervicalis	Depresses hyoid bone after swallowing
<b>Omohyoid</b>	7	Superior border of scapula medial to suprascapular notch	Lower border of body of hyoid bone just lateral to attachment of sternohyoid	Anterior rami of C1 to C3 through the ansa cervicalis	Depresses and fixes hyoid bone
<b>Thyrohyoid</b>	8	Oblique line on lamina of thyroid cartilage	Greater horn and adjacent aspect of body of hyoid bone	Fibers from anterior ramus of C1 carried along hypoglossal nerve [XII]	Depresses hyoid bone, but when hyoid bone is fixed raises larynx
<b>Sternothyroid</b>	9	Posterior surface of manubrium of sternum	Oblique line on lamina of thyroid cartilage	Anterior rami of C1 to C3 through the ansa cervicalis	Draws larynx (thyroid cartilage) downward



## Branches of the external carotid artery

---

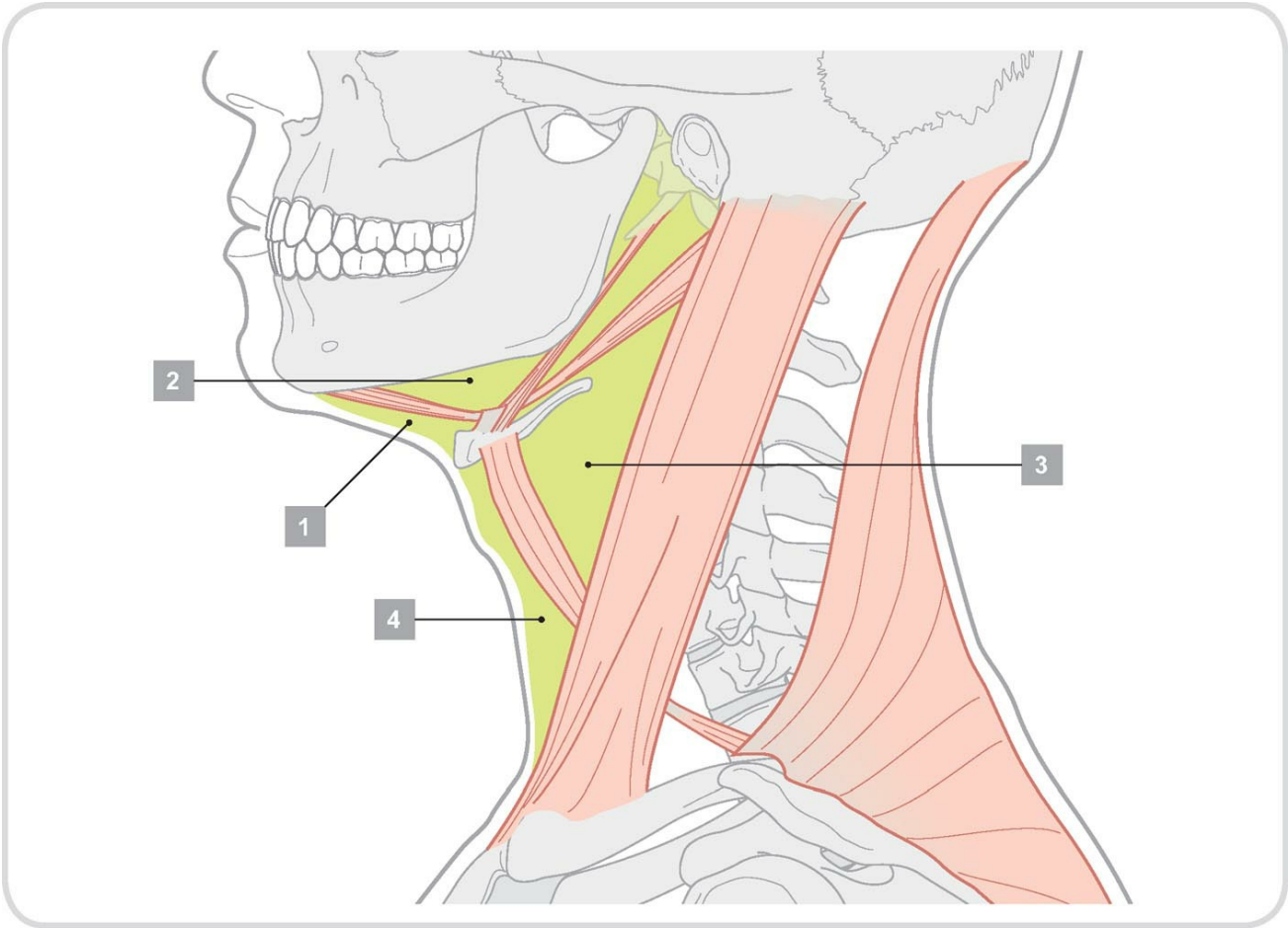
Artery		Parts supplied
<b>Superior thyroid artery</b>	1	Thyrohyoid muscle, internal structures of the larynx, sternocleidomastoid and cricothyroid muscles, thyroid gland
<b>Ascending pharyngeal artery</b>	2	Pharyngeal constrictors and stylopharyngeus muscle, palate, tonsil, pharyngotympanic tube, meninges in posterior cranial fossa
<b>Lingual artery</b>	3	Muscles of the tongue, palatine tonsil, soft palate, epiglottis, floor of mouth, sublingual gland
<b>Facial artery</b>	4	All structures in the face from the inferior border of the mandible anterior to the masseter muscle to the medial corner of the eye, the soft palate, palatine tonsil, pharyngotympanic tube, submandibular gland
<b>Occipital artery</b>	5	Sternocleidomastoid muscle, meninges in posterior cranial fossa, mastoid cells, deep muscles of the back, posterior scalp
<b>Posterior auricular artery</b>	6	Parotid gland and nearby muscles, external ear and scalp posterior to ear, middle and inner ear structures
<b>Superficial temporal artery</b>	7	Parotid gland and duct, masseter muscle, lateral face, anterior part of external ear, temporalis muscle, parietal and temporal fossae
<b>Maxillary artery</b>	8	External acoustic meatus, lateral and medial surface of tympanic membrane, temporomandibular joint, dura mater on lateral wall of skull and inner table of cranial bones, trigeminal ganglion and dura in vicinity, mylohyoid muscle, mandibular teeth, skin on chin, temporalis muscle, outer table of bones of skull in temporal fossa, structures in infratemporal fossa, maxillary sinus, upper teeth and gingivae, infra-orbital skin, palate, roof of pharynx, nasal cavity



## Subdivisions of the anterior triangle of the neck—a regional approach

Subdivision		Boundaries	Contents
<b>Submental triangle (unpaired)</b>	1	Mandibular symphysis; anterior belly of digastric muscles; body of hyoid bone	Submental lymph nodes; tributaries forming the anterior jugular vein
<b>Submandibular triangle (paired)</b>	2	Lower border of mandible; anterior belly of digastric muscle; posterior belly of digastric muscle	Submandibular gland; submandibular lymph nodes; hypoglossal nerve [XII]; mylohyoid nerve; facial artery and vein
<b>Carotid triangle (paired)</b>	3	Posterior belly of digastric muscle; superior belly of omohyoid muscle; anterior border of sternocleidomastoid muscle	Tributaries to common facial vein; cervical branch of facial nerve [VII]; common carotid artery; external and internal carotid arteries; superior thyroid; ascending pharyngeal; lingual, facial, and occipital arteries; internal jugular vein; vagus [X], accessory [XI], and hypoglossal [XII] nerves; superior and inferior roots of ansa cervicalis; transverse cervical nerve
<b>Muscular triangle (paired)</b>	4	Midline of neck; superior belly of omohyoid muscle; anterior border of sternocleidomastoid muscle	Sternohyoid, omohyoid, sternohyoid, and thyrohyoid muscles; thyroid and parathyroid glands; pharynx

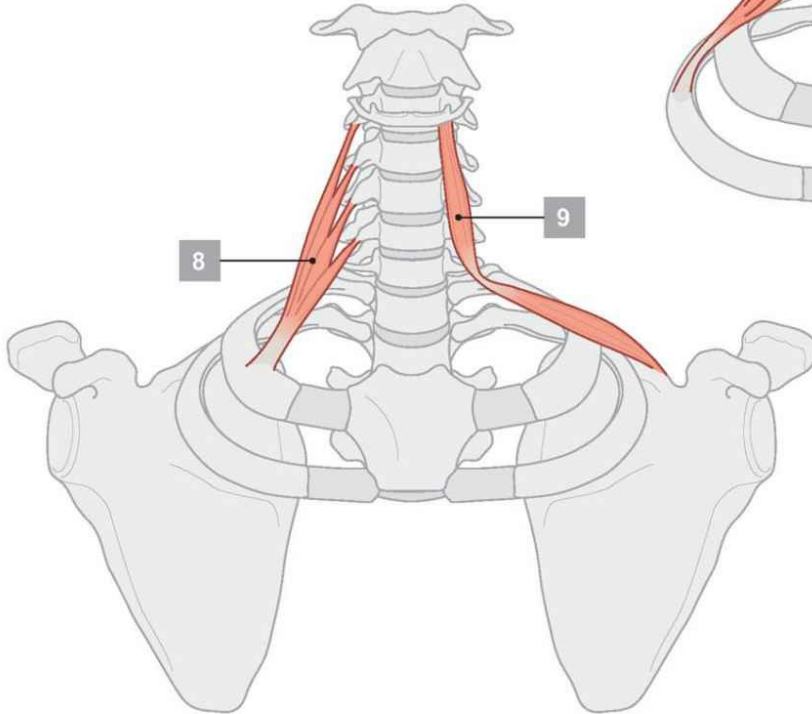
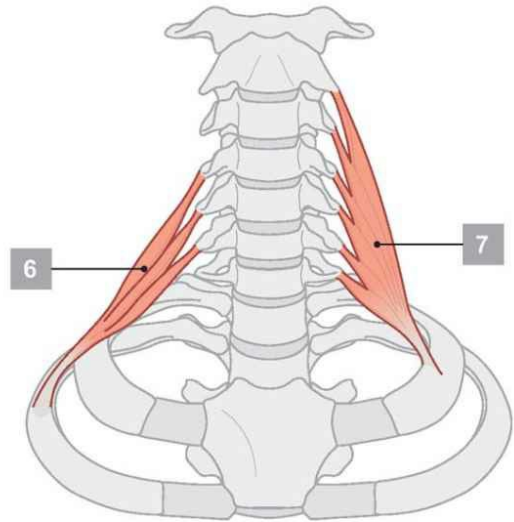
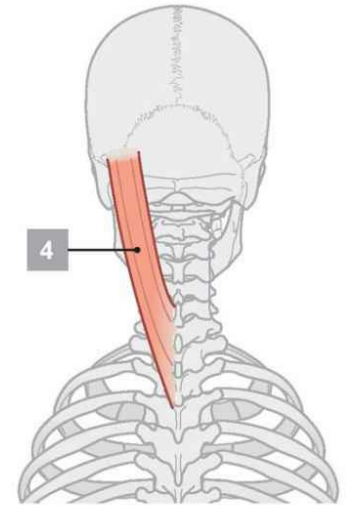
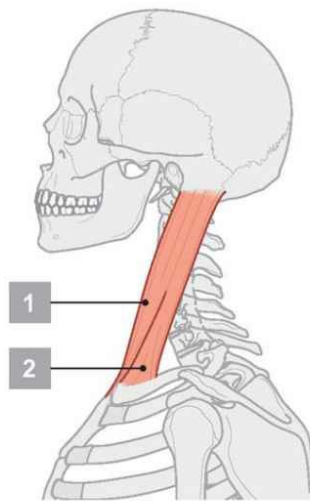
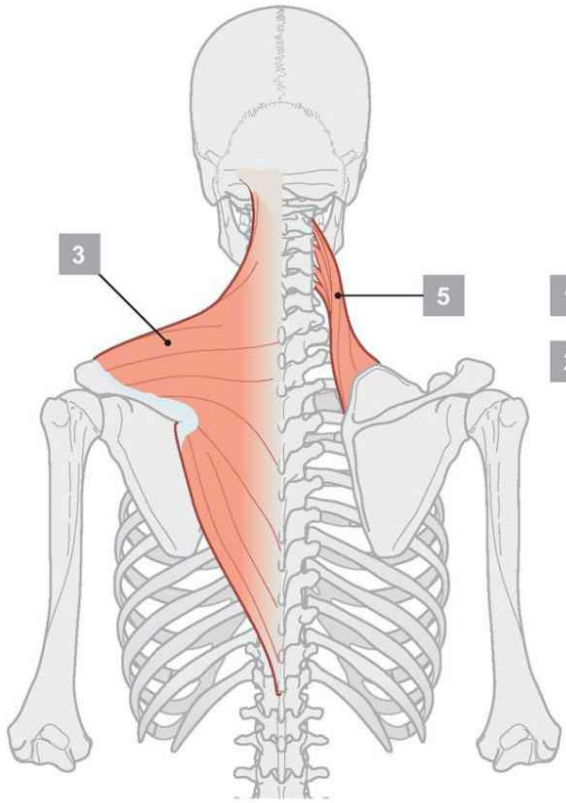




## Muscles associated with the posterior triangle of the neck

Parentheses indicate possible involvement

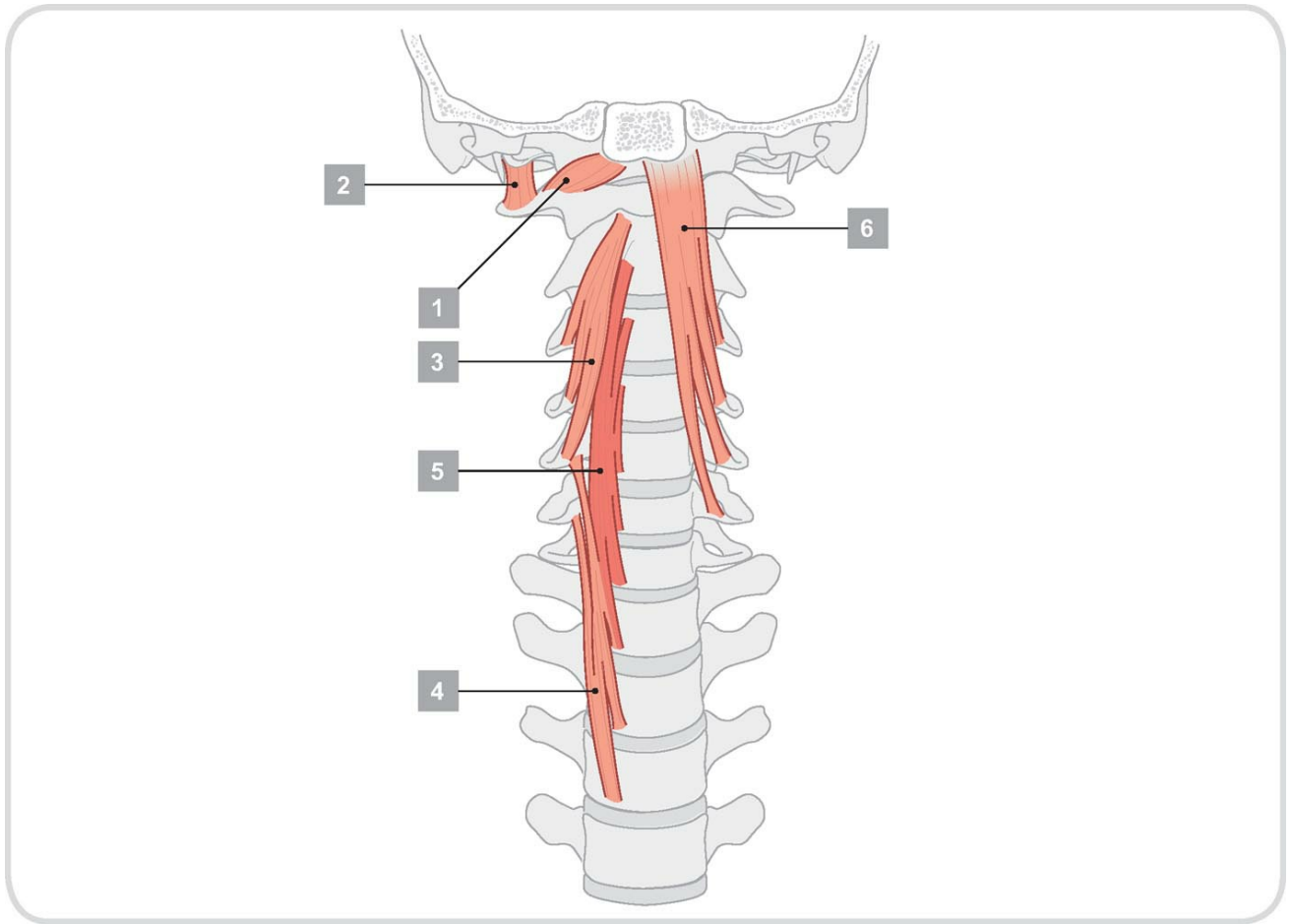
Muscle		Origin	Insertion	Innervation	Function
<b>Sternocleidomastoid— Sternal head</b>	1	Upper part of anterior surface of manubrium of sternum	Lateral one-half of superior nuchal line	Accessory nerve [XI] and branches from anterior rami of C2 to C3 (C4)	Individually—will tilt head toward shoulder on same side rotating head to turn face to opposite side; acting together, draw head forward
<b>—Clavicular head</b>	2	Superior surface of medial one-third of clavicle	Lateral surface of mastoid process		
<b>Trapezius</b>	3	Superior nuchal line; external occipital protuberance; ligamentum nuchae; spinous processes of vertebrae CVII to TXII	Lateral one-third of clavicle; acromion; spine of scapula	Motor—accessory nerve [XI]; proprioception—C3 and C4	Assists in rotating the scapula during abduction of humerus above horizontal; upper fibers—elevate, middle fibers—adduct, lower fibers—depress scapula
<b>Splenius capitis</b>	4	Lower half of ligamentum nuchae; spinous processes of vertebrae CVII to TIV	Mastoid process, skull below lateral one-third of superior nuchal line	Posterior rami of middle cervical nerves	Together, draw head backward; individually, draw and rotate head to one side (turn face to same side)
<b>Levator scapulae</b>	5	Transverse processes of CI to CIV	Upper part of medial border of scapula	C3, C4; and dorsal scapular nerve (C4, C5)	Elevates scapula
<b>Posterior scalene</b>	6	Posterior tubercles of transverse processes of vertebrae CIV to CVI	Upper surface of rib II	Anterior rami of C5 to C7	Elevation of rib II
<b>Middle scalene</b>	7	Transverse processes of vertebrae CII to CVII	Upper surface of rib I posterior to the groove for the subclavian artery	Anterior rami of C3 to C7	Elevation of rib I
<b>Anterior scalene</b>	8	Anterior tubercles of the transverse processes of vertebrae CIII to CVI	Scalene tubercle and upper surface of rib I	Anterior rami of C4 to C7	Elevation of rib I
<b>Omohyoid</b>	9	Superior border of scapula medial to scapular notch	Inferior border of body of hyoid bone	Ansa cervicalis; anterior rami of C1 to C3	Depress the hyoid bone





## Prevertebral and lateral muscles

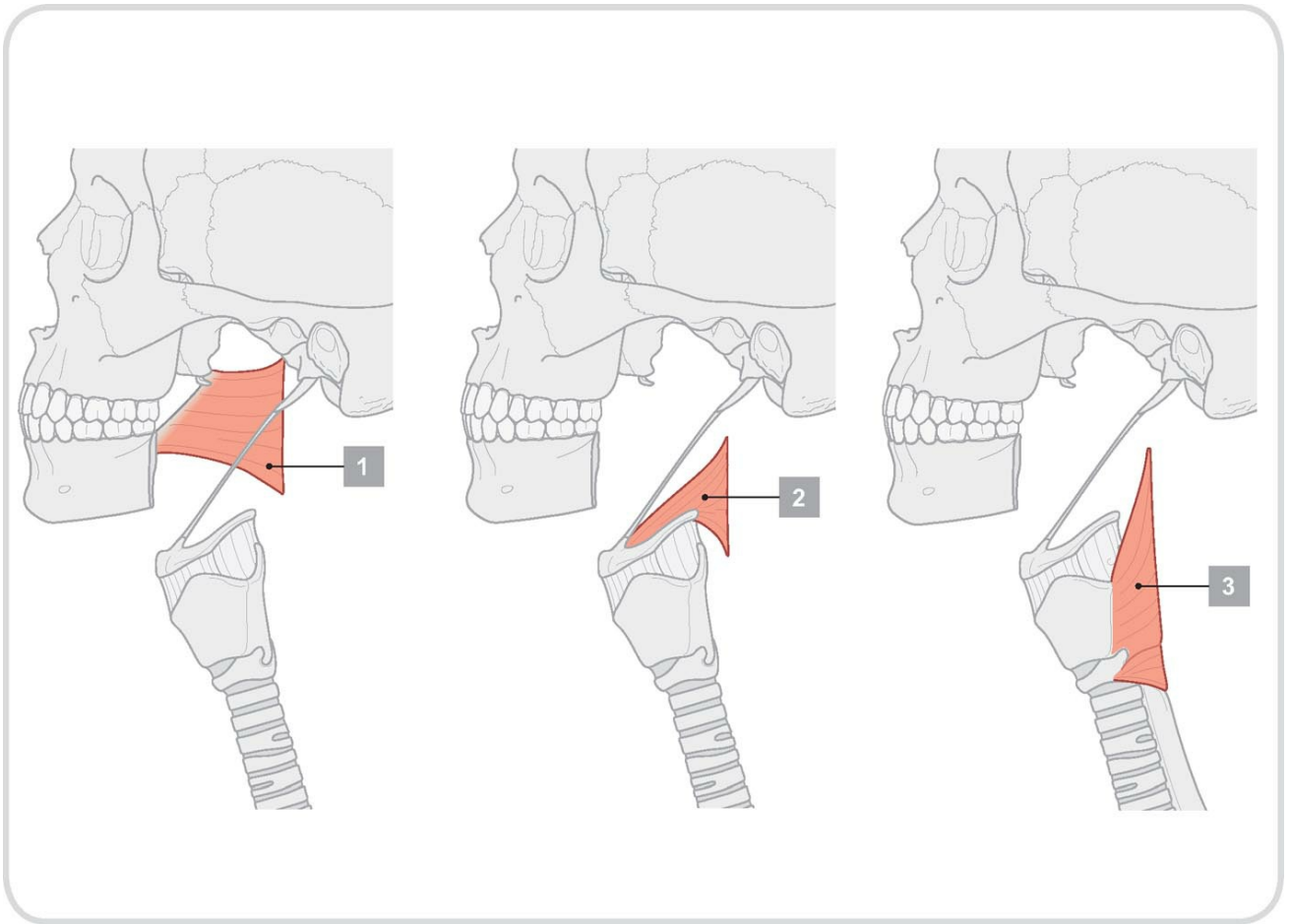
Muscle		Origin	Insertion	Innervation	Function
<b>Rectus capitis anterior</b>	1	Anterior surface of lateral part of atlas and its transverse process	Inferior surface of basilar part of occipital bone	Branches from anterior rami of C1, C2	Flexes head at atlanto-occipital joint
<b>Rectus capitis lateralis</b>	2	Superior surface of transverse process of atlas	Inferior surface of jugular process of occipital bone	Branches from anterior rami of C1, C2	Flexes head laterally to same side
<b>Longus colli – Superior oblique part</b>	3	Anterior tubercles of transverse processes of vertebrae CIII to CV	Tubercle of anterior arch of atlas	Branches from anterior rami of C2 to C6	Flexes neck anteriorly and laterally and slight rotation to opposite side
<b>–Inferior oblique part</b>	4	Anterior surface of bodies of vertebrae TII, TIII, and maybe TIII	Anterior tubercles of transverse processes of vertebrae CV and CVI		
<b>–Vertical part</b>	5	Anterior surface of bodies of TII to TIII and CV to CVII	Anterior surface of bodies of vertebrae CII to CIV		
<b>Longus capitis</b>	6	Tendinous slips to transverse processes of vertebrae CIII to CVI	Inferior surface of basilar part of occipital bone	Branches from anterior rami of C1 to C3	Flexes the head



## Constrictor muscles of the pharynx

Muscle		Posterior attachment	Anterior attachment	Innervation	Function
Superior constrictor	1	Pharyngeal raphe	Pterygomandibular raphe and adjacent bone on the mandible and pterygoid hamulus	Vagus nerve [X]	Constriction of pharynx
Middle constrictor	2	Pharyngeal raphe	Upper margin of greater horn of hyoid bone and adjacent margins of lesser horn and stylohyoid ligament	Vagus nerve [X]	Constriction of pharynx
Inferior constrictor	3	Pharyngeal raphe	Cricoid cartilage, oblique line of thyroid cartilage, and a ligament that spans between these attachments and crosses the cricothyroid muscle	Vagus nerve [X]	Constriction of pharynx



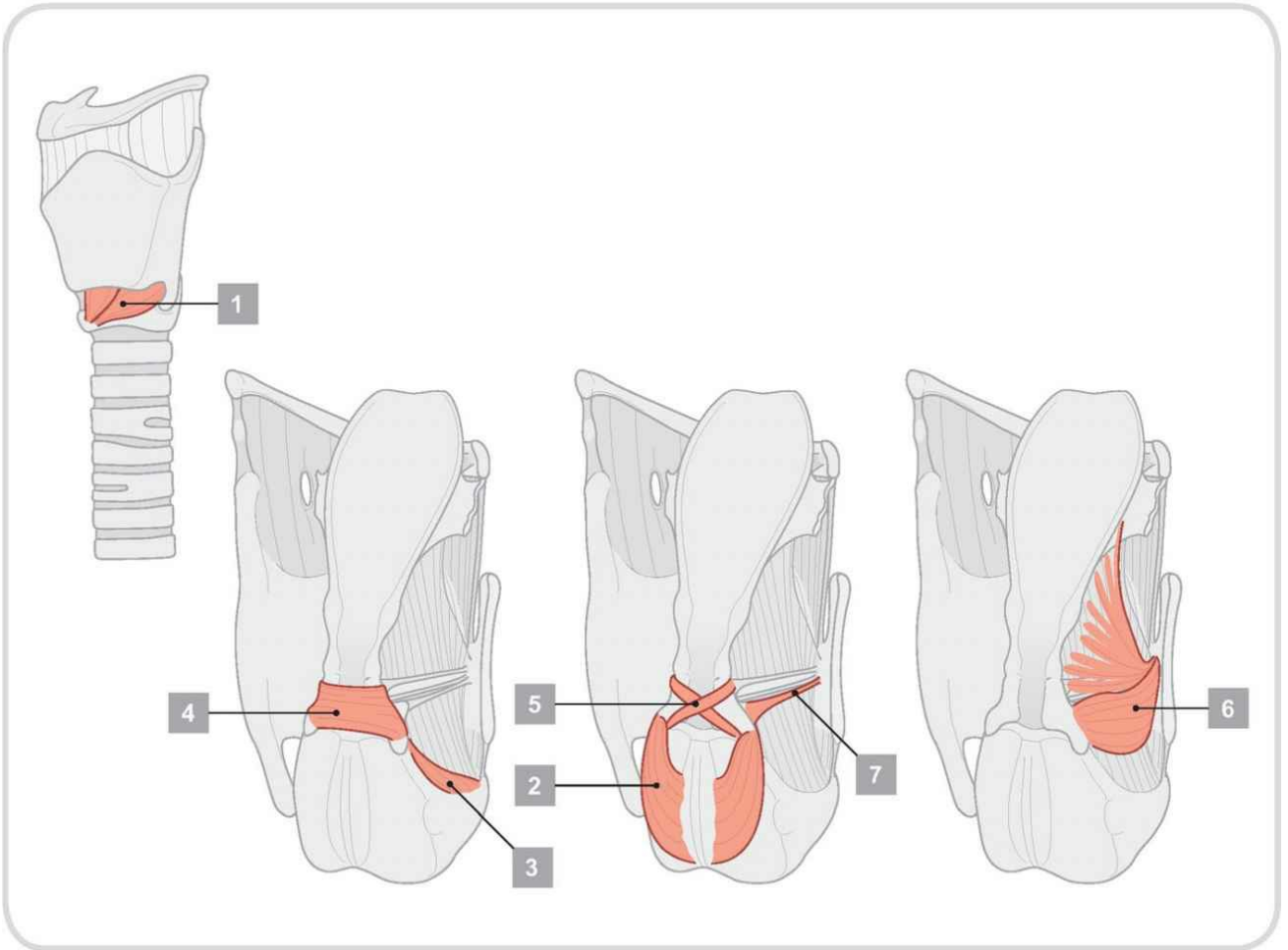
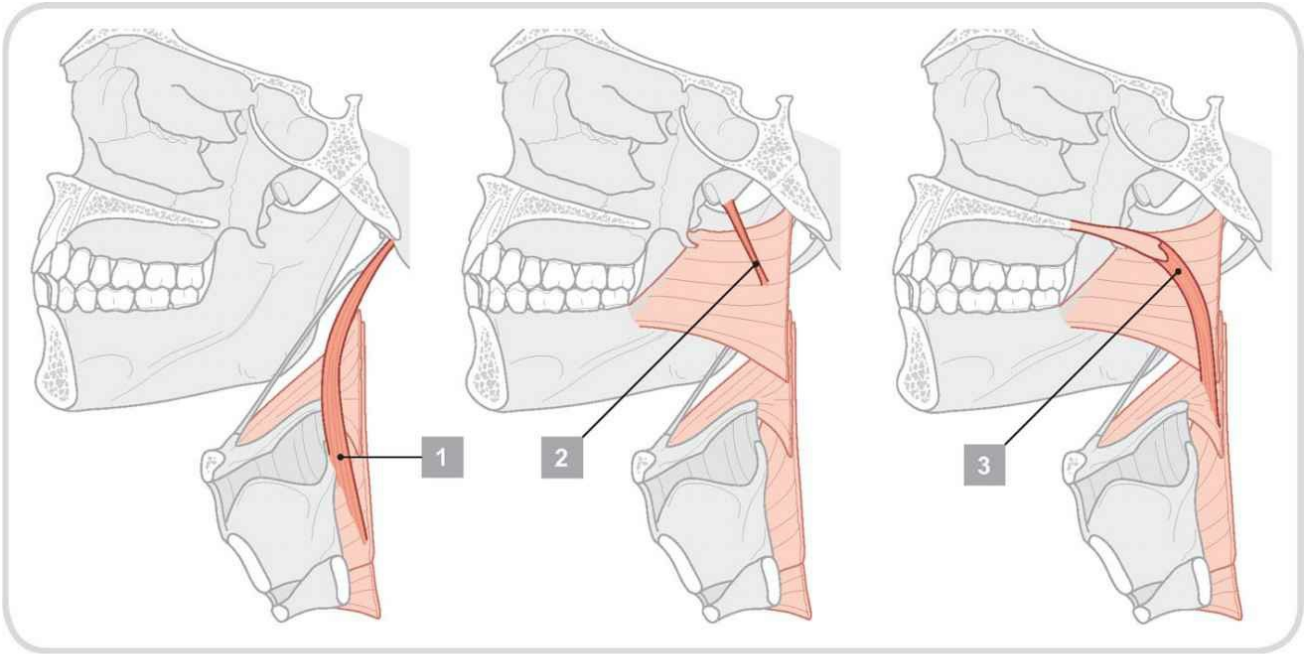


## Longitudinal muscles of the pharynx

Muscle		Origin	Insertion	Innervation	Function
<b>Stylopharyngeus</b>	1	Medial side of base of styloid process	Pharyngeal wall	Glossopharyngeal nerve [IX]	Elevation of the pharynx
<b>Salpingopharyngeus</b>	2	Inferior aspect of pharyngeal end of pharyngotympanic tube	Pharyngeal wall	Vagus nerve [X]	Elevation of the pharynx
<b>Palatopharyngeus</b>	3	Upper surface of palatine aponeurosis	Pharyngeal wall	Vagus nerve [X]	Elevation of the pharynx; closure of the oropharyngeal isthmus

## Intrinsic muscles of the larynx

Muscle		Origin	Insertion	Innervation	Function
<b>Cricothyroid</b>	1	Anterolateral aspect of arch of cricoid cartilage	Oblique part—inferior horn of the thyroid cartilage; straight part—inferior margin of thyroid cartilage	External branch of superior laryngeal nerve from the vagus nerve [X]	Forward and downward rotation of the thyroid cartilage at the cricothyroid joint
<b>Posterior crico-arytenoid</b>	2	Oval depression on posterior surface of lamina of cricoid cartilage	Posterior surface of muscular process of arytenoid cartilage	Recurrent laryngeal branch of the vagus nerve [X]	Abduction and external rotation of the arytenoid cartilage. The posterior crico-arytenoid muscles are the primary abductors of the vocal folds. In other words, they are the primary openers of the rima glottidis.
<b>Lateral crico-arytenoid</b>	3	Superior surface of arch of cricoid cartilage	Anterior surface of muscular process of arytenoid cartilage	Recurrent laryngeal branch of the vagus nerve [X]	Internal rotation of the arytenoid cartilage and adduction of vocal folds
<b>Transverse arytenoid</b>	4	Lateral border of posterior surface of arytenoid cartilage	Lateral border of posterior surface of opposite arytenoid cartilage	Recurrent laryngeal branch of the vagus nerve [X]	Adduction of arytenoid cartilages
<b>Oblique arytenoid</b>	5	Posterior surface of muscular process of arytenoid cartilage	Posterior surface of apex of adjacent arytenoid cartilage; extends into aryepiglottic fold	Recurrent laryngeal branch of the vagus nerve [X]	Sphincter of the laryngeal inlet
<b>Thyro-arytenoid</b>	6	Thyroid angle and adjacent cricothyroid ligament	Anterolateral surface of arytenoid cartilage; some fibers continue in aryepiglottic folds to the lateral margin of the epiglottis	Recurrent laryngeal branch of the vagus nerve [X]	Sphincter of vestibule and of laryngeal inlet
<b>Vocalis</b>	7	Lateral surface of vocal process of arytenoid cartilage	Vocal ligament and thyroid angle	Recurrent laryngeal branch of the vagus nerve [X]	Adjusts tension in vocal folds

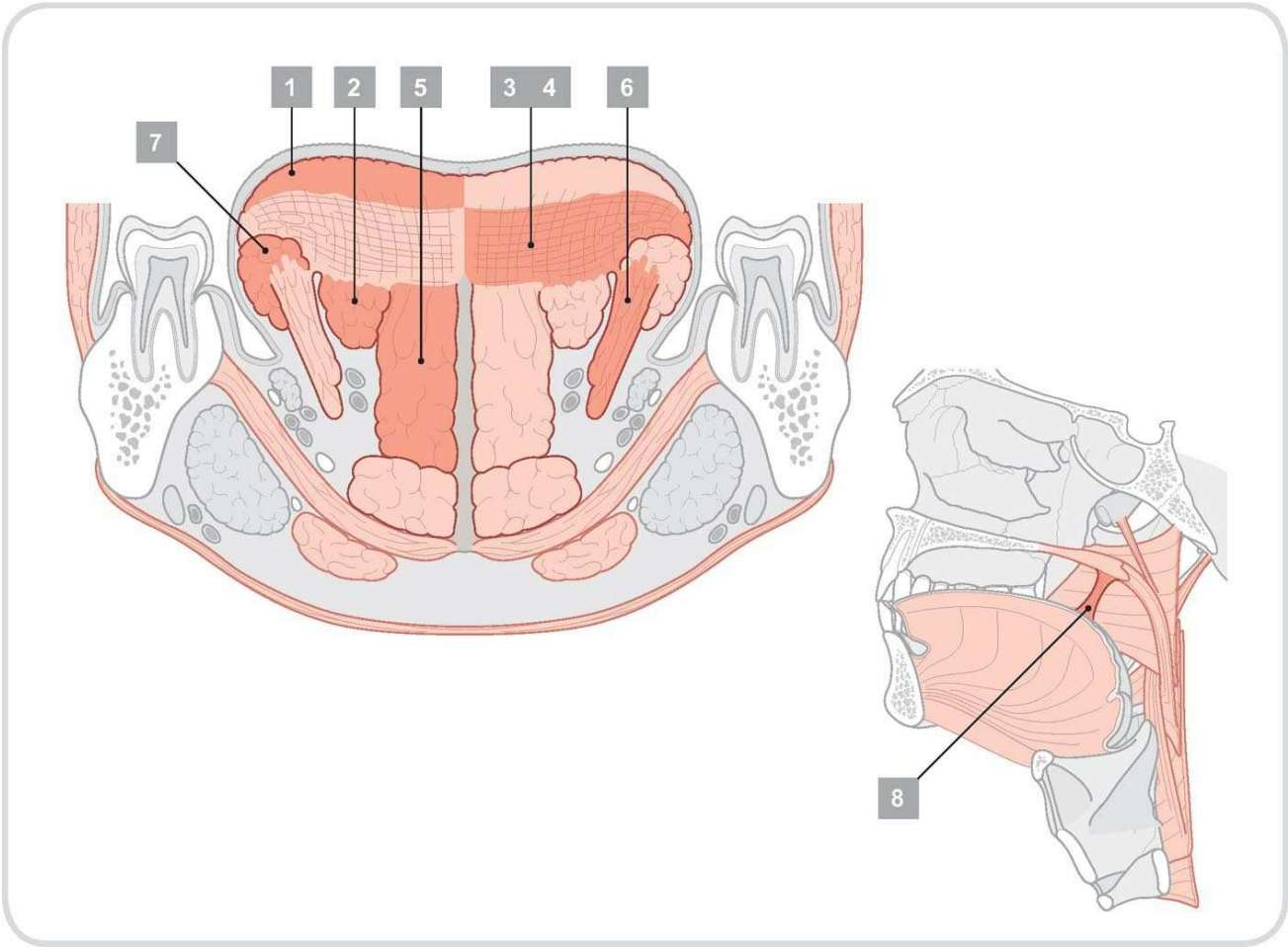
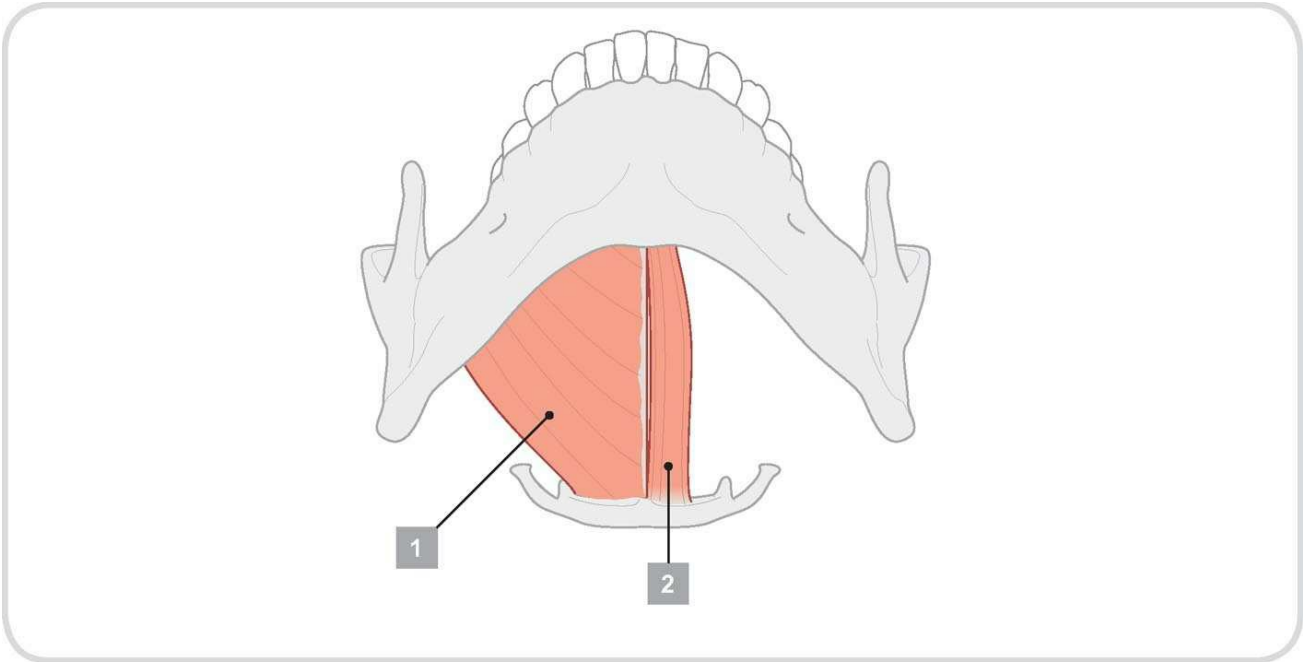


## Muscles in the floor of the oral cavity

Muscle		Origin	Insertion	Innervation	Function
Mylohyoid	1	Mylohyoid line of mandible	Median fibrous raphe and adjacent part of hyoid bone	Nerve to mylohyoid from the inferior alveolar branch of mandibular nerve [V <sub>3</sub> ]	
Geniohyoid	2	Inferior mental spines of mandible	Body of hyoid bone	C1	Supports and elevates floor of oral cavity; depresses mandible when hyoid is fixed; elevates and pulls hyoid forward when mandible is fixed

## Muscles of the tongue

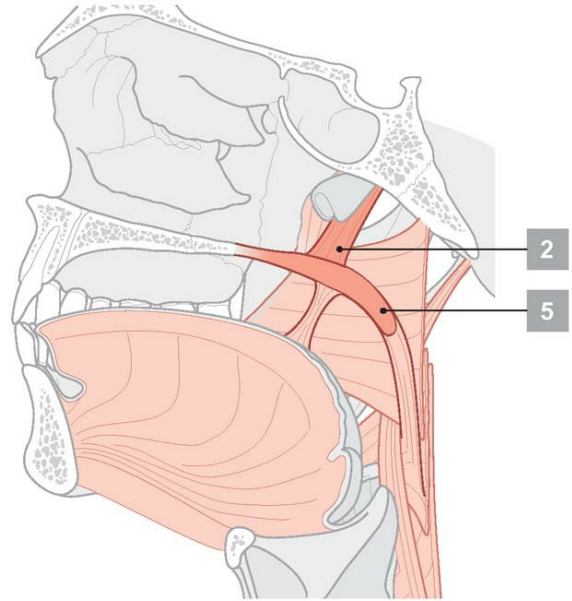
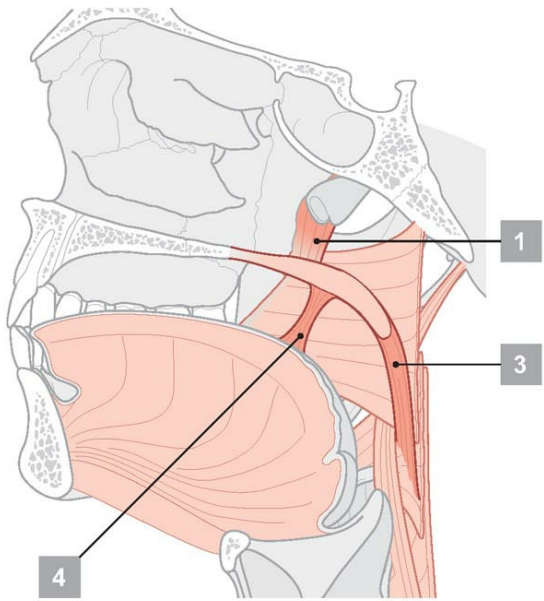
Muscle		Origin	Insertion	Innervation	Function
<b>Intrinsic</b>					
Superior longitudinal (just deep to surface of tongue)	1	Submucosal connective tissue at the back of the tongue and from the median septum of the tongue	Muscle fibers pass forward and obliquely to submucosal connective tissue and mucosa on margins of tongue	Hypoglossal nerve [XII]	Shortens tongue; curls apex and sides of tongue
Inferior longitudinal (between genioglossus and hyoglossus muscles)	2	Root of tongue (some fibers from hyoid)	Apex of tongue	Hypoglossal nerve [XII]	Shortens tongue; uncurls apex and turns it downward
Transverse	3	Median septum of the tongue	Submucosal connective tissue on lateral margins of tongue	Hypoglossal nerve [XII]	Narrows and elongates tongue
Vertical	4	Submucosal connective tissue on dorsum of tongue	Connective tissue in more ventral regions of tongue	Hypoglossal nerve [XII]	Flattens and widens tongue
<b>Extrinsic</b>					
Genioglossus	5	Superior mental spines	Body of hyoid; entire length of tongue	Hypoglossal nerve [XII]	Protrudes tongue; depresses center of tongue
Hyoglossus	6	Greater horn and adjacent part of body of hyoid bone	Lateral surface of tongue	Hypoglossal nerve [XII]	Depresses tongue
Styloglossus	7	Styloid process (anterolateral surface)	Lateral surface of tongue	Hypoglossal nerve [XII]	Elevates and retracts tongue
Palatoglossus	8	Inferior surface of palatine aponeurosis	Lateral margin of tongue	Vagus nerve [X] (via pharyngeal branch to pharyngeal plexus)	Depresses palate; moves palatoglossal fold toward midline; elevates back of the tongue





## Muscles of the soft palate

Muscle		Origin	Insertion	Innervation	Function
<b>Tensor veli palatini</b>	1	Scaphoid fossa of sphenoid bone; fibrous part of pharyngotympanic tube; spine of sphenoid	Palatine aponeurosis	Mandibular nerve [V <sub>3</sub> ] via the branch to medial pterygoid muscle	Tenses the soft palate; opens the pharyngotympanic tube
<b>Levator veli palatini</b>	2	Petrous part of temporal bone anterior to opening for carotid canal	Superior surface of palatine aponeurosis	Vagus nerve [X] via pharyngeal branch to pharyngeal plexus	Only muscle to elevate the soft palate above the neutral position
<b>Palatopharyngeus</b>	3	Superior surface of palatine aponeurosis	Pharyngeal wall	Vagus nerve [X] via pharyngeal branch to pharyngeal plexus	Depresses soft palate; moves palatopharyngeal arch toward midline; elevates pharynx
<b>Palatoglossus</b>	4	Inferior surface of palatine aponeurosis	Lateral margin of tongue	Vagus nerve [X] via pharyngeal branch to pharyngeal plexus	Depresses palate; moves palatoglossal arch toward midline; elevates back of the tongue
<b>Musculus uvulae</b>	5	Posterior nasal spine of hard palate	Connective tissue of uvula	Vagus nerve [X] via pharyngeal branch to pharyngeal plexus	Elevates and retracts uvula; thickens central region of soft palate



---

# INDEX

---

## A

### Abdomen

- arterial supply of viscera, [159](#)
- coronal section, [158](#)
- dermatomes, [207](#)
- imaging, coronal section, [158](#)
- innervation of, [201](#)
- lymphatics, [200](#)
- muscles of, [137–141](#)
- quadrants and regions of, [135](#)
- referred pain diagram, [204–205](#)
- sagittal section, [157](#)
- surface anatomy, [134](#)
- venous drainage of viscera, [182–183](#)
- visceral motor innervation, [203](#)
- visceral sensory innervation, [204–206](#)

### Abdominal aorta, [137](#), [156](#), [159](#), [301](#)

- branches of, [194](#)
- imaging, [196–197](#)
- positioning, [197](#)

### Abdominal esophagus, [160](#)

### Abdominal ostium, [245](#)

### Abdominal viscera, [155](#)

### Abdominal wall

- anterior, [153](#)
- arteries of, [143](#)
- dermatomes, [145](#)
- innervation of, [144–145](#)
- layers of, [136–137](#)
- posterior, [185](#)
- vessels of, [186](#)

- superficial veins, 184
- transverse section, 137
- vasculature of, 142

Abducent nerve, 500, 515, 586

Abductor digiti minimi, 359–362, 446, 448–449

Abductor hallucis, 358–362

Abductor pollicis brevis, 446, 448–449, 458

Abductor pollicis longus, 9, 433, 437–438

Abductor pollicis longus tendon, 442, 446–447

Accessory ligament, 66

Accessory nerve, 37, 500–501, 544, 587

Acetabular foramen, 299

Acetabular fossa, 296, 299–300

Acetabular labrum, 300

Acetabular ligament, transverse, 299–300

Acetabular roof, 300

Acetabulum, 214, 216, 222, 260, 296

Achilles tendon, 5

Acoustic meatus

- external, 522–523, 529
- internal, 487, 522–524, 526

Acromioclavicular joint, 62, 387, 390

Acromioclavicular ligament, 390, 399

Acromion, of scapula, 4–7, 20, 36, 39, 387–388

Adductor brevis, 8, 307, 311, 318

Adductor canal, 312

Adductor hallucis, 362

Adductor hiatus, 311–312, 329

Adductor longus, 8, 307–308, 311–312, 318

Adductor magnus, 8–9, 303, 307, 309, 311, 315–316, 318, 329

Adductor magnus tendon, 311

Adductor pollicis, 446, 448–449

Adductor tubercle, 306

Adrenal medulla, 206

Adventitia of great vessels, 93

Afferent lymphatic vessels, 12

Ala of nose, 568–569

Ala of sacrum, 214, 216, 222–223, 229, 296–297

Alar cartilage, 568–569

Alveolar arch, 486, 574

Alveolar artery

- anterior superior, 537, 578
- inferior, 509, 535, 578
- posterior superior, 537, 578

Alveolar bone, 577

Alveolar foramen, 529, 536

Alveolar nerve

- anterior superior, 537, 571, 578–579
- inferior, 530, 533, 578
- middle superior, 537, 578–579
- posterior superior, 537, 579

Alveolar plexus, superior, 537, 578

Alveolar process, 480

Alveolar vein

- anterior superior, 578
- inferior, 535, 559, 578
- posterior superior, 578

Ampulla, 526

Anal aperture, 229–231, 257–258, 260

Anal canal, 168, 224, 226, 232

- coronal section, 233
- in sagittal plane, 3

Anal columns, 233

Anal crypt, 233

Anal sinus, 233

Anal sphincter

- external, 233
- cutaneous part, 224, 226, 232
- deep part, 224, 226, 232
- superficial, 224, 226, 232
- internal, 224, 226, 232–233

Anal triangle, 257

Anal valve, [233](#)

Anastomotic loops, [46](#)

Anatomical position, [2](#)

Anatomical snuffbox, [458](#)

Anconeus, [414](#), [437](#)

Angular artery, [508](#), [512](#)

Angular gyrus, [496](#)

Angular vein, [508](#), [512](#), [517](#)

Ankle, [7](#), [337](#)

- bones, [295](#)
- imaging, [340](#)
- ligaments, [338–339](#)

Anococcygeal ligament, [230](#)

Anococcygeal nerves, [254](#)

Ansa cervicalis, [546–547](#), [581](#)

Antebrachial vein, [426](#), [459](#)

Anterior, as anatomical direction, [2](#)

Anterolateral central arteries, [502](#)

Anteromedial arteries, [502](#)

Anterosuperior margin of pubic symphysis, [223](#)

Antihelix, [522](#)

- crura of, [522](#)

Antitragus, [522](#)

Anular ligament, [422](#), [424–425](#), [435](#), [446](#)

Anulus fibrosus, [32–33](#)

Aorta

- abdominal, [74](#), [137](#), [156](#), [159](#), [301](#), [314](#)
- branches of, [194](#)
- imaging, [196–197](#)
- positioning, [197](#)
- retroperitoneal, [188](#)
- arch of, [10](#), [63](#), [74](#), [88](#), [99](#)
- ascending, [10](#), [74](#), [89](#), [94](#), [102](#)
- esophageal branches of, [118](#)
- thoracic, [10](#), [74](#), [82](#), [88–89](#), [101](#), [107](#)

Aortic arch, [502](#)

Aortic hiatus, 73, 186–187

Aortic nodes, 77, 200, 270–271

Aorticorenal ganglion, 201, 203

Aortic plexus, 201

Aortic valve, 100–101

- auscultation point for, 106

Apical foramen, 577

Apical segment, of lung, 87

Apicoposterior segment

- of bronchi, 87
- of lung, 87

Appendicular artery, 159

Appendix, 12, 168

- in coronal section of abdomen, 158
- orifice of, 170
- positions of, 170

Arachnoid mater, 48–49

Arachnoid trabeculae, 49

Arcuate artery, 348, 357

Arcuate eminence, 487

Arcuate ligament

- lateral, 185, 187
- medial, 73, 185, 187
- median, 73, 185–186

Arcuate line, 136, 140, 153

Arcuate line of ilium, 218, 221–223, 296

Areola, 4, 68–69

Arms

- anterior compartment, 410–411, 433–436
- arteries, 412, 416, 436, 439
- bones, 387
- compartments of, 410
- imaging, 419, 423, 425, 441
- lymphatics, 417, 459
- muscle attachments, 409, 411, 415, 432
- muscles, 410–411, 414–415, 434–435, 437–438



nerves, 412, 416, 420–421, 426, 436, 439, 460–461  
posterior compartment, 414–416, 437–439  
surface anatomy, 386, 410, 414, 433, 437  
transverse section, 418–419, 440  
veins, 413, 459

Arterial arcades, 167

Arteria rectae, 172

Arteries, 314. *See also individual arteries*

to abdominal viscera, 159

abdominal wall, 143

arm

anterior compartment, 412, 436

posterior compartment, 416, 439

to brain, 502, 504

imaging, 503

dural, 494

eyes, 517

foot, 356–357, 363–364

gluteal, 304–305

hand, 450–452, 456

hip joint, 301

infratemporal fossae, 535

knee, 329

leg, 344, 348

nasal cavity, 571

neck, 548–551

parotid region, 509

pelvic, 248

pterygopalatine fossa, 537

spleen, 162–163

stomach, 162–163

to teeth, 578

temporal fossae, 535

thigh, 313

thoracic wall, 74

thyroid gland, 566

- tongue, [581](#)
- Articular cartilage, [328](#), [425](#)
- Articular cavity, [328](#)
- Articular disc, [531](#)
- Articular facet
  - in elbow, [422](#)
  - vertebral, [24](#), [26](#)
- Articularis genus, [307](#)
- Articular process
  - column of, [23](#)
  - inferior, [22](#)
  - superior, [297](#)
- Articular tubercle, [486](#), [529](#), [531](#)
- Articulus genus, [328](#)
- Ary-epiglottic, [563](#)
- Ary-epiglottic fold, [555](#), [557](#), [562](#)
- Arytenoid
  - oblique, [557](#), [563](#)
  - transverse, [554](#), [557](#), [563](#)
- Arytenoid cartilage, [561–562](#)
- Ascending aorta, [10](#)
- Ascending colon, [154–155](#), [164](#), [168](#)
  - in coronal section of abdomen, [158](#)
- Asterion, [482](#)
- Atlanto-axial joint, [23](#)
  - lateral, [23](#)
- Atlanto-occipital joint, [501](#), [539](#)
- Atrioventricular bundle, [100](#), [105](#)
- Atrioventricular node, [105](#)
- Atrioventricular ring, [100](#)
- Atrium
  - left, [94–95](#), [98](#)
  - right, [63](#), [94–97](#), [101](#), [103](#)
- Auditory ossicles, [524](#)
- Auricular artery, posterior, [508–509](#), [548](#)
- Auricular muscle

- anterior, [507](#)
- posterior, [507](#)
- superior, [507](#)
- Auricular nerve, great, [544](#), [546–547](#)
- Auricular site for clavicle, [64](#)
- Auricular vein, posterior, [508](#), [535](#), [541](#)
- Auriculotemporal nerve, [505](#), [533–535](#)
- Auscultation, triangle of, [36–37](#)
- Auscultation points, [106](#)
- Axial plane, [2–3](#)
- Axilla, [68](#)
  - walls of, [398–399](#)
- Axillary artery, [10](#), [69](#), [403–404](#), [412](#)
- Axillary nerve, [13](#), [397](#), [405](#), [407](#), [416](#)
- Axillary nodes, [12](#), [143](#)
  - apical, [69](#)
  - central, [69](#)
  - lateral, [69](#)
  - pectoral, [69](#)
  - subscapular, [69](#)
- Axillary process, [68–69](#)
- Axillary vein, [413](#)
- Azygos vein, [11](#), [82](#), [119](#), [187](#)

## **B**

### **Back**

- cutaneous nerves, [53](#)
- dermatomes, [53](#)
- muscles of, [36–43](#)
  - deep, [40–41](#)
  - intermediate, [39](#)
  - suboccipital region, [43](#)
  - superficial, [37](#)
  - surface, [37](#)
  - transverse section, [42](#)
- surface anatomy of, [20](#), [36](#)

- transverse section of thoracic region, 52
- Bare area, of liver, 175
- Basal segment, posterior
  - of bronchi, 87
  - of lung, 87
- Basilar artery, 502
- Basilar membrane, 526
- Basilic vein, 11, 386, 396–397, 413, 426, 459
- Basivertebral vein, 47
- Benign prostatic hypertrophy, 238
- Biceps brachii, 8, 397, 410–411, 433
- Biceps brachii tendon, 8, 392, 433–434
- Biceps femoris, 9, 302, 307, 309, 315–316, 318, 342, 345
- Biceps femoris tendon, 5, 294, 315
- Bicipital aponeurosis, 410, 426, 433
- Bifid spinous process, 24
- Bifurcate ligament, 338–339, 354
- Bile duct(s), 165, 175, 179–180
- Bladder, 147–148, 150, 192, 224, 226, 239
  - apex of, 234
  - in coronal section of abdomen, 158
  - female, 235
  - imaging, 237–238
  - innervation of, 276
  - in situ, 232
  - male, 234
  - neck of, 234, 237
  - positioning, female, 235
  - in sagittal plane, 3
  - surface projection
    - female, 235
    - male, 234
  - transverse vesical fold, 239
- Body, surface of
  - anterior view, 4
  - posterior view, 5

Bone marrow, 12

Bones. *See also See Skeleton;individual bones*

Bony orbit, 510

Brachial artery, 10, 397, 402–404, 416, 426, 436

Brachialis, 8, 410–411, 426, 433–434

Brachial plexus, 13, 397, 405, 545

- cords of, 405–407

Brachial veins, 11, 413

Brachiocephalic nodes, 77

Brachiocephalic trunk, 10, 82–83, 88, 107, 110, 113, 502

Brachiocephalic vein

- in axial plane, 3
- left, 75, 82, 88, 101, 110, 566
- right, 11, 82, 101, 110, 566–567

Brachioradialis, 8, 410, 414, 426, 433, 437–438

Brain, 496–500

- arterial supply, 502, 504
- imaging, 503
- commissures, 497
- imaging, 497–499
- lobes, 497

Brainstem, 497

Breast, 4, 68–69

Bregma, 485

Bronchial arteries, 82–83, 118

Bronchial cartilage, 86

Bronchial tree, 86

Bronchomediastinal trunk, 77, 553

Bronchopulmonary segments, 87

Bronchus, 83

- inferior lobar, 86, 88
- left main, 86, 88–89
- middle lobar, 88
- right main, 89
- superior lobar, 86, 88

Buccal artery, 509, 535

Buccal nerve, [505](#), [533](#), [579](#)  
Buccinator, [8](#), [506–507](#), [530](#), [556](#), [582](#)  
Buccopharyngeal fascia, [540](#), [556](#), [582](#)  
Buck's fascia, [240](#), [242](#)  
Bulbospongiosus, [224](#), [237](#), [242](#), [257–258](#)  
Bulbo-urethral duct, [242](#)  
Bulbo-urethral gland, [236](#), [242](#), [261](#)  
Bundle branch, left, [105](#)  
Bursae  
    deep infrapatellar, [328](#)  
    glenohumeral joint, [394](#)  
    prepatellar, [328](#)  
    semimembranosus, [328](#)  
    subtendinous, [328](#)  
    suprapatellar, [328](#)

## C

Calcaneal artery  
    lateral, [363–364](#)  
    medial, [363–364](#)  
Calcaneal tendon, [5](#), [9](#), [294](#), [354](#)  
Calcaneal tubercle, [332](#)  
Calcaneal tuberosity, [294–295](#), [333](#), [358](#)  
Calcaneocuboid joint, [335](#)  
Calcaneocuboid ligament, [354](#)  
Calcaneofibular ligament, [338–339](#), [354](#)  
Calcaneometatarsal ligament, [358](#)  
Calcaneonavicular ligament, [339](#)  
Calcaneus, [7](#), [295](#), [332–334](#), [336](#)  
Calcarine sulcus, [496–497](#)  
Calyx  
    major, [190](#)  
    minor, [190](#)  
Camper's layer, [136–137](#)  
Canines, [575](#)  
Capitate, [428](#), [430](#), [442](#)

Capitis superior, oblique, 41

Capitulum, 6, 408

Capsule

- of lens, 518
- of lymph node, 12

Caput medusae, 184

Cardia, of stomach, 160

Cardiac branches (sympathetic), 110

Cardiac impression, 82–83

Cardiac nerves, sympathetic, 126, 547

Cardiac notch, 82–83, 166

Cardiac orifice, 171

Cardiac plexus, 88, 126

- deep, 107
- superficial, 107

Cardiac skeleton, 100

Cardiac vein(s)

- anterior, 102
- great, 94–95, 99, 102
- middle, 95, 102
- posterior, 102
- small, 94, 102

Cardial notch, of stomach, 160

Caroticotympanic nerve, 524

Carotid artery

- common, 508, 541, 548
  - in axial plane, 3
- left, 10, 74, 88, 101, 110, 113, 502, 550–551, 567
- right, 74, 82, 88, 101, 109–110, 402, 502, 550, 567

external, 494, 502, 508–509, 535, 548

- left, 10, 502, 566
- right, 567

internal, 502, 508, 548

- left, 10, 502, 566
- right, 502, 567

Carotid canal, 486, 525

Carotid nerve, internal, [537](#)  
Carotid sheath, [540](#)  
Carotid sinus, [502](#), [548](#)  
Carotid triangle, [538](#)  
Carpal arch, dorsal, [456](#)  
Carpal artery, [439](#)  
Carpal bones, [6](#), [387](#), [428](#)  
Carpal ligament, [431](#)  
Carpal tunnel, [442](#)  
    imaging, [443](#)  
Carpometacarpal joint, [428](#), [431](#)  
Cauda equina, [13](#), [33–34](#), [45](#), [48](#)  
Caudal, as anatomical direction, [2](#)  
Caudate lobe, of liver, [175](#), [177](#)  
Caudate process, [177](#)  
Caval opening, [73](#)  
Cavernous nerve, [256](#)  
Cavernous sinus, [495](#), [500](#), [502](#)  
Cecum, [155](#), [168](#), [170–171](#)  
    in coronal section of abdomen, [158](#)  
Celiac ganglion, [201](#), [203](#)  
Celiac nodes, [200](#), [270–271](#)  
Celiac trunk, [10](#), [159](#)  
    branching of, [163](#)  
    distribution of, [162](#)  
    imaging, [163](#)  
    positioning of, [163](#)  
Cement (dental), [577](#)  
Central arteries, [518](#)  
    anterolateral, [502](#)  
Central incisors, [575](#)  
Central nodes, [417](#)  
Central sulcus, [497](#)  
Central tendon of diaphragm, [73](#), [187](#)  
Central vein, [518](#)  
Cephalic vein, [11](#), [386](#), [396–397](#), [413](#), [459](#)



- Cerebellar artery
  - anterior inferior, 502, 504
  - posterior, 501
  - posterior inferior, 504
  - superior, 501–502, 504
- Cerebellar peduncles, 501
- Cerebellum, 50, 496–497, 501, 504
- Cerebral arterial circle, 502
- Cerebral artery
  - anterior, 502, 504
  - middle, 502, 504
  - posterior, 502, 504
- Cerebral hemispheres, blood supply, 504
- Cervical artery
  - ascending, 46, 548, 550–551
  - deep, 46, 550–551
  - transverse, 37–38, 402, 404, 548, 550–551, 566–567
- Cervical cardiac nerves, 88
- Cervical ganglia, 202, 546
- Cervical nerve(s), 44
  - transverse, 544, 546
- Cervical nodes, 12
  - anterior superficial, 552
  - deep, 552–553
  - posterior lateral, 552
  - superficial, 552
  - transverse, 552
- Cervical pleura, 80
- Cervical plexus, 13, 546–547
- Cervical vertebrae, 21–25, 388
- Cervical vertebral column, 50
- Cervix of uterus, 226, 243, 245, 247
- Cervix of vagina, 244
- Check ligament, medial, 511
- Chest wall
  - anterior female, 62

- anterior male, 62
- Chiasmatic sulcus, 487
- Choanae, 569–570
- Chordae tendineae, 97, 99
- Chorda tympani nerve, 523, 525, 533–534, 581
- Choroid, 511, 518
- Choroidal artery
  - anterior, 502
  - posterior lateral, 502
- Choroid plexus, 497
- Ciliary artery
  - anterior, 518
  - long posterior, 517–518
  - short posterior, 517–518
- Ciliary body, 518
- Ciliary ganglion, 515, 519
- Ciliary muscle, 518
- Ciliary nerves, 515
  - long, 519
  - short, 519
- Ciliary process, 518
- Cingulate gyrus, 496
- Circle of Willis, 502
- Circular muscle of esophagus, 556–557
- Circular muscle of rectum, 233
- Cisterna chyli, 12, 77, 119, 200
- Clavicle, 4, 6–7, 62–63, 71, 114, 387
  - articular surface for, 389
  - joints and ligaments, 390
  - muscle attachments, 390
- Clavicopectoral triangle, 410
- Clavipectoral fascia, 70, 397
- Clinoid process
  - anterior, 487
  - middle, 487
  - posterior, 487

## Clitoris

- crus of, [243](#), [264](#)
- dorsal artery of, [248](#), [268](#)
- dorsal nerve of, [269](#)
- dorsal vein of, [268](#)
- frenulum of, [259](#)
- glans of, [150](#), [226](#), [243](#), [258](#)
- suspensory ligament of, [264](#)

## Clivus, [487](#)

## Cluneal nerves

- inferior, [53](#), [273](#), [304](#), [316–317](#)
- medial, [53](#), [304](#)
- middle, [273](#)
- superior, [273](#)

## C1 nerve, [501](#), [544](#), [546](#)

## C2 nerve, [43](#), [53](#), [501](#), [544](#), [546](#)

## C3 nerve, [43](#), [53](#), [544](#), [546](#)

## C4 nerve, [544](#), [546](#)

## C5 nerve, [34](#), [544](#), [546](#)

## C6 nerve, [34](#), [544](#)

## C7 nerve, [34](#), [544](#)

## C8 nerve, [34](#), [544](#)

## Coccygeal cornu, [296](#)

## Coccygeal curvature, [21](#)

## Coccygeal nerves, [44](#)

## Coccygeal plexus, [254](#), [267](#), [273](#)

## Coccygeus, [229](#), [243](#), [247](#)

## Coccyx, [6–7](#), [21–22](#), [31](#), [214–218](#), [220–222](#), [228–229](#), [231](#)

## Cochlea, [522](#), [526](#)

## Cochlear duct, [526](#)

## Cochlear nerve, [522–523](#), [526](#)

## Colic artery

- left, [159](#), [172](#)
- middle, [159](#), [166](#), [172](#)
- right, [159](#), [166](#), [172](#)

## Colic flexure, [188](#)

- in coronal plane, 3
- right, 168, 188

Colic impression, on spleen, 161

Colic vein

- left, 182–183
- middle, 183
  - branch of, 182
- right, 183

Collateral branches, 72

Collateral ligaments, 353–354, 425, 431

Collateral sulcus, 496

Colliculus

- inferior, 497
- superior, 497

Colon

- ascending, 154–155, 159, 164, 166, 168
  - in coronal section of abdomen, 158
- descending, 154, 159, 164, 168, 188
- haustra of, 168
- sigmoid, 147, 159, 168, 171, 224, 226, 232
  - in coronal plane, 3
  - in coronal section of abdomen, 158
- transverse, 155, 159, 165, 168
  - in coronal plane, 3
  - in coronal section of abdomen, 158

Colonoscopy, 171

Commissural ligament, 445

Communicating artery

- anterior, 502, 504
- posterior, 502, 504

Communicating vein, 541

Compressor urethrae, 235, 261

Conduction system of heart, 105

Condylar process, 482, 574

Condyle

- in elbow

- lateral, 7
- medial, 7
- in knee
  - lateral, 295, 306
  - medial, 295, 306
- occipital, 486
- Cone of light, 523
- Conjoint tendon, 138, 140, 148, 150
- Conjunctiva, 511, 518
- Conjunctival fornix, 511
- Conjunctival sac, 511
- Conoid tubercle, 390
- Constrictor
  - inferior, 542, 556–557, 565, 583
  - middle, 530, 542, 556–557, 580, 583
  - superior, 530–531, 556, 580, 583–584
- Conus arteriosus, 97
- Conus elasticus, 561
- Conus medullaris, 13, 45
- Coraco-acromial ligament, 390, 392
- Coracobrachialis, 8, 410–411
- Coracoclavicular ligament, 390
- Coracohumeral ligament, 392
- Coracoid process, 6, 62, 70–71, 387–388, 397
- Cornea, 511, 518
- Corniculate cartilage, 561
- Corniculate tubercle, 555, 562–563
- Cornua, 31
- Coronal plane, 2–3
- Coronal suture, 482, 485
- Coronary artery(ies), 103
  - left, 94, 100, 102, 104
    - anterior interventricular branch, 102–104
    - circumflex branch, 102–104
    - diagonal anterior interventricular branch, 103
  - left-dominant system, 104

- right, 94, 100, 102–103
  - marginal branch, 103
  - posterior interventricular branch, 103
  - sinu-atrial nodal branch, 103
- right-dominant system, 103
- variations, 103–104
- Coronary ligament, 174
  - anterior, 175
  - posterior, 175
- Coronary sinus, 94, 96, 99, 102
- Coronary sulcus, 94, 100–102
- Coronary vessels, 102
- Coronoid fossa, 408, 422, 425
- Coronoid process, 422, 482, 574
- Corpus albicans, 244
- Corpus callosum, 497
- Corpus cavernosum, 224, 236, 240, 242, 262
- Corpus luteum, 244
- Corpus spongiosum, 224, 236–237, 240, 242, 262
- Corrugator supercilii, 506
- Costal cartilage, 64–65, 72
- Costal facet
  - inferior, 32
  - superior, 32
  - transverse, 32
- Costal groove, 72
- Costal margin, 4, 62, 125, 134, 396
- Costal pleura, 80, 114
- Costocervical trunk, 46, 548, 550–551
  - left, 74
  - right, 74
- Costochondral junction, 67
- Costoclavicular ligament, 390
- Costodiaphragmatic recess, 63, 79–81
- Costomediastinal recess, 79–81
- Costotransverse ligament, 32

Costovertebral joint, 66  
Costovertebral ligament, radiate, 32  
Costoxiphoid ligament, 67  
Cranial, as anatomical direction, 2  
Cranial cavity, 487  
Cranial fossa, 487  
Cranial nerves, 500–501, 586–587  
Cremasteric muscle, 137–138, 140, 147–148, 236, 240  
Cremasteric vessels, 148  
Cribriform plate, 487  
Crico-arytenoid  
    lateral, 563  
    posterior, 557, 563  
Cricoid arch, 562, 565  
Cricoid cartilage, 554, 556, 560–563, 565  
Cricopharyngeus, 565, 567  
Cricothyroid, 543, 556, 565  
Cricothyroid articular capsule, 86  
Cricothyroid joint, 560  
Cricothyroid ligament, 538, 565  
Cricothyroid muscle, 563  
Cricotracheal ligament, 560  
Cricovocal membrane, 561  
Crista galli, 487, 568–570  
Crista terminalis, 96  
Crown, of tooth, 577  
Cruciate ligaments, 325–327  
Cruciform ligament, 446  
Crura of antihelix, 522  
Crus of clitoris, 243, 264  
Crus of diaphragm  
    left, 119, 185, 187  
    right, 73, 119, 185, 187  
Crus of penis, 242, 262  
Cubital fossa, 4, 386, 426  
Cubital nodes (supratrochlear or epitrochlear), 12, 417, 459

Cubital vein, median, [11](#), [413](#), [426](#), [459](#)

Cuboid, [332–334](#)  
tuberosity of, [332](#)

Cuneiform  
intermediate, [332–334](#)  
lateral, [332](#), [334](#)  
medial, [332–334](#)

Cuneiform cartilage, [561](#)

Cuneiform tubercle, [555](#), [562–563](#)

Cuneocuboid ligament, [354](#)

Cuneonavicular ligaments, [354](#)

Cuneus, [497](#)

Cupula, [80](#)

Cutaneous nerve(s), [17](#)  
arm, [402](#), [416](#), [420–421](#), [426](#), [436](#), [460–461](#)  
femoral lateral, [273](#)  
femoral posterior, [254](#), [273](#)  
lateral  
of thigh, [198–199](#)  
T3-T11, [125](#)  
T7-T11, [145](#)  
lateral cutaneous branch of, [76](#)  
legs, [349](#)  
perforating, [254](#)  
perineal, [273](#)  
sural, [349](#)  
thoracic, [125](#)

CI vertebra, [7](#), [21](#), [23–25](#), [501](#)  
posterior ramus of, [43](#)  
transverse process of, [43](#)

CII vertebra, [7](#), [21](#), [23–24](#), [50](#), [539](#)  
posterior ramus of, [43](#)  
spinous process of, [23](#), [40–41](#), [43](#)  
transverse process of, [43](#)

CIII vertebra, [23](#), [539](#)  
posterior ramus of, [43](#)



- spinous process of, 23
- CIV vertebra, 23–24, 539
- CV vertebra, 22–24, 539
- CVI vertebra, 23, 539
- CVII vertebra, 6, 539
  - spinous process of, 71
- Cisterna chyli, 270–271
- Cystic artery, 159, 163, 181
- Cystic duct, 165, 179–180

## D

- Dartos fascia, 236, 240
- Deciduous teeth, 575
- Decussation of pyramids, 501
- Deep artery
  - of penis, 242
  - of thigh, 10, 301, 314, 317–318
- Deep nodes, 12
- Deep palmar arch, 10
- Deep vein, of thigh, 11, 318
- Deltoid, 4–5, 8–9, 37, 396–397, 410, 414, 542
- Deltoid fascia, 542
- Deltoid ligament of ankle, 338
- Deltoid tuberosity, 391
- Demifacet for articulation, vertebral, 22
- Dens, 24
- Denticulate ligament, 49
- Dentine, 577
- Depressor anguli oris, 506–507
- Depressor labii inferioris, 506–507
- Depressor septi, 506
- Dermatomes
  - abdominal, 207
  - abdominal wall, 145
  - arms, 461
  - in back, 53

- legs, 368–369
- perineal, 273
- thoracic, 125

Descending colon, 154, 159, 168, 188

Detrusor muscle, 232

Diaphragm, 73, 79

- central tendon of, 73, 187
- in coronal plane, 3
- costal, 73
- crus of
- features of, 73
- inferior view, 187
- left dome of, 63
- lumbar part, 73
- positioning of, 187
- right dome of, 63

Diaphragma sellae, 494, 500

Diaphragmatic nodes, 77

Diaphragmatic pleura, 80, 114

Diaphragmatic surface of heart, 94

Diencephalon, 497

Digastric, 543

Digital arteries

- dorsal, 348, 356–357, 458
- palmar, 450–452, 456
- plantar, 363–364

Digital nerves

- dorsal, 457
- palmar, 450, 453, 457–458
- plantar, 363

Digital phalanx, 332

Digital veins

- dorsal, 459
- palmar, 459

Digiti minimi, 358

Dilator pupillae, 518

Directions, anatomical, [2](#), [575](#)

Distal, as anatomical direction, [2](#), [575](#)

Dorsal hood, [365](#)

Dorsalis pedis artery, [10](#), [348](#), [356–357](#)

Dorsum

- of foot, [2](#), [4](#), [355](#)
- of hand, [2](#), [454](#)
- of nose, [568](#)

Dorsum sellae, [487](#), [536](#)

Ductus deferens, [147–149](#), [224](#), [233](#), [239–240](#)

- ampulla of, [236](#), [238–239](#), [242](#)
- artery of, [241](#)
- left, [236](#)
- positioning, [237](#)
- right, [236](#)

Duodenal cap, [164](#)

Duodenal papilla

- major, [165](#), [179](#)
- minor, [179](#)

Duodenojejunal flexure, [165](#), [167](#), [179](#)

Duodenum, [159](#), [164–165](#)

- ascending part, [164–165](#)
- in coronal section of abdomen, [158](#)
- descending part, [164–165](#), [188](#)
- imaging, [165](#), [171](#)
- inferior part, [164–165](#)
- in situ, [164](#)
- superior part, [164–165](#)
- suspensory muscle of, [165](#)
- vasculature of, [181](#)

Dural arteries, [494](#)

Dural nerves, [494](#)

Dural partitions, [492](#)

Dural sheath, [511](#)

## E

Ear(s), 523

imaging, 527

internal, 522–523, 526

left, 94, 97, 99, 101

middle, 524

right, 96–97

surface anatomy, 522

Efferent ductules, 241

Efferent lymphatic vessel, 12

left, 119, 185, 187

right, 73, 119, 185, 187

Ejaculatory duct, 236, 238

beginning of, 239

opening of, 237

Elbow joint, 7, 387, 422–425

Emissary veins, 535, 578

Enamel (dental), 577

Endocardium, 93

Endometrium, 244

Endoscopy, GI tract, 171

Endothoracic fascia, 72

Epicardium, 124

Epicondyle

in elbow

lateral, 6–7, 388, 408, 422, 424, 434–435

medial, 6–7, 388, 408, 422, 424, 434–435

in knee

lateral, 295, 306

medial, 306

Epicranial aponeurosis, 506–507

Epididymis, 147

appendix of, 240

body of, 241

head of, 149, 236, 241

tail of, 241

Epigastric artery

inferior, 142–143, 147, 224, 226, 248–249  
    left, 149, 151  
    right, 148, 150  
superficial, 143, 240, 301, 314  
superior, 73, 142–143, 187  
    right, 74

Epigastric region, 135

Epigastric vein  
    inferior, 142, 147, 224, 226, 248–249  
    left, 149, 151  
    right, 148, 150  
    superficial, 240, 366  
    superior, 142  
    right, 75

Epigastric vessels, inferior, 141

Epiglottis, 554, 557, 560–563, 582

Epiphyseal plate, 300

Episcleral space, 518

Epitrochlear nodes, 417, 459

Epitympanic recess, 523, 525

Epoöphoron, 245

Erectile muscles  
    female, 264  
    male, 262

Erectile tissue  
    female, 264–265  
    male, 262–263

Erector spinae, 9, 36, 40–42, 52, 137

Esophageal artery, 159

Esophageal branches, 162

Esophageal hiatus, 73, 185

Esophageal impression, on liver, 175

Esophageal mucosa, 160

Esophageal plexus, 116, 118

Esophageal varices, 184

Esophageal vein, 184

Esophagus, 82, 88, 554–555  
    abdominal, 160  
    in axial plane, 3

Ethmoidal artery  
    anterior, 517, 571  
    posterior, 517, 571

Ethmoidal bulla, 568–569

Ethmoidal cells, 568

Ethmoidal foramen  
    anterior, 510  
    posterior, 510

Ethmoidal nerve, 494, 515, 571

Ethmoid bone, 479, 487–488, 510, 536, 569

Excretory duct of lacrimal gland, 512

Extensor carpi radialis brevis, 414, 437

Extensor carpi radialis brevis tendon, 442

Extensor carpi radialis longus, 9, 414, 437–438

Extensor carpi radialis longus tendon, 442

Extensor carpi ulnaris, 414

Extensor carpi ulnaris tendon, 442

Extensor digiti minimi, 437

Extensor digiti minimi tendon, 442

Extensor digitorum, 9, 414, 437

Extensor digitorum longus, 8, 345–347

Extensor digitorum tendon, 442

Extensor hallucis longus, 8, 347

Extensor hood, 365

Extensor indicis, 9, 438, 442

Extensor pollicis brevis, 9, 437–438

Extensor pollicis brevis tendon, 442

Extensor pollicis longus, 9, 438

Extensor pollicis longus tendon, 442

Extensor retinaculum, 358, 437

Extensor tendons, 294

Extradural fat, 47

Extraperitoneal fascia, 137, 141, 148, 150

Eyeball, 518  
Eyelash, 511  
Eyelid, 511–512  
    inferior, 510  
    superior, 510  
Eyes, 6  
    imaging, 519–521  
    movements, 516  
    muscles, 514  
    nerves, 515, 518  
    sagittal section, 511  
    vasculature, 517

## F

Facial artery(ies), 10, 502, 508, 548  
    transverse, 508–509, 512  
Facial canal, prominence of, 524  
Facial lymphatics, 508  
Facial muscles, 506–507  
Facial nerve, 501, 508–509, 513, 523–524, 534, 587  
Facial nodes, 508, 552  
Facial surface anatomy, 510  
Facial vasculature, 508  
Facial vein, 11, 508, 517, 535, 541  
    common, 541  
    deep, 509, 559  
    transverse, 508–509  
Falciform ligament, 141, 153, 166  
False ribs, 64  
Fat, extradural, 47  
Femoral artery, 142–143, 147–148, 150, 240, 317–318, 329  
    lateral circumflex, 304, 314, 317  
        ascending branch of, 301, 313–314  
        descending branch of, 10, 301, 316–317  
        transverse branch of, 10, 301, 313–314  
left, 194

- medial circumflex, 301, 304–305, 314, 316–317
- Femoral branch, 198
- Femoral cutaneous vein, 366
- Femoral head, ligament of, 299–300
- Femoral nerve, 13, 198, 305, 312–313
  - intermediate cutaneous branch, 199
  - medial cutaneous nerve from, 199
  - muscular branches, 313
- Femoral nodes, 12
- Femoral sheath, 312
- Femoral triangle, 312
- Femoral vein, 11, 142–143, 147–148, 150, 240, 318
- Femur, 6–7, 295, 297
  - distal end, 306
  - fovea of, 298
  - greater trochanter of, 228
  - head of, 298–300
  - lesser trochanter of, 228
  - neck of, 297–298, 300
  - proximal, 298
  - shaft of, 298
- Fibrocartilaginous joint, 67
- Fibroelastic membrane, 561
- Fibromuscular stroma, 234, 237
- Fibrous capsule, of kidney, 190
- Fibrous pericardium, 92–93, 124
- Fibrous ring, of aortic valve, 100
- Fibrous trigone, 100
- Fibula, 7, 331
  - head of, 4, 6, 294–295
  - proximal end, 306
- Fibular artery, 10, 344, 348
  - circumflex, 329
- Fibular collateral ligament, 310, 322
- Fibularis brevis, 342, 345–347
- Fibularis brevis tendon, 9, 294, 338, 353



Fibularis longus, 8–9, 302, 342, 345–347  
Fibularis longus tendon, 294, 338, 353  
Fibularis tertius, 347  
Fibular nerve, 13  
    common, 316–317, 344, 348  
    deep, 348–349, 356–357  
    superficial, 348–349, 356  
Fibular retinaculum, 338  
Fibular trochlea, 332–333  
Fibular vein, posterior, 11  
Filiform papillae, 582  
Filum terminale, 44–45  
Fimbriae, 244  
Flank  
    left, 135  
    right, 135  
Flexor carpi radialis, 8, 410, 426, 433–434  
Flexor carpi radialis tendon, 433–434, 442, 446–447  
Flexor carpi ulnaris, 9, 414, 426, 433–434  
Flexor carpi ulnaris tendon, 434, 446–447  
Flexor digiti minimi, 446  
Flexor digiti minimi brevis, 359–362, 448–449  
Flexor digitorum brevis, 359–360  
Flexor digitorum longus, 9, 343, 359  
Flexor digitorum longus tendon, 353  
Flexor digitorum profundus, 8, 435, 438  
Flexor digitorum profundus tendons, 433–434, 442, 446–447  
Flexor digitorum superficialis, 433–435  
Flexor digitorum superficialis tendons, 433–434, 442, 446–448  
Flexor hallucis brevis, 359–362  
Flexor hallucis longus, 9, 343, 362  
Flexor hallucis longus tendon, 353  
Flexor pollicis brevis, 446, 448–449  
Flexor pollicis longus, 8, 433–435  
Flexor pollicis longus tendon, 433–434, 442, 446–447  
Flexor retinaculum, 365, 433–434, 442, 446–447

Floating ribs, [64](#)

Foliate papillae, [582](#)

Foot

arteries, [356–357](#), [363–364](#)

bones of, [295](#), [332–335](#)

dorsum of, [2](#), [4](#), [355](#)

innervation, [356–357](#), [363–364](#)

joints, [335](#)

ligaments, [353–354](#)

median longitudinal arch, [333](#)

muscle attachments, [352](#)

musculature, plantar, [359–362](#)

plantar surface of, [2](#)

surface anatomy, [355](#)

transverse arch, [333](#)

Foramen lacerum, [486](#), [574](#)

Foramen magnum, [486–487](#), [502](#)

Foramen ovale, [486–487](#), [522](#), [529](#), [531](#), [536](#)

valve of, [98](#)

Foramen rotundum, [487](#), [536](#)

Foramen spinosum, [486–487](#), [529](#), [534–535](#)

Foramen transversum, [24](#)

Foregut, innervation of, [203–205](#)

Fornix, [497](#)

Fossa ovalis, [96](#)

limbus of, [96](#)

Fourchette, [259](#)

Fovea centralis, [518](#)

Fovea of femur, [298](#)

Free taenia, [170](#)

Frontal bone, [6](#), [479–480](#), [482](#), [485](#), [510](#), [529](#), [569](#)

Frontal crest, [487](#)

Frontalis, [8](#)

Frontal lobe, [497](#), [504](#)

Frontal nerve, [515](#)

Frontal operculum, [496](#)

Frontal process of maxilla, 480  
Frontal process of zygomatic bone, 528  
Frontal sinus, 554, 568–570  
Frontal suture, 479–480  
Frontobasal artery, lateral, 504  
Frontonasal duct, 569  
Fundiform ligament of penis, 240, 242, 262  
Fundus, of bladder, 234  
Fungiform papillae, 582

## G

Gallbladder, 154–155, 165, 178–179  
    body of, 175, 179  
    in coronal plane, 3  
    in coronal section of abdomen, 158  
    neck of, 175, 179  
    positioning of, 179  
Ganglion impar, 202, 255–256  
Gastric artery(ies)  
    left, 159, 162, 181  
    right, 159, 162, 181  
    short, 159, 162, 181  
Gastric canal, 160  
Gastric folds, 160  
Gastric impression  
    of liver, 175  
    of spleen, 161  
Gastric mucosa, 160  
Gastric vein  
    left, 182–183  
    right, 183  
    short, 182–183  
Gastric vessels, short, 161  
Gastrocnemius, 5, 8–9, 294, 302, 307, 309, 342, 345–346  
Gastroduodenal artery, 159, 162–163, 165, 181  
    branches of, 162

Gastroesophageal junction, 171

Gastrointestinal tract, imaging, 171

Gastro-omental artery

- left, 159, 161–162, 181
- right, 159, 162–163

Gastro-omental vein

- left, 161, 181–183
- right, 183

Gemellus inferior, 9, 303, 315

Gemellus superior, 9, 303, 307, 315

Genicular artery

- descending, 314, 317, 329
  - articular branch, 313–314, 317
  - saphenous branch, 313–314, 317, 329
- inferior lateral, 314, 316–317, 329, 344
- inferior medial, 316–317, 329, 348
- medial genicular, 314
- superior lateral, 313–314, 316–317, 329, 344
- superior medial, 316–317, 329, 344

Geniculate ganglion, 522, 524, 537

Genioglossus, 554, 580, 582–583

Geniohyoid, 554, 580, 582

Genital branch, 198

Genitofemoral nerve, 198–199

- femoral branch of, 148, 150, 199, 305
- genital branch of, 147–149, 151, 153, 240

Gingiva, 577, 579

Glabella, 480

Glans of clitoris, 150, 226, 243, 258

Glans penis, 4, 20, 214, 236, 242, 252, 262

Glenohumeral joint, 392–394, 401

Glenohumeral ligament, 392

Glenoid cavity, 389

Glenoid labrum, 400

Glossoepiglottic fold, 582

Glossopharyngeal nerve, 500–501, 534, 545–546, 558, 581, 587

Gluteal artery  
inferior, 194, 248, 304–305, 314, 316–317  
superior, 194, 248, 250, 266, 301, 304, 314, 316–317  
  deep branch of, 304–305, 316–317  
  superficial branch, 305, 316–317

Gluteal fold, 5, 215, 217, 294

Gluteal line  
inferior, 296  
posterior, 296

Gluteal nerve  
inferior, 254, 256, 267, 304  
superior, 254–256, 267, 304–305, 317

Gluteal region, 302–304

Gluteal surface, 217, 222, 296

Gluteal tuberosity, 298

Gluteal vein  
inferior, 304  
superior, 249–250, 266, 304  
  right, 195

Gluteus maximus, 9, 257–258, 294, 303–304, 307, 309, 318

Gluteus medius, 9, 303–304, 307, 309

Gluteus minimus, 303, 307

Gonadal vein, left, 182

Gonadal vessels, 192  
  left, 186  
  right, 186, 192

Gracilis, 8–9, 303, 308–309, 311–312, 318, 342

Gracilis tendon, 311

Granular foveolae, 485

Gray ramus communicans, 78, 255, 405

Greater omentum, 154

Greater trochanter, 6–7

Greater tubercle, 6–7

Great saphenous vein, 11

Great vessels, adventitia of, 93

Groin

left, [135](#)

right, [135](#)

Gut tube, [137](#)

## H

Hair cells

inner, [526](#)

outer, [526](#)

Hallucis longus, extensor, [8](#)

Hamate, [428](#), [430](#), [442](#)

Hamulus, [486](#)

Hands

arteries, [450–452](#), [456](#)

bones, [387](#), [428](#), [430](#)

dorsal hoods, [455](#)

dorsum of, [454](#)

imaging, [429](#)

joints, [431](#)

ligaments, [431](#)

lymphatics, [459](#)

muscle attachments, [444](#)

muscles, [448–449](#)

nerves, [450–451](#), [453](#), [457](#)

surface anatomy, [386](#), [445](#), [454](#)

tendon sheaths of, [446](#)

veins, [459](#)

Hard palate, [486](#), [554](#), [556](#), [583](#)

Haustra of colon, [168](#)

Head

nerves, [588](#)

surface anatomy, [478](#)

Head of fibula, [4](#)

Heart

anterior surface of, [94](#)

base of, [95](#)

chambers of, [101](#)

- computed tomography of, 94
- conduction system of, 105
- in coronal plane, 3
- diaphragmatic surface of, 95
- innervation of, 107
  - visceral afferents, 127
  - visceral motor, 126
- posterior view of, 94–95
- sounds, 106
- valves of, 101
- vasculature, 102–104
- visceral afferents from, 127

Helicotrema, 526

Helix, 522

Hemi-azygos vein, 75, 82, 119, 187

- accessory, 47, 75, 83, 116

Hemorrhoids, 184

Hepatic artery

- common, 10, 159, 162–163, 181
  - distribution of, 181
- left, 159, 181
- proper, 158–159, 162, 165
  - left branch, 176
  - right branch of, 176
- right, 159, 181

Hepatic duct

- common, 165, 176, 179–180
- in coronal section of abdomen, 158
- left, 179–180
- right, 179, 181

Hepatic vein(s), 11, 162, 186, 195

- arrangement of, 176
- in coronal section of abdomen, 158
- entering inferior vena cava, 176
- intermediate, 176
- left, 176

- right, 176
- Hepatoduodenal ligament, 166
- Hepatopancreatic ampulla, 179
- Hernias, inguinal, 152
  - direct, 152
  - indirect, 152
- Hesselbach's triangle, 152–153
- Hiatus semilunar, 569–570
- Hilum, 82, 110
  - of spleen, 161
- Hindgut, innervation of, 203–205
- Hip joint, 7, 295, 299–300
  - arterial supply, 301
  - ligaments, 311
- Hoods, dorsal, of hand, 455
- Horizontal fissure, 81–82
- Horizontal plane, 2
- Humeral artery
  - anterior circumflex, 10, 397, 402–404, 412, 416
  - posterior circumflex, 397, 402–404, 412, 416
- Humeral ligament, 392
  - transverse, 398, 401
- Humeral nodes, 417
- Humeral nutrient artery, 404, 412, 416
- Humeral vein
  - anterior circumflex, 413
  - posterior circumflex, 413
- Humeroradial joint, 422
- Humero-ulnar joint, 422
- Humerus, 6–7, 36–37, 70, 387–388
  - distal end, 408
  - greater tubercle, 391
  - head of, 391
  - lesser tubercle, 391
  - middle facet, 391
  - neck of, 391



- proximal, 391
- superior facet, 391
- Hyaline cartilage, 32
- Hyaloid canal, 518
- Hymen, 259
- Hyoepiglottic ligament, 560–561, 582
- Hyoglossus, 556, 580–581
- Hyoid bone, 539, 554, 562–563
- Hypochondrium
  - left, 135
  - right, 135
- Hypogastric nerve, 274
  - left, 255
  - right, 201–202, 255–256
- Hypogastric plexus, 201, 256
  - inferior, 203, 255–256, 274
  - superior, 201–202, 256, 274
- Hypoglossal canal, 486–487
- Hypoglossal nerve, 500–501, 544, 547, 581, 587
- Hypophyseal arteries, 502
- Hypophyseal fossa, 487, 536, 569
- Hypothalamic sulcus, 497
- Hypothalamus, 497
- Hypothenar eminence, 386, 445, 448
- Hypothenar muscles, 8, 436

## I

- Ileal artery, 166, 172
- Ileal vein, 166, 182–183
- Ileocecal fold, 170
- Ileocecal fold flaps, 170
- Ileocecal junction, 170
  - in coronal section of abdomen, 158
- Ileocolic artery, 159, 172
  - in coronal section of abdomen, 158
- Ileocolic vein, 183

- in coronal section of abdomen, 158
- Ileum, 166–168, 170
  - in coronal section of abdomen, 158
  - imaging, 167
- Iliac artery
  - common, 224, 226, 313–314
    - left, 10, 253
    - retroperitoneal, 188
    - right, 186, 192, 194, 248–249
  - deep circumflex, 142–143, 149, 151, 194, 248, 301, 314
  - external, 143, 148, 150, 194, 224, 226, 248–249, 301, 313
    - left, 10, 192
    - retroperitoneal, 188
    - right, 266
  - internal, 194, 200, 224, 226, 248, 266, 301
    - anterior trunk, 266
    - left, 10, 192
    - right, 192, 250
  - superficial circumflex, 142–143, 301, 314
- Iliac crest, 5, 7, 20, 36, 39–41, 214–218, 222, 228–229, 297
  - tubercle of, 296
- Iliac fossa, 198, 214, 216, 218, 296–297
- Iliac nodes, 12
  - common, 200, 270–271
  - external, 200, 270–272
  - internal, 200, 270–272
- Iliac spine
  - anterior inferior, 222–223, 297
  - anterior superior, 4, 134, 220, 222–223, 228–229, 295, 297
  - posterior inferior, 296
  - posterior superior, 7, 40, 222, 228–229, 295–297
- Iliac tuberosity, 296
- Iliacus, 147, 153, 166, 185, 224, 226, 233, 307–308, 310, 312–313
- Iliacus fossa, 312
- Iliac vein(s)
  - common, 195, 224, 226, 253

- left, 11, 192
- right, 249
- deep circumflex, 142, 149
- external, 11, 148, 150, 184, 224, 226, 248–249
  - left, 186, 192, 195
  - right, 192, 195, 266
- internal, 11, 224, 226, 249, 253, 266
  - anterior trunk, 266
  - left, 250
  - right, 195
- superficial circumflex, 142, 366
- Iliococcygeus, 229–231, 233, 247, 260, 262, 264
- Iliocostalis, 40, 71
- Iliocostalis cervicis, 40, 71
- Iliocostalis lumborum, 40
- Iliocostalis thoracis, 40
- Iliofemoral ligament, 228, 301
- Iliohypogastric nerve, 53, 144, 198, 305
  - anterior cutaneous branch of, 145, 199
  - lateral cutaneous branch of, 144, 199
- Ilio-inguinal nerve, 144, 148, 150, 198–199, 240, 273, 305
- Iliolumbar artery, 194, 248, 250
  - iliac branch of, 194
- Iliolumbar ligament, 220
- Iliolumbar vein, 250
- Iliopsoas, 8, 307, 310, 318
- Iliopubic eminence, 218
- Iliotibial tract, 8–9, 294, 302, 308, 318, 329
- Ilium, 6, 296
  - arcuate line, 218, 222–223
  - gluteal surface of, 215, 222
- Imaging, of spinal cord, 50–51
- Incisive canal, 569
- Incisive fossa, 486, 574, 583
- Incisive nerve, 533, 578
- Incisors, 575

Incus, [523–525](#)  
    ligament of, [525](#)

Inferior, as anatomical direction, [2](#)

Infraclavicular nodes, [417](#)

Infraglenoid tubercle, [389](#)

Infraglottic space, [562](#)

Infrahyoid muscles, [540](#)

Infraorbital artery, [509](#), [512](#), [537](#), [578](#)

Infraorbital fissure, [536](#)

Infraorbital foramen, [480](#), [482](#), [510](#), [536](#)

Infraorbital groove, [510](#)

Infraorbital nerve, [512](#), [537](#), [571](#), [578](#)

Infraorbital vein, [509](#), [517](#), [578](#)

Infrapatellar bursa, [328](#)

Infraspinatus muscle, [9](#), [37–39](#), [52](#), [400–401](#), [414](#)

Infraspinous fossa, [389](#)

Infratemporal bones, [529](#)

Infratemporal crest, [529](#)

Infratemporal fossae, [528](#), [530–531](#)  
    arteries, [535](#)  
    nerves, [534](#)  
    veins, [535](#)

Infratrochlear artery, [512](#)

Infratrochlear nerve, [505](#), [512](#), [515](#)

Infratrochlear vein, [512](#)

Inguinal canal, [146](#), [148–149](#), [150–151](#), [236](#)

Inguinal hernias, [152](#)  
    direct, [152](#)  
    indirect, [152](#)

Inguinal ligament, [138](#), [143](#), [148](#), [150](#), [153](#), [185](#), [214](#), [216](#), [221](#), [240](#), [310](#), [312](#)  
    surface, [134](#)

Inguinal nodes, [12](#)  
    deep, [270–271](#)  
    inferior superficial, [270–271](#)  
    superficial, [367](#)  
    superolateral superficial, [271](#)

- superomedial superficial, 270–271
- Inguinal region
  - female, 146–147, 150–151
  - male, 146–147, 148–149
- Inguinal ring
  - deep, 146, 148–149, 150–151, 153
  - superficial, 138, 146, 148, 150, 236, 240
- Inguinal triangle, 153
  - right, 152
- Inion, 484
- Insula, 504
- Interarytenoid fold, 562
- Interarytenoid notch, 555, 557, 562
- Intercarpal ligament, 428, 431
- Interchondral joint, 67
- Interclavicular ligament, 390
- Intercondylar fossa, 328
- Intercondylar line, 306
- Intercostal artery(ies), 72, 78, 143
  - anterior, 74
    - collateral branch of, 74
  - left supreme, 75, 118
  - posterior, 46, 74
    - collateral branch of, 74
    - left, 46
    - right, 46
  - right supreme, 74
  - supreme, 550–551
- Intercostal membrane, external, 70, 72
- Intercostal muscle, 68, 72
  - external, 8–9, 52, 71–72, 398
  - innermost, 52, 72
  - internal, 8, 52, 71–72
- Intercostal nerve(s), 13, 32, 72, 76, 78, 119, 204
  - anterior cutaneous branch of, 76, 125, 145
  - lateral cutaneous branch of, 76, 144

- sixth thoracic, 69
- small collateral branch of, 76
- thoracic, 69
- Intercostal nodes, 77
- Intercostal space, 64
- Intercostal vein, 72
  - left superior, 75
  - posterior, 47
- Intercostal vessels, 142
- Intercostobrachial nerve, 405–406, 420
- Intercuneiform ligaments, 354
- Intergluteal cleft, 5, 20, 215, 217
- Intermaxillary suture, 574
- Intermediate nerve, 522–524
- Interossei muscles, 362
- Interosseous artery
  - anterior, 436
  - common, 412, 436, 439
  - posterior, 436, 439
  - recurrent, 416, 436, 439
- Interosseous membrane, 328, 435
- Interosseous nerve, 436, 439
- Interphalangeal joints, 335, 431, 455
- Intersphincteric groove, 233
- Interspinalis cervicis, 43
- Interspinous ligament, 35
- Interthalamic adhesion, 497
- Intertragic notch, 522
- Intertransversarius, 41
- Intertrochanteric crest, 295, 297–298, 301
- Intertrochanteric line, 295, 297–298
- Intertubercular plane, 135
- Intertubercular sulcus, 388, 391
- Interureteric fold, 235
- Interventricular septum, 124
- Interventricular sulcus, anterior, 94, 101

Interventricular vein, anterior, [102](#)  
Interventricular vessels, anterior, [99](#)  
Intervertebral disc, [21](#), [24](#), [32](#)  
    LV-SI, [220–221](#)  
Intervertebral disc problems, [33–34](#)  
Intervertebral disc protrusion, [33](#)  
Intervertebral foramen, [26](#), [32](#), [48](#)  
Intervertebral vein, [47](#)  
Intestinal nodes, [12](#)  
Intestinal trunk, [200](#)  
Intestine  
    large, [12](#), [168](#)  
        imaging, [169](#)  
        surface projections, [168](#)  
    small, [154–155](#), [188](#)  
        in coronal plane, [3](#)  
        lymph nodes in, [12](#)  
        in sagittal plane, [3](#)  
Intra-articular ligament, [66](#)  
Intraparietal sulcus, [496](#)  
Investing layer, [540](#)  
Iridocorneal angle, [518](#)  
Iris, [510–511](#)  
Ischial ramus, [296–297](#)  
Ischial spine, [7](#), [214–223](#), [229–231](#), [295](#), [297](#)  
Ischial tuberosity, [7](#), [215](#), [217](#), [222](#), [231](#), [257–258](#), [260](#), [296](#), [299](#), [301](#), [303](#)  
Ischio-anal fossa, [153](#), [233](#)  
Ischiocavernosus, [242](#), [257–258](#), [262](#)  
Ischiococcygeus, [229–231](#)  
Ischiofemoral ligament, [228](#), [301](#)  
Ischiopubic arch, [261](#)  
Ischiopubic ramus, [222](#), [231](#)  
Ischium, [6](#), [296](#)  
    ramus of, [214–218](#), [222](#)

## J

Jejunal artery, 166, 172

Jejunal vein, 166, 182–183

Jejunum, 166–167, 188

in coronal section of abdomen, 158

imaging, 167

Joint(s)

acromioclavicular, 62, 387, 390

ankle, 7, 337

atlanto-axial, 23

atlanto-occipital, 501, 539

calcaneocuboid, 335

carpometacarpal, 428, 431

clavicular, 390

costovertebral, 66

cricothyroid, 560

elbow, 7, 387, 422–425

fibrocartilaginous, 67

foot, 335

in hand, 431

hip, 7, 295, 299–300

humero-radial, 422

humero-ulnar, 422

interchondral, 67

interphalangeal, 335, 431, 455

knee, 7, 320–321, 324–327

lumbosacral, 220

manubriosternal, 64, 67

metacarpophalangeal, 431

metatarsophalangeal, 294, 335

midcarpal, 428

radio-ulnar, 422, 427

sacro-iliac, 6, 31, 216, 221, 223, 229, 296–297

shoulder, 7, 387–388

spinal, 35–36

sternoclavicular, 62, 388, 390

sternocostal, 64, 66–67



- subtalar, 335
- synovial, 66–67
- talocalcaneonavicular, 335
- tarsometatarsal, 335
- temporomandibular, 530–532
- tibiofibular, 320
- wrist, 7, 387, 427–429
- xiphisternal, 64, 67
- zygapophyseal, 24, 28–29

Jugular foramen, 486–487

Jugular notch, 62, 64, 524

Jugular trunk, 77, 553

Jugular tubercle, 487

Jugular vein

- anterior, 11, 541
- external, 11, 508, 535, 541, 559
- internal, 11, 75, 77, 82, 110, 508–509, 535, 541, 559
  - left, 101, 109–110, 566
  - right, 101, 109, 397, 567

Jugulodigastric node, 508, 552–553

Jugulo-omohyoid node, 508, 552–553

## **K**

### **Kidney(s)**

- anterior surface structures, 188
- fascia surrounding, 188
- fat surrounding, 188
- fibrous capsule of, 190
- gross structure of, 190
- hilum of, 190
- imaging, 191
- inferior pole of, 190
- lateral border, 190
- left, 162, 165, 188
- medial border, 190
- posterior surface structures, 188

- retroperitoneal position of, 188
- right, 162, 165
  - anterior surface, 190
  - internal structure, 190
  - retroperitoneal, 188
- superior pole of, 190
- surface projection of, 188
- vasculature, 192–193
- visceral sensory diagram, 206–207

## Knee

- arteries, 329
- bones of, 295
- bursa, 328
- capsule, 328–329
- ligaments of, 322–323
- surface, 329

Knee joint, 7, 295, 320–321, 324–327

## L

Labial artery

inferior, [508](#)

posterior, [268](#)

superior, [508](#)

Labial vein

inferior, [508](#)

posterior, [268](#)

superior, [508](#)

Labium majus, [226](#), [259](#)

Labium minus, [150](#), [226](#), [258–259](#)

Labyrinthine artery, [502](#)

Lacrimal apparatus, [512](#)

Lacrimal artery, [512](#), [517](#)

Lacrimal bone, [479](#), [482](#), [488](#), [510](#), [536](#)

Lacrimal canaliculi, [512](#)

Lacrimal caruncle, [512](#)

Lacrimal crest, [512](#)

Lacrimal fold, [512](#)

Lacrimal gland, [512–513](#)

Lacrimal lake, [510](#)

Lacrimal nerve, [505](#), [512–513](#), [515](#), [537](#)

Lacrimal papilla, [512](#)

Lacrimal punctum, [512](#)

Lacrimal sac, [511](#)

Lacrimal sac fossa, [514](#)

Lactiferous ducts, 68

Lactiferous sinuses, 68

Lacunar ligament, 148, 153, 219

Lambda, 485

Lambdoid suture, 482, 484–485

Large intestine, 12, 168–169

- imaging, 169
- surface projections, 168

Laryngeal artery

- inferior, 567
- superior, 548

Laryngeal cartilage, 561

Laryngeal cavity, 562

Laryngeal inlet, 554–555, 562

Laryngeal nerve, 564

- external, 564
- internal, 564
- left recurrent, 107, 110, 558, 564, 566
- right recurrent, 88, 107, 110, 558, 564, 566
- superior, 545, 558, 564

Laryngeal saccule, 562

Laryngeal vein, superior, 559

Laryngeal ventricle, 562

Laryngopharynx, 554–555

Larynx, 4

- external features, 560
- muscles, 563

nerves, [564](#)

surface anatomy, [560](#), [565](#)

Lateral, as anatomical direction, [2](#)

Lateral ligament, [530](#)

Latissimus dorsi, [5](#), [36–38](#), [137–138](#), [396–397](#), [410](#)

Leg

arteries, [344](#), [348](#)

bones, [295](#)

dermatomes, [368–369](#)

imaging, [351](#)

ligaments, [324](#)

lymphatics, [367](#)

menisci, [324–325](#)

muscle attachments, [341](#)

muscles, [342–343](#), [345–347](#)

nerves, [344](#), [348–349](#)

superficial muscles, [342](#)

surface anatomy, [294](#)

transverse section, [350–351](#)

veins, [366](#)

Lens, [511](#), [518](#)

Lesser curvature, of stomach, [160](#)

Lesser omentum, [156](#), [166](#)

Lesser trochanter, [6–7](#)

Levator anguli oris, [506–507](#)

Levator ani, [153](#), [224](#), [226](#), [229–231](#), [233](#), [237](#), [261–262](#)

Levatores costarum, [41](#)

Levator labii superioris, 506–507

Levator labii superioris alaeque nasi, 506–507

Levator palpebrae superioris, 511, 514

Levator palpebrae superioris tendon, 506, 511–512

Levator scapulae, 9, 36–39, 542–543

Levator veli palatini, 524–525, 531, 556–557, 583

Ligamenta flava, 35

Ligamentum arteriosum, 92, 94, 97, 109–110, 116

Ligamentum nuchae, 20, 35–36, 39–40

Ligamentum venosum, fissure for, 175

Limbus, of fossa ovalis, 96

Linea alba, 134, 136–137, 141

Linea aspera, 295, 297–298

Lingual artery, 502, 509, 548, 581, 584

Lingual glands, 584

Lingual gyrus, 496–497

Lingual nerve, 530, 534, 578–579, 582, 584

Lingual tonsil, 12, 554, 582

Lingual vein

- deep, 581, 584
- dorsal, 581

Lingula, 82–83, 531, 574

Lip, lower, 582

Liver, 174, 188

- anterior medial segment V, 177
- anterior surface, 174
- caudate lobe of, 175, 177

- in coronal plane, [3](#)
- in coronal section of abdomen, [158](#)
- inferior border of, [166](#), [174](#)
- lateral segment II, [177](#)
- lateral segment III, [177](#)
- left lobe of, [154–155](#), [166](#)
- location of, [174](#)
- medial segment IV, [177](#)
- posterior lateral segment VII, [177](#)
- posterior surface of, [175](#)
- quadrate lobe, [175](#)
- right anterior lateral segment VI, [177](#)
- right lobe of, [154–155](#), [174](#)
- round ligament of, [153](#), [155](#), [166](#), [174](#)
- segments of, [177](#)
- surface projection of, [174](#)
- vessels of, [176](#)
- visceral surface of, [175](#)
- L1 nerve, [43](#), [53](#), [144](#), [148](#), [150](#),
  - anterior ramus, [305](#)
  - lateral cutaneous branch of, [144](#)
- L2 nerve, anterior ramus, [305](#)
- L3 nerve, anterior ramus, [305](#)
- L4 nerve, [34](#)
- L5 nerve, [34](#)
- Lobule, [522](#)
- Longissimus, [40](#), [71](#)

Longissimus capitis, [40](#), [43](#)  
Longissimus cervicis, [40](#)  
Longissimus thoracis, [40](#)  
Longitudinal axis, [2](#)  
Longitudinal ligament, anterior, [220–221](#)  
Longitudinal muscle  
    of esophagus, [556–557](#)  
    of rectum, [233](#)  
    of tongue, [582](#)  
Longus capitis, [542–543](#)  
Longus colli, [543](#)  
Lumbar arteries, [194](#)  
Lumbar ganglia, [202](#)  
Lumbar meninges, [48](#)  
Lumbar nerves, [34](#), [44](#)  
Lumbar node, [200](#), [270–271](#)  
Lumbar plexus, [13](#), [198](#)  
    cutaneous distribution, [199](#)  
Lumbar triangle, [37](#)  
Lumbar trunk  
    left, [200](#)  
    right, [200](#)  
Lumbar vein, ascending, [119](#)  
Lumbar vertebrae, [21–22](#), [27–30](#)  
Lumbosacral articular surface, [296](#)  
Lumbosacral joint, [220](#)  
Lumbosacral ligament, [220](#)



Lumbosacral trunk, 198, 254–255, 305

Lumbricals, 359–360, 447–448

Lunate, 428, 430

Lunate surface, 299

Lung(s)

- apex of, 88
- left, 79, 83
- right, 79, 82

Lunule, 100

LI vertebra, 21

LIII vertebra, 22

LIV vertebra, 29–30, 33

LV vertebra, 21, 27–28, 31, 221, 224, 226, 296

Lymphatic drainage, 553

Lymphatic duct, right, 12

Lymphatic system, 12

- in abdomen, 200
- in abdominal wall, 143
- in arms, 417, 459
- facial, 508
- in hands, 459
- in legs, 367
- in neck, 552–553
- in perineum, 272
  - female, 271
  - male, 270
- in thoracic wall, 77

Lymphatic trunk(s), 69  
termination of, 77

## M

Malleolar artery

anterior lateral, 348, 356–357  
anterior medial, 348, 356–357

Malleolar fold

anterior, 523, 525  
posterior, 523

Malleolus, 4, 6–7

lateral, 4, 6–7, 294–295, 345

Malleus, 523–524

ligament of, 523, 525

Mammary gland, 68

Mammillary body, 496, 501

Mammography, 69

Mandible, 6, 479, 529, 554

alveolar part, 480  
angle of, 7, 482, 574  
bay of, 480  
body of, 482, 574  
lateral view, 574  
medial view, 574  
posterior view, 574  
ramus of, 480, 482, 574  
superior view, 574

Mandibular canal, 530–531, 582

Mandibular fossa, 486, 529

Mandibular nerve, 494, 500–501, 505, 513, 519, 533–534, 537, 578

Mandibular node, 552

Mandibular symphysis, 574

Manubriosternal joint, 64, 67

Manubrium of sternum, 3, 6, 62, 64, 388, 540

Marginal artery, 159, 172

Marginal sulcus, 497

Marginal vessels, 102

Masseter, 8, 506–507, 528, 530, 542

Masseteric artery, 535

Masseteric fascia, 542

Masseteric nerve, 533

Mastoid air cells, 524–525

Mastoid antrum, 525

Mastoid nodes, 508, 552

Mastoid notch, 484, 486

Mastoid process, 7, 43, 482, 484, 486, 525, 529, 542

Maxilla, 6, 479–480, 529

Maxilla bone, 482, 489

Maxillary artery, 494, 502, 509, 535, 537, 548, 578

Maxillary nerve, 494, 500, 505, 513, 519, 533–534, 537, 558, 578

Maxillary sinus(es), 537, 568, 575

Maxillary vein, 509, 535, 541, 559, 578

Medial, as anatomical direction, 2

Median nerve, 13, 397, 405, 407, 412, 426, 436, 457

Mediastinal pleura, [93](#), [108–109](#)

Mediastinal plexus, [110](#)

Mediastinum, [79](#), [91](#), [116](#)

anterior, [91](#)

imaging, [113](#), [115](#), [117](#), [120](#), [121–122](#)

inferior, [91](#)

middle, [91](#)

posterior, [91](#), [118–119](#)

subdivisions of, [91](#)

superior, [91](#), [108](#)

imaging, [111](#)

nerves of, [110](#)

trachea in, [112](#)

transverse section at TIV, [121](#)

transverse section at TV, [122](#)

vasculature, [109–110](#)

transverse section at TIII, [120](#)

Medulla

adrenal, [206](#)

renal, [190](#)

Medulla oblongata, [496–497](#)

Medullary arteries, segmental, [46](#)

Medullary sinus, [12](#)

Medullary vellum

inferior, [497](#)

superior, [497](#)

Meningeal artery, [494](#)

- middle, [509](#), [533](#), [535](#)
- recurrent, [517](#)
- Meningeal nerve, [533–534](#)
- Meninges, [48–49](#), [492](#)
- Meniscus (menisci), [326–327](#)
  - lateral, [322](#), [325](#)
  - medial, [325](#)
- Mental artery, [509](#), [535](#)
- Mental foramen, [480](#), [482](#), [529](#), [535](#), [574–575](#)
- Mentalis, [506–507](#)
- Mental nerve, [505](#), [533](#), [578](#)
- Mental protuberance, [480](#)
- Mental spines, [574](#), [580](#)
- Mental tubercle, [480](#)
- Mental vein, [535](#)
- Mesenteric artery(ies), [172](#)
  - inferior, [10](#), [159](#), [162](#), [172](#), [186](#), [192](#), [194](#)
  - superior, [10](#), [159](#), [162](#), [172](#), [181–182](#), [186](#), [192](#), [194](#), [270](#)
    - branching, [173](#)
    - in coronal section of abdomen, [158](#)
    - positioning of, [173](#)
- Mesenteric ganglion
  - inferior, [203](#)
  - superior, [201](#)
- Mesenteric nodes
  - inferior, [200](#), [270–271](#)
  - superior, [200](#), [270–271](#)

Mesenteric vein

inferior, [11](#), [181–183](#)

retroperitoneal, [188](#)

superior, [11](#), [162](#), [181–183](#), [188](#)

in coronal section of abdomen, [158](#)

Mesenteric vessels, superior, [166](#)

Mesentery, [158](#), [166](#)

Mesial, as anatomical direction, [575](#)

Meso-appendix, [170](#)

Mesocolon, transverse, [188](#)

Mesosalpinx, [245](#)

Metacarpal artery

dorsal, [456](#)

palmar, [450–452](#)

Metacarpal ligaments, [431](#), [445](#), [447](#)

Metacarpals, [6](#), [387](#), [428](#), [430](#)

Metacarpal vein, dorsal, [458–459](#)

Metacarpophalangeal joint, [431](#)

Metatarsal arteries

deep, [348](#)

dorsal, [357](#)

plantar, [357](#), [364](#)

Metatarsal ligaments, [353–354](#), [358](#)

Metatarsals, [6–7](#), [295](#), [332–334](#)

Metatarsophalangeal joint(s), [335](#)

of great toe, [294](#)

Metencephalon, [496](#)

Midbrain, [501](#)

Midcarpal joint, [428](#)

Middle lobe of lung, [82](#)

Midgut, innervation of, [203–205](#)

Midline raphe, [237](#), [242](#), [262](#)

Mitral valve, [98–99](#), [101](#)  
auscultation position for, [106](#)

Modiolus, [526](#)  
lamina of, [526](#)

Molars, [575](#)

Mons pubis, [258](#)

Mucosa  
esophageal, [160](#)  
gastric, [160](#)  
of rectum, [233](#)  
tracheal, [86](#)

Mucosal linings of nasal cavity, [570](#)

Multifidus, [41](#), [43](#)

Muscle(s). *See also individual muscles*  
abdomen, [137–141](#)  
arm, [410–411](#), [414–415](#), [434–435](#), [437–438](#)  
back, [36–43](#)  
eye, [514](#)  
facial, [506–507](#)  
foot, plantar, [359–362](#)  
gluteal, [302–303](#)  
hand, [448–449](#)

infratemporal fossa, 530–531

knee, 329

larynx, 563

leg, 342–343, 345–347

neck, 542–543

oral cavity, 580

palate, 583

pharynx, 556–557

rotator cuff, 400–401

thigh, 307

thoracic wall, 72

#### Muscle attachments

clavicle, 390

foot, 352

hand, 444

lower leg, 341

shoulder, 409

skull, 490–491

thigh, 307, 310–311, 315

upper limb, 394–395, 411, 415, 432

Muscular triangle, 538

Musculi pectinati, 96

Musculocutaneous nerve, 13, 397, 405–407, 412, 426

Musculofascial pouch, 236

Musculophrenic artery, 74, 142–143

Musculophrenic vein, right, 75

Musculus uvulae, 557, 583



Mylohyoid, [533–534](#), [542–543](#), [580](#), [582](#)

Mylohyoid line, [574](#)

Myometrium, [244](#)

## N

Naris, [568](#)

Nasal aperture, posterior, [486](#)

Nasal artery

dorsal, [517](#)

external, [571](#)

lateral, [508](#), [571](#)

Nasal bone, [479–480](#), [482](#), [485](#), [568–569](#)

Nasal cartilage, accessory, [568](#)

Nasal cavity, [512](#), [554](#), [568](#)

bones, [569](#)

imaging, [572–573](#)

mucosal linings, [570](#)

nerves, [571](#)

Nasal concha

inferior, [479–480](#), [568–570](#)

middle, [512](#), [568–570](#)

superior, [568–570](#)

Nasal crest, [480](#)

Nasalis, [506–507](#)

Nasal meatus

inferior, [512](#), [570](#)

middle, [570](#)

- superior, 570
- Nasal nerve(s), 537
  - external, 505
  - posterior inferior lateral, 571
  - posterior superior lateral, 571
- Nasal septum, 557, 570
- Nasal spine
  - anterior, 480
  - posterior, 486, 574
- Nasal vein, 571
  - lateral, 508, 571
- Nasal vestibule, 570
- Nasion, 480
- Nasociliary nerve, 515, 519
- Nasofrontal vein, 517
- Nasolacrimal duct, 512, 569–570
- Nasopalatine nerve, 571, 579, 583
- Nasopharynx, 554–555
- Navicular, 332–334
- Navicular fossa, 236, 242
- Neck. *See also* Larynx; Pharynx
  - arteries, 548–551
  - bones, 539
  - compartments, 540
  - fascia, 540
  - imaging, 549, 551, 555
  - lymphatics, 552–553

muscles, 542–543, 556–557

nerves, 544–546

surface anatomy, 478, 538

veins, 541

Nerve(s), 13–17. *See also individual nerves*

abdominal, 201

abdominal wall, 144–145

arm, 426

    anterior compartment, 412, 436

    cutaneous, 420–421, 460–461

    posterior compartment, 416, 439

in back, cutaneous, 53

bladder, 276

cardiac, 107

cranial, 500–501, 586–587

cutaneous, 17

    arm, 402, 416, 420–421, 426, 436, 460–461

    femoral lateral, 273

    femoral posterior, 254, 273

    lateral

        of thigh, 198–199

        T7-T11, 145

    lateral cutaneous branch of, 76

    legs, 349

    perforating, 254

    perineal, 273

    sural, 349

dural, [494](#)  
eyes, [515](#), [518](#)  
facial, [508](#)  
foot, [356–357](#), [363–364](#)  
gluteal, [304–305](#)  
gums, [579](#)  
hand, [450–451](#), [453](#), [457](#)  
head, [588](#)  
infratemporal fossae, [535](#)  
lacrimal gland, [513](#)  
larynx, [564](#)  
leg, [344](#), [348–349](#)  
nasal cavity, [571](#)  
neck, [544–546](#)  
oral cavity, [585](#)  
parasympathetic, [15](#)  
pelvic, [254–255](#)  
perineal, [269](#)  
pharynx, [558](#)  
pterygopalatine fossa, [537](#)  
reproductive system  
    female, [275](#)  
    male, [274](#)  
spinal, [44–45](#), [47](#)  
    anterior rami of, [254](#)  
    nomenclature of, [44](#)  
sympathetic, [14](#)

teeth, [578–579](#)  
thigh, [313](#), [316](#)  
thoracic wall, [76](#)  
tongue, [581](#)

Nipple, [4](#), [68](#)

Nodule, in aortic valve, [100](#)

Nose, [568](#). *See also entries at Nasal*

Nuchal line

inferior, [484](#), [486](#)

superior, [37](#), [40](#), [484](#), [486](#)

Nucleus pulposus, [32](#)

herniation of, [33–34](#)

Nucleus solitarius, [127](#)

## O

Oblique fissure, [81–83](#), [85](#)

Oblique line, [480](#)

Oblique muscles (in eyes)

inferior, [514](#), [516](#)

superior, [514](#), [516](#)

Oblique muscles (in trunk)

external, [8–9](#), [37–39](#), [42](#), [71](#), [136–138](#), [141–142](#), [148–149](#), [150–151](#), [240](#)

internal, [8–9](#), [42](#), [136–138](#), [141–142](#), [148–149](#), [150–151](#), [240](#)

Oblique vein, of left atrium, [102](#)

Obliquus capitis inferior, [41](#), [43](#)

Obliquus capitis superior, [41](#), [43](#)

Obturator artery, [236](#), [248](#), [250](#), [253](#), [266](#), [299](#), [301](#), [314](#)

- posterior branch, 301
- Obturator canal, 155, 221, 228–230
- Obturator externus, 8, 307, 313
- Obturator foramen, 198, 214–218, 220, 222–223, 234, 260, 297
- Obturator internus, 9, 153, 228, 230–231, 242, 260, 264, 303, 307
  - fascia covering, 229
  - tendon of, 228, 260
- Obturator membrane, 153, 155, 219, 221, 299
- Obturator nerve, 13, 198–199, 254, 256, 267, 273, 305, 313, 318
  - cutaneous branch, 199
  - muscular branches, 313
  - posterior branch, 313
- Obturator node, 272
- Obturator vein, 236, 249–250, 253, 266
- Obtuse margin, 94, 101
- Occipital artery, 43, 494, 502, 508–509, 548, 581
- Occipital bone, 7, 40, 479, 482, 484–485, 487
- Occipital condyles, 486, 539
- Occipital crest
  - external, 484
  - internal, 487
- Occipitalis, 9
- Occipital lobe, 497
- Occipital nerve
  - greater, 43, 53
  - lesser, 544, 546–547
  - third, 43, 53

Occipital nodes, [508](#), [552](#)  
Occipital pole, [496](#)  
Occipital protuberance, external, [7](#), [35](#), [37](#), [484](#), [486–487](#)  
Occipital vein, [508–509](#), [541](#)  
Occipitofrontalis, [506–507](#), [542](#)  
Occipitomastoid suture, [482](#), [484](#)  
Occipitotemporal gyri, [496](#)  
Oculomotor nerve, [500–501](#), [515](#), [519](#), [586](#)  
Odontoid process, [24](#)  
Olecranon, [5](#), [7](#), [386–387](#), [408](#), [414](#), [422](#), [425](#)  
Olecranon fossa, [408](#), [425](#)  
Olfactory bulb, [496](#), [500–501](#), [571](#)  
Olfactory nerves, [500](#), [571](#), [586](#)  
Olfactory tract, [496](#), [501](#)  
Olive, [501](#)  
Omental appendices, [168](#)  
Omental bursa, [156](#)  
Omental foramen, [166](#)  
Omentum  
    greater, [154](#)  
    lesser, [156](#)  
Omohyoid, [542–543](#)  
Ophthalmic artery, [502](#)  
    inferior, [535](#)  
Ophthalmic nerve, [494](#), [500–501](#), [505](#), [513](#), [515](#), [519](#), [533–534](#), [537](#)  
Ophthalmic vein(s), [509](#)  
    inferior, [517](#), [535](#)

superior, 517

Opponens digiti minimi, 362, 446, 448–449

Opponens pollicis, 448–449, 458

Optic canal, 487, 510, 536

Optic chiasm, 497, 500–501

Optic disc, 518

Optic nerve, 500–501, 511, 515, 518, 586

Oral, as anatomical direction, 575

Oral cavity, 554

- bones, 574–575, 577
- imaging, 576
- muscles, 580
- nerves, 585
- root of, 584

Oral vestibule, 582

Ora serrata, 518

Orbicularis oculi, 8, 506–507, 511

Orbicularis oris, 8, 506–507, 582

Orbital fissure

- inferior, 480, 510
- superior, 480, 487, 510, 536

Orbital gyri, 496

Orbital nerves, 537

Orbital septum, 506, 511–512

Orbital sulci, 496

Oropharyngeal isthmus, 584

Oropharynx, 554–555, 584



Otic ganglion, 534  
Oval window, 523–524, 526  
Ovarian artery, 10, 150, 251  
    left, 147  
    right, 194  
Ovarian plexus, 201  
Ovarian vein(s), 11, 195, 251  
    left, 147  
Ovarian vessels, 244  
Ovary(ies), 147, 226, 243–245  
    structure of, 244  
    suspensory ligament, 226, 244

## **P**

Palate, 583–584  
    hard, 486, 554, 556, 583  
    soft, 554–555, 570, 583  
Palatine aponeurosis, 583–584  
Palatine artery, 537  
    greater, 571, 583–584  
    lesser, 537, 583–584  
Palatine bone, 479, 510, 529, 536  
Palatine canal, 536  
Palatine foramen, 486, 574, 583  
Palatine glands, 554, 584  
Palatine nerve, 537  
    greater, 579, 583–584

- lesser, [537](#), [583–584](#)
- Palatine rugae, [583](#)
- Palatine tonsil, [12](#), [554](#), [582–584](#)
- Palatine vein, greater, [571](#)
- Palatoglossal arch, [554](#), [582](#), [584](#)
- Palatoglossus, [580–584](#)
- Palatopharyngeal arch, [554](#), [584](#)
- Palatopharyngeus, [556–557](#), [582–584](#)
- Palatovaginal canal, [536](#), [569](#)
- Palmar aponeurosis, [434](#), [445](#)
- Palmar arch
  - deep, [10](#)
  - superficial, [10](#)
- Palmar interosseous, [448–449](#)
- Palmaris brevis, [445](#)
- Palmaris longus, [8](#), [410](#), [426](#), [434](#)
- Palmaris longus tendon, [433–434](#), [442](#), [445](#)
- Palmar ligament, [431](#), [447–448](#)
- Palmar surface, of hand, [2](#)
- Palpable bone
  - anterior view, [6](#)
  - superior view, [7](#)
- Palpebral fissure, [512](#)
- Palpebral ligament, [506](#), [512](#)
- Pampiniform plexus, [149](#), [240–241](#)
- Pancreas, [156](#), [178–179](#), [188](#)
  - anterior surface of, [178](#)

- body of, 164, 178
- fundus of, 179
- head of, 158, 164, 178
- imaging, 178
- neck of, 164
- positioning of, 180
- retroperitoneal, 188
- tail of, 178
- uncinate process, 178
- vasculature of, 181

#### Pancreatic artery

- dorsal, 181
- inferior, 181

#### Pancreatic duct

- accessory, 179
- main, 179

#### Pancreatic notch, 178

#### Pancreaticoduodenal artery

- anterior inferior, 162, 181
- anterior superior, 162
- inferior, 159, 162
- posterior, 159
- posterior inferior, 162, 181
- posterior superior, 162, 181
- superior, 159, 162

#### Pancreaticoduodenal vein, 183

#### Papillary muscle

- anterior, [97](#), [99](#), [105](#)
- posterior, [97](#), [99](#), [105](#)
- septal, [97](#)
- Paracentral lobule, [497](#)
- Paracolic gutter
  - left, [155](#)
  - right, [155](#)
- Parahippocampal gyrus, [496](#)
- Paranasal sinuses, [568](#)
- Paranephric fat, [188](#)
- Parasternal nodes, [69](#), [77](#)
- Parasympathetic nerves, [15](#)
  - in face, [534](#)
- Parathyroid gland
  - inferior, [565](#), [567](#)
  - superior, [565](#), [567](#)
- Paratracheal nodes, [553](#)
- Para-urethral gland, opening of duct, [259](#)
- Parietal bone, [7](#), [479](#), [482](#), [484–485](#), [487](#)
- Parietal foramen, [485](#)
- Parietal lobe, [497](#)
- Parietal peritoneum, [136–137](#), [141](#), [148](#), [224](#)
- Parietal pleura, [72](#), [79–81](#), [124](#)
  - cervical, [92](#)
- Parietomastoid suture, [482](#)
- Parieto-occipital sulcus, [497](#)
- Parotid duct, [506–507](#)

Parotid fascia, [542](#)

Parotid gland, [506](#), [508–509](#), [530](#)

Parotid nodes, [508](#), [552](#)

Parotid region

- arteries, [509](#)
- veins, [509](#)

Pars flaccida, [523](#)

Pars opercularis, [496](#)

Pars orbitalis, [496](#)

Pars triangularis, [496](#)

Patella, [4](#), [6](#), [294](#), [306](#)

Patellar ligament, [310](#), [322](#), [329](#)

Patellar retinaculum, [329](#)

Patellar surface, [306](#)

Pecten pubis, [214](#), [218](#), [223](#), [296](#)

Pectineal line, [214](#), [218](#), [223](#), [296](#)

Pectineus, [8](#), [307–308](#), [311–312](#), [318](#)

- nerve to, [313](#)

Pectoral fascia, [68](#)

Pectoralis major, [3–4](#), [8](#), [68–70](#), [410](#), [542](#)

- abdominal part, [138](#), [396](#)
- in axial plane, [70](#)
- clavicular part, [396](#)
- sternocostal part, [396](#)

Pectoralis major fascia, [542](#)

Pectoralis minor, [8](#), [68](#), [70–71](#), [397](#)

Pectoral nerve

- lateral, [70](#), [397](#), [405–406](#)
- medial, [70](#), [397](#), [405–406](#)
- Pectoral nodes, [417](#)
- Pectoral region, [71](#), [396](#)
- Pedicle, [22](#), [30](#), [45](#)
- Pelvic bone, [295–296](#)
- Pelvic brim, [223](#)
- Pelvic cavity
  - female, [279–285](#)
  - floor, [229–231](#)
  - imaging, [277–285](#)
  - lateral wall, [228](#)
  - male, [232](#), [277–279](#)
- Pelvic fascia, [247](#)
- Pelvic girdle, [218](#)
  - imaging, [219](#)
  - orientation of, [223](#)
- Pelvic inlet, [222](#)
- Pelvic nerve plexus, [255](#)
- Pelvic outlet, [222](#)
- Pelvis
  - arterial supply of, [248](#)
  - articulated, [214–216](#), [297](#)
  - lymphatics, [272](#)
    - female, [271](#)
    - male, [270](#)
  - renal, [188](#), [190](#)

- subpubic angle in
  - female, [216](#)
  - male, [214](#)
- surface anatomy
  - female, [216–217](#)
  - male, [214–215](#)
- venous drainage of, [249](#)
- viscera
  - female, [226](#)
    - imaging, [227](#)
  - male, [224](#)
    - imaging, [225](#)
  - vasculature, [250](#)

## Penis, [4](#), [242](#)

- bulb of, [224](#), [236–237](#), [262](#)
  - artery of, [268](#)
  - vein of, [268](#)
- crus of, [242](#), [262](#)
- deep artery of, [242](#), [268](#)
- dorsal arteries of, [240](#), [247](#), [252](#), [266](#), [268](#)
- dorsal nerve of, [267](#), [269](#), [273](#)
- dorsal veins of, [240](#), [247](#), [252](#), [266](#)
- frenulum of, [242](#)
- fundiform ligament of, [240](#), [242](#), [262](#)
- glans, [20](#), [214](#), [236](#), [242](#), [252](#), [262](#)
- prepuce of, [242](#)
- skin of, [242](#)

- suspensory ligament of, [224](#), [242](#), [262](#)
  - venous drainage, [252](#)
- Pericardiophrenic artery, [92](#), [114](#)
  - left, [108](#)
- Pericardiophrenic vein, [92](#), [114](#)
  - left, [109](#)
  - right, [109](#)
- Pericardiophrenic vessels, [92](#)
- Pericardial cavity, [93](#)
- Pericardial layers, [93](#)
- Pericardial reflections, [94–95](#)
- Pericardial sac, [93](#)
- Pericardial sinus
  - oblique, [93](#), [124](#)
  - transverse, [93](#)
- Pericardium, [92](#), [109–110](#)
  - fibrous, [92–93](#), [124](#)
  - serous, [93](#), [124](#)
- Peridontium, [577](#)
- Perineal artery, [266](#)
  - transverse branches, [268](#)
- Perineal branches, [316](#)
- Perineal membrane, [153](#), [232](#), [234–235](#), [237](#), [242](#), [261](#)
- Perineal muscle
  - deep transverse, [232](#), [236](#), [261](#)
  - superficial transverse, [242](#), [257–258](#), [264](#)
- Perineal nerve, [267](#), [269](#), [273](#)



posterior labial branch, 269

posterior scrotal branch, 269

## Perineal pouch

deep, 153, 232, 234–235, 237, 243, 261

motor branches, 269

muscles of, 261

superficial, 237

## Perineal vein, 249, 266

transverse branches, 268

## Perinephric fat, 188

## Perineum

borders of, 260

ceiling of, 260

dermatomes, 273

female, 260

lymphatics, 272

female, 271

male, 270

male, 224, 260

imaging, 225

nerves of, 269

surface anatomy

female, 216–217, 258–259

male, 214–215, 256, 259

vasculature of, 268

## Periorbita, 511

## Periosteum, 511

Peritoneal cavity, [137](#)  
    arrangement of abdominal contents, [157](#)  
    greater and lesser sacs of, [156](#)  
    imaging, [157](#)

Peritoneum, [226](#), [239](#)  
    parietal, [136–137](#), [141](#), [148](#), [224](#)  
    visceral, [224](#)

Pes anserinus, [307](#)

Petrosal nerve  
    deep, [537](#)  
    greater, [513](#), [522](#), [537](#)  
    lesser, [524](#)

Petrosal sinus, [495](#)

Petrotympenic fissure, [529](#), [534](#)

Peyer's patch, [12](#)

Phalanges (foot), [6](#), [295](#), [332–334](#)

Phalanges (hand), [6](#), [387](#), [428](#), [430](#)

Pharyngeal artery, [494](#), [537](#)  
    ascending, [548](#)

Pharyngeal constrictor(s), [554](#)  
    superior, [507](#)

Pharyngeal nerve, [537](#)

Pharyngeal raphe, [556](#)

Pharyngeal recess, [554](#), [570](#)

Pharyngeal tonsil, [12](#), [554–555](#), [570](#)

Pharyngeal tubercle, [486](#), [556](#)

Pharyngobasilar fascia, [556–557](#), [583](#)

Pharyngo-epiglottic fold, [557](#)

Pharyngotympanic tube, [523–525](#), [554–557](#), [570](#), [574](#)

Pharynx, [554–555](#)

innervation, [558](#)

muscles, [556–557](#)

veins, [558](#)

Phrenic artery

inferior

left, [187](#), [194](#)

recurrent branch of, [194](#)

right, [194](#)

interior, [192](#)

right, [187](#)

inferior, [187](#)

Phrenic nerve(s), [13](#), [204](#), [405](#), [545–546](#)

left, [92](#), [187](#)

right, [92](#), [114](#)

Phrenic vein(s), inferior

left, [195](#)

right, [195](#)

Pia arterial plexus, [46](#)

Pia mater, [48–49](#)

Pillar cells, [526](#)

Pineal gland, [497](#), [501](#)

Piriform aperture, [480](#)

Piriform fossa, [555](#)

Piriformis, [9](#), [228–231](#), [243](#), [260](#), [303–305](#), [307](#)

Piriform recess, [562](#)

Pisiform, [428](#), [430](#), [442](#)

Pisohamate ligament, [431](#), [434](#), [447](#)

Pisometacarpal ligament, [431](#), [434](#), [447](#)

Pituitary gland, [496–497](#), [500](#)

Planes, anatomical, [2](#)

Plantar aponeurosis, [358](#)

Plantar artery

- deep, [348](#), [356](#), [364](#)
- lateral, [363–364](#)
- medial, [363–364](#)

Plantar calcaneonavicular ligament, [353](#)

Plantar cuboideonavicular ligament, [353](#)

Plantar cuneonavicular ligament, [353](#)

Plantar interossei, [361–362](#)

Plantaris, [9](#), [307](#), [309](#), [342–343](#)

Plantar ligament, [338](#), [353](#)

- long, [353–354](#)

Plantar lymph vessels, [367](#)

Plantar metatarsal ligaments, [353](#)

Plantar nerve

- lateral, [349](#), [363–364](#)
- medial, [349](#), [363–364](#)

Plantar surface, of foot, [2](#)

Plantar tarsometatarsal ligaments, [353](#)

Platysma, [506–507](#), [542](#), [582](#)

Pleural cavity(ies), [79](#)

left, [79](#)

Pleural recesses, surface projections of, [81](#)

Pons, [496–497](#), [501](#)

Pontine arteries, [502](#)

Popliteal artery, [10](#), [316–317](#), [329](#), [344](#), [348](#)

Popliteal fossa, [5](#), [330](#)

Popliteal ligament, [322](#)

Popliteal nodes, [12](#), [367](#)

Popliteal vein, [11](#), [344](#), [367](#)

Popliteus, [9](#), [307](#), [343](#)

Popliteus tendon, [322](#)

Porta hepatis, [175](#)

Portal hypertension, venous enlargement in, [184](#)

Portal triad, [176](#)

Portal vein, [11](#), [164](#), [176](#), [181](#)

- in coronal section of abdomen, [158](#)
- formation of, [183](#)
- left branch, [176](#)
- right branch, [176](#)

Portosystemic anastomoses, [184](#)

Postcentral gyrus, [496](#)

Postcentral sulcus, [496](#)

Posterior, as anatomical direction, [2](#)

Posterior cord, [407](#)

Posterior segment, of lung, [87](#)

Posterior triangle, [538](#)

Posterolateral arteries, [502](#)

Posteromedial arteries, [502](#)  
Postremal chamber, [518](#)  
Preaortic nodes, [200](#), [270–271](#)  
Preauricular nodes, [508](#), [552](#)  
Precuneus, [497](#)  
Prelaryngeal nodes, [553](#)  
Premolars, [575](#)  
Pre-occipital notch, [496](#)  
Prepatellar bursa, [328](#)  
Prepuce of penis, [242](#)  
Presymphyseal node, [270](#)  
Pretracheal layer, [540](#)  
Pretracheal nodes, [553](#)  
Pretracheal space, [540](#)  
Prevertebral layer of neck, [540](#)  
Prevertebral plexus, [14](#), [203](#), [255](#)  
Princeps pollicis artery, [451–452](#)  
Procerus, [506–507](#)  
Processus vaginalis, ligamentous remnant of, [241](#)  
Profunda brachii artery, [10](#), [397](#), [402–404](#), [412](#), [416](#)  
Pronator quadratus, [8](#), [433–435](#), [446](#)  
Pronator teres, [8](#), [410](#), [426](#), [433–434](#), [438](#)  
Prostate, [153](#), [224](#), [232](#), [234](#), [237–239](#)  
    anterior region, [238](#)  
    capsule of, [234](#), [237](#)  
    central zone, [238](#)  
    glandular elements, [237](#)

- imaging, [237–239](#)
- peripheral zone, [238](#)
- transitional zone, [238](#)
- venous drainage, [252](#)

Prostatic ducts, openings of, [237](#)

Prostatic fascia, [247](#)

Prostatic plexus, [247](#), [252](#), [256](#)

Prostatic sinus, [237](#)

Prostatic urethra, [224](#), [234](#), [237](#)

Prostatic utricle, [237](#)

Proximal, as anatomical direction, [2](#)

Psoas major, [29](#), [42](#), [137](#), [147](#), [153](#), [185](#), [187–188](#), [270](#), [313](#)

Psoas minor, [185](#), [270](#)

Pterion, [482](#)

Pterygoid(s), [556](#)

- lateral, [530–532](#), [534](#)
- medial, [530–531](#), [534](#)

Pterygoid artery, [535](#)

Pterygoid canal, [486](#), [536–537](#)

Pterygoid fossa, [486](#)

Pterygoid hamulus, [529](#), [531](#), [536](#), [569](#), [574](#)

Pterygoid plate, [536](#)

- medial, [556](#)

Pterygoid plexus of veins, [509](#), [517](#), [559](#), [578](#)

Pterygoid process, [574](#)

Pterygomandibular raphe, [507](#), [531](#), [556](#), [582](#), [584](#)

Pterygomaxillary fissure, [529](#)

Pterygopalatine canal, 536

Pterygopalatine fossa, 529, 536–537, 558

Pterygopalatine ganglion, 513, 537

Pubic crest, 218, 221–223, 296

Pubic ligament, inferior, 231, 260

Pubic ramus

- inferior, 214–216, 218, 222–223, 233, 296–297, 299
- superior, 214–218, 296–297

Pubic region, 135

Pubic symphysis, 4, 6, 134, 139, 214–218, 220–224, 226, 228–231, 297

- anterosuperior margin, 223

Pubic tubercle, 134, 137, 214, 216, 218, 220, 222–223, 228, 234, 296–297, 299

Pubic vessels, 148

Pubis, 6

- body of, 215, 217

Pubocervical ligament, 247

Pubococcygeus, 229–231, 233, 247, 260, 262, 264

Pubofemoral ligament, 301

Puboprostatic ligament, 234, 247

Puborectalis, 229, 231, 233, 260, 262, 264

Pubovesical ligament, 235

Pudendal artery, 266

- external
  - deep, 240, 301, 314
  - superficial, 142–143, 301
- internal, 248, 253, 266, 268, 301, 305
- left, 247



- right, 252
- Pudendal canal, 233
- Pudendal nerve, 248, 254–256, 267, 269, 276, 304
- Pudendal vein, 266
  - external, 366
  - internal, 184, 249, 253, 266, 268
    - left, 247
    - right, 252
  - superficial external, 142, 240
- Pulmonary artery(ies), 82–83, 98–99
  - left, 88–89, 94–95, 109–110
  - right, 88, 94–95
    - branches of, 101, 109–110
- Pulmonary ligament, 80, 82–83
- Pulmonary plexus, 88
  - posterior, 88
- Pulmonary trunk, 63, 74, 89
- Pulmonary valve, 97, 101
- Pulmonary vein(s), 82–83, 88, 98–99, 109
  - left, 88, 94–95, 101, 109–110
  - right, 93–95, 101, 110, 114
- Pulmonary vessels, 88
  - imaging, 89–90
- Pulp cavity, 577
- Pupil, 510
- Pyloric antrum, 160, 164
  - in coronal section of abdomen, 158

Pyloric canal, [160](#)

Pyloric orifice, [160](#), [179](#)

Pyloric sphincter, [171](#)

Pylorus, [160](#), [171](#)

Pyramid, [501](#)

Pyramidal eminence, [523](#)

Pyramidalis, [140](#), [149](#), [151](#)

Pyramid in renal medulla, [190](#)

## Q

Quadrangular membrane, [561](#)

Quadrangular space, [416](#)

Quadrangle lobe, of liver, [175](#)

Quadratus femoris, [9](#), [303–304](#), [307](#), [315](#)

Quadratus lumborum, [41–42](#), [137](#), [185–188](#), [194](#)

Quadratus plantae, [360](#), [362](#)

Quadriceps femoris, [307](#), [310](#), [345](#)

Quadriceps femoris tendon, [322](#), [346](#)

## R

Radial artery, [10](#), [412](#), [426](#), [436](#), [439](#), [458](#)

Radial collateral artery, [403–404](#), [412](#), [416](#), [436](#)

Radial collateral ligament, [424](#)

Radial fossa, [408](#)

Radial groove, [391](#)

Radialis indicis artery, [450–452](#), [458](#)

Radial nerve, [13](#), [397](#), [402](#), [407](#), [412](#), [416](#), [426](#), [439](#)

Radial notch, [408](#), [422](#), [427](#)

Radial recurrent artery, [412](#), [416](#), [436](#)

Radial recurrent vein, [413](#)

Radial styloid process, [427](#)

Radial tuberosity, [422](#), [427](#)

Radial vein, [11](#)

Radiate ligament, [66](#)

Radicular artery

- anterior, [46](#)
- posterior, [46](#)
- Radicular vein
  - anterior, [47](#)
  - posterior, [47](#)
- Radiocarpal ligament, [431](#)
- Radio-ulnar joint, [422](#), [427](#)
- Radio-ulnar ligament, [431](#)
- Radius, [6–7](#), [387](#), [427](#), [435](#)
  - borders of, [427](#)
  - head of, [7](#), [422](#), [427](#)
  - neck of, [427](#)
  - proximal end, [408](#)
- Rami communicantes, [32](#), [45](#)
- Ramus of ischium, [214–218](#), [222](#)
- Ramus of mandible, [480](#), [482](#), [574](#)
- Rectal artery
  - inferior, [248](#), [252–253](#), [268](#)
  - middle, [194](#), [248](#), [250](#), [253](#)
  - superior, [159](#), [172](#), [192](#), [250](#), [253](#)
- Rectal fascia, [233](#)
- Rectal nerve, inferior, [267](#), [269](#)
  - cutaneous branches, [273](#)
- Rectal neurovascular bundle, [253](#)
- Rectal vein
  - inferior, [249](#), [252–253](#), [268](#)
  - middle, [184](#), [249–250](#), [252–253](#)

superior, [183](#), [250](#), [253](#)

Rectal venous plexus

external, [233](#), [253](#)

internal, [233](#), [253](#)

perimuscular, [253](#)

Rectal vessels, superior, [188](#)

Recto-uterine pouch, [226](#), [245](#), [247](#)

Rectovaginal septum, [247](#)

Rectovesical pouch, [224](#)

Rectovesical septum, [247](#)

Rectum, [147](#), [159](#), [168](#), [171](#), [224](#), [233](#)

circular muscle of, [233](#)

coronal section, [233](#)

inferior transverse fold, [233](#)

in situ, [232](#)

longitudinal muscle, [233](#)

middle transverse fold of, [233](#)

mucosa of, [233](#)

positioning of, [233](#)

in sagittal plane, [3](#)

surface projection, female, [233](#)

venous drainage of, [253](#)

Rectus

inferior, [511](#), [514](#), [516](#)

lateral, [511](#), [514](#), [516](#)

medial, [511](#), [514](#), [516](#)

superior, [511](#), [514](#), [516](#)

Rectus abdominis, 8, 136–137, 140–142, 149, 151  
    position of tendinous intersection, 134

Rectus capitis anterior, 543

Rectus capitis lateralis, 543

Rectus capitis posterior major, 41, 43

Rectus capitis posterior minor, 41, 43

Rectus femoris, 8, 302, 307–308, 310, 312, 318

Rectus sheath, 8  
    anterior wall, 136, 141  
    organization of, 141  
    posterior wall, 136–137, 141, 153

Referred pain diagram, abdominal, 204–205

Regional vertebrae, 22

Renal artery  
    left, 10, 192, 194, 270  
    right, 192, 194

Renal column, 190

Renal cortex, 190

Renal impression  
    on liver, 175  
    on spleen, 161

Renal medulla, 190

Renal papilla, 190

Renal pelvis, 188, 190

Renal sinus, 190

Renal vasculature, 192–193

Renal vein(s), 195

left, [147](#), [192](#)

right, [192](#)

Reproductive system

female, [243–246](#)

innervation, [275](#)

male, [236–242](#)

innervation, [274](#)

Rete testes, [241](#)

Reticular fiber, [12](#)

Retina, [511](#), [518](#)

Retinal artery, central, [517](#)

Retromandibular vein, [508–509](#), [535](#), [541](#), [559](#), [578](#)

Retromolar fossa, [574](#)

Retromolar triangle, [574](#)

Retropharyngeal space, [540](#)

Retropubic space, [224](#)

Rhomboid major, [9](#), [36–38](#), [52](#), [400](#), [414](#)

Rhomboid minor, [9](#), [36–38](#), [400](#)

Rib(s)

I, [6](#), [63–65](#)

II, [64–65](#)

III, [64](#)

IV, [64](#)

V, [64–65](#)

VI, [64](#)

VII, [64](#)

VIII, [64](#)

IX, [64](#)

X, [64](#)

XI, [63–64](#), [73](#), [188](#)

XII, [63–65](#), [73](#), [187–188](#)

anatomy of, [65](#)

articulations of, [66–67](#)

demifacets for articulation of, [22](#)

false, [64](#)

floating, [64](#)

head of, [65](#)

neck of, [65](#)

placement of, [63](#)

true, [64](#)

Rima glottidis, [562](#)

Rima vestibuli, [562](#)

Risorius, [506–507](#), [542](#)

Root canal, [577](#)

Rotator cuff muscles, [400–401](#)

Rotatores thoracis, [41](#)

Round window, [523–524](#), [526](#)

## S

Saccule, [526](#), [563](#)

Sacral artery(ies)

lateral, [46](#), [194](#), [248](#), [250](#)

median, [186](#), [194](#), [248](#), [253](#)

Sacral canal, [218](#), [222](#), [230](#), [296](#)



Sacral cornua, [31](#), [217](#), [296](#)

Sacral crest

lateral, [31](#)

median, [31](#)

Sacral curvature, [21](#)

Sacral dimple, at posterior iliac spine, [5](#), [20](#), [217](#)

Sacral foramina, [31](#)

anterior, [216](#), [297](#)

posterior, [215](#), [217](#), [228](#), [296–297](#)

Sacral ganglia, [202](#)

Sacral hiatus, [215](#), [217](#), [296–297](#)

Sacral meninges, [48](#)

Sacral nerve(s), [34](#), [44](#), [198](#)

Sacral node

lateral, [270–272](#)

median, [272](#)

middle, [270](#)

Sacral plexus, [13](#), [254](#)

Sacral promontory, [3](#), [223](#)

Sacral vein

lateral, [249–250](#)

median, [195](#), [249](#), [253](#)

Sacrococcygeal ligaments, [220–221](#), [230](#)

Sacro-iliac joint, [6](#), [31](#), [216](#), [221–223](#), [229](#), [296–297](#)

Sacro-iliac ligament

anterior, [220–221](#)

interosseous, [221](#)

- posterior, [220–221](#), [228](#)
- Sacrospinous ligament, [220–221](#), [228](#), [230](#), [303](#), [305](#)
- Sacrospinous ligament, [221–222](#), [228](#), [230–231](#), [260–262](#), [264](#), [303](#), [305](#)
- Sacrotuberous ligament, [221–222](#), [228](#), [230–231](#), [260–262](#), [264](#), [303](#), [305](#)
- Sacrum, [6–7](#), [21–22](#), [31](#), [214–218](#), [220](#), [222–223](#), [228–230](#), [295–296](#)
  - ala of, [214](#), [222–223](#), [229](#), [297](#)
  - articular surface of, [221](#)
- Sagittal axis, [2](#)
- Sagittal plane, [2–3](#)
- Sagittal sinus, [495](#)
- Sagittal suture, [484–485](#)
- Salivary glands, [580](#)
- Salpingopharyngeal fold, [554–555](#)
- Salpingopharyngeus, [556–557](#), [583](#)
- Saphenous hiatus, [366–367](#)
- Saphenous nerve, [13](#), [312–313](#), [348](#), [356](#)
  - from femoral nerve, [199](#)
- Saphenous vein
  - accessory, [366](#)
  - great, [11](#), [270–271](#), [312](#), [318](#), [366](#)
  - small, [11](#), [366](#)
- Sartorius, [8](#), [294](#), [302](#), [307–310](#), [312](#), [318](#), [342](#), [346](#)
  - nerve to, [313](#)
- Sartorius tendon, [310](#)
- Scala tympani, [526](#)
- Scala vestibuli, [526](#)
- Scalene(s), [8](#), [540](#)
  - anterior, [396](#), [542–543](#)

middle, 396–397, 543

posterior, 396, 542–543

Scalp, 492

Scaphoid, 428, 430, 458

Scaphoid fossa, 486, 574

Scapula, 6–7, 387–388

acromion of, 5–6, 20, 36, 39

anterior view, 389

in axial plane, 3, 70

inferior angle of, 5, 7, 20, 36–37, 63, 389

lateral border of, 389

lateral view, 389

medial border of, 5, 389

muscles of, 400–401

spine of, 5, 20, 36–38, 387

superior angle of, 7, 36, 63, 389

in transverse section of thoracic vertebral column, 52

Scapular artery

circumflex, 403–404, 412, 416

dorsal, 37, 402, 550

Scapular ligament, 388, 402

Scapular nerve, dorsal, 37–38, 405–407

Scarpa's layer, 136–137, 240

Sciatic foramen

greater, 220–221, 228, 255, 303

lesser, 220–221, 228

Sciatic nerve, 13, 254, 304–305, 316–318

- muscular branch, [316–317](#)
- Sciatic notch
  - greater, [215, 217, 296](#)
  - lesser, [218](#)
- Sclera, [510–511, 518](#)
- Scleral venous sinus, [518](#)
- Scrotal artery, posterior, [252, 266, 268](#)
- Scrotal nerve, posterior, [267](#)
- Scrotal raphe, [259](#)
- Scrotal vein, posterior, [252, 266, 268](#)
- Scrotum, [4, 214, 240](#)
  - septum of, [240](#)
  - skin of, [240](#)
- Secretory lobules, of mammary gland, [68](#)
- Segmental muscles, [41](#)
- Semicircular canal
  - anterior, [522–523, 526](#)
  - lateral, [522–523, 526](#)
  - posterior, [522–523, 526](#)
- Semilunar cusp, [97, 100](#)
- Semilunar line, [134](#)
- Semimembranosus, [302, 307, 309, 315–316, 318, 342](#)
- Semimembranosus bursa, [328](#)
- Semimembranosus tendon, [315, 322](#)
- Seminal colliculus, [237–238](#)
- Seminal vesicle, [236, 238–239, 242](#)
  - imaging, [238](#)

- positioning, [237](#)
- Seminiferous tubule, [241](#)
- Semispinalis capitis, [9](#), [39–40](#), [43](#)
- Semispinalis cervicis, [43](#)
- Semispinalis thoracis, [41](#)
- Semitendinosus, [9](#), [302–303](#), [309](#), [315–316](#), [318](#), [342](#)
- Semitendinosus tendon, [315](#)
- Septal cartilage, [568–569](#)
- Septomarginal trabecula, [97](#), [105](#)
- Septum pellucidum, [497](#)
- Serous pericardium, [93](#)
  - visceral layer of, [124](#)
- Serratus anterior, [8](#), [38–39](#), [52](#), [70–71](#), [138](#), [398](#), [400](#)
  - in axial plane, [70](#)
- Serratus posterior inferior, [39](#), [71](#)
- Serratus posterior superior, [39](#), [71](#)
- Sesamoids, [333–334](#), [361](#), [430](#)
- Shoulder
  - bones, [388](#)
  - muscle attachments, [409](#)
  - vessels and nerves, [402](#)
- Shoulder joint, [7](#), [387–388](#)
- Sigmoid arteries, [159](#), [172](#)
- Sigmoid colon, [147](#), [159](#), [168](#), [224](#), [226](#), [232](#)
  - in coronal section of abdomen, [158](#)
  - in transverse plane, [3](#)
- Sigmoid sinus, [495](#)

Sigmoid vein, [183](#)

Sinu-atrial node, [105](#)

SI vertebra, body of, [221](#)

Skeleton

anterior view of, [6](#)

cardiac, [100](#)

posterior view of, [7](#)

Skull

anterior view, [480–481](#)

arteries, [494](#)

bones, [479](#)

cavity, [487](#)

imaging, [481](#), [483](#)

inferior view, [486](#)

lateral view, [482–483](#)

muscle attachments, [490–491](#)

posterior view, [484](#)

roof, [485](#)

superior view, [485](#)

venous sinuses, [495](#)

Small intestine, [154–155](#), [166](#)

in coronal plane, [3](#)

lymph nodes in, [12](#)

in sagittal plane, [3](#)

S1 nerve, [53](#)

S3 nerve, [53](#)

Soft palate, [554–555](#), [570](#), [583](#)

Soleal line, [295](#)

Soleus, [8–9](#), [343](#), [345–346](#)

Somatic afferents, [127](#)

Somatic sensory fiber, [127](#)

Spermatic cord, [138–139](#), [147–148](#), [236](#)  
    positioning, [241](#)

Spermatic fascia  
    external, [149](#), [240](#)  
    internal, [149](#)

Spheno-ethmoidal recess, [570](#)

Sphenoidal sinus, [500](#), [554](#), [568–570](#)

Sphenoid bone, [479](#), [486–487](#), [529](#), [536](#), [574](#)

Sphenomandibular ligament, [530–531](#)

Sphenopalatine artery, [535](#), [537](#), [571](#)

Sphenopalatine foramen, [536](#), [569](#), [571](#)

Sphenopalatine vein, [535](#), [571](#)

Sphenoparietal sinus, [495](#)

Sphenoparietal suture, [482](#)

Sphenosquamous suture, [482](#)

Sphincter pupillae, [518](#)

Sphincter urethrovaginalis, [235](#), [261](#)

Spinal artery  
    anterior, [46](#), [49](#), [504](#)  
    posterior, [46](#), [49](#), [501](#), [504](#)  
        left, [46](#)  
        right, [46](#)  
    segmental, [46](#)

Spinal cord, [23](#), [26](#), [32](#), [45](#)  
    cervical enlargement of, [45](#), [50](#)  
    in cranium, [500](#)  
    features of, [45](#)  
    imaging of, [50–51](#)  
    lumbosacral enlargement of, [45](#)  
    segmental supply of, [46](#)  
    vasculature of, [46](#)  
    venous drainage of, [47](#)

Spinal ganglion, [127](#)

Spinalis, [40](#)

Spinalis cervicis, [43](#)

Spinalis thoracis, [40](#)

Spinal joints and ligaments, [35–36](#)

Spinal nerves, [34](#), [44–45](#), [76](#)  
    anterior rami of, [254](#)  
    meningeal branches, [49](#)

Spinal vein  
    anterior, [47](#)  
    posterior, [47](#)

Spiral ganglion, [526](#)

Spiral ligament, [526](#)

Spiral organ, [526](#)

Spiral valve, [180](#)

Splanchnic nerve(s), [114](#), [202](#)  
    greater, [116](#), [119](#), [187](#), [201–203](#)  
    least, [119](#), [201–202](#), [276](#)



- lesser, [119](#), [187](#), [201–202](#), [276](#)
- lumbar, [201–203](#), [276](#)
- pelvic, [201–203](#), [254–256](#), [274](#), [276](#)
- sacral, [202–203](#), [255–256](#), [276](#)
- thoracic, [202](#)

Spleen, [155](#), [159](#), [162](#), [188](#)

- in abdominal cavity, [161](#)
- arteries of, [162–163](#)
- in coronal section of abdomen, [158](#)
- hilum of, [161](#)
- imaging of, [161](#)
- location of, [161](#)
- surface projection of, [161](#)
- surfaces of, [161](#)

Splenic artery, [10](#), [159](#), [161–162](#), [181](#)

Splenic vein, [11](#), [161](#), [181–183](#)

Splenic vessels, [181](#)

Splenius capitis, [9](#), [36–40](#), [43](#), [71](#), [542](#)

Splenius cervicis, [9](#), [39–40](#), [71](#)

Splenorenal ligament, [161](#)

Squamous suture, [482](#)

Stapedius muscle nerve, [524](#)

Stapedius tendon, [524](#)

Stapes, [523–524](#)

Sternal angle, [62](#)

Sternal notch, [4](#)

Sternoclavicular joint, [62](#), [388](#), [390](#)

Sternocleidomastoid, [4](#), [8–9](#), [43](#), [506](#), [540](#), [542–543](#)

Sternocostal joint, [64](#), [66–67](#)

Sternocostal ligaments, [67](#)

Sternohyoid, [542–543](#)

Sternothyroid, [543](#)

Sternum, [64](#)

- in axial plane, [70](#)
- body of, [6](#), [62](#), [72](#)
- manubrium of, [3](#), [6](#), [62](#), [64](#), [72](#), [388](#), [540](#)

Stomach, [154](#), [162](#), [188](#)

- arteries of, [162–163](#)
- body of, [160](#), [171](#)
- in coronal plane, [3](#)
- in coronal section of abdomen, [158](#)
- external features, [160](#)
- fundus of, [171](#)
- imaging, [160](#)
- internal features, [160](#)
- positioning of, [160](#)
- surface projection of, [160](#)

Straight sinus, [495](#)

Striate artery, middle, [502](#)

Styloglossus, [531](#), [556](#), [581](#)

Stylohyoid, [542–543](#)

Stylohyoid ligament, [539](#), [556–557](#), [580](#)

Styloid process, [482](#), [486](#), [525](#), [529](#), [531](#), [542](#), [556–557](#)

- radial, [427](#)

Stylomandibular ligament, 530–531

Stylomastoid foramen, 486, 524

Stylopharyngeus, 556–557, 580, 583

Subarachnoid space, 48

Subclavian artery, 46, 70, 404, 548

- left, 10, 74, 83, 88, 101, 109–110, 113, 502, 550–551, 566
  - in axial plane, 3
- right, 10, 74, 82, 88, 101, 109–110, 397, 502, 550, 566–567

Subclavian groove, 390

Subclavian nerve, 405

Subclavian trunk, 77, 553

Subclavian vein, 413

- left, 11, 75, 101, 110, 541, 559
- right, 11–12, 77, 82, 101, 109–110, 567

Subclavicular nodes, 552

Subclavius, 70–71, 116, 397

Subcostal artery, 143, 194

Subcostal muscles, 72

Subcostal nerve, T12, 76, 144

- anterior cutaneous branch of, 125, 145
- lateral cutaneous branch of, 125, 144

Subcostal plane, 135

Subcostal vein, left, 75

Subepicardial fat, 93

Sublingual caruncle, 584

Sublingual fold, 584

Sublingual gland, 534, 580, 582, 584

Sublingular fossa, [574](#)

Submandibular duct, [580](#), [582](#), [584](#)

Submandibular fossa, [574](#)

Submandibular ganglion, [534](#), [581](#)

Submandibular gland, [534](#)

Submandibular nodes, [12](#), [508](#), [552–553](#), [582](#)

Submental nodes, [508](#), [552–553](#)

Submental vein, [541](#)

Subparotid node, [552](#)

Subphrenic recess, [156](#)

Subpopliteal recess, [328](#)

Subpubic angle

- female, [216](#)
- male, [214](#)

Subscapular artery, [403–404](#), [412](#)

Subscapular fossa, [389](#)

Subscapularis, [52](#), [400–401](#)

Subscapular nerve, [405](#), [407](#)

Subscapular nodes, [417](#)

Subtalar joint, [335](#)

Subtendinous bursa, [328](#)

Sulcus terminalis, [94–95](#)

Superciliary notch, [480](#)

Superficial temporal artery, [10](#)

Superior, as anatomical direction, [2](#)

Superolateral nodes, [367](#)

Superomedial nodes, [367](#)

Supinator, 8–9, 426, 434, 438

Supinator crest, 408

Supraclavicular nerve(s), 420, 544, 546–547

- intermediate, 125
- lateral, 125
- medial, 125

Supracondylar line

- lateral, 306
- medial, 306

Supracondylar ridge, 408

Supraduodenal artery, 159, 162, 165, 181

Supraglenoid tubercle, 389

Supramandibular triangle, 538

Supramarginal gyrus, 496

Supramastoid crest of temporal bone, 528

Supra-orbital artery, 508, 512, 517

Supra-orbital foramen, 482

Supra-orbital nerve, 505, 512–513, 515, 537

Supra-orbital notch, 480, 510

Supra-orbital vein, 508, 512, 517

Suprapatellar bursa, 328

Suprapatellar fat, 328

Suprarenal artery

- inferior
  - left, 192
  - right, 192, 194
- middle, 186

- left, [192](#)
- right, [194](#)
- superior
  - left, [192](#), [194](#)
  - right, [192](#), [194](#)
- Suprarenal gland, [162](#)
  - left, [186](#), [188](#), [192](#), [195](#)
  - right, [186](#), [188](#), [192](#), [194](#)
- Suprarenal impression, on liver, [175](#)
- Suprarenal vein(s)
  - left, [192](#), [195](#)
  - right, [192](#), [195](#)
- Suprascapular artery, [402](#), [404](#), [416](#), [548](#), [550–551](#), [566–567](#)
- Suprascapularis, [397](#)
- Suprascapular nerve, [402](#), [405](#)
- Suprascapular notch, [388–389](#)
- Supraspinatus muscle, [9](#), [38–39](#), [397](#), [400](#)
- Supraspinous fossa, [388–389](#)
- Supraspinous ligament, [35](#), [220](#)
- Suprasternal space, [540](#)
- Supratrochlear artery, [508](#), [512](#), [517](#)
- Supratrochlear nerve, [505](#), [512](#), [515](#)
- Supratrochlear nodes, [417](#), [459](#)
- Supratrochlear vein, [508](#), [512](#), [517](#)
- Sural arteries, [316](#), [344](#)
- Sural nerve, [13](#), [317](#), [344](#), [349](#)
- Surface anatomy

- of abdomen, [134](#)
- of arm, [410](#), [414](#), [433](#), [437](#)
- of back, [20](#), [36](#)
- of body
  - anterior view, [4](#)
  - posterior view, [5](#)
- of ears, [522](#)
- of face, [510](#)
- of foot, [355](#)
- of gluteal region, [302](#)
- of hand, [445](#), [454](#)
- of head, [478](#)
- of knee, [329](#)
- of larynx, [560](#), [565](#)
- of lower limbs, [294](#)
- of mediastinum, [91](#)
- of neck, [478](#), [538](#)
- of pelvis and perineum
  - female, [216–217](#), [258–259](#)
  - male, [214–215](#), [257](#), [259](#)
- of superior mediastinum, [108](#)
- of thorax, [62](#)
- of upper limbs, [386](#)

Suspensory ligament

- of clitoris, [264](#)
- of eye, [511](#)
- of ovary, [226](#), [244](#)

- of penis, [68](#), [224](#), [242](#), [262](#)
- Sustentaculum tali, [332–333](#), [338](#)
- Sutural bone, [484](#)
- Sympathetic cardiac nerves, [126](#)
- Sympathetic ganglia, [32](#), [201](#)
  - cervical, [126](#), [405](#)
  - fifth thoracic, [88](#)
  - third thoracic, [107](#)
- Sympathetic nerves, [14](#)
- Sympathetic trunk, [78](#), [119](#), [546–547](#)
  - left, [107](#), [256](#)
  - left lumbar, [255](#)
  - right, [88](#), [107](#), [256](#)
- Synovial membrane
  - in lower limbs, [299–300](#)
  - in upper limbs, [392](#), [424](#)
- Synovial sheaths, in hand, [446](#)

## T

- Taenia, free, [170](#)
- Taenia coli, [166](#), [168](#)
- Talocalcaneal ligament, [338–339](#), [354](#)
- Talocalcaneonavicular joint, [335](#)
- Talofibular ligament, [338–339](#)
  - anterior, [354](#)
- Talonavicular ligament, [338](#), [354](#)
- Talus, [6](#), [332–334](#), [336](#)



Tarsal artery

lateral, [348](#)

medial, [348](#)

Tarsal bones, [6](#)

Tarsal gland, [511](#)

Tarsal muscle, superior, [511](#)

Tarsal sinus, [333](#)

Tarsal tunnel, [365](#)

Tarsometatarsal joints, [335](#)

Tarsometatarsal ligaments, [354](#)

Tarsus

inferior, [511–512](#), [514](#)

superior, [511–512](#)

Tectorial membrane, [526](#)

Teeth, [575](#)

anatomy, [577](#)

crown of, [577](#)

imaging, [576–577](#)

neck of, [577](#)

nerves, [578–579](#)

root of, [577](#)

vasculature, [578](#)

Tegmen tympani, [487](#), [525](#)

Temporal artery

deep, [535](#)

middle, [535](#)

superficial, [502](#), [508–509](#), [512](#), [535](#), [548](#), [578](#)

Temporal bone(s), [479](#), [482](#), [487](#), [529](#), [574](#)  
    mastoid process of, [43](#)

Temporal fossae, [528](#), [530–531](#)  
    arteries, [535](#)  
    nerves, [534](#)  
    veins, [535](#)

Temporal gyri, [496](#)

Temporalis, [8](#), [506](#), [528](#), [530](#)

Temporal line  
    inferior, [528](#)  
    superior, [528](#)

Temporal lobe, [497](#)

Temporal nerves, deep, [533–534](#)

Temporal sulcus, superior, [496](#)

Temporal vein  
    deep, [535](#)  
    superficial, [11](#), [508–509](#), [512](#), [535](#), [541](#), [559](#), [578](#)

Temporomandibular joint, [530–532](#)

Tendinous arch, of levator ani, [229–230](#), [233](#)

Tendinous intersection, [140](#)

Tensor fasciae latae, [8](#), [294](#), [302–304](#), [307–309](#), [318](#)

Tensor tympani muscle, [524](#)

Tensor tympani tendon, [523](#), [525](#)

Tensor veli palatini, [530–531](#), [556](#), [583](#)

Tentorium cerebelli, [494](#), [500](#)

Teres major, [9](#), [37–39](#), [52](#), [400–401](#), [414–415](#)

Teres minor, [9](#), [38–39](#), [400–401](#), [414](#)

Testes, [20](#), [147](#), [241](#)

appendix of, [240](#)

lobules of, [240](#)

Testicular artery, [10](#), [148](#), [164](#), [240–241](#)

right, [147](#), [194](#)

Testicular plexus, [201](#)

Testicular vein(s), [11](#), [148](#), [164](#), [195](#)

Thalamus, [497](#), [501](#)

Thenar eminence, [386](#), [445](#), [448](#)

Thenar muscles, [8](#), [436](#), [442](#)

Thigh

arteries, [313–314](#), [316](#)

bones of, [295](#)

compartments of, [308–309](#)

deep artery of, [301](#), [314](#), [318](#)

deep vein of, [11](#), [318](#)

lateral cutaneous nerve of, [198–199](#)

muscle attachments, [307](#), [310–311](#), [315](#)

musculature, [308–311](#), [315](#)

nerves, [313](#), [316](#)

transverse section, [318–319](#)

Thoracic aorta, [10](#), [74](#), [82](#), [88–89](#), [101](#), [107](#)

Thoracic aperture

inferior, [63](#)

superior, [63](#)

Thoracic artery

internal, [10](#), [69](#), [74](#), [92](#), [143](#), [548](#), [550–551](#)

- mammary branches of, 69
- lateral, 69–70, 403–404, 412
- superior, 403–404, 412

Thoracic cavity, 79

- left, 116–117
- right, 114–115

Thoracic curvature, 21

Thoracic duct, 12, 77, 124, 187, 553

Thoracic ganglia, 202

Thoracic meninges, 48–49

Thoracic nerves, 44, 397, 405, 547

Thoracic vein(s)

- internal, 75, 109
- lateral, 142

Thoracic vertebrae, 21–22, 26–27, 74

Thoracic visceral plexus, 14

Thoracic wall, 72

- anterior, 71
- arteries of, 74
- lateral, 71
- lymphatics of, 77
- posterior, 71
- veins, 75

Thoraco-acromial artery, 70, 403, 412

- acromial branch, 397, 404
- clavicular branch, 397, 404
- deltoid branch, 397, 404

- pectoral branch of, [69](#), [404](#)
- Thoracodorsal artery, [403–404](#)
- Thoracodorsal nerve, [407](#)
- Thoracoepigastric vein, [142](#)
- Thoracolumbar fascia, [37](#), [39](#), [42](#)
- Thorax
  - bony framework of, [63–64](#)
  - dermatomes and cutaneous nerves of, [125](#)
  - surface anatomy, [62](#)
  - transverse section, [124](#)
- Thymus gland, [12](#), [108](#)
- Thyro-arytenoid, [563](#)
- Thyrocervical trunk, [548](#), [550–551](#), [566](#)
- Thyro-epiglottic, [563](#)
- Thyro-epiglottic ligament, [561](#)
- Thyrohyoid, [542–543](#)
- Thyrohyoid ligament, [560](#), [563](#)
- Thyrohyoid membrane, [556](#), [560](#), [562–563](#), [565](#)
- Thyroid artery
  - inferior, [548](#), [550–551](#), [566–567](#)
  - superior, [502](#), [548](#), [566–567](#)
- Thyroid cartilage, [554](#), [556](#), [560–561](#), [563](#), [565](#)
  - inferior horn of, [86](#)
  - left lamina of, [86](#)
  - superior horn of, [86](#)
- Thyroid gland, [553–554](#), [565](#)
  - isthmus of, [565](#)

- left lobe, 565, 567
- right lobe, 565
- vasculature, 566

Thyroid notch, 538, 560, 565

- superior, 86

Thyroid prominence, 538, 560, 565

Thyroid tubercle, 560

Thyroid vein(s)

- inferior, 109, 566
- middle, 566
- superior, 566

Tibia, 4, 6–7, 294, 331

- proximal end, 306

Tibial artery

- anterior, 10, 313–314, 316–317, 329, 344, 348, 356–357
- posterior, 10, 313–314, 329, 344, 357, 364

Tibial collateral ligament, 310, 322

Tibialis anterior, 8, 302, 345–347

Tibialis anterior tendon, 353

Tibialis posterior, 343

Tibialis posterior tendon, 353–354

Tibial nerve, 13, 316–317, 344, 363–364

Tibial recurrent artery, anterior, 314

Tibial tuberosity, 4, 6, 294, 306

Tibial vein

- anterior, 11
- posterior, 11

Tibiofibular joint, 320

Tibiofibular ligament, 338–339

T10 nerve, 144

T12 nerve, 76, 144

- lateral cutaneous branch of, 144

Tongue, 534, 554, 581

- apex of, 582
- arteries, 581
- frenulum of, 584
- inferior surface, 584
- root of, 555, 557
- veins, 581

Tonsils, 12, 554–555, 570, 582–584

Torus levatorius, 554

Torus tubularis, 554–555, 570

Trabecula, 12

Trabeculae carneae, 97, 99

Trachea, 79, 88, 110, 554–555

- in axial plane, 3
- bifurcation of, 113
- positioning of, 63
- in superior mediastinum, 112

Tracheal bifurcation, 86

Tracheal cartilages, 86

Tracheal mucosa, 86

Tracheal nodes, 12, 77

Tracheobronchial nodes, 114

Tragus, [522](#)

Transversalis fascia, [42](#), [136–137](#), [140–142](#), [148](#)

Transverse colon, [155](#), [159](#), [165](#)

- in coronal plane, [3](#)
- in coronal section of abdomen, [158](#)

Transverse fasciculi, [358](#)

Transverse plane, [2](#)

Transverse ridges, of sacrum, [296](#)

Transverse sinus, [495](#)

Transversospinales muscles, [41–42](#)

Transversus abdominis, [8](#), [40](#), [42](#), [136–137](#), [141–142](#), [148](#), [185](#)

- aponeurosis of, [137](#), [139](#)

Transversus thoracis muscles, [72](#)

Trapezium, [428](#), [430](#), [442](#)

Trapezius, [5](#), [8–9](#), [36–37](#), [396–397](#), [410](#), [414](#), [506](#)

Trapezoid, [428](#), [430](#), [442](#)

Trapezoid line, [390](#)

Triangle, lumbar, [37](#)

Triangle of auscultation, [36–37](#)

Triangular interval, [401](#), [416](#)

Triangular ligament, right, [174–175](#)

Triceps brachii, [9](#), [396](#), [400–401](#), [410](#), [414–415](#), [433–434](#), [437](#)

Tricuspid valve, [96–97](#), [100–101](#)

- auscultation point for, [106](#)

Trigeminal ganglion, [500–501](#), [537](#)

Trigeminal impression, [487](#)

Trigeminal nerve, [13](#), [500–501](#), [513](#), [519](#), [534](#), [537](#), [586](#)



- cutaneous distribution, 505
- mandibular division, 533
- Trigone, 232, 234–235, 237, 242
- Triquetrum, 428, 430, 442
- Triticeal cartilage, 560
- Trochanter
  - greater, 6–7, 228, 294–295, 297–298, 300–301, 303, 310
  - lesser, 6–7, 228, 295, 297–298, 300–301, 303
- Trochanteric fossa, 298
- Trochlea, 6, 408, 514
- Trochlear nerve, 500–501, 515, 586
- Trochlear notch, 408
- True ribs, 64
- Tuberculum sellae, 487, 536
- Tunica albuginea, 241–242, 244
- Tunica vaginalis, 236, 240–241
  - parietal layer of, 149, 151
  - visceral layer of, 149, 151
- TI vertebra, 21, 26, 63, 539
  - spinous process of, 5
- TII vertebra, 64
- TIII vertebra, 26–27
- TV vertebra, 22
- TIX vertebra, 26
- TXII vertebra, 21, 26–27, 63–64
  - spinous process of, 5, 20, 63
- Tympanic membrane, 523, 526

Tympanic nerve, [524](#)  
Tympanic plate, [529](#)  
Tympanic plexus, [524](#), [534](#)  
Tympanomastoid fissure, [529](#)

## U

Ulna, [6–7](#), [387](#), [427](#)  
    proximal end, [408](#)  
    tuberosity of, [422](#)  
Ulnar artery, [10](#), [412](#), [426](#), [436](#), [439](#)  
Ulnar collateral artery, [403–404](#), [412](#), [416](#), [439](#)  
Ulnar collateral ligament, [431](#)  
Ulnar collateral vein, [413](#)  
Ulnar nerve, [13](#), [397](#), [405–407](#), [412](#), [426](#), [436](#), [439](#), [453](#)  
Ulnar notch, [427](#)  
Ulnar recurrent artery, [412](#), [416](#), [436](#), [439](#)  
Ulnar vein, [11](#)  
Ulnocarpal ligament, [431](#)  
Umbilical artery, [248](#), [250](#), [253](#)  
Umbilical fold  
    lateral, [149](#)  
    left, [153](#)  
    left bilateral, [141](#)  
    medial, right, [153](#)  
    median, [153](#)  
Umbilical ligament  
    medial, [149](#), [151](#)

- median, [141](#), [149](#), [151](#)
  - right, [141](#)
- Umbilical region, [135](#)
- Umbilicus, [4](#), [134](#)
- Umbo, [523](#)
- Uncinate process, [24](#), [178](#), [569](#)
- Uncovertebral joint, [24](#)
- Uncus, [496–497](#)
- Urachus, [151](#), [224](#), [226](#), [232](#), [234](#)
- Ureter(s), [226](#)
  - left, [147](#), [162](#), [164](#), [186](#), [234–235](#), [239](#)
    - retroperitoneal, [188](#)
  - right, [162](#), [234–235](#), [239](#)
    - retroperitoneal, [188](#)
  - surface projection of, [188](#)
  - visceral sensory diagram, [206–207](#)
- Ureteric orifice, [232](#), [234–235](#), [237](#)
- Urethra, [238](#)
  - female, [226](#), [235](#)
  - membranous, [224](#), [237](#)
  - penile, [238](#)
  - prostatic, [224](#), [234](#), [237](#)
  - in sagittal plane, [3](#)
  - spongy, [224](#), [236](#), [242](#)
- Urethral orifice, external, [20](#)
  - female, [258](#)
  - male, [242](#), [259](#)

## Urethral sphincter

external, [20](#), [226](#), [232](#), [234–235](#), [237–238](#), [261](#)

internal, [232](#)

## Urogenital hiatus, [229–231](#), [260](#)

## Urogenital triangle, [257](#)

## Uterine artery, [250–251](#)

## Uterine tube, [147](#), [150](#), [226](#), [243–244](#)

ampulla of, [244](#)

folds of, [244](#)

infundibulum of, [244](#)

isthmus of, [244](#)

## Uterine vein, [250–251](#)

## Uterosacral ligament, [226](#), [245](#), [247](#)

## Uterus, [147](#), [150](#), [244–245](#)

body of, [226](#), [243](#)

external os, [226](#), [243](#)

fundus of, [244–245](#)

imaging, [246](#)

innervation, [275](#)

internal os, [244](#)

round ligament of, [146–147](#), [150](#), [226](#), [243–245](#)

in sagittal plane, [3](#)

surface projections, [244](#)

vasculature of, [251](#)

## Utricle

auricular, [526](#)

prostatic, [237](#)

Utriculosaccular duct, [526](#)

Uvula, [554–555](#), [557](#), [583](#)

## V

Vagal ganglion, inferior, [127](#), [564](#)

Vagal trunk, [118](#)

    anterior, [201–203](#)

    posterior, [201–203](#)

Vagina, [226](#)

    fornix, posterior, [226](#)

    posterior fornix, [243](#)

    in sagittal plane, [3](#)

Vaginal artery, [248](#), [250–251](#)

Vaginal orifice, [226](#), [235](#), [258](#)

Vaginal wall, [244](#)

Vagus nerve, [587](#)

    cardiac branches of, [110](#)

    carotid body branch, [545](#)

    in cranium, [500–501](#)

    dorsal motor nucleus, [126](#)

    inferior ganglion of, [558](#)

    left, [88](#), [107](#), [110](#), [118](#), [203](#), [564](#)

    parasympathetic cardiac branches, [126](#)

    pharyngeal branch, [545](#)

    in pharynx, [558](#)

    right, [88](#), [107](#), [110](#), [118](#), [203](#), [564](#)

    thoracic cardiac branch of, [107](#)

Vallate papilla, 557, 582

Vallecula, 554, 582

Valve(s)

aortic, 100–101

auscultation point for, 106

of foramen ovale, 98

heart, 101

of inferior vena cava, 96

of lymph node, 12

mitral, 98–99, 101

auscultation point for, 106

pulmonary, 97, 101

tricuspid, 97

auscultation point for, 106

Vasa recta, 167, 172

Vasculature. *See also* Arteries; Vein(s)

Vastus intermedius, 307, 310, 318

Vastus lateralis, 8, 294, 302–303, 307–310, 318, 329, 342, 345–346

Vastus medialis, 8, 294, 307–308, 310, 318, 329, 346

Vein(s). *See also individual veins*

arm, 413, 459

eyes, 517

facial, 508

hands, 459

infratemporal fossae, 535

leg, 366

nasal cavity, 571

neck, 541  
parotid region, 509  
pelvic, 249  
pharynx, 558  
of prostate and penis, 252  
rectal, 253  
teeth, 578  
temporal fossae, 535  
thoracic wall, 75  
thyroid gland, 566  
tongue, 581

#### Vena cava

inferior, 11, 75, 82, 94, 96–99, 101, 162, 188, 195  
    abdominal, imaging, 196  
    imaging, 196  
    valve of, 96  
superior, 11, 63, 74, 82, 89, 94–99, 101, 566

#### Venous arch, dorsal, 294, 366

#### Venous plexus, rectal

external, 233  
internal, 233

#### Venous sinuses, dural, 495

#### Ventricle

left, 63, 93–95, 98–99, 101  
right, 74, 94, 96, 97, 103, 105

#### Vertebra(e). *See also individual vertebrae*

cervical, 21–25

- lumbar, [21–22](#), [27–30](#)
- regional, [22](#)
- thoracic, [21–22](#), [26–27](#), [74](#)

Vertebral artery, [10](#), [43](#), [46](#), [404](#), [501–502](#), [548](#), [550–551](#)

- left, [502](#)
- right, [502](#)

Vertebral canal, [33](#)

Vertebral column, [7](#)

- anterior view, [21](#)
- cervical, [50](#)
- lateral view, [21](#)
- posterior view, [21](#)
- splanchnic nerves and, [202](#)
- upper thoracic, [50](#)

Vertebral foramen, [22](#)

Vertebral plexus, anterior

- external, [47](#)
- internal, [47](#)

Vertebral spinous process, [20](#)

Vertebra prominens, [5](#), [20](#), [23](#)

Vertical axis, [2](#)

Vesical artery

- inferior, [248](#), [250](#)
- superior, [248](#), [250](#)

Vesical fascia, [232](#), [234](#)

Vesical plexus, [249](#), [252](#)

Vesical vein



inferior, [249–250](#), [253](#)  
superior, [247](#), [249–250](#), [253](#)  
Vesico-uterine pouch, [226](#), [247](#)  
Vesicular appendix, [245](#)  
Vestibular, as anatomical direction, [575](#)  
Vestibular aqueduct, [526](#)  
Vestibular fold, [562](#)  
Vestibular gland, greater, [243](#), [264](#)  
    opening of duct, [259](#)  
Vestibular ligament, [561](#)  
Vestibular nerve, [522–523](#), [526](#)  
Vestibule, [526](#)  
Vestibulocochlear nerve, [500–501](#), [522–523](#), [526](#), [587](#)  
Visceral pleura, [79](#), [124](#)  
Vitreous chamber, [518](#)  
Vocal fold, [554](#), [562](#)  
Vocalis, [563](#)  
Vocal ligament, [561](#), [563](#)  
Vocal process of arytenoid, [561](#), [563](#)  
Vomer, [479](#), [486](#), [488](#), [568–569](#), [574](#)  
Vorticose veins, [517](#)

## **W**

White ramus communicans, [78](#), [126](#)  
Wrist crease, [445](#)  
Wrist joint, [7](#), [387](#), [427–429](#)

## X

Xiphisternal joint, [64](#), [67](#)

Xiphoid process, [4](#), [6](#), [62–64](#), [134](#)

## Z

Zona orbicularis, [300–301](#)

Zonular fibers, [518](#)

Zygapophyseal joint, [24](#), [28–29](#), [220–221](#)

capsule of, [35](#)

Zygomatic arch, [528–529](#)

Zygomatic bone, [6](#), [479](#), [482](#), [485](#), [510](#), [529](#), [536](#)

Zygomatic nerve, [537](#)

Zygomaticofacial artery, [508](#)

Zygomaticofacial bone, [482](#)

Zygomaticofacial nerve, [505](#), [533](#), [537](#)

Zygomaticofacial vein, [508](#)

Zygomaticotemporal artery, [508](#)

Zygomaticotemporal nerves, [505](#), [513](#), [533](#), [537](#)

Zygomaticotemporal vein, [508](#)

Zygomatic process of frontal bone, [480](#), [528](#)

Zygomatic process of maxilla, [480](#)

Zygomatic process of temporal bone, [482](#)

Zygomaticus major, [506–507](#)

Zygomaticus minor, [506–507](#)